

# Poranění hrudníku

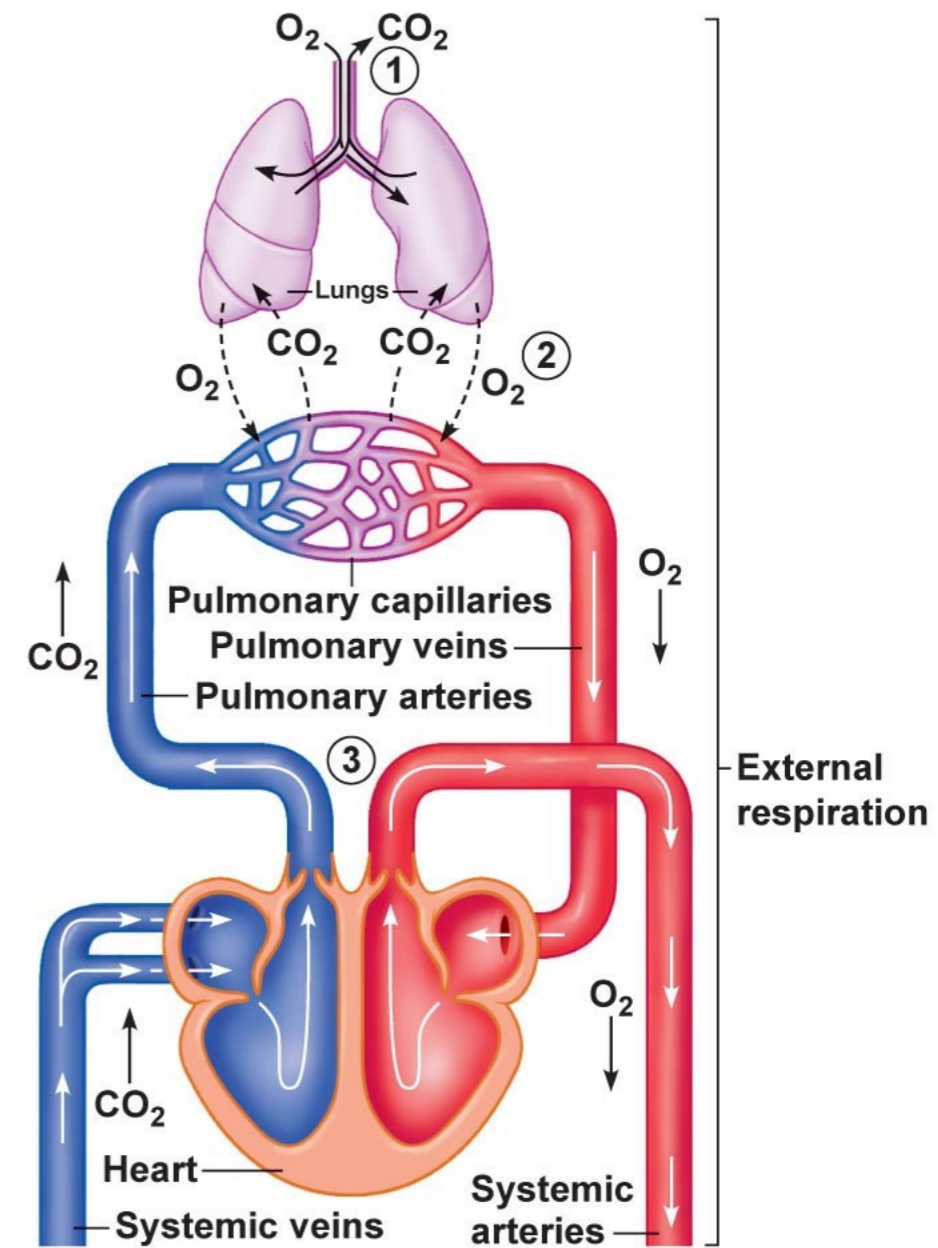
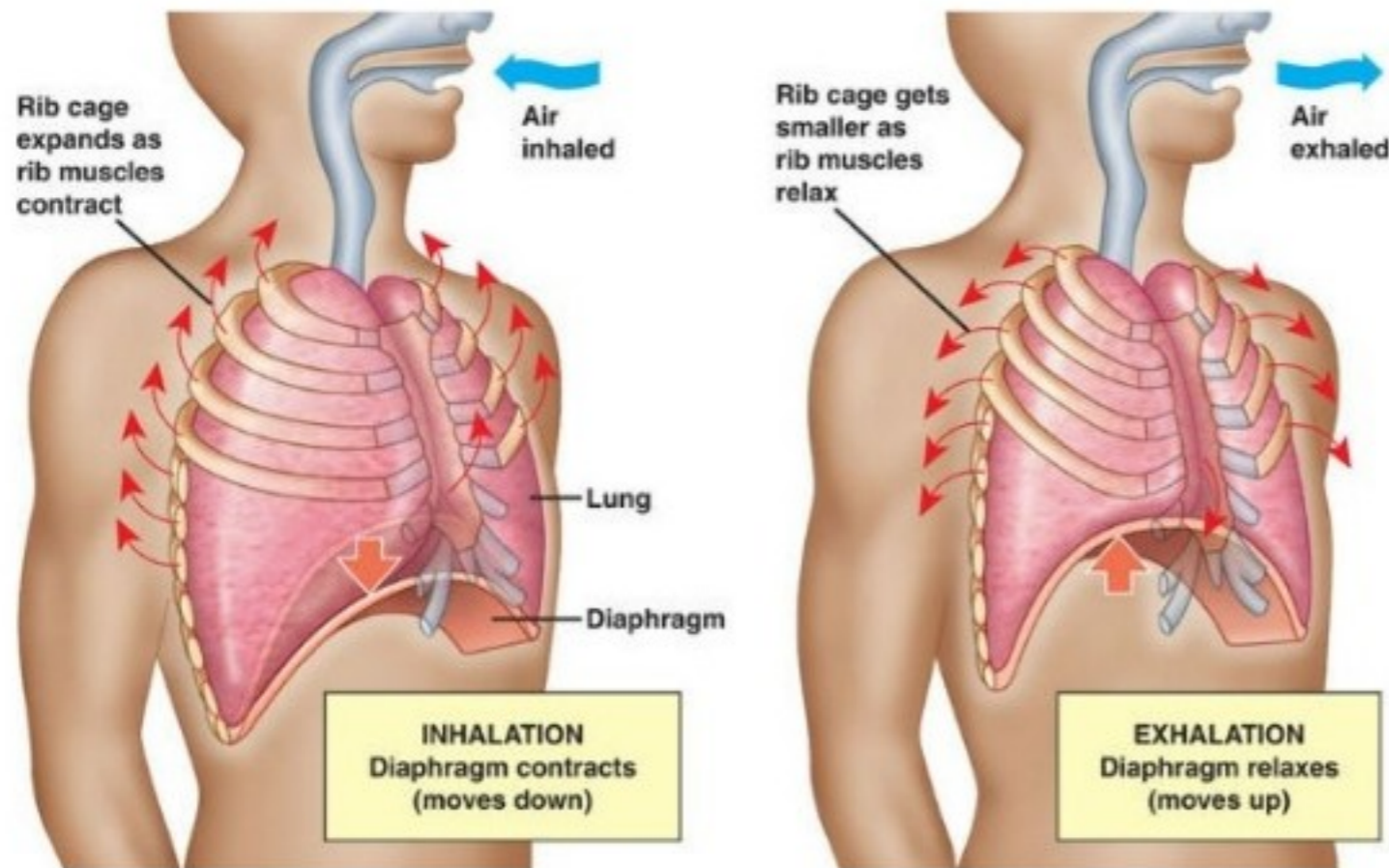
---

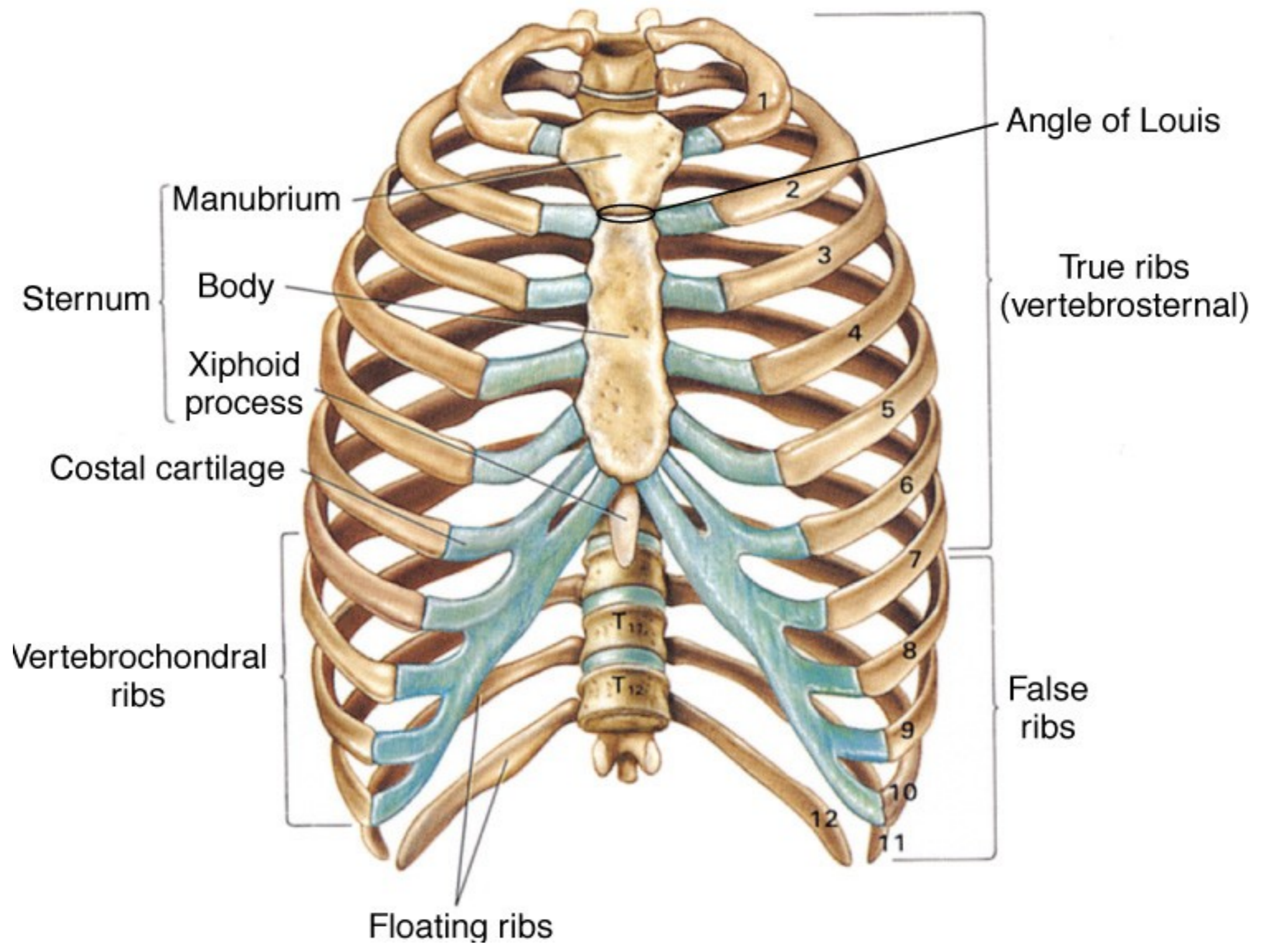
**MUDr. Martin Chovanec**

DKlinika úrazové chirurgie, Fakultní nemocnice Brno

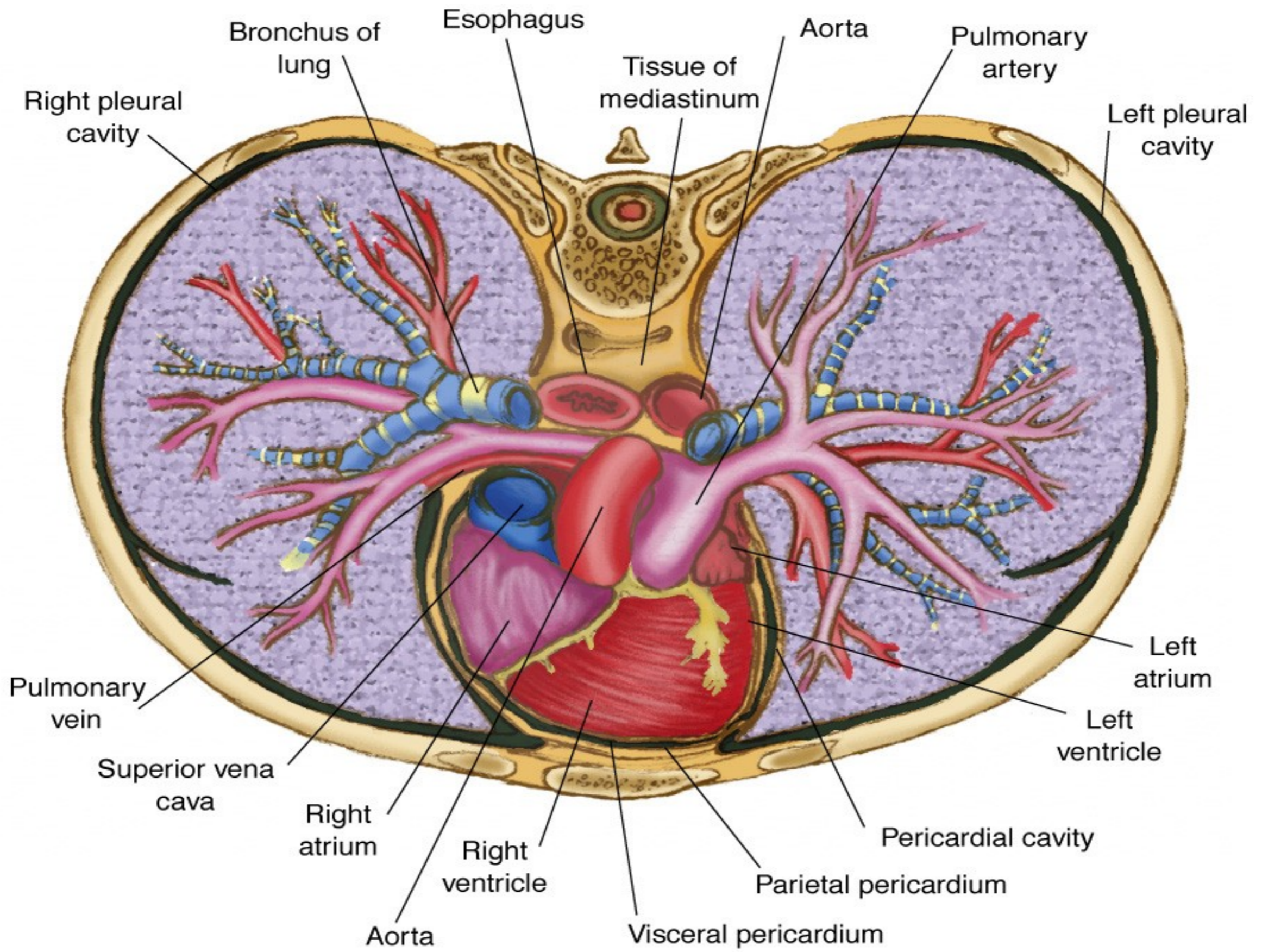


# Ventilace vs. respirace

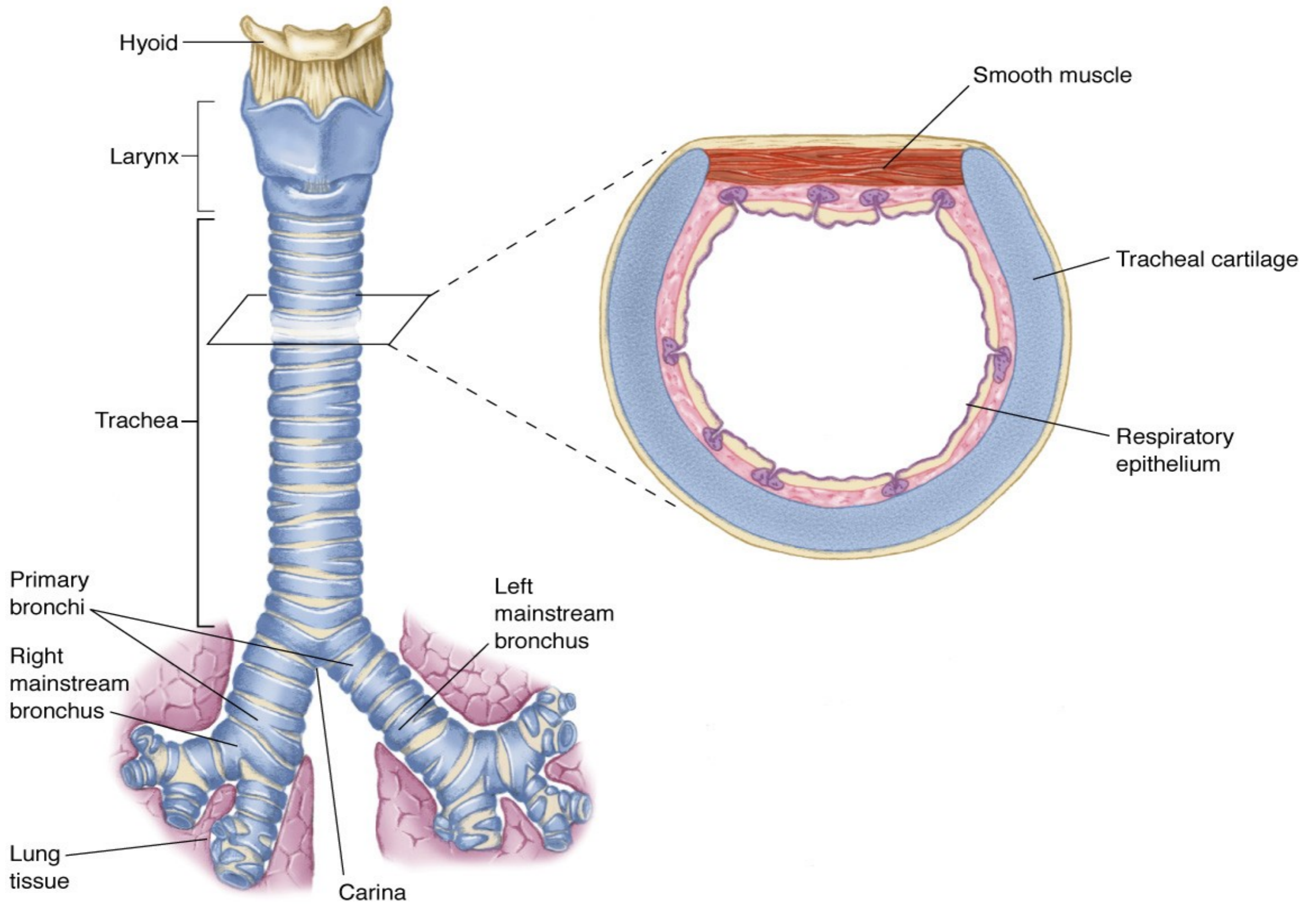




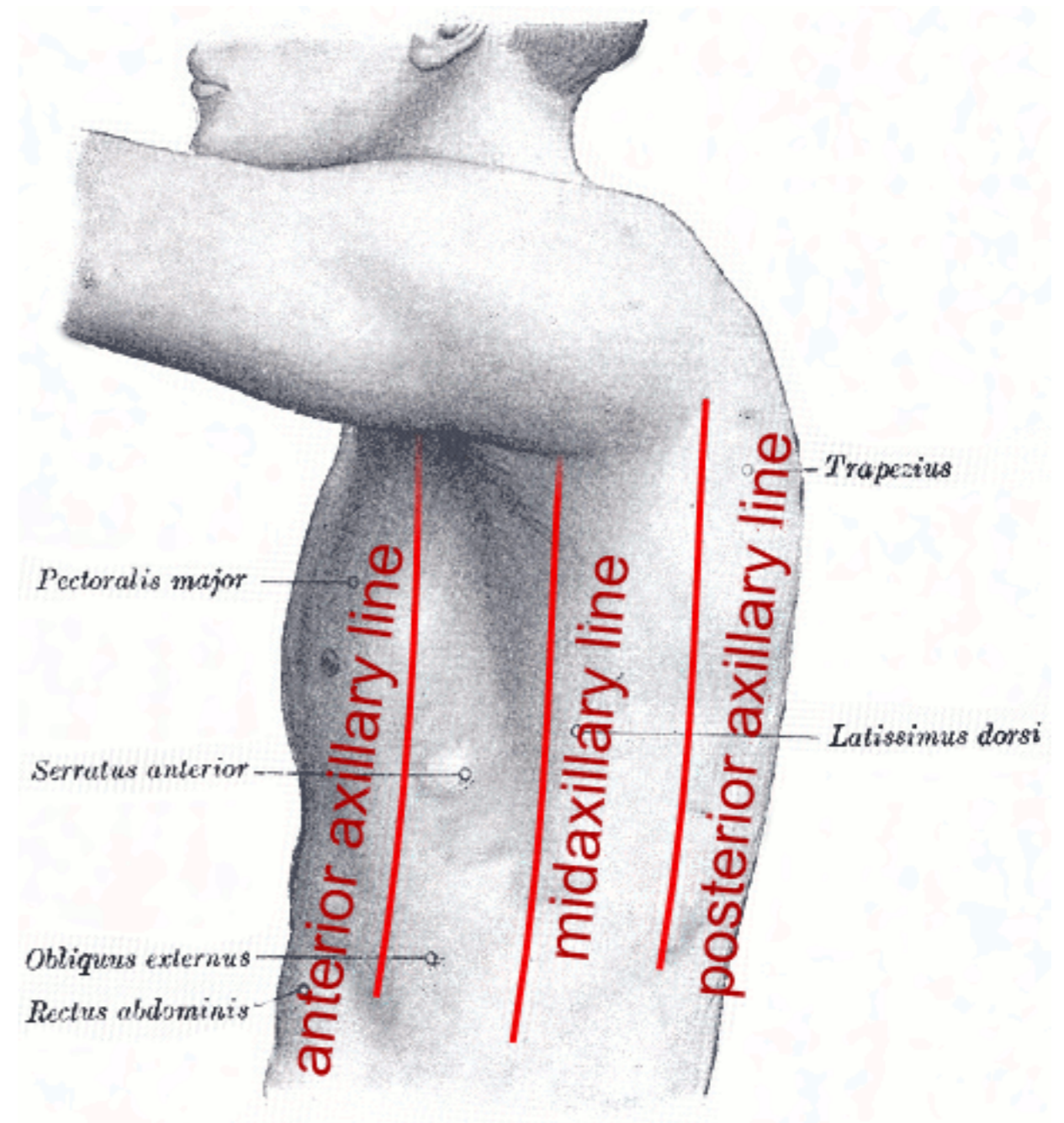
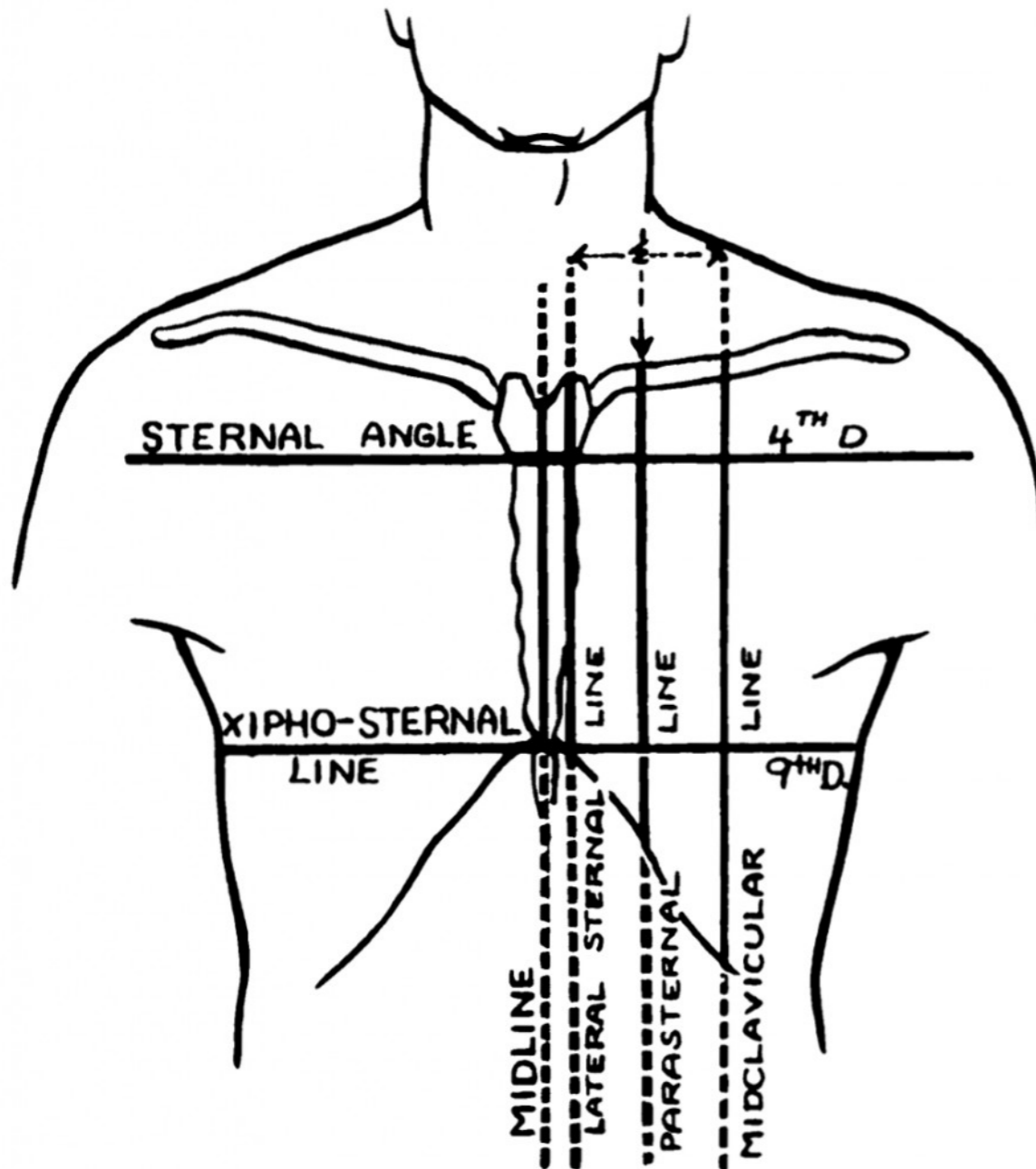






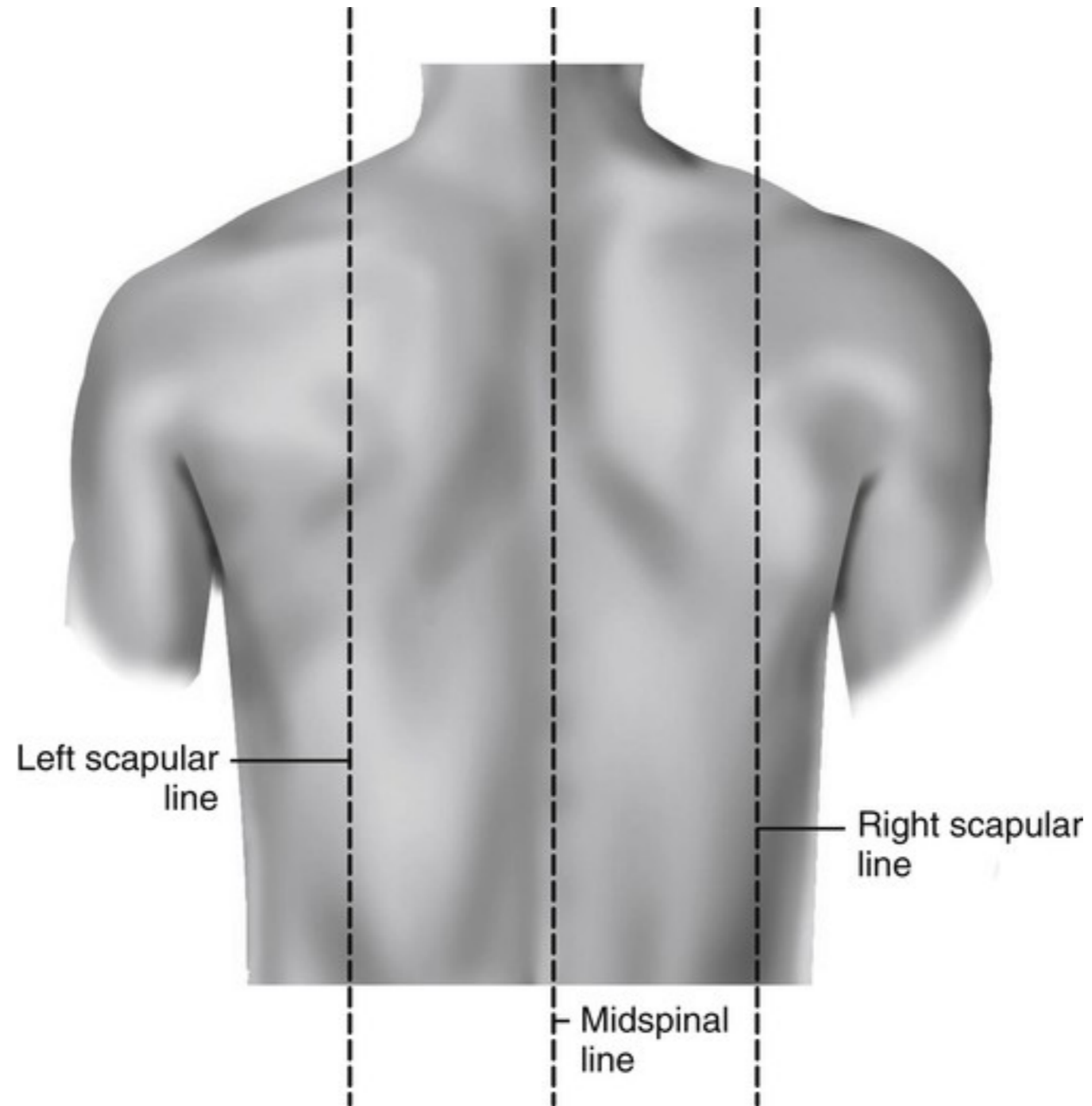


# Topografie



# Topografie

---

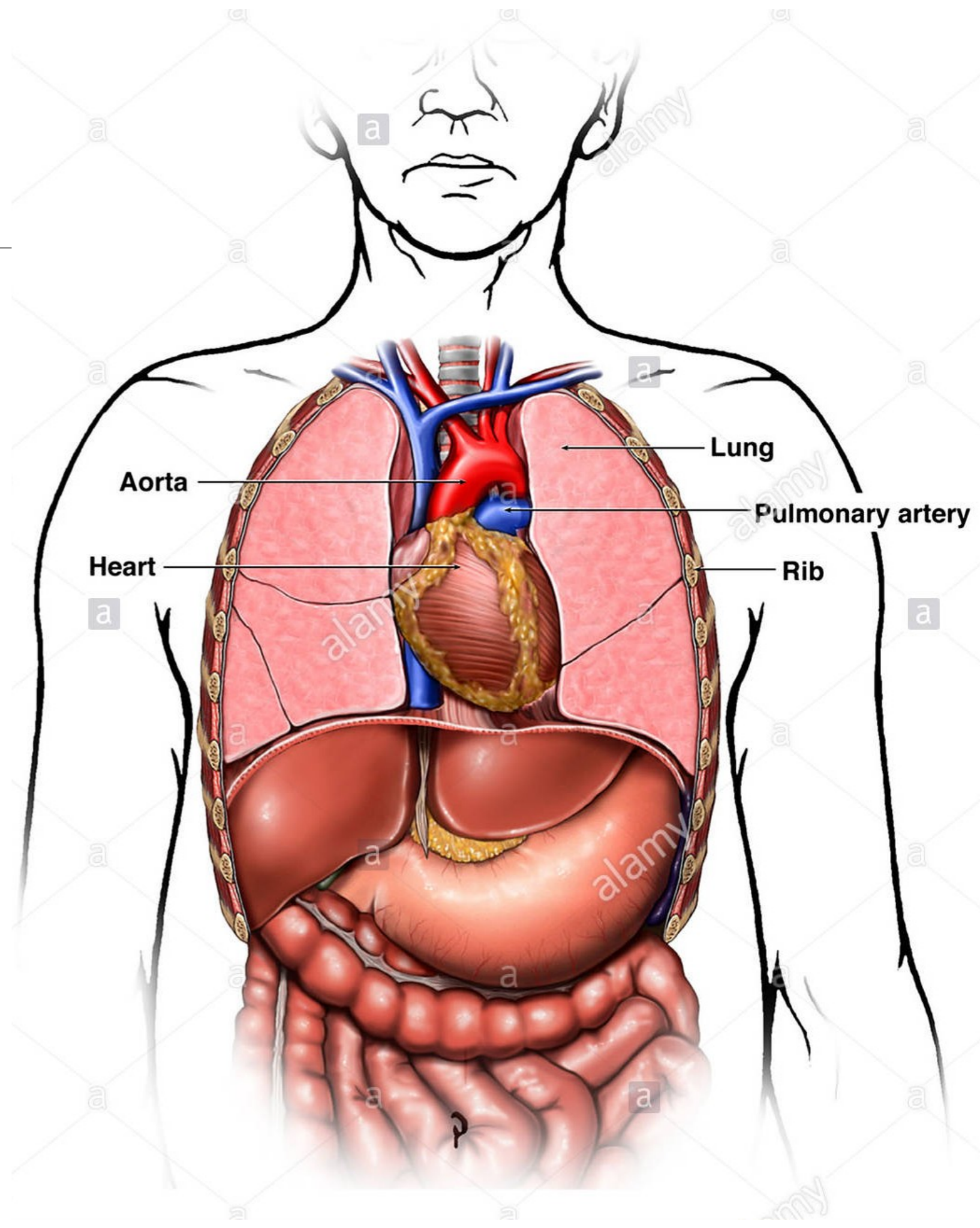




# Důležité struktury

---

- srdce
- plíce
- velké cévy
- trachea a bronchiální strom
- žebra
- sternum, Th páteř

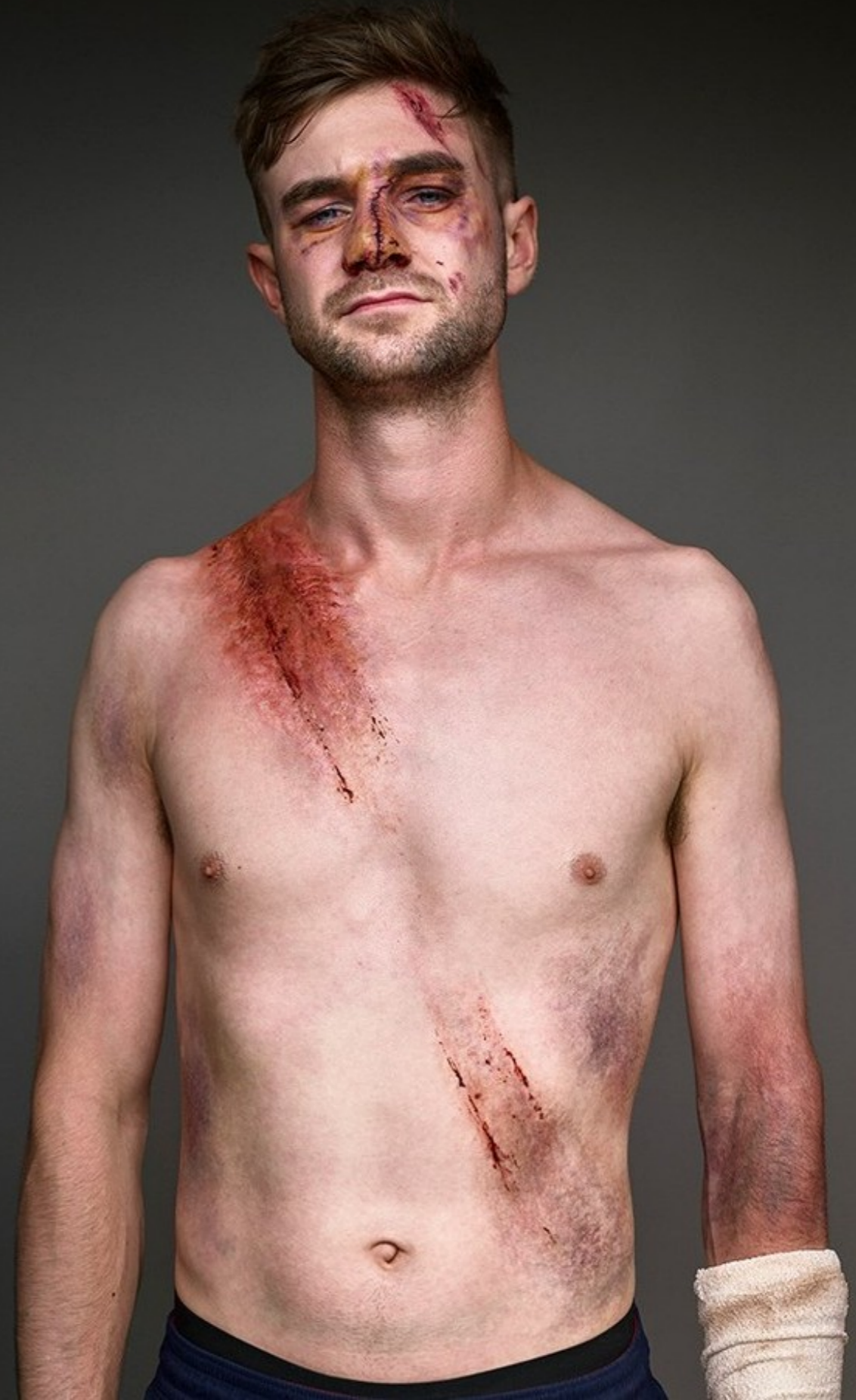



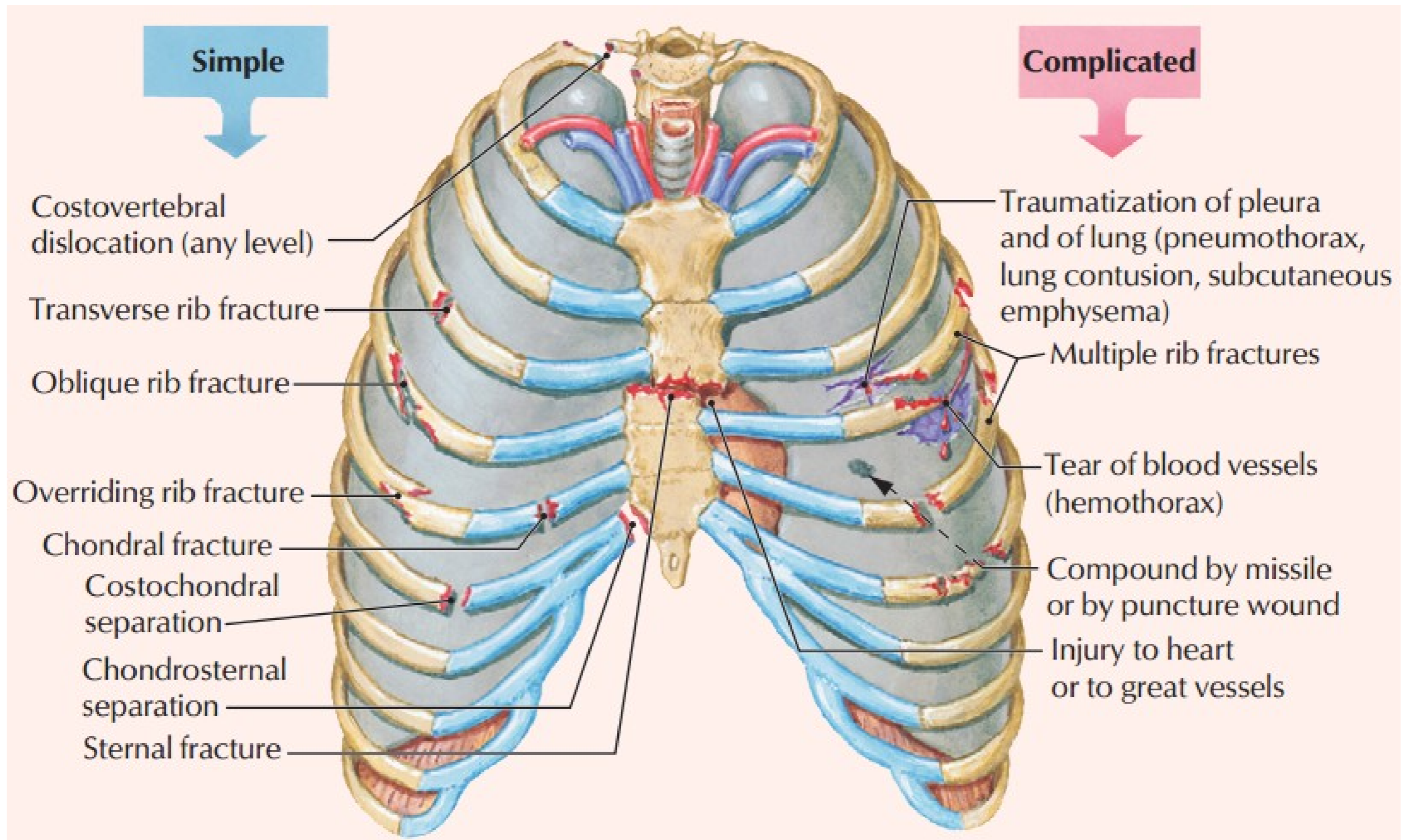
# Sdružené poranění

---

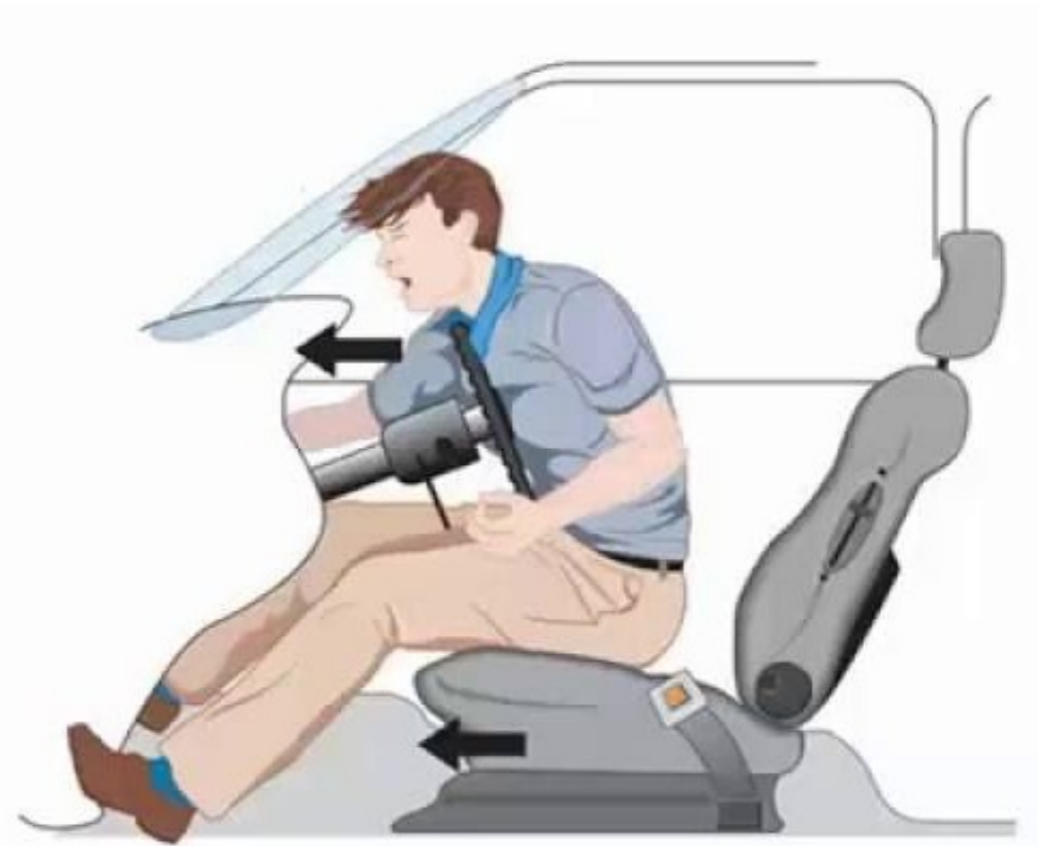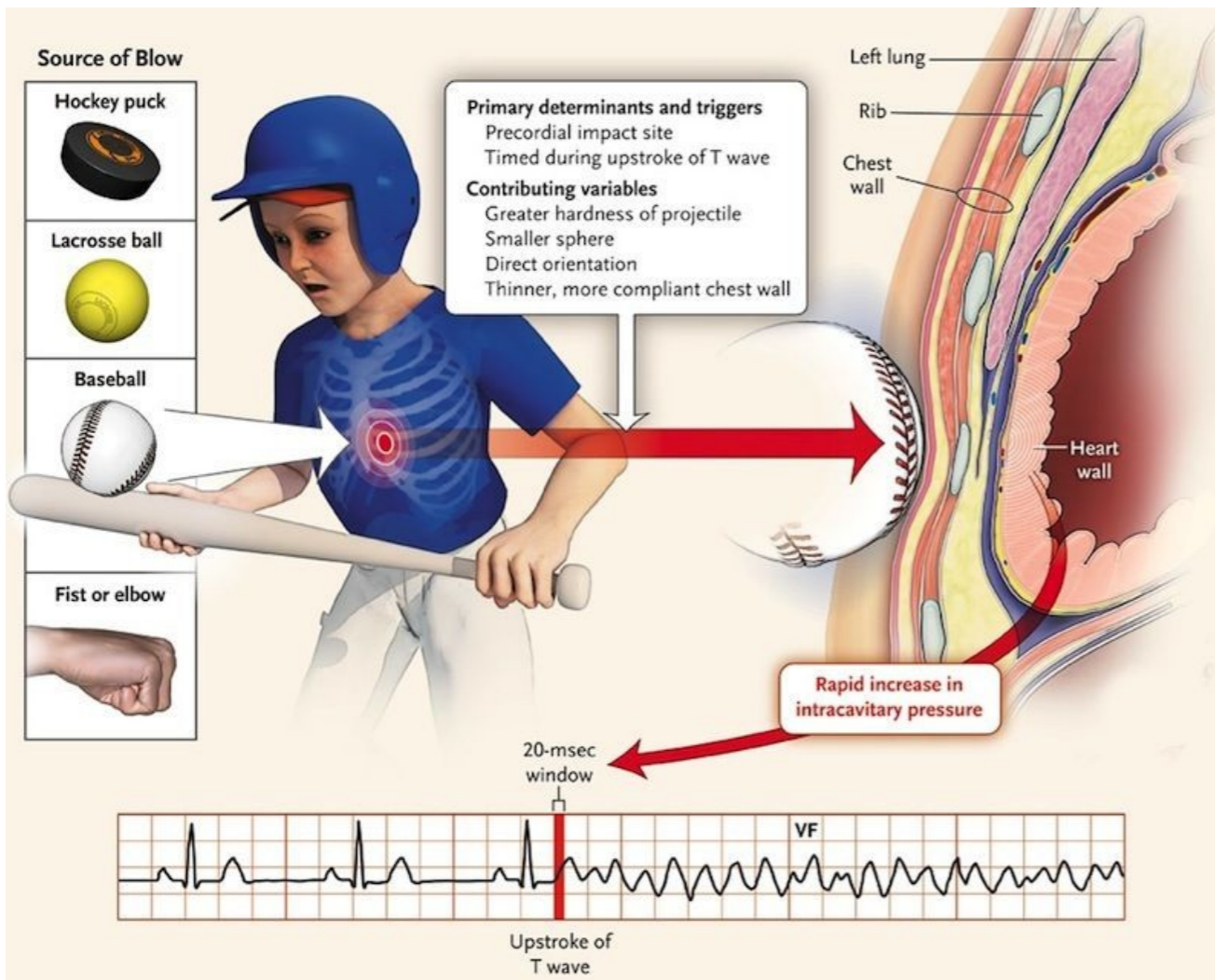
- poranění hrudníku často provázeno poranění orgánů v DB
- rozdělení poranění
  - ostré (penetrující/nepenetrující)
  - tupé - majorita

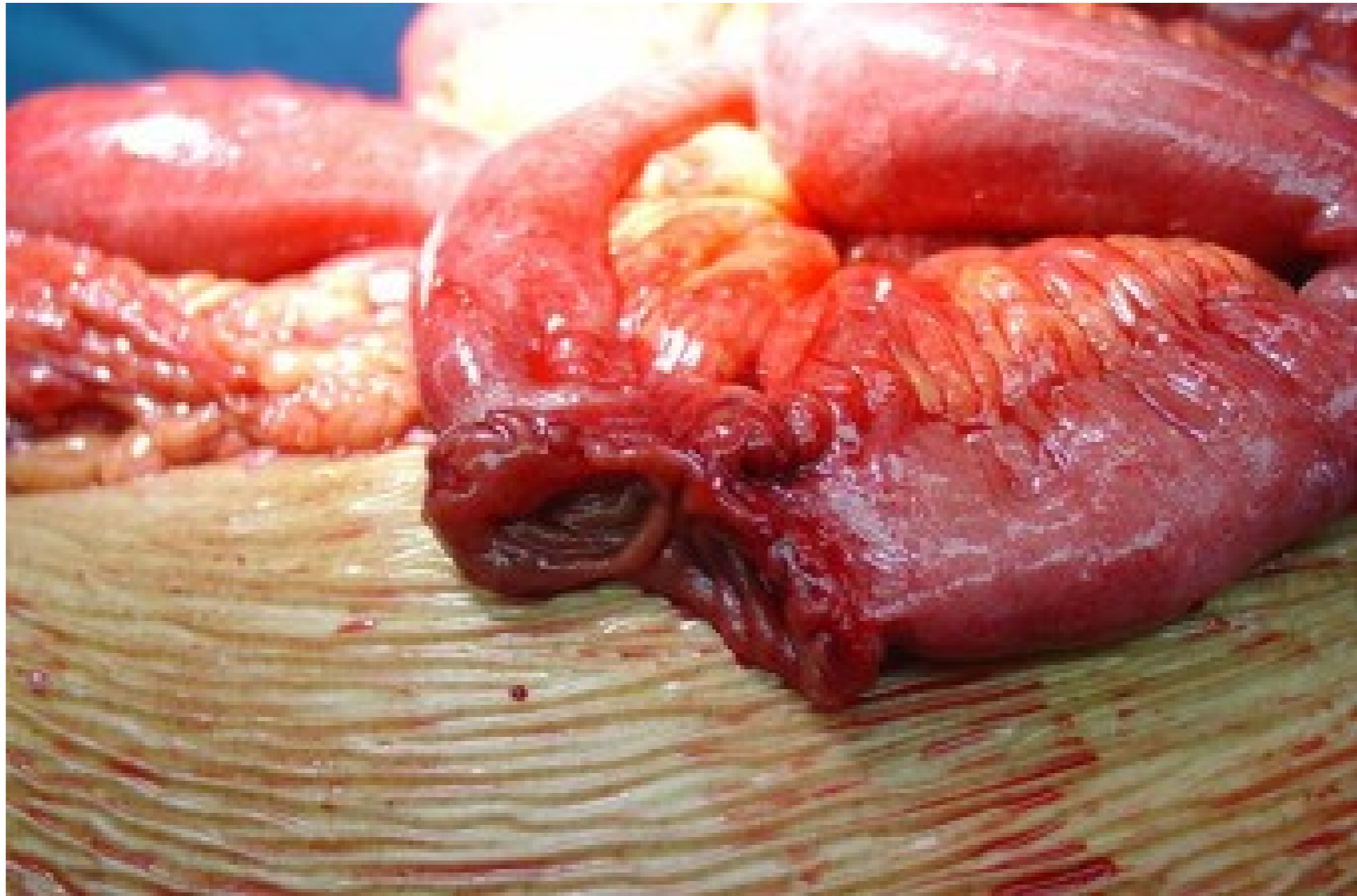


# Poranění hrudníku - přehled

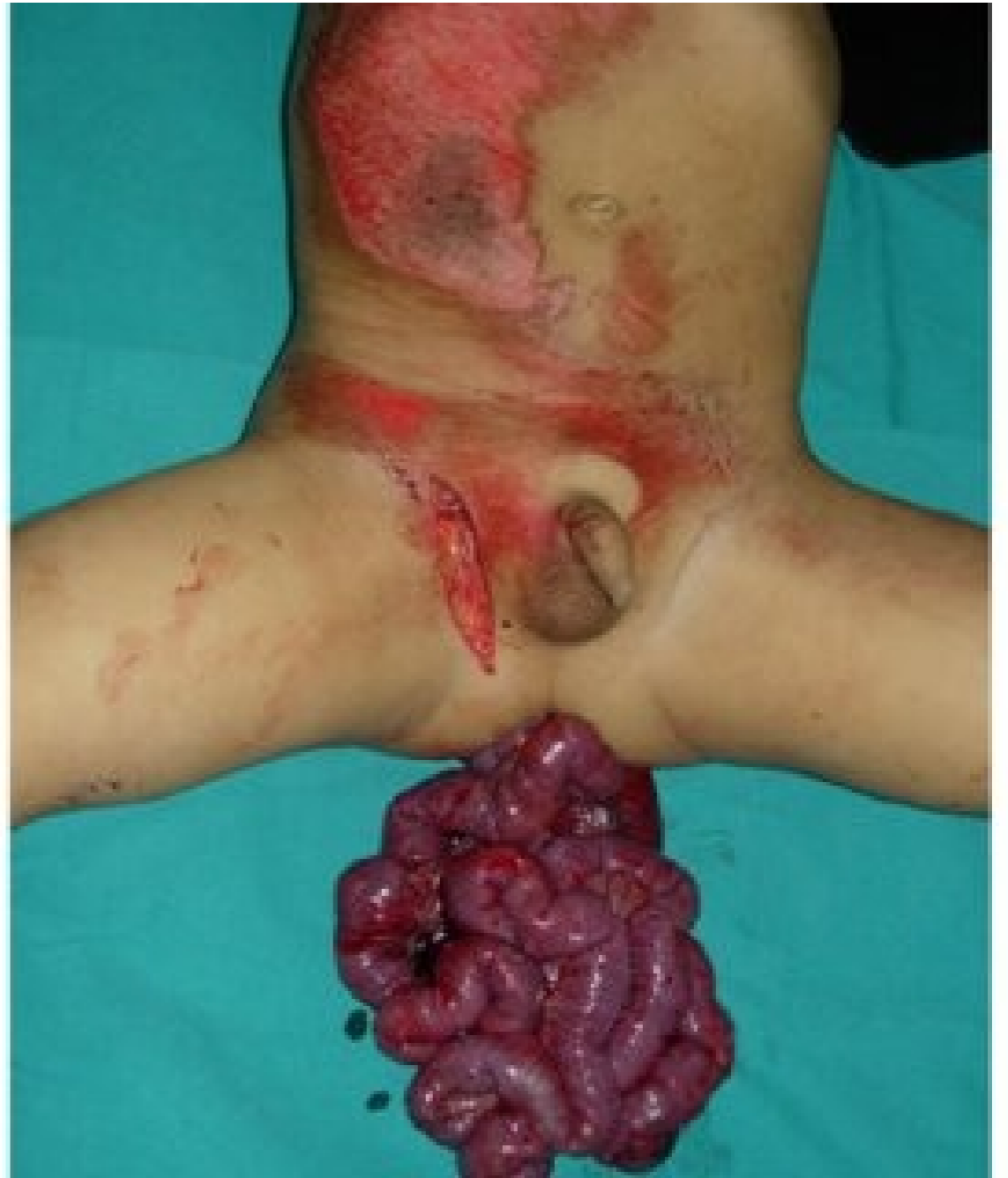
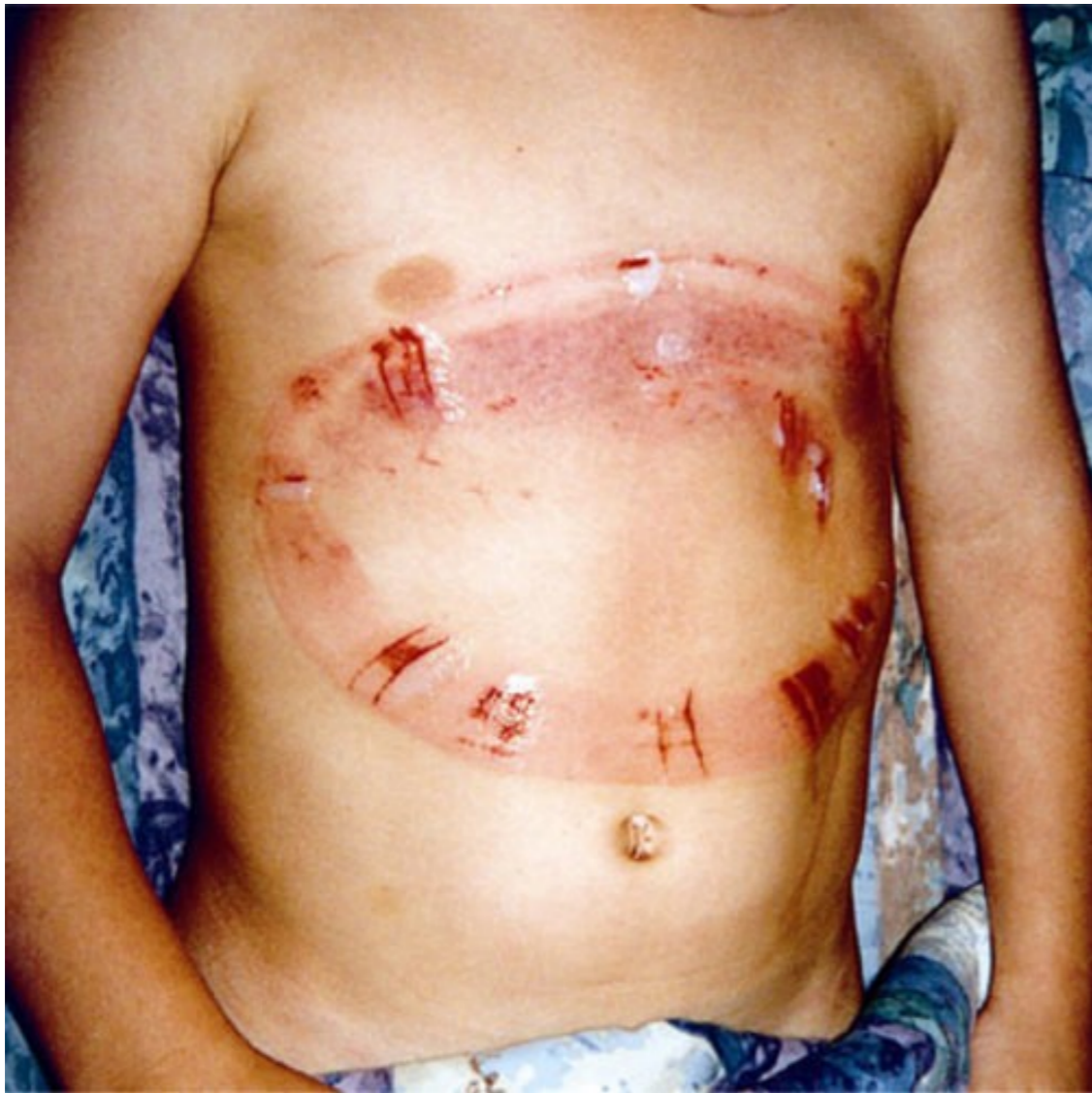


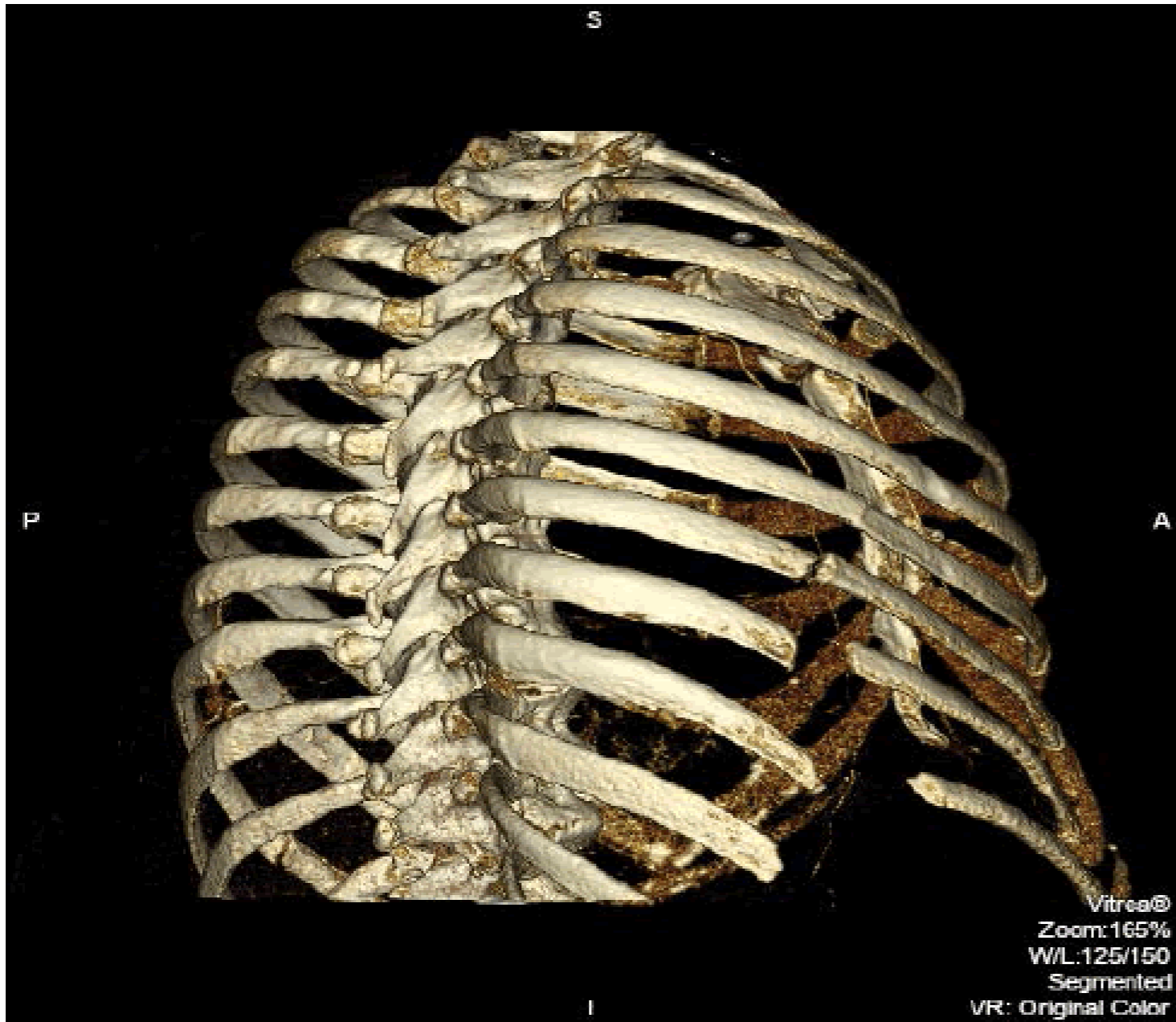








# Zlomeniny žeber

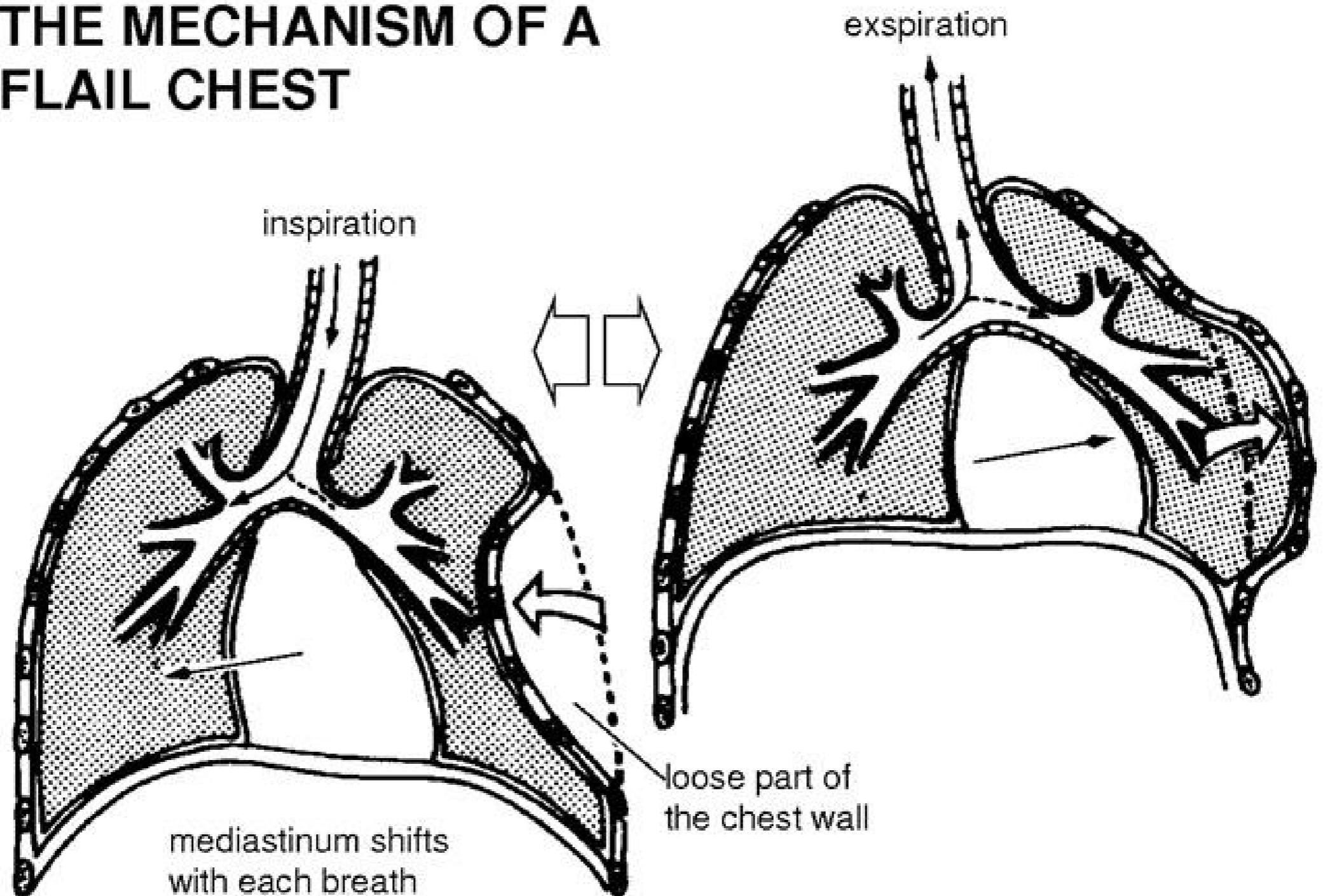


- jednoduchá vs sériová fr. žeber
- dvířková zlomenina žeber
- vlající hrudník/mediastinum
- zlomenina sternu často v koincidenci s fr. Thp (předožadní násilí)



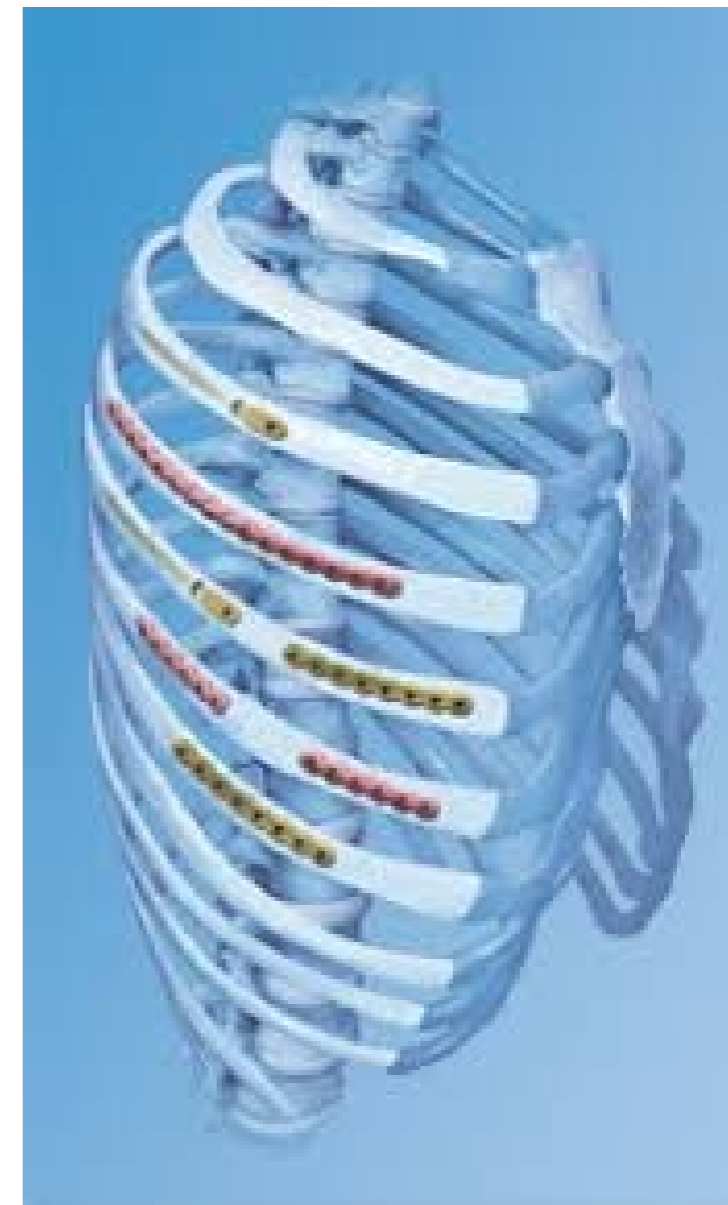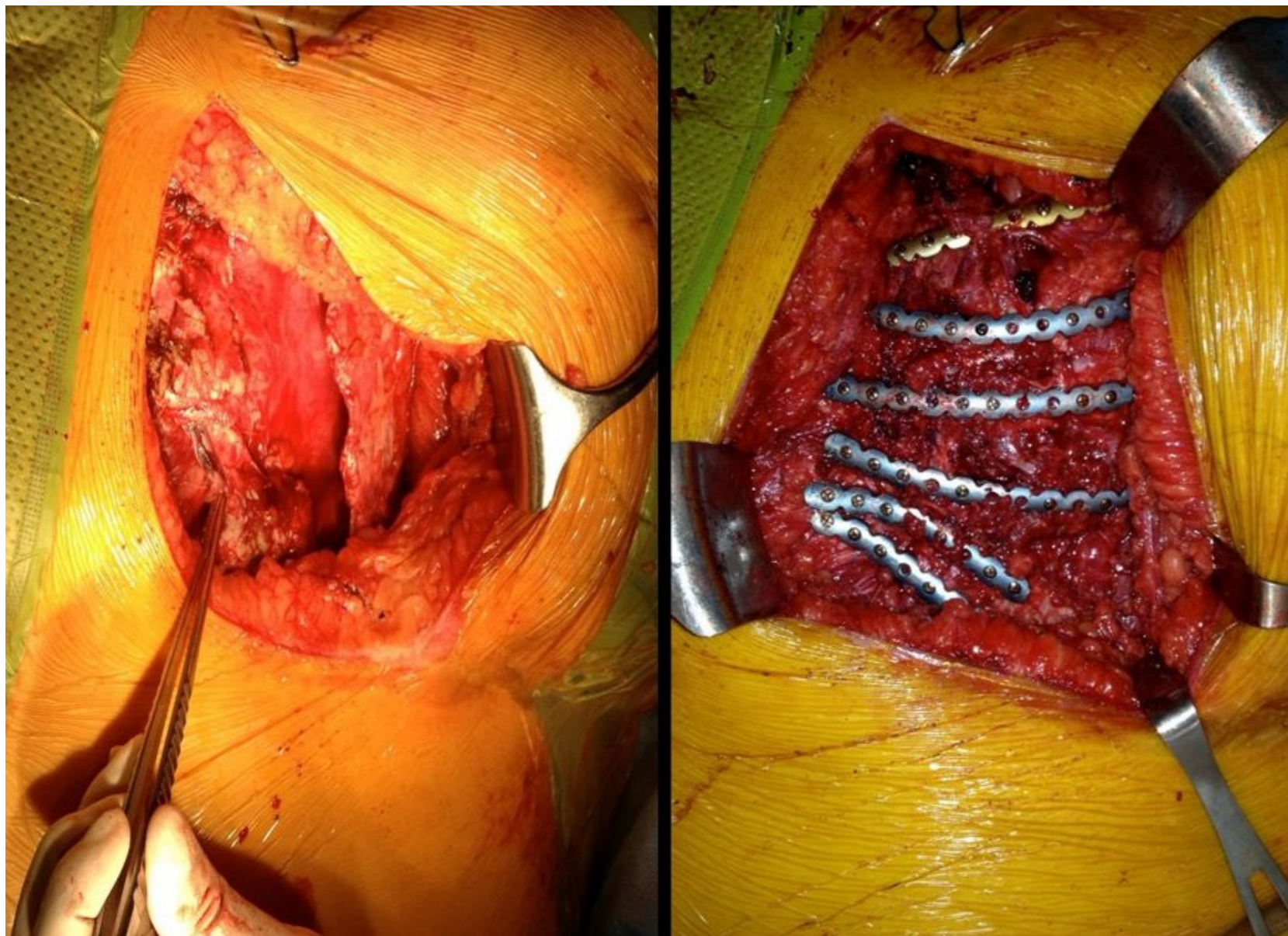
# Flail chest

## THE MECHANISM OF A FLAIL CHEST



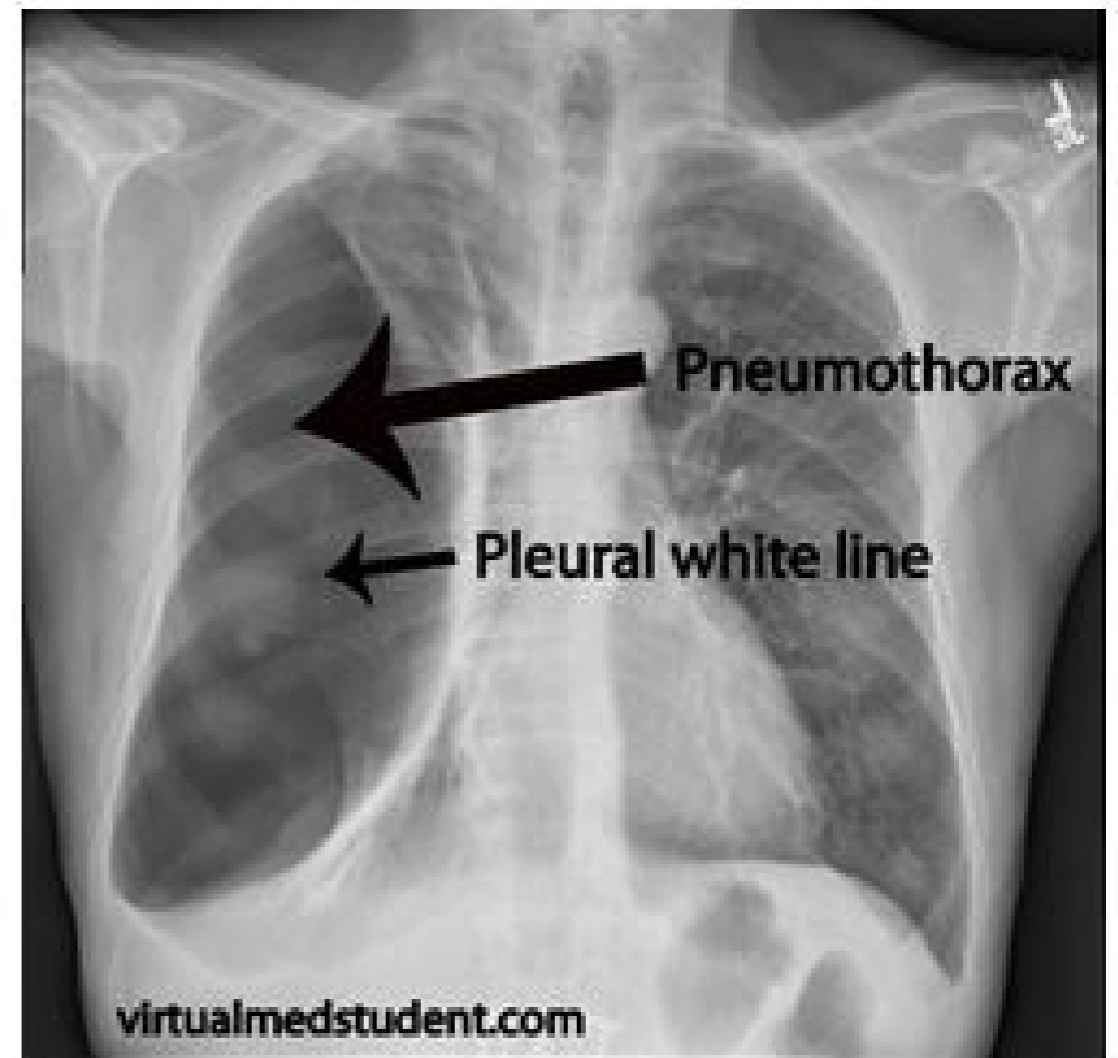
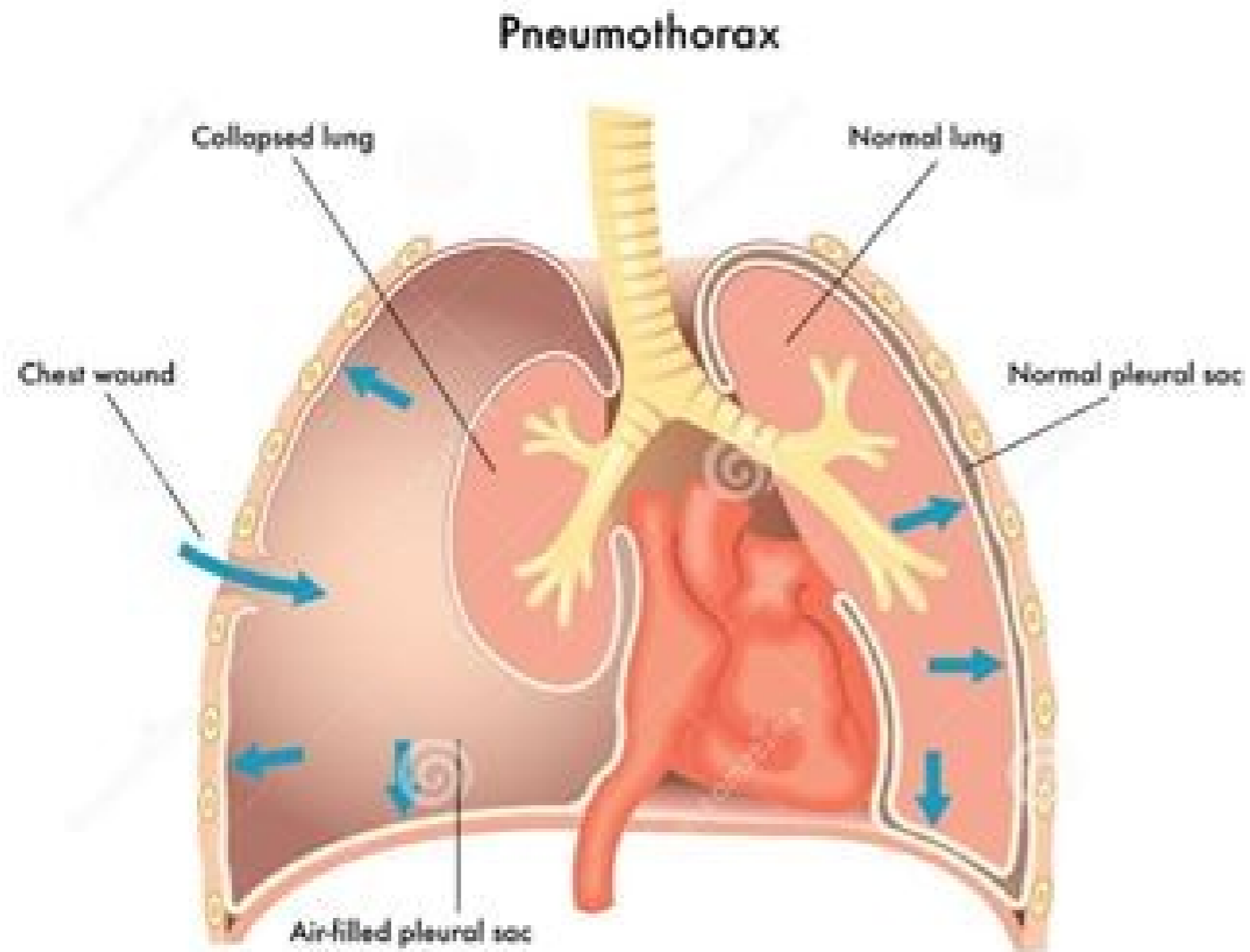
# Stabilizace hrudní stěny

---



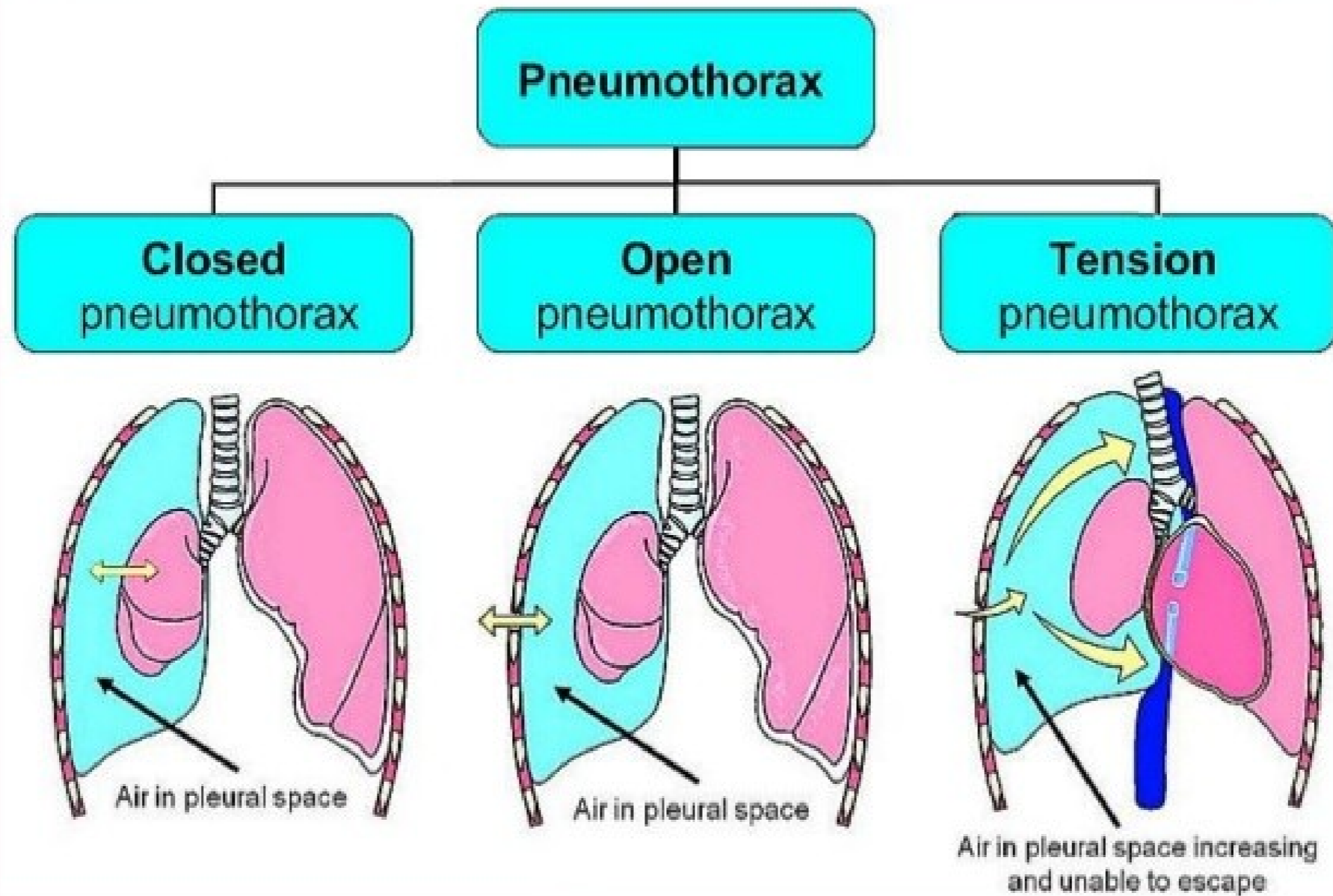


# Traumatický pneumothorax



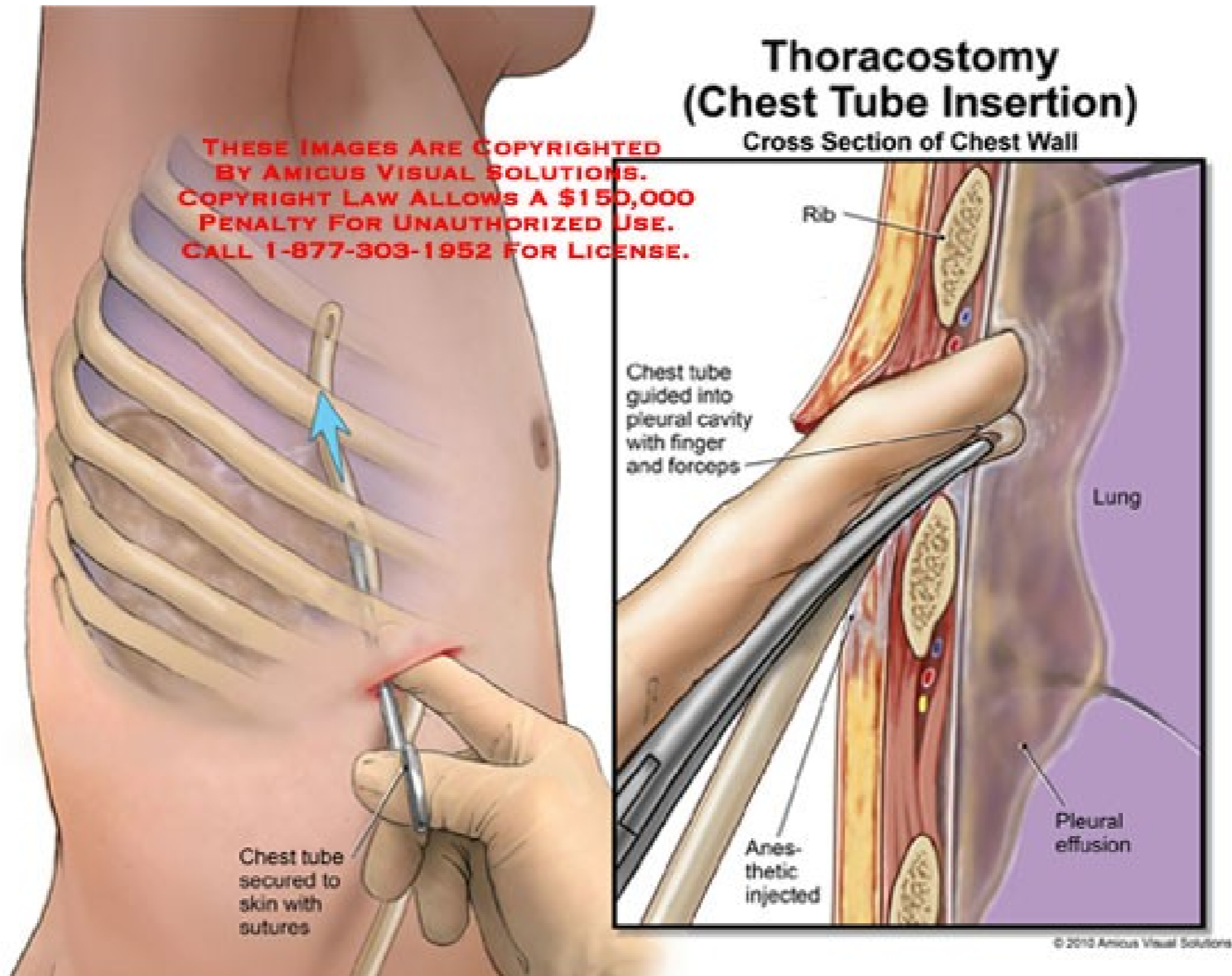
# Typy PNO

## Pathophysiology



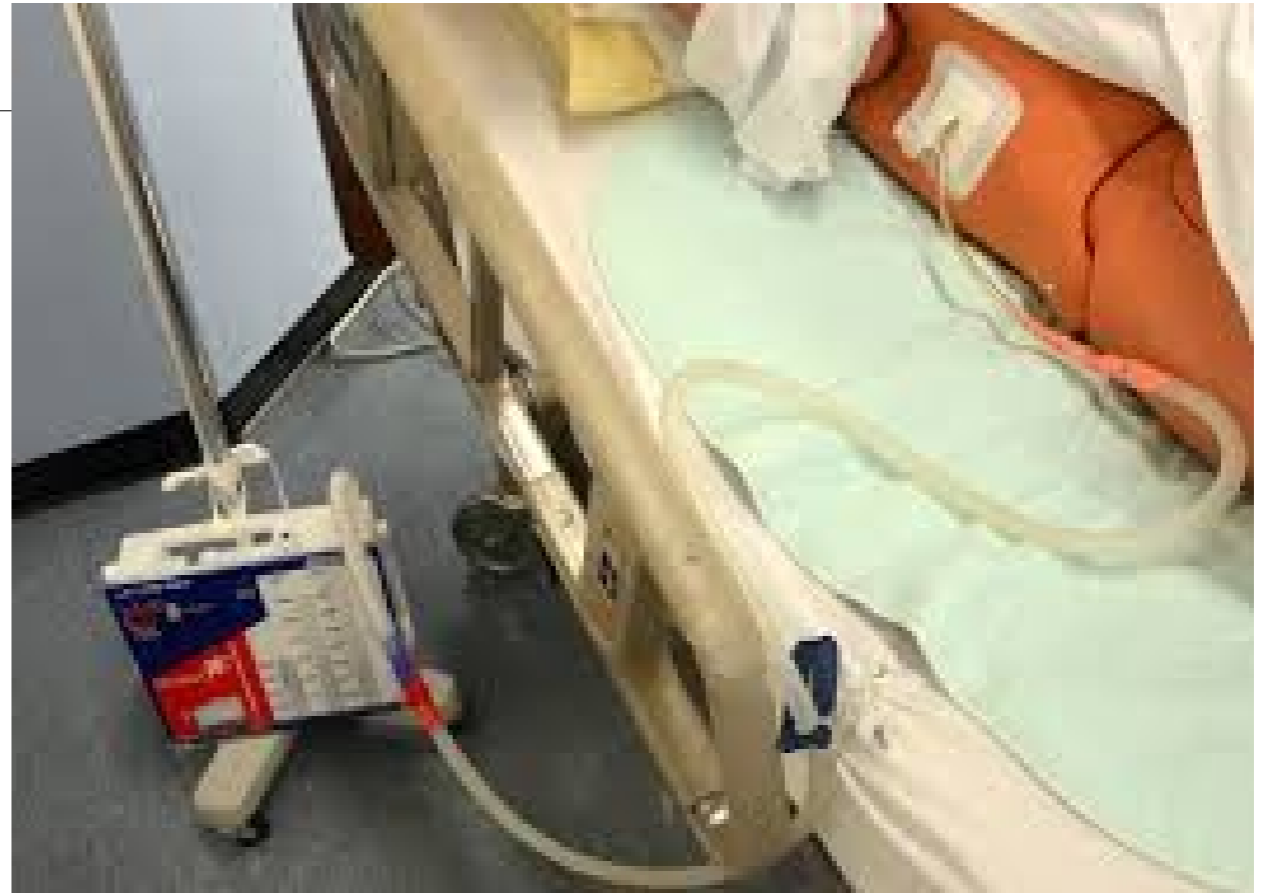

# Traumatický pneumothorax



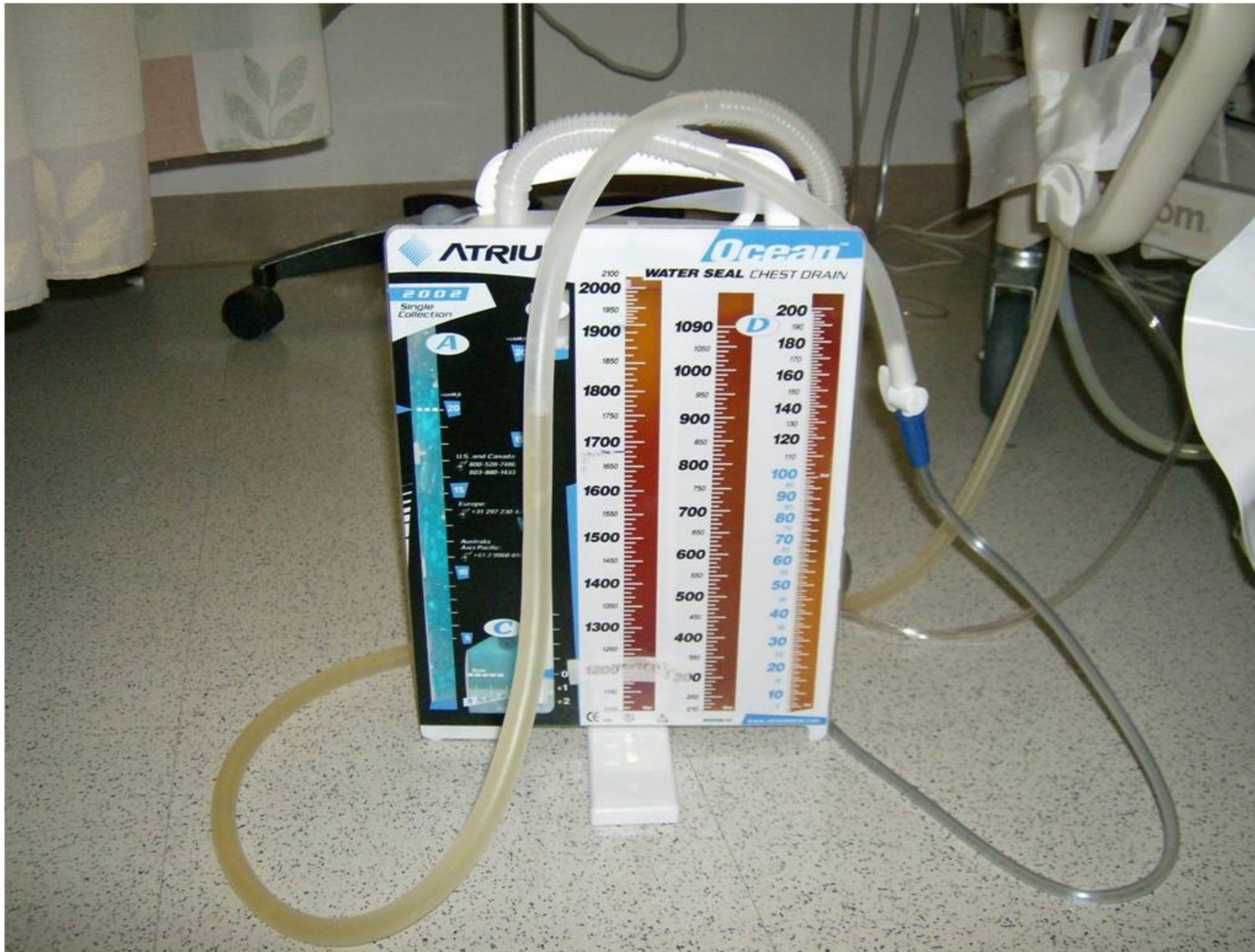
# Traumatický pneumothorax

---



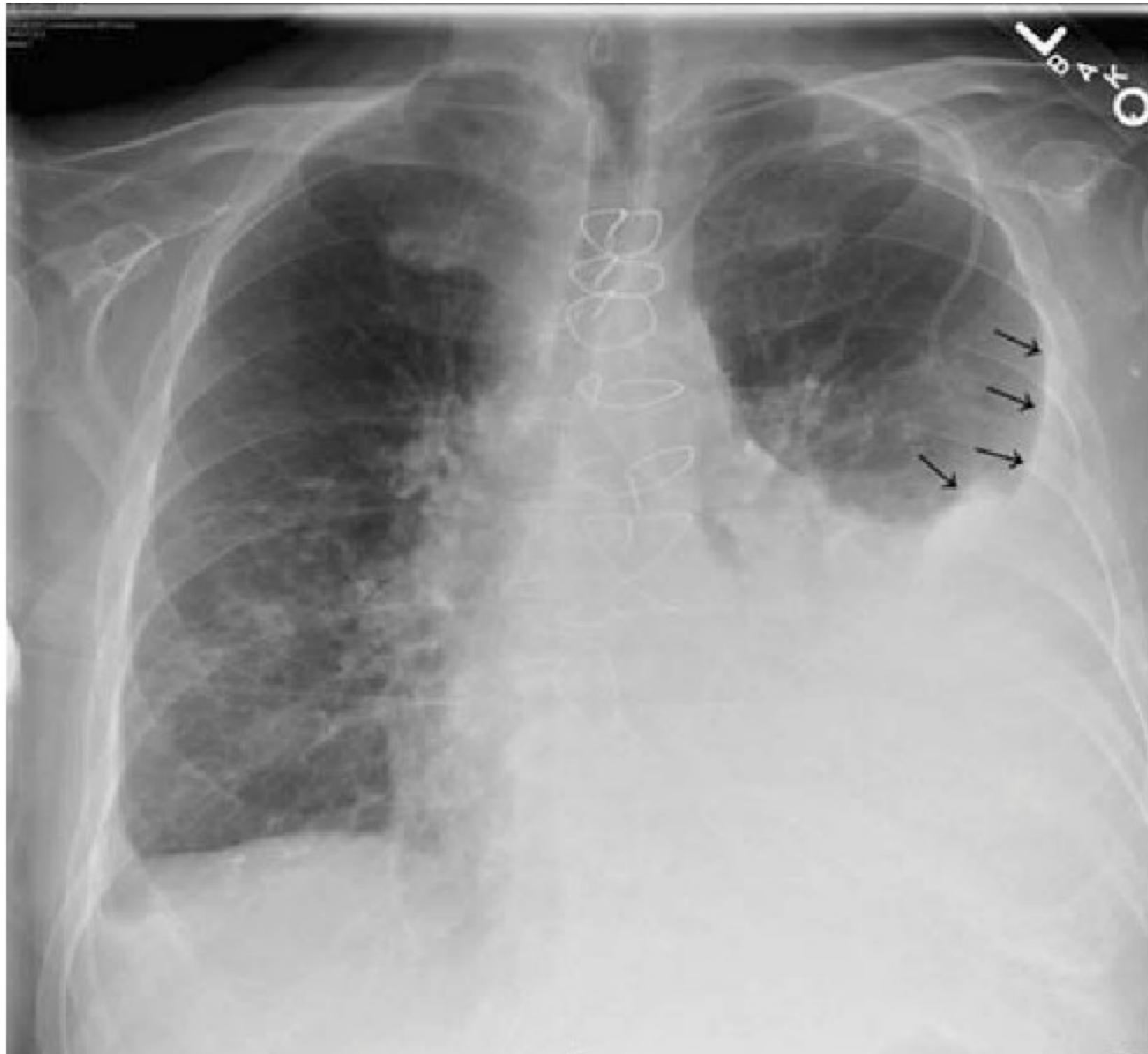


# Traumatický pneumothorax



# Traumatický hemothorax

---



# Traumatický hemothorax

---

