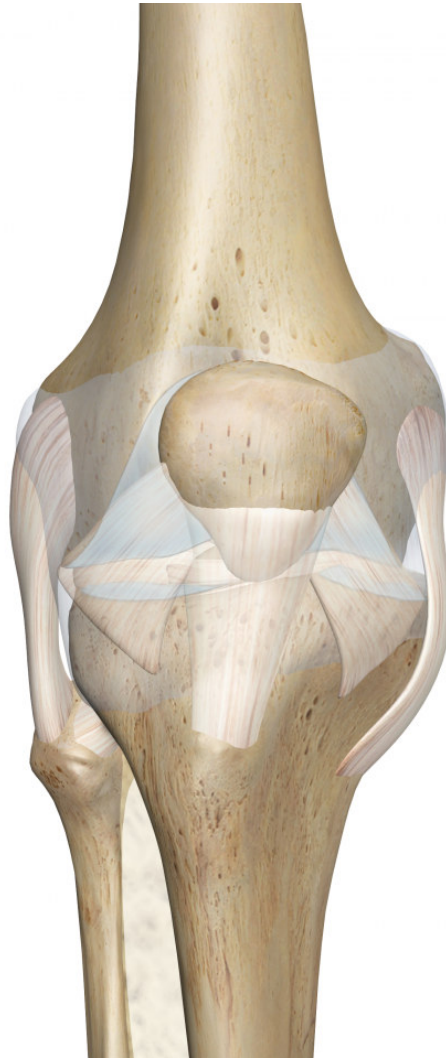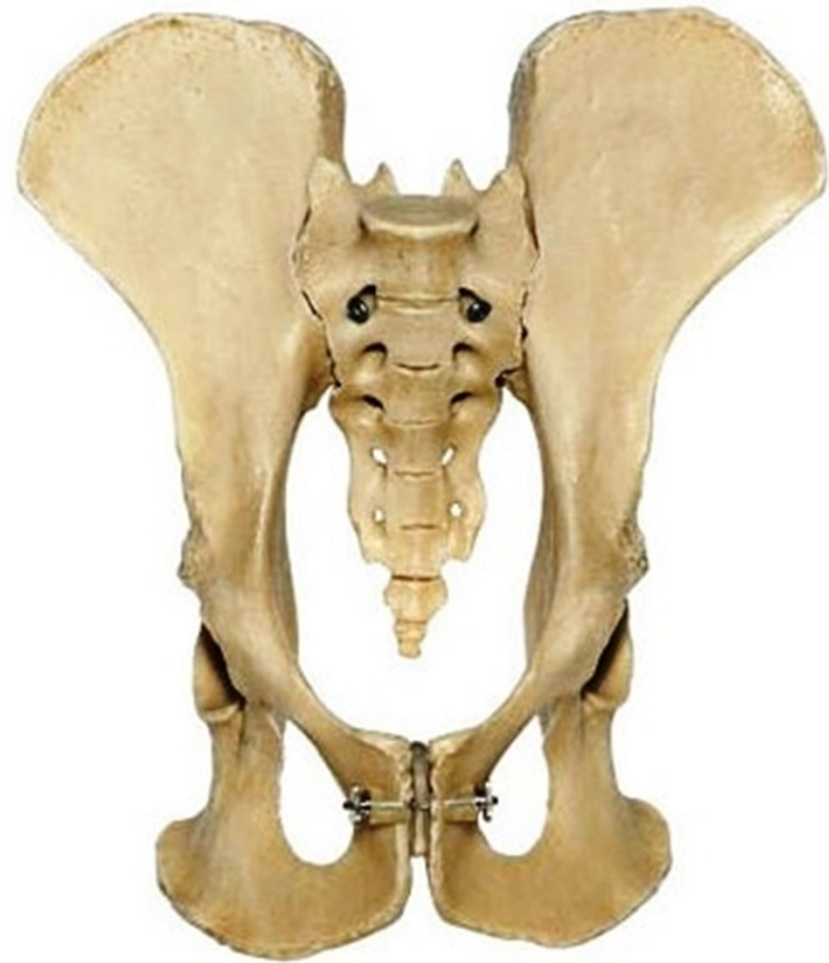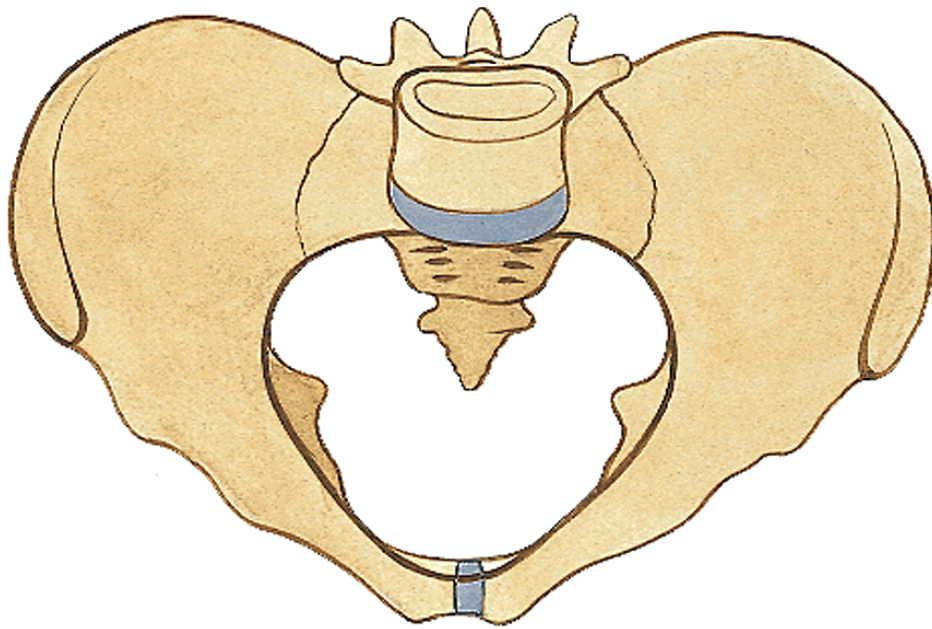


JOINTS OF THE LOWER EXTREMITY



Pelvis as a whole:

By connection of **os coxae** with **os sacrum** through **sacroiliac joint** and **symphysis** in the front, there is created a solid circle



Articulatio sacroiliaca

Type: **tough joint- amphiarthrosis**

Articular surfaces:

facies auricularis ossis sacri

facies auricularis ossis ilii

Articular capsule: **short, tough**

Ligaments:

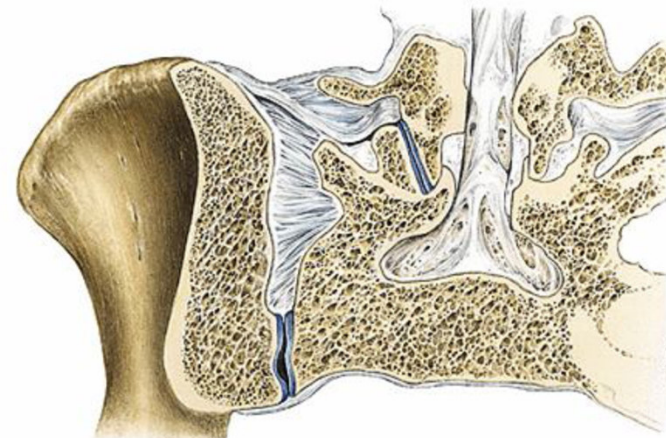
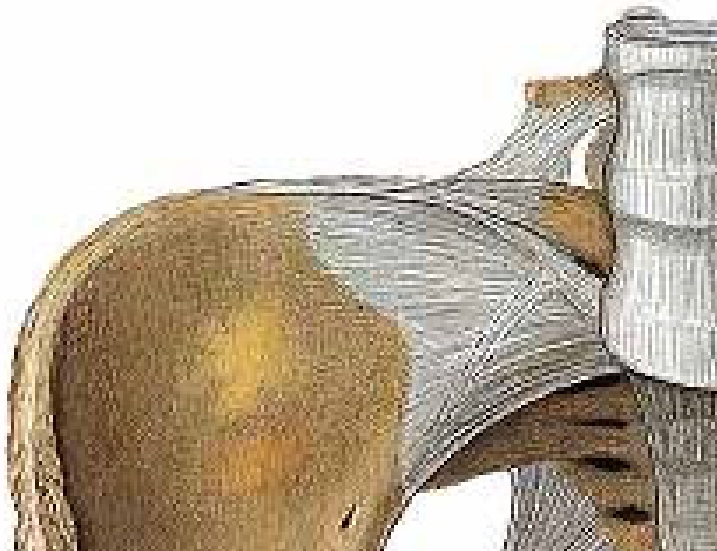
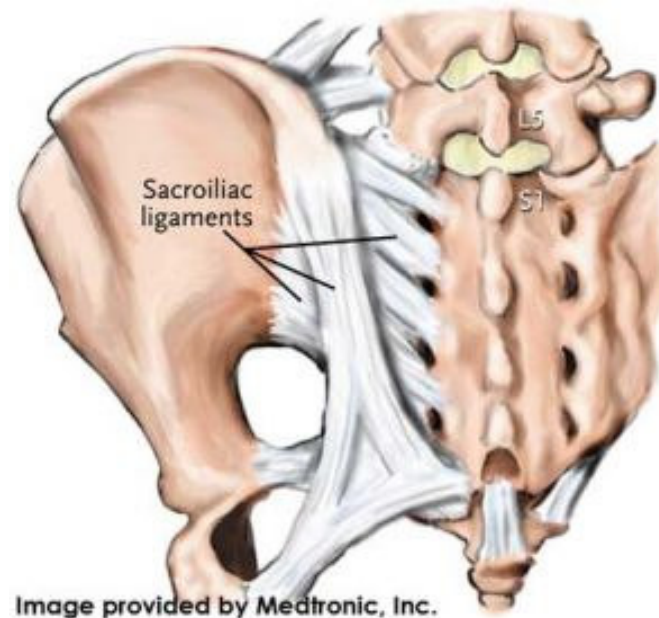
lig. sacroiliacum ventrale

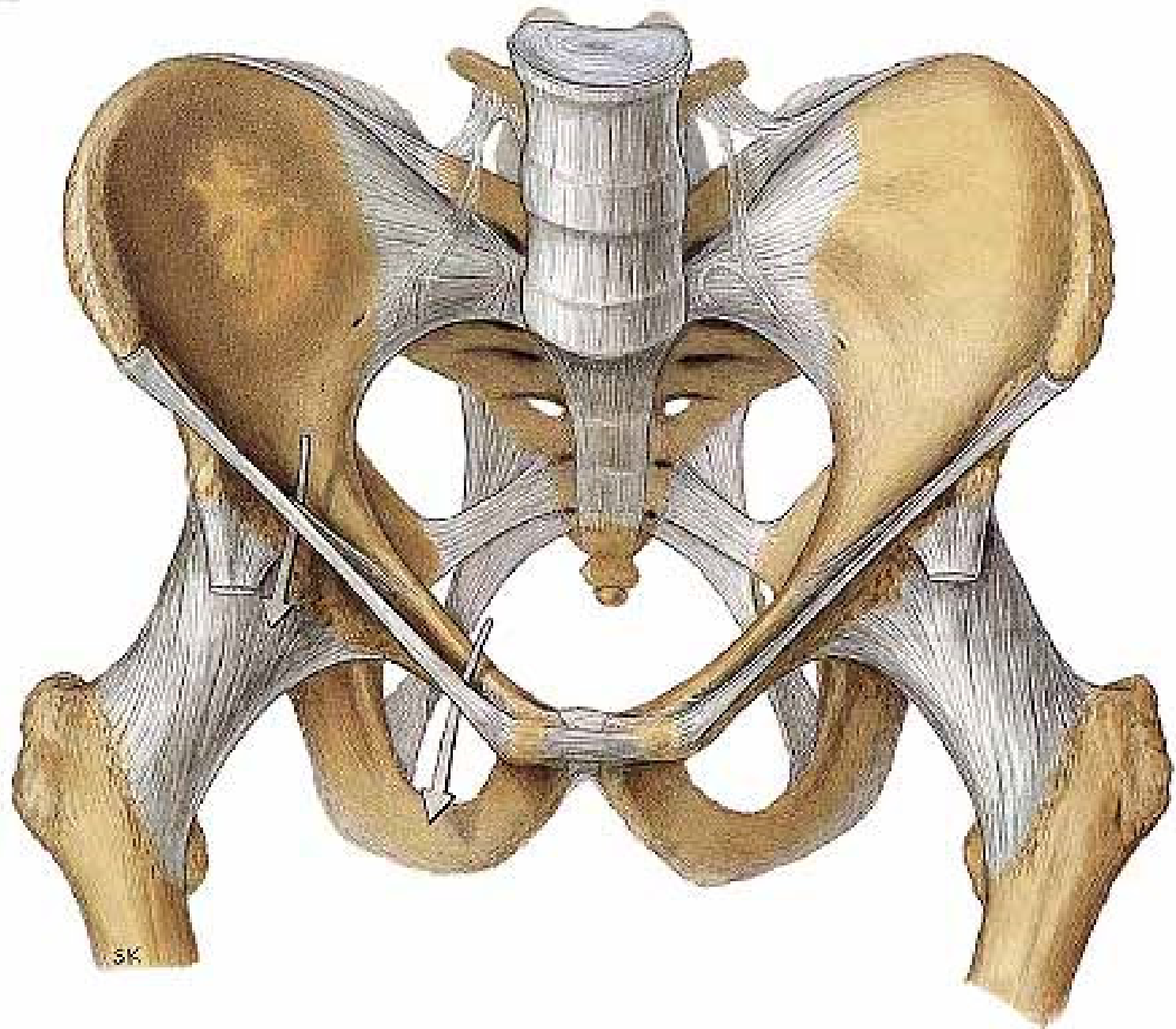
lig. sacroiliacum dorsale

lig. sacroiliacum interosseum

lig. iliolumbale from L4-5 to dorsal side of crista iliaca

Movements: **minimal**





Articulationes cinguli

Symphysis pubica

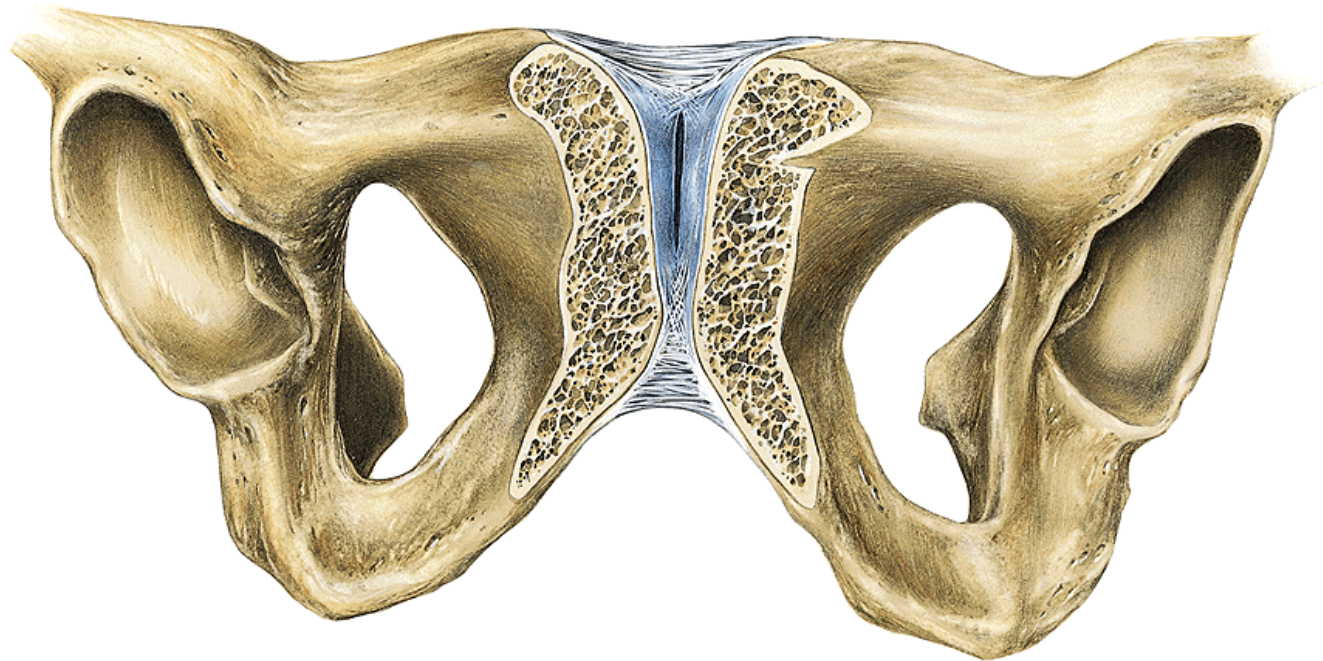
Type: **tough, cartilaginous connection**

discus interpubicus- at the back **eminentia retropubica**

(palpable), there is sometimes a cleft inside

Contact surfaces: **facies symphybiales (os pubis)**

Ligaments: **lig. pubicum inferius = lig. arcuatum pubis** – from below, it holds even when the pelvic bones are spread out
lig. pubicum superius



Ligaments of pelvis
lig. inguinale

lig. sacrospinale

foramen ischiadicum majus

(it is divided by the course of **m. piriformis**
into **foramen suprapiriforme et infrapiriforme**)

lig. sacrotuberale

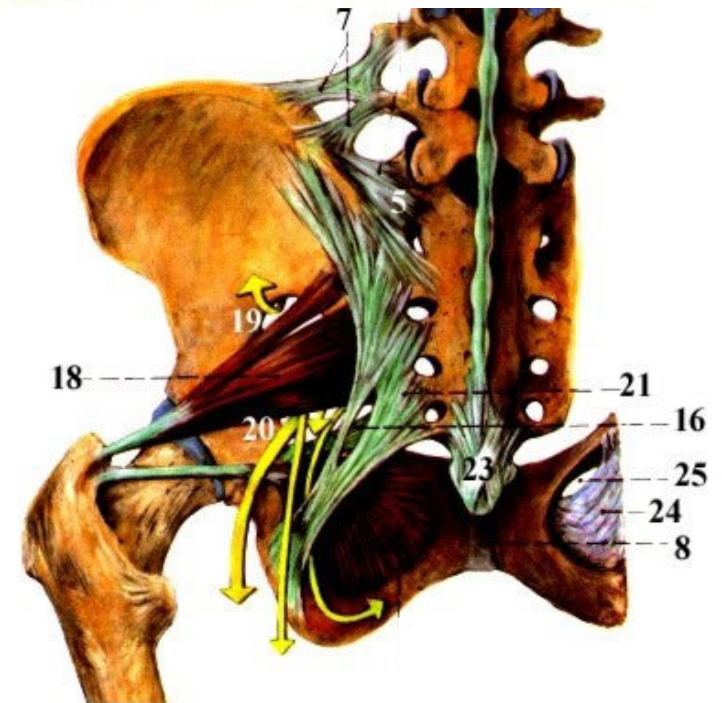
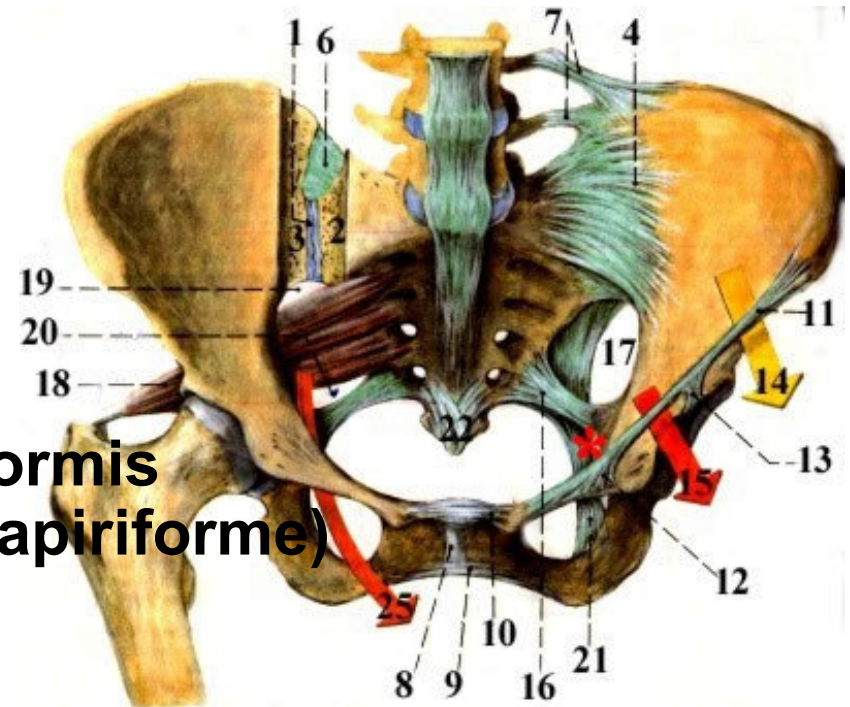
foramen ischiadicum minus

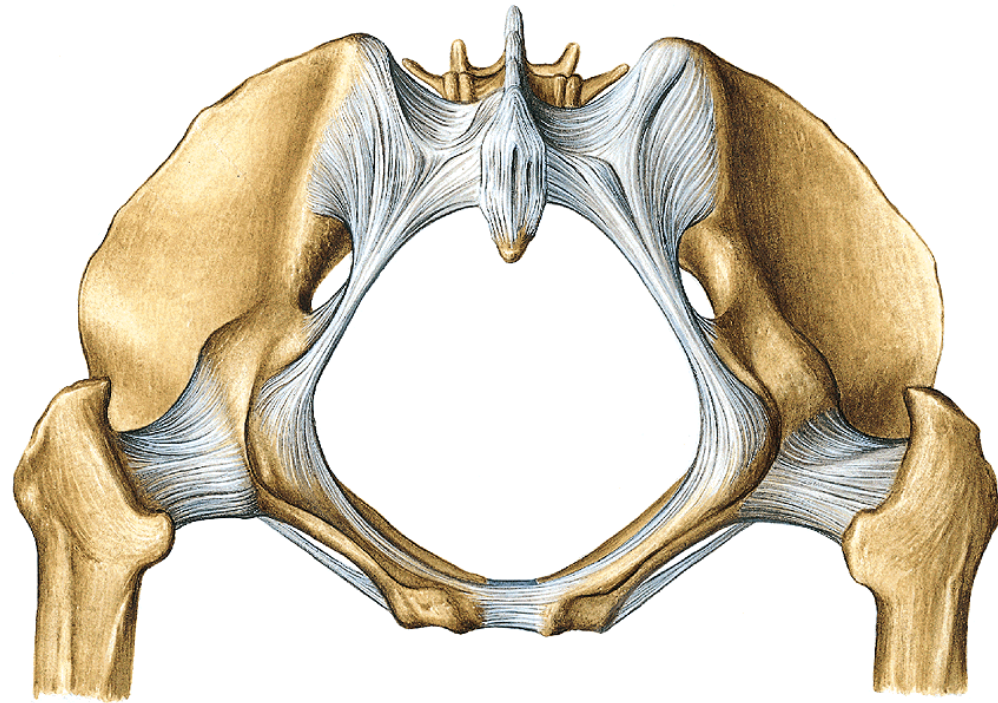
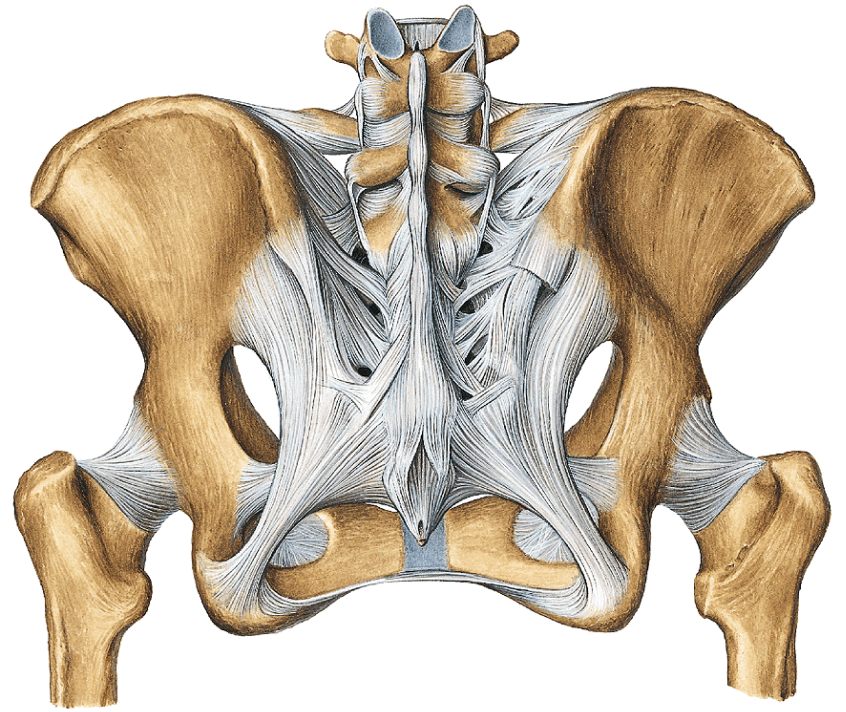
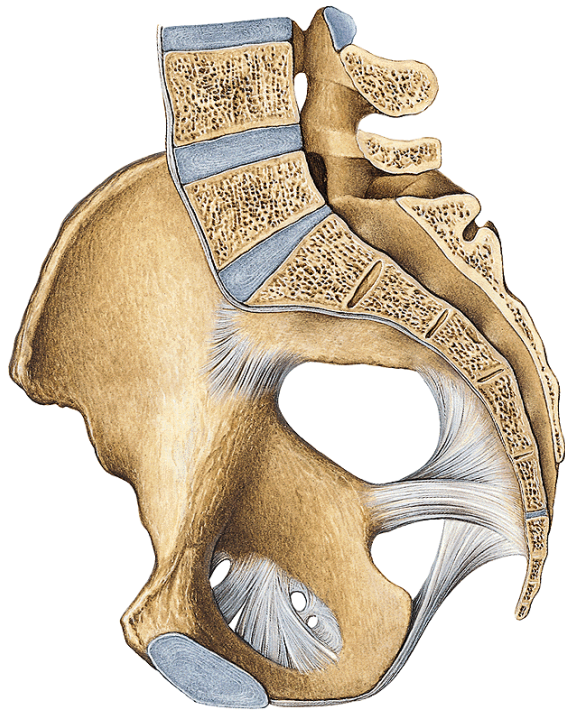
lig. sacrococcygeum anterius

lig. sacrococcygeum posterius

membrana obturatoria

canalis obturatorius





Pelvis as a whole:

Linea terminalis separates the large and small pelvis from each other.

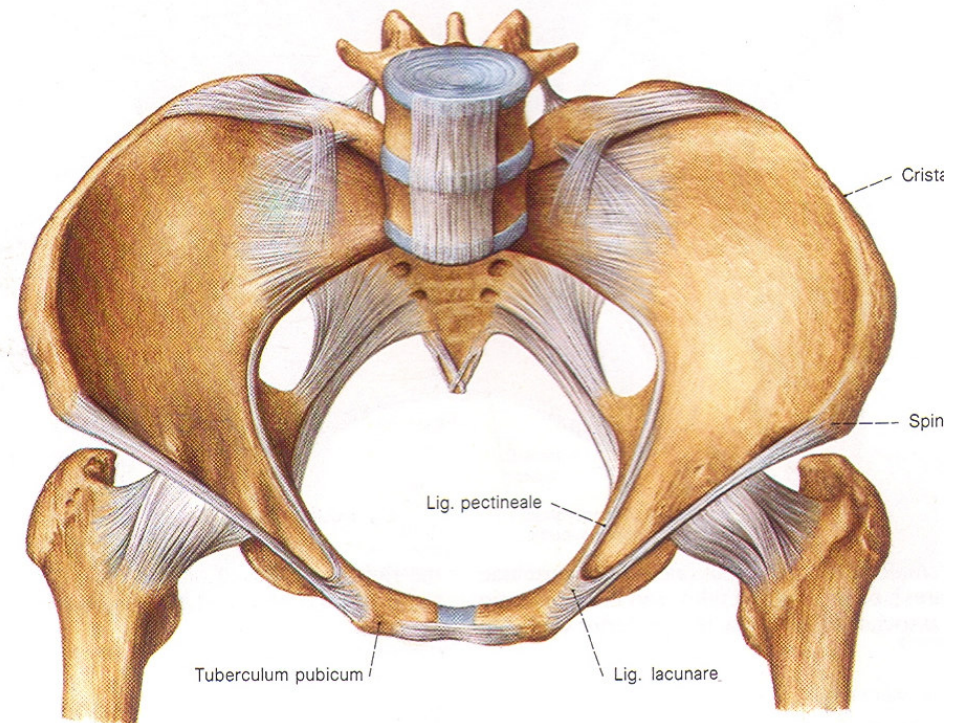
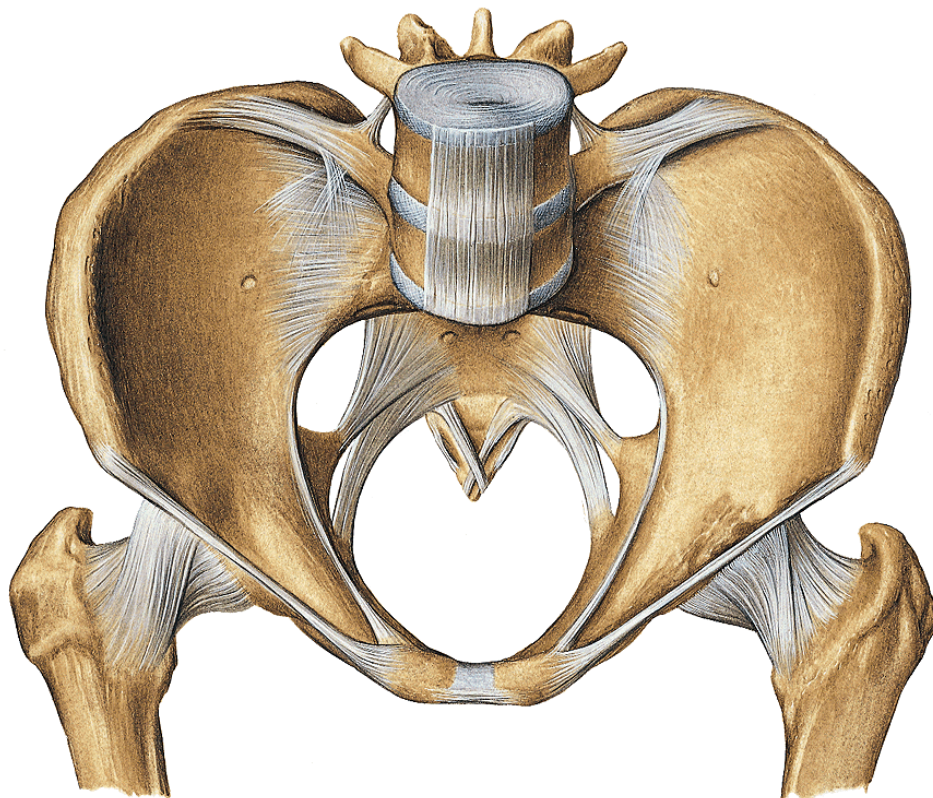
Pelvis major is a part of abdominal cavity

Pelvis minor contains a part of organs of genital and urinary systems.

The small pelvis in the woman presents important birth canal. In connection with this function, there are significant gender differences on the pelvis.

Male pelvis is higher and narrower

Female pelvis is lower and wider



Gender differences of pelvis

Female pelvis:

sacrum wider and shorter,

promontorium protrudes less into the **entrance**- oval shaped,

coccyx shorter and more movable,

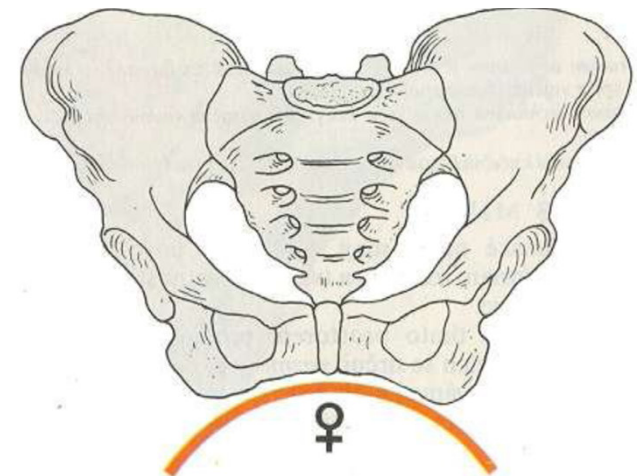
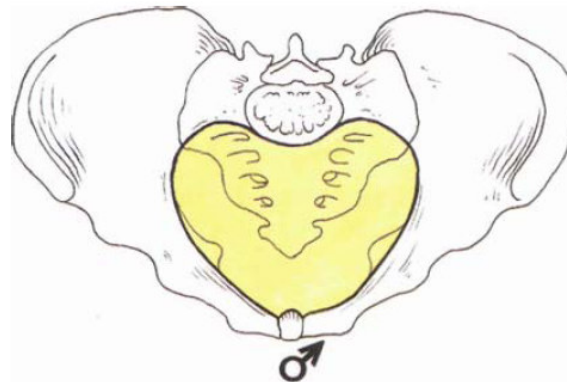
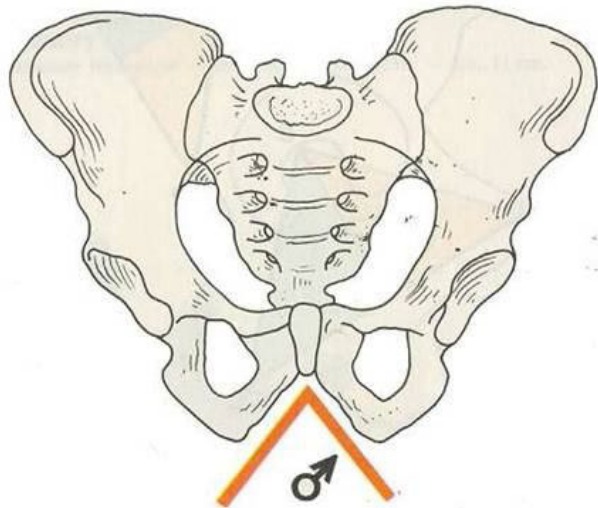
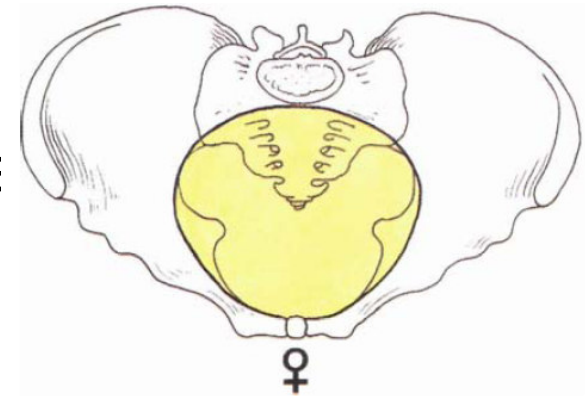
ala ossis illii- in the frontal plane

arcus pubicus

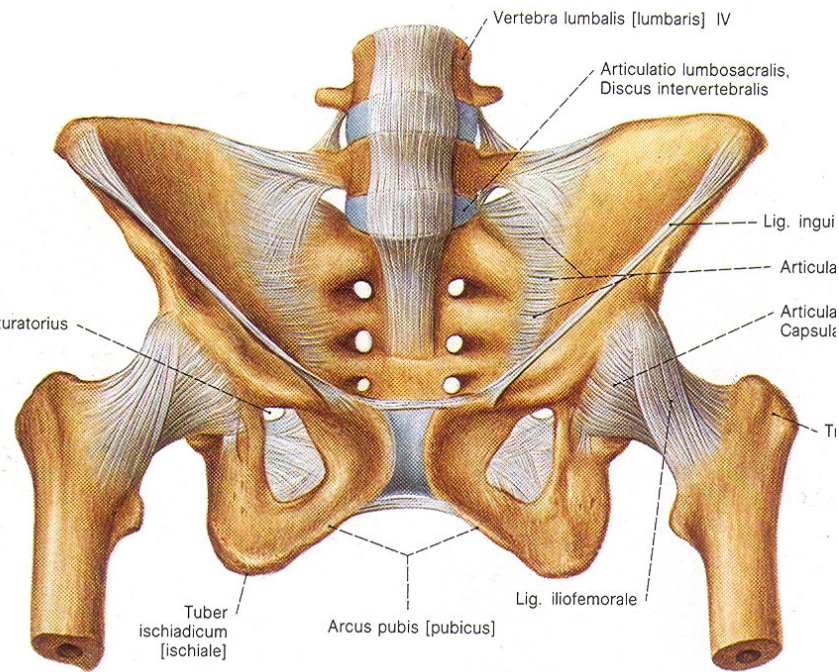
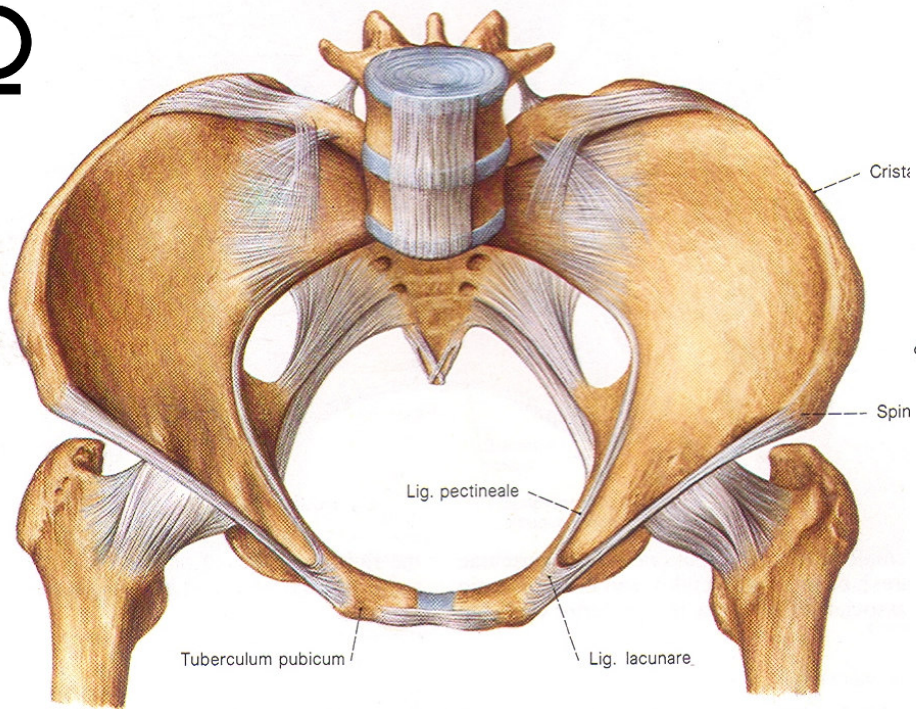
foramen obturatum lower – triangular shape

tubera ischiadica- further from each other

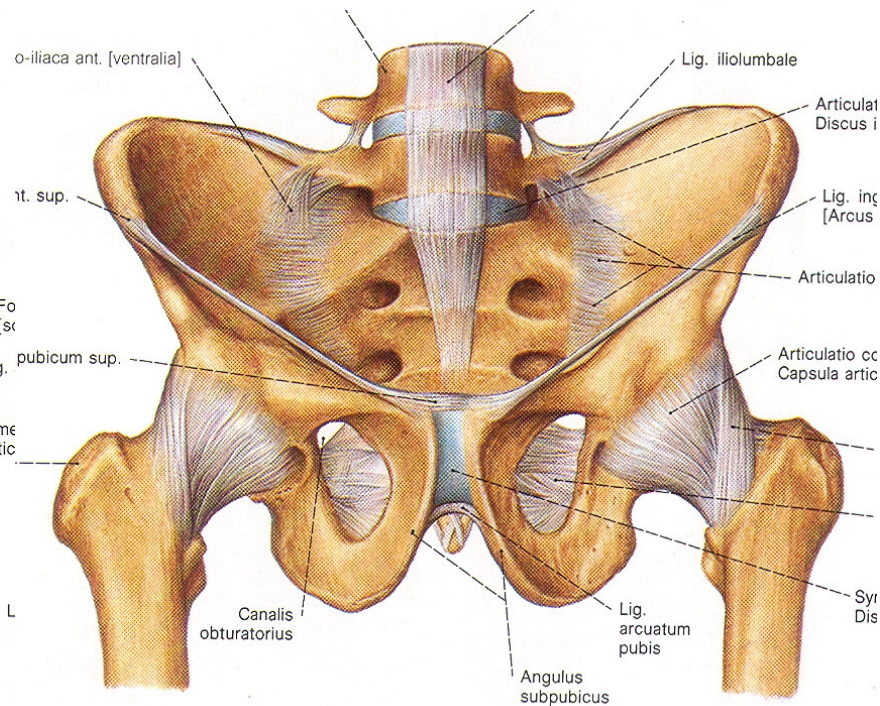
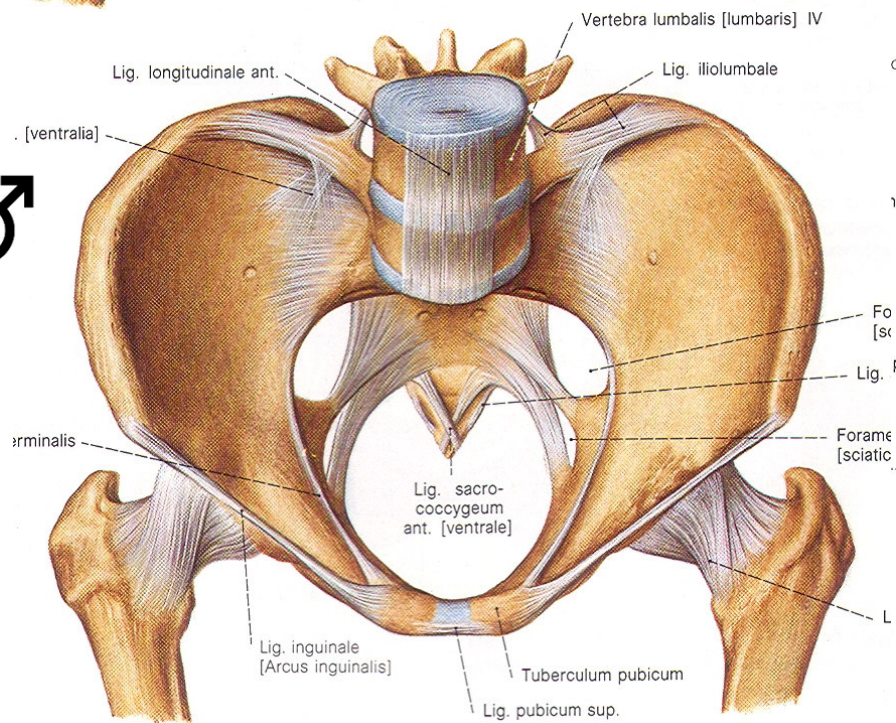
symphysis pubica- lower



♀



♂



Dimensions of the pelvis


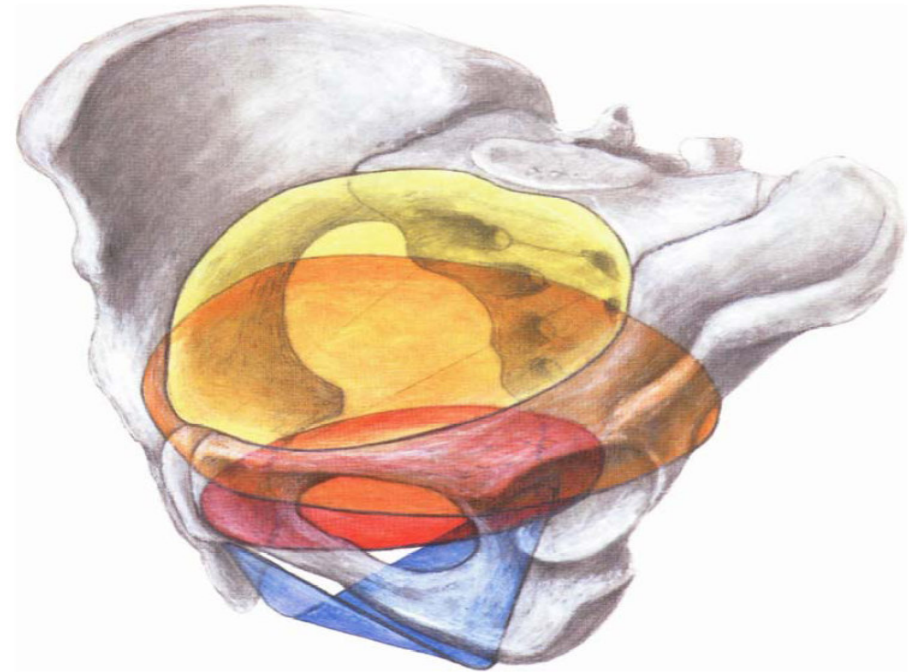
- The largest dimension of newborn skull- **the length - 11,5 cm** must be consistent with dimensions of single **pelvic planes**
- The newborn head rotates during the birth so, that its largest dimension passes through the largest dimension of appropriate **plane**:

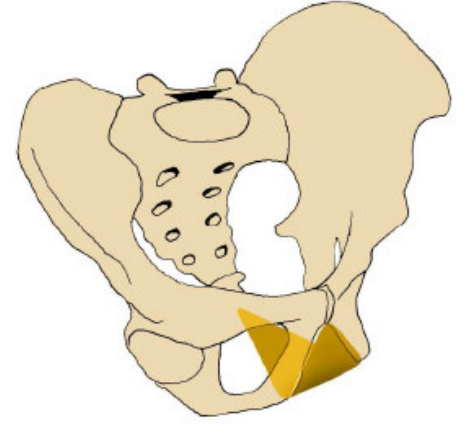
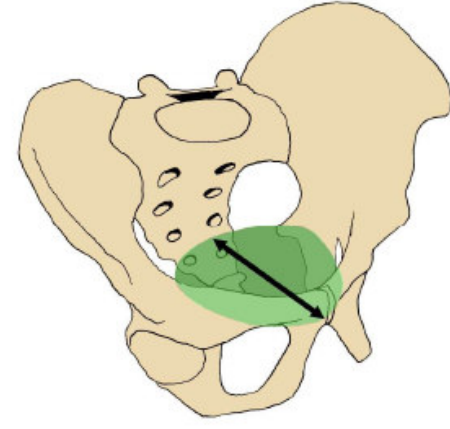
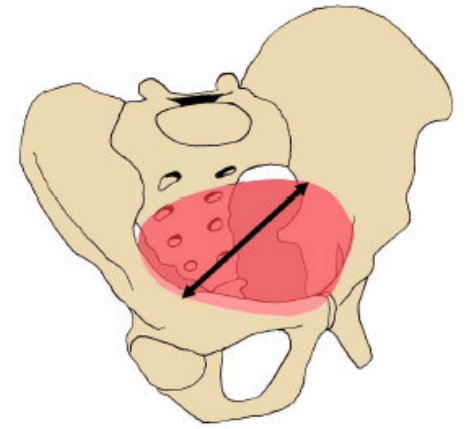
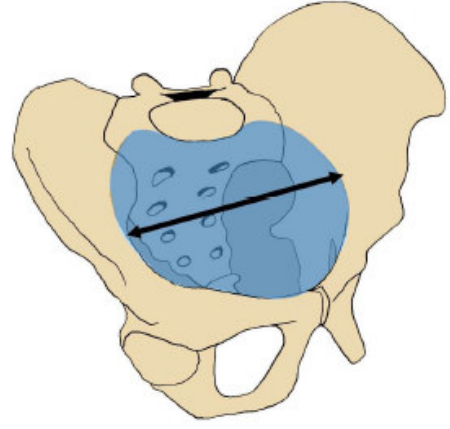
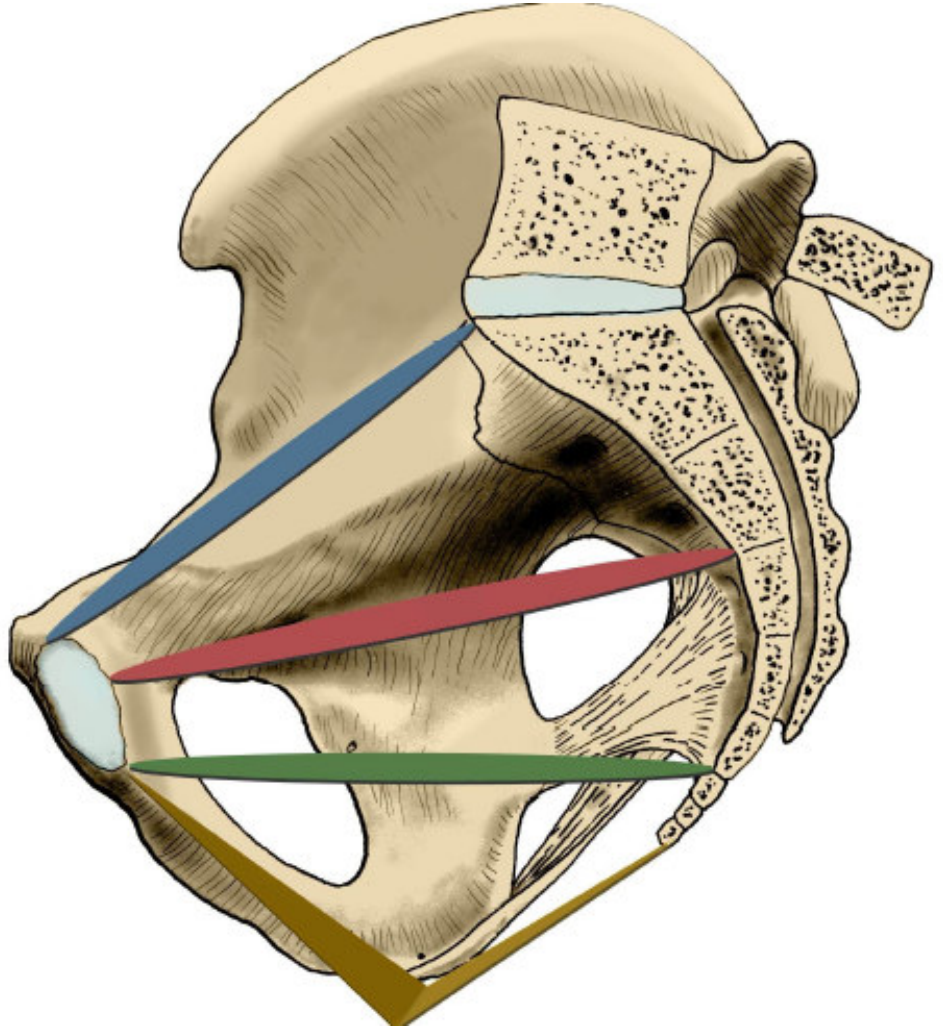
aditus pelvis

amplitudo pelvis

angustia pelvis

exitus pelvis





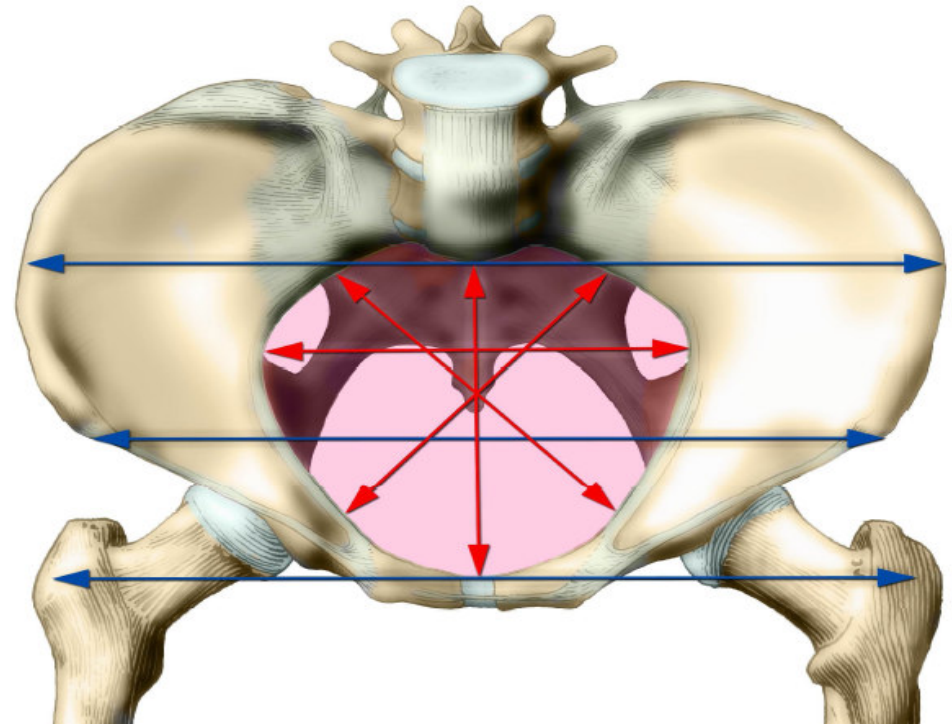
External pelvis dimensions

Distantia bispinalis 26cm

Distantia bicristalis 29cm

Distantia bitrochanterica 31cm

Conjugata externa- upper edge
of symphysis to the spinous
proces of L5: 18 - 20cm



Articulatio coxae

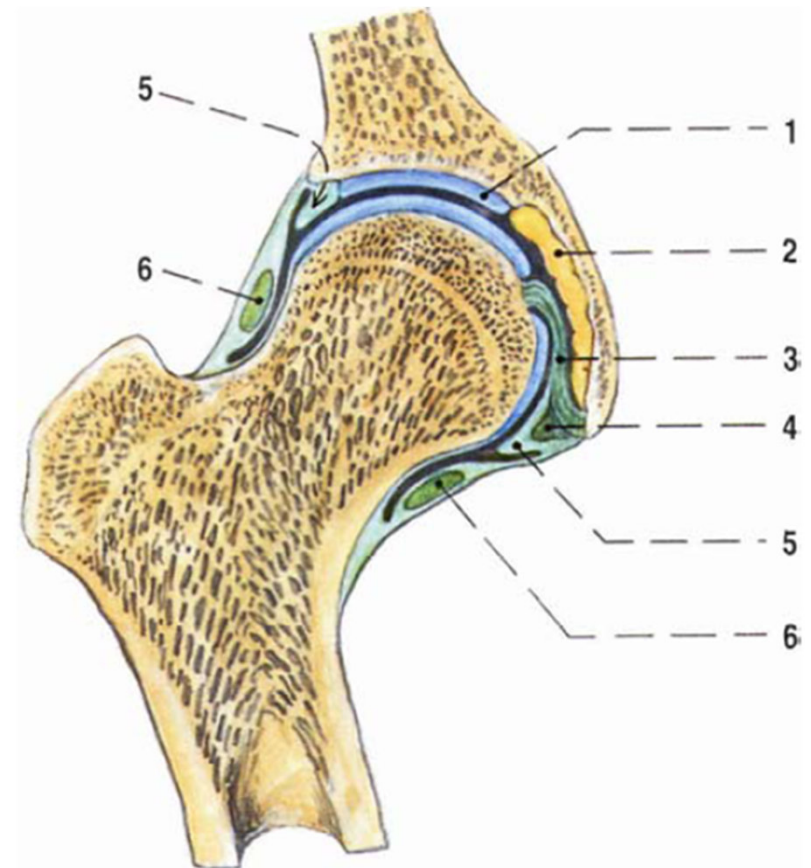
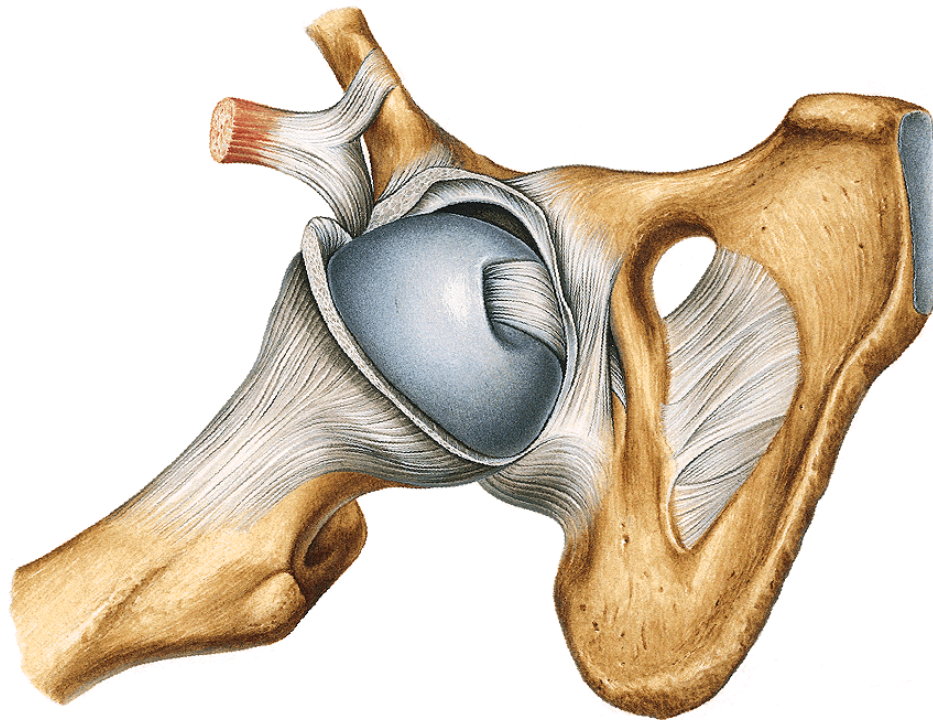
Type: **spherical, restricted – enarthrosis**

Articular head: **caput femoris**

Articular pit: **facies lunata acetabuli**, enlarged by **labrum acetabuli**, **pulvinar acetabuli**

Articular capsule:

**From margins of acetabulum
ventrally to linea intertrochanterica
dorsally to collum femoris**



Ligaments:

lig. transversum acetabuli

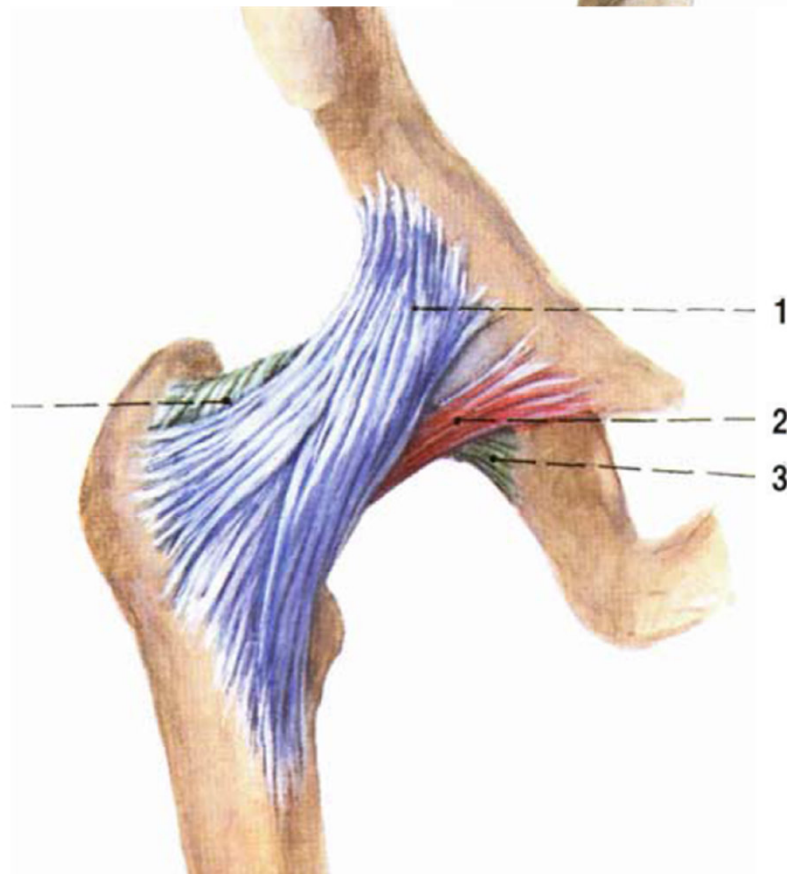
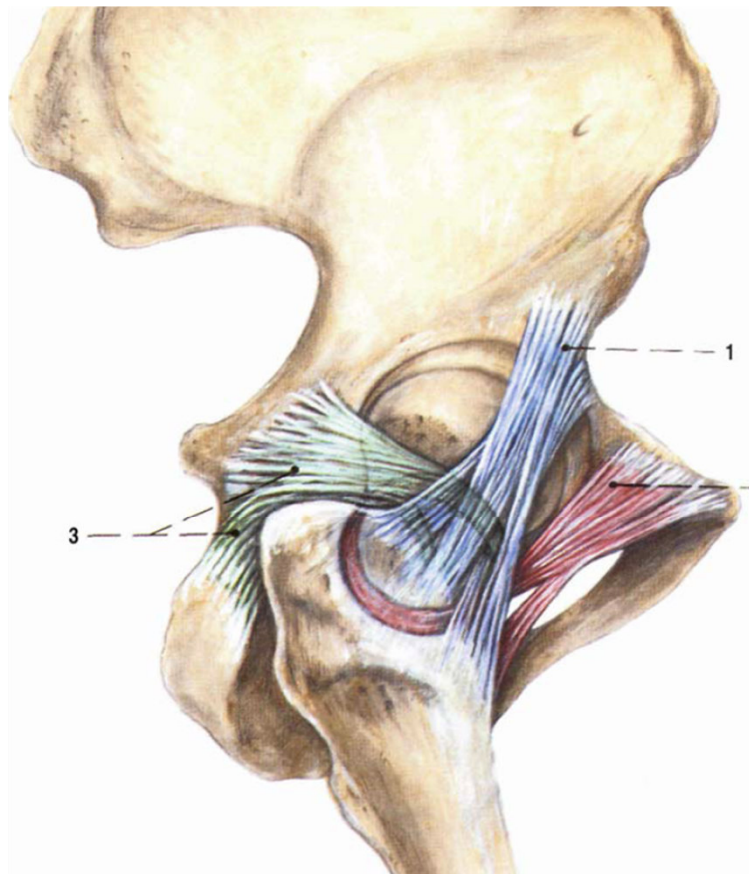
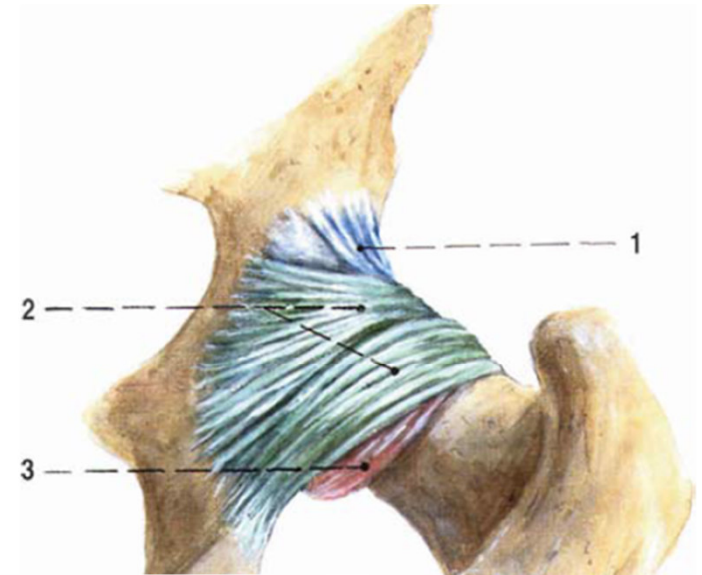
lig. iliofemorale

lig. pubofemorale

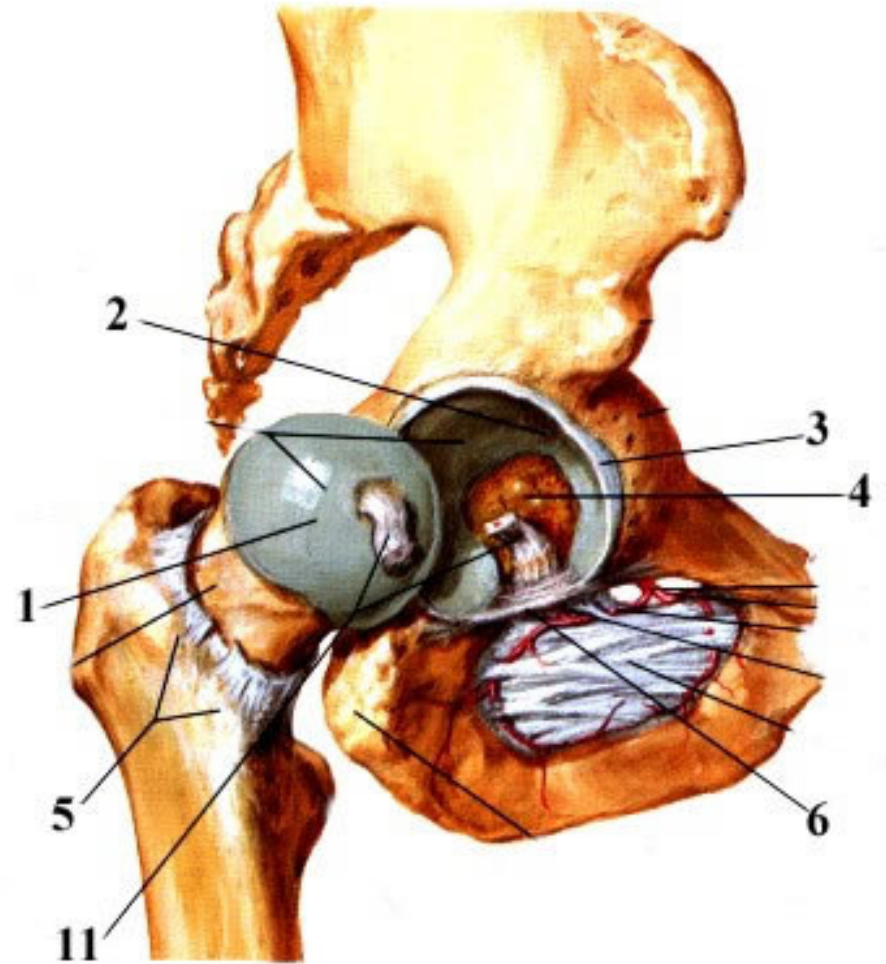
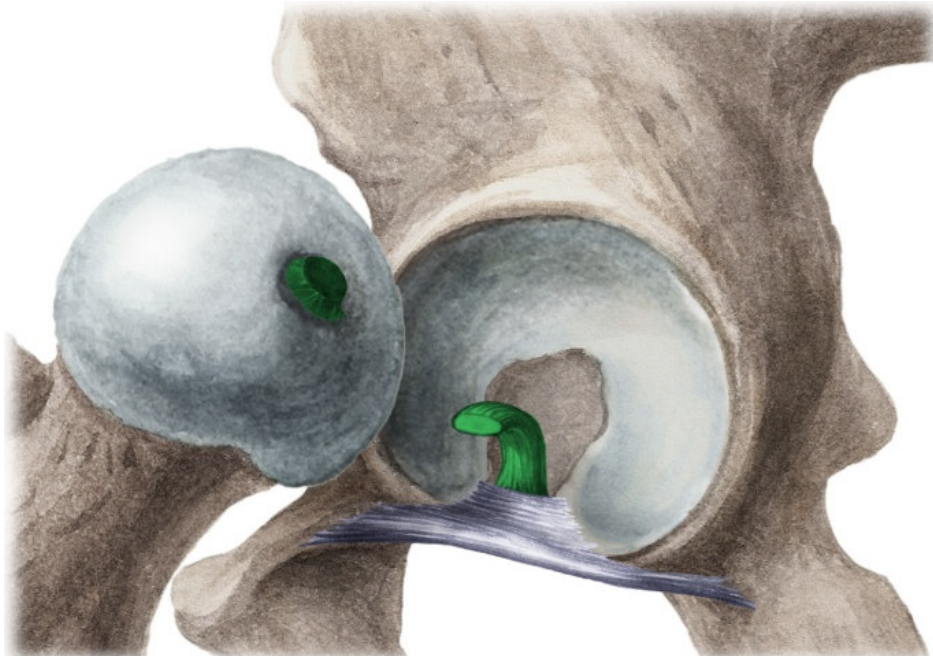
lig. ischiofemorale

lig. capitis femoris

} **zona orbicularis**



Movements:
flexion, extension
abduction, adduction
rotation



Articulatio genus

Type: **composed joint, trochlear**

Tibio-femoral part:

Articular head: **condyli femoris**

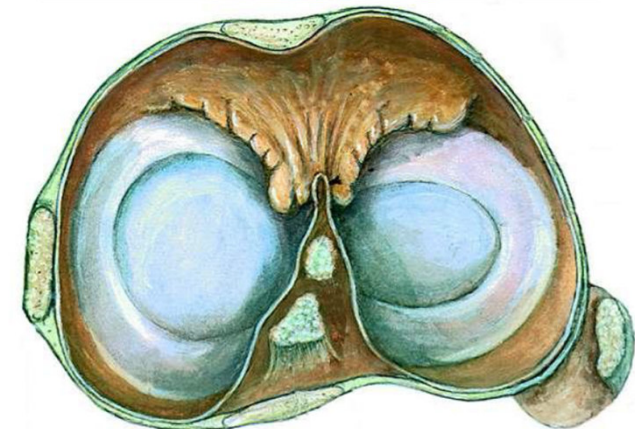
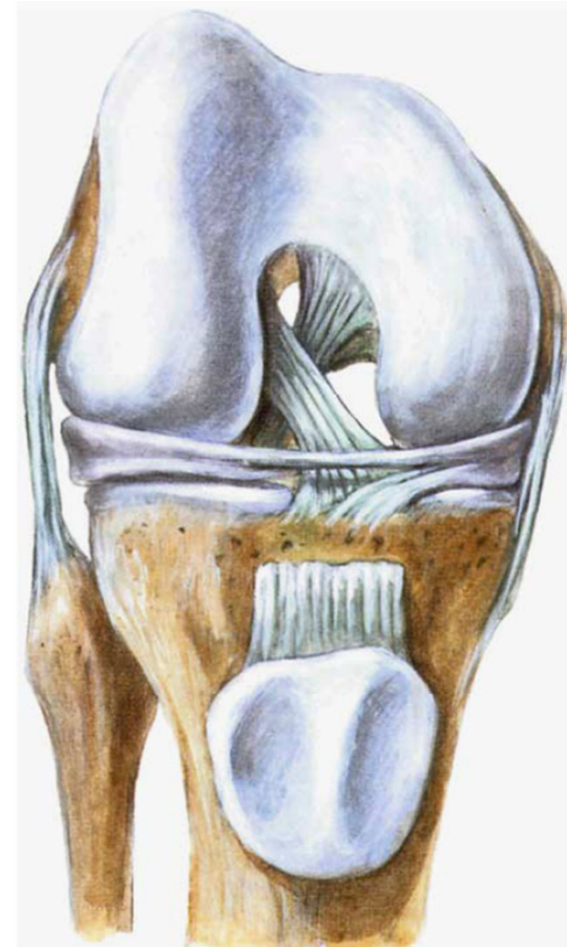Articular pit: **facies articulares superiores tibiae, meniscus medialis, meniscus lateralis**

Patello-femoral part:

Articular head: **facies articulares patellae**

Articular pit: **facies patellaris femoris**

Articular capsule: **fibrous and synovial layers**



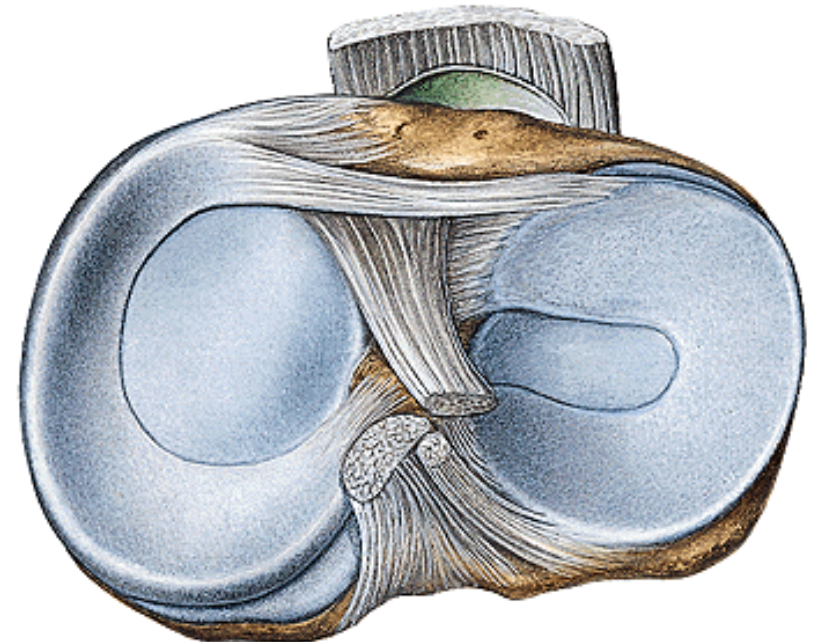
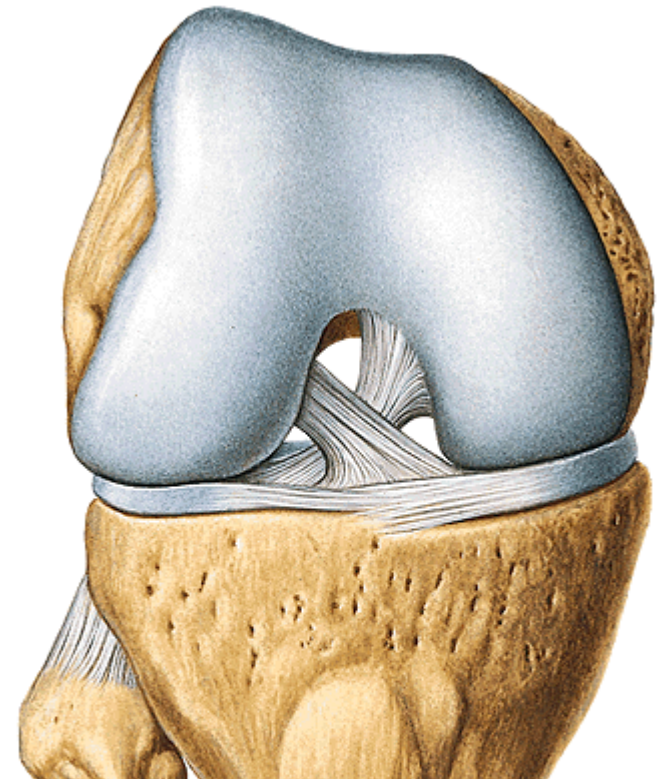
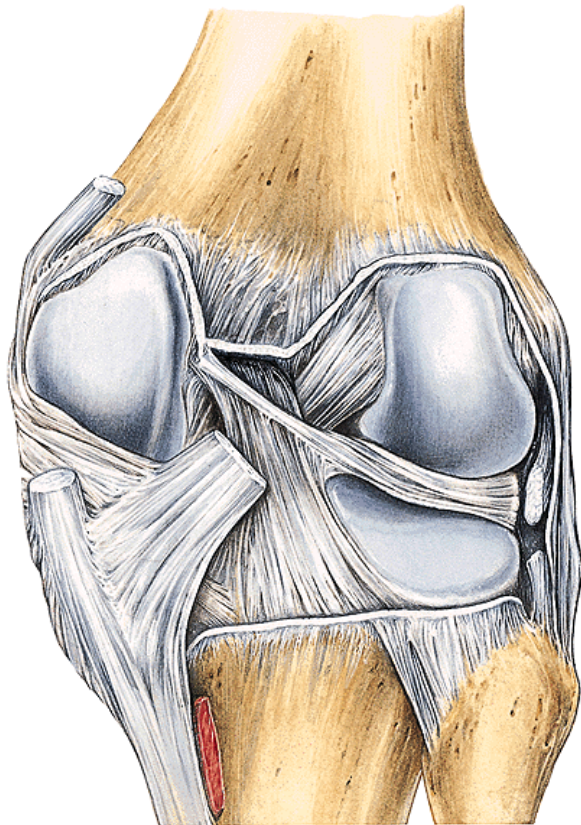
Ligaments:

a) intraarticular

lig. cruciatum anterius

lig. cruciatum posterius

lig. transversum genus



b) extraarticular

Tendon of m. quadriceps femoris - lig. patellae

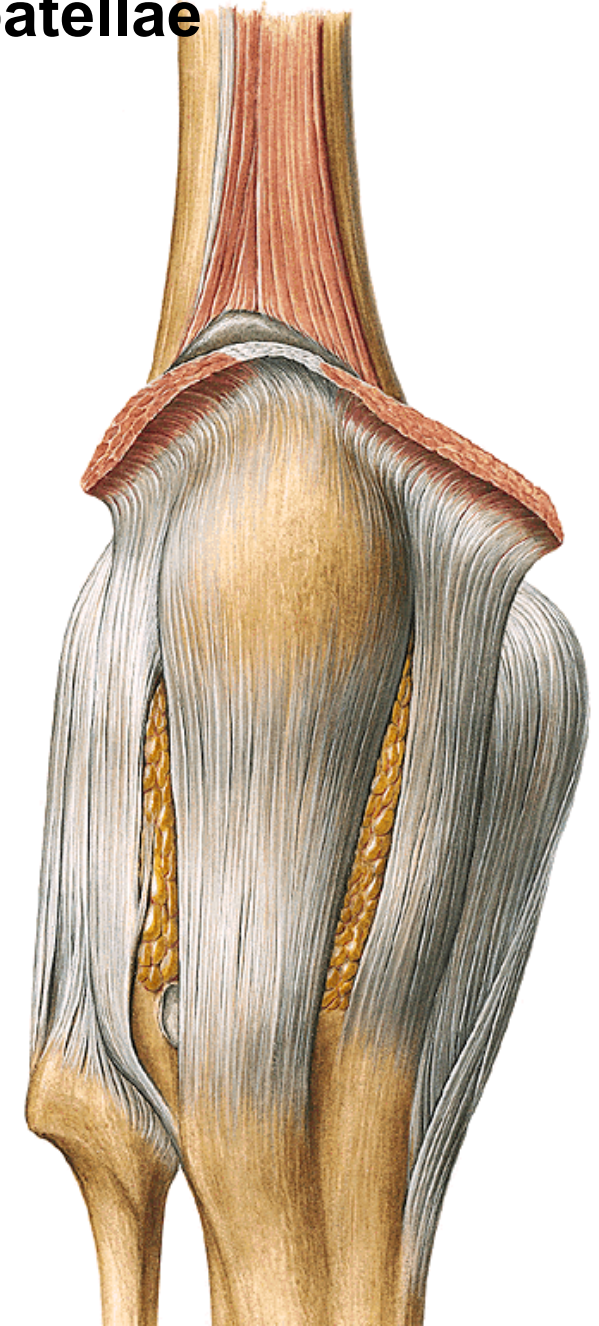
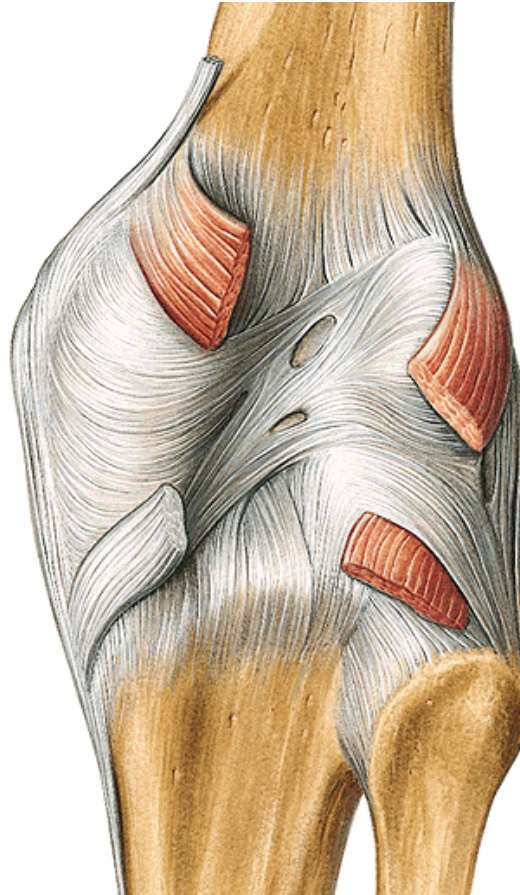
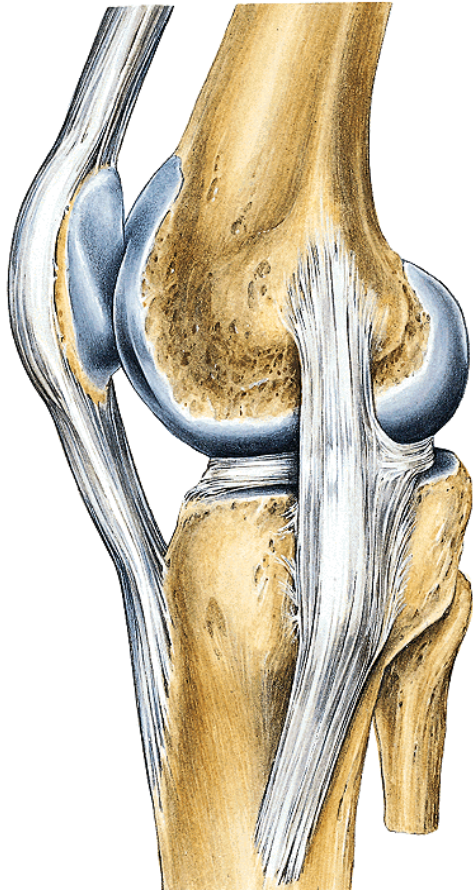
retinaculum patellae mediale

retinaculum patellae laterale

lig. collaterale fibulare

lig. collaterale tibiale

lig. popliteum obliquum



Synovial layer:

plica synovialis patellaris

plicae alares

corpus adiposum infrapatellare

Bursae:

b. suprapatellaris

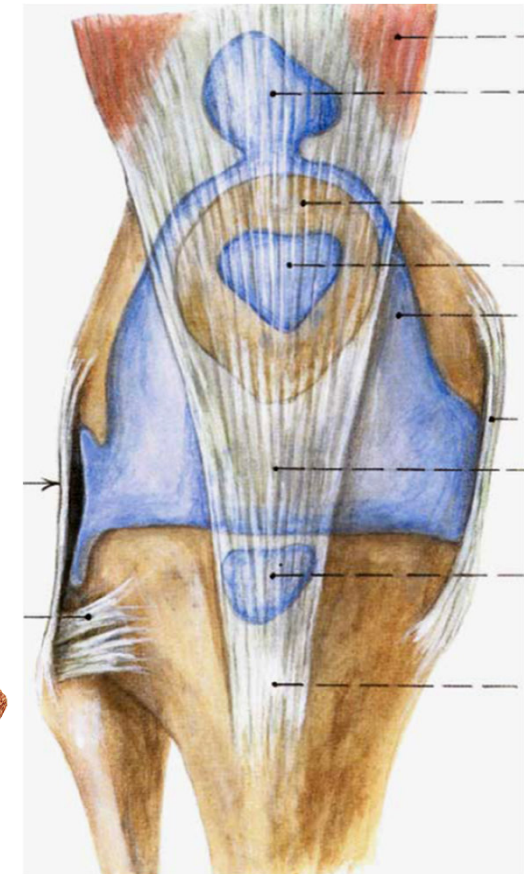
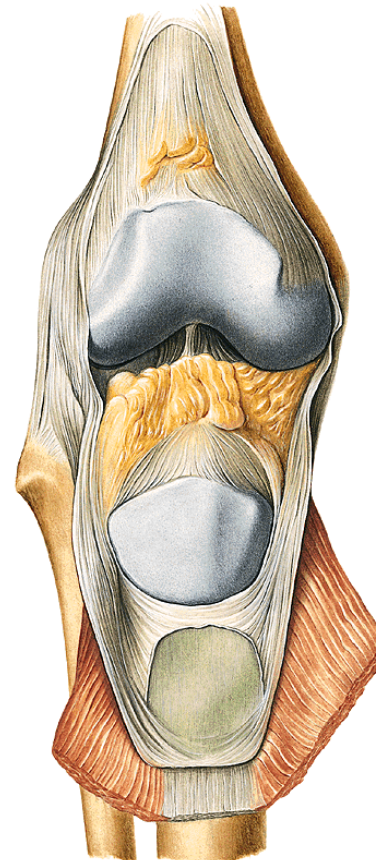
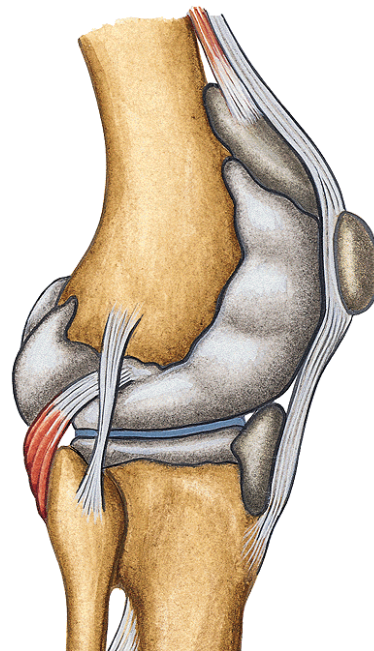
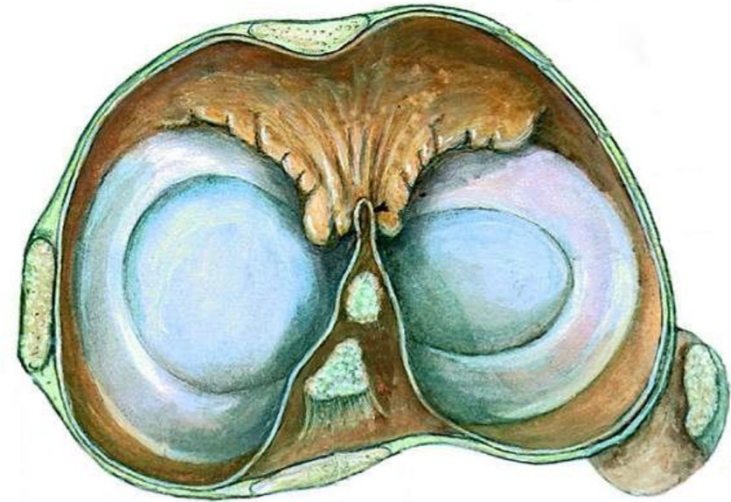b. profunda infrapatellaris

b. prepatellaris subcutanea

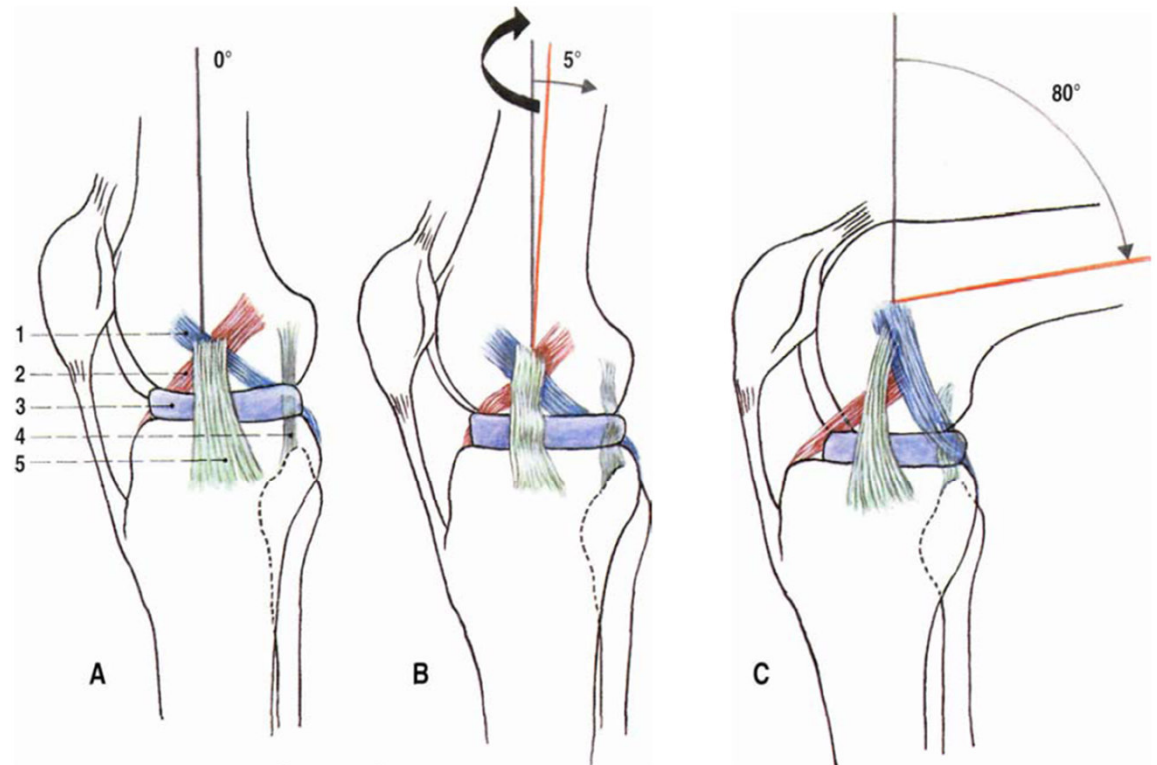
b. infrapatellaris subcutanea

b. prepatellaris subtendinea

b. anserina

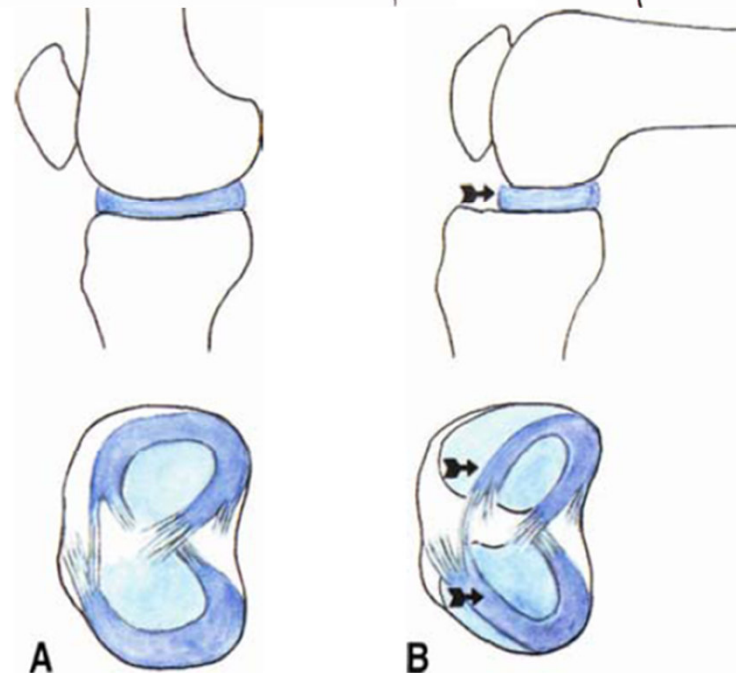


Movements:

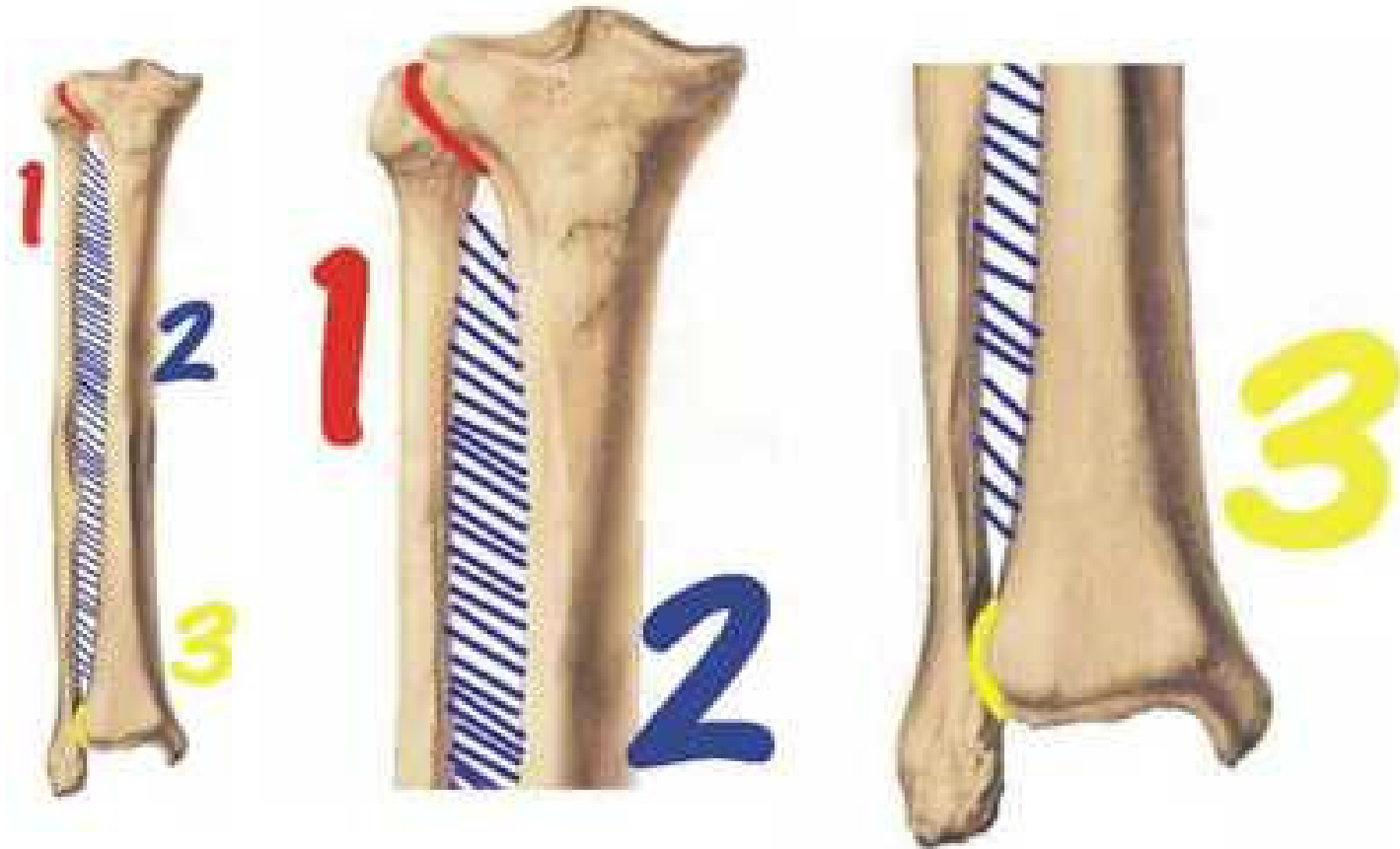


Flexion/extension - 4 phases:

- 1. Initial rotation**
- 2. Rolling movement**
- 3. Slide movement**
- 4. Final rotation**



Connections of tibia and fibula



Articulatio tibiofibularis

Type: plane joint

Articular surfaces: **facies articularis tibiae**

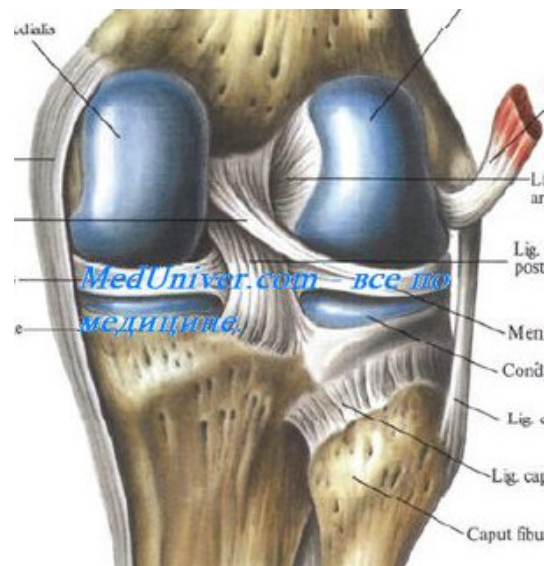
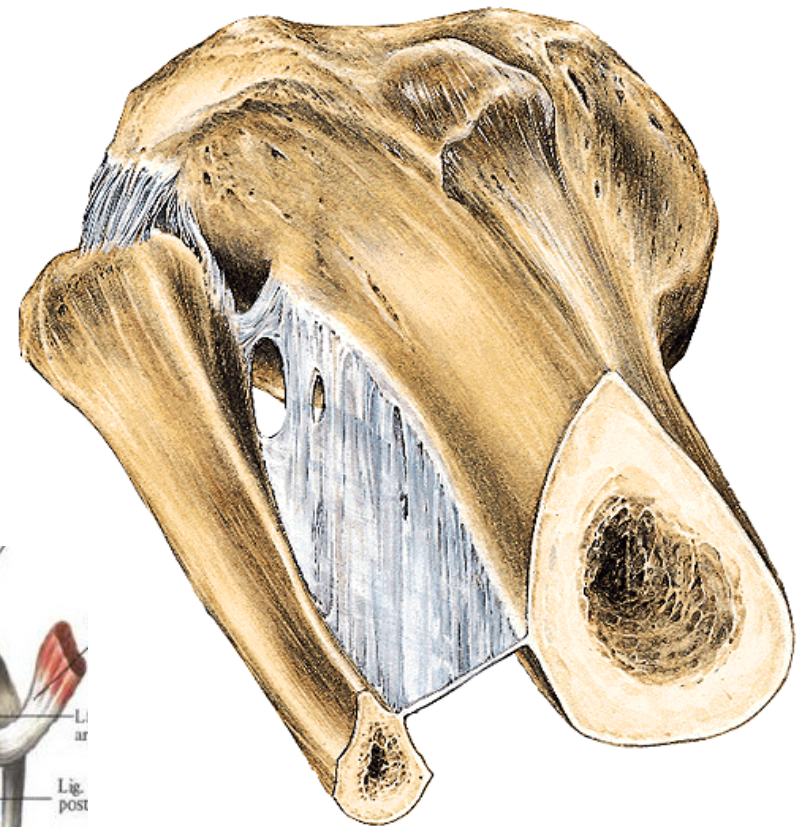
facies articularis capitis fibulae

Articular capsule: short, tough

Ligaments:

- **lig. capitis fibulae anterior**
- **lig. capitis fibulae posterior**

Movements: sliding, minimal



Membrana interossea cruris

Fibrous membrane between **margo interosseus** of tibia and **margo interosseus** of fibula.

Syndesmosis tibiofibularis

Type: fibrous connection

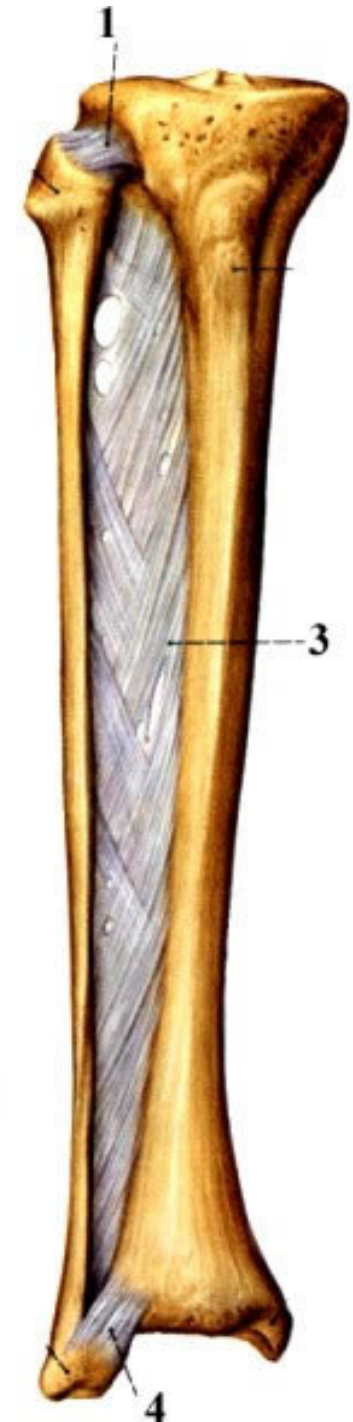
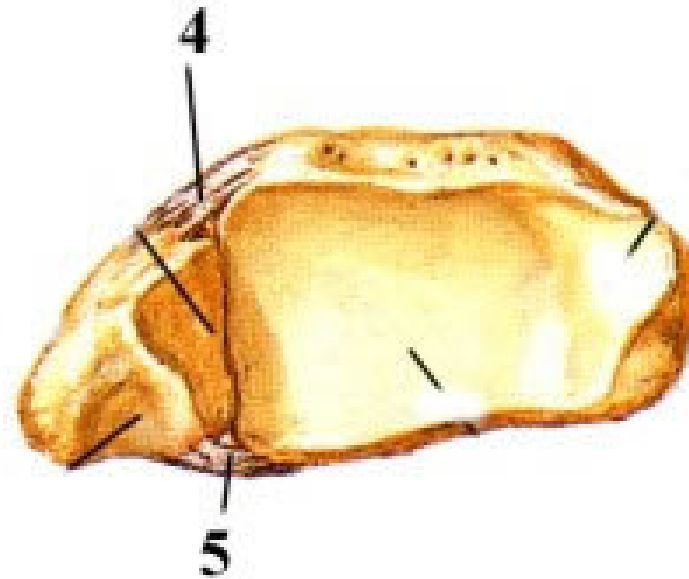
Surfaces: **incisura fibularis tibiae**,
distal end of fibula

Ligaments:

lig. tibiofibulare anterius

lig. tibiofibulare posterius

Movements: minimal



Articulatio talocruralis

Type: **composed, trochlear joint**

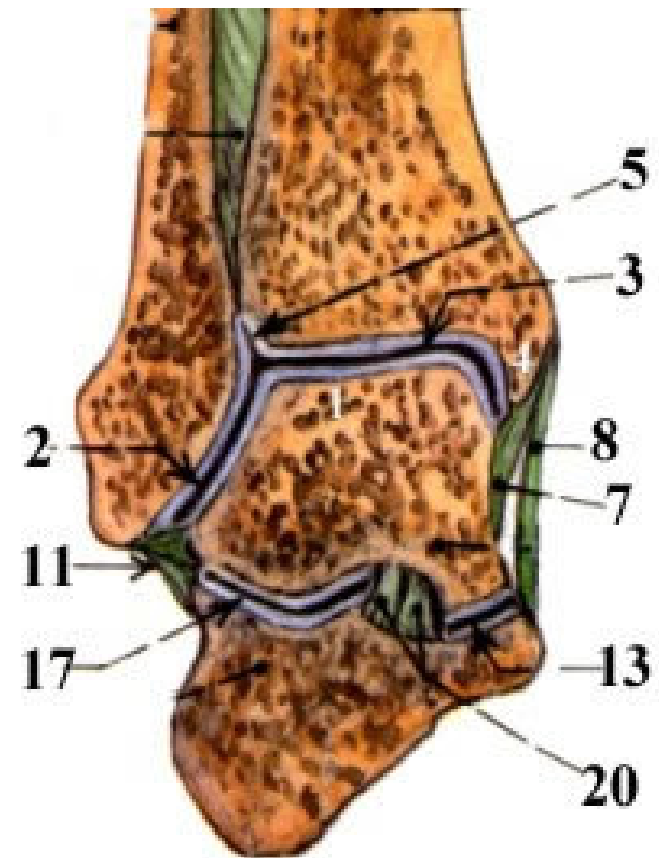
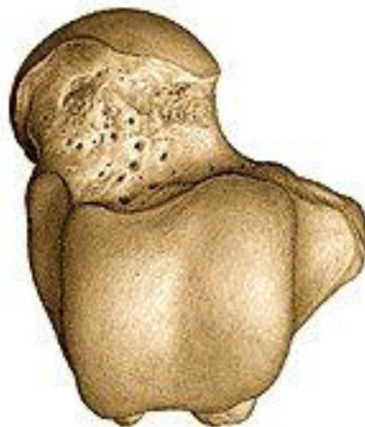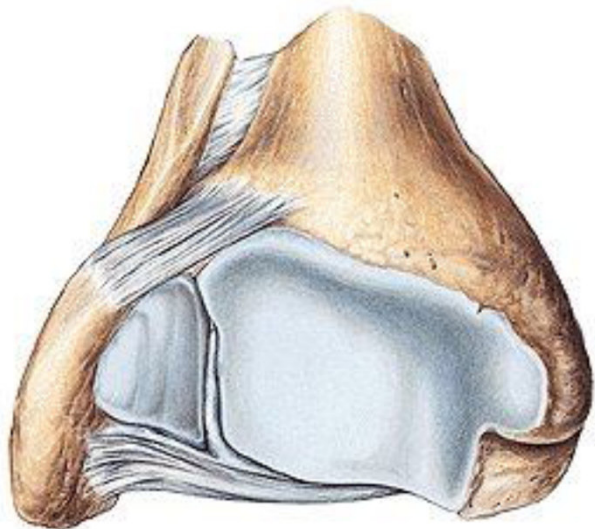
Articular head: **trochlea tali**

Articular pit: **facies articularis malleoli lateralis, facies articularis inferior tibiae et facies articularis malleoli medialis - tibiofibular fork**

Articular capsule: **it is attached to margins of articular surfaces**

Movements:

plantar and dorsal flexion



Ligaments:

lig. collaterale mediale = lig. deltoideum

pars tibionavicularis

pars tibiotalaris anterior

pars tibiocalcanearis

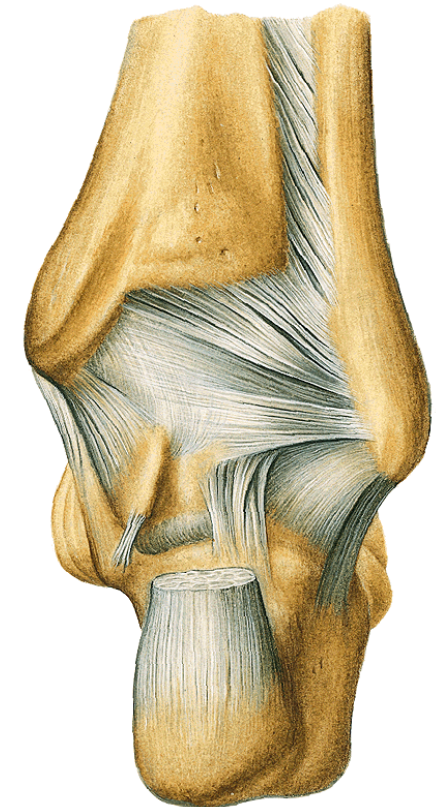
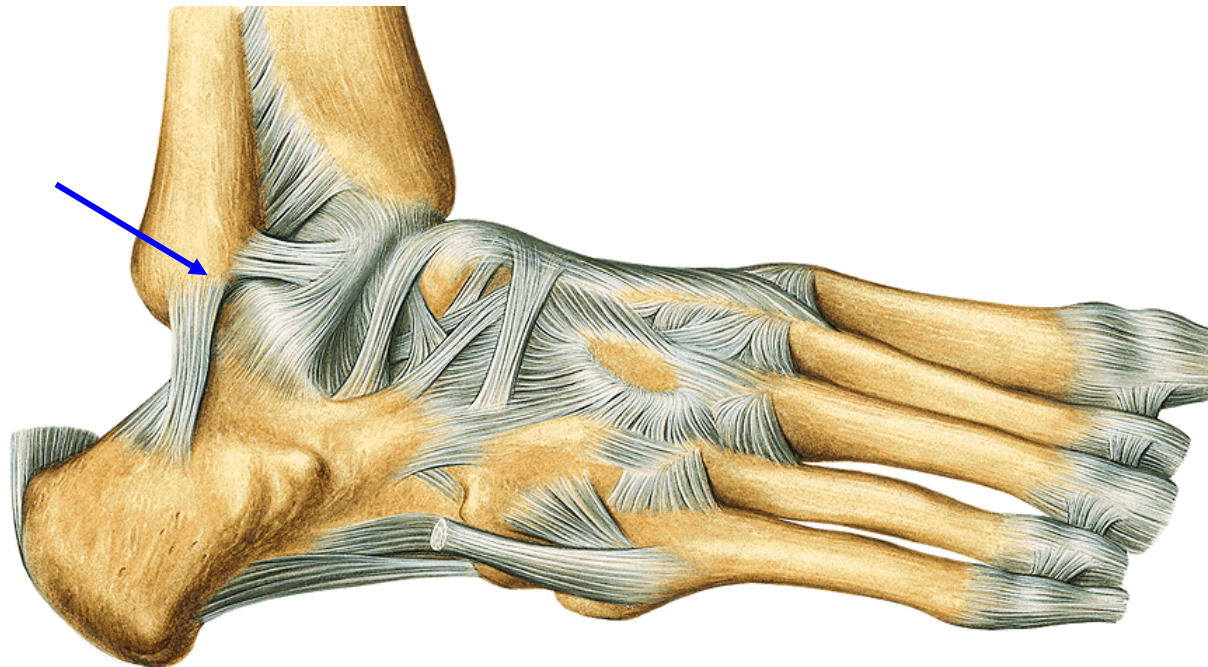
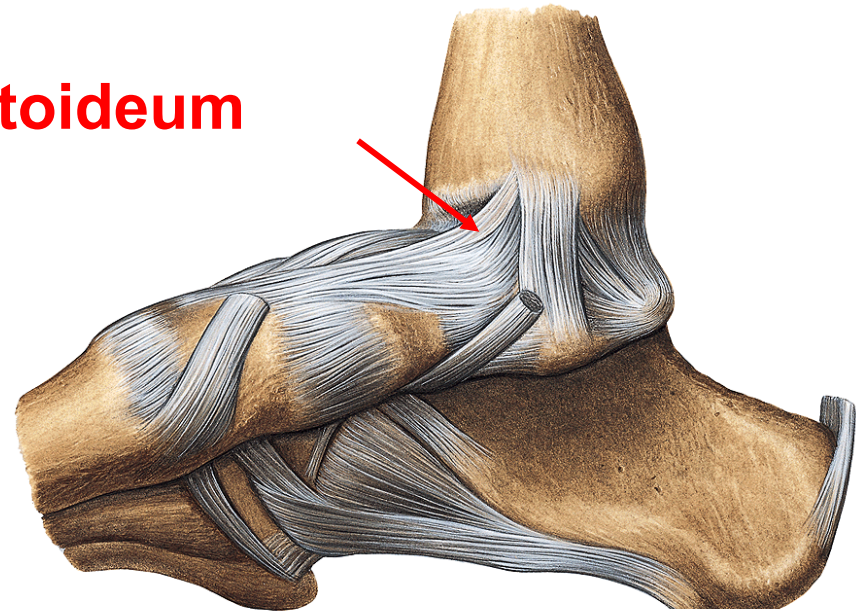
pars tibiotalaris posterior

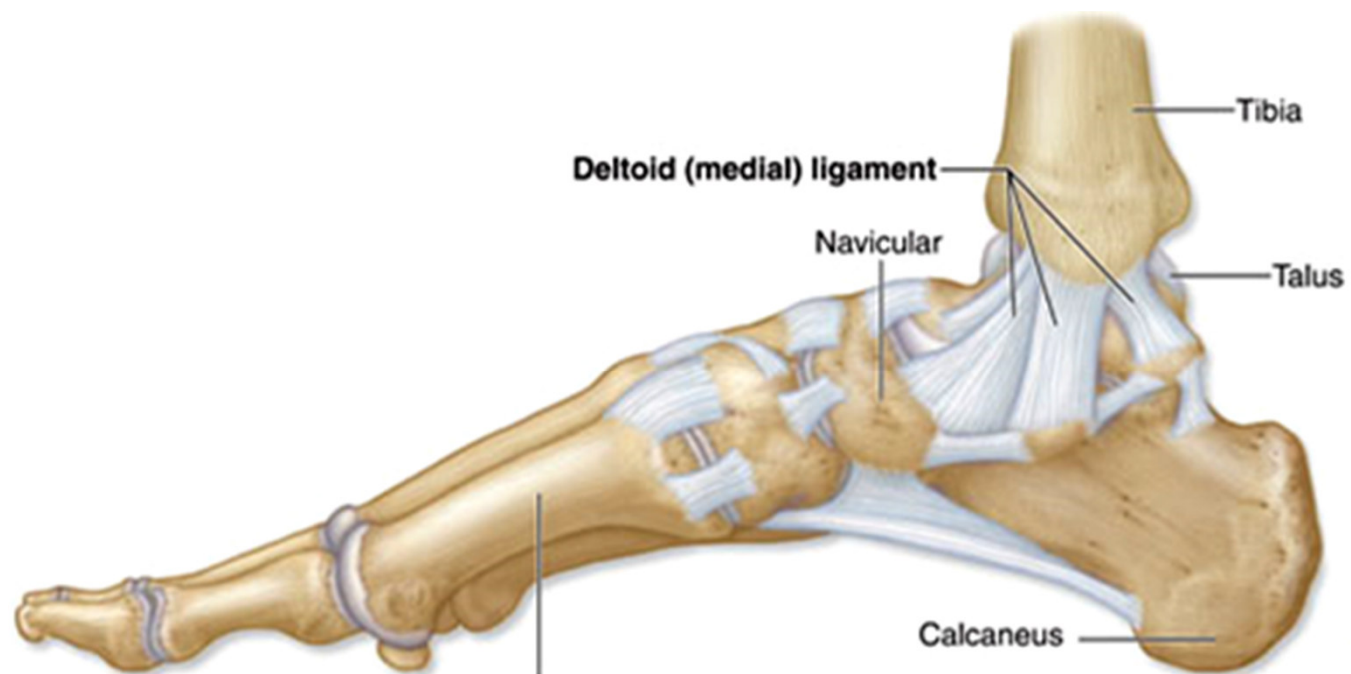
lig. collaterale laterale

lig. talofibulare anterius

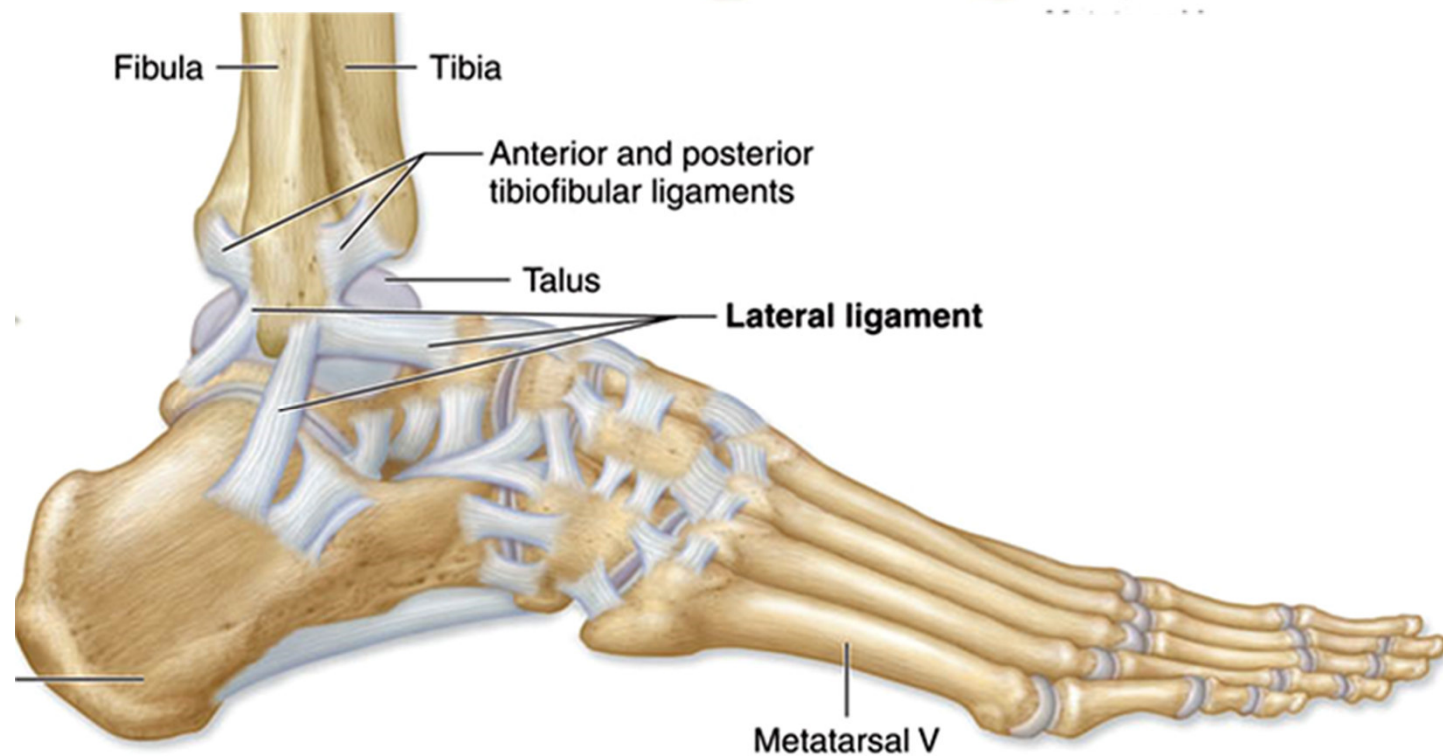
lig. calcaneofibulare

lig. talofibulare posterius





Mi



Articulatio subtalaris (talocalcanea)

Typ: cylindrical joint

Articular head: **facies articularis talaris posterior calcanei**

Articular pit: **facies articularis calcanearis posterior tali**

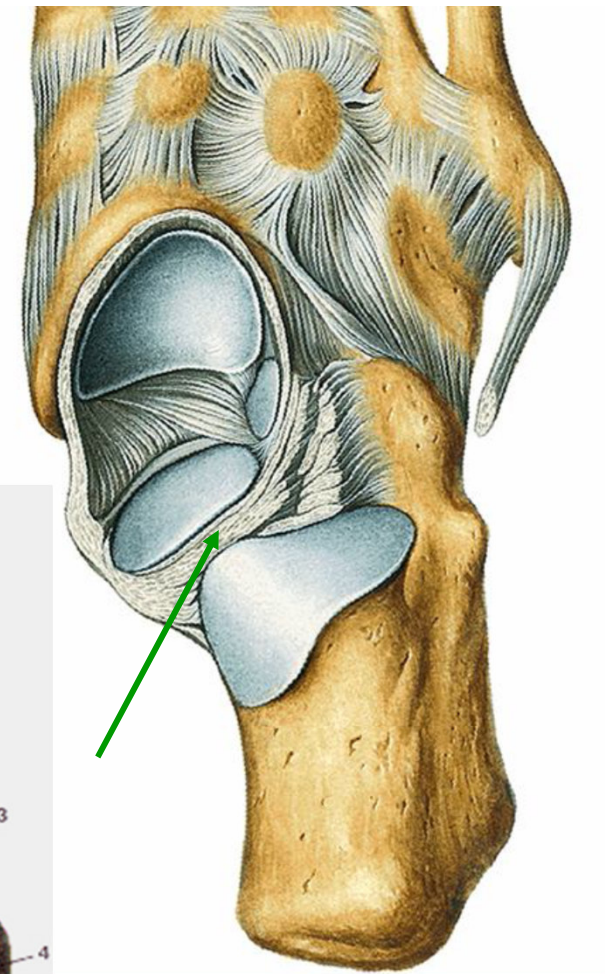
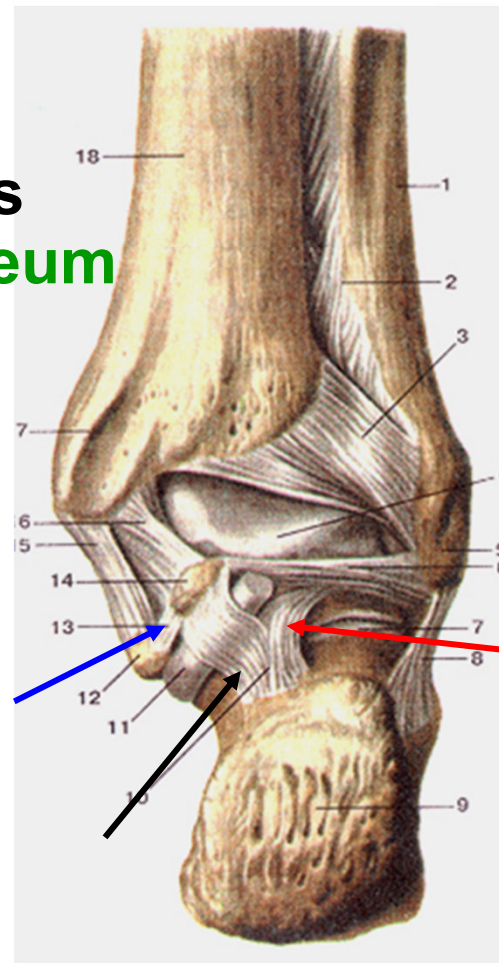
Ligaments:

lig. talocalcaneum laterale

lig. talocalcaneum mediale

lig. talocalcaneum posterius

lig. talocalcaneum interosseum
(within sinus tarsi)



Articulatio talocalcaneonavicularis

Type: spherical joint

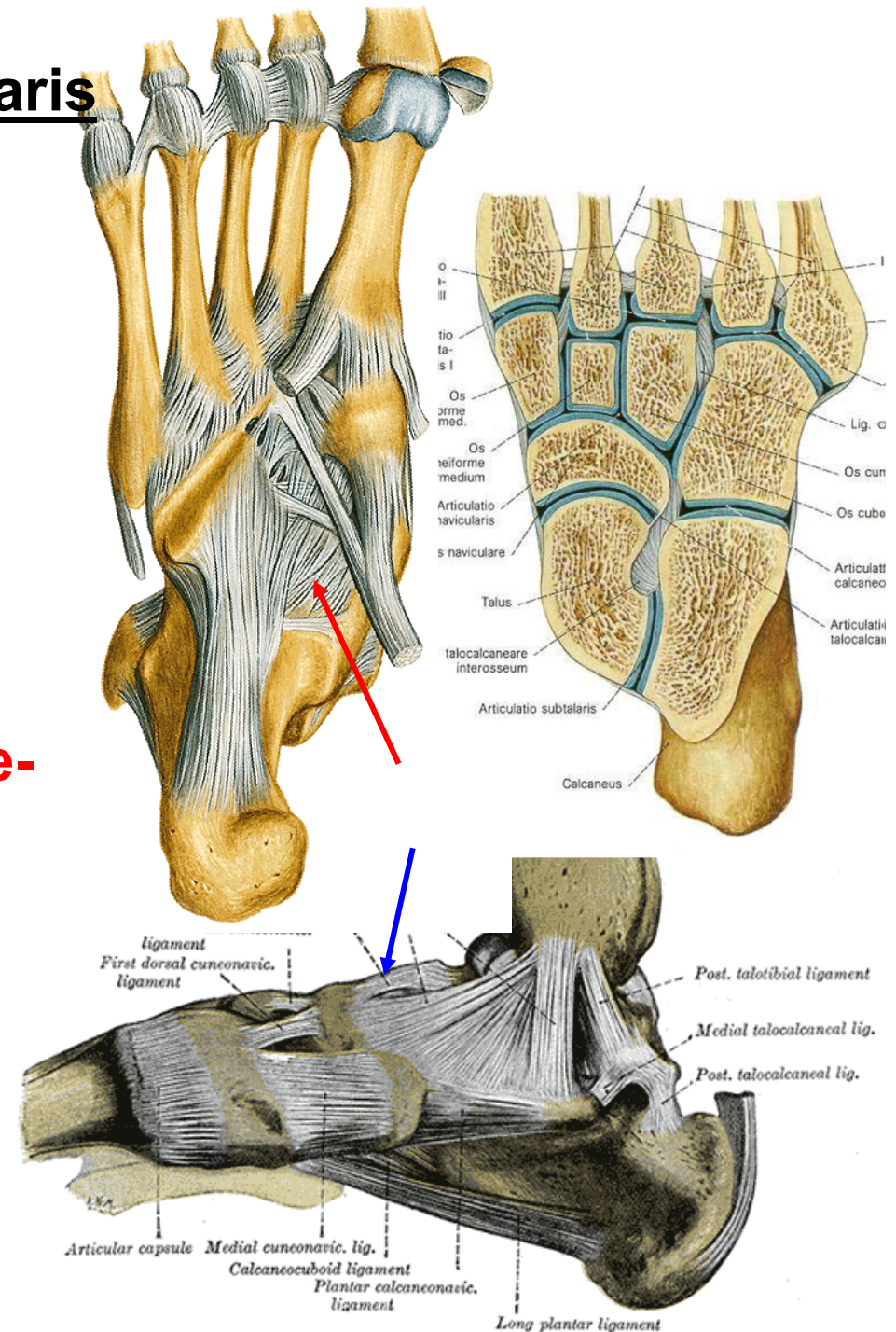
Articular head: caput tali, facies articularis calcanea media et anterior tali

Articular pit: os naviculare, facies articularis talaris media et anterior calcanei, fibrocartilago navicularis

Ligaments:

lig. calcaneonaviculare plantare-fibrocartilago navicularis

lig. talonaviculare dorsale



Articulatio calcaneocuboidea

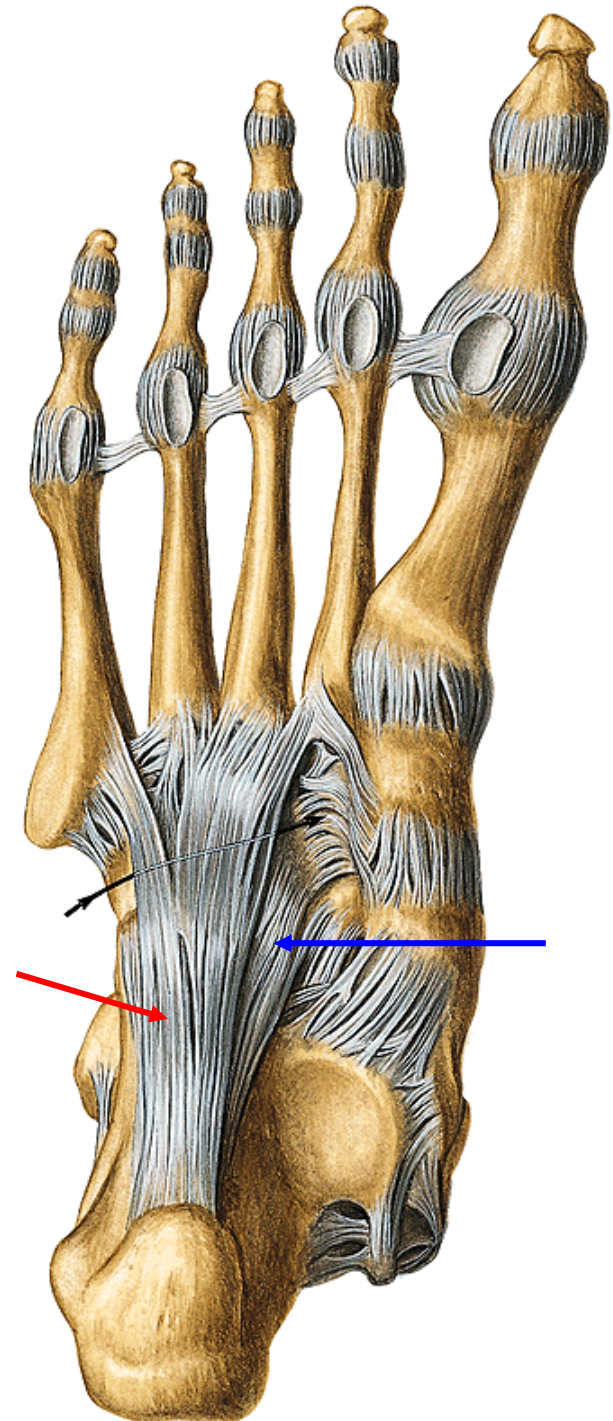
Type: amphiarthrosis

Articular surfaces: **facies articularis cuboidea calcanei, os cuboideum**

Ligaments:

lig. calcaneocuboideum plantare

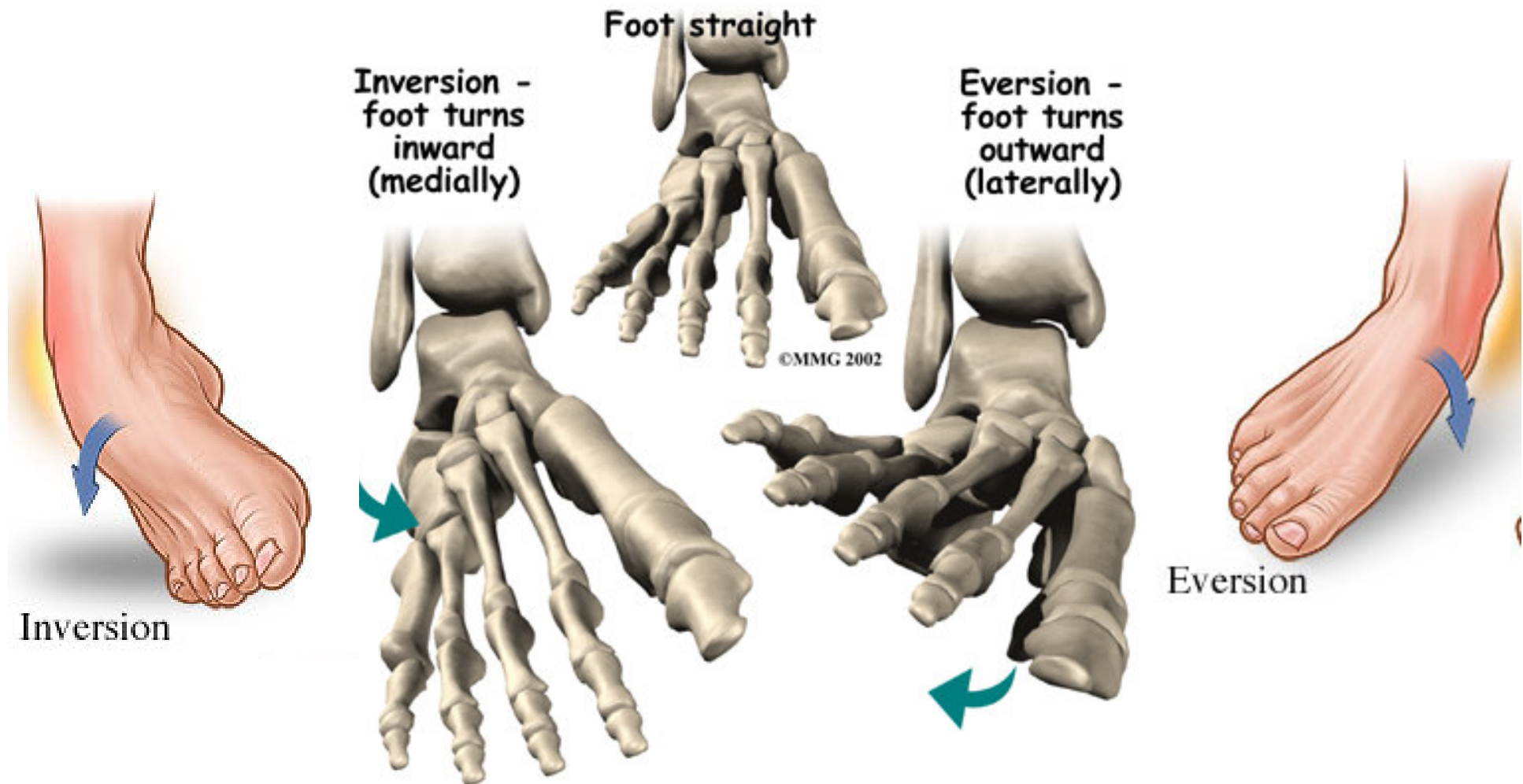
lig. plantare longum

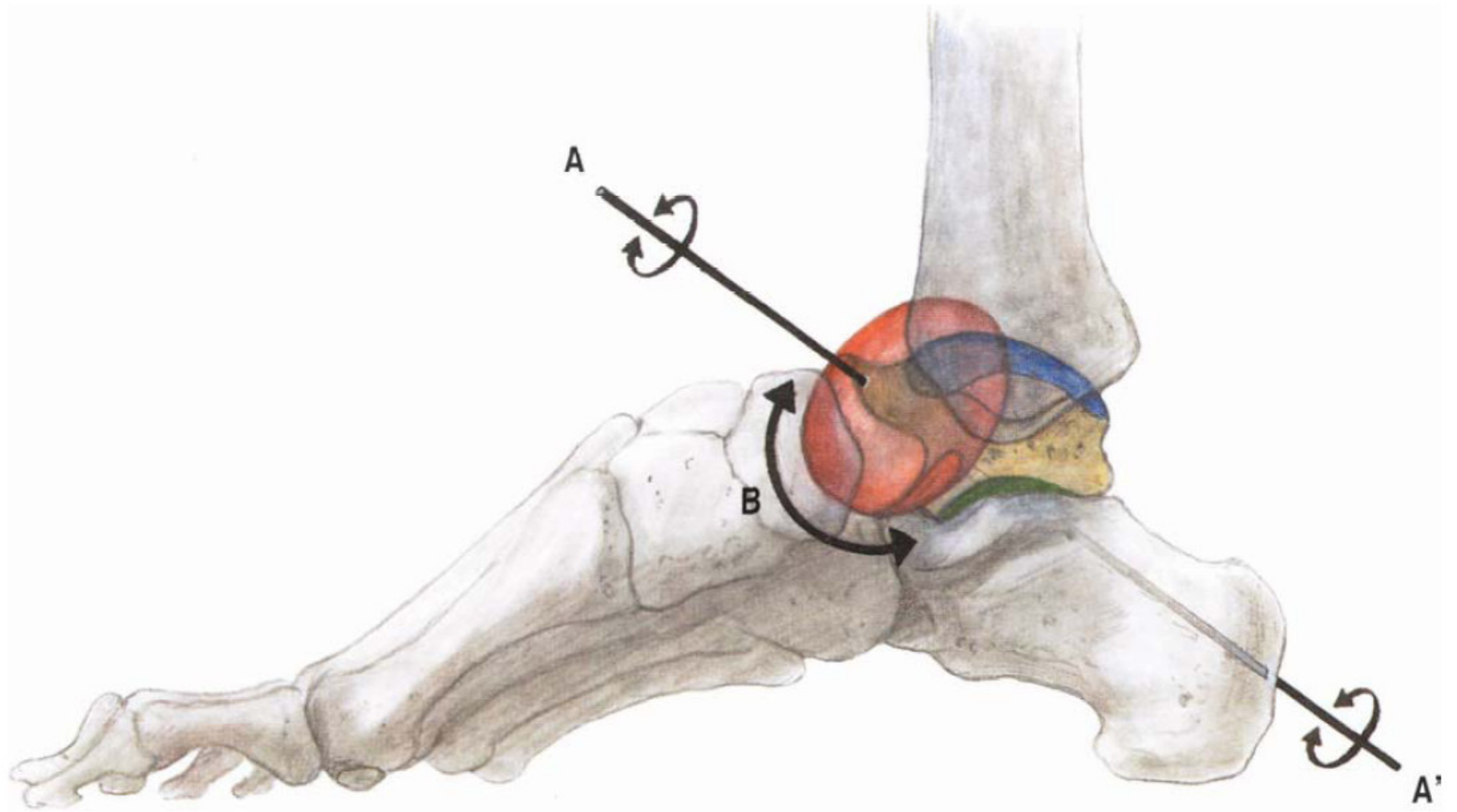


Movements: combined

inversion - plantar flexion, adduction and supination

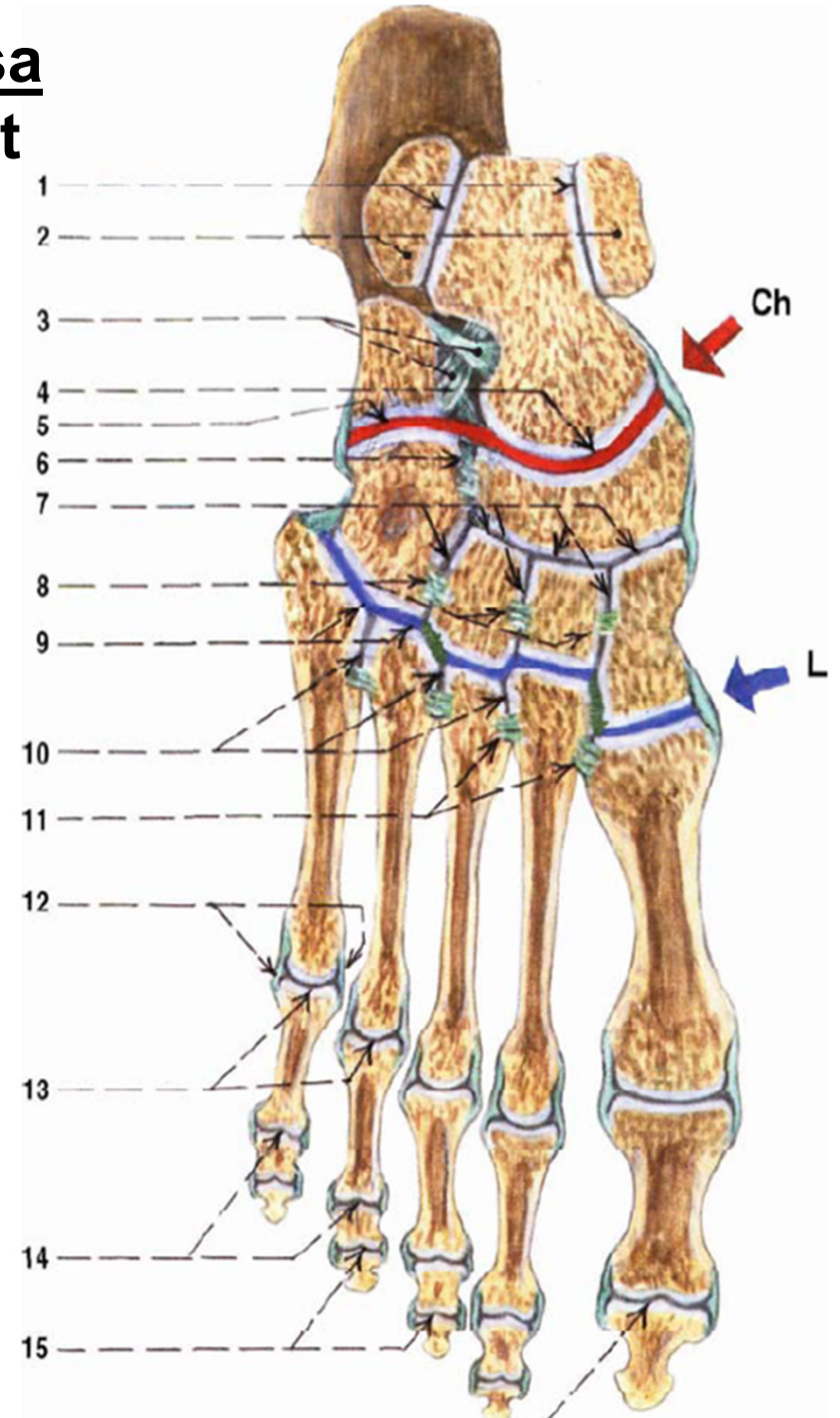
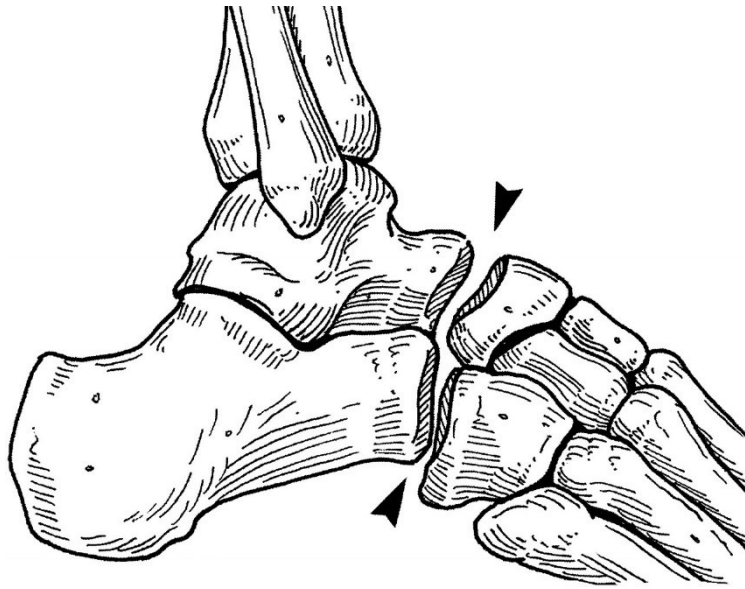
eversion - dorsal flexion, abduction and pronation





Chopart's joint = art. tarsi transversa

- articular line: art. talonavicularis et calcaneocuboidea



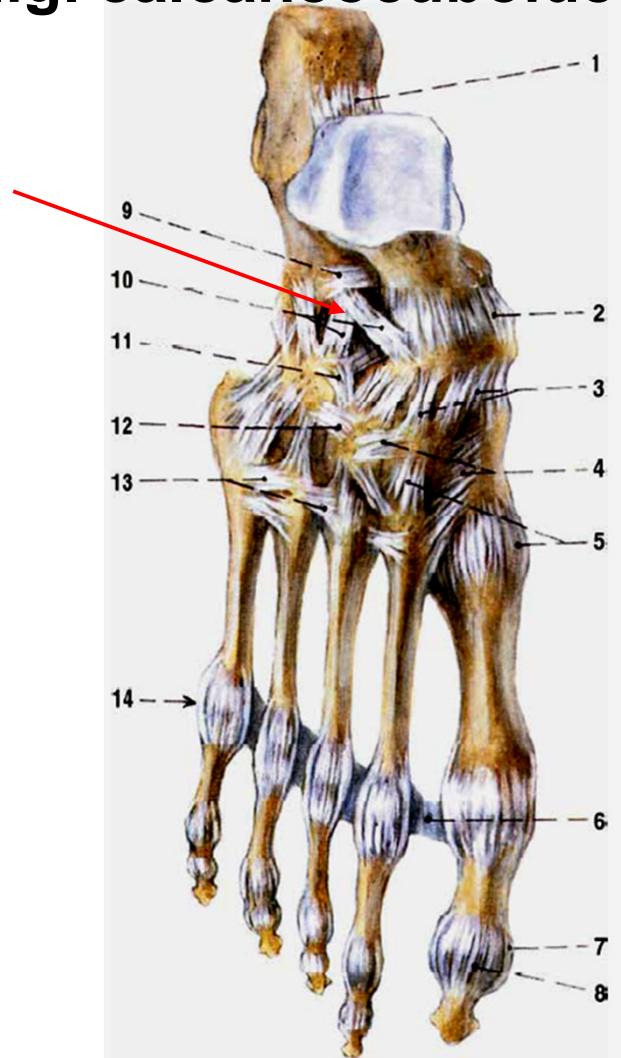
Ligaments: dorsal side:

lig. talonaviculare

lig. bifurcatum:

lig. calcaneonaviculare

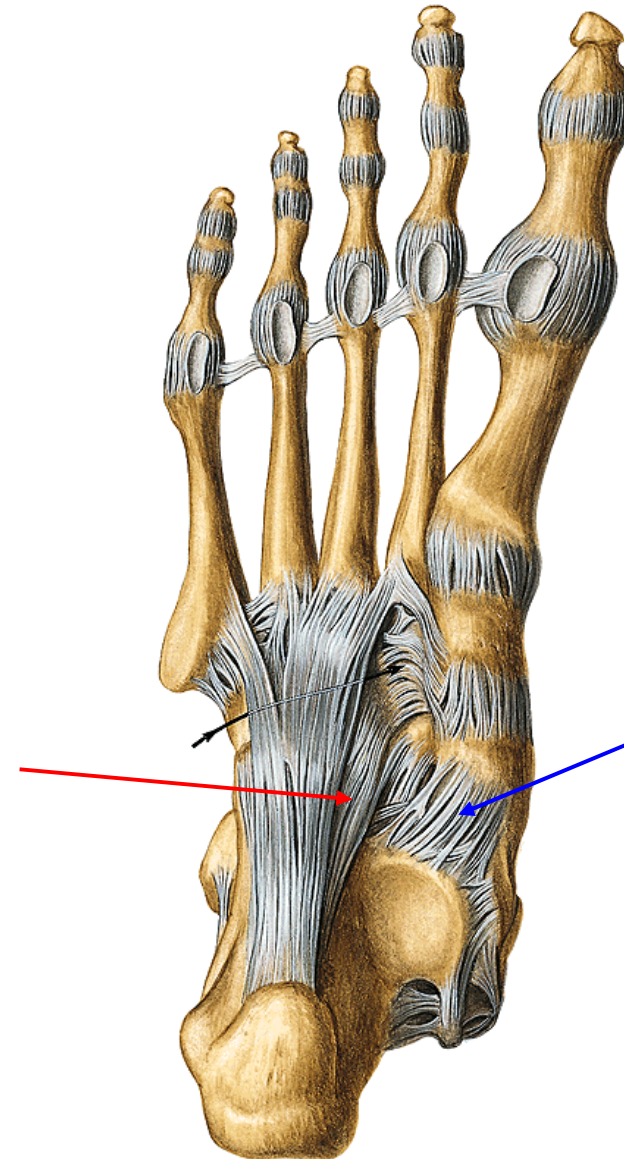
lig. calcaneocuboideum



Plantar side:

lig. calcaneonaviculare plantare

lig. calcaneocuboideum plantare



Articulatio cuneonavicularis

Type: composed, tough joint

Connection of three ossa cuneiformia with os naviculare, ossa cuneiformia between each other and os cuneiforme laterale with os cuboideum

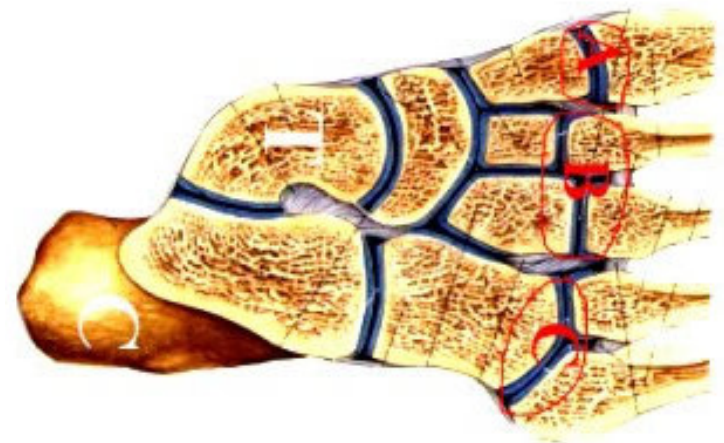
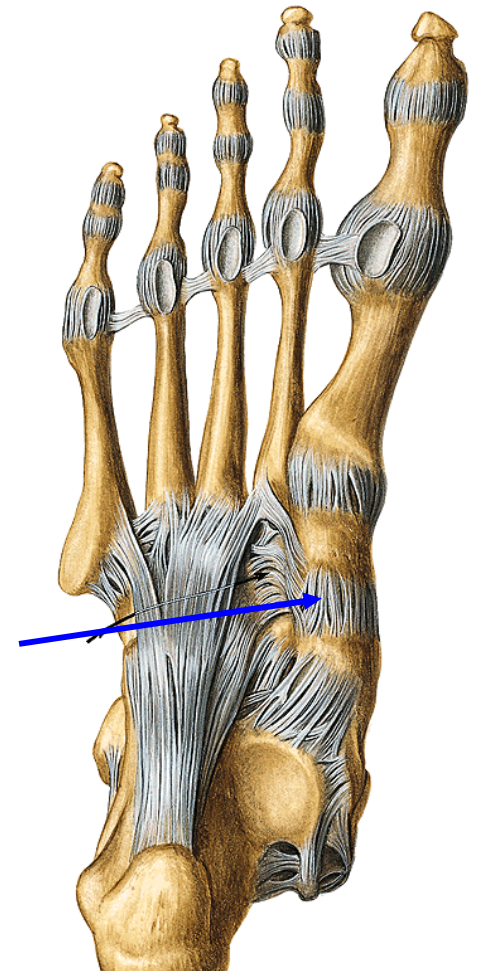
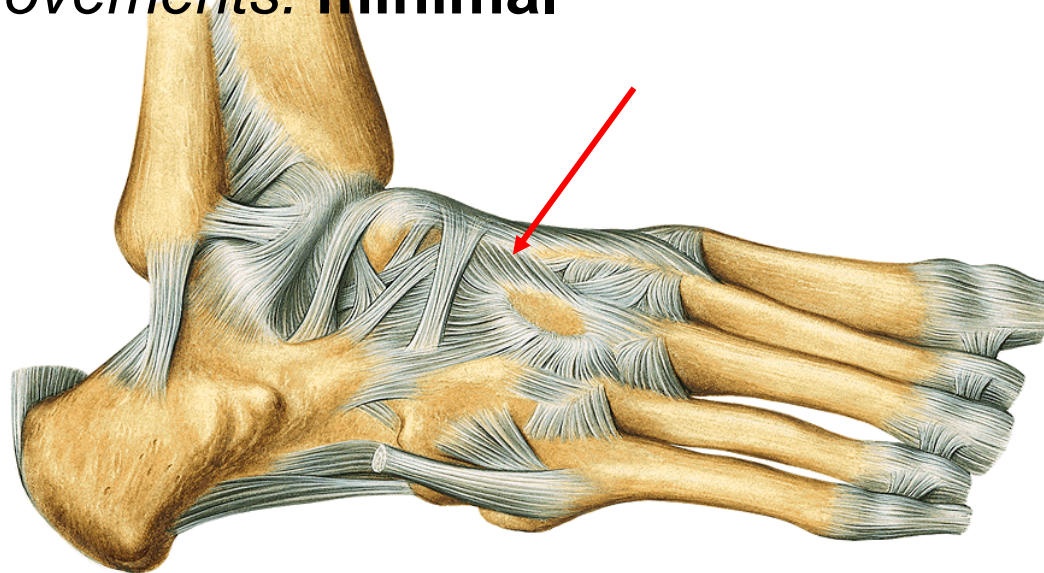
Ligaments:

ligg. cuneonavicularia **dorsalia** et **plantaria**

ligg. intercuneiformia dorsalia, plantaria et interossea

ligg. cuneocuboideum dorsale, plantare et interosseum

Movements: minimal



Lisfranck's joint= functional unit:

Articulationes tarsometatarsales

Distal row of tarsal bones and bases of metatarsal bones

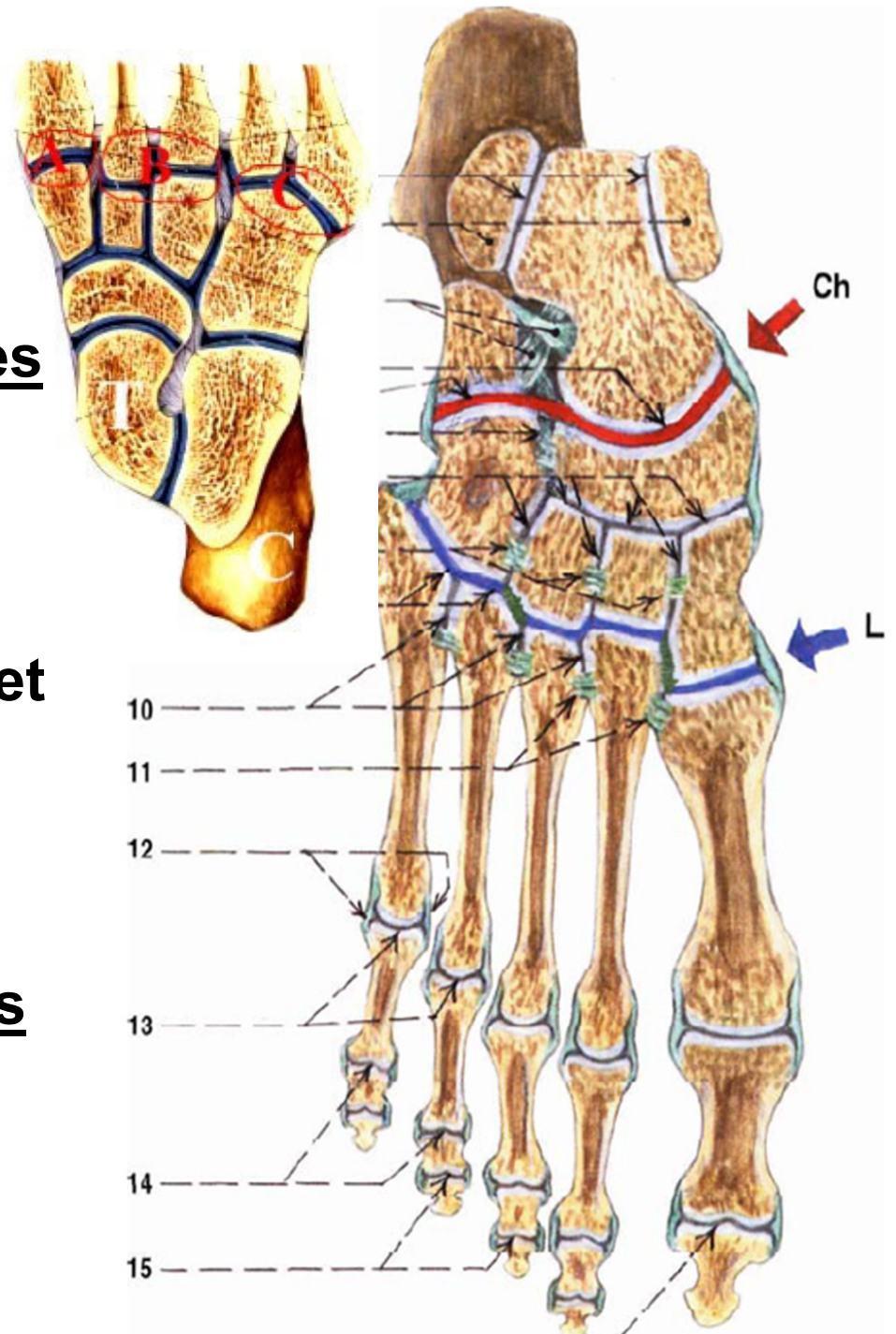
A. os cuneiforme mediale - os metatarsale I

B. os cuneiforme intermedium et laterale - os metatarsale II et III

C. os cuboideum - os metatarsale IV et V

Articulationes intermetatarsales

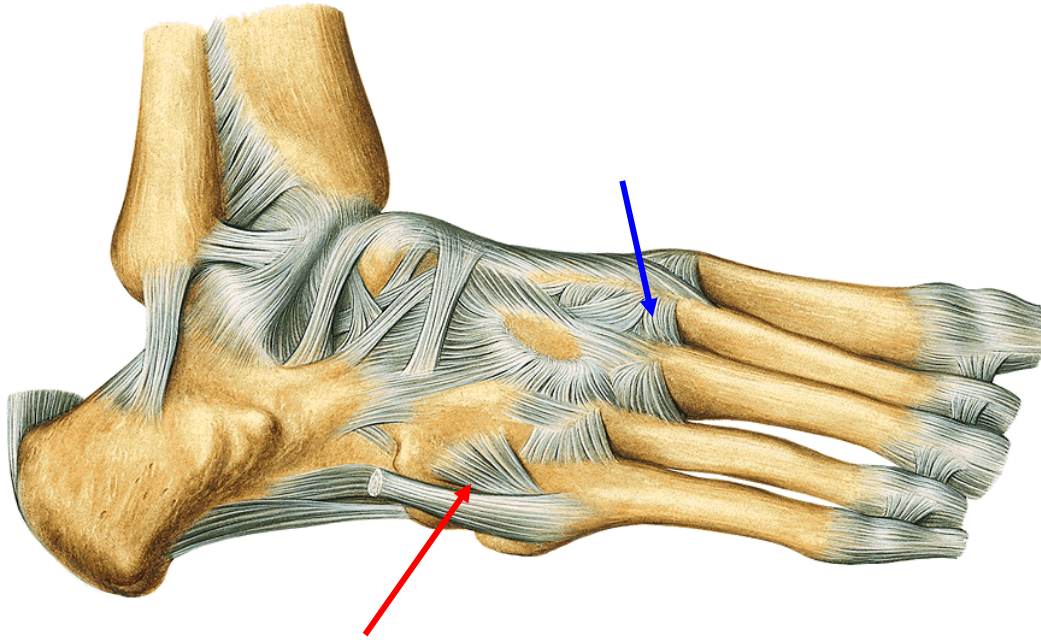
Connections between bases of adjacent metatarsal bones.



Ligaments:

Dorsal side:

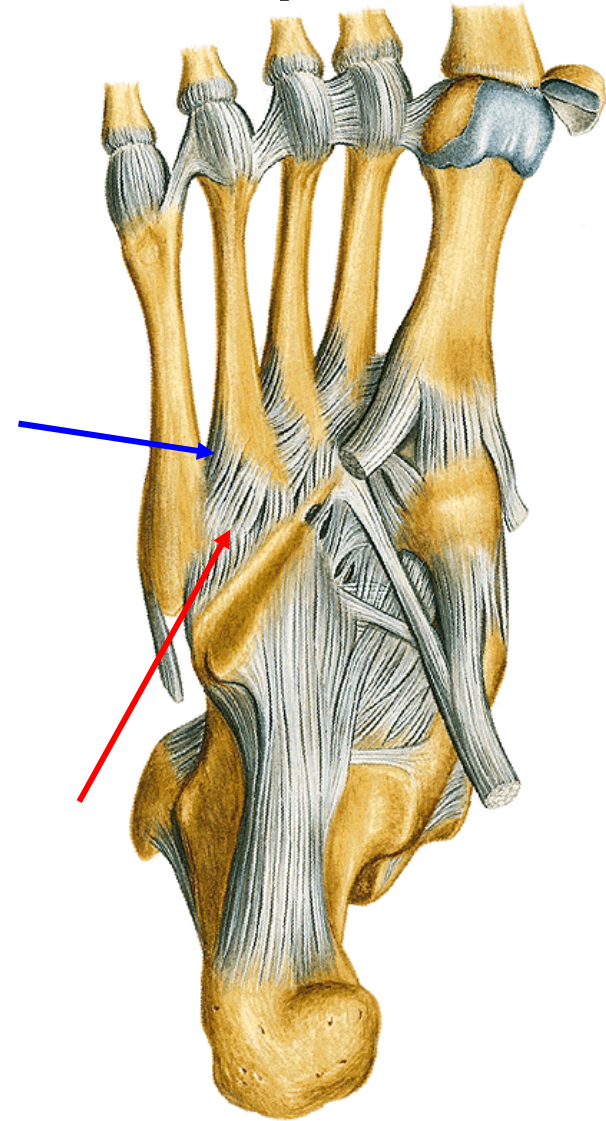
**ligg. metatarsalia dorsalia
et interossea**



ligg. tarsometatarsalia dorsalia

Plantar side:

ligg. metatarsalia plantaria



ligg. tarsometatarsalia plantaria

Articulationes metatarsophalangeae

Type: transition between cylindrical and spherical joints

Articular head: caput ossis metatarsalis

Articular pit: basis phalangis proximalis

Ligaments:

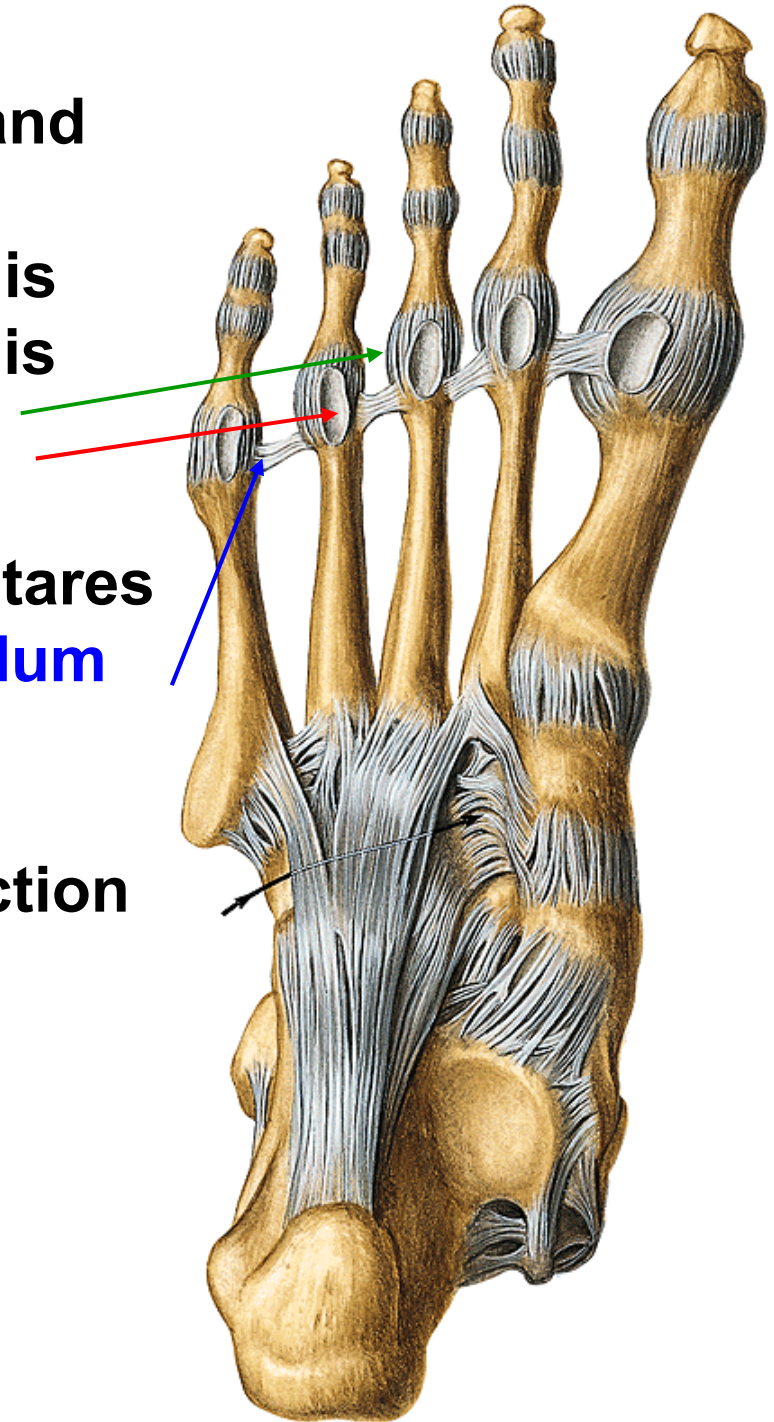
ligg. collateralia

ligg. plantaria - fibrocartilagineae plantares

lig. metatarsale transversum profundum

Movements: flexion and extension

in small range - abduction and adduction



Articulationes interphalangeae pedis

Type: **trochlear joint**

Articular head: **caput phalangis**

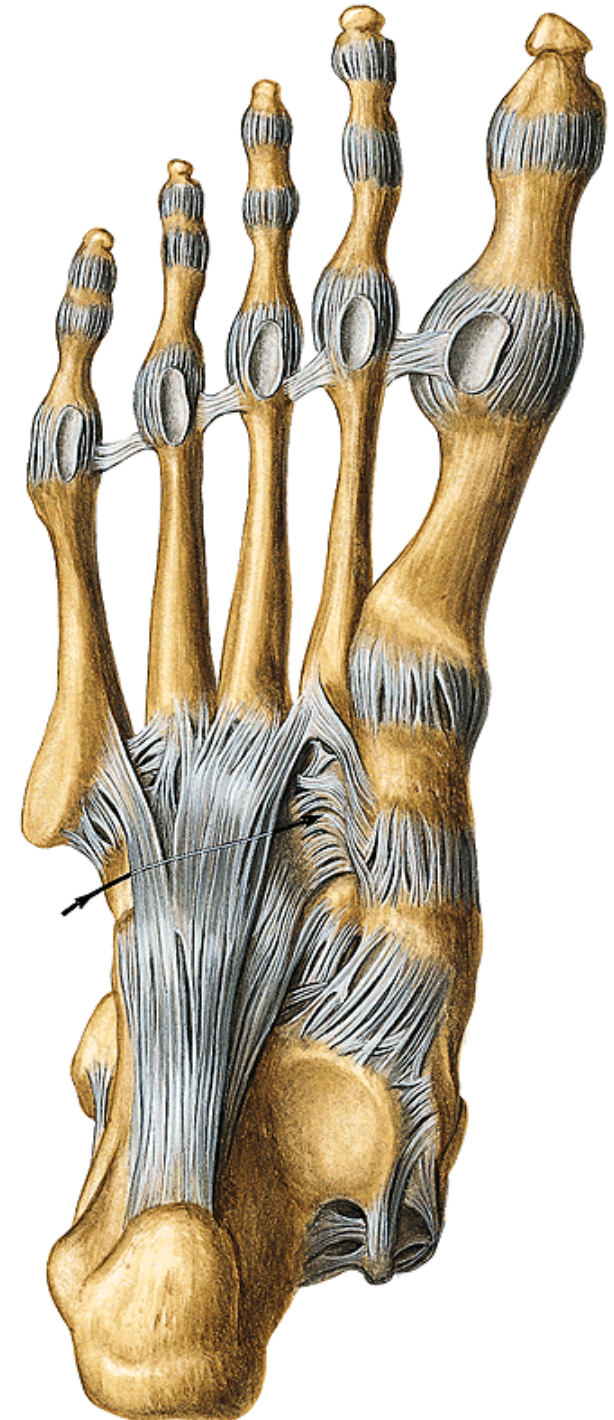
Articular pit: **basis phalangis**

Ligaments:

ligg. plantaria - fibrocartilaginea plantares

ligg. collateralia

Movements: **flexion and extension in restricted range**

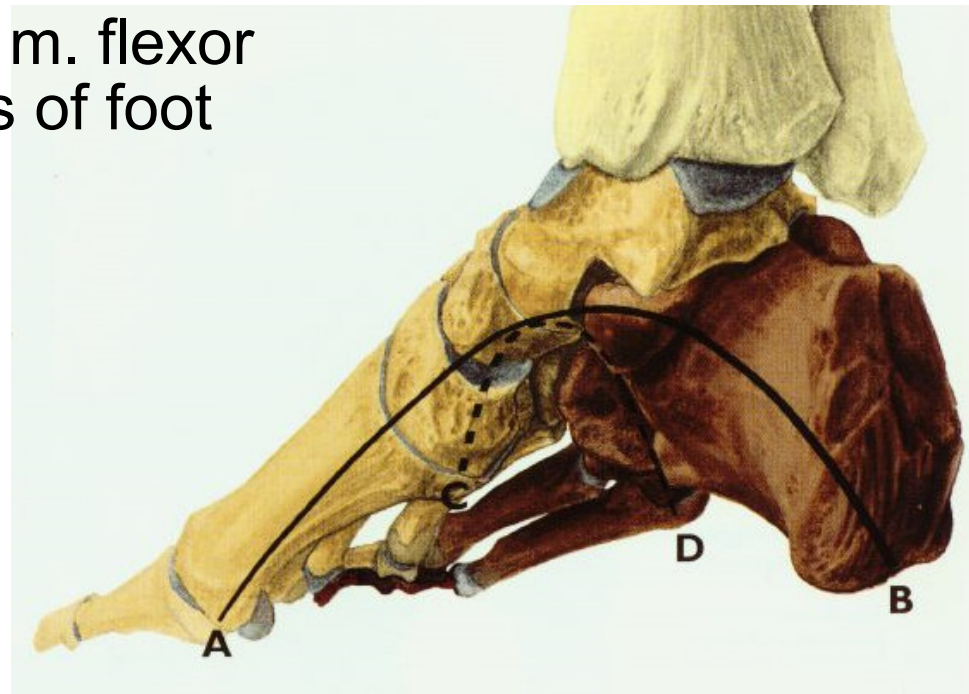
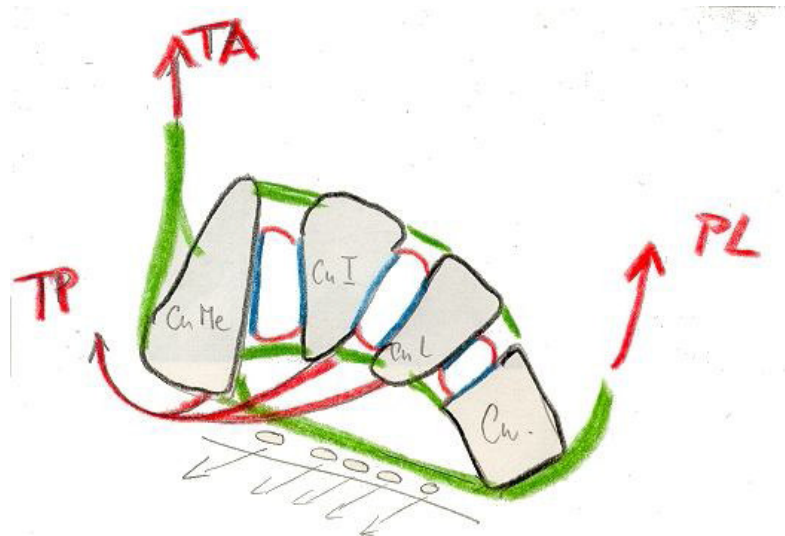
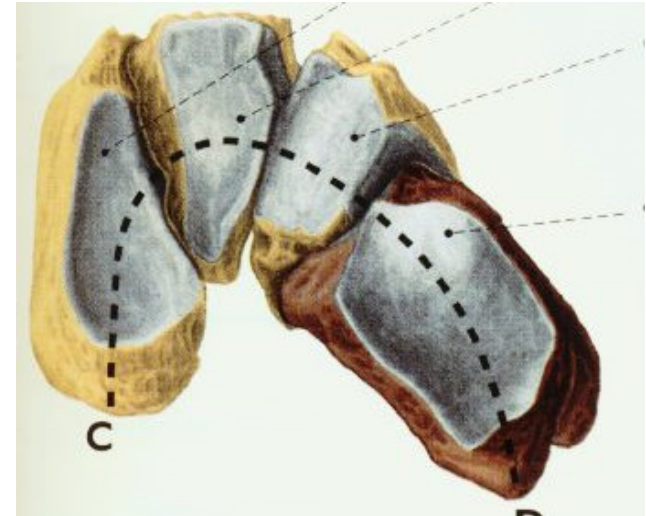


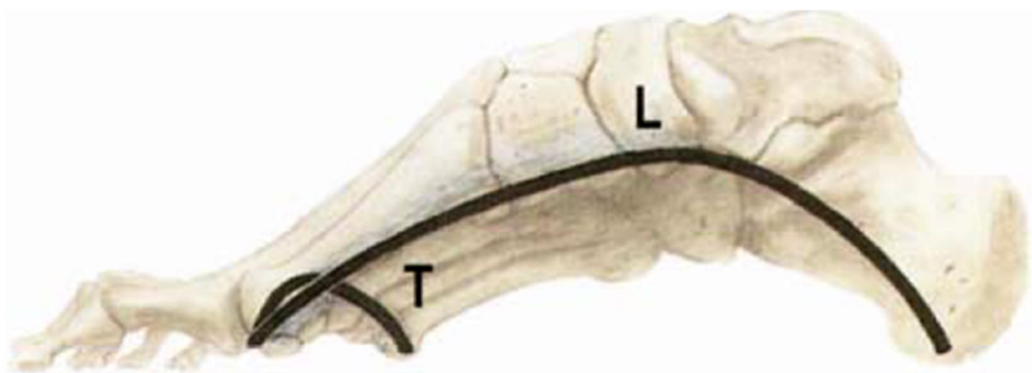
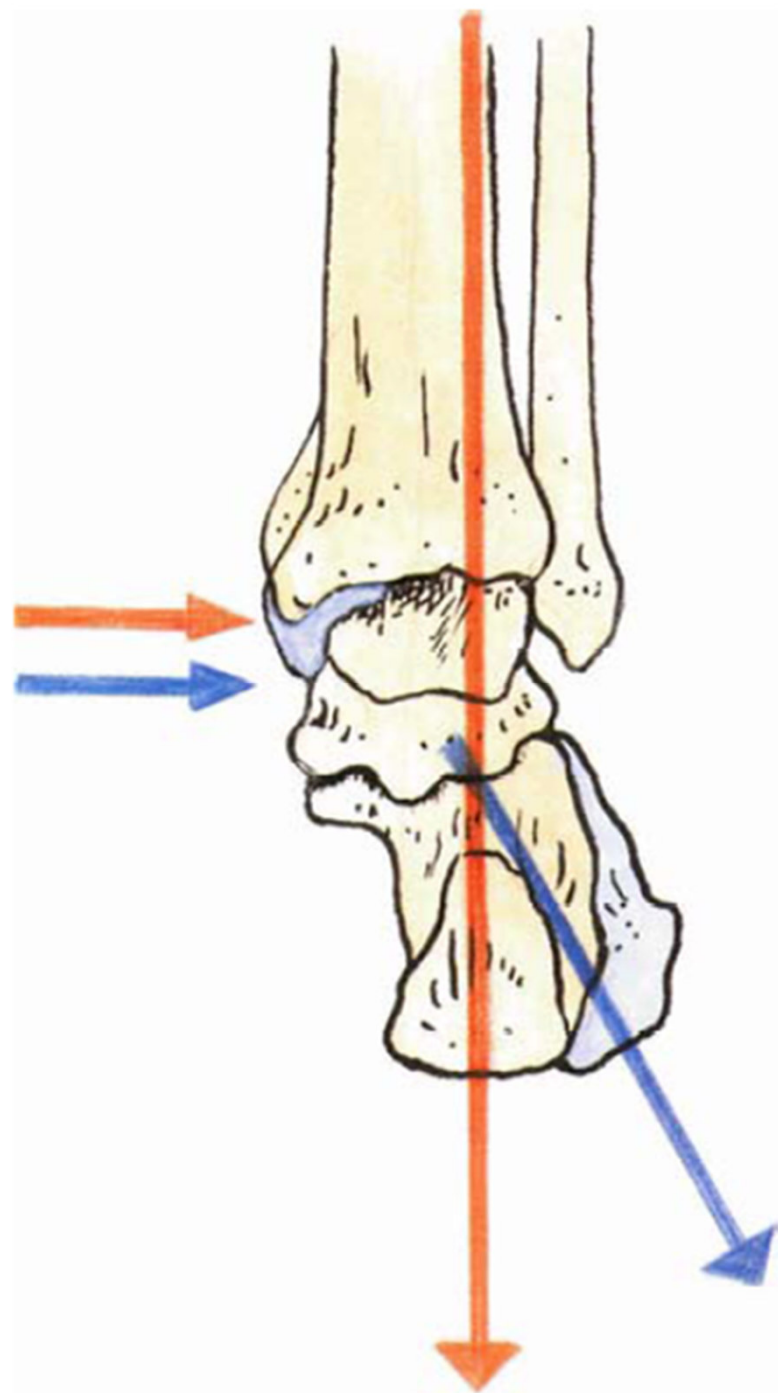
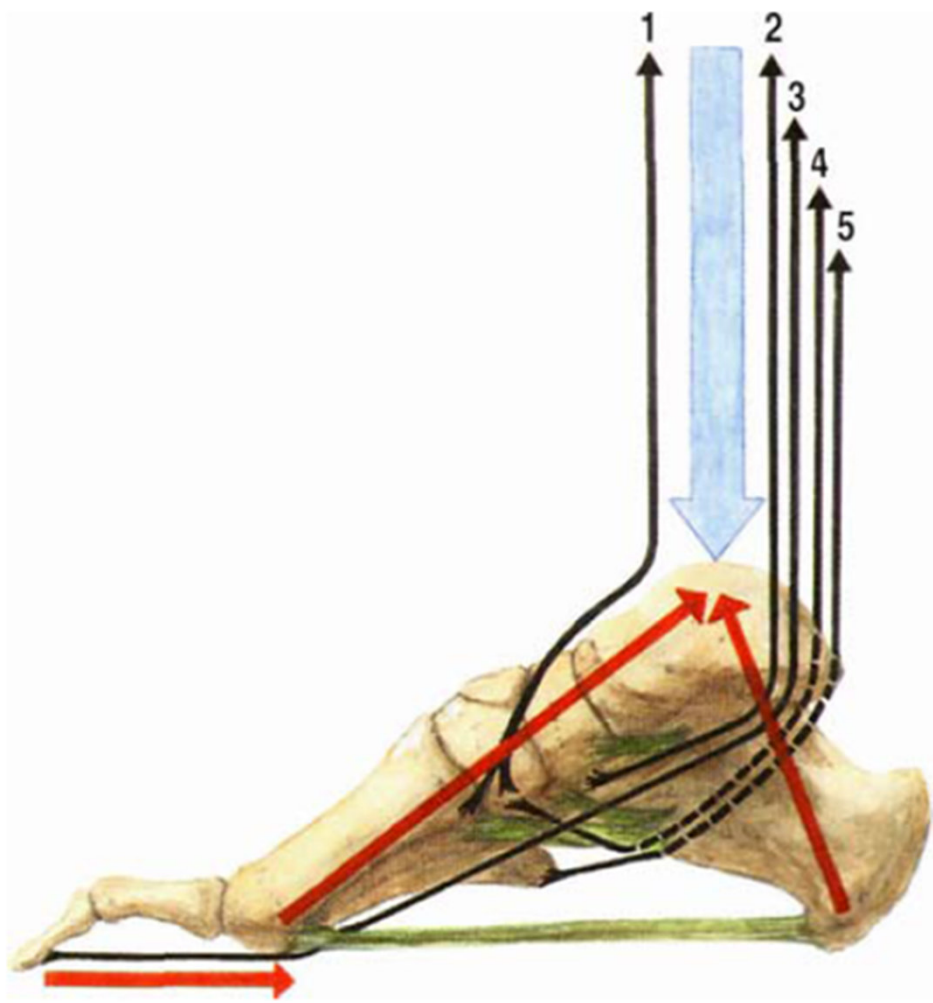
Foot vault

- It prevents compression of soft tissues in the foot
- It allows flexibility of the foot during walking

transversal – it is given by arch of ossa cuneiformia, it is held by interosseous ligaments, m. peroneus longus, m. tibialis anterior, m. adductor hallucis

longitudinal – top is talus, aponeurosis, lig. plantare longum, m. tibialis ant. et post., m. flexor hallucis longus, m. flexor digitorum longus, short muscles of foot





Thank you for your attention!

Obrázky:

Atlas der Anatomie des Menschen/Sobotta. Putz,R., und Pabst,R. 20. Auflage.

München:Urban & Schwarzenberg, 1993

Netter: Interactive Atlas of Human Anatomy.

Naňka, Elišková: Přehled anatomie. Galén, Praha 2009.

Čihák: Anatomie I, II, III.

Drake et al: Gray's Anatomy for Students. 2010