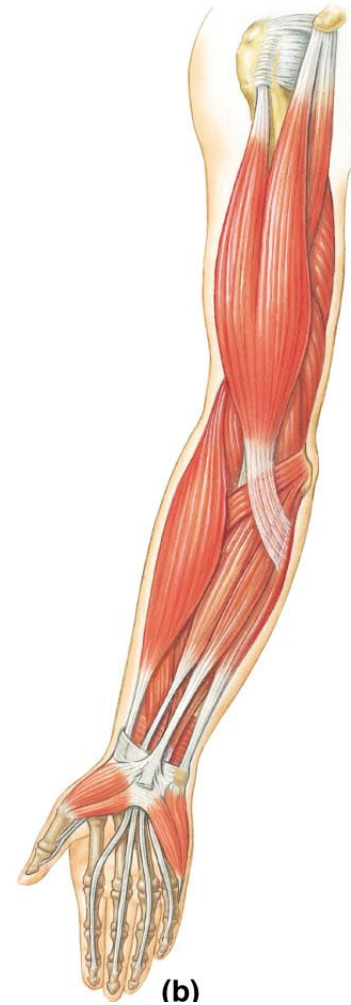
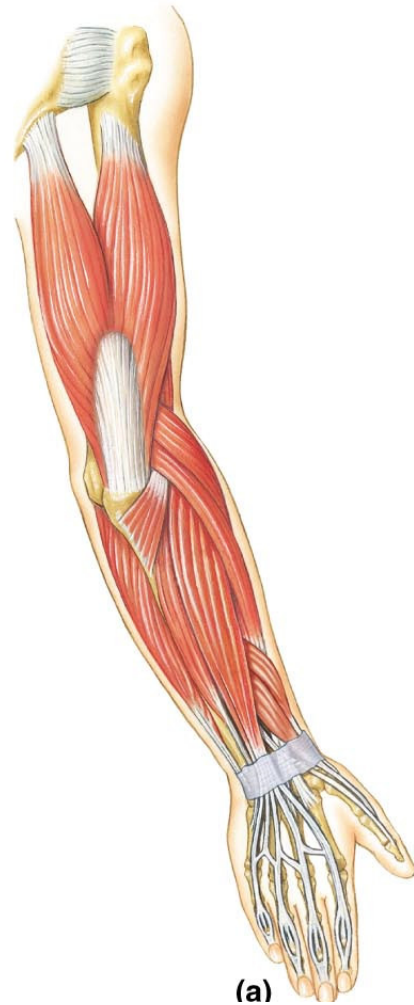
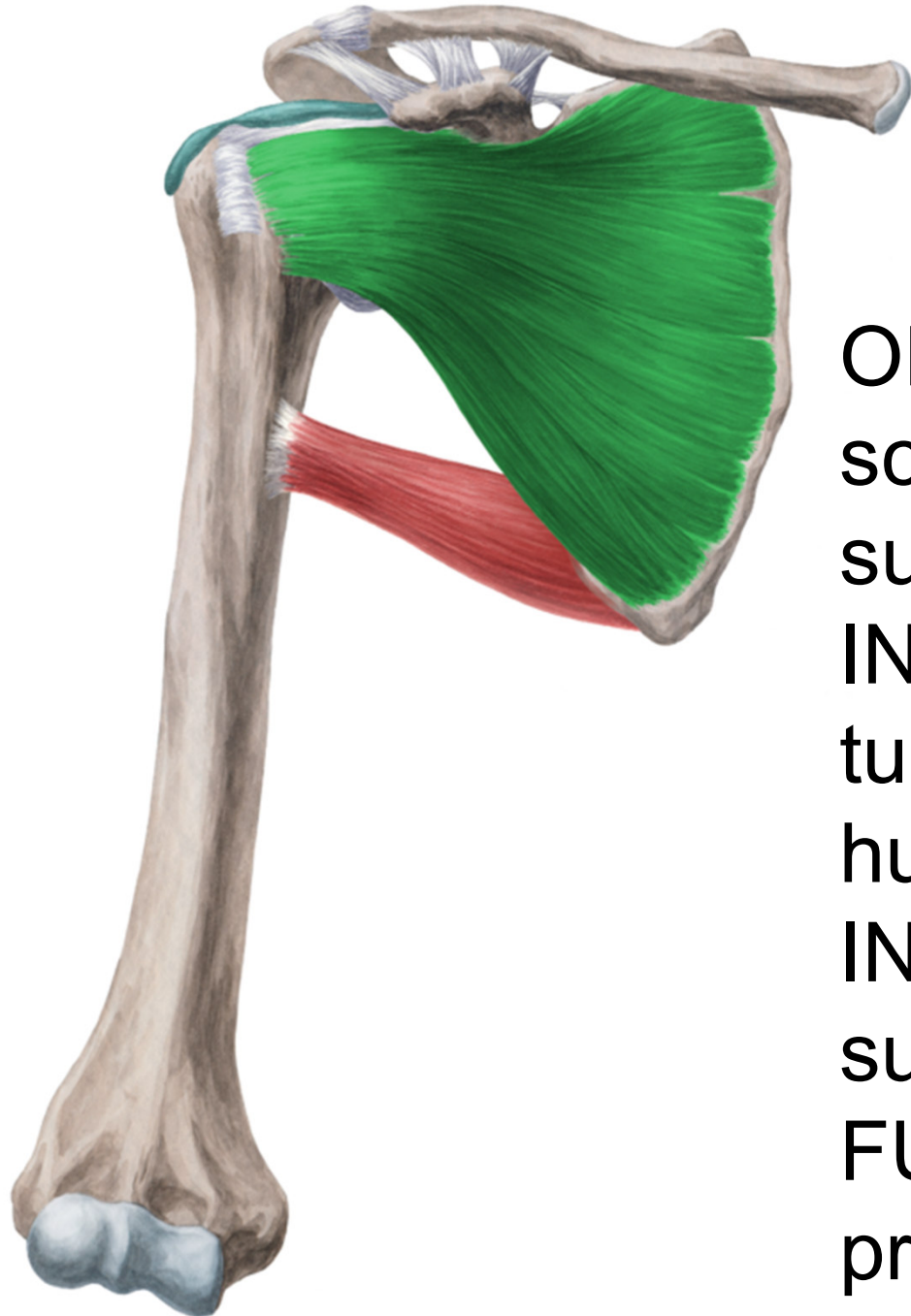


# Muscles of the upper extremity



# Musculi humeri (Shoulder muscles)



# Musculus subscapularis

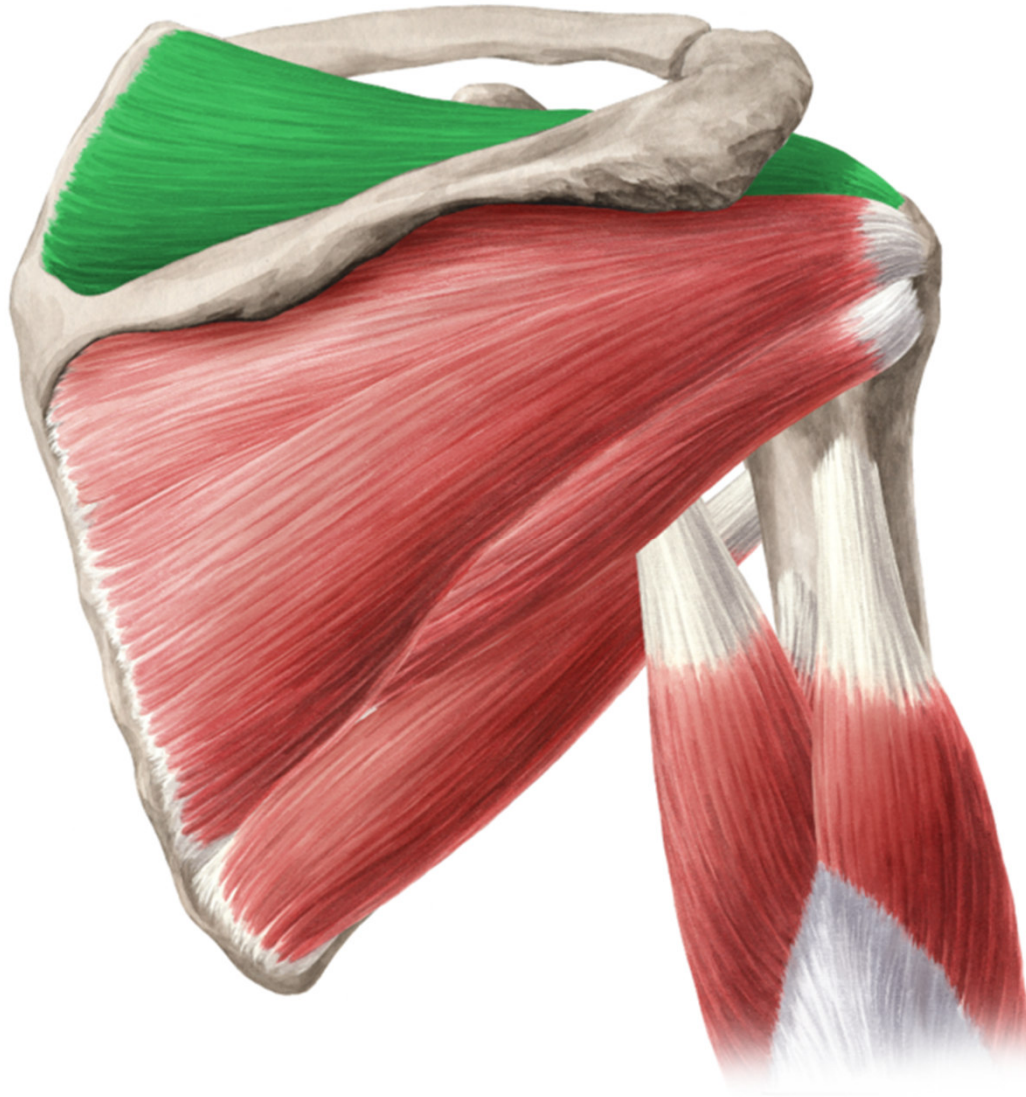
ORIGIN: facies costalis  
scapulae (fossa  
subscapularis)

INSERTION:  
tuberculum minus  
humeri

INNERVATION: n.  
subscapularis

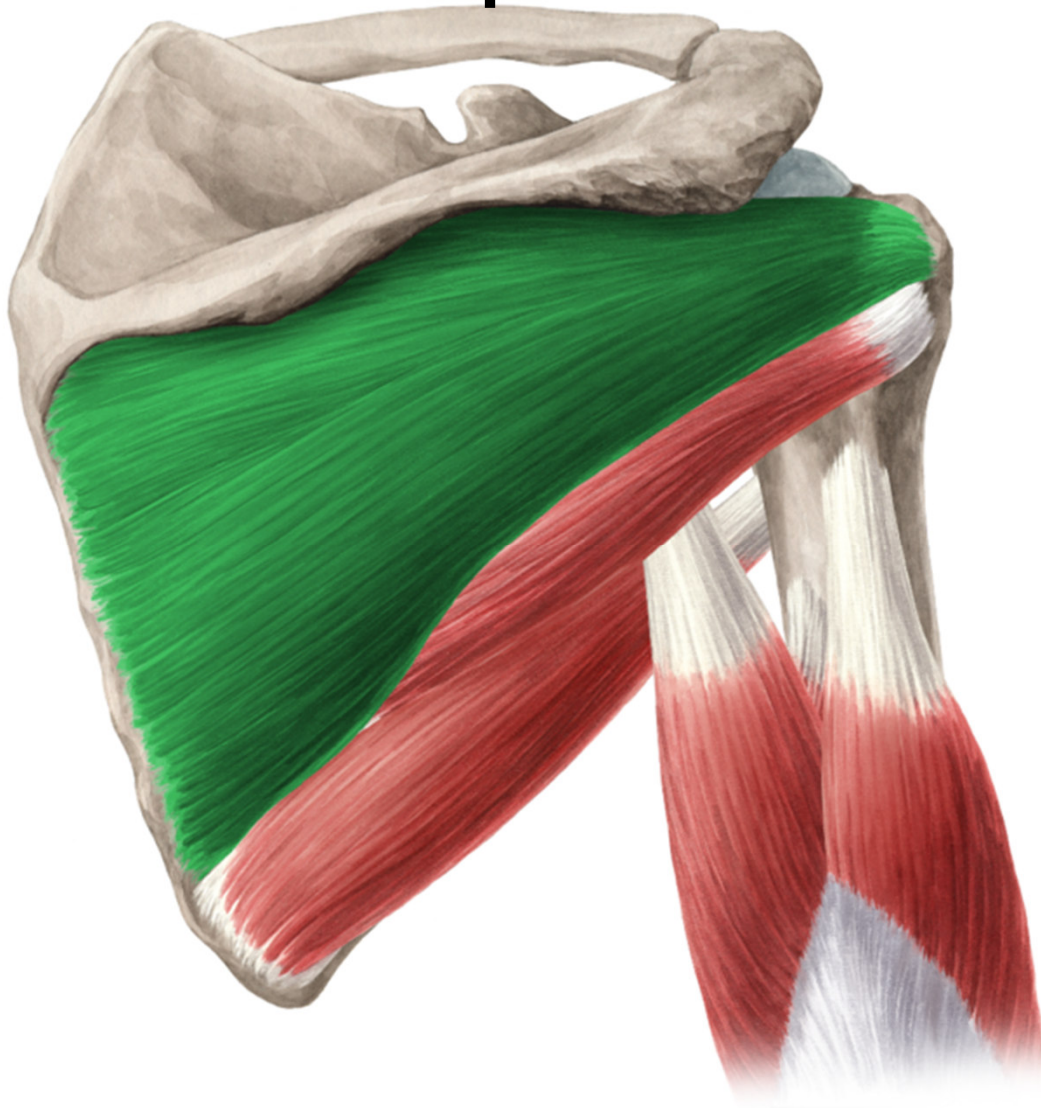FUNCTION: humeral  
pronation, adduction

# Musculus supraspinatus



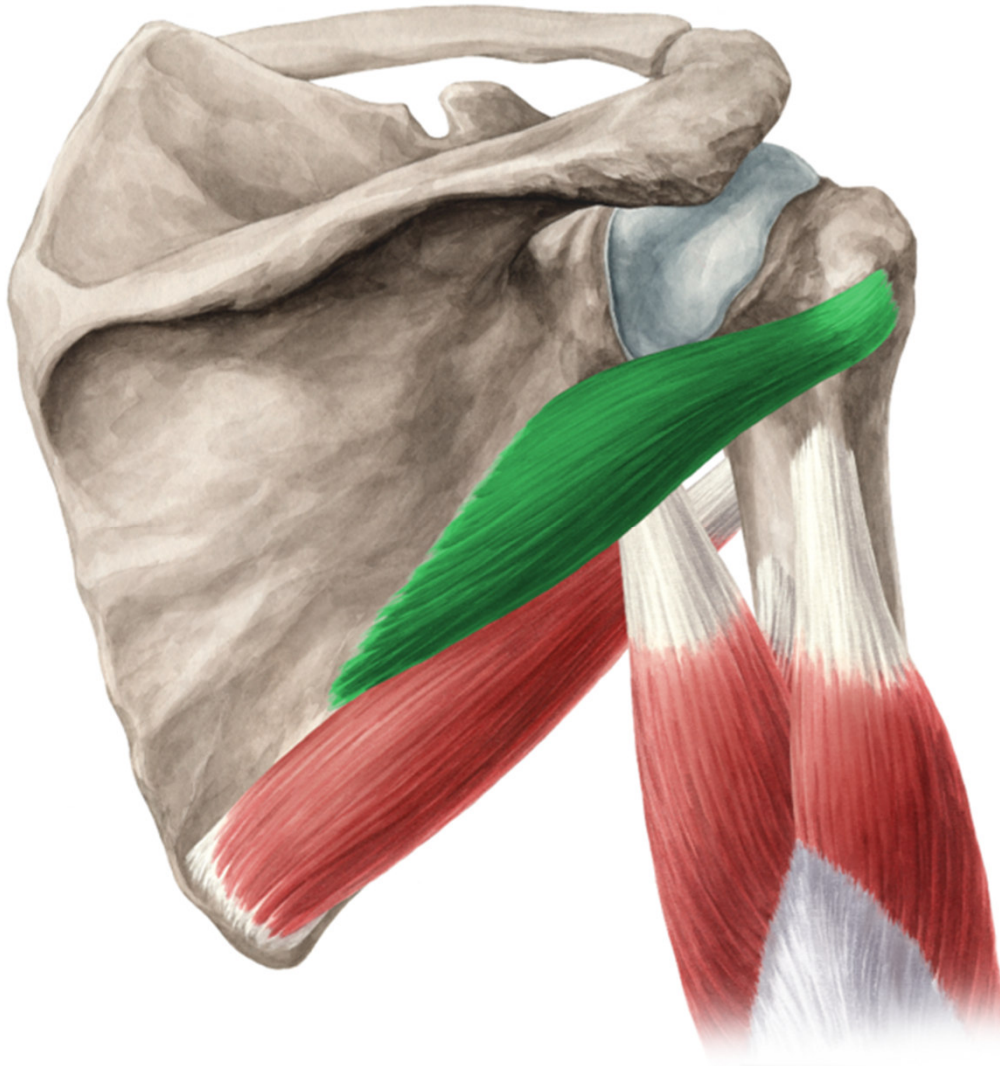
- **ORIGIN:** fossa supraspinata
- **INSERTION :** tuberculum majus humeri
- **INNERVATION:** n. suprascapularis
- **FUNCTION:** humeral supination and abduction

# Musculus infraspinatus



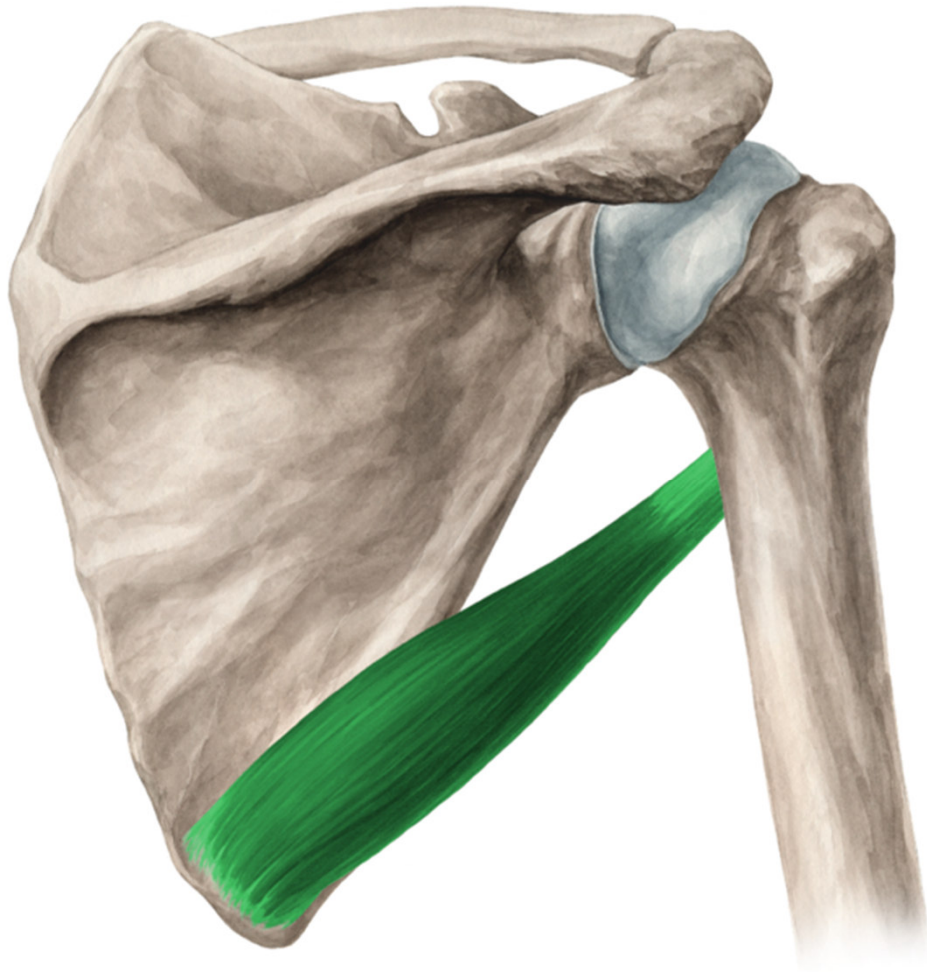
- **ORIGIN:** fossa infraspinata
- **INSERTION :** tuberculum majus humeri
- **INNERVATION:** n. suprascapularis
- **FUNCTION:** humeral supination

# Musculus teres minor

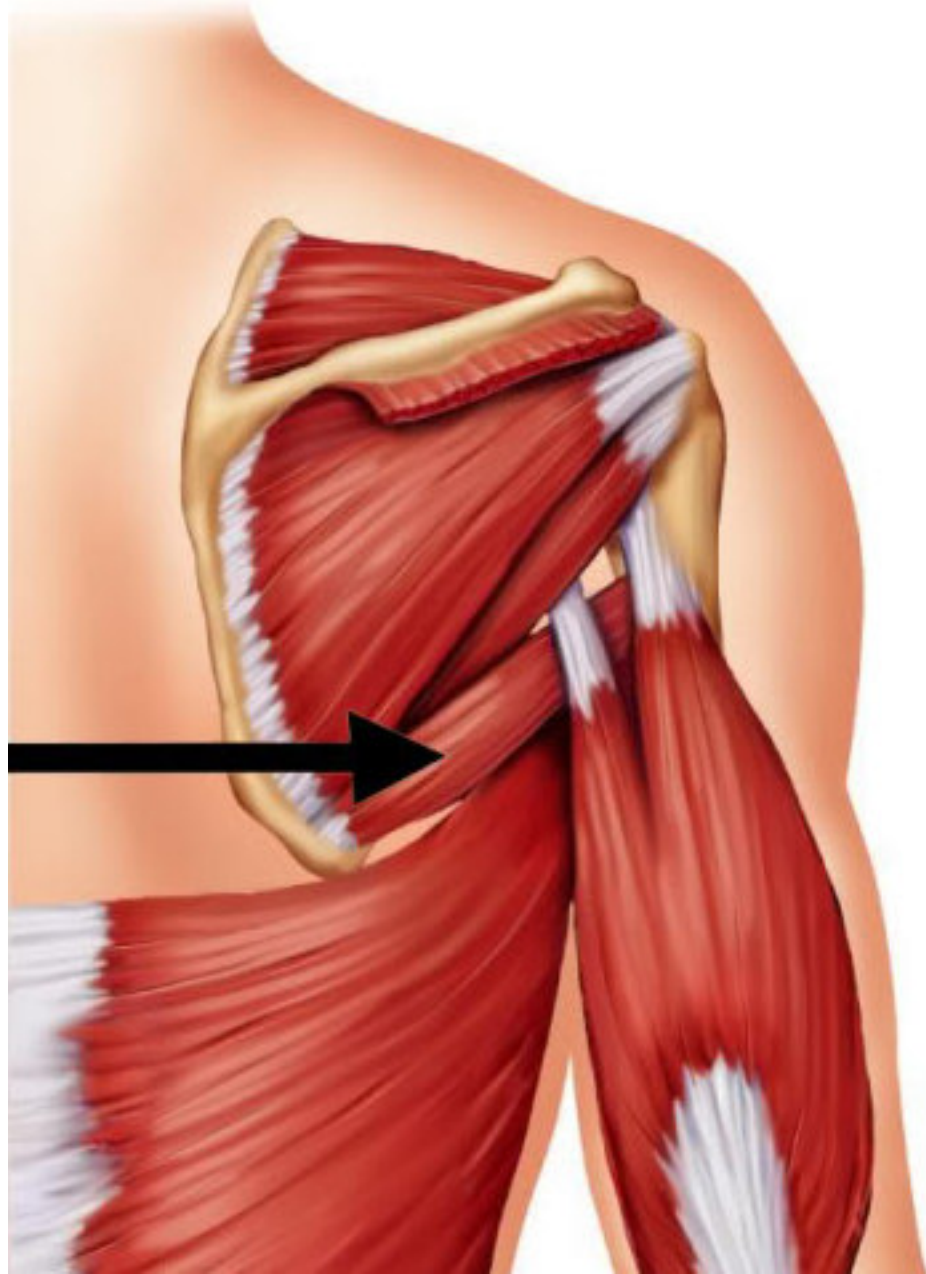


- **ORIGIN:** margo lateralis scapulae
- **INSERTION :** tuberculum majus humeri
- **INNERVATION:** n. axillaris
- **FUNCTION:** humeral supination

# Musculus teres major

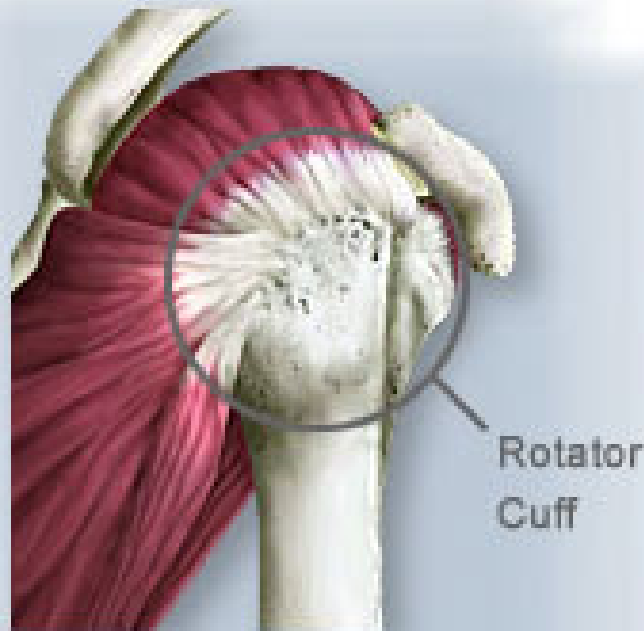

- **ORIGIN:** angulus inferior scapulae
- **INSERTION :** crista tuberculi minoris
- **INNERVATION:** n. subscapularis
- **FUNCTION:** adduction, extension and humeral pronation

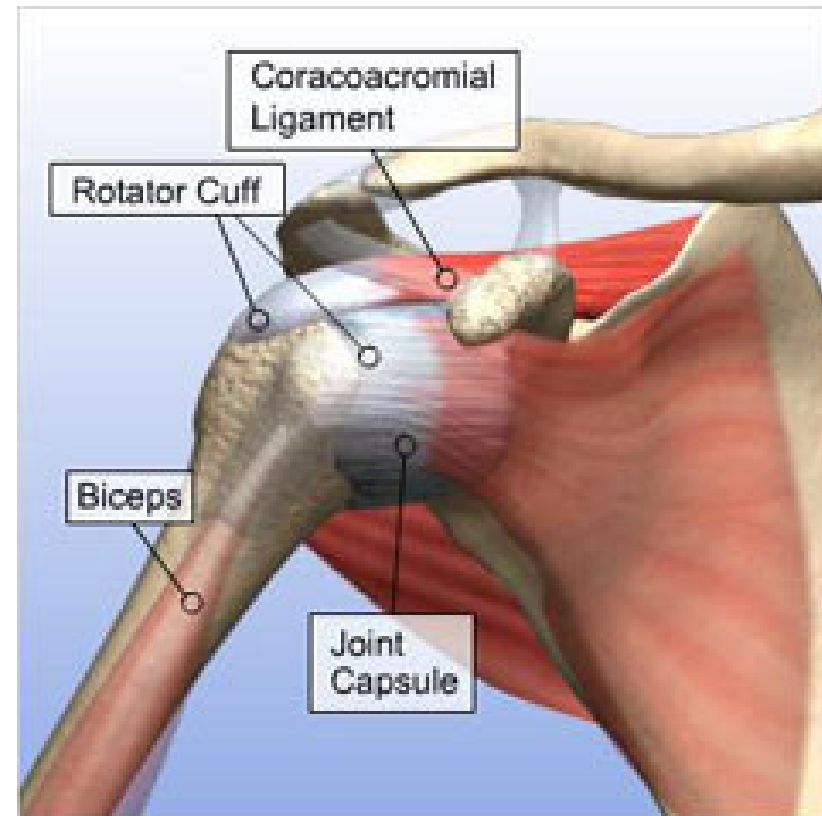


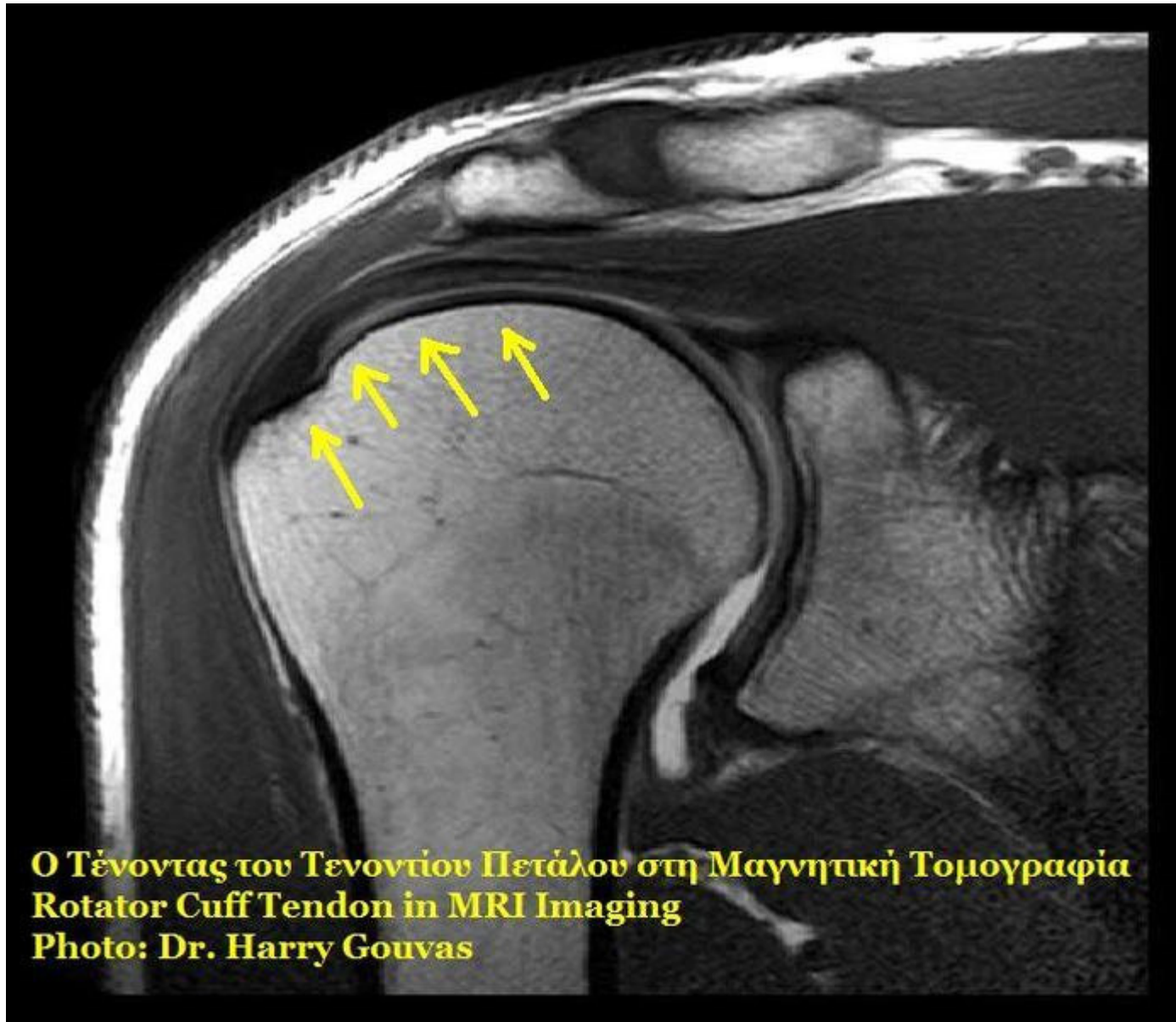


- Insertions of m. supraspinatus, infraspinatus, teres minor and subscapularis into the articular capsule of shoulder joint– ROTATOR CUFF (in clinical practice)



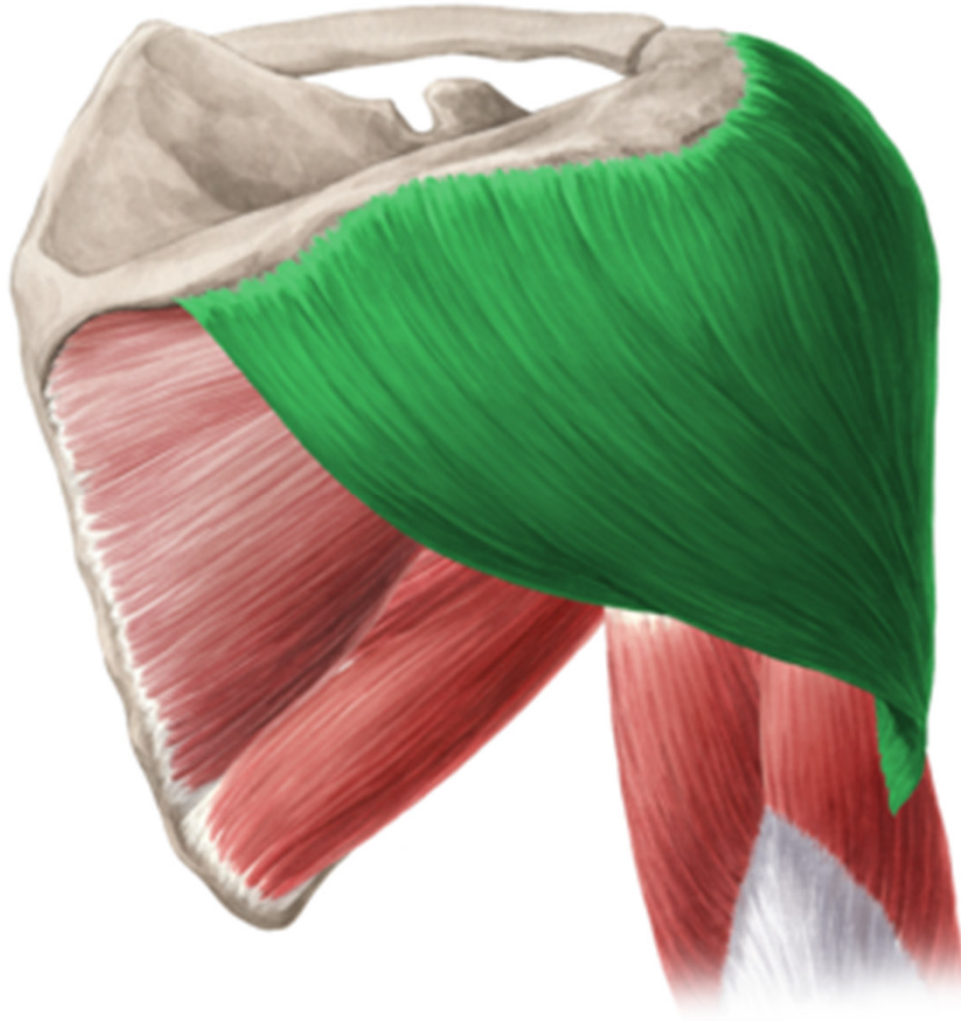
**Shoulder, Lateral View**



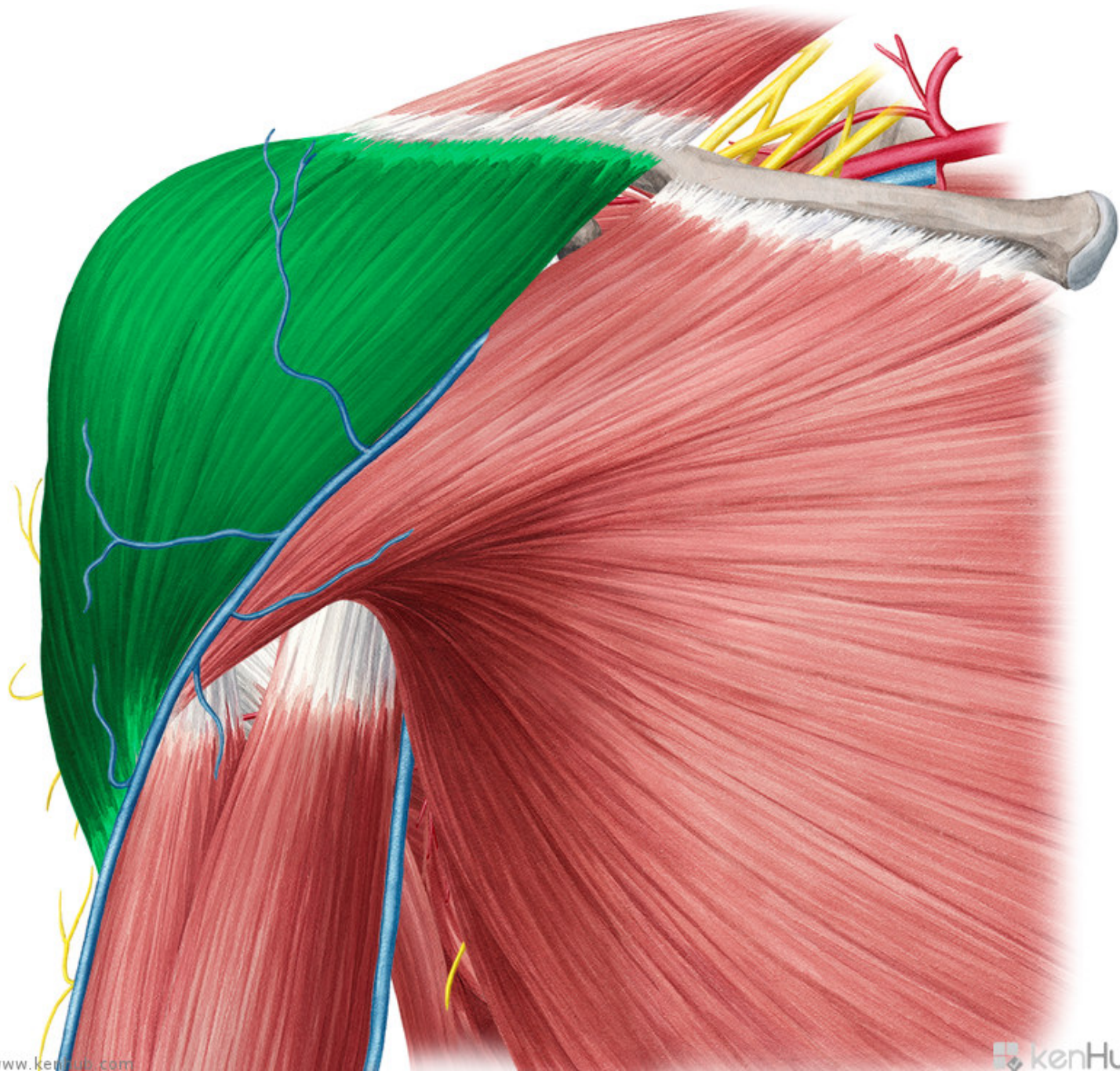


**Ο Τένοντας του Τενοντίου Πετάλου στη Μαγνητική Τομογραφία**  
**Rotator Cuff Tendon in MRI Imaging**  
**Photo: Dr. Harry Gouvas**

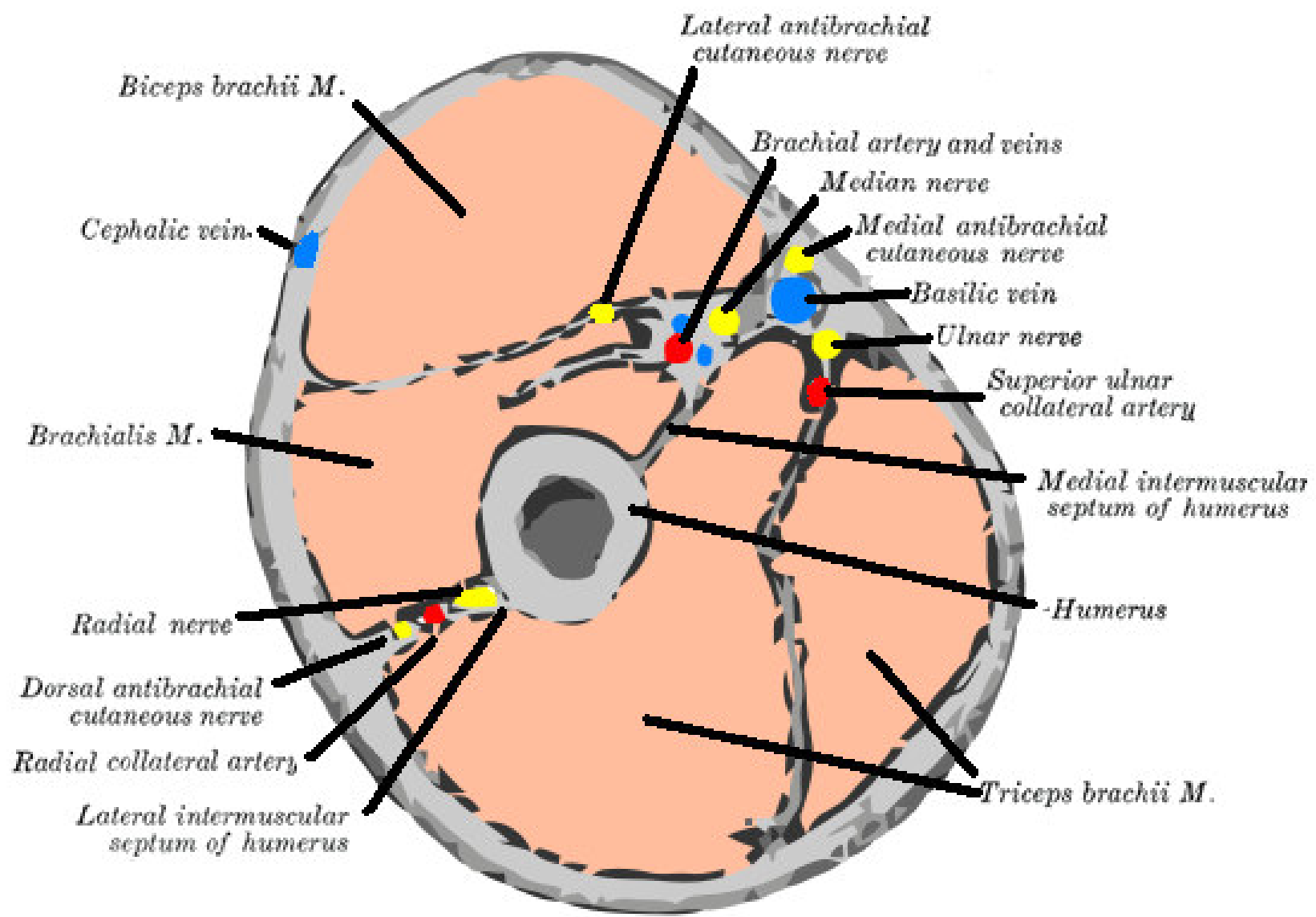
# Musculus deltoideus



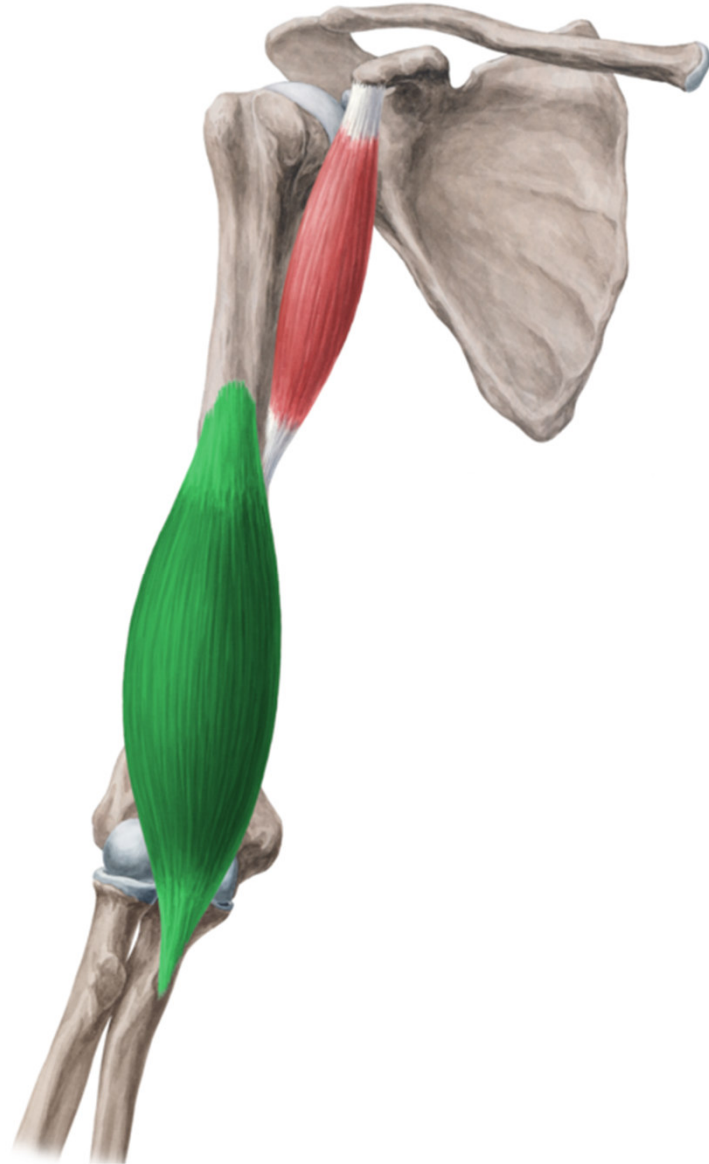
- **ORIGIN:** clavicula, acromion, spina scapulae
- **INSERTION :** tuberositas deltoidea humeri
- **INNERVATION:** n. axillaris
- **FUNCTION:** abduction, anteflexion, dorsiflexion in shoulder joint



# Musculi brachii (brachial muscles)

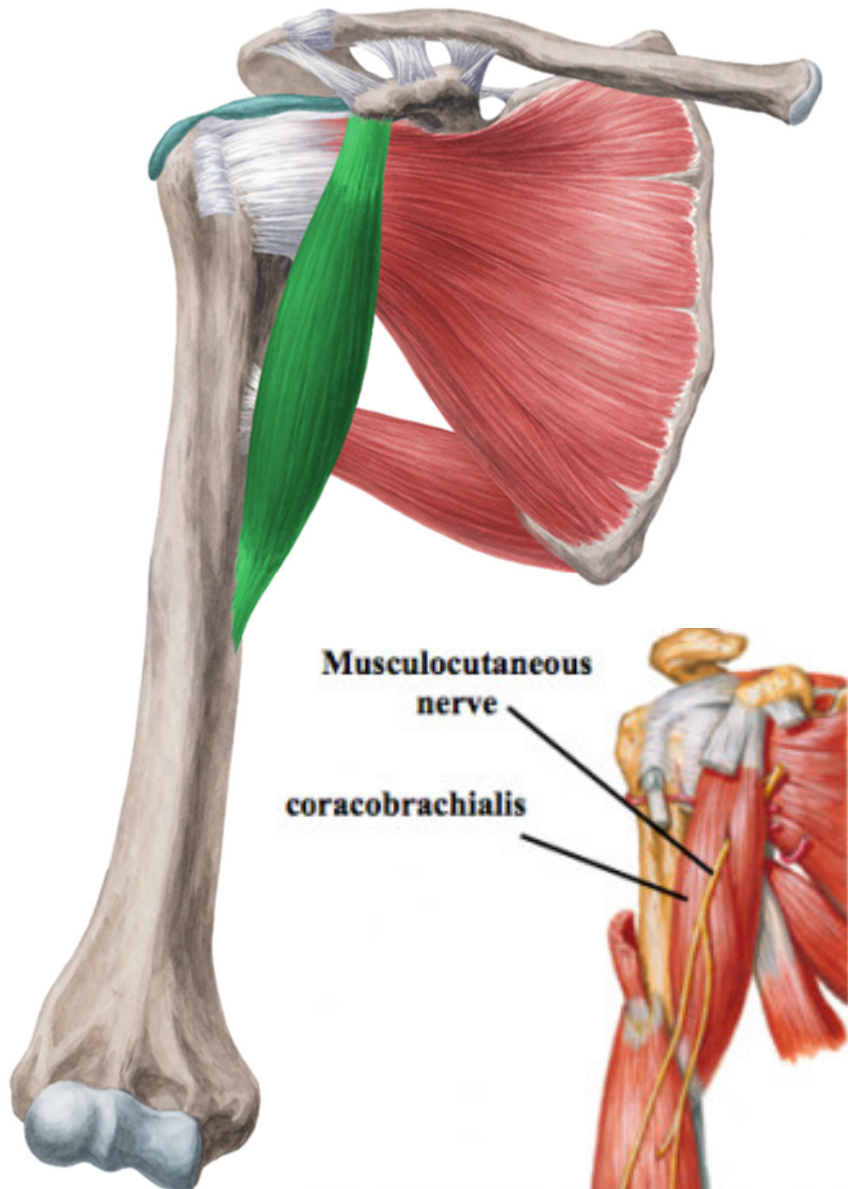


# Musculus brachialis.



- ORIGIN: distal half of humeral body
- INSERTION :  
tuberositas ulnae
- INNERVATION: n.  
musculocutaneus
- FUNCTION:  
flexion of forearm
- It is covered by  
biceps

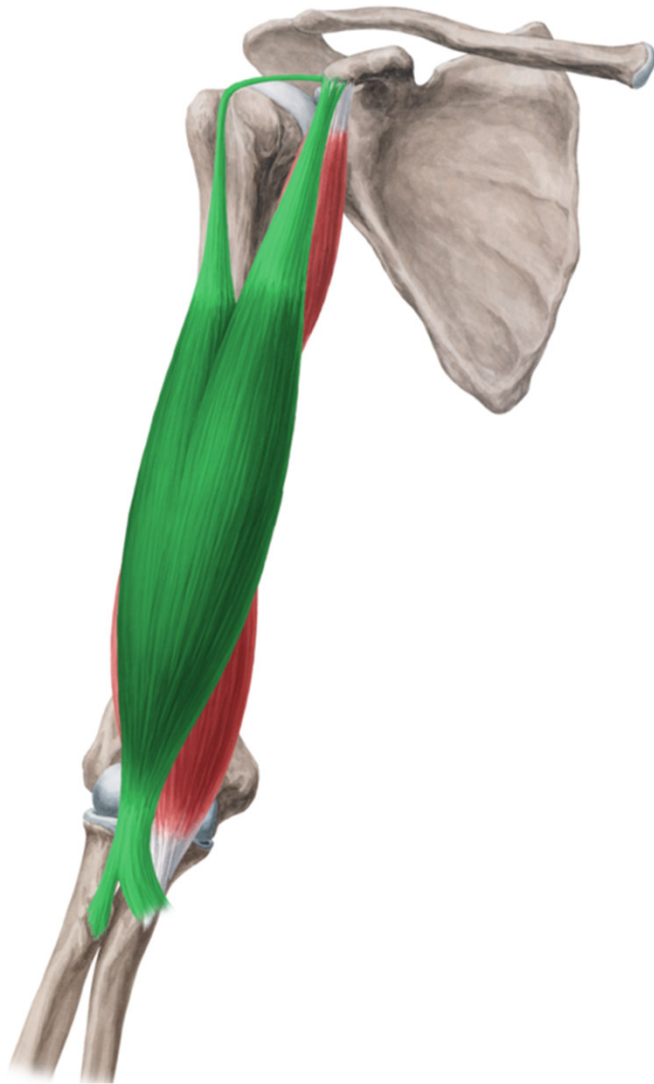# Musculus coracobrachialis



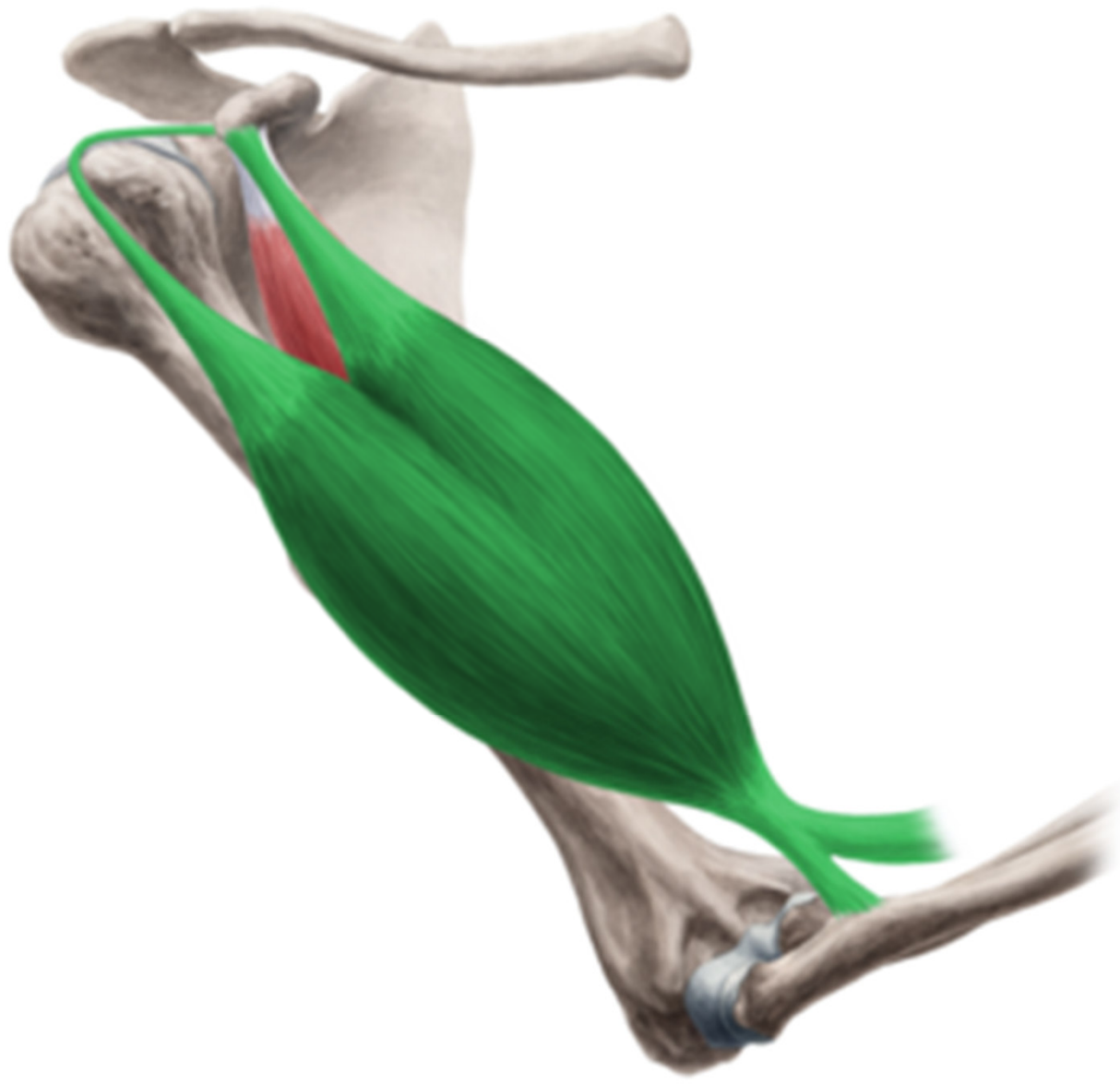- **ORIGIN:** processus coracoideus scapulae
- **INSERTION:** internal side of corpus humeri
- **INNERVATION:** n. musculocutaneus
- **FUNCTION:** adduction and partial anteflexion



# Musculus biceps brachii



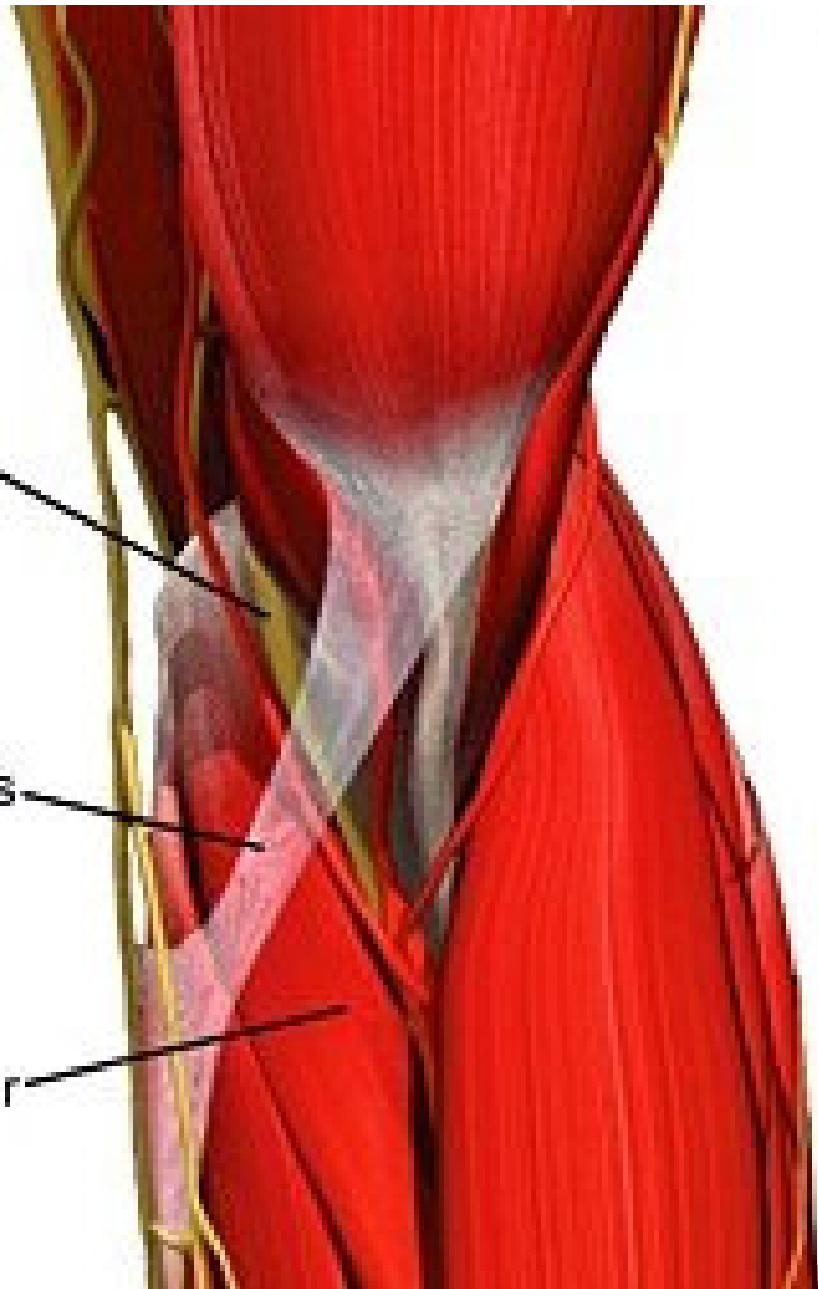
- **ORIGIN:** caput longum-tuberculum supraglenoidale scapulae, caput breve-processus coracoideus scapulae
- **INSERTION :** tuberositas radii, aponeurosis m. bicipitis brachii (lacertus fibrosus)
- **INNERVATION:** n. musculocutaneus
- **FUNCTION:** flexion of forearm in supination, c. longum-abduction of arm, c. breve- anteflexion and adduction



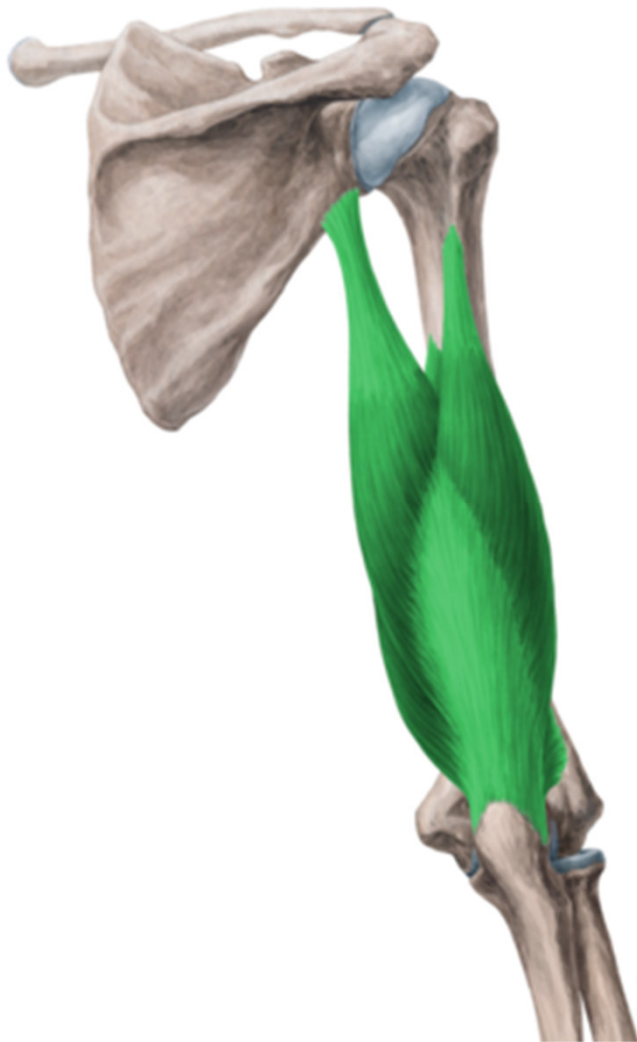median  
nerve

bicipital  
aponeurosis

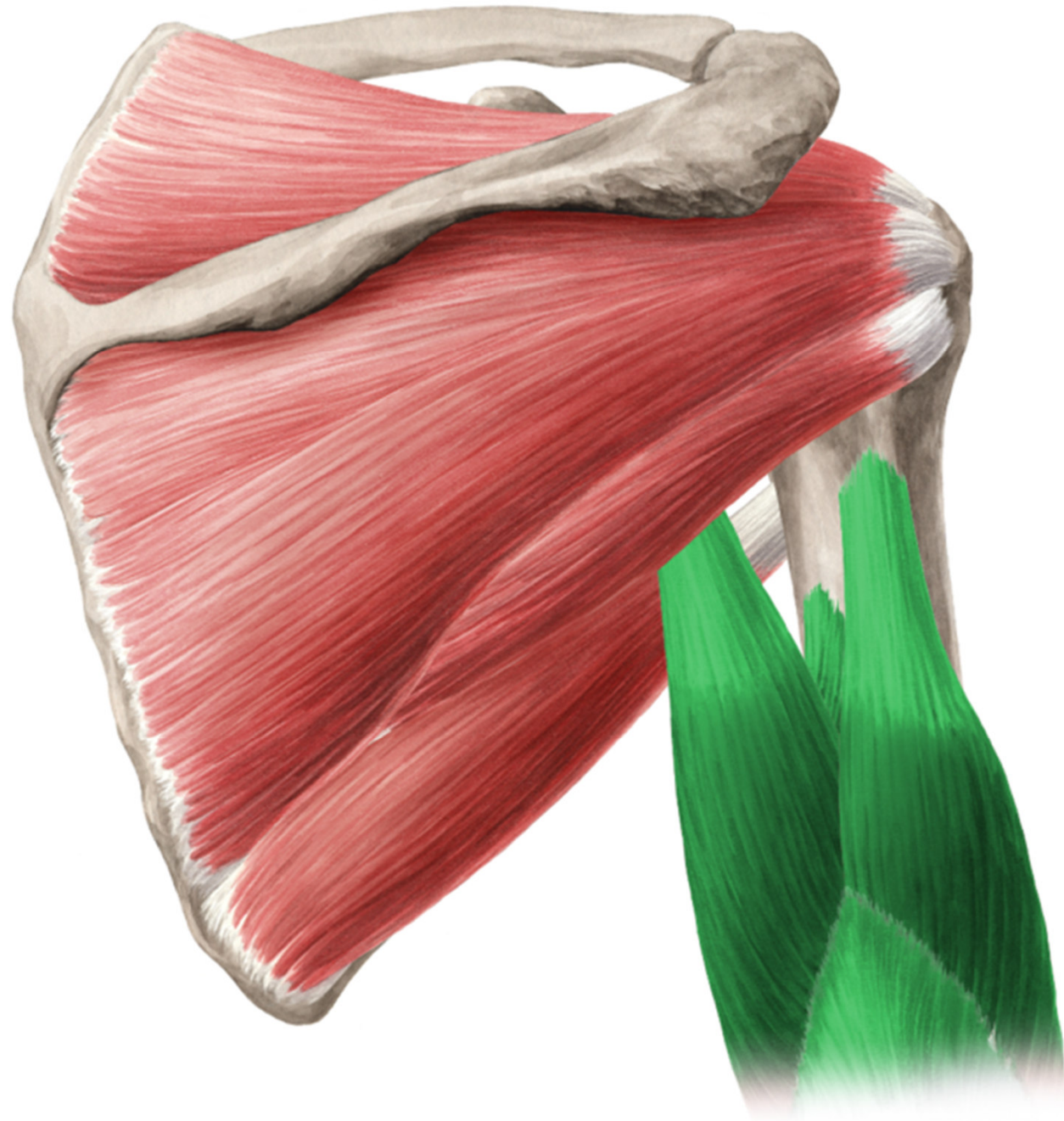pronator  
teres



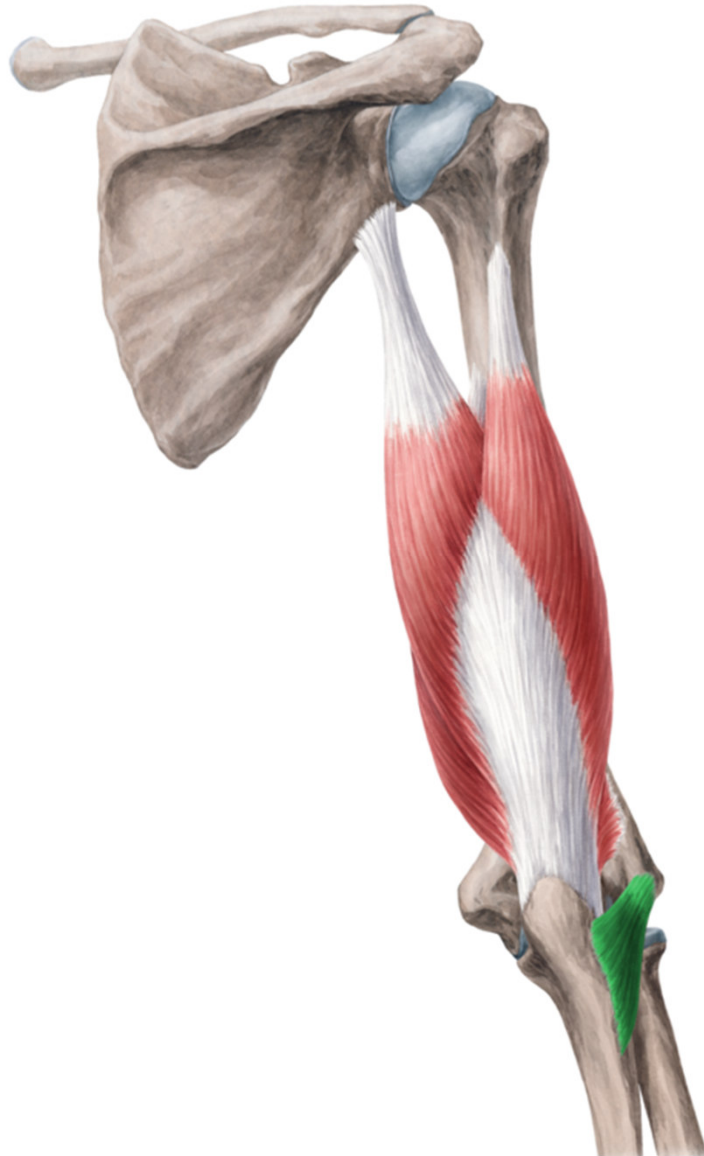# Musculus triceps brachii



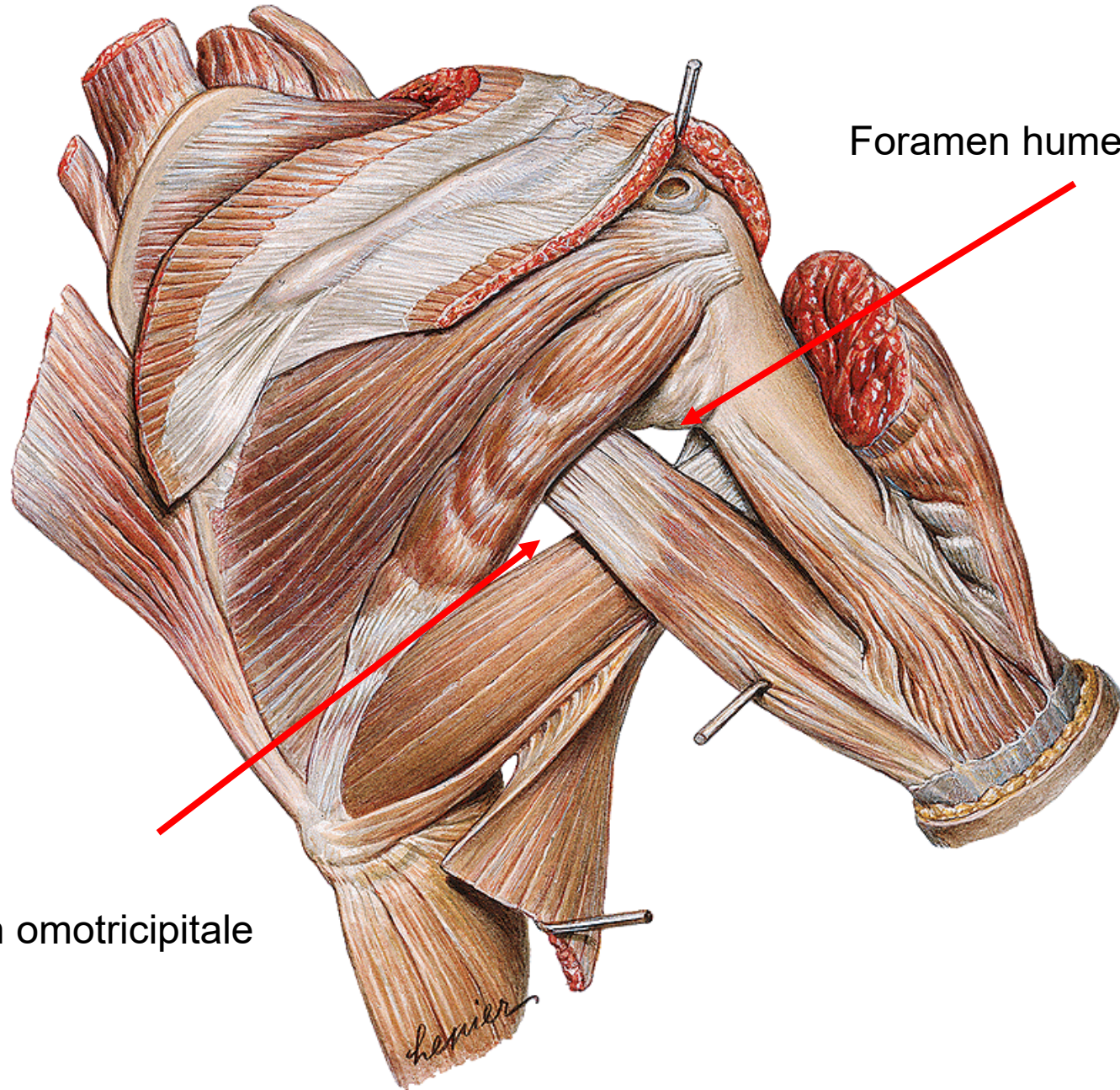
- **ORIGIN:** caput longum-tuberculum infraglenoidale scapulae, caput laterale-proximally from sulcus nervi radialis, caput mediale-distally from sulcus nervi radialis
- **INSERTION :** olecranon ulnae
- **INNERVATION:** n. radialis
- **FUNCTION:** extension of forearm, c. longum-adduction of arm



# Musculus anconaeus



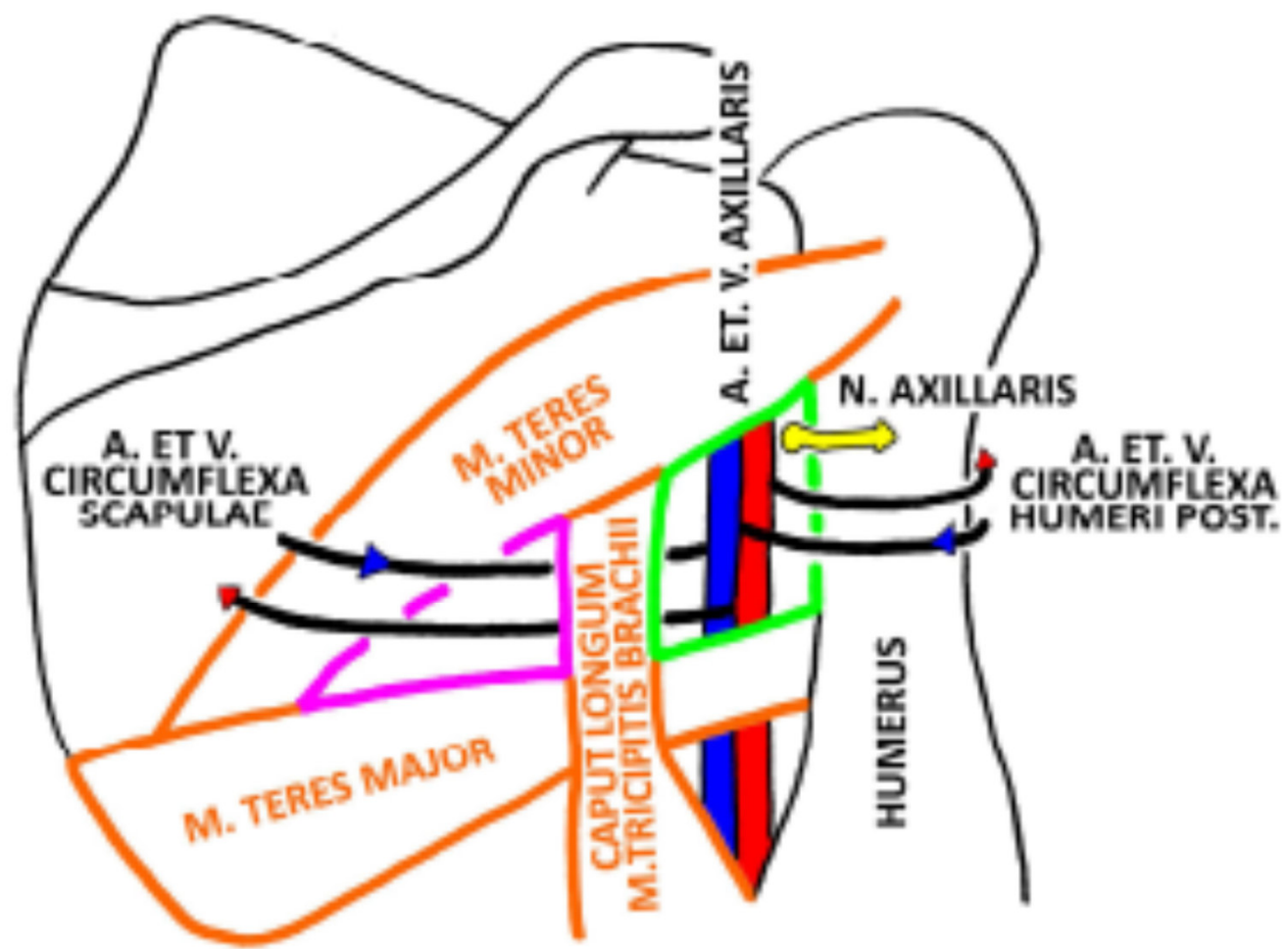
- **ORIGIN:** epicondylus lateralis humeri
- **INSERTION :** olecranon ulnae
- **INNERVATION:** n. radialis
- **FUNCTION:** extension of forearm



Foramen humerotricipitale

Foramen omotricipitale

# FORAMEN OMOTRICIPITALE ET HUMEROTRICIPITALE

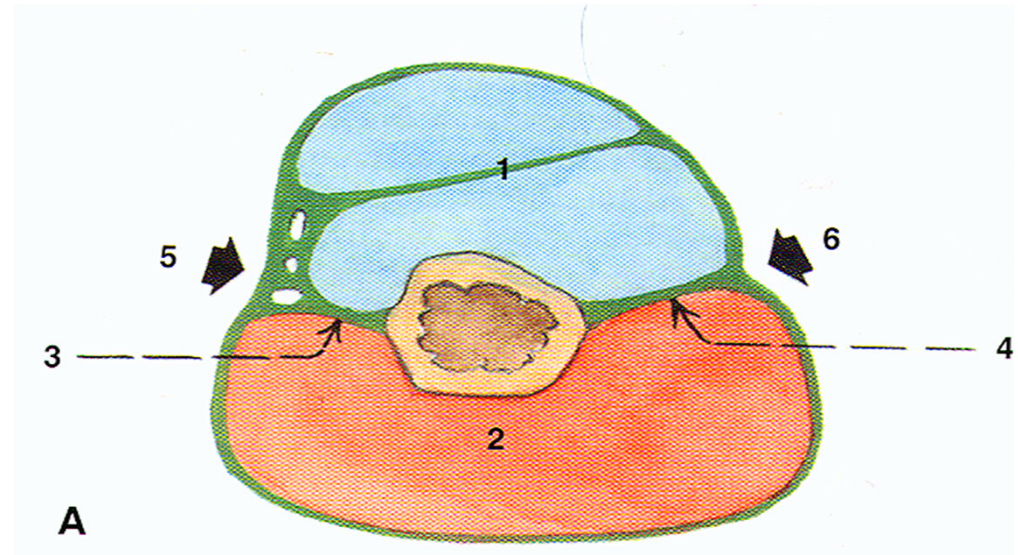
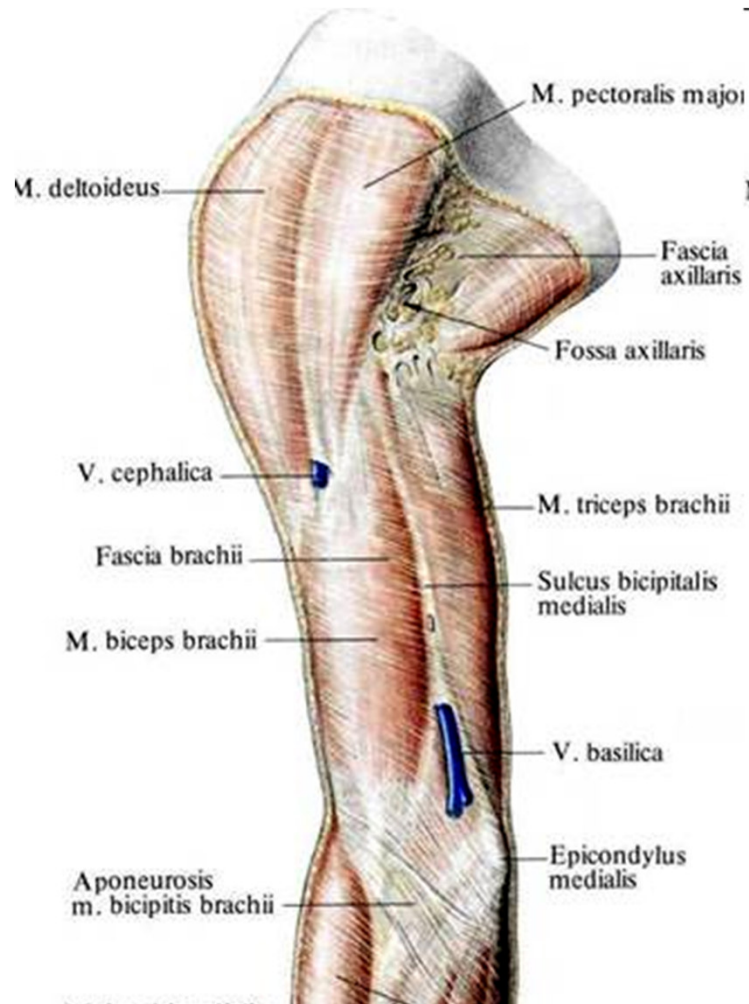




## Fascia brachii

- It is proximal continuation of fascia deltoidea and distally continues as fascia antebrachii

septum intermusculare brachii mediale et laterale- they pull fascia into the depth → sulcus m. bicipitis lateralis et medialis



# Thank you for your attention!

**Obrázky:**

**Atlas der Anatomie des Menschen/Sobotta. Putz,R., und Pabst,R. 20. Auflage.**

**München:Urban & Schwarzenberg, 1993**

**Netter: Interactive Atlas of Human Anatomy.**

**Naňka, Elišková: Přehled anatomie. Galén, Praha 2009.**

**Čihák: Anatomie I, II, III.**

**Drake et al: Gray's Anatomy for Students. 2010**