

4. Pain of the hypogastrium

Pain of the hypogastrium is one of the most common reasons patients are referred by for imaging. Hypogastric pain can be divided into acute and chronic. The task of imaging methods is primarily to rule out a acute abdomen.

The most available methods are **X-ray and abdominal ultrasound**.

Abdominal X-ray

X-ray of the abdomen is performed **in upright or supine position**. Upright position enables to assess the presence of pneumoperitoneum , which appears as a crescent-shaped clearing in the subfrenic area. Supine X-ray is used to evaluate the width of the intestinal loops - to confirm the bowel obstruction (physiologically diameter of small intestine is up to 3 cm, cecum up to 9 cm, the rest of the large intestine up to 6 cm).

Abdominal ultrasound

Abdominal ultrasound is the method of choice in basic differential diagnosis.

In difficult conditions of sonographic examination (obese patient, flatulence) or unclear ultrasound conclusions, CT can be supplemented.

Acute appendicitis

The most common causes of hypogastric pain is inflammation, especially acute **appendicitis** . During sonography, the normal appendix is compressible, painless, with a clearly visible stratification of the wall width up to 3 mm, the total width of the appendix does not exceed 6 mm. Inflammatory changes appear as enlargement of the appendix (to more than 6-7 mm), blurring of the wall layers and hypoechogenicity of the wall (due to edema - fluid is on ultrasound hypoechogenic , i.e. dark), hypervascularisation, further is usually present edema of the surrounding fat and periappendicular fluid. In case of significant clinical suspicion and failure to find the appendix on ultrasound (up to 50%), CT (pelvis) or diagnostic laparotomy with possible appendectomy can be performed.

Diverticulitis

Other inflammatory cause of hypogastric pain include acute **diverticulitis**. Diverticula without inflammatory changes are a common finding in elderly patients. Diverticulitis can manifest clinically in the same way as appendicitis, but diverticula is most often found in the sigmoid colon and colon descendens - so the pain is most often in the left lower abdomen. If diverticulitis is suspected, **ultrasound examination** is the method of first choice. An X-ray of the abdomen is suitable for the assessment of pneumoperitoneum and in the context of a wider differential diagnosis (ileus). The inflammatory altered diverticulum looks on ultrasound as a hypoechogenic formation externally connected to the intestinal wall, in the vicinity there is hyperechogenic edematous fat. In uncomplicated diverticulitis with a typical image, ultrasound examination is sufficient. On ultrasound, there is often limited visualisation of the pelvis and aboral part of the sigmoid, especially in obese patients. CT is used to detect complications, including abscesses and perforations.

Other causes of hypogastric pain

Uncommon causes of hypogastric pain include inflammatory bowel disease (see enteritis and colitis). The method of first choice is ultrasound. X-ray of the abdomen can be performed as part of a broader differential diagnosis (temperature and diarrhea are not typically manifested as pneumoperitoneum or bowel obstruction).

Mesenteric lymphadenitis is an inflammatory process of lymph nodes, especially in the right hypogastrium, which can clinically mimic acute appendicitis. This diagnosis can be considered in young patients with the finding of numerous lymph nodes in the right hypogastrium without any other explanatory pathology on the ultrasound.

Other causes of abdominal pain include diseases of urinary system. **Renal colic** is manifested with colic flank pain irradiating into the inguinal canal (see chapter renal colic).

Cystitis is usually determined clinically and in the laboratory (dysuria, odynouria, increased CRP). During sonography, the bladder must be sufficiently filled, otherwise it loses its informative value (the collapsed wall is usually thick). In cystitis, the ultrasound finding is usually negative; in advanced conditions on ultrasound, diffuse **edematous thickening of the wall** along the entire circumference of the bladder can be observed (focal thickening with absent stratification of the wall are suspected of the presence of a tumor). The thickening of the wall can be mimicked by trabeculization of the wall present in prostatic hypertrophy (muscle strengthening due to urethral obstruction).

In women, hypogastric is a frequently caused by pathology of the genital system. These include ovarian cyst rupture, adnexitis and adnexal torsion. Transabdominal ultrasound can reveal non-specific signs of inflammation such as free fluid and swelling around the affected structures.

Ovarian torsion is on ultrasound is visualised as an enlargement of the ovary with significantly reduced to disappeared vascularization in Doppler mode, there may be free fluid in the vicinity. In the case of ovarian cyst rupture on ultrasound, there is usually visible ovary with the cyst (in the case of bleeding, it usually has an echoic content) and fluid in the vicinity.

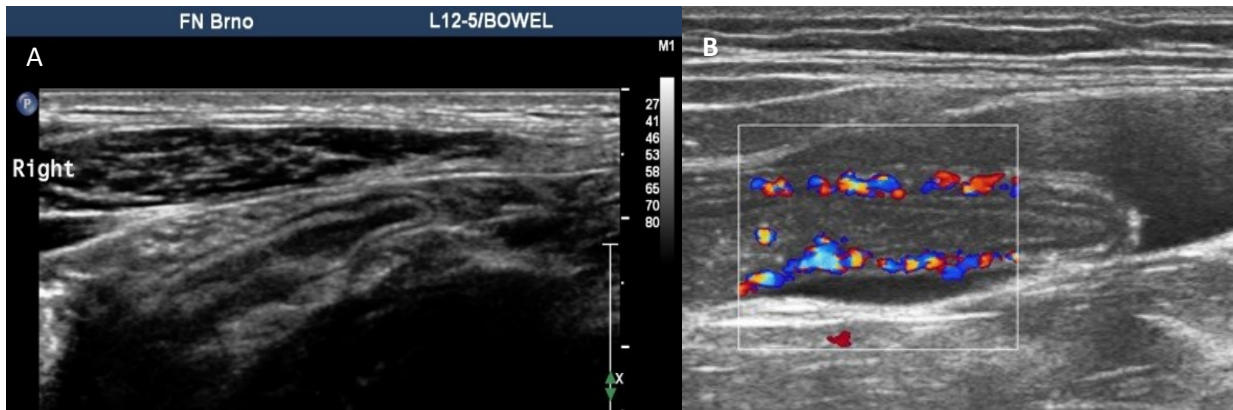


Fig. A - Normal appendix (longitudinal plane) on ultrasound.

Fig. B – Signs of acute appendicitis.

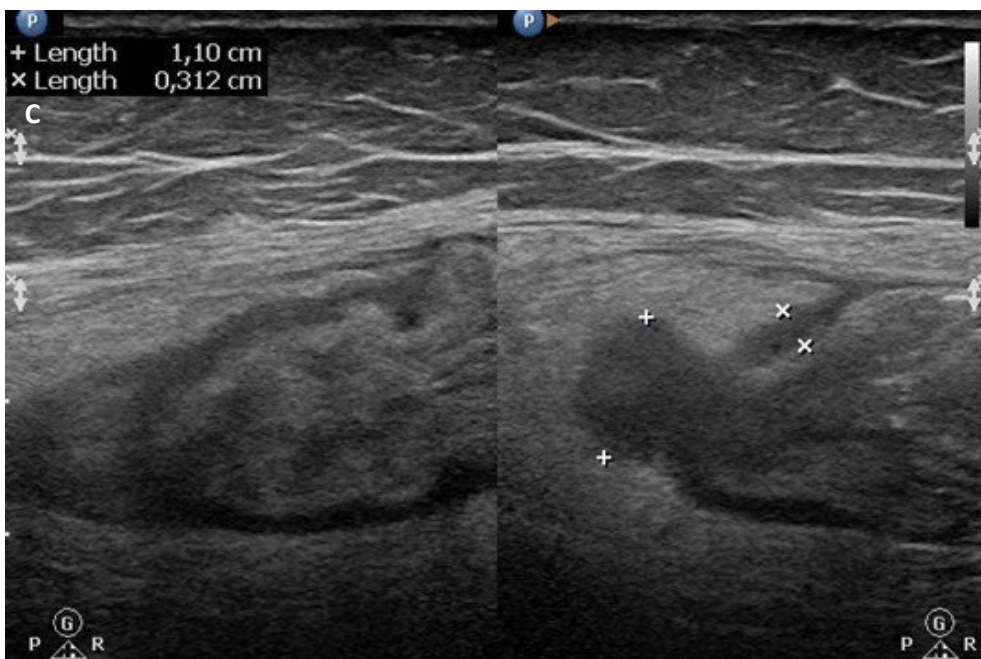


Fig. C – Signs of acute diverticulitis on ultrasound – hypochoic diverticulum with swelling of adjacent fat