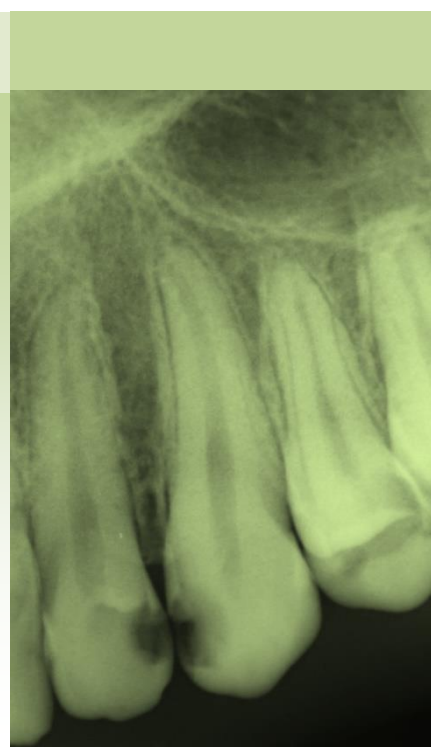


# Diagnosics of the dental caries

## x-ray diagnostics



### Aim

To introduce students to X-ray diagnostics and interpretation of X-ray pictures in the area of Preventive Dentistry, Cariology and Paediatric Dentistry.

### Outcomes

Students will be competent to diagnose the dental caries, its forms and severity, topographical relationship between primary and permanent teeth as well as to indicate appropriate endodontic treatment both in primary and permanent dentition including teeth with open apices and primary teeth under root resorption.

### Target group

ZLPZ041c, ZLDL0922c, ZLDL0821p

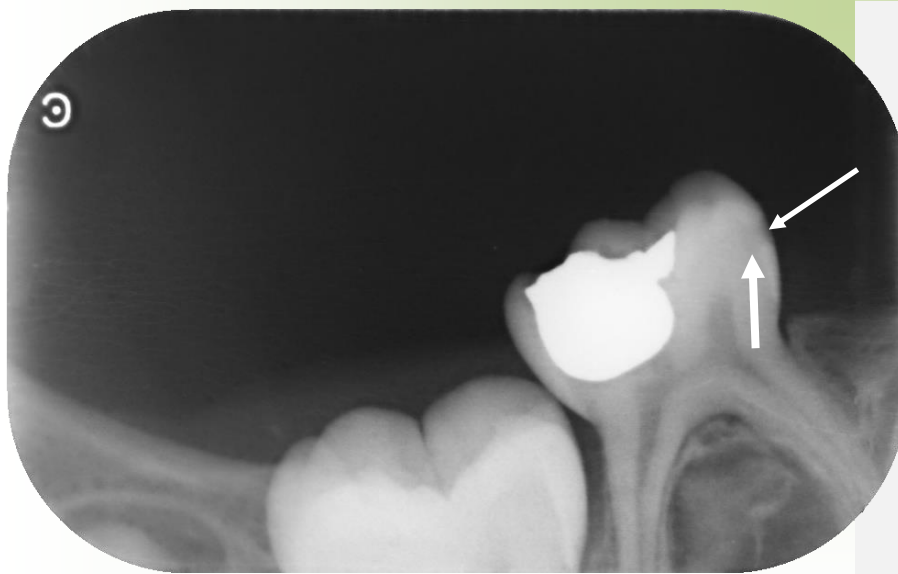
### Prerequisites

Knowledge of following subjects is necessary to understand the topics: Anatomy of teeth, Imaging techniques in dentistry, Preventive dentistry, Cariology, Pediatric dentistry.

### Contents

Enamel caries - Caries incipiens ..	2
Caries in dentine	7
Caries in dentine - Caries pulpa proxima .....	9
Caries in dentine - Caries ad pulpam penetrans .....	12
Primary dentition .....	14
Early childhood caries (ECC) .....	16
Premature loss of primary molars .....	20
Course of primary molars resorption.....	25
Age of the child 8 years .....	31
Age of the child 9 years .....	32
Age of the child 10 years .....	33
Age of the child 12 years .....	34
Assessment of the root developmental stage.....	35

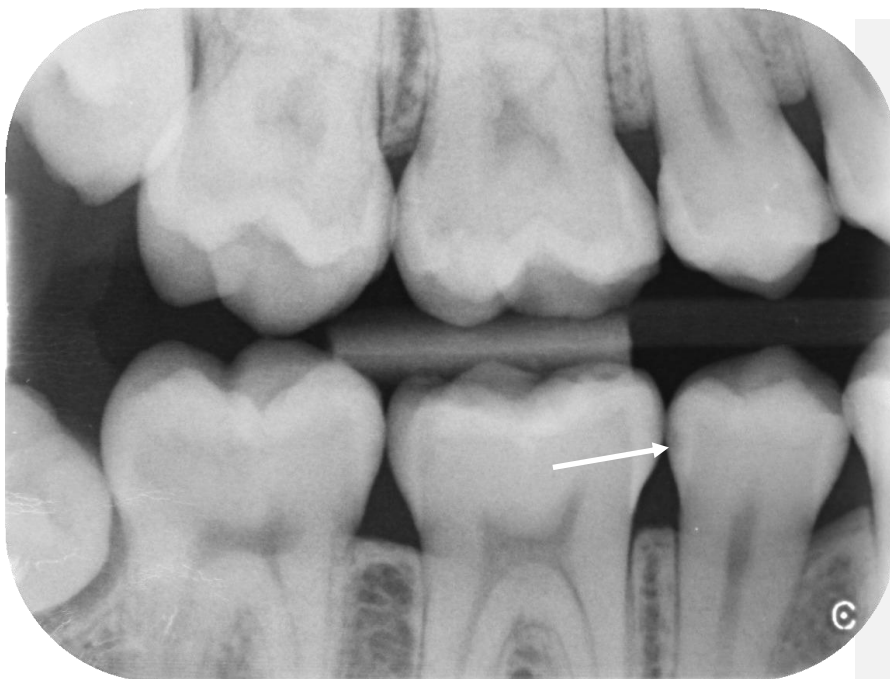## Enamel caries - Caries incipiens



Periapical projection. 85, low conical radiolucency mesially (→), reaching into the outer half of the enamel. Higher magnification demonstrates the radiolucency penetrating slightly into the dentine (→).

### Commentary

Dg: caries in dentine, D3.



B-W projection. 45 distal surface, caries incipiens (→). Higher magnification demonstrates radiolucency also in the inner half of the enamel - D2.

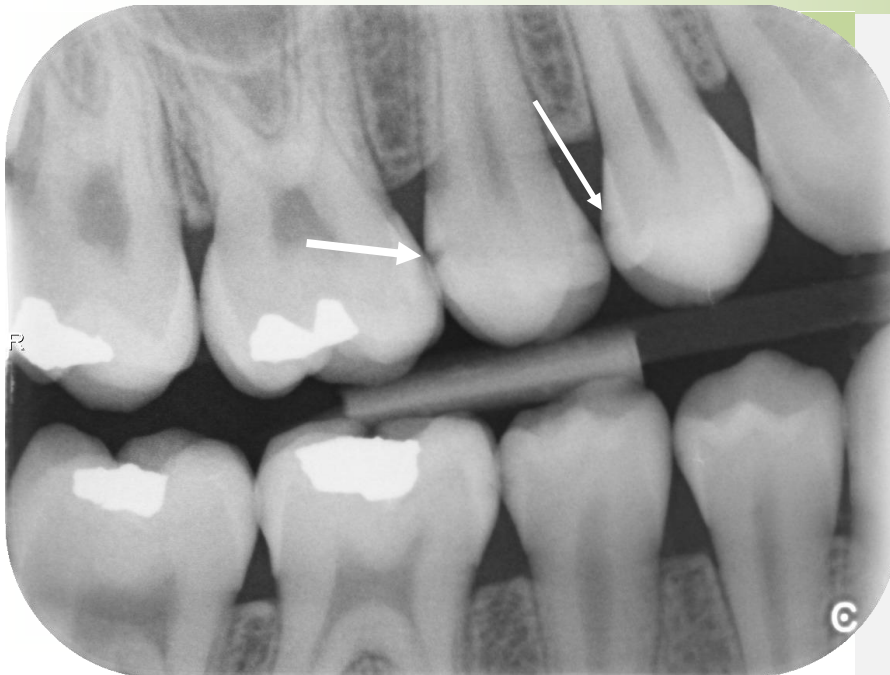### Commentary

Dg: enamel caries D2

### Study motivation

Identify caries incipiens in other localizations (16,15,46, 47).

## Enamel caries - Caries incipiens



### Commentary

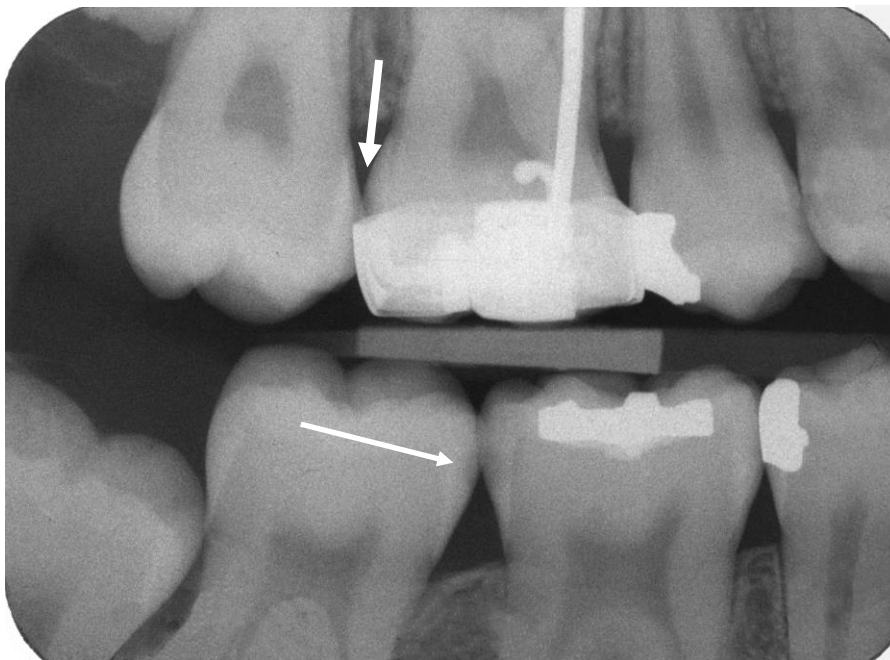
Dg: D2.

15 distally – the lesion on the boundary between D1 a D2.

### Study motivation

Assess remaining approximal surfaces and determine the diagnosis.

B-W projection. 14 caries incipiens on the distal surface (→) DG: D1, 15 caries superficialis distally (→) and mesially.

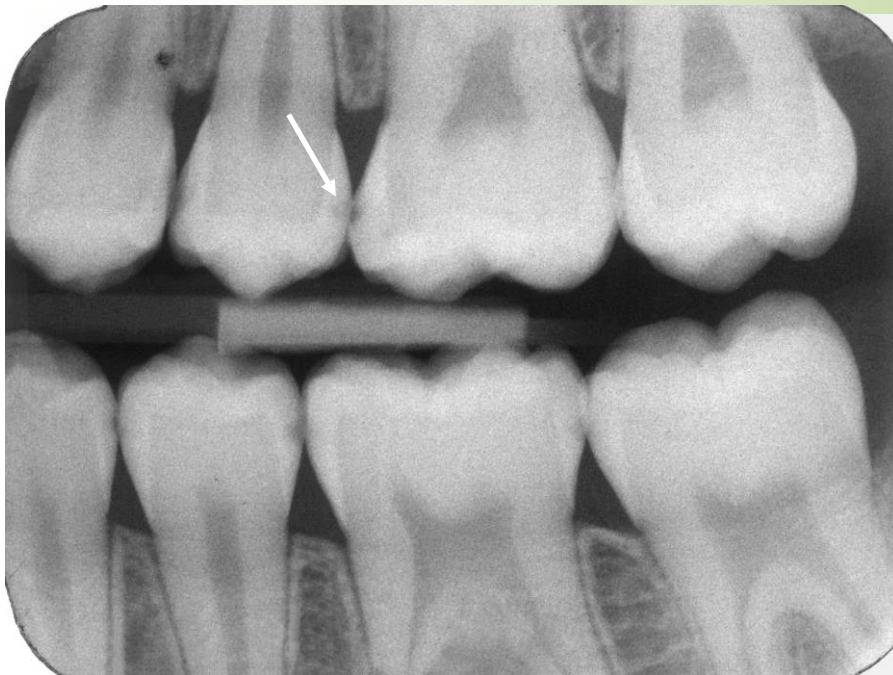

### Study motivation

Assess the remaining surfaces.

B-W projection. 17, 16 caries incipiens D1 (→), however, D2 is suspicious on 16, 47 caries incipiens D1 mesially (→), 46 caries superficialis D2 distally.

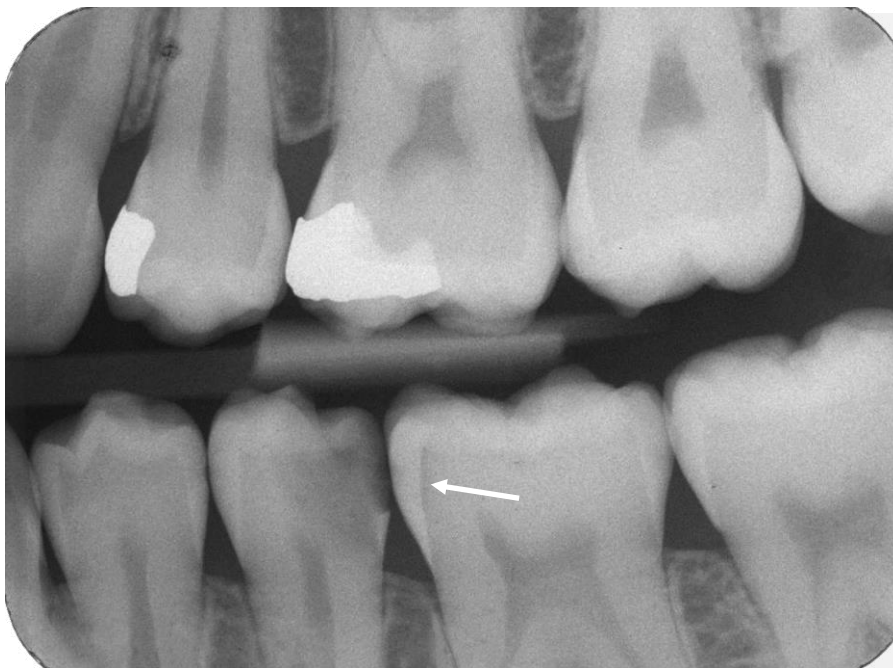## Enamel caries - Caries incipiens



### Study motivation

Localize the lesions.

B-W projection. 35 Caries superficialis D2 on the distal surface (→).  
D1 lesion on several approximal surfaces of molars and premolars.



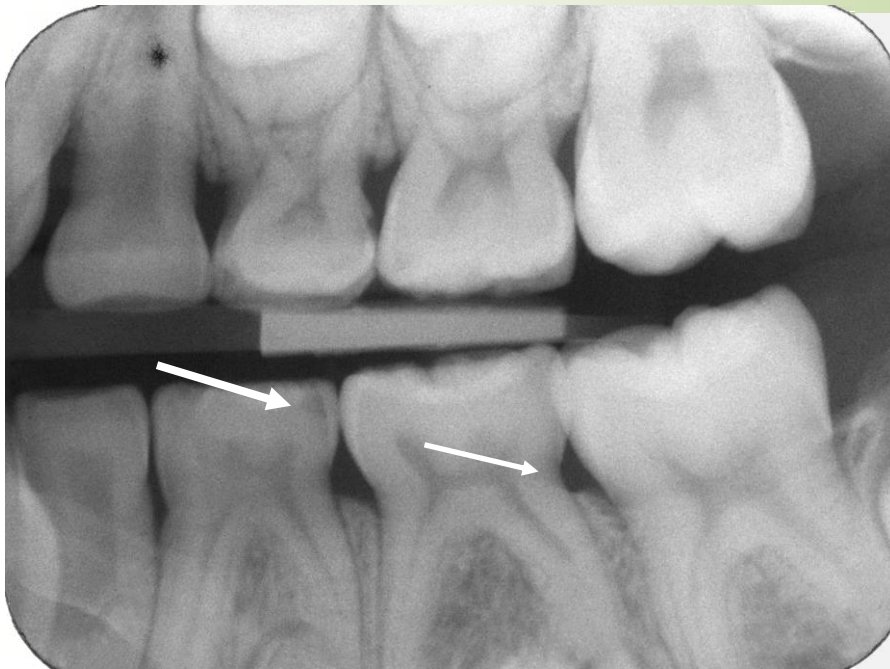
### Commentary

Dg: D3, chronic caries.

B-W projection. Dentine caries D4 on the distal surface of 35.  
Another diagnosis: caries pulpae proxima.  
Radiolucency in dentine along the entire dentine-enamel junction mesially (→), mild surface radiolucency in enamel (D1) missing the typical conical character.



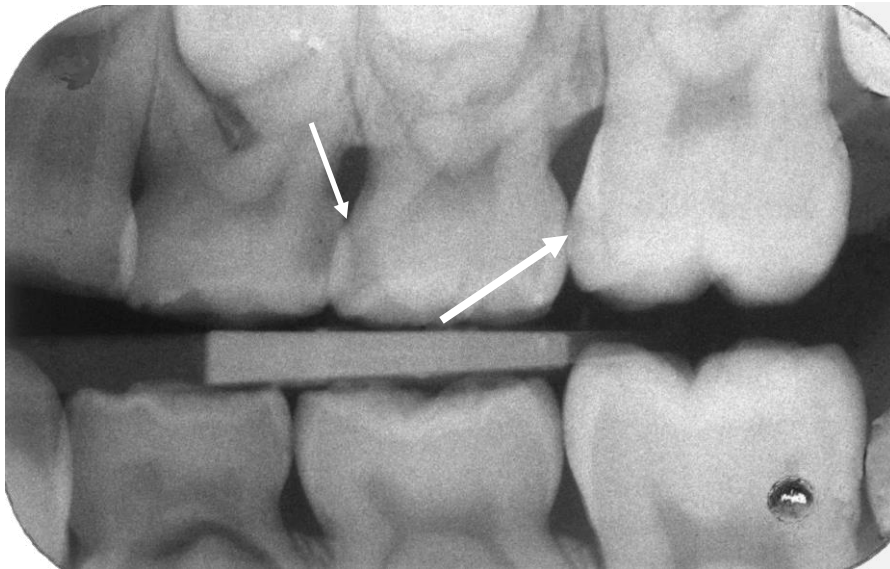
## Enamel caries - Caries incipiens



B-W projection. 74 caries in dentine D3 distally (→),  
75 radiolucency - burn out effect distally. (→).

### Study motivation

Identify another lesions and compare morphology of primary and permanent molars.

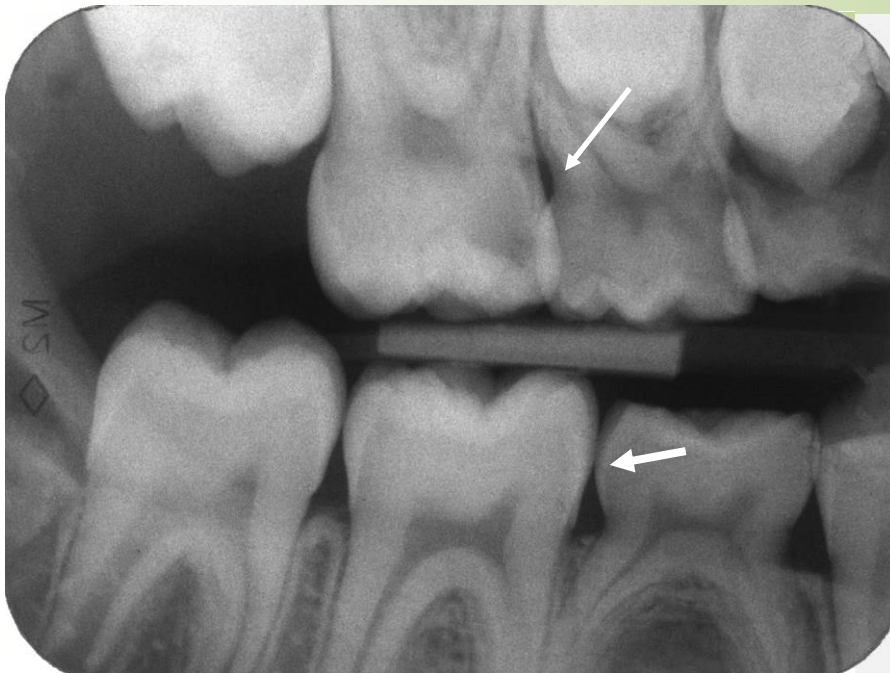


B-W projection. 64 distally, 65 mesially caries in dentine D4 (→),  
26 caries in dentine D3(→).

### Study motivation

Identify another lesions and compare morphology of primary and permanent molars.

## Enamel caries - Caries incipiens



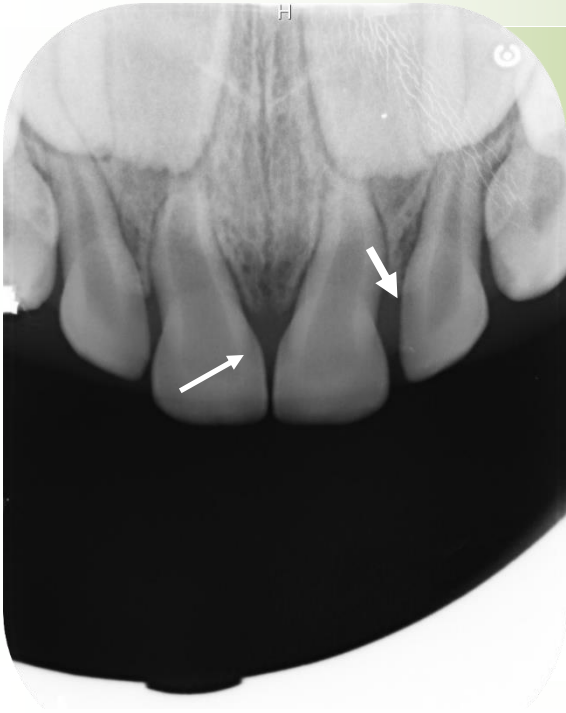
### Study motivation

Identify another lesions and compare morphology of primary and permanent molars.

B-W. projection. 16 caries in dentine D4, caries pulpaе proxima, burn-out effect 55 (→).

Caries superficialis affecting 85 distally (→).

## Caries in dentine



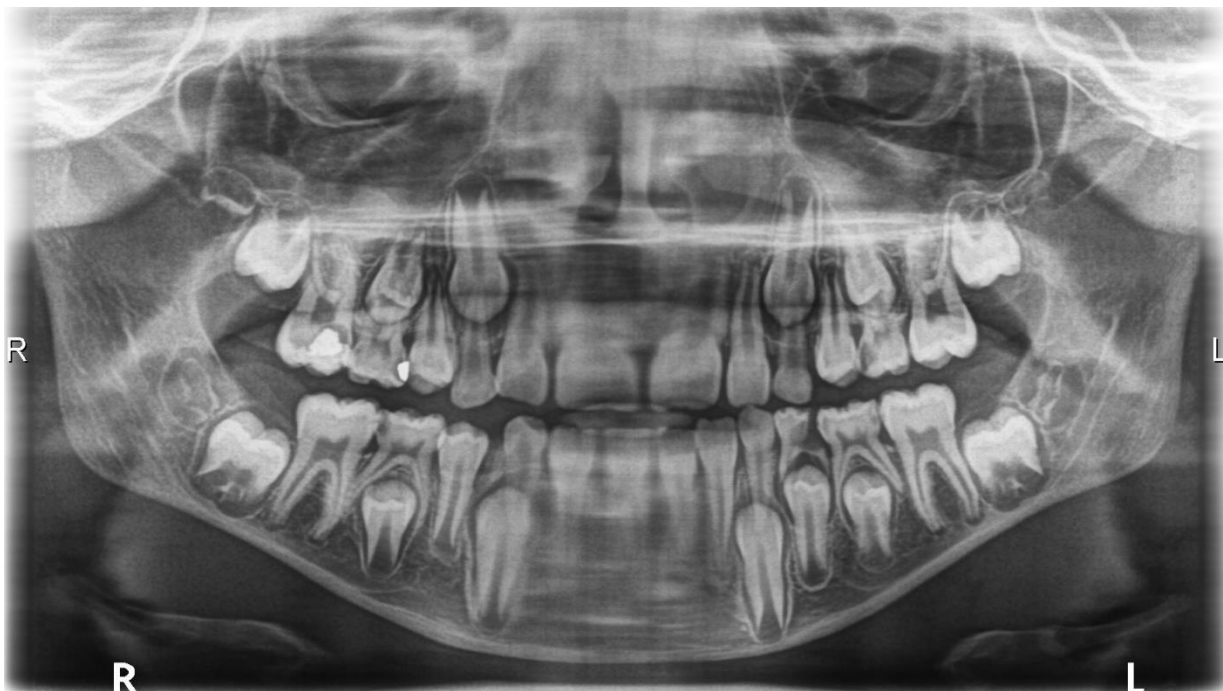Periapical projection, primary dentition, 5-year child. caries superficialis 51,61, mesially (→). Caries in dentine 52, 62 (→).

### Commentary

Caries pulpae proxima.

### Study motivation

Evaluate the thickness of dentine wall and the size of the dental pulp cavity in all 4 incisors.

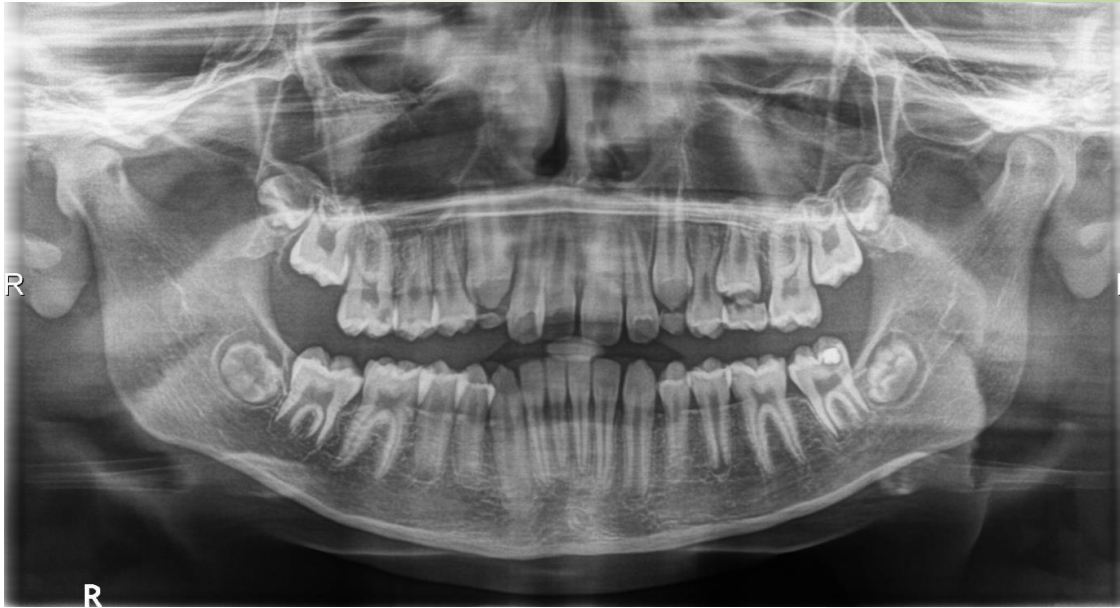

OPG, 10-year-old child, mixed dentition. Caries in dentine: 55-caries sec., 16-caries sec. 65, 75, 85- caries in dentine, 74 caries ad pulp. penetrants.

### Study motivation

Evaluate the state of other teeth in the dentition and calculate the dmft, DMFT indices.

## Caries in dentine



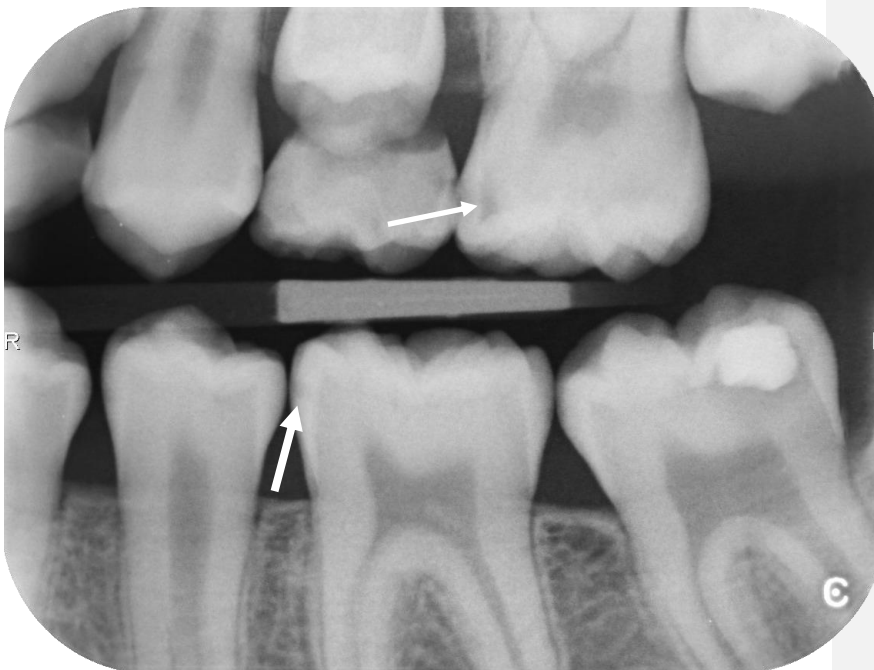OPG, child, 11 years. Susceptible caries in dentine 16 mesially, 15 distally, 26 mesially and distally, 37 secondary caries, 36 caries in dentine mesially, 35 distally.

### Commentary

Caries pulpae proxima.

### Study motivation

For students of the 4. year: Describe developmental root stages in permanent erupted/erupting permanent teeth.



BW projection – left. The x-ray demonstrates substantially smaller extent of radiolucency than that visible on OPG projection. 26 (→), 36 (→)

B-W projection is more precise.

26 mesially corresponds to D3, distally to D0,

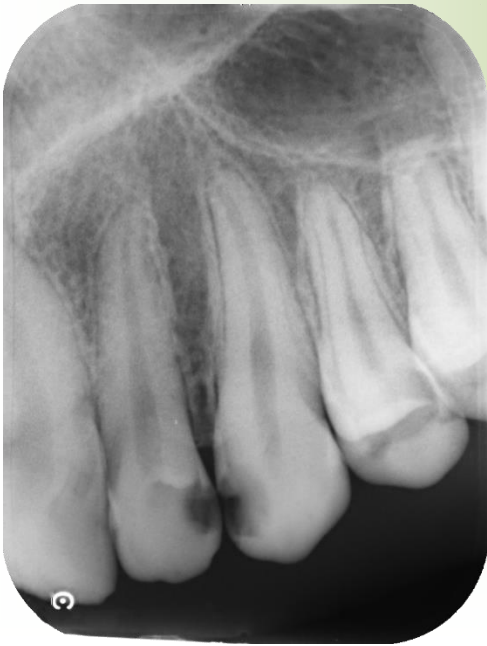35 corresponds to D0,

36 corresponds to D1,

37, caries extent corresponds approximately to the depth between D3 to D4.



## Caries in dentine - Caries pulpaе proxima



Periapical projection, extensive radiolucency localized on the distal surface of 22 and mesial surface of 23 extending to the dental pulp vicinity.

### Commentary

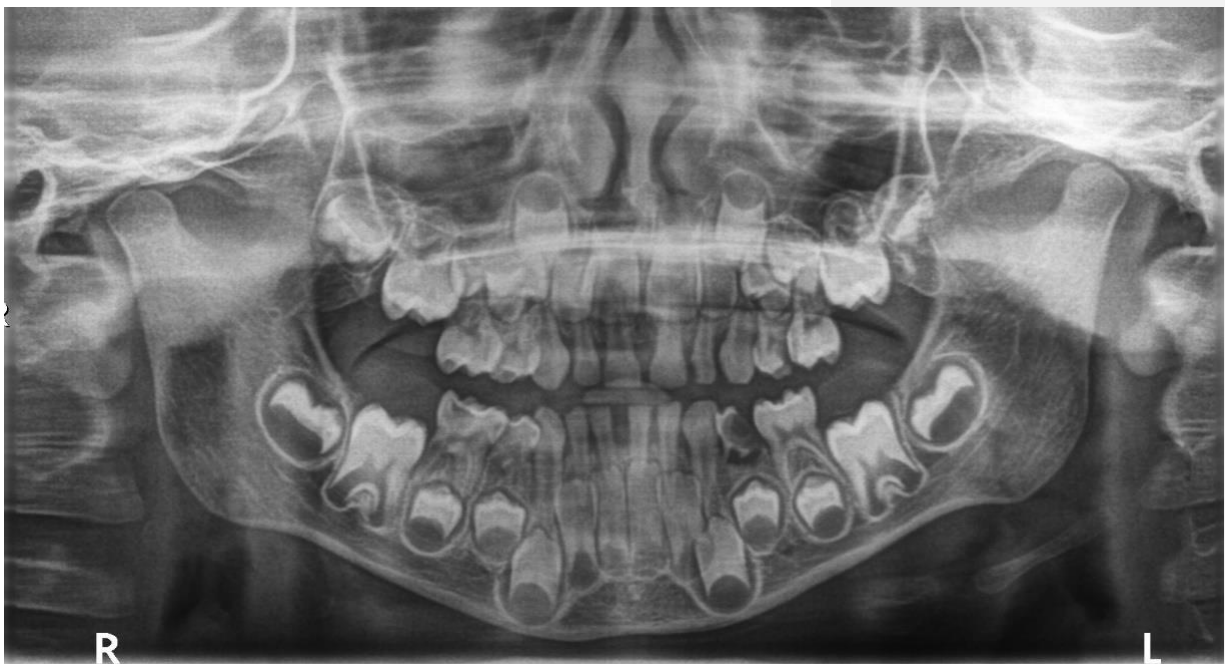
Caries pulpaе proxima.

### Study motivation

Describe carious lesions on remaining teeth.

### Commentary

Dg. Early childhood caries.

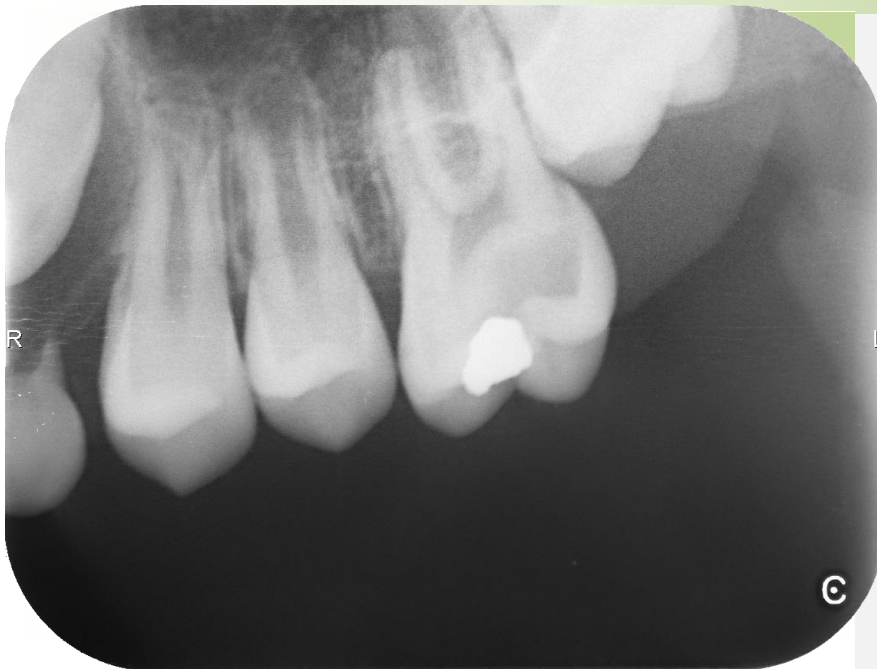

OPG of primary dentition. Caries pulpaе proxima in teeth 85, 74. Distinct radiolucency in the root area of 74, the roots are almost resorbed.

### Study motivation

Assess the state of remaining teeth of the primary dentition. Mention the age, in which marked root resorption of the first primary molars can be detected.

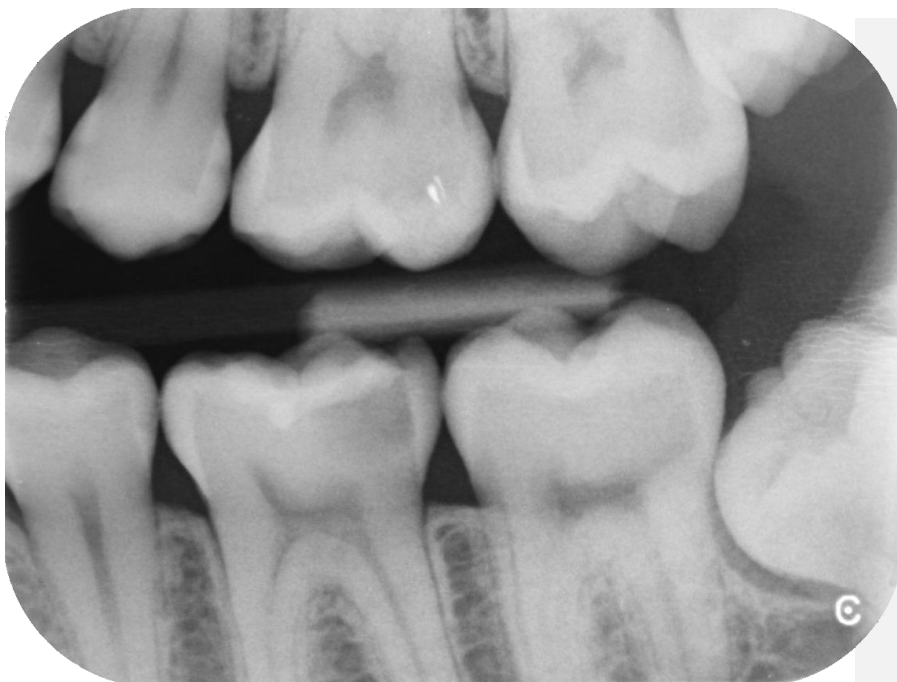## Caries in dentine - Caries pulpae proxima



Periapical projection. 26 caries pulpae proxima, secondary caries.

### Study motivation

Repeat: types of the dental caries.

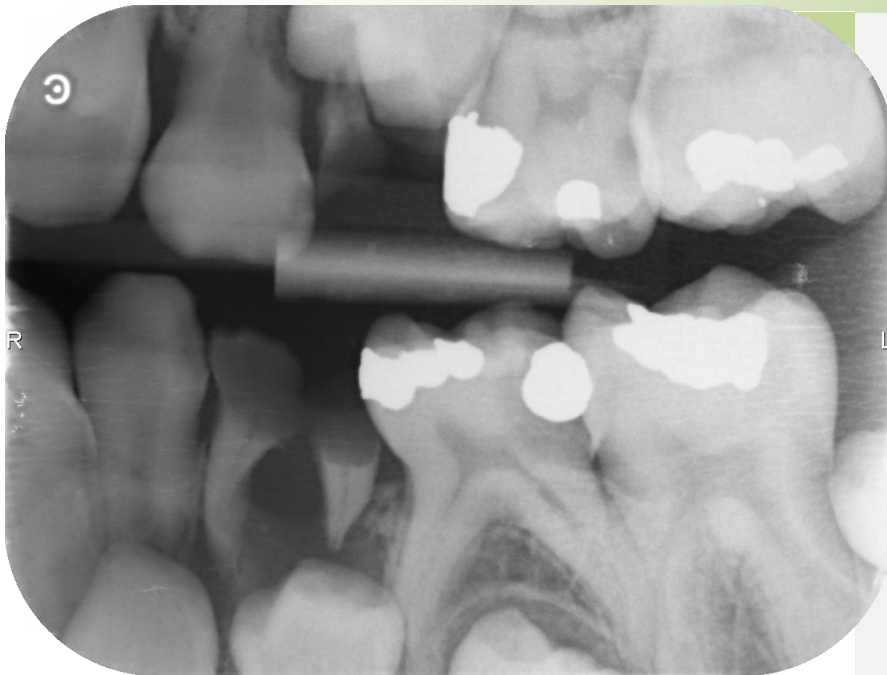


B-W projection. 36, caries pulpae proxima, primary caries.  
Cariou lesion D0 on approximal surfaces of 36.

### Study motivation

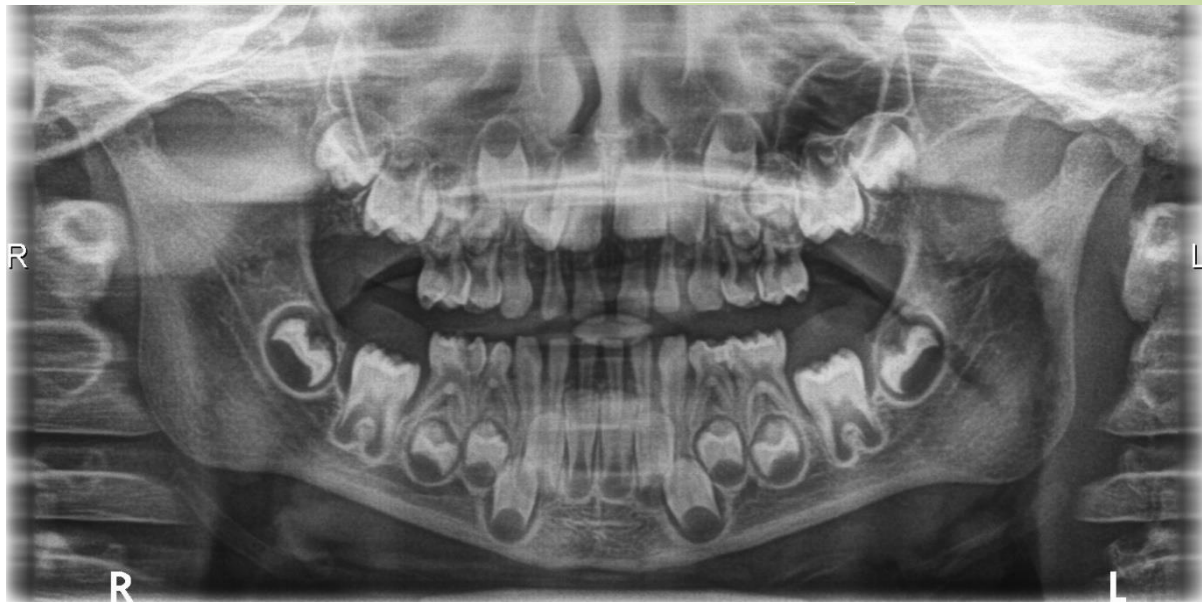
Repeat: types of the dental caries, mention the ways of microbes penetration into teeth.  
Cariou lesion D0 on approximal surfaces of 36.

## Caries in dentine - Caries pulpae proxima



B-W projection. 75 caries pulpae proxima, caries sec.  
74, 64 destructed by caries, persisting roots of the teeth surrounded by expressed radiolucency visible also in the interradicular space, susp. ostitis.

## Caries in dentine - Caries ad pulpam penetrants

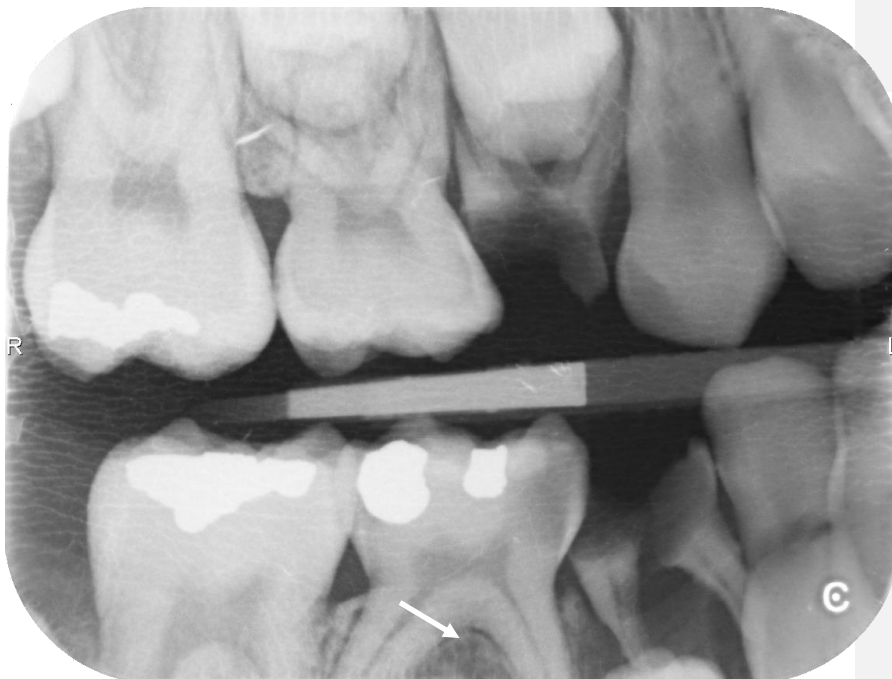

OPG, primary dentition. Child, 5 years. Marked teeth destruction in the lower jaw. Caries ad pulpam penetrants in: 85, 84, 74, 75. Dental caries penetrating into the dental pulp. Extensive carious defects also in the upper jaw, because of teeth overlapping the distinct diagnosis in individual teeth is not possible.

### Commentary

The case can be diagnosed as early childhood caries, so called ECC.

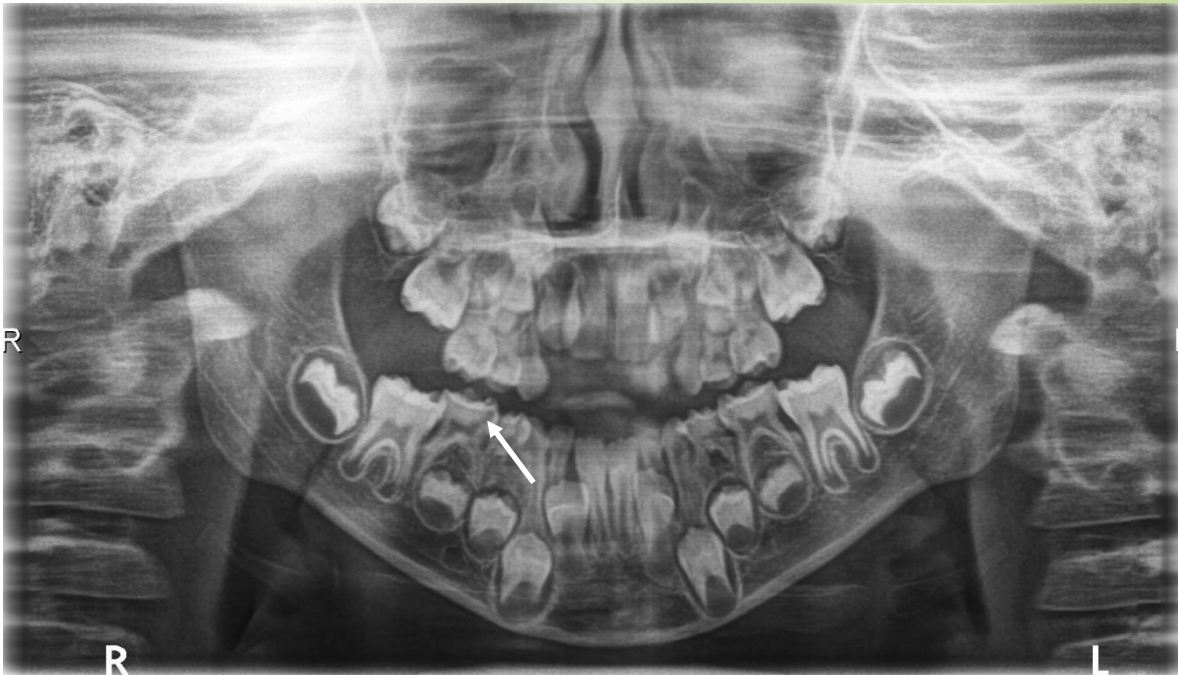
Notice the beginning of root resorption of lower primary molars.



B-W projection, child, 9 years. 85, Caries ad pulpam penetrants mesially, mild radiolucency of bone in bifurcation, signaling beginning of periodontitis (→). Total destruction of teeth 54, 84.



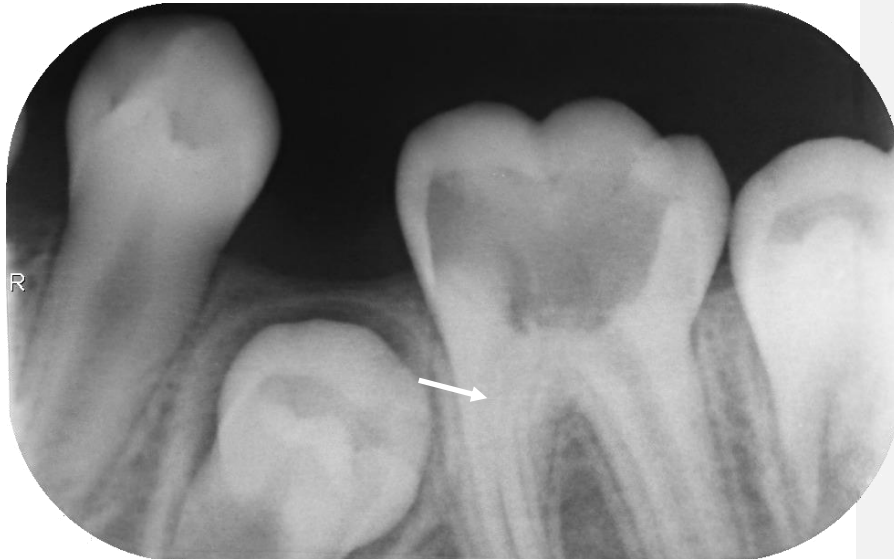## Caries in dentine - Caries ad pulpam penetrants



OPG, mixed dentition, child, 5 years. Caries ad pulpam penetrants 85, 75 – distinct radiolucency extending from mesial dental pulp horns to the dental pulp cavity. (→).  
74 – interradicular radiolucency suggesting otitis.

### Commentary

Assess condition of remaining teeth both in upper and lower jaws. Determine the developmental stage of 46, 36.

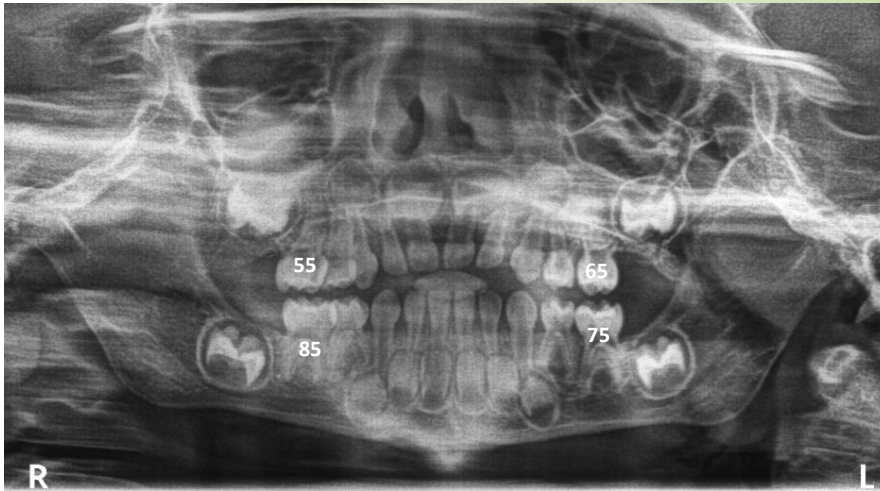


BW projection, child, 11 years, 36. Extensive radiolucency in the dental pulp cavity, neither its ceiling nor the floor can be defined distinctly. Caries penetrates inside, till to the root canal orifice. Distinct manifestation of defensive dental pulp reaction, radioopacity in the mesial root canal – dental pulp obliteration (→).

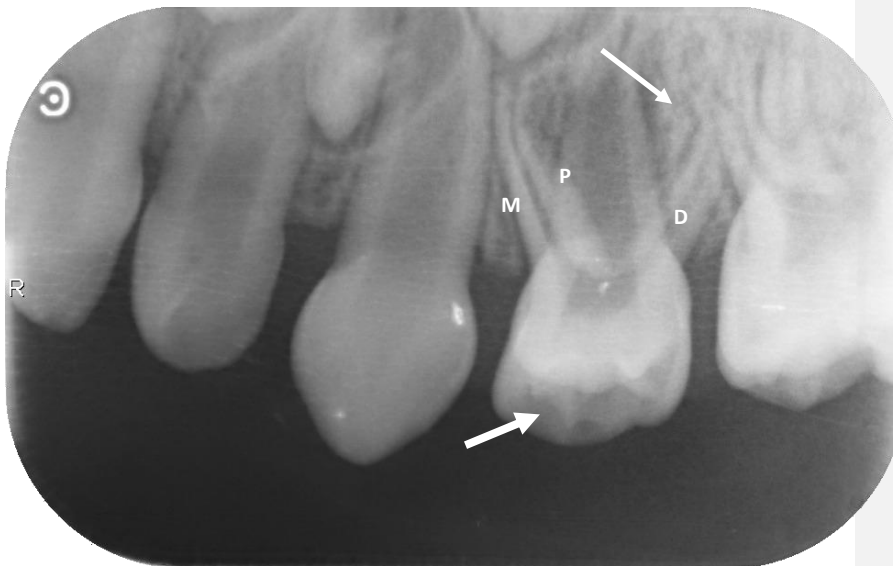### Commentary

Describe morphology of 34.

# Primary dentition



OPG. Child, 2 and half a year. Primary carious dentition. Second primary molars are numbered. (FDI system). All primary molars display areas with mild radiolucency, susp. caries. Changes in the crown shape of 61 indicate presence of caries. Remaining upper incisors have irregular radiolucency in the crown, susp. caries.



Periapical projection, the same case as on the previous OPG. 64-distinct radiolucency in the interradicular space. Mesiobuccal root-M, distobuccal root-D, palatal root-P. Presence of the fourth root cannot be excluded. (→) Radiolucency in the occlusal part of the crown (→), caries does not penetrate inside the dental pulp cavity.

## Commentary

Buds of 45,44 a 34, 35 are not visible yet, mineralization of their crowns will start later. Buds of all first permanent molars are present, their crowns are formed, they mineralize gradually.

## Study stimulation

Detect all radiolucent areas in the present teeth. Compare dentine thickness and size of dental pulp cavity Repeat: development and eruption of primary and permanent teeth.

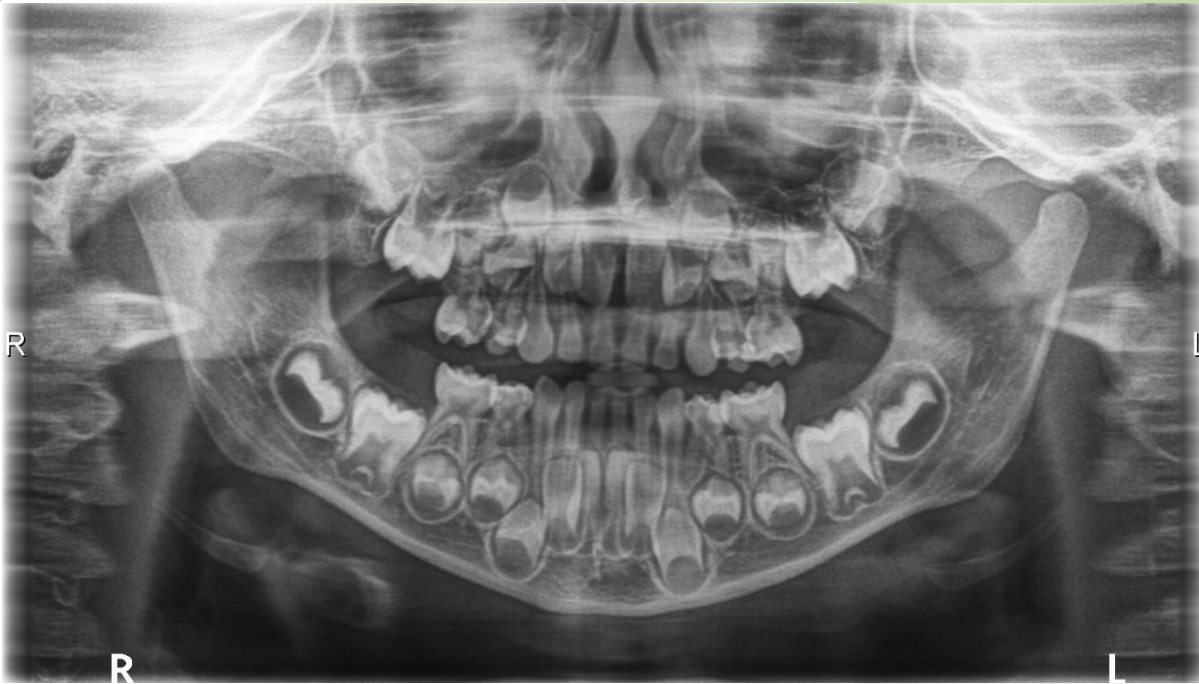## Commentary

Cause of the interradicular radiolucency in the 64 area is a disease of the dental pulp (necrosis/gangrene) because of untreated dental caries (64).

## Study stimulation

Assess the root development of 64 (M root), evaluate the thickness of the dentinal wall in all the present teeth and evaluate radiolucency in the crown of 62. Compare with the image in OPG.

## Primary dentition



OPG. Child, 6 years. Primary, carious dentition, example of ECC. Buds of permanent teeth are present, including the second molars. Presence of the third molars cannot be at that age confirmed. Permanent molars are in a different stage of crown/root development (36, 46). Primary incisors in the upper and lower jaws exhibit signs of root resorption, which is in lower central incisors advanced. First signs of root resorption can be observed in lower primary molars, in the upper jaw the situation is not well distinct (overlapping teeth).

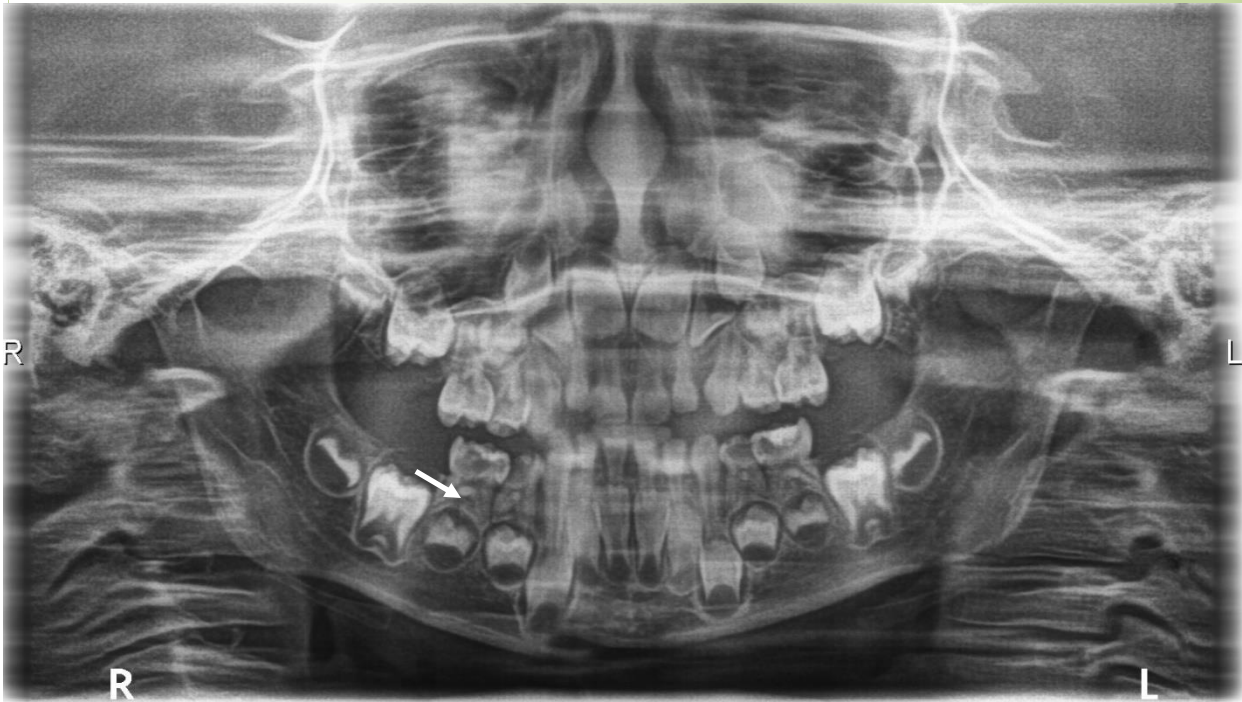
### Commentary

Considering the caries severity there is a danger of loss of points of contact in molar region and as a result mesial shift of primary molars. The result of the situation may be premature loss of space for permanent successors and the crowding (ectopic eruption).

### Study stimulation

Calculate dmft and dmfs index. Observe the arrangement of buds of permanent teeth in the frontal region – repeat development and eruption of permanent teeth.

## Early childhood caries (ECC)



OPG. Age of the child: 5 years. Destruction of primary dentition. Radiolucency of different extent can be detected in all teeth except for frontal lower teeth. Owing to the radioopacity (summation effect) in the midline exact caries detection in this area is not possible. (→ -interradicular radiolucency 85)

### Commentary

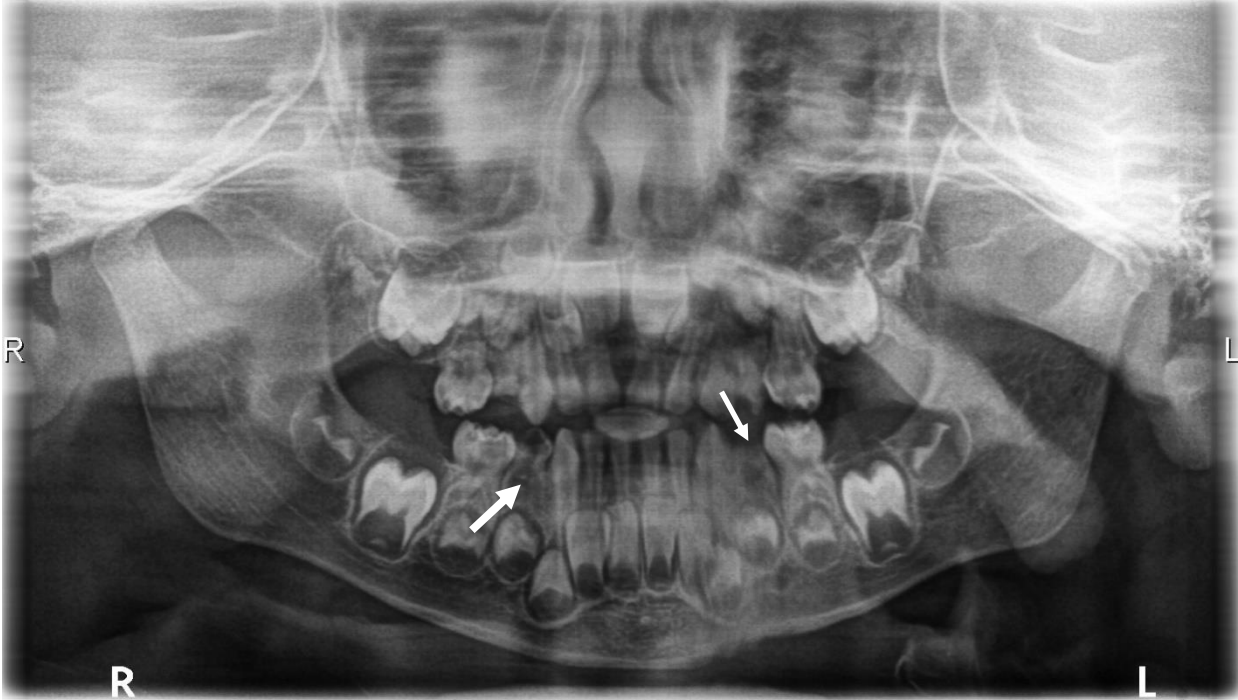
Caries pulpae proxima/ad pulpam penetrans affecting all primary molars. Mild interradicular radiolucency suggesting penetration infection into that region is visible (→). Root resorption of lower primary molars has already started. Exact diagnosis in individual upper primary teeth cannot be determined.

### Study motivation

Describe possible way of infection penetration from the dental pulp cavity into the interradicular space. Repeat morphology of molars. Can we use root canal therapy (root canal filling) in the case presented on the OPG?



## Early childhood caries (ECC)



OPG. Age of the child: 3 and a half a year. Destruction of primary dentition. Radiolucency of different extent affecting all the teeth except for lower frontal teeth. Radix of 54 and loss of space for 15 can be detected in the 54 area. Tooth 84 is separated by caries into two parts (→), distinct radiolucency in the interradicular area, susp. ostitis. The same picture can be observed in 74 area (→). Buds of molars 17,16,26,27, 36, 37, 46, 47 can be detected.

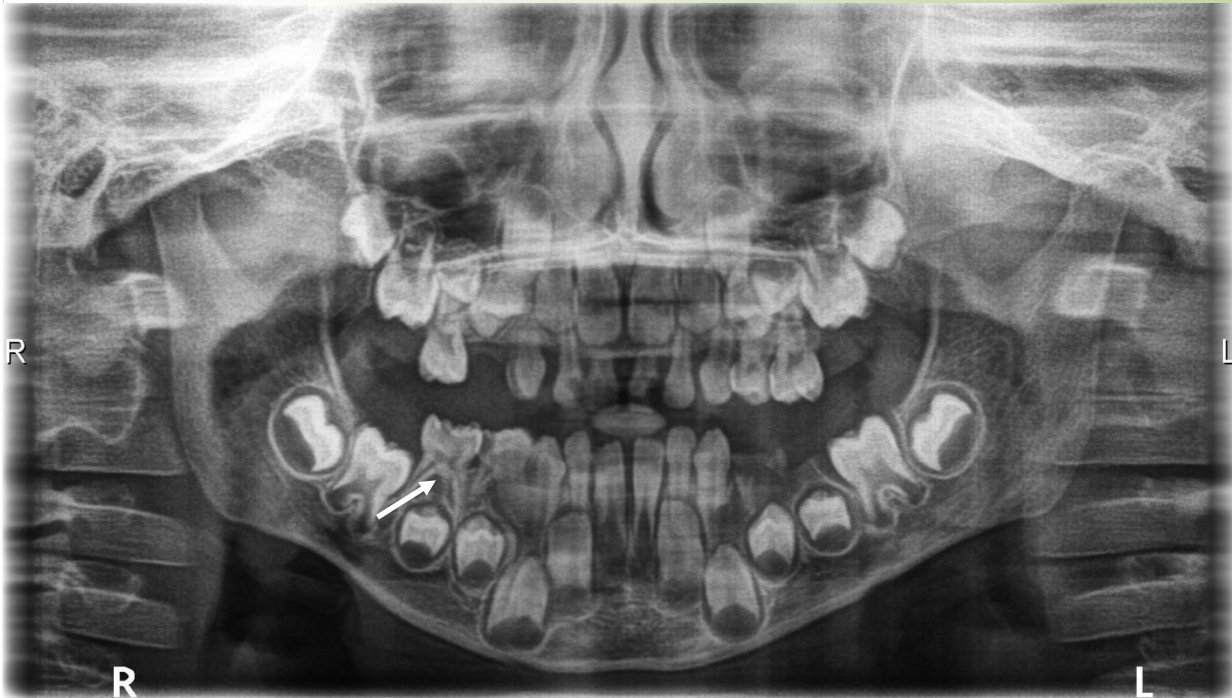
### Commentary

Surgical-conservative treatment followed by space maintainers will be recommended. In favourable situation prefabricated crowns on second primary molars with corresponding space maintainers can be used (teeth are vital or treated by coronal pulpotomy).

### Study stimulation

Assess dmft and dmfs.

## Early childhood caries (ECC)



OPG. Age of the child: six and half a year. Mixed dentition, permanent upper central incisors, and lateral lower incisors before eruption. Lower permanent central incisors erupting, permanent first molars before eruption. Primary dentition is destructed by dental caries.  
54 extracted  
75, 74 only radices.  
85, 84 caries ad pulpam penetrans, interradicular radiolucency (→), susp. ostitis.

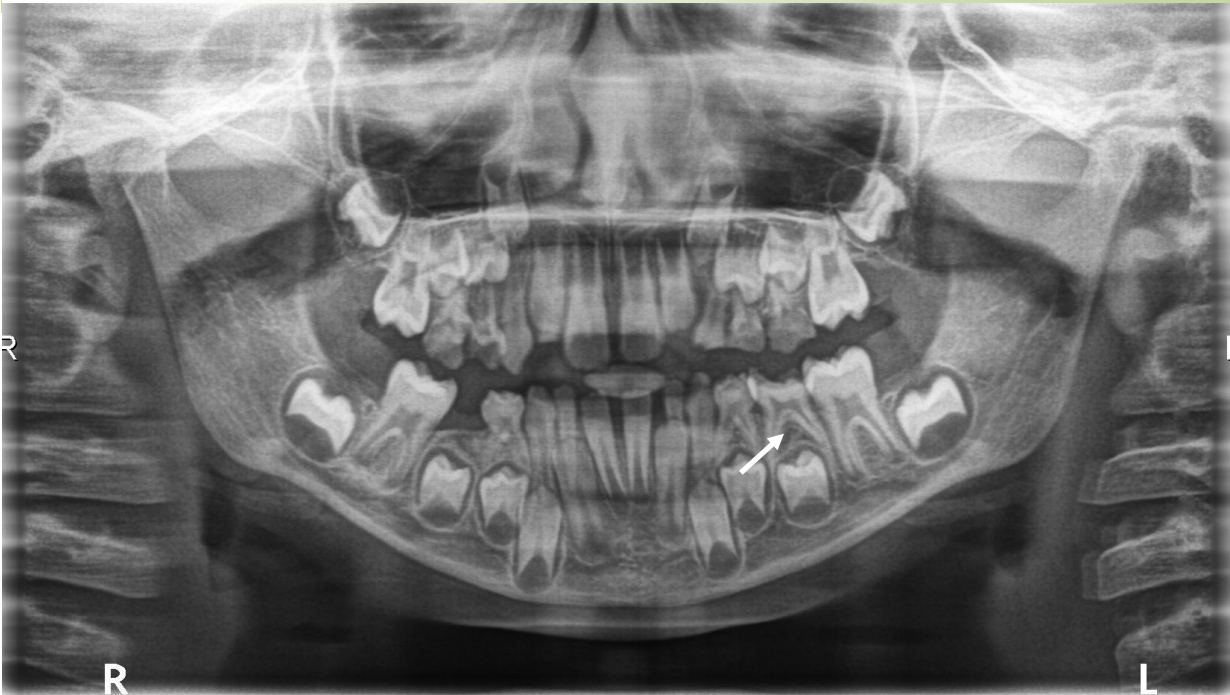### Commentary

Surgical and conservative treatment followed by prosthetic rehabilitation is suggested (suitable space maintainers - removable).

### Study stimulation

Suggest suitable prophylactic measures considering erupting permanent teeth above all the molars.

## Early childhood caries (ECC)



OPG. Age of the child: 7 years. Erupted both lower first permanent molars, upper first permanent molars erupting, central permanent incisors erupted both in the upper and lower jaw. Carious destruction of primary molars, their roots display different stages of resorption  
Interradicular radiolucency in teeth 54, 75, 74 (→), 85 extracted, 46 inclined mesially.

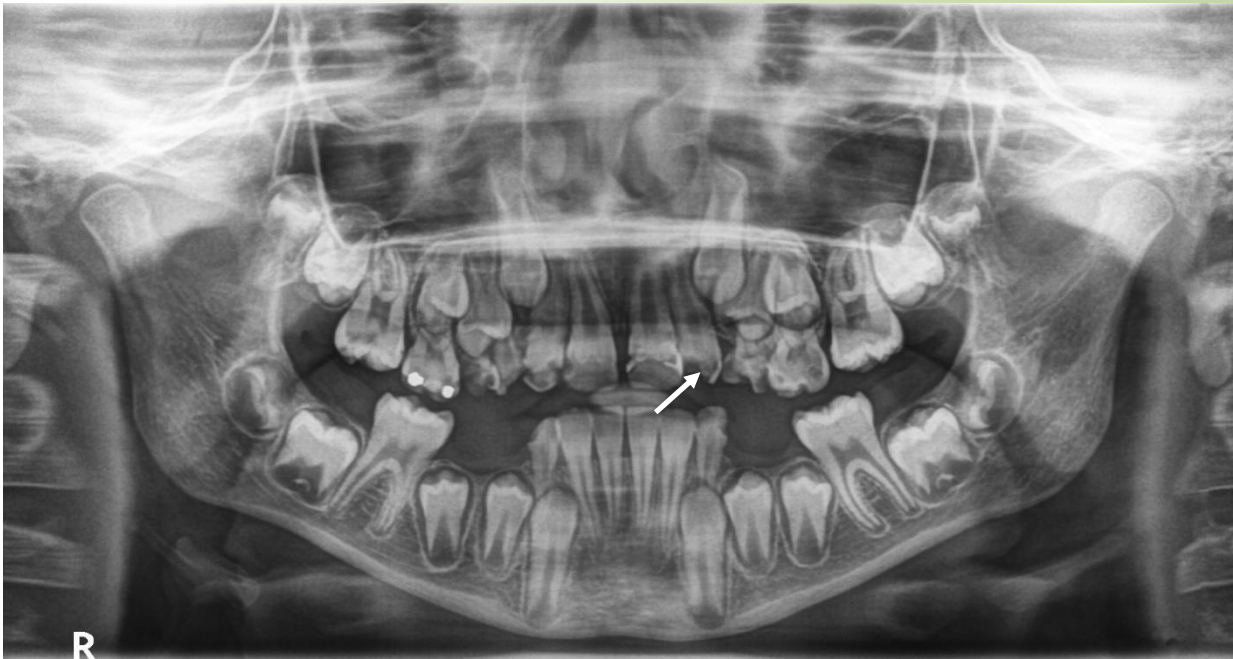
### Commentary

ECC is a dangerous state because of easy transfer of cariogenic microflora from primary to permanent dentition.

### Study motivation

Assess the caries risk for permanent dentition (transfer of microbes) and suggest appropriate measures to stop transfer of microbes and to prevent caries spreading. Suggest the suitable therapy of affected teeth.

## Premature loss of primary molars



OPG. Age of the child: 9 years. Mixed dentition. Carious destruction of all upper primary molars which are before elimination, 53 is destroyed by caries.

Lack of space for 23.

Fragment of 63, shift of 64 into the gap mesially.

Permanent incisors 12, 11, 21, 22 are affected by caries circularly.

22 caries reaching into the pulp proximity (→).

Primary molars in the lower jaw are extracted (missing).

Teeth 73 and 83 are caries affected (D4).

Lower primary molars were prematurely extracted, mesial shift of 46, 36 into the gap followed the extraction. Consequence of the situation will be lack of space for premolars in future. Crowding can be expected.

### Commentary

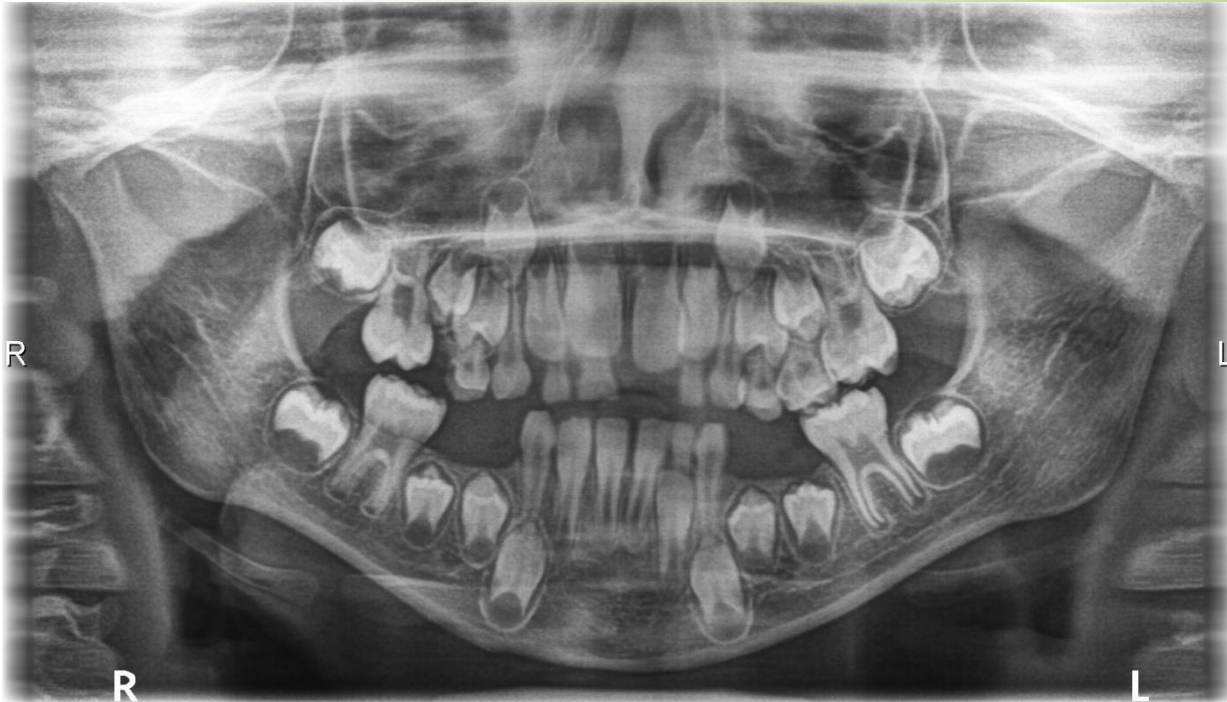Lack of space for premolars can develop not only because of premature extraction of primary molars but also because of loss of points of contact in molar region in case of approximal caries.

### Study motivation

Repeat time of permanent teeth eruption.



## Premature loss of primary molars

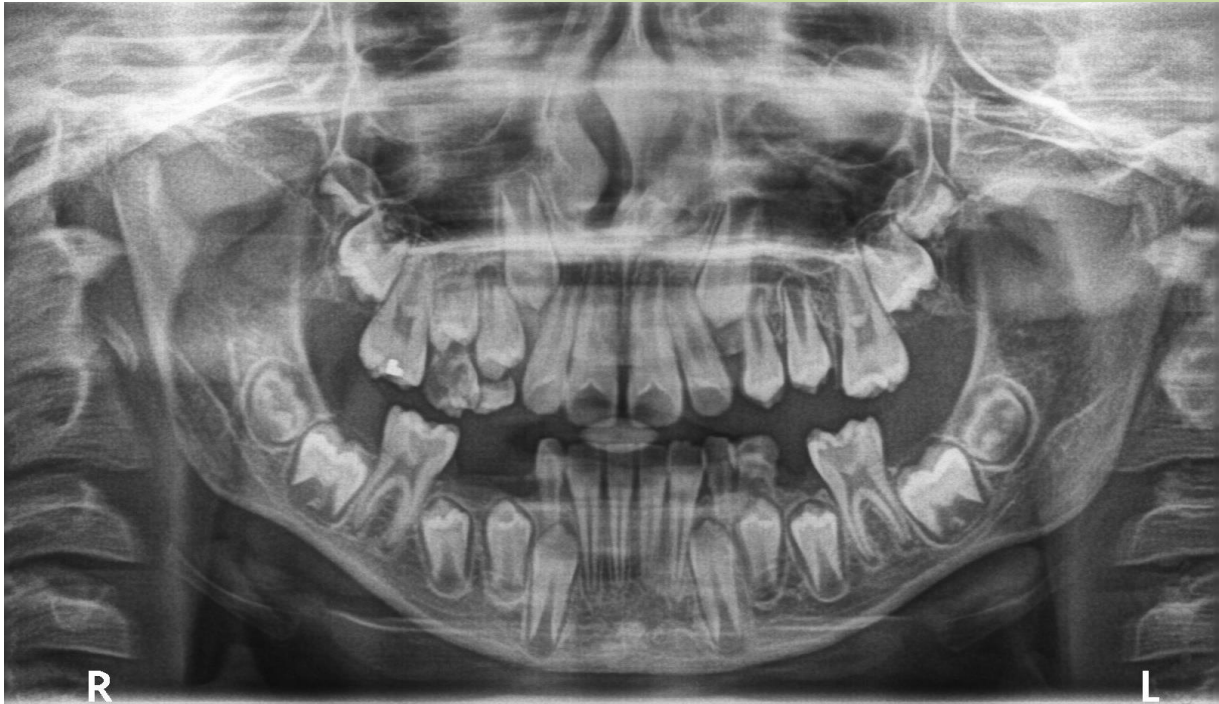

OPG. Age of the child: 8 years and 9 months. Mixed dentition, persisting primary molars severely destroyed, 55, 85, 84, 74, 75 extracted prematurely. Loss of space for premolars and mesial shift of molars is obvious.

### Study motivation

Repeat time of permanent teeth eruption.

## Premature loss of primary molars



OPG. Age of the child: 9 years. Mixed dentition. Remaining primary teeth are caries affected as well as all first permanent molars.

16 car. sec.

26 car. media (D3),

36 car. pulpa prox. (D4)

46 car. ad pulpam penetrants. Crowding in permanent dentition can be expected.

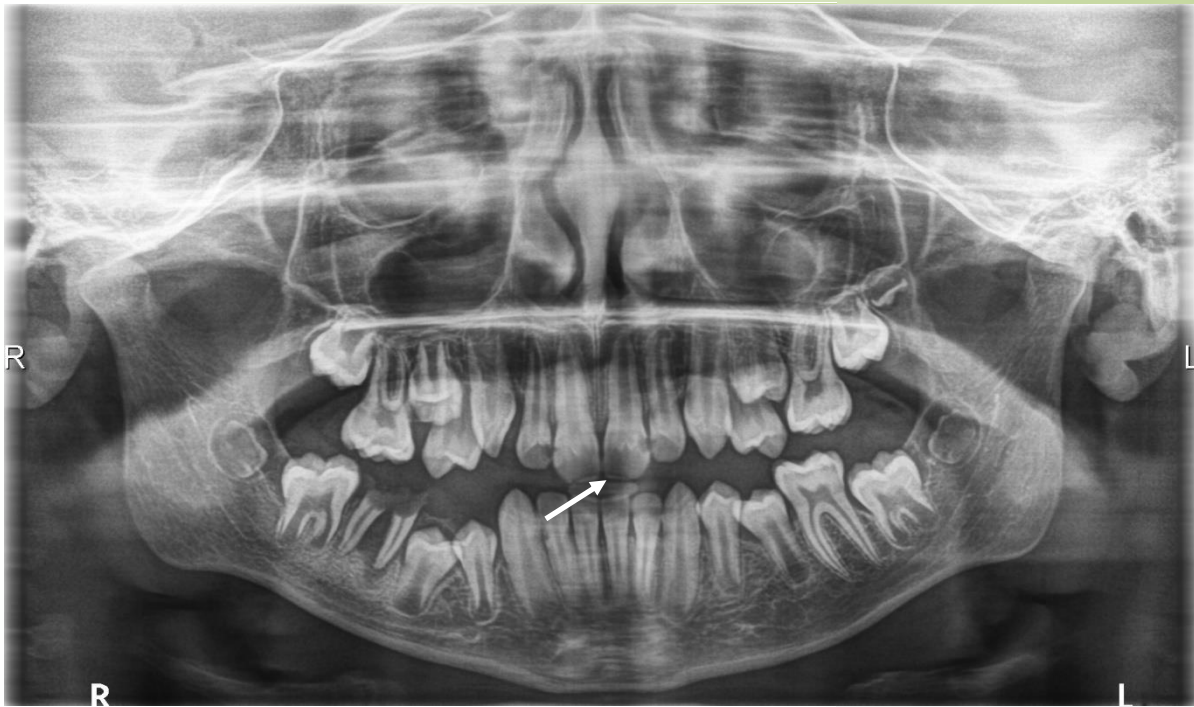### Commentary

All first permanent molars incline mesially.

### Study stimulation

Assess the state of dentition and suggest the possibilities of treatment.

## Premature loss of primary molars

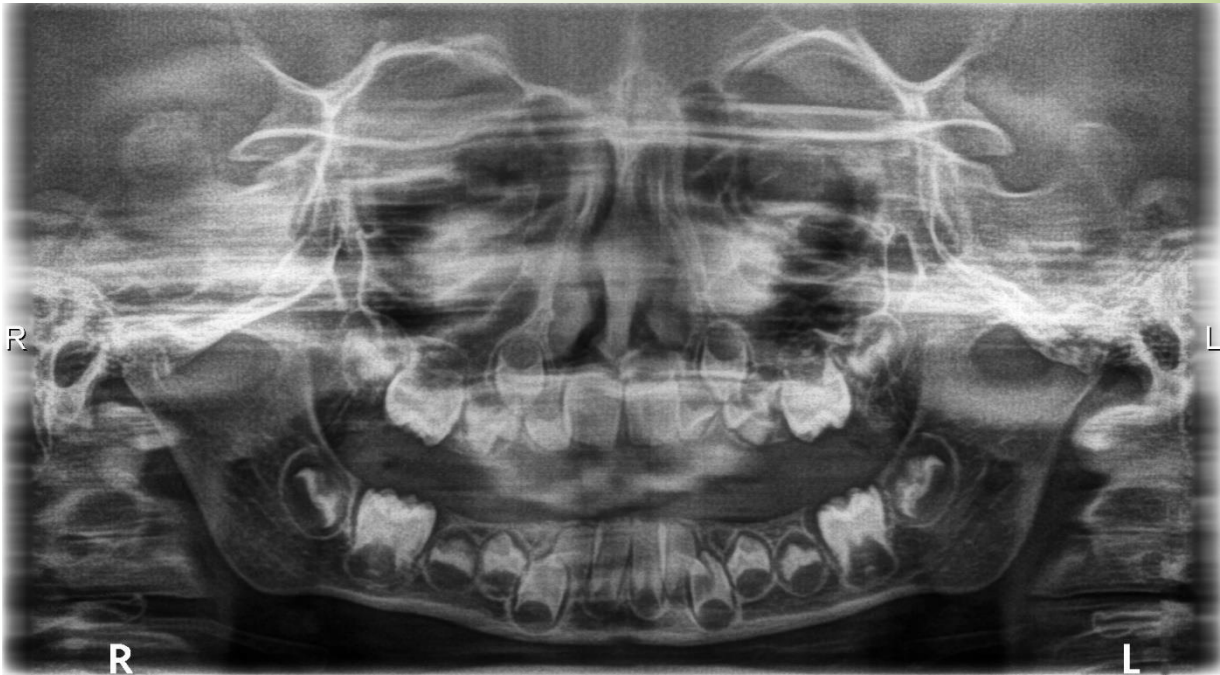


OPG. Age of the child: 10 years. Permanent dentition with premature loss of primary molars, consequence of ECC.  
Fragment of 85 in 45 area.  
Caries in upper incisors (→).  
Crowding in premolar area in all quadrants.  
Cariou destruction of 46 crown.  
Root separation by caries process in 46.  
Interradicular and periapical radiolucency in 46, susp. apical periodontitis/ostitis.

### Commentary

Lack of space for 15, 25, 35, 45, ectopic eruption or tooth retention can be expected.

## Premature loss of primary molars



OPG. Age of the child: 5 years. Extreme situation, no primary tooth is preserved (all teeth are missing) all primary teeth had to be extracted because of extreme carious destruction. Buds of all permanent teeth can be seen on OPG, except for the third molars, which cannot be, at this age, visible yet.

### Commentary

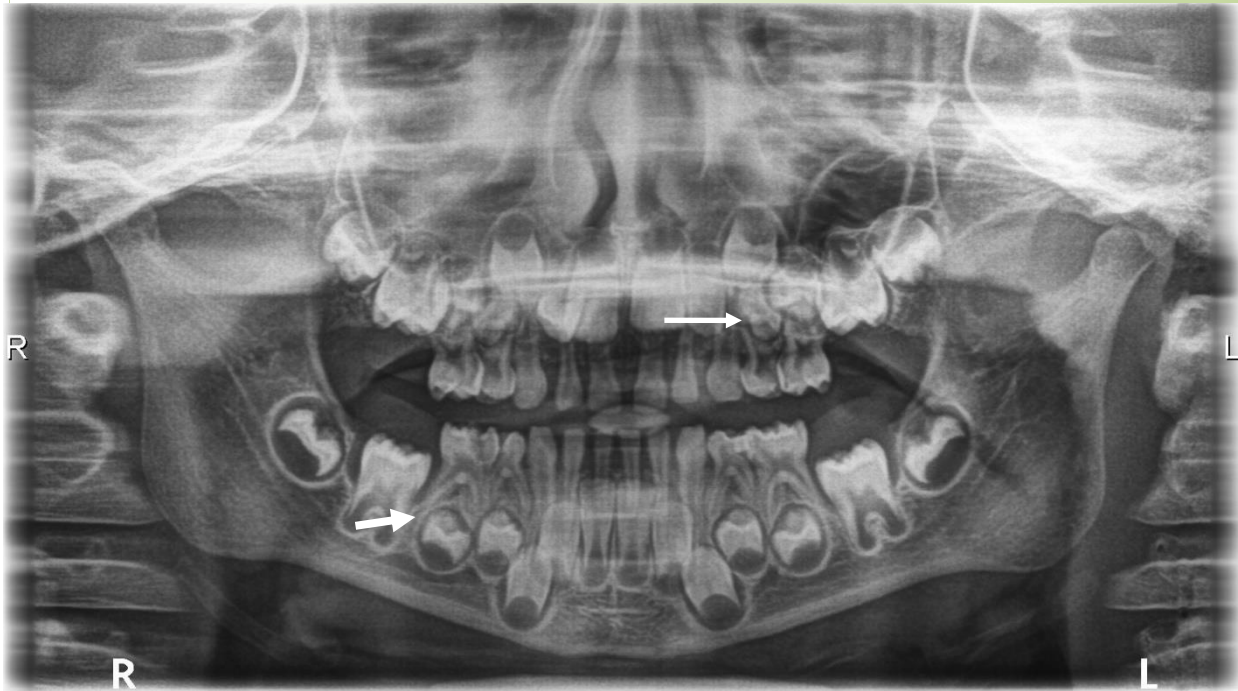
Removable space maintainers in the upper and lower jaws are indicated.

### Study motivation

Assess state of development of individual permanent teeth (7 stages). Describe step by step procedures which are performed both in surgery and laboratory when making the removable space maintainer



## Course of root resorption in primary molars



OPG. Age of the child: 5 and half a year. Caries affected primary dentition (ECC). Stage of root resorption in primary frontal teeth in upper and lower jaw cannot be distinctly determined because of teeth overlapping and radioopacity in frontal region (summation effect in OPG technique).

Stage of root resorption can be determined in upper molars. Cusps of premolars are in close vicinity to trifurcation of all primary molars (→). Root resorption of lower molars is also in progress, buds of premolars resorb not only the apical part of the root but also the root surface from the interradicular space (→).

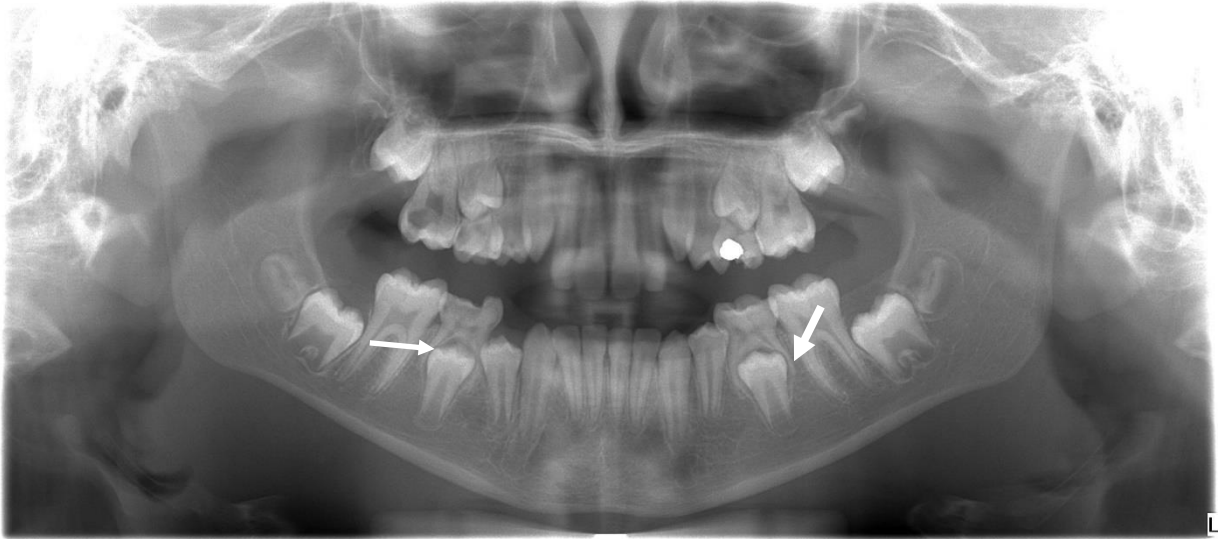### Commentary

Assessment of root resorption in primary teeth is important for treatment planning and suitable therapy. Evaluate the relationship between roots of primary teeth and crowns (peri coronal sac) of permanent teeth.

### Study motivation

Determine the suitable therapy in the following diagnosis: 85, 84 chronic periodontitis, 74 ostitis, 75 chronic ulcerous pulpitis.

## Course of root resorption in primary molars



OPG. Age of the child: 10 years. Mixed dentition. Teeth 55, 65 before shedding.

Roots of the 85 (→) and 75 (→) display almost intact length on the x-ray, however, their resorption is very progressed on the surface turned into the interradicular space. Roots are extremely thinned, and their resorption is reaching into the dental pulp cavity.

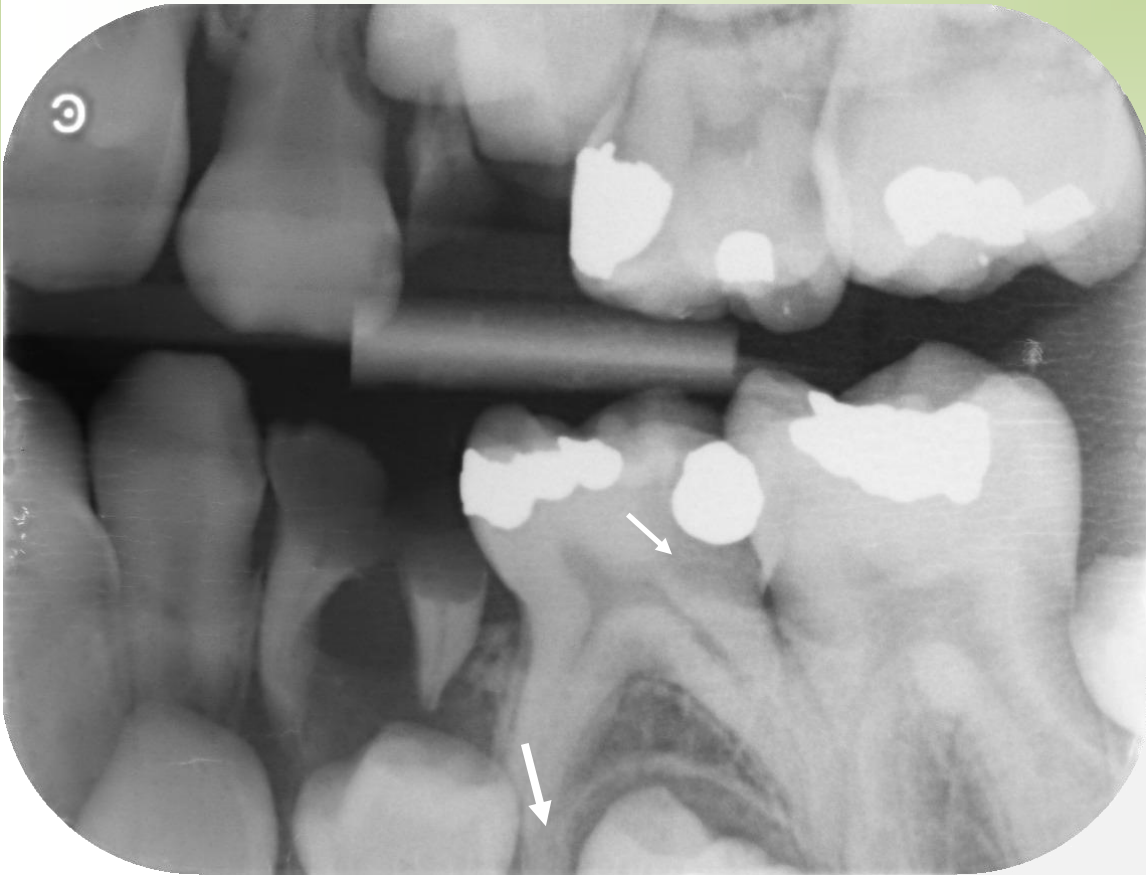
### Commentary

Primary molars should be preserved if possible, to maintain the sufficient space for premolars. Notice the relationship between roots of primary molars and crowns (pericoronal sac) of permanent teeth.

### Study motivation

Suggest suitable endodontic treatment in case of following diagnosis. 85 partial pulpitis, 75 dental pulp hyperaemia in case of dental pulp exposure in decayed dentine area.

## Course of root resorption in primary molars



B-W projection. Age of the child: 9 years. Mixed dentition. Radiolucency in dentine 75 distally, under the filling, reaching into the dental pulp vicinity (→). Bud of 35 in proximity of 75 bifurcation, beginning of root resorption can be seen mesially (→). Tooth 74 destroyed by caries, pronounced radiolucency in root area, susp. ostitis.

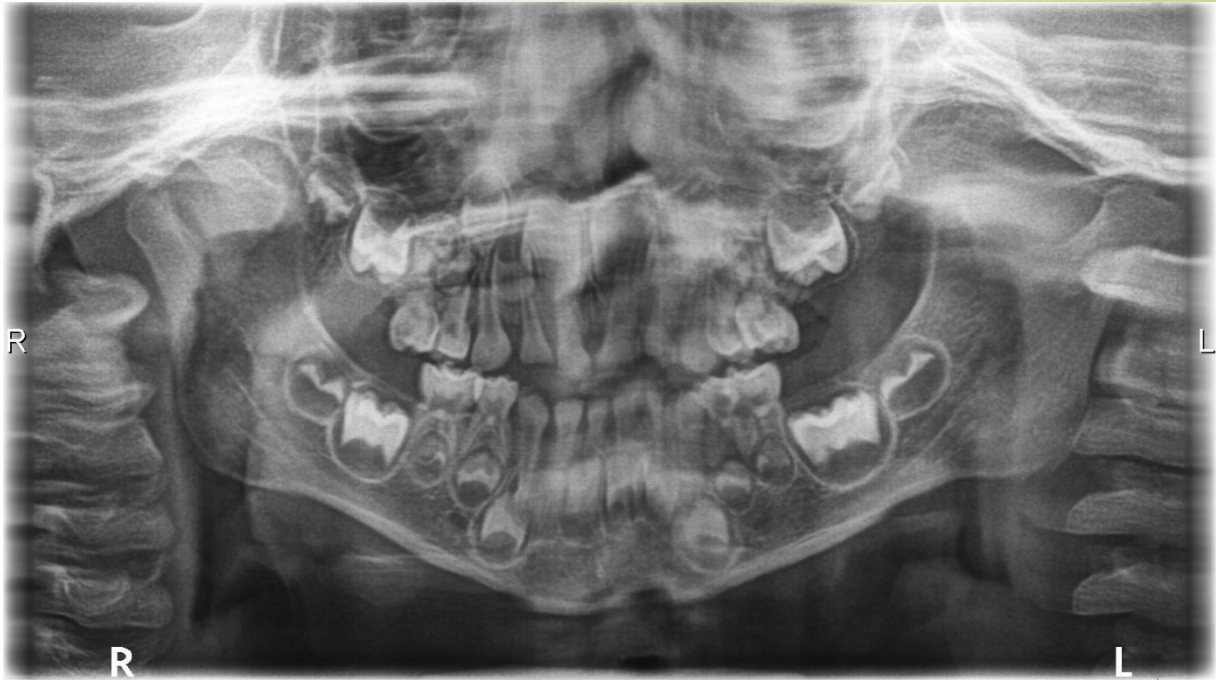### Commentary

Would you indicate extraction of 74? If yes, why?

### Study stimulation

Suggest the therapy suitable for 75 and explain how to maintain the space after extraction of 74.

## Course of root resorption in primary molars



OPG. Age of the child: 4 years. Primary dentition. Roots of primary teeth are in the rest stage at this age. The teeth finished their development and resorption has not started yet. Buds of permanent teeth are at a distance so that they cannot participate on the resorption yet. Situation in the upper jaw is, however, indistinct because of teeth overlapping.

### Commentary

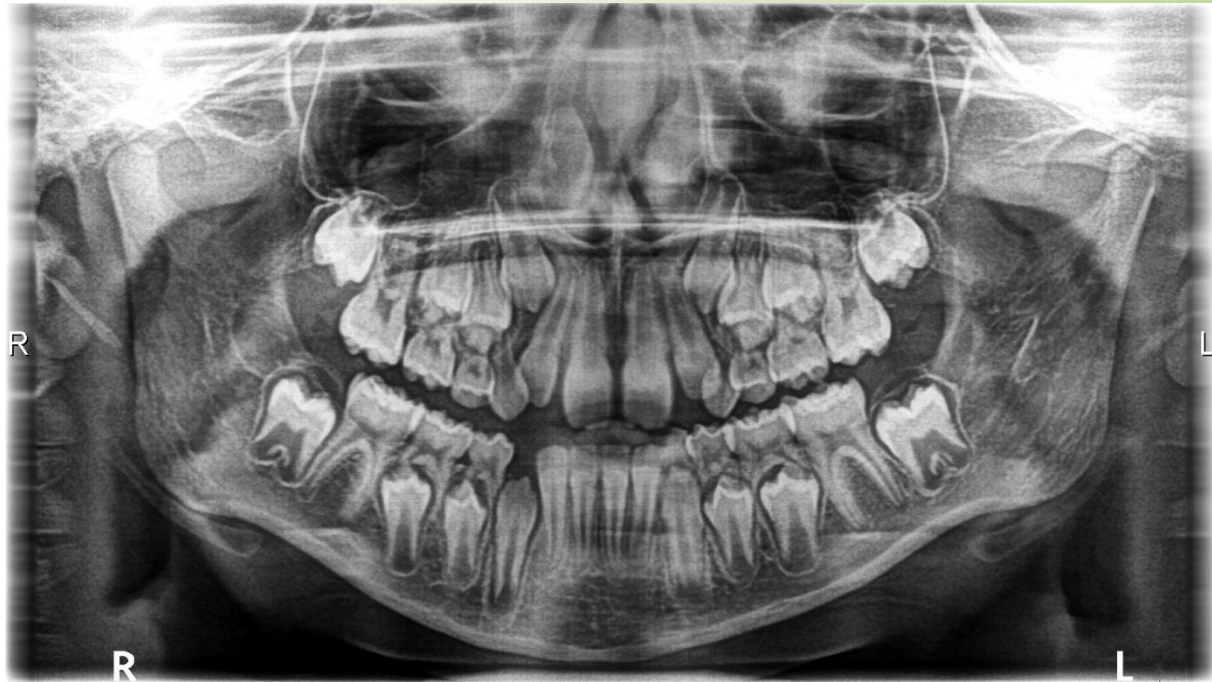Cariou, untreated primary dentition. Assess the relation between roots of primary molars and crowns of premolars (pericoronal sac).

### Study stimulation

Suggest suitable filling therapy, possible endodontic treatment of 85, 84 in following diagnosis: partial pulpitis, total pulpitis, dental pulp necrosis.



## Course of root resorption in primary molars



OPG. Age of the child: 9 years. Mixed dentition. Primary teeth shortly before shedding, intact, roots of primary teeth are under progressed resorption. Notice the relationship between roots of primary teeth and buds of permanent teeth (pericoronal sac).

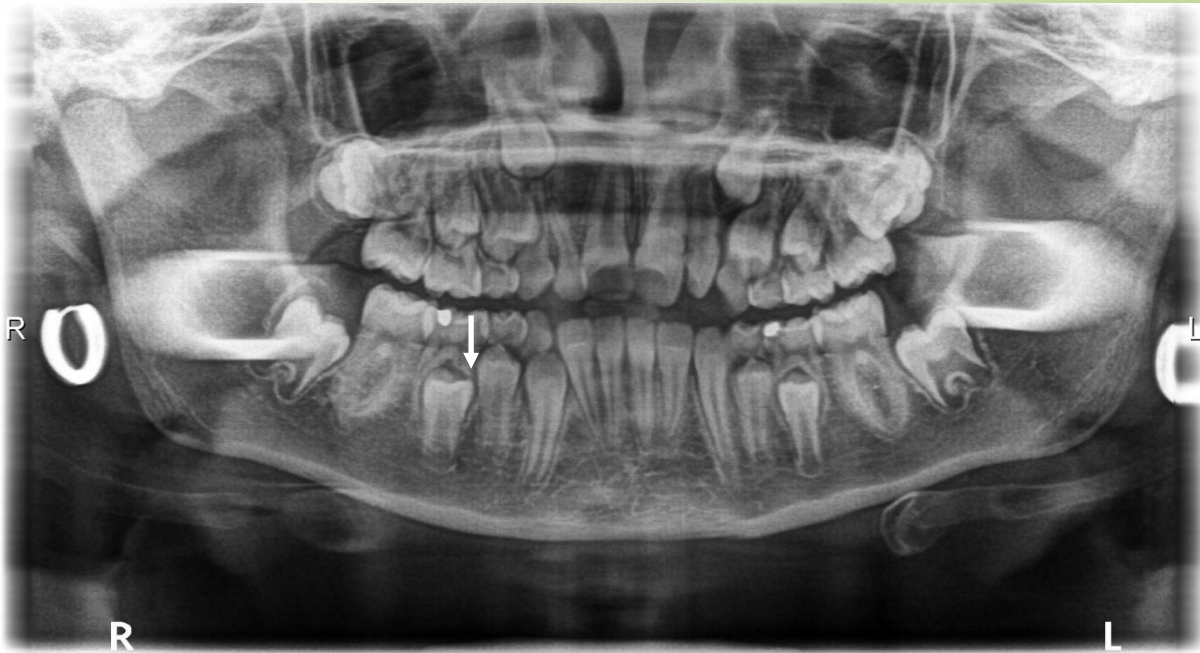### Commentary

Diastema between 11, 21, lack of space for 13, 23 can be expected.

### Study motivation

Suggest suitable therapy in case of resorptive pulpitis in 84. Can it be expected in this case?

## Course of root resorption in primary molars



OPG. Age of the child: 10 years. Mixed, treated dentition.

75 susp.car. sec.

Primary molars in a different stage of root resorption shortly before shedding, except for 53. Lack of space for the permanent tooth in the area 23.

Roots of 85 and 75 are long, resorption is in progress from the interradicular space. Their continuity is almost interrupted by resorption (→).

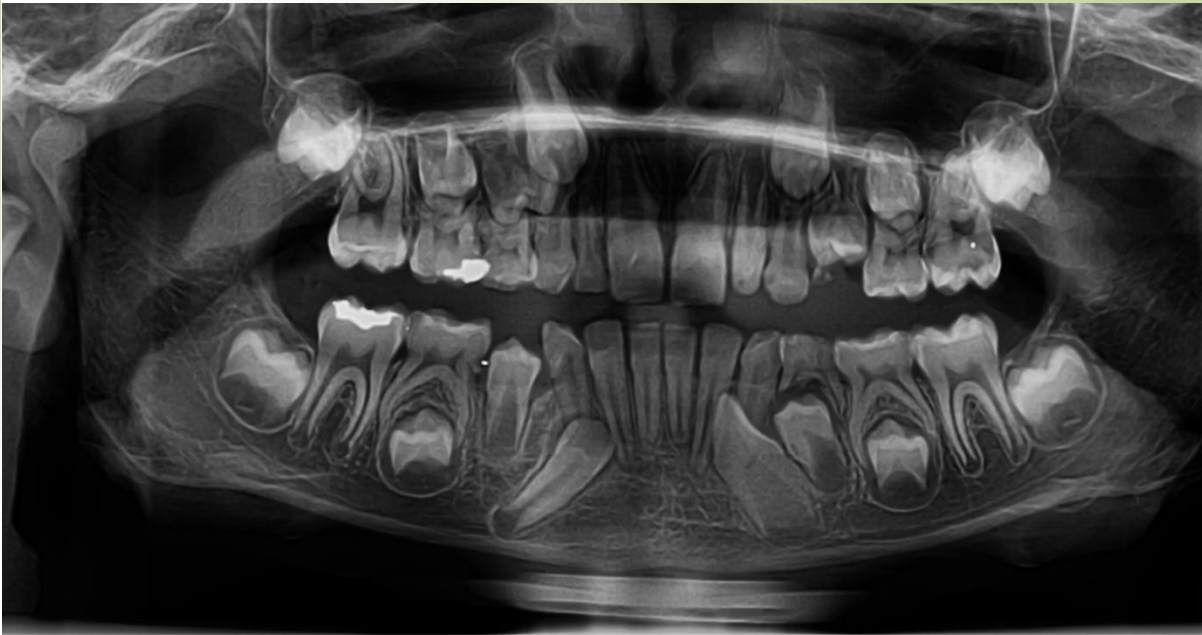### Commentary

Radiopaque strands stretching towards 47, 37 are artefacts due to the wrong x-ray technique – earrings were not removed on taking x-ray.

### Study stimulation

Suggest suitable therapy for secondary caries – car. pulp. proxima affecting 75 including possible complications.

## Course of root resorption in primary molars



### Age of the child: 8 years

---

OPG.

Mixed dentition.

**Root resorption:**

Beginning root resorption in the apical part of 85, bud of 45 is approaching to the interradicular space of 85.

Similar situation in the apical part of 75.

**Permanent dentition, root development:**

1. stage of root development can be observed on the teeth: 22 and 44,
2. stage of root development: 46, 36,
3. stage of root development: beginning 21, more advanced 32, 42, 31, root is slowly closed 41.

### Commentary

---

The presented patient will be followed during resorption of roots of 85, 75 and during eruption of permanent teeth including classification of root developmental stages in developing permanent dentition.

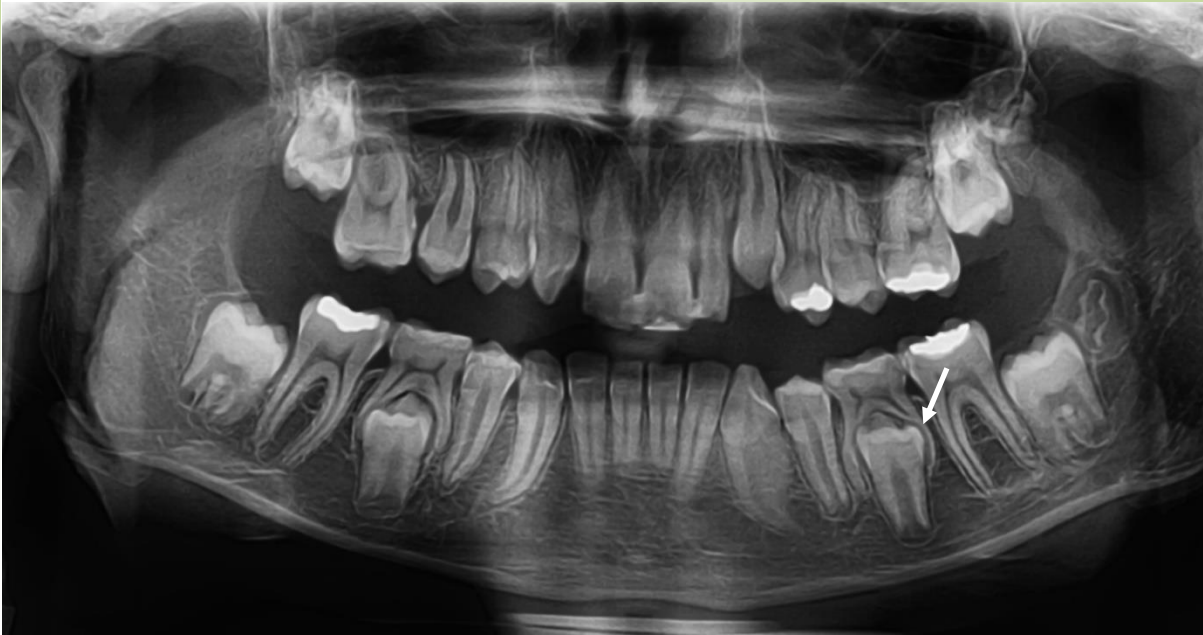### Study stimulation

---

Repeat the characteristics of teeth with developing roots (open apices).

Assess stage of root resorption in 85, 65, 74.

## Course of root resorption in primary molars



### Age of the child: 9 years

OPG.

#### **Root resorption** in primary teeth:

All primary teeth in the upper jaw have already been replaced by permanent teeth.

In the lower jaw the root resorption of 85, 75 is in progress, crowns of premolars occupy the whole interradicular space, their cusps are approaching to bifurcation. Marked resorption of root walls turned towards to buds of premolars (→), noticeable attenuation of the root wall, resorption is opening the dental pulp cavity. The length of roots seems to remain unchanged.

#### **Permanent teeth:**

2. developmental stage: 15, 23, 34.

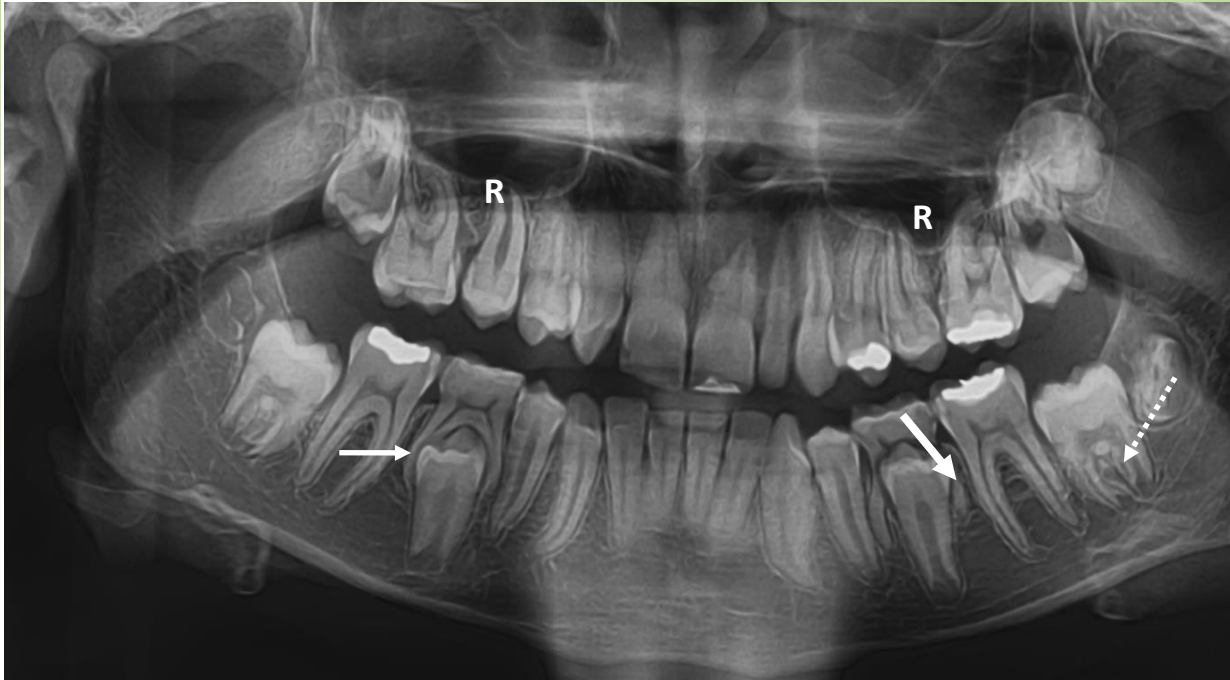
3. developmental stage: 36, 44, 46.

### Commentary

Developmental stages are mentioned only in quite distinct and representative cases.



## Course of root resorption in primary molars



### Age of the child: 10 years

OPG.

**Root resorption:** 85 in comparison with the previous x-ray the situation has not progressed and remains unchanged. Penetration into the root canal is obvious (→), the root length remains the same, roots embrace the crown of the 45.

Resorption of 75 advanced substantially, the tooth is before elimination, roots, even though practically separated, persist in the bud neighbourhood (→).

#### Permanent teeth:

1. stage of development 37 (\*\*\*→),
  3. stage of development 15 (between 2-3), 23, 25, 34, .
- First permanent molars finished the root development.

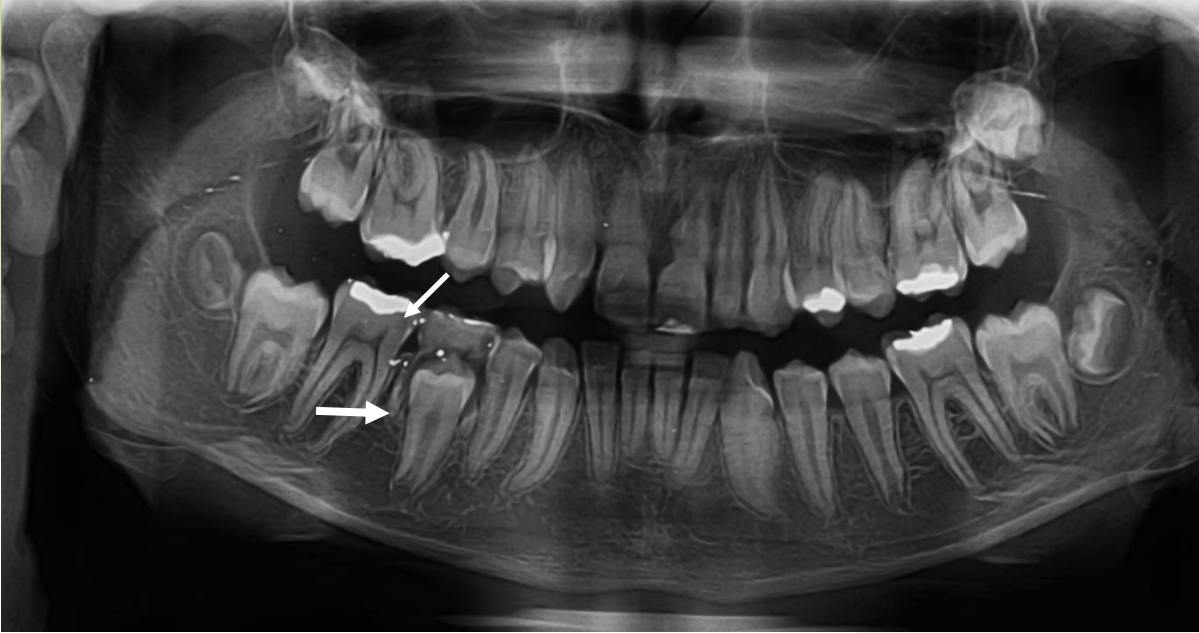
### Commentary

Bilaterally well-developed recessus of maxillary sinus (R).

### Study stimulation

Assess the relation between maxillary sinus and roots of permanent teeth. Determine to which of them.

## Course of root resorption in primary molars



### Age of the child: 12 years

OPG.

**Resorption of roots:** 85 in the terminal stage, the tooth before elimination. Both roots, however, persist in the apical/middle part (→).

Permanent teeth:

2. stage of development: 37, 35, 47 (between 1. - 2.),

3. stage of development: 15, 25, 34. Remaining permanent teeth finished the root development.

All 3. molars (buds) are present.

### Commentary

Caries affecting the 46 (→) - radiolucency, as well as on the 85.

### Study stimulation

Trace at which age the caries could be diagnosed and suggest the suitable therapy at those time. Which therapy will be suitable at the present time?

Determine the cause of caries development on the mesial surface of 46. Identify remaining carious lesions and suggest their therapy. Find out the anomaly present in this case.

# Evaluation of root developmental stage

On treatment the teeth with not fully developed roots, mainly in permanent dentition, the assessment of the stage of root development is decisive in the choice of the suitable therapy. Seven developmental stages can be recognised, for the clinical treatment, however, only last four stages of them are of clinical importance. We can distinguish stages: 1, 2, 3 and 4.

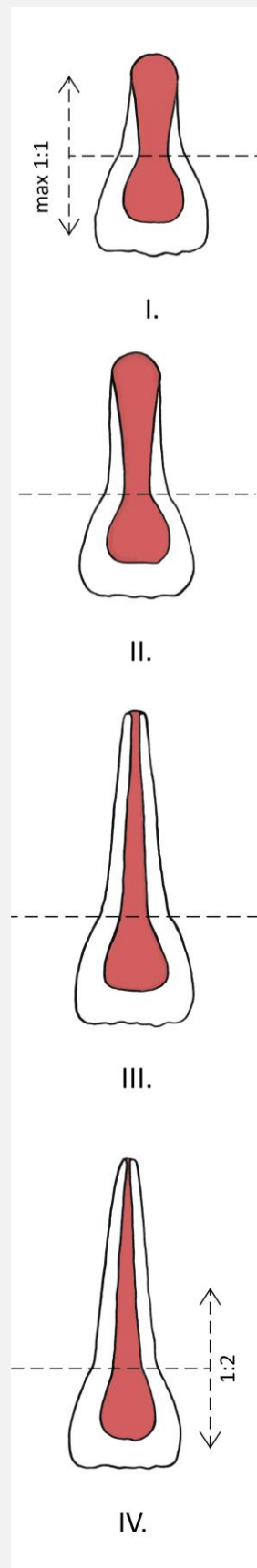
## Stages of root development - characteristics

**I. stage of development:** the root is shorter than the crown, maximally of the same length (1:1). Dentine layer is very thin, dental pulp cavity is large, dentinal walls are divergent apically and the foramen apical is very large (open apex) – shape of the mesenchymal papilla..

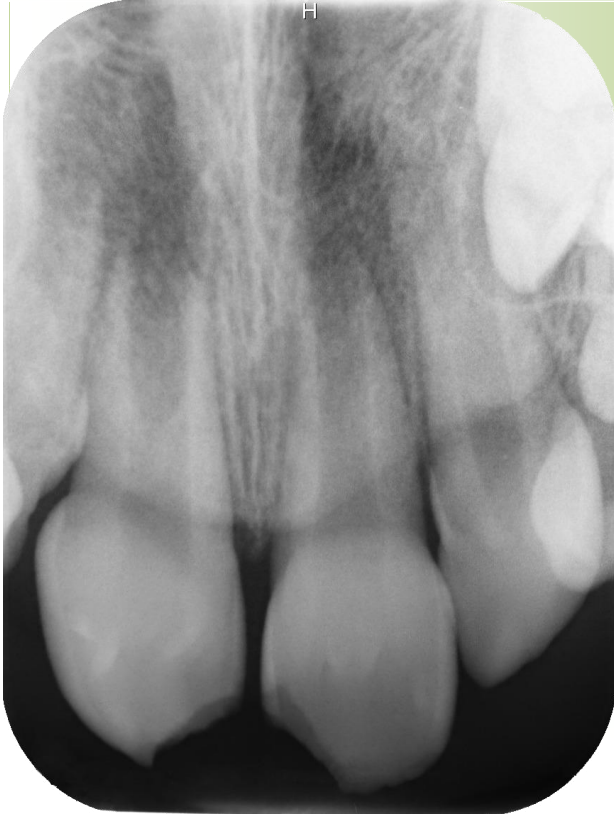**II. stage of development:** the root is longer than the crown, dental pulp is large, dentinal walls of the root are divergent apically, foramen apical is large (open), dentine layer is very thin

**III. stage of development:** the root reached almost its expected length, dentine is thicker than in previous stages, dentinal walls are parallel in the apical part, dentine layer is thin, dental pulp cavity is large, the pulpal horns are high.

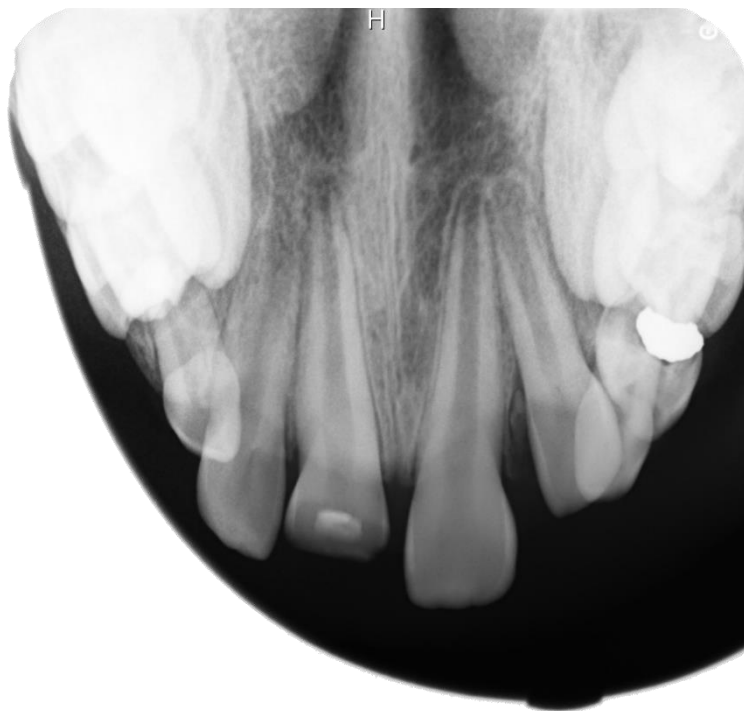
**IV. stage of development:** the root has reached the expected length (2:1), foramen apical is closed (physiological constriction), dentine is thicker, but the dental pulp cavity remains large, the horns remain high.



## Evaluation of root developmental stage



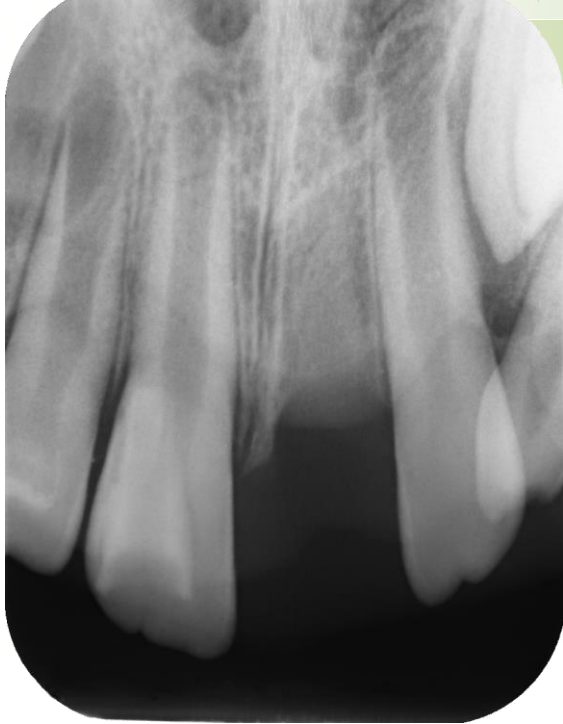Tooth 11, end of the 1. developmental stage.  
Tooth 21 beginning of the 2. developmental stage.



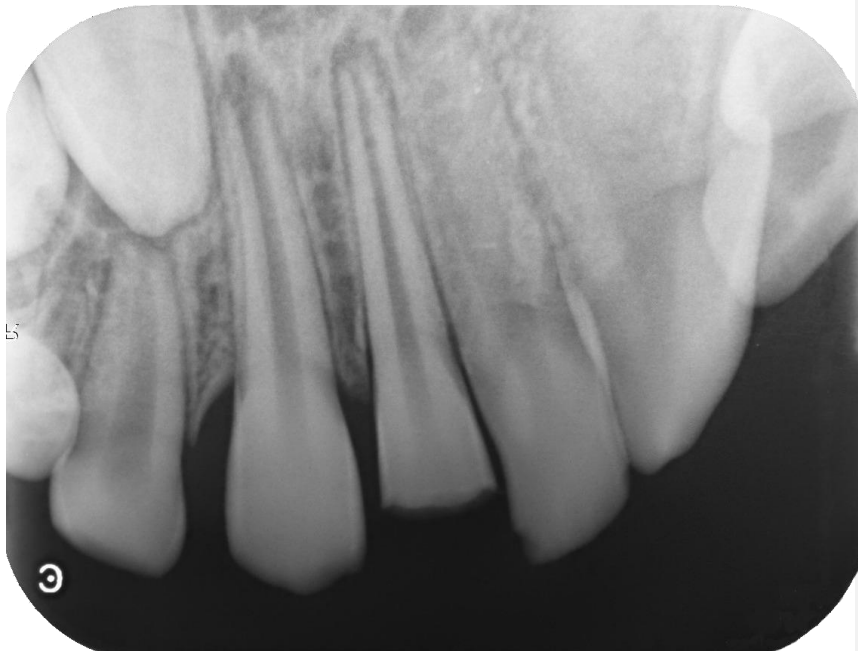
All four upper incisors are in the 2. developmental stage  
Teeth 11 and 12 are in more advanced phase than 21 and 22



## Evaluation of root developmental stage

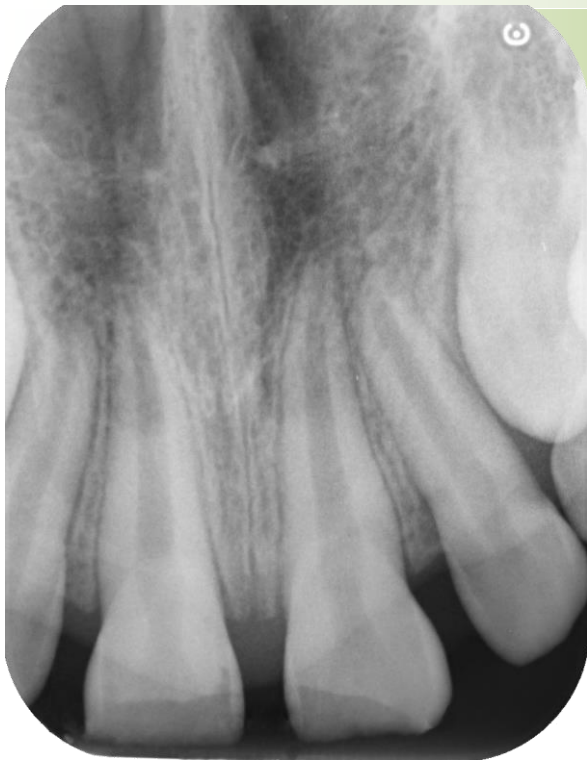

Tooth 12 is in the 1. developmental stage.  
11 and 22 are in the 2. developmental stage, but they differ slightly in the length of the root in thickness of dentine and size of the apical papilla.  
Tooth 21 is missing because of avulsion.

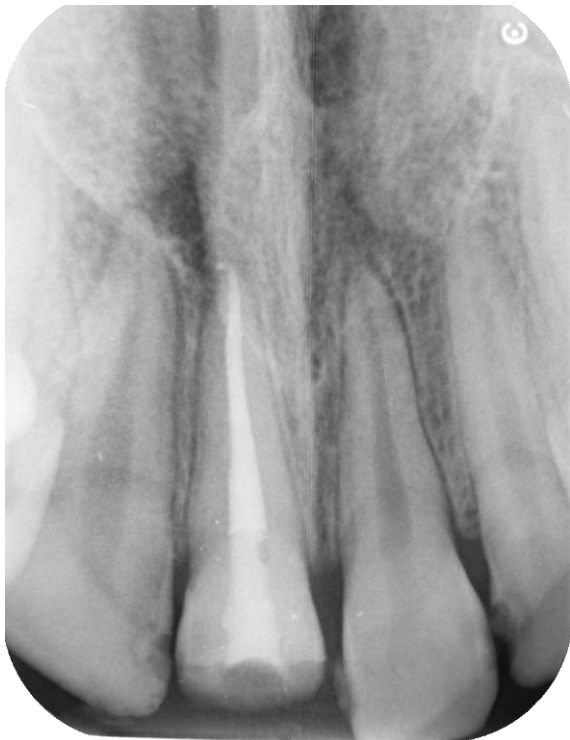

Tooth 11 in the 3. developmental stage (crown fracture).  
Tooth 12 is in the 2. developmental stage. Periapical radiolucency and periodontal space enlargement in the region 12 and 11 is a consequence of vitality loss after the injury and arising apical periodontitis.

## Evaluation of root developmental stage

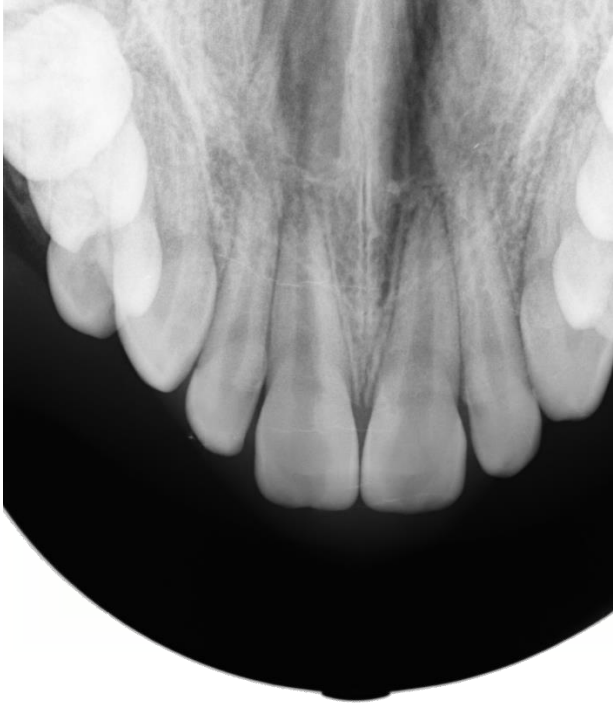


Central incisors (11 a 21) are in the 3. developmental stage, 12 in the 2. stage, 22 inclines palatally, stage of the development cannot be precisely determined.

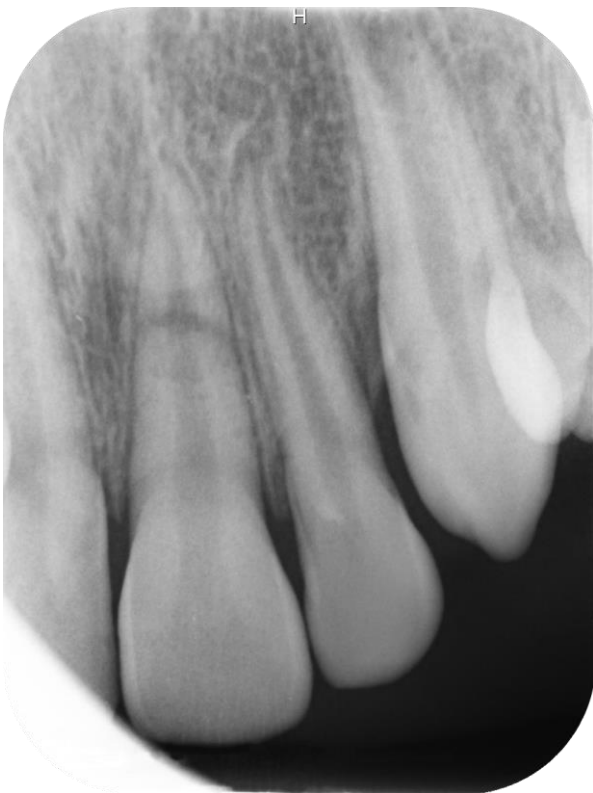

All four permanent incisors are in the 4. developmental stage, 11 is filled to the apex of the root.

## Evaluation of root developmental stage



Teeth 11 and 21 are almost in the 4. developmental stage, even though apical foramen does not display distinct wall convergency.

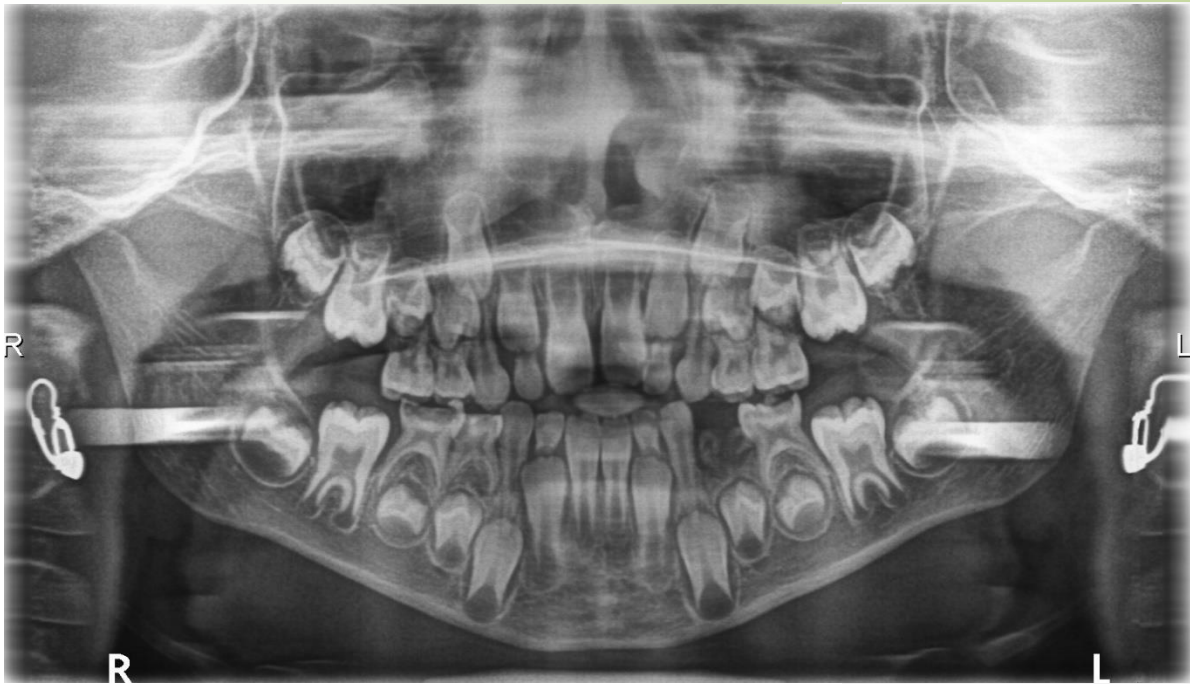


21 in the 4. developmental stage, 22 almost in the 3. stage.

### Commentary

Transverse fracture of the root with mild fragment dislocation.

## Evaluation of root developmental stage



OPG. Age of the child: 8 years.

1. developmental stage: 11, 21, 36, 31, 41, 46

### Commentary

---

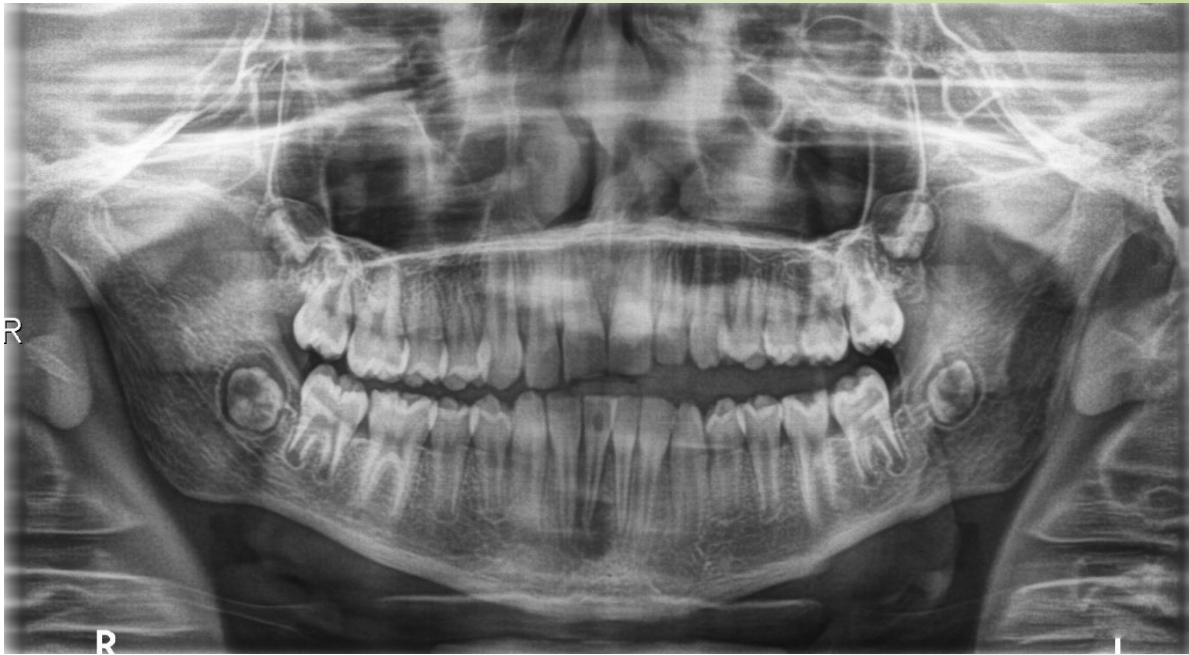Strongly radiopaque strands are artefacts – shades of earrings.

### Study motivation

---

Assess dmft index.  
Determine type of dental caries as to its depth in the dentine and determine the teeth with inflammatory changes of periodontium – radiolucency in the interradicular space.

## Evaluation of root developmental stage



OPG. Age of the child: 10 and half a year.

1. developmental stage: 47, 37
2. developmental stage: 13, 23, 45, 44, 33, 34, 35, may be also: 43, x-ray is not quite distinct in the area.
3. developmental stage: 22, 42, 32
4. developmental stage: 41, 31

### Commentary

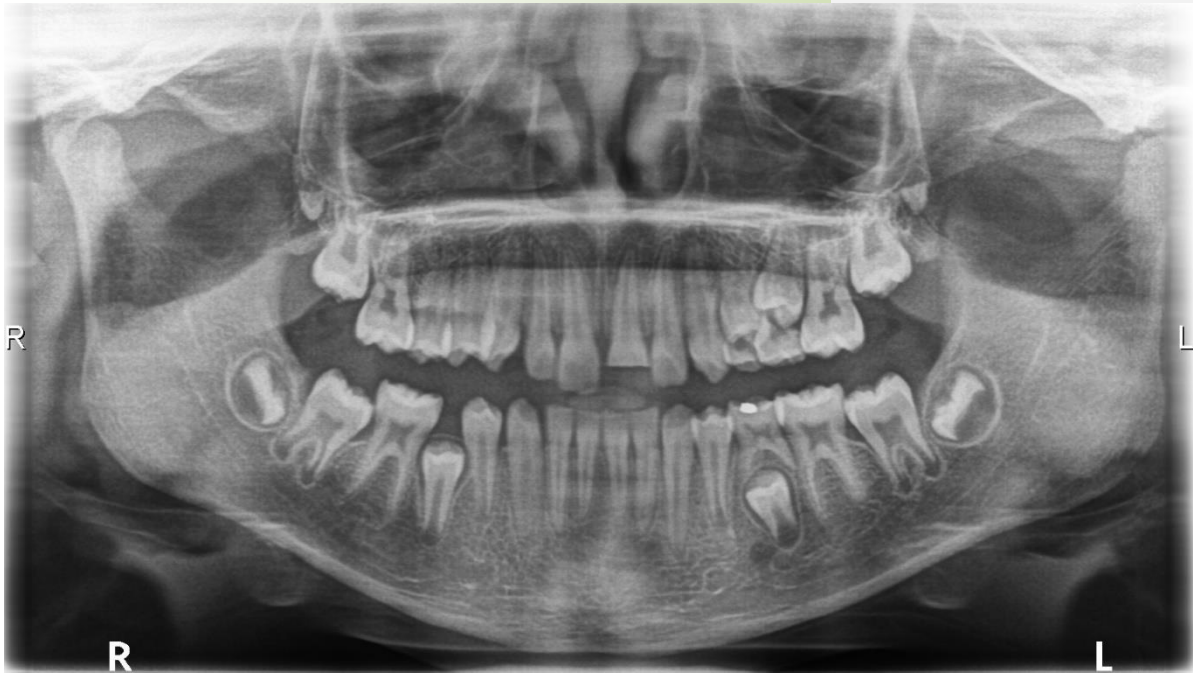Determination of developmental stages in teeth of the upper jaw is difficult because of summation effect.

### Study stimulation

Compare radiolucency in the periapical region and its character in teeth: 41 versus 31 and versus 47, 37. Describe the differences and state the diagnosis in the case of 41.



## Evaluation of root developmental stage



OPG. Age of the child: 10 years.

1. developmental stage: 47, 37
2. developmental stage: 44, 34
3. developmental stage: 33
4. developmental stage: 42, 32

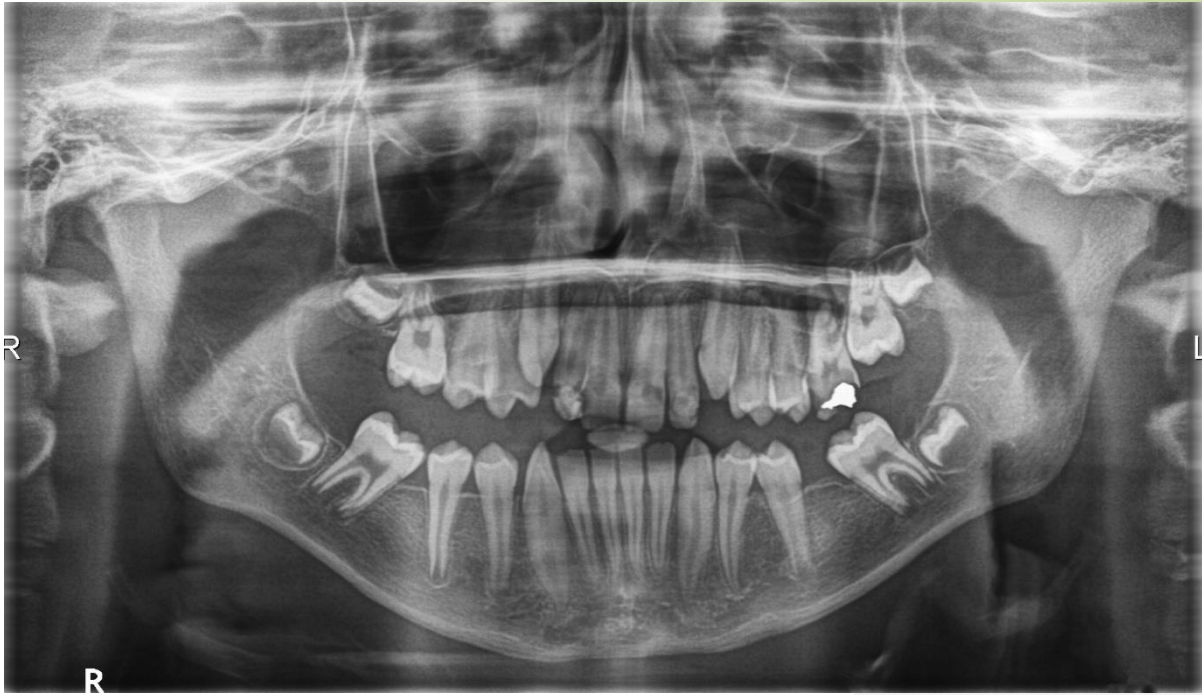### Commentary

Determination of developmental stages in teeth of the upper jaw is difficult because of summation effect. (subtraction effect).

### Study stimulation

Determine pathological process in the periapical periodontium and adjacent bone of the tooth.

## Evaluation of root developmental stage



OPG. Age of the child: 13 years.

Developmental stages in the upper jaw cannot be determined on the OPG because of summation effect.

1. developmental stage: 37 (on the borderline).
2. developmental stage: 45, 35
3. developmental stage: 44
4. developmental stage: 42, 41, 31, 32

### Commentary

---

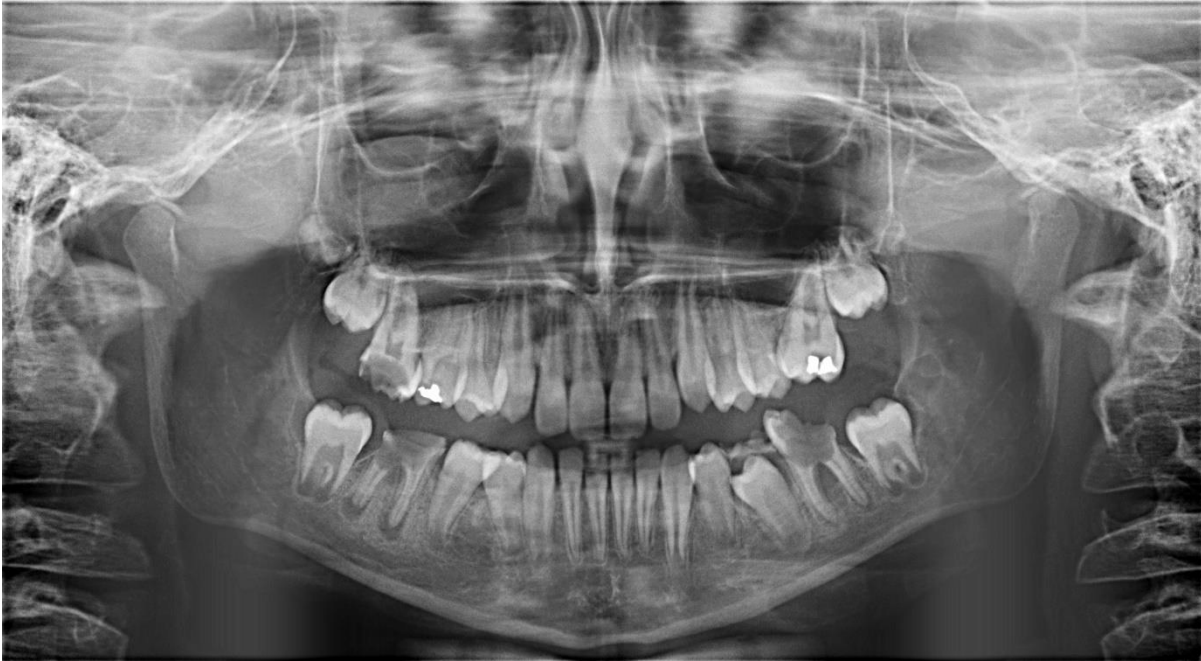All buds of third permanent molars are present.

### Study stimulation

---

Assess the diagnosis of 26 and suggest suitable therapy.

## Evaluation of root developmental stage



OPG. Age of the child: 11 years.

Developmental stages in the upper jaw cannot be exactly determined.

1. developmental stage: 47, 37
2. developmental stage: 45, 44, 43, 33, 34,
3. developmental stage: 46, 36
4. developmental stage: 42, 41, 31, 32

### Commentary

Duration of the second developmental stage is quite long; root is growing into the length gradually. That is why the signs of the developmental stage are different, especially the length of the root, but also the other criteria.

### Study stimulation

Compare periapical radiolucency in teeth 47 versus 46, and 37 versus 36. Describe differences and state the diagnosis and suggest suitable therapy. Also suggest the therapy in the molar region in the upper jaw.