



PD

PEDIATRIC DENTISTRY

**FILLING THERAPY IN PRIMARY DENTITION
PRACTICAL TRAINING**

OBJECTIVE

After termination of the practical training the students will be familiar with theoretical basis and practical skills necessary for the treatment of primary dentition by fillings.

TARGET GROUP

Students of the 5th year, Dentistry.
aZLDL0922c

PRACTICE

Vacational practice assigned to the 4th year of Dentistry is required.

KNOWLEDGE

Knowledge necessary for the enrolment of the subject is given in corresponding prerequisites.

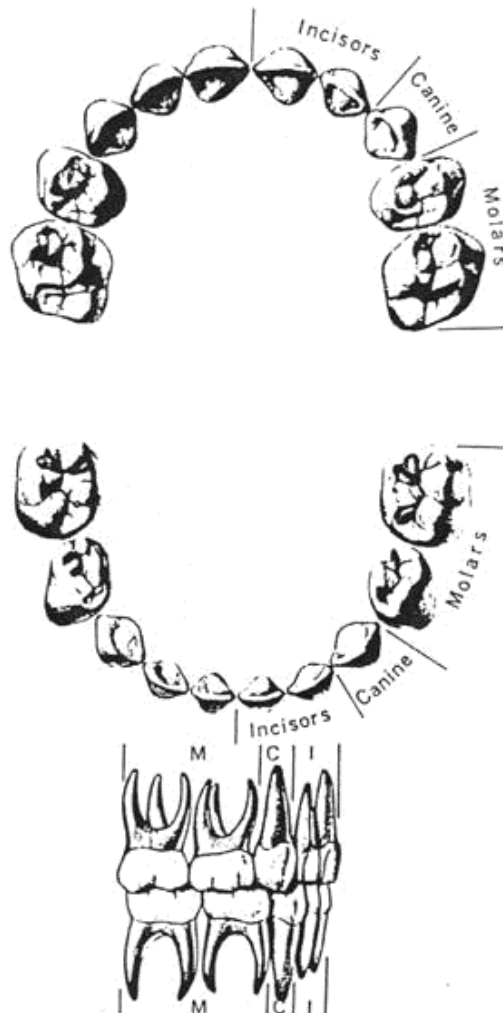
OUTCOMES

Students are familiar with working procedures essential for the treatment of the primary dentition with fillings and are able to treat children in the clinical part of the subject: Paediatric dentistry.

COMMENTARY

Remember – the primary teeth differ from the permanent in number, shape, size, structure and in the color.


PRIMARY DENTITION




COMMENTARY

Filling therapy is indicated in D3-
reaching deeper in the dentine and
in D4 (cariea pulp. proxima)


DIAGRAMMATIC REPRESENTATIONS OF CARIES DIAGNOSTICS ON BITE-WING RADIOGRAPHS




Sound on bitewing



Radiolucency confined to enamel
(up to 1/2- caries incipiens)



Radiolucency in the enamel up
to the enamel-dentine junction
(caries superficialis)



Radiolucency in the enamel
and
in the outer half of dentine

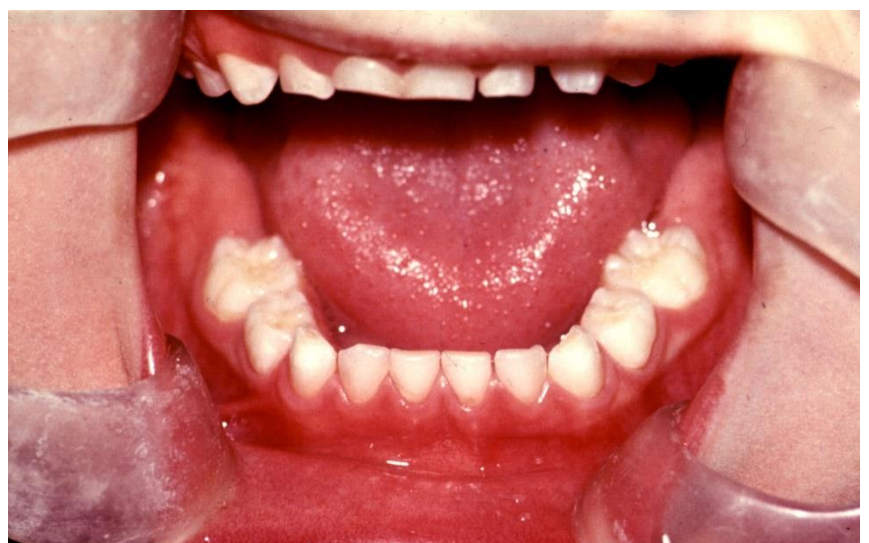
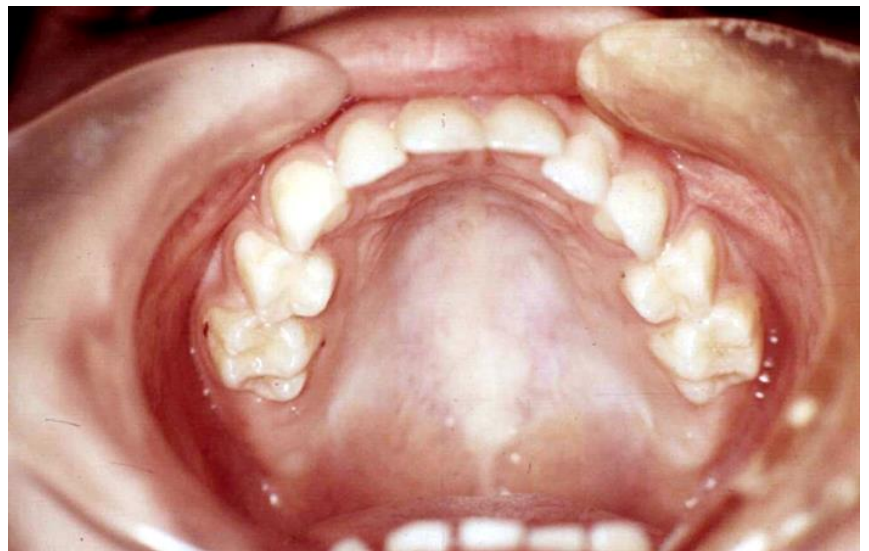
Radiolucency in the enamel
and dentine
reaching to the inner half of
dentine
(caries pulp. prox.)

COMMENTARY

Describe morphology of primary teeth, especially that of molars.

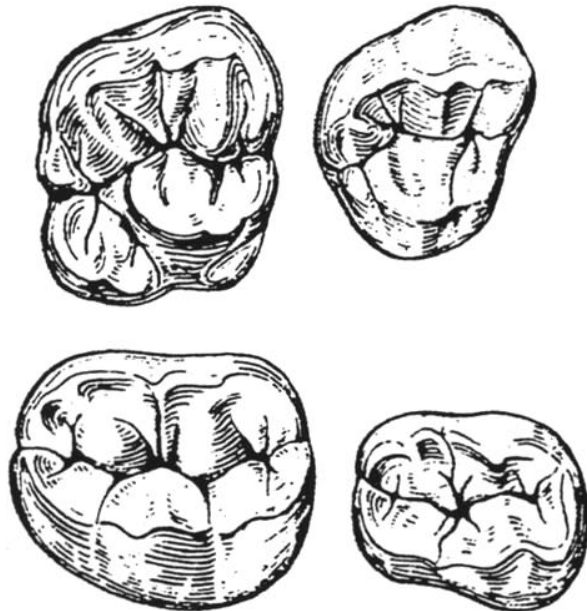
MORHOLOGY OF PRIMARY TEETH IN THE UPPER AND LOWER JAWS



COMMENTARY

Describe number of cusps in individual molars and depict the course of the fissure complex in individual molars.

SCHEMATIC OUTLINE OF OCCLUSAL SURFACES OF PRIMARY MOLARS



THE STUDY STIMULUS

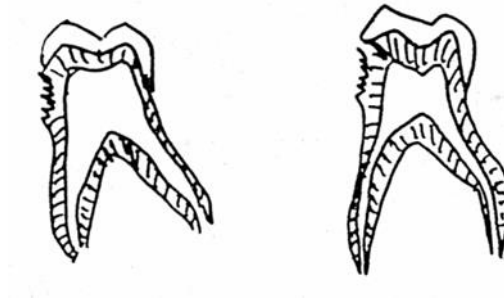
Repeat: morphology of teeth.

COMMENTARY

Preparation and filling materials for class I according to Black.

DENTAL CARIES - PRIMARY DENTITION

CARIES DEPTH

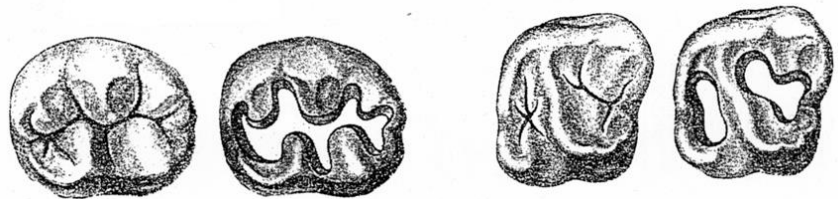


a) 3 years

b) 6 years

2 mm — molar
a) car. pulp. proxima
b) caries media

OCCLUSAL CARIES



diameter of the bur – 1 mm, depth - 0,5 mm in dentin

FILLING

- GIC (or. + alkaline cement)
- compomer (or + alkaline cement)
- composite resin (+ dentine adhesive, or capping of pulpal wall with alkaline cement)

COMMENTARY

Repeat: important information for preparations, materials for primary teeth treatment.

WORKING PROCEDURE

- hand instruments
- low revolutions
- minimal pressure
- checking of the cavity

- Permanent filling



PEDIATRIC DENTISTRY

FILLING THERAPY IN PRIMARY DENTITION
PRACTICAL TRAINING

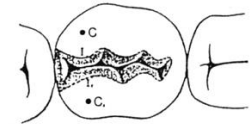
COMMENTARY

Working procedures/steps for class II preparation according to Black. Compare morphology of primary and permanent teeth.

APPROXIMAL CARIES

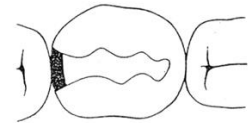
CARIES MEDIA

marginal ridge is not affected
otherwise
caries pulpa proxima or caries penetrans



THE FILLING SHOULD INCLUDE

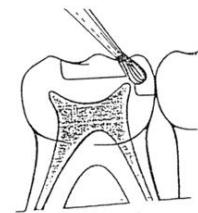
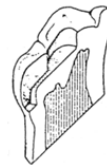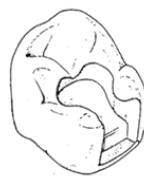preventive extension
retention
resistency



NEIGHBOURING TOOTH HAS TO BE INVESTIGATED

isthmus - 1/3 of the intercuspal distance not less than 1,5 mm
gingival wall - 1 mm

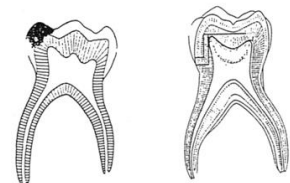
DENTAL PULP MUST NOT BE THREATENED



Aim attention to the extent of the dental pulp size – horns reaching almost to the dentino-enamel junction.

MESIAL HORN – EASY PERFORATION

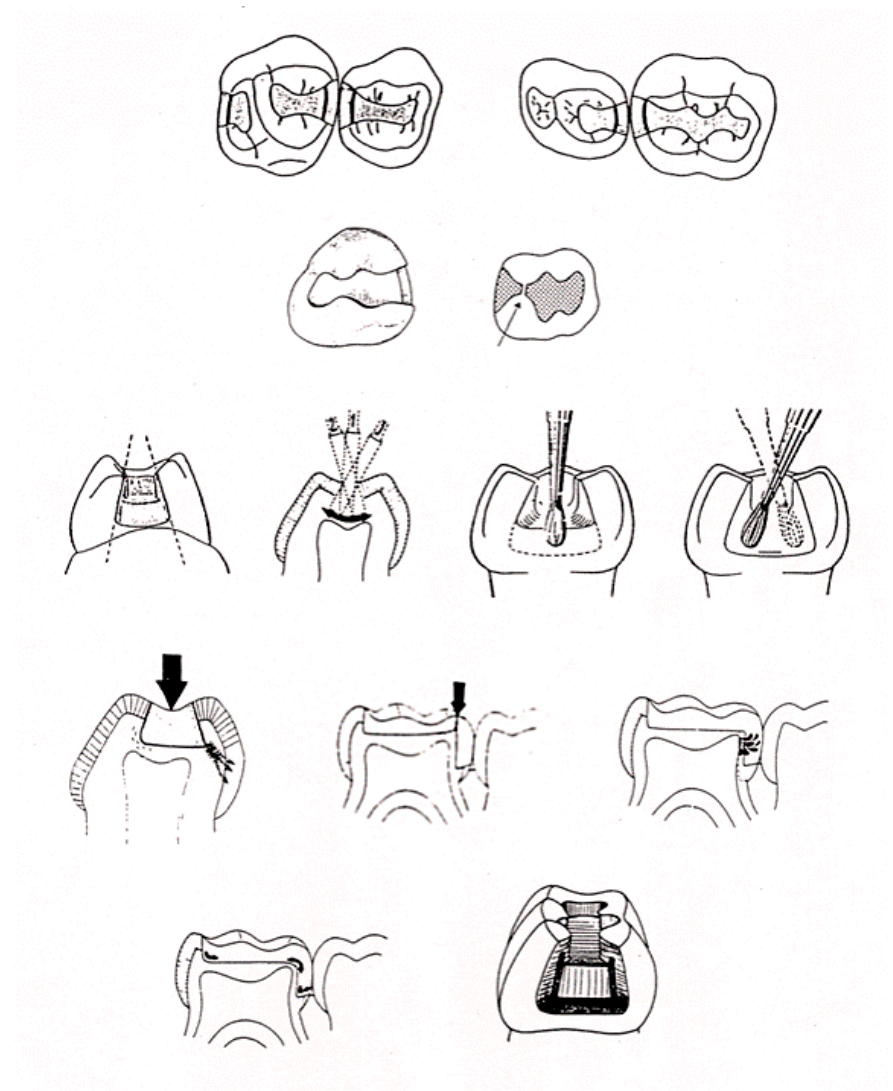
| | | | |
|---|----|----|---|
| V | IV | IV | V |
| | IV | IV | |



COMMENTARY

All rules of the class II cavity preparation have to be respected, i.e. rule of preventive extension, retention and resistency. Approximal walls of the cavity converge occlusally, must not reach the cusps of the tooth, all transitions are rounded. For composite materials not only adhesion but also macroretention are used.

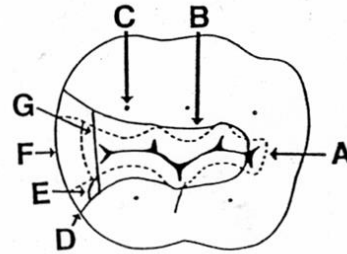
PREPARATION OF THE APPROXIMAL WALL OF THE PRIMARY MOLAR



COMMENTARY

Survey of the most frequent errors in class II preparation in primary molars. Dotted line represents the correct preparation.

ERRORS DURING PREPARATION – CLASS II CAVITY

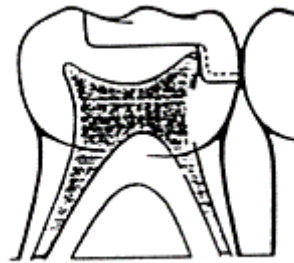


- A. Insufficient preventive extension – fissure complex not involved totally in the preparation.
- B. Excessively involved cusps – loss of hard tissues
- C. Isthmus too large – greater than 1/3 of the intercusp distance
- D. Approximal walls divergent too much: the cause of the following errors
 - E. The angle between axial and buccal/lingual walls too great
 - F. gingivally small extension – point of contact is not in the filling (in the gingival region)
 - G. gingival wall too great mesio-distally – more than než 1 mm

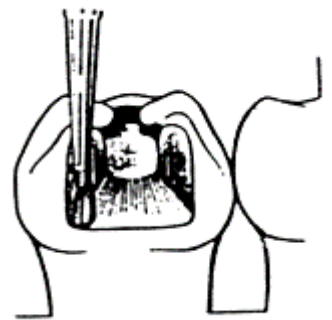
COMMENTARY

Be carefull on preparation of the approximal wall, on careless preparation dental pulp can be exposed as well as on large or deeply subgingivally reaching shoulder.

ERRORS DURING CAVITY PREPARATION APPROXIMALLY

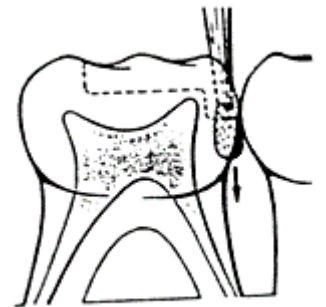


Dental pulp exposure (horn)

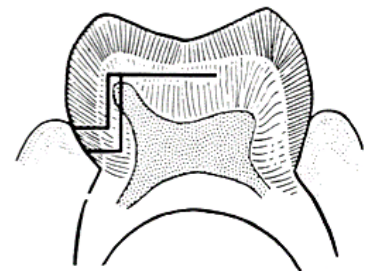


Loss of wall convergence

Too deep shoulder preparation



Consequence – dental pulp exposure



COMMENTARY

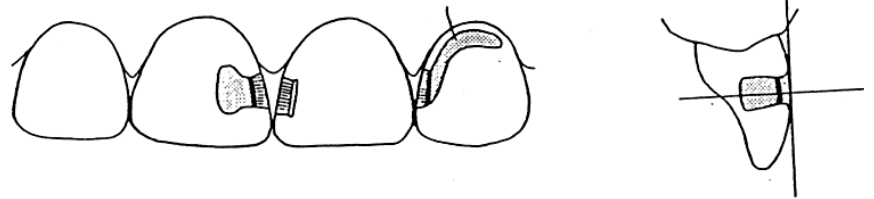
Access for class III. preparation is from the labial surface. Extent of cavity corresponds to the extent of caries. Dovetail preparation can be done on the labial surface in case of an extensive caries..

Class III and V can be connected into one cavity in case that only narrow strip of healthy hard tissues would remain between them.

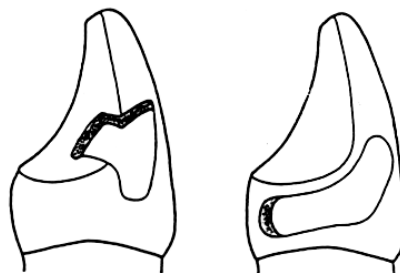
Class V is not frequent in primary dentition. If filling is used for the treatment the preparation is performed according to the rules valid for the permanent dentition.

CLASS III.

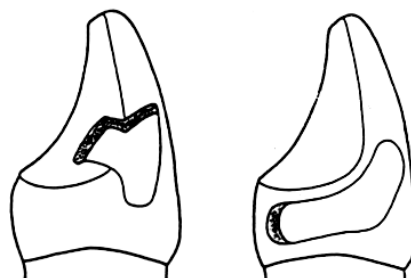
Access opening from the labial surface, the size of cavity is given by the caries size.



Access opening in primary maxillary canines may be from the palatatal surface, in mandibular canines from vestibular surface.



The dovetail is usually placed into the strong marginal ridge, not directly to the oral surface.

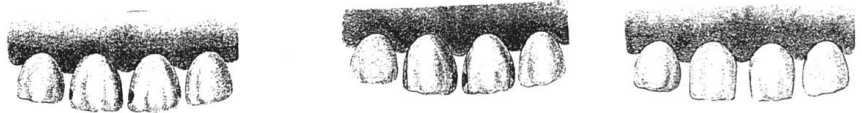


COMMENTARY

Incisal edge is not restored in the treatment of the class IV. The filling usually covers only the dentine wound.

CLASS IV.

- Not very frequent
- Crown must not be restored esthetically – a cover of the dentin wound
- Teeth before shedding – grinding of approximal surface, impregnation by fluorides



FILLING IN CLASS III. AND IV.

- Composite resin + etching technique
- glassionomer cement
- compomers + etching technique
- Ag- quite exceptionally in class III – gingival bleeding

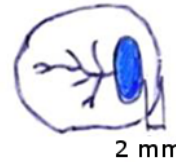
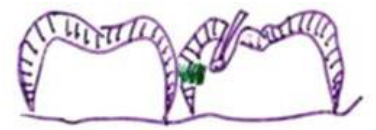COMMENTARY

Tunnel preparation is indicated rather in the permanent dentition, in primary teeth, if it is possible, on the second molars mesially. GICs, chemically cured, reinforced by resin are recommended.

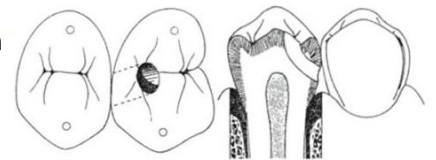
TUNNEL PREPARATION

CONDITIONS

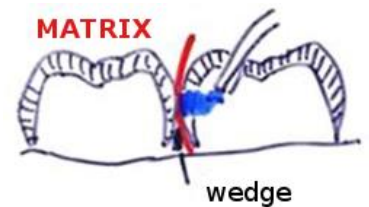
non affected marginal ridge
caries of small extent.



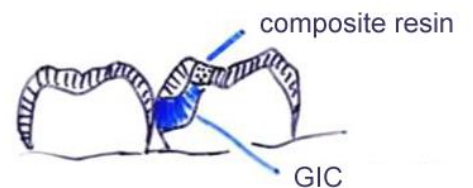
access – round bur
access channel – to
extend bucco-lingually



removal of carious masses,
matrix application + wedge



esthetic improvement by composite resin (compomer) not necessary

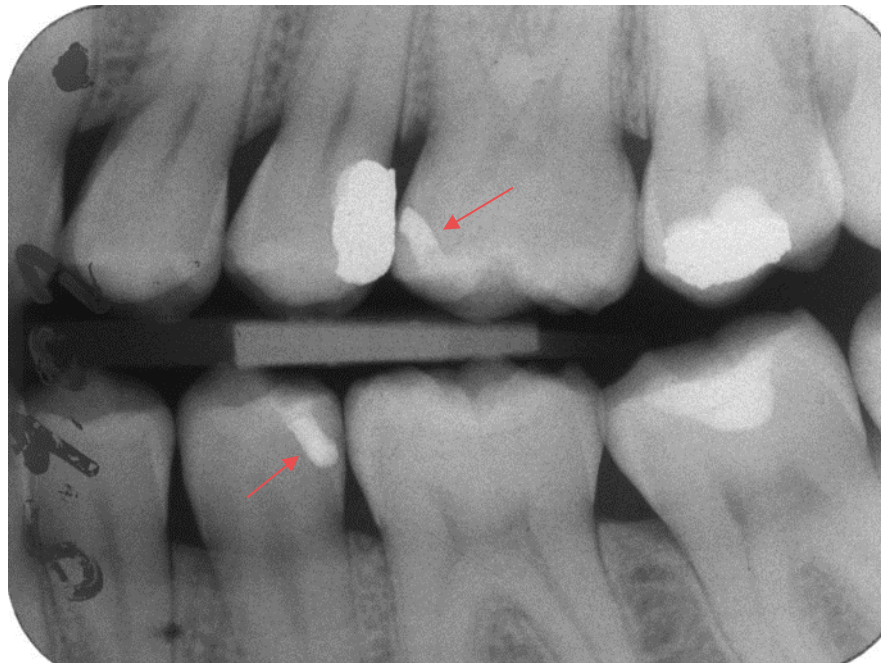

fissure complex has to be sealed

COMMENTARY

B-W projection, tunnel preparation,
26 a 35 (arrow).

RTG: BITE-WING PROJECTION



COMMENTARY

Caries is localized approximally, gingivally, marginal ridge is not affected, not undermined, caries is not too extensive and is localized below the point of contact. Occlusal box is replaced by preparation on the buccal surface.

a) Model of the tooth 54. Auxilliary cavity (dove-tail) on the buccal surface does not require the isthmus as it is not exposed to strong masticatory forces. Cavity on the approximal surface is parallel to the cervical line (i.e. horizontal) and terminates in the healthy tissue. Carious tissue has to be removed.

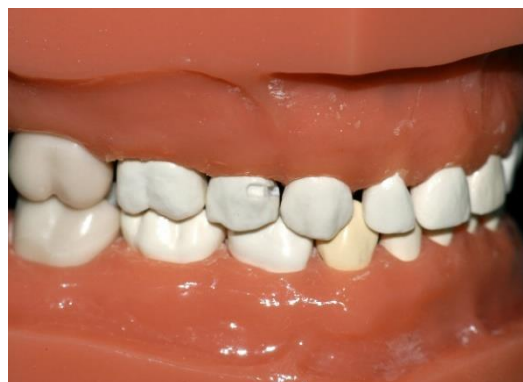b) View on the buccal surface with the cavity prepared mesially.

c) Matrix (for better visibility metallic) secured with a wooden wedge. Usually, transparent matrix for GIC is used (no connection between the GIC and metal). On GIC application the matrix is slightly folded back (in this case mesially). Chemically cured dosed resin modified GIC is used. Matrix is pressed toward the tooth and is removed after the material sets.

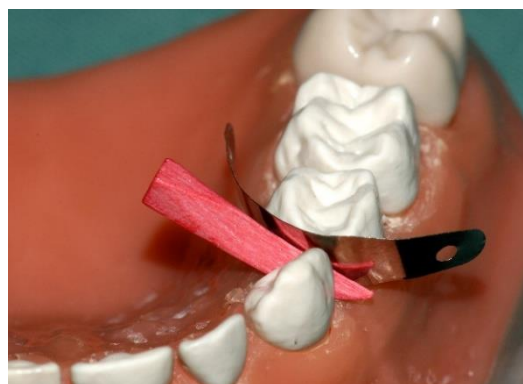BUCCAL PREPARATION



a)



b)



c)

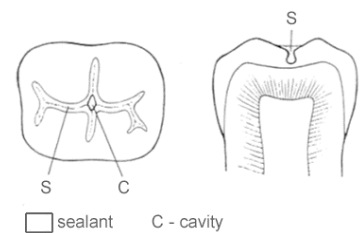
COMMENTARY

Working procedure for the preventive filling making. X-ray in bite-wing projection is necessary for preventive filling indication

PREVENTIVE FILLING

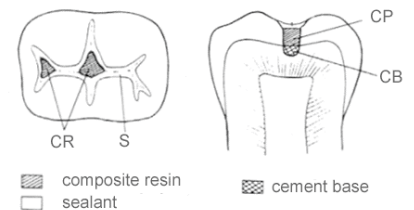
SEALANT FILLING

caries confined to enamel of pit or fissure
- only sealant
at the present time rather exceptionally,
(D1 –D3 are treated by prophylactic methods)



PREVENTIVE FILLING

- Composite resin + etching technique
- glassionomer cement
- compomers



Indication:

primary molars, premolars, permanent molars

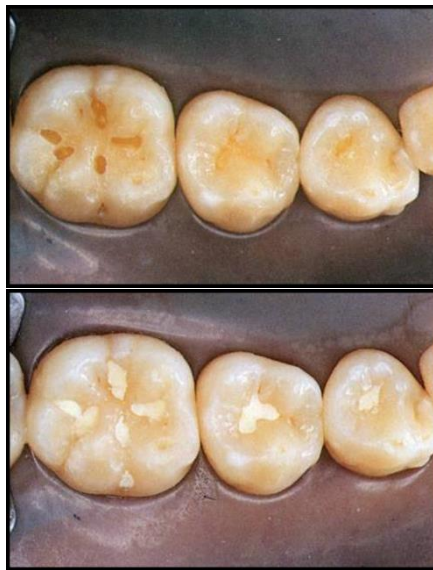Contraindication:

approximal caries on the treated tooth (D1 and more), no open caries of class II on remaining teeth, more extensive caries (more than 1/3 of inter-cuspal distance), chronic caries, DMFT/dmft \geq 5

COMMENTARY

- a. Cavity preparation
- b. Filling, GIC.
- c. Enamel etching
- d. Etched enamel in fissures
- e. Sealed preventive filling

PREVENTIVE FILLING, WORKING PROCEDURE



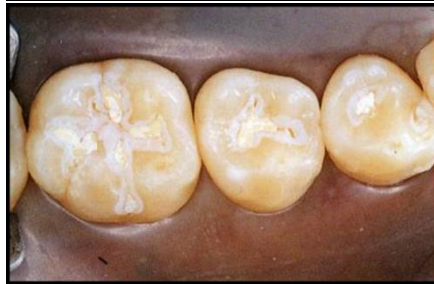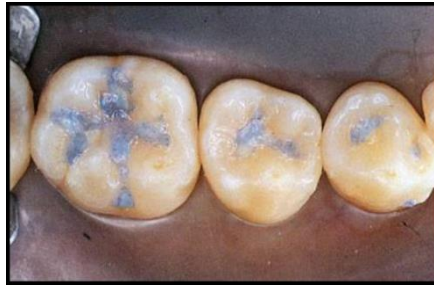a.

b.

PD

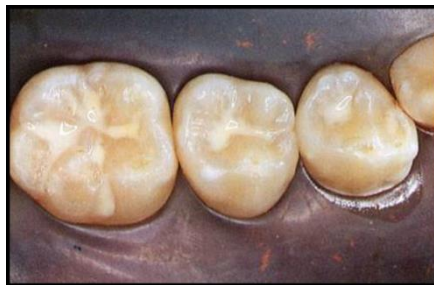PEDIATRIC DENTISTRY

**FILLING THERAPY IN PRIMARY DENTITION
PRACTICAL TRAINING**



c.

d.



e.

COMMENTARY

This method is used only exceptionally.

Indication

- the crown is not destructed
- points of contact are maintained (mesio-distal diameter)
- child is healthy
- the only gangrenous tooth in dentition

Permanent drainage, the tooth 54, 16 not erupted yet. In case of extraction of 54 there is a danger of mesial movement of 55 and 16.

ADVANTAGE AGAINST THE OPEN TOOTH METHOD

- *better hygiene*
- *better masticatory function*
- *better function as space maintainer*

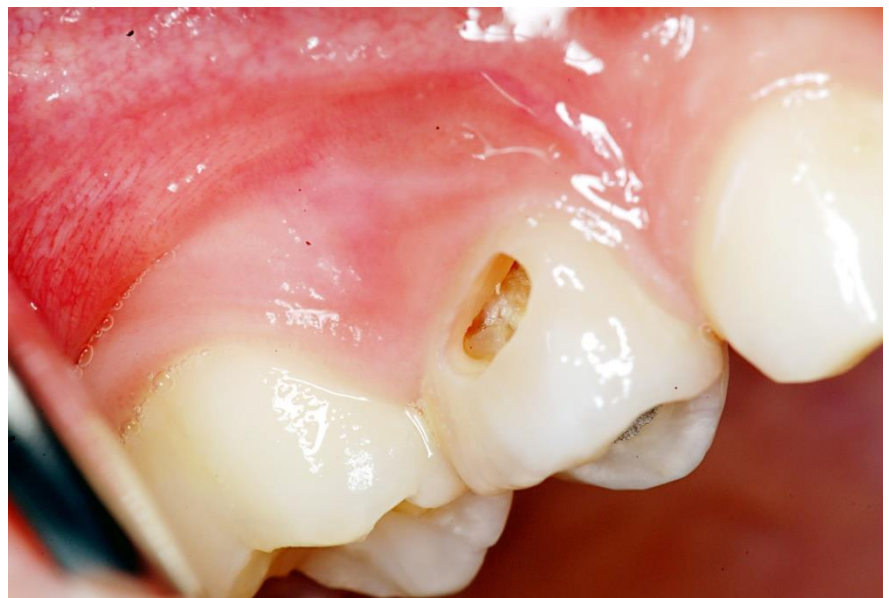PERMANENT DRAINAGE

Modification of the open tooth technique

WORKING PROCEDURE

It is possible to restore the tooth

1. removal of gangrenous masses
2. disinfection of root canals
3. Calcium hydroxide is applied on the floor of the dental pulp cavity
4. the overlaid by zinc oxid cement
5. hermetic filling
6. Large communication reaching into the dental pulp cavity is prepared from the vestibular surface- along the gingival margin
7. Calcium hydroxid is rinsed out of the dental pulp cavity
8. the only gangrenous tooth in the dentition





PD

PEDIATRIC DENTISTRY

**FILLING THERAPY IN PRIMARY DENTITION
PRACTICAL TRAINING**