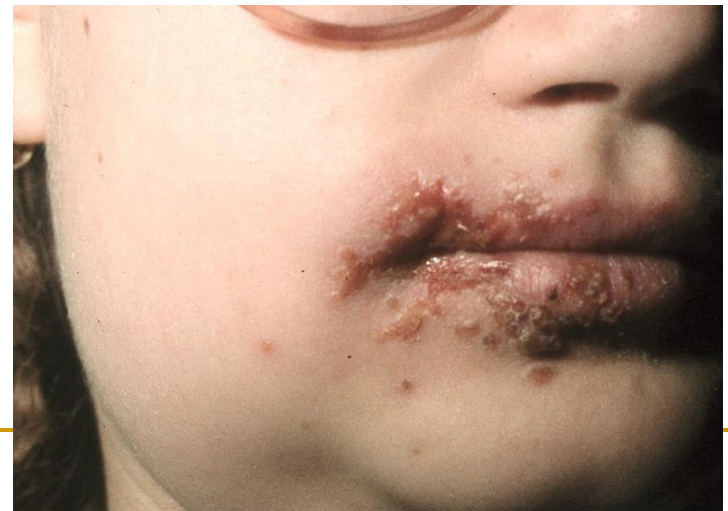
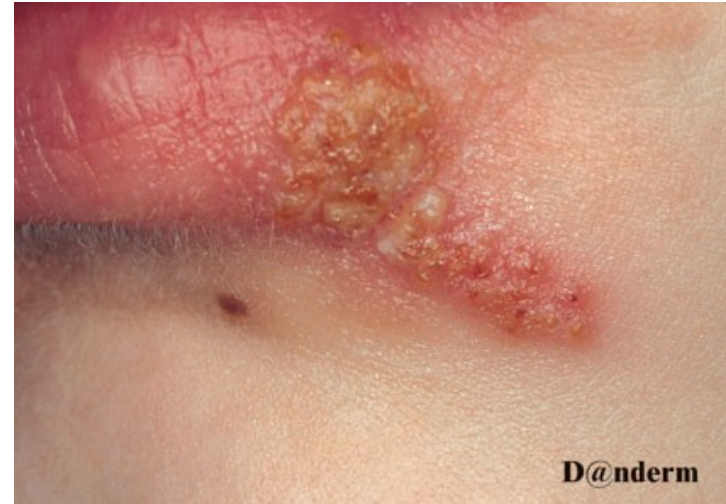Oral diseases

H. Jedličková

Oral diseases – viral etiology

- Herpes simplex HSV1 (2) (recidivans)-herpes labialis
- Gingivostomatitis herpetica – severe primary infection
- Erythema multiforme triggered by HS (late hypersensitivity)
- Herpes varicella zoster II. , III. trigeminus branch - mucous membrane lesions
- Infectious rashes
- Herpangina, hand-foot-mouth disease (coxsackie A), morbilli (morbillivirus) Koplik's spots



Common warts - human papillomavirus HPV 1-68

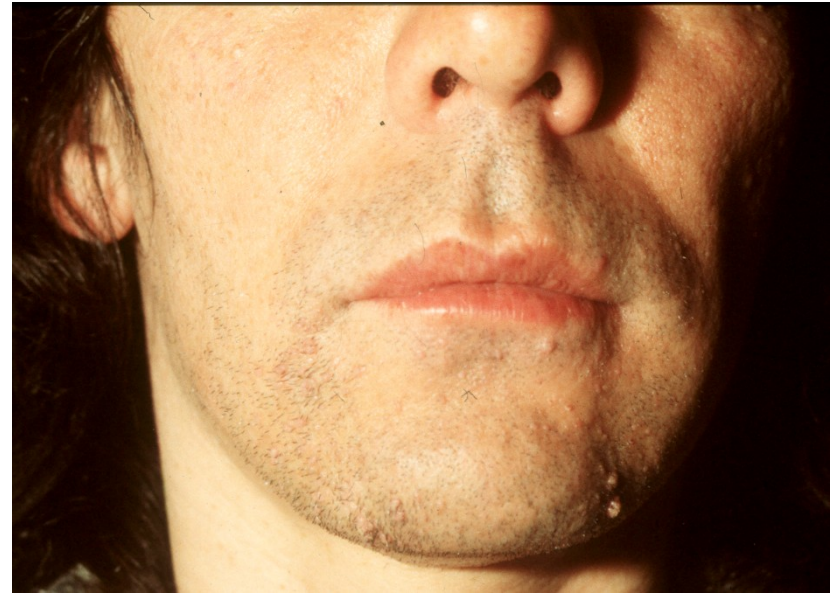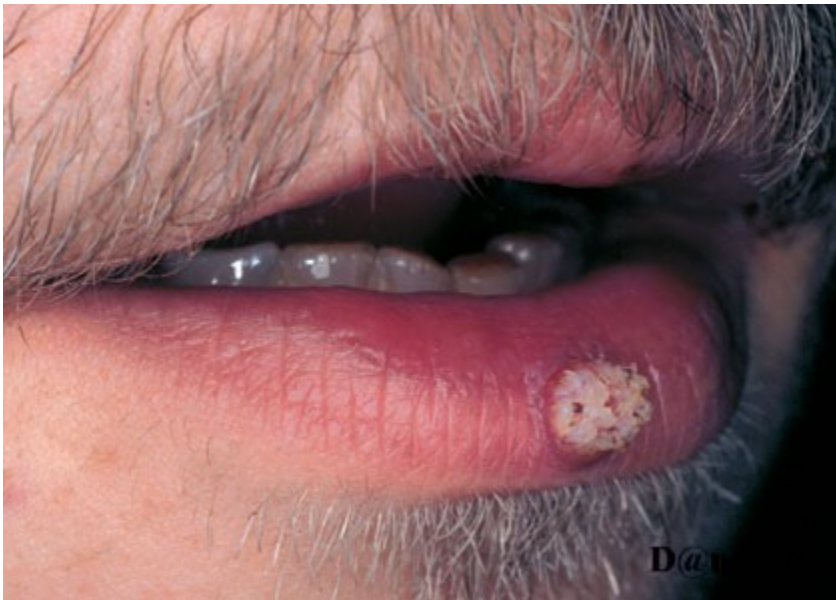(2,4,40)

Verruca vulgaris

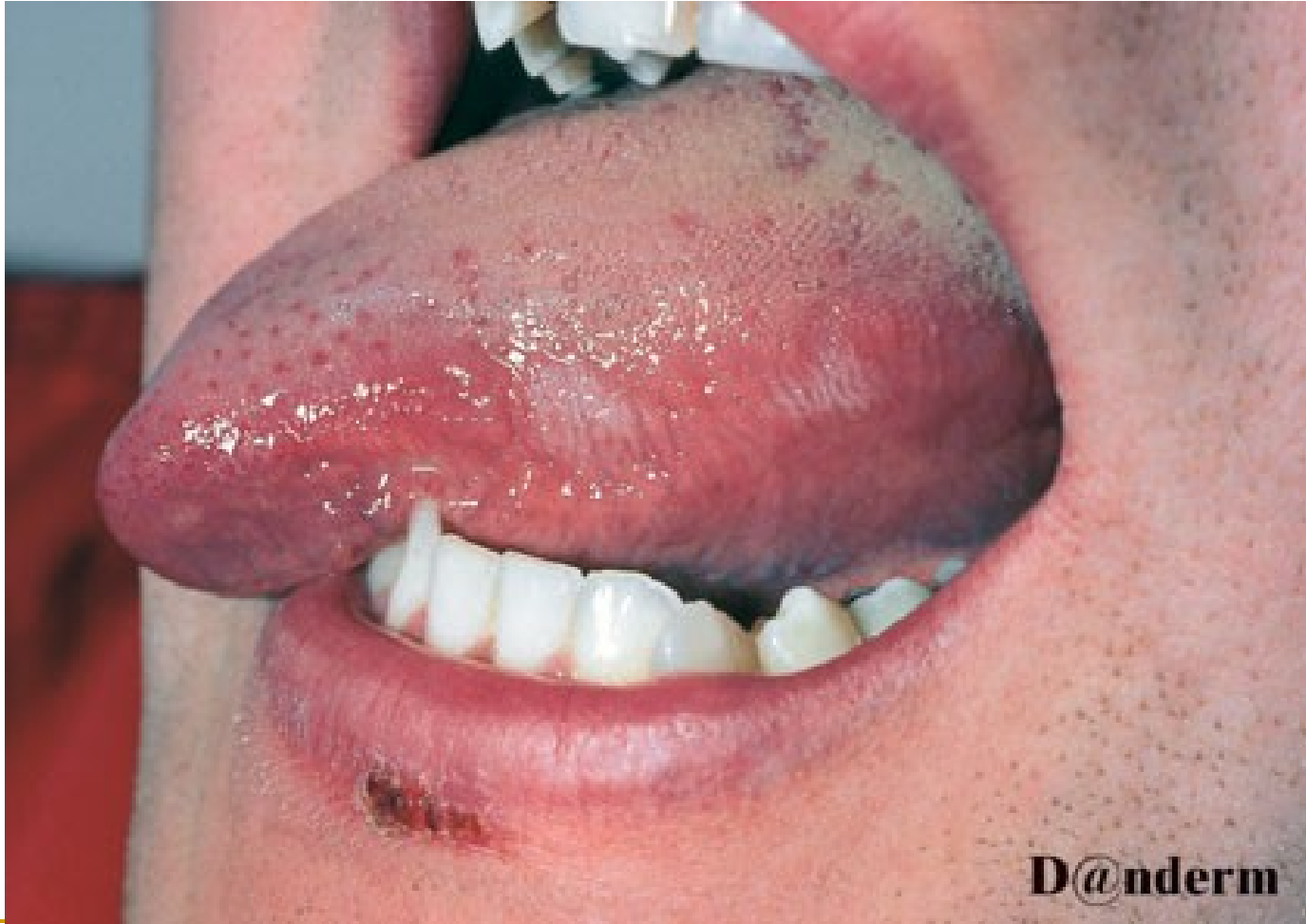Verruca vulgaris filiformis

Papillomatosis oris – condylomata plana type 13, 32

Verruca plana, (condyloma accuminatum is genital HPV infection)



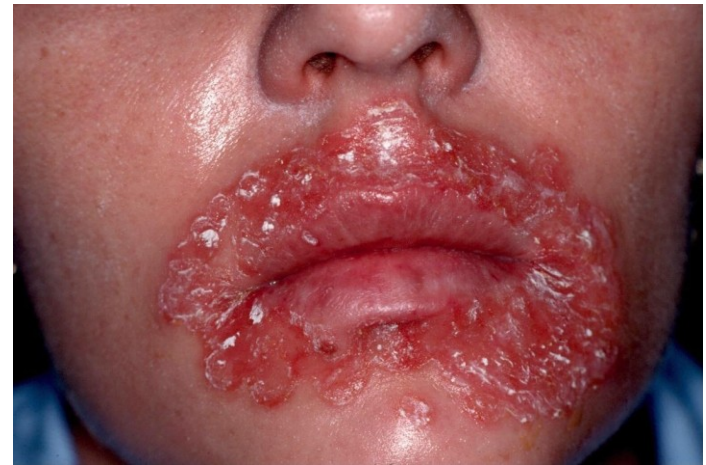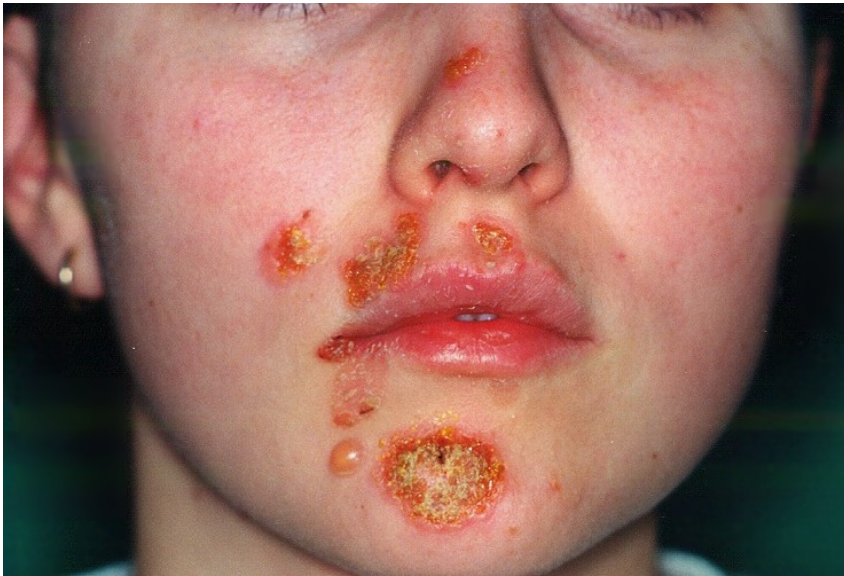EBV hairy leucoplakia - HIV



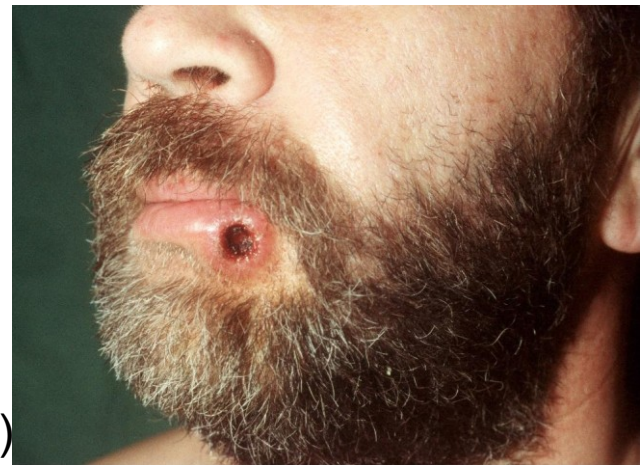Oral diseases – bacterial

Impetigo staphylogenes, streptogenes

Bullous impetigo (staph)

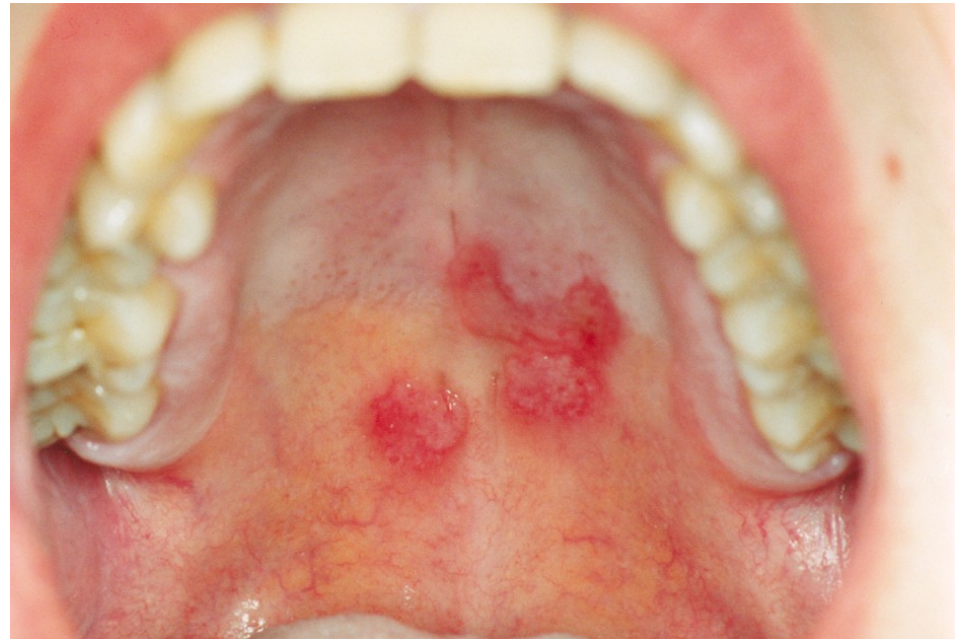

Chancriform pyodermia)



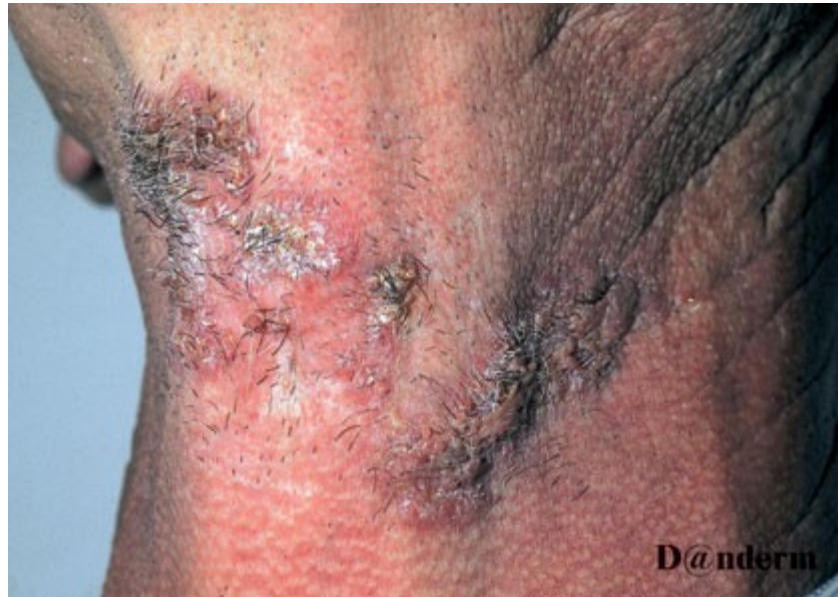Oral diseases – bacterial - other

- Scarlet fever – strept. pyogenes – (strawberry tongue)
- Syphilis – chancre, mucous patches, tonsillitis, makrocheilia, guma, lymphadenopathy
- Gonococcal stomatitis – pharyngitis, erosions, lymphadenopathy
- Mycobacteria – tbc cutis colliquativa
- Stomatitis ulcerosa, necrotising gingivitis, noma (fusobacteria, streps, treponemas etc) – in malnutrition



Actinomyces – cervicofacial form *actinomyces israelii*

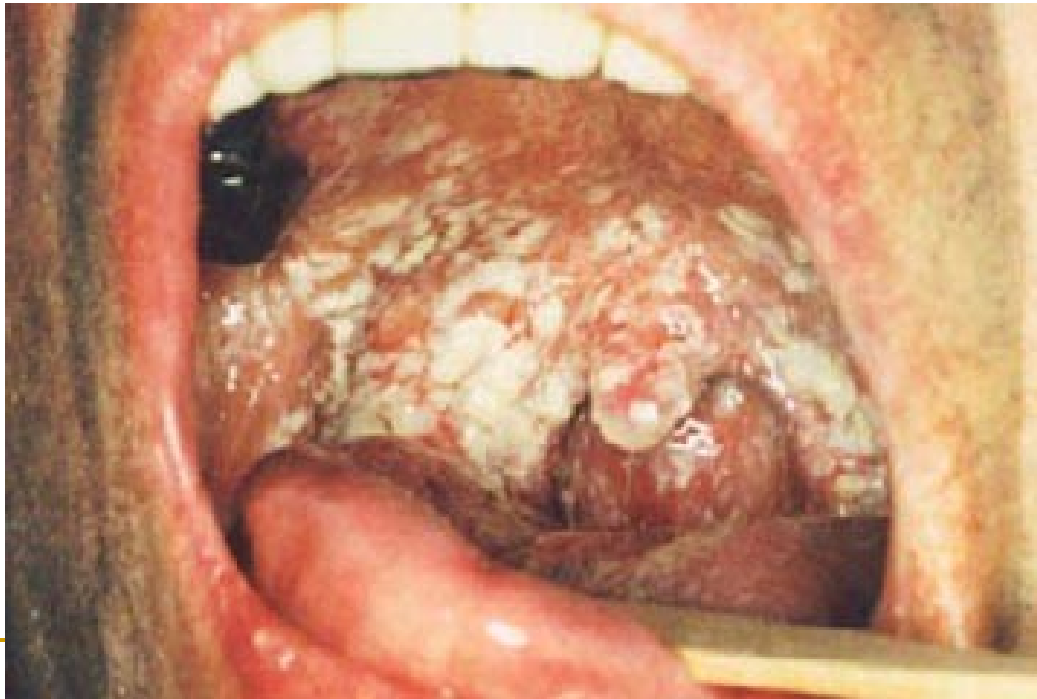Commensal oral flora – opportunistic pathogens
Formation of fistulas, discharge with white grains
Tx –PNC, clindamycin – 3 weeks



D@nderm

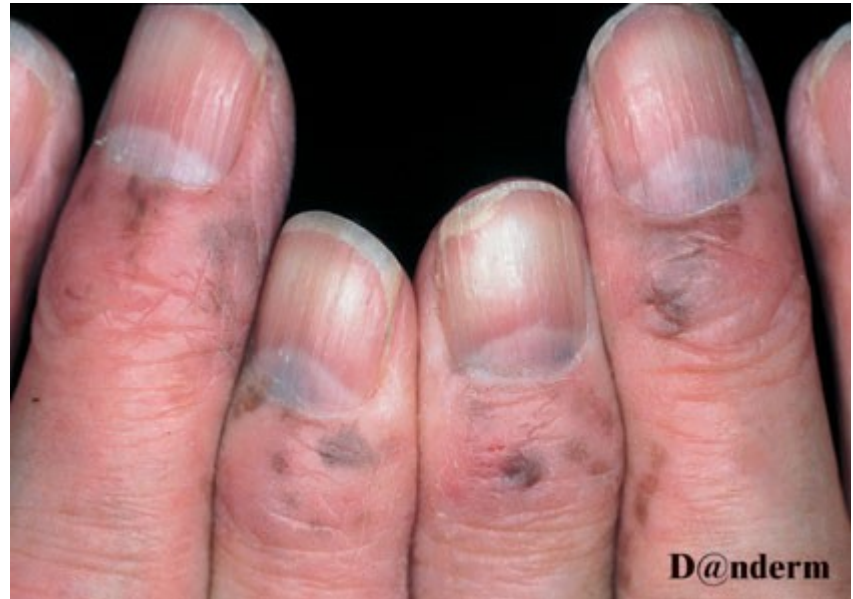Oral diseases - fungal

- Candidiasis – soor – thrush
- (candida albicans, tropicalis, glabrata, crusei)
- Newborns, ATB therapy, topical corticosteroids, immunosuppression, diabetes mellitus, oral diseases, HIV



Oral diseases – pigmentary changes

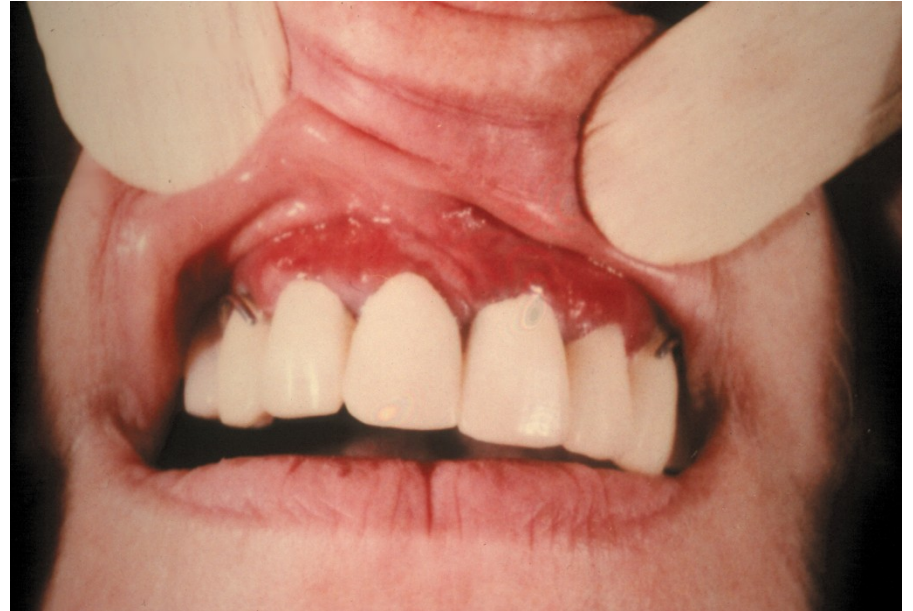- Normal pigmentation
- Lentigo, ephelis
- Blue nevus / melanocytic nevus
- Melanoma
- Peutz Jeghers syndrome (intestinal polyps)
- Laugier Hunziker syndrom (no polyps)
- Amalgam tattoo
- Drug induced pigmentation
- Addison disease



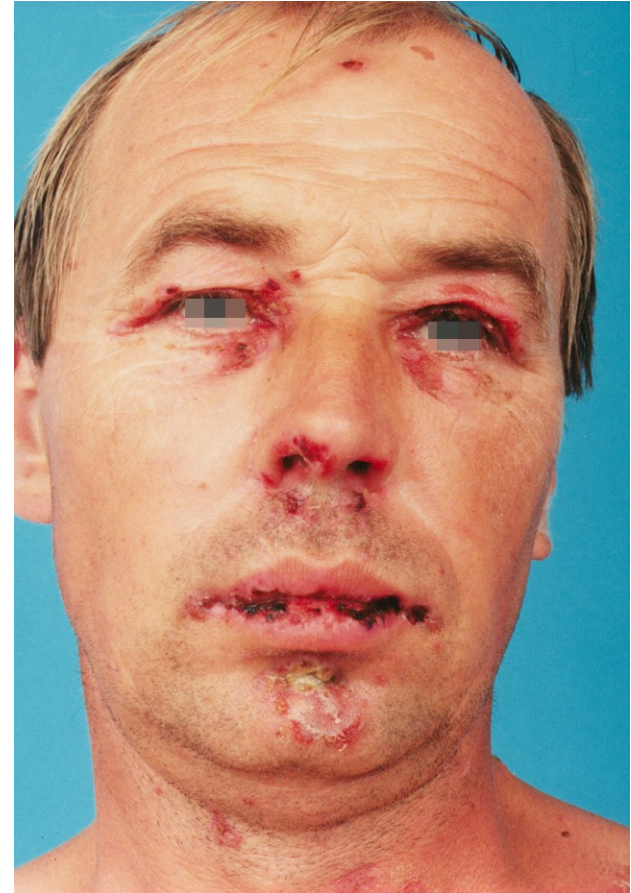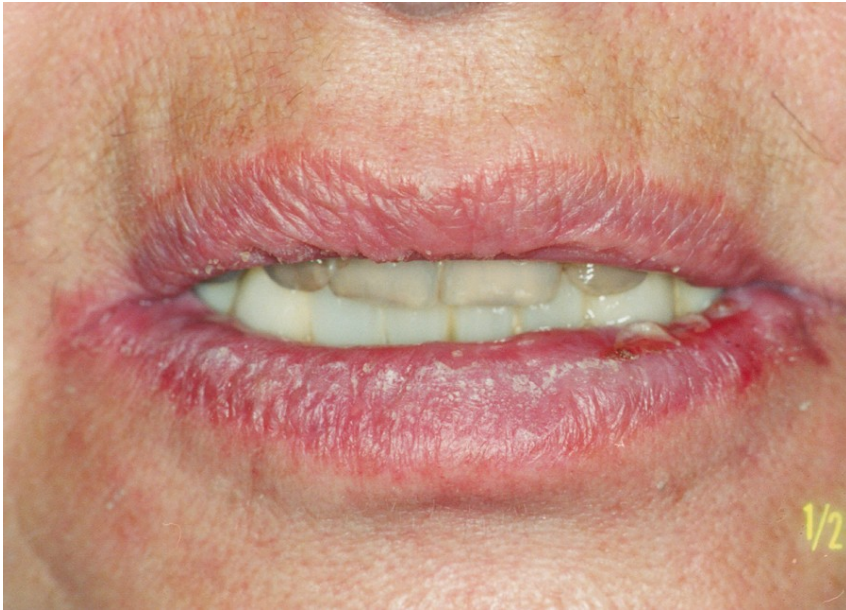Oral diseases – blistering, autoimmune

- Pemphigus – p. vulgaris (desmogleins)
- Pemphigoid – cicatricial (anti BP, laminin 332 antibodies)
- Linear IgA dermatosis
- Epidermolysis bullosa acquisita EBA

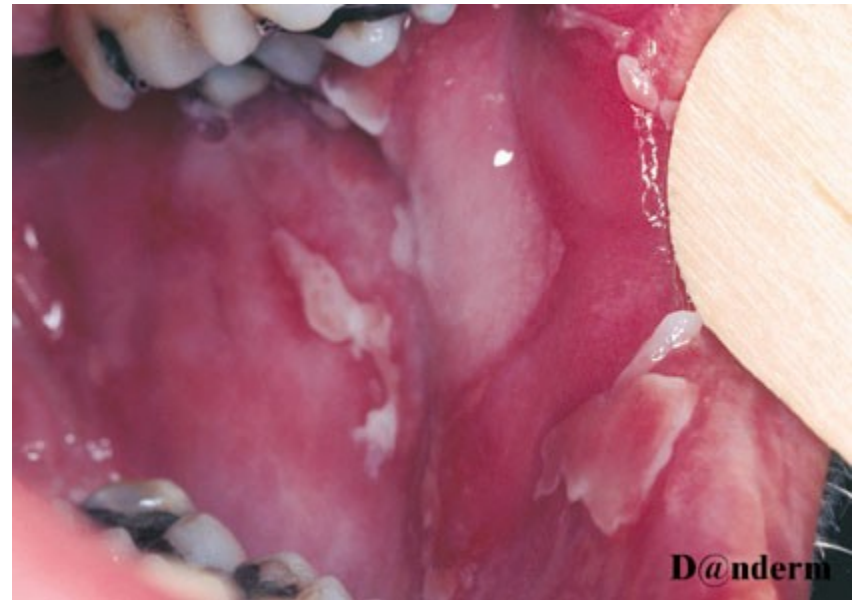
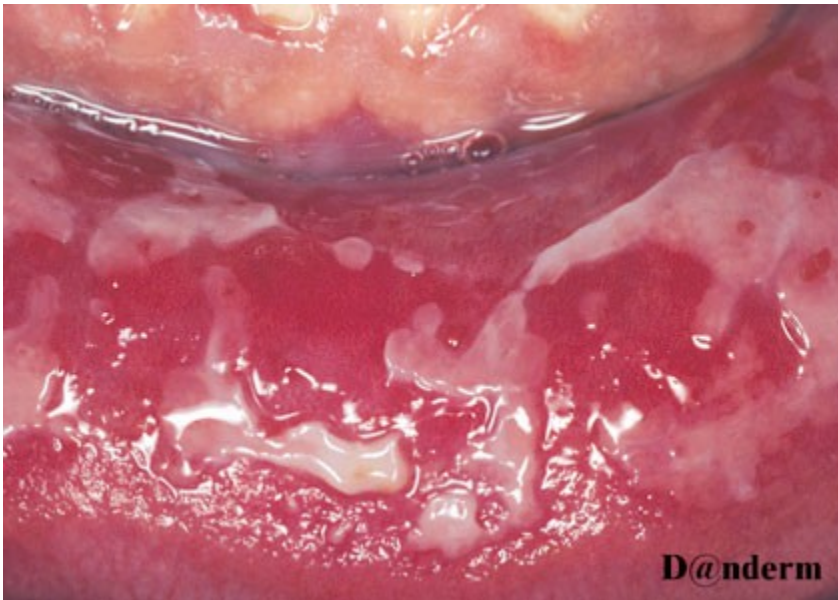
- Desquamative gingivitis
- Erosions, scarring



Pemphigus vulgaris

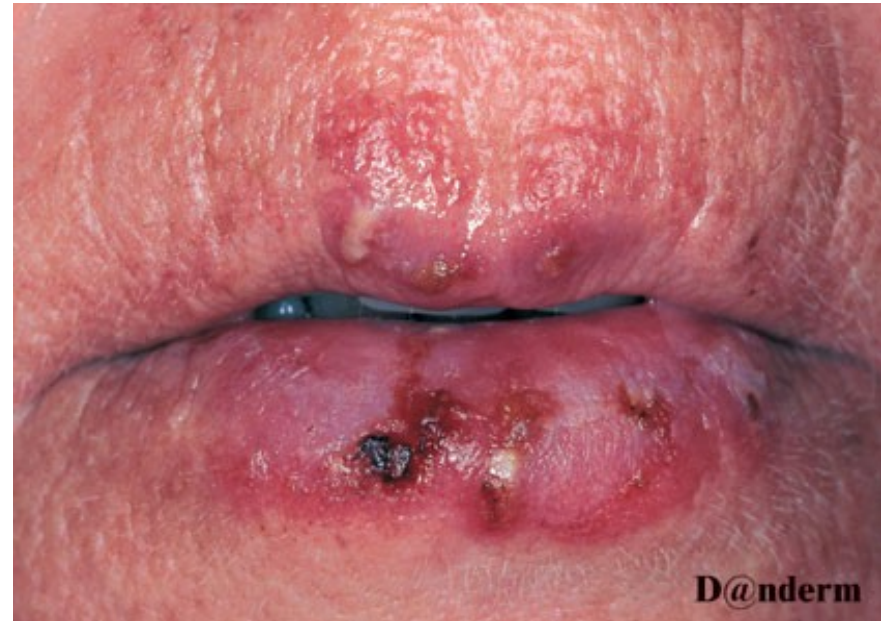
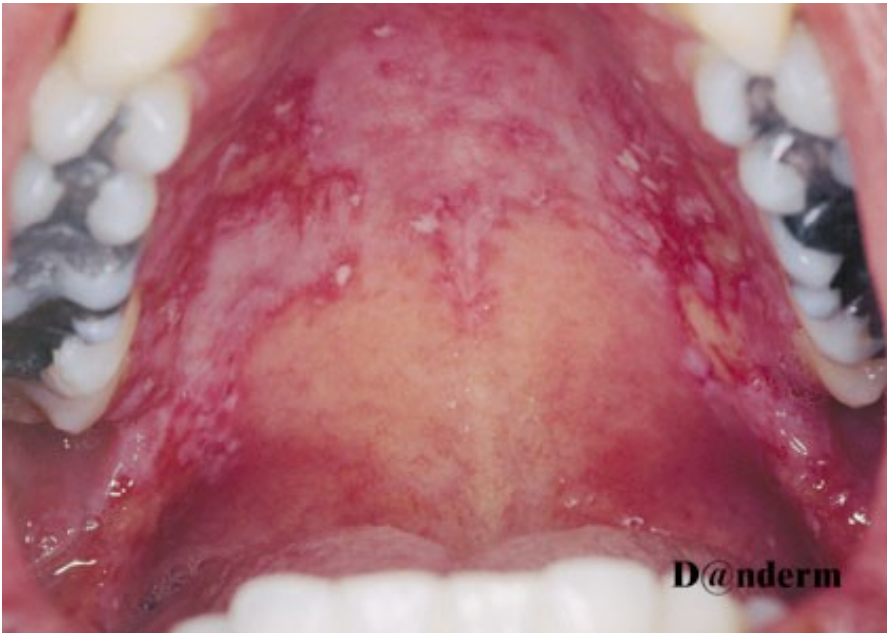
Pemphigus vulgaris



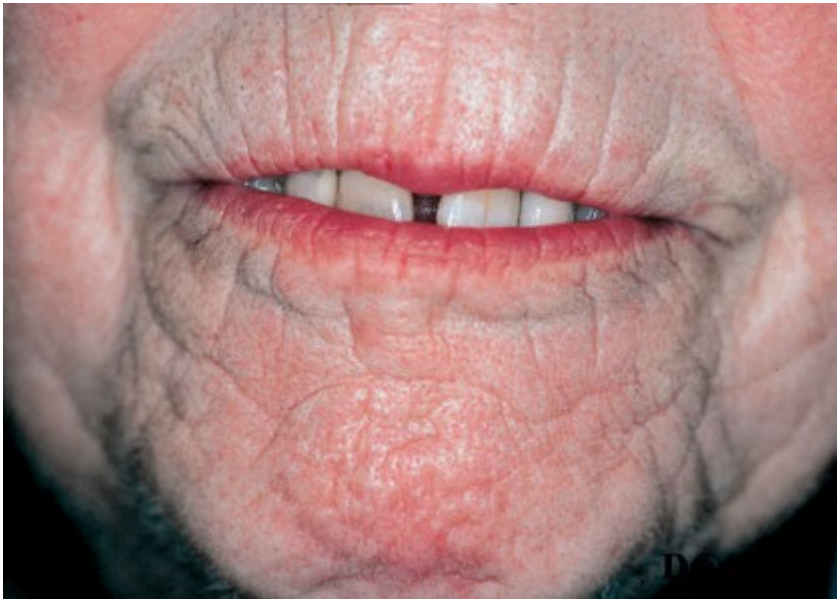
Oral connective tissue diseases

- Lupus erythematosus – SLE, CDE oral erosions, scarring
- Scleroderma – microstomia
- Sjögren syndrome - sicca syndrome



Scleroderma

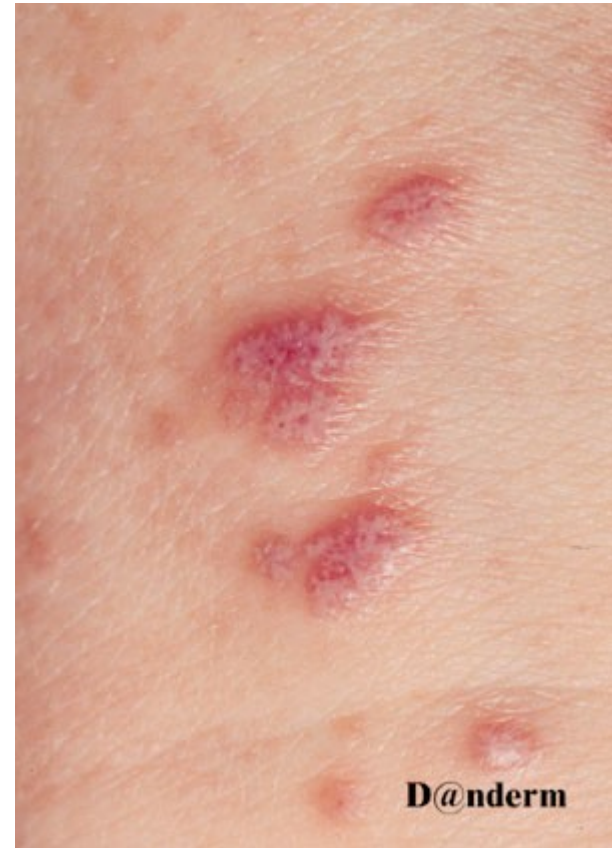Systemic scleroderma x localized scleroderma



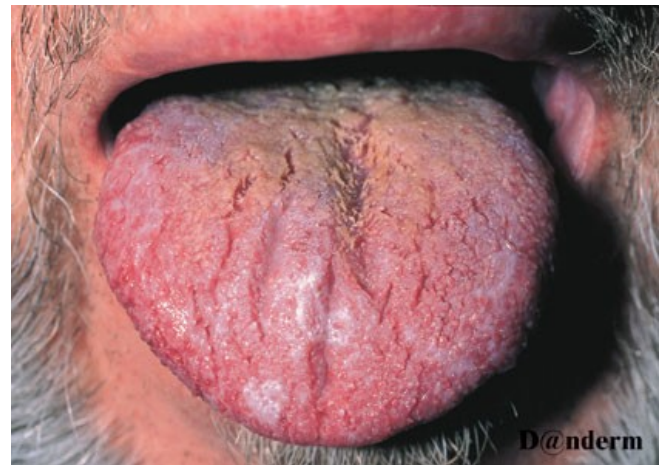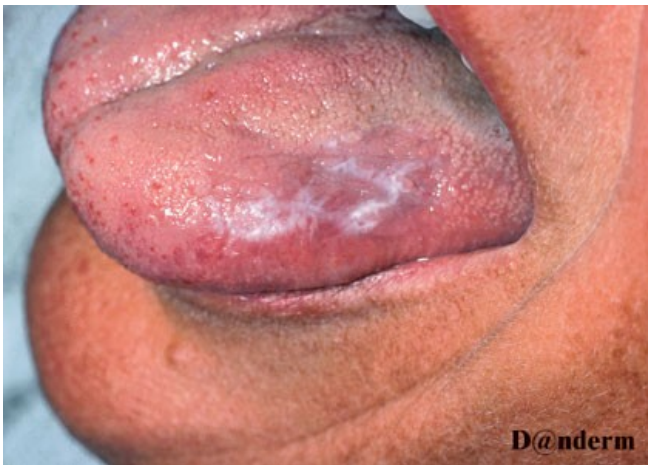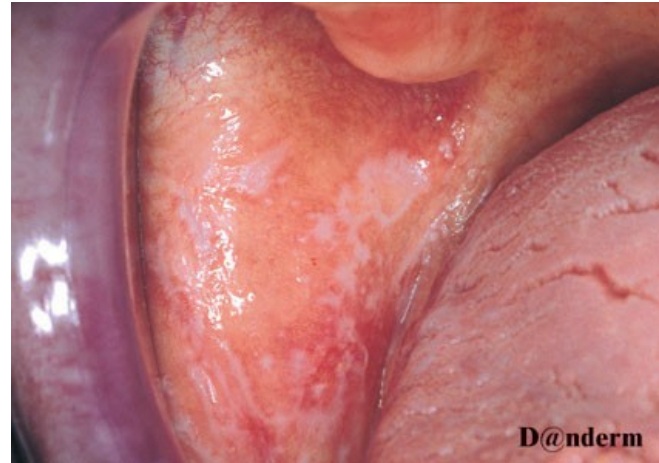
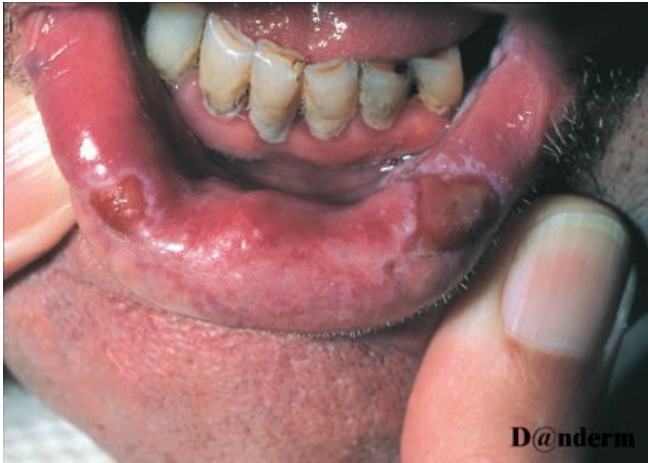Lichen ruber planus

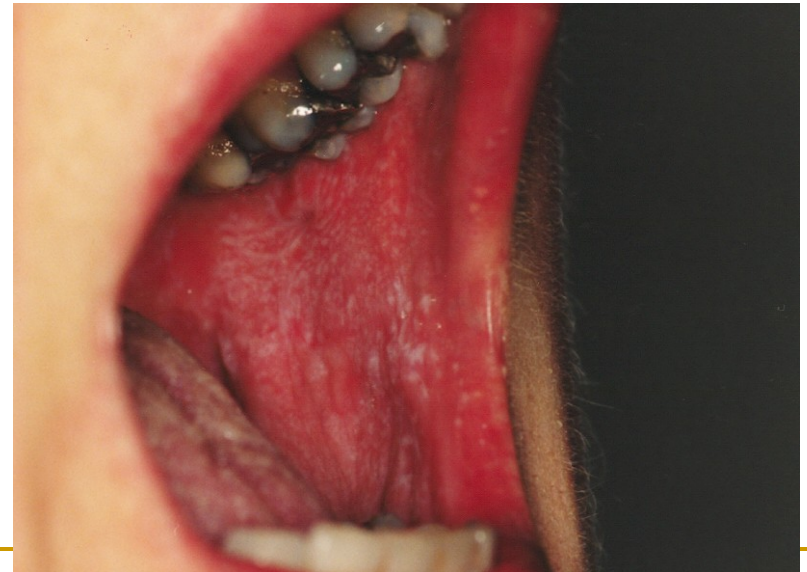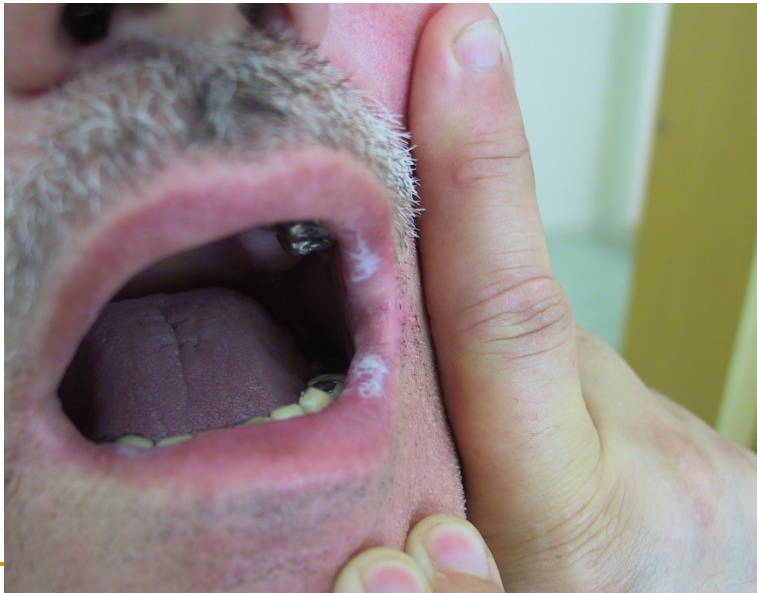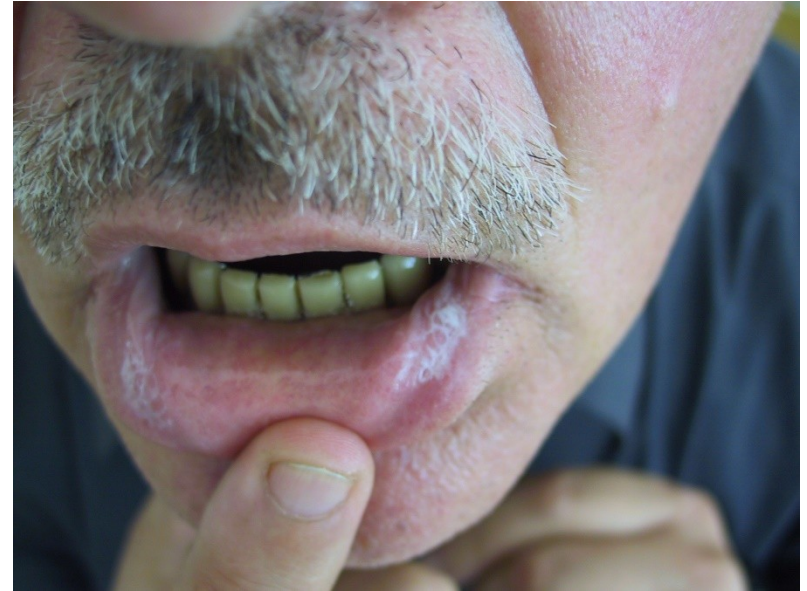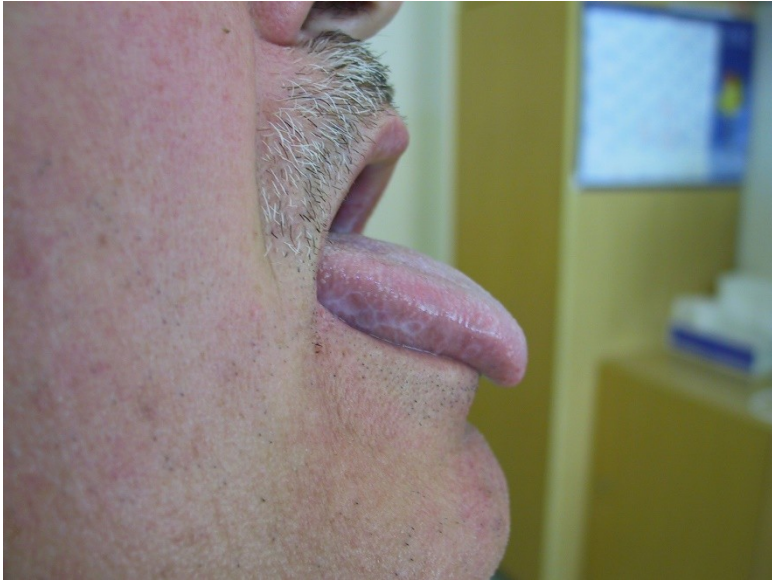Non infectious inflammatory disorder –
lichenoid reaction in dermoepidermal
junctions
delayed hypersensitivity reaction

Etiology – viral – hepatitis C, respiratory vv.
Drug eruptions – betablockers, antimalarials
Contact stomatitis - gold
Autoimmune diseases
Chronic GVHD



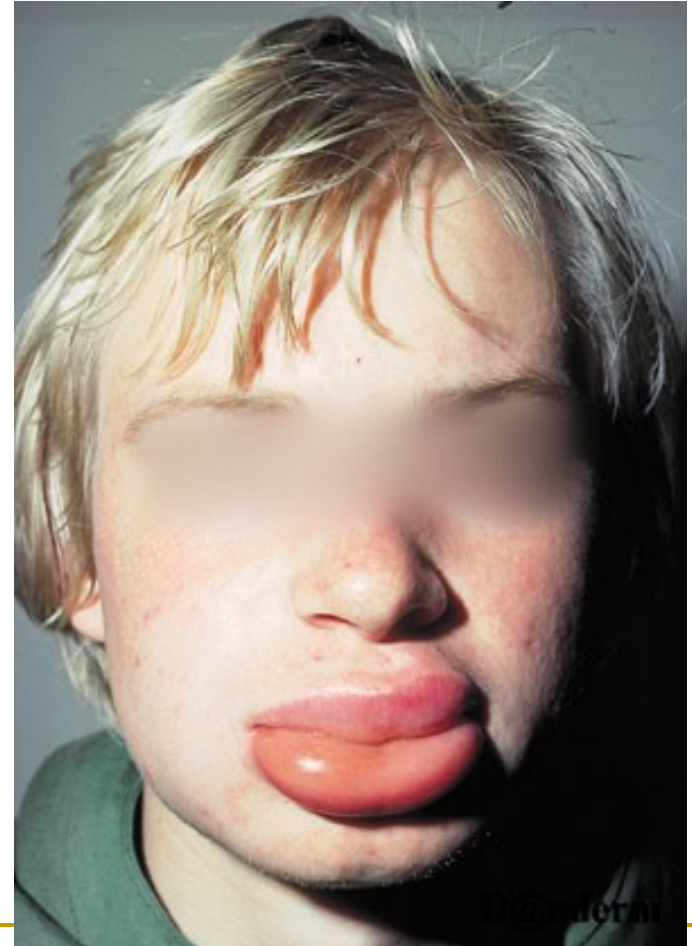Lichen planus mucosae erosivus





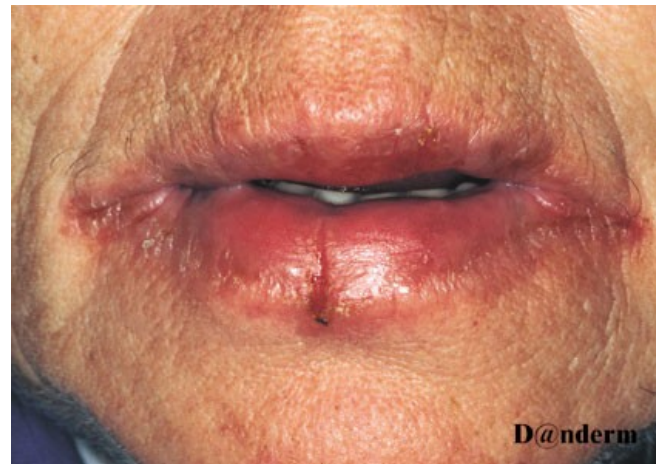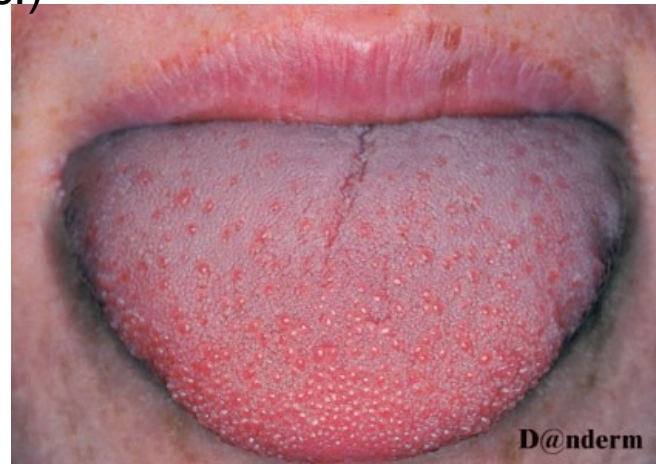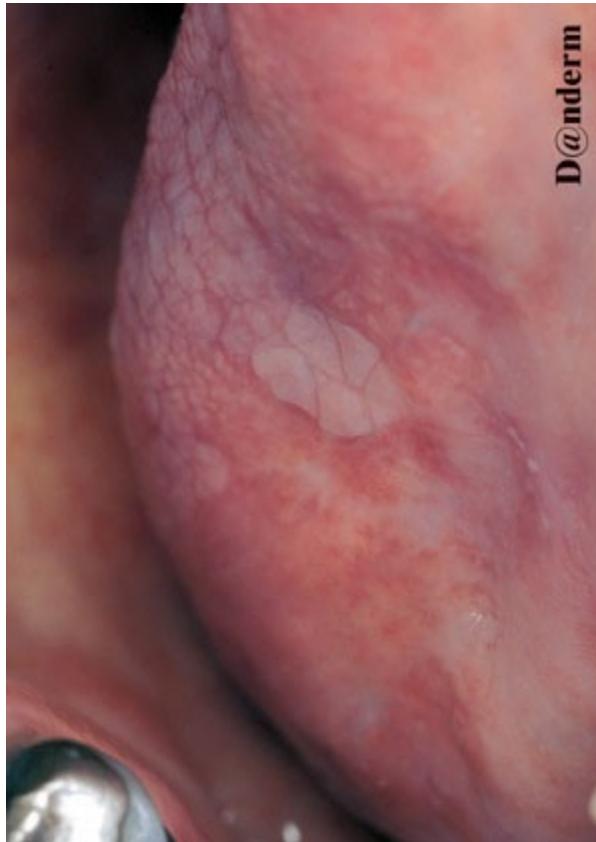
Oral allergic diseases

- Angioneurotic/Quincke edema
- IgE mediated, alternative complement activation pathway
- hereditary abnormal C1-esterase INH
- Contact allergic stomatitis
- Oral food allergy syndrome
- Fixed drug eruption
- Erythema multiforme



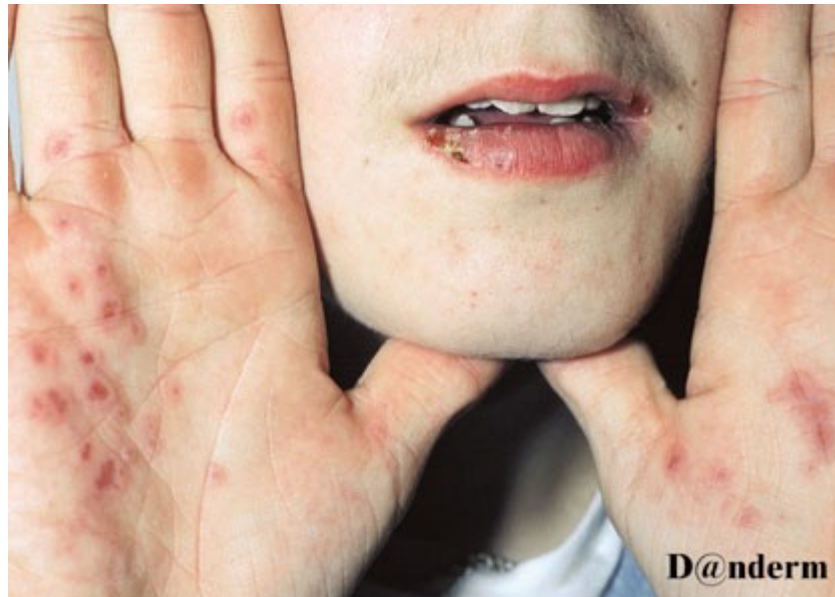Contact allergic stomatitis

Mouthwashes, dental materials, gold etc.)



Erythema exsudativum multiforme

- EM – minor form – delayed hypersensitivity after herpes simplex infections

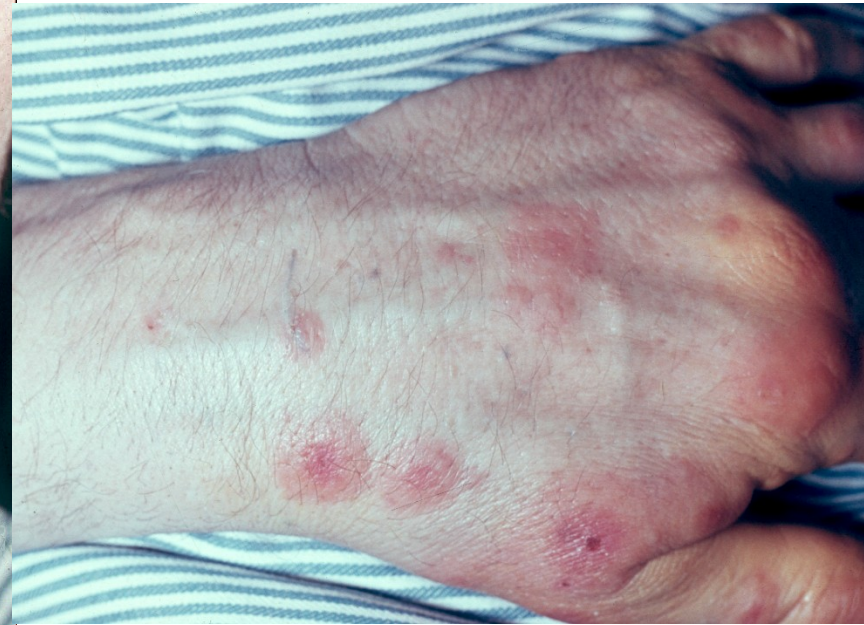
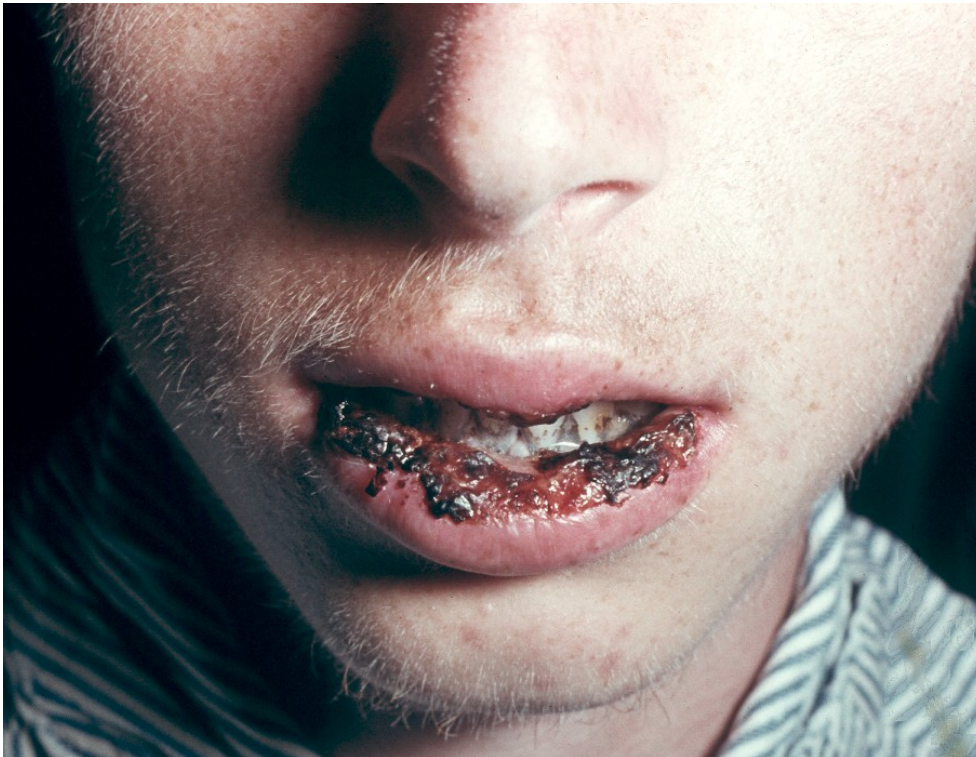
D@nderm

Stevens-Johnson syndrom, TEN (toxic epidermal necrolysis)

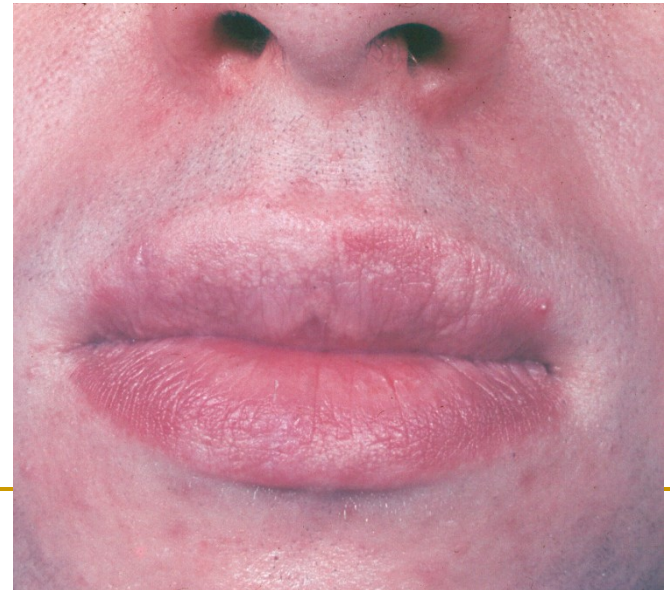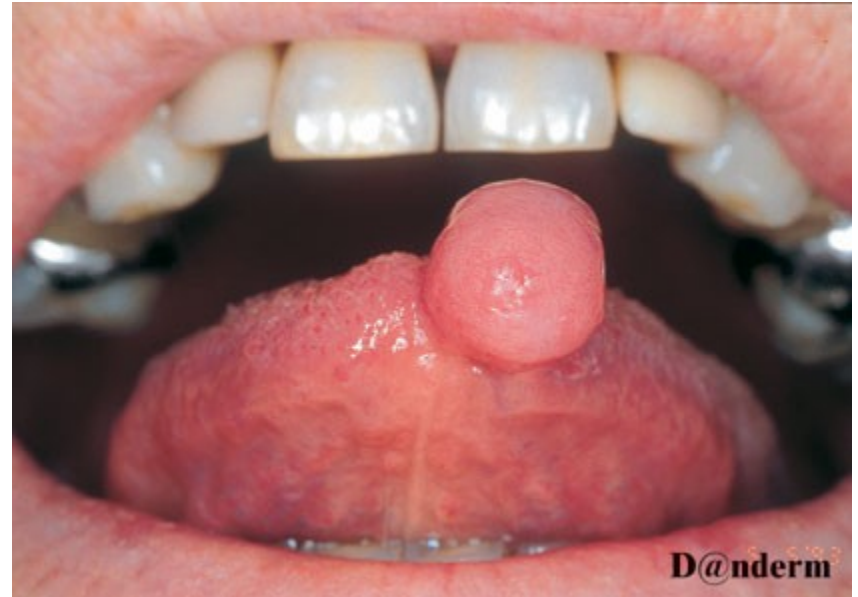
major form of EM with inductions of massive apoptosis of keratinocytes - drug eruption (cotrimoxazol, antiepileptics)

Lethality depends on body surface area affected



Tumors – benign

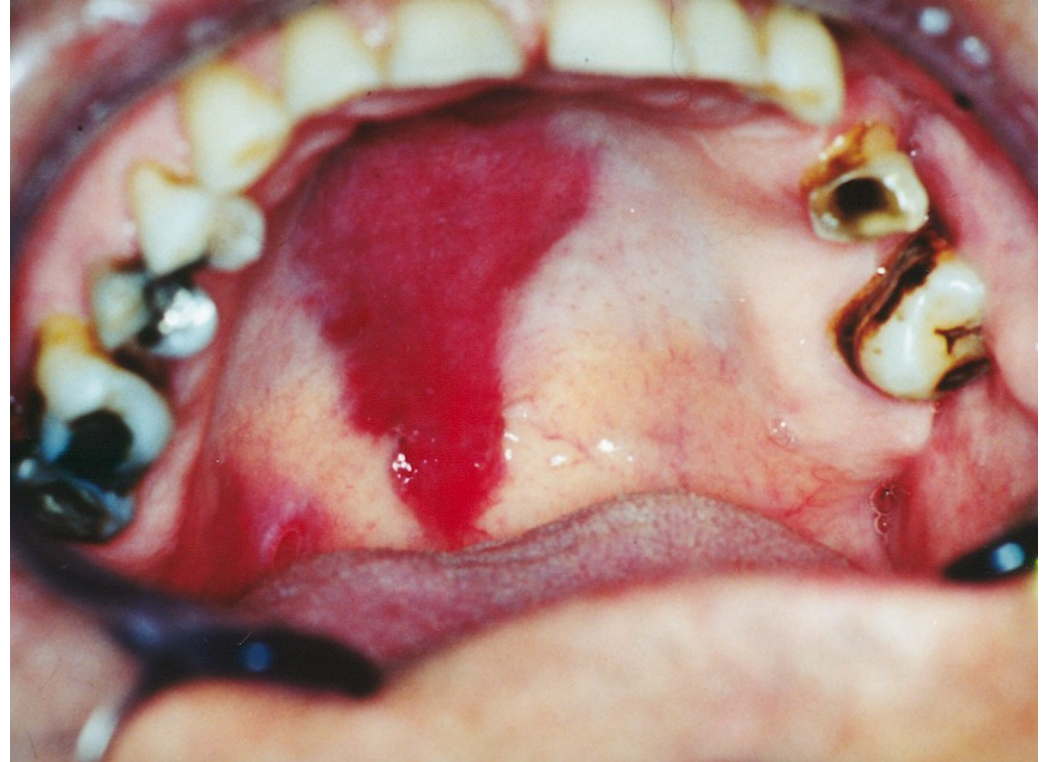
- Papilloma
- Fibroma
- Epulis (fibromatous, ossifying, acanthomatous)
- Pyogenic granuloma (vascular lesion, often in pregnancy)
- Neuroma
- Granular cell tumor
- Pleomorphic adenoma (salivary glands)
- Morsicatio buccarum (reactive hyperplasia)
- White sponge nevus



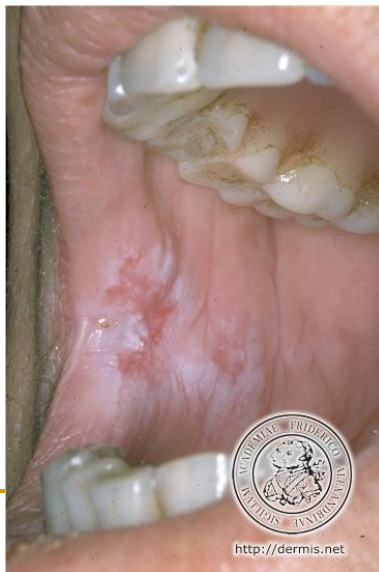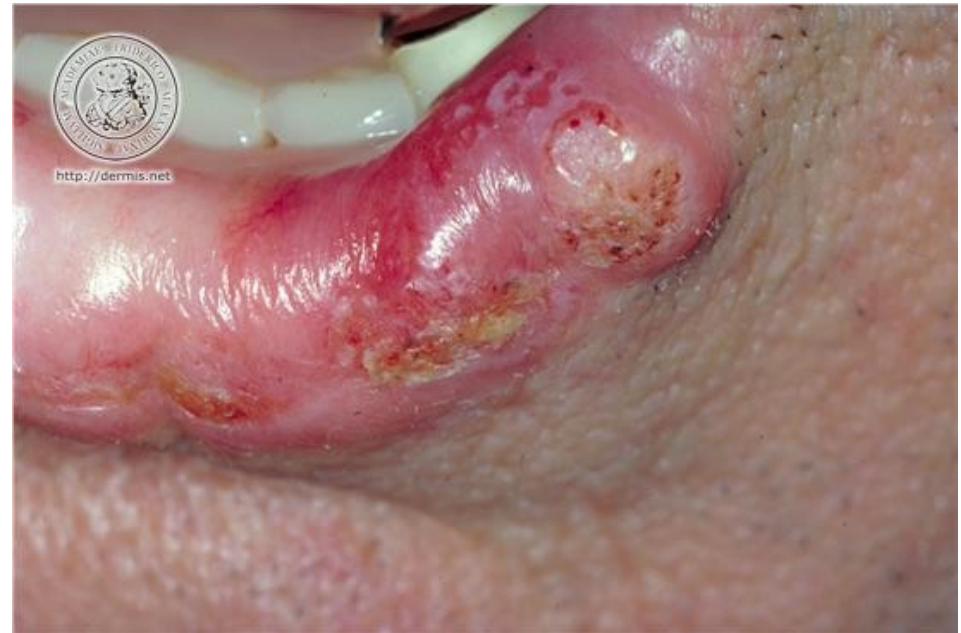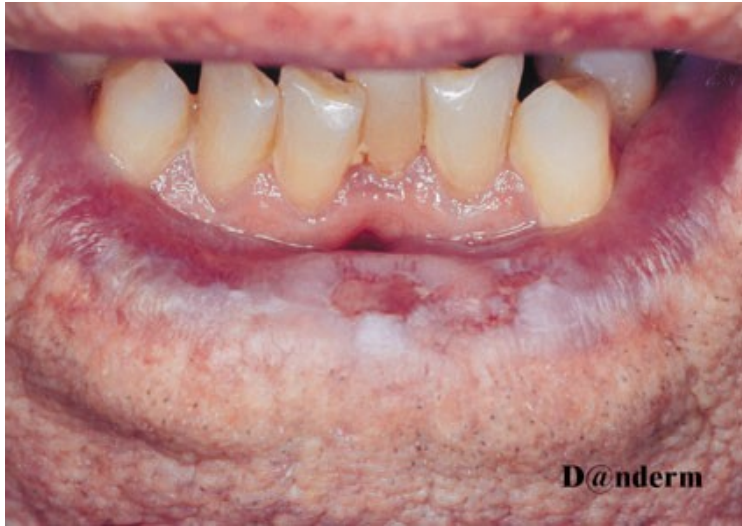Tumors malignant

- Leucoplakia –precancerous
- Leucokeratosis nicotina palati
- Squamous cell carcinoma – most common
- Smokers, hot food, HPV, toxic substances, lichen erosivus
- Melanoma - rare
- Kaposi sarcoma (HHV 8) in HIV!
- Basal cell carcinoma - lips

Kaposi sarcoma



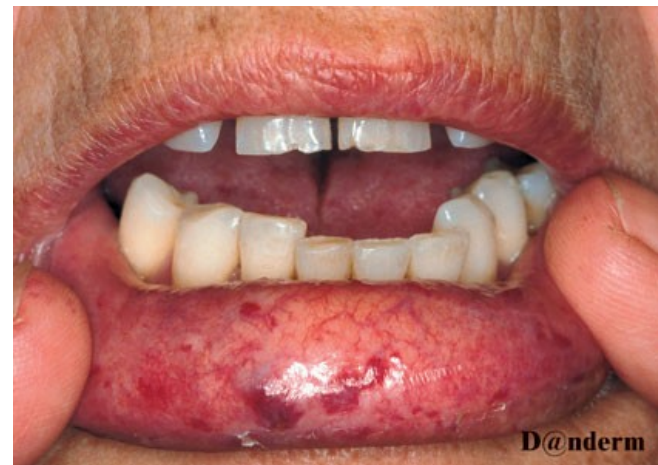Ca spinocellulare



Oral diseases - hereditary

- Epidermolysis bullosa hereditary
- Darier disease
- Osler disease
- Ehlers Danlos syndrome

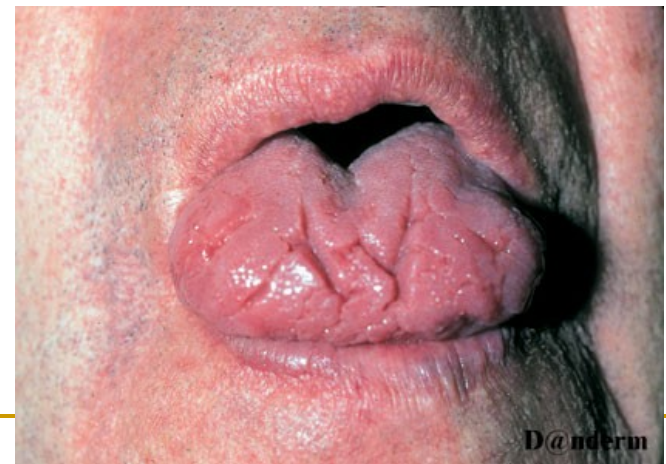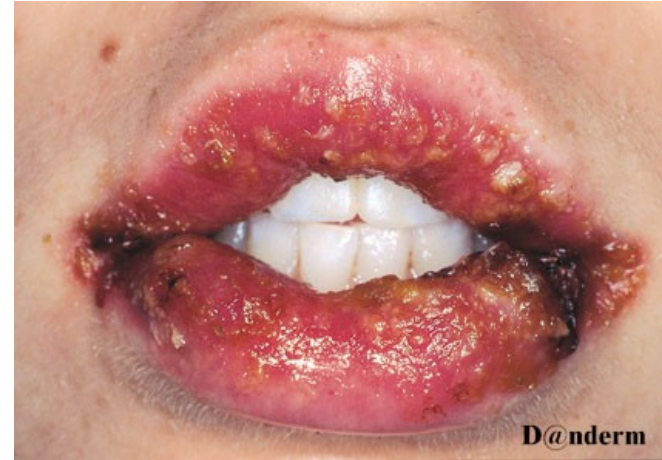Ehlers Danlos syndrome



Osler disease

Cheilitis

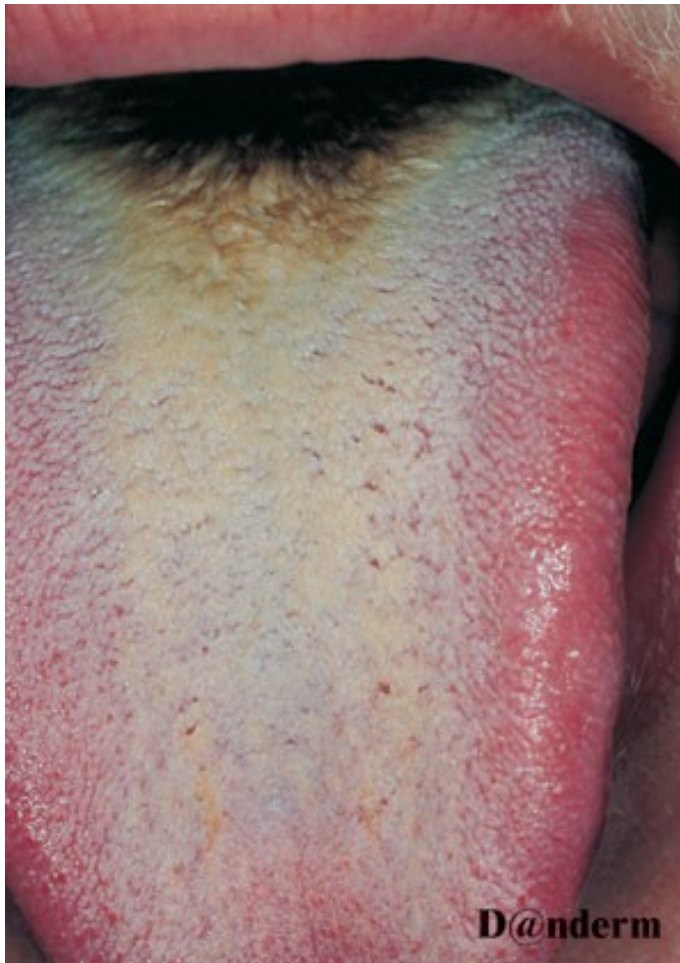- Angular cheilitis – candida, streps, avitaminosis, anemia
- Cheilitis sicca – atopic
- Actinic cheilitis
- Cheilitis granulomatosa – Melkersson Rosenthal syndrom (cheilitis, paresis n.VII., lingua plicata)



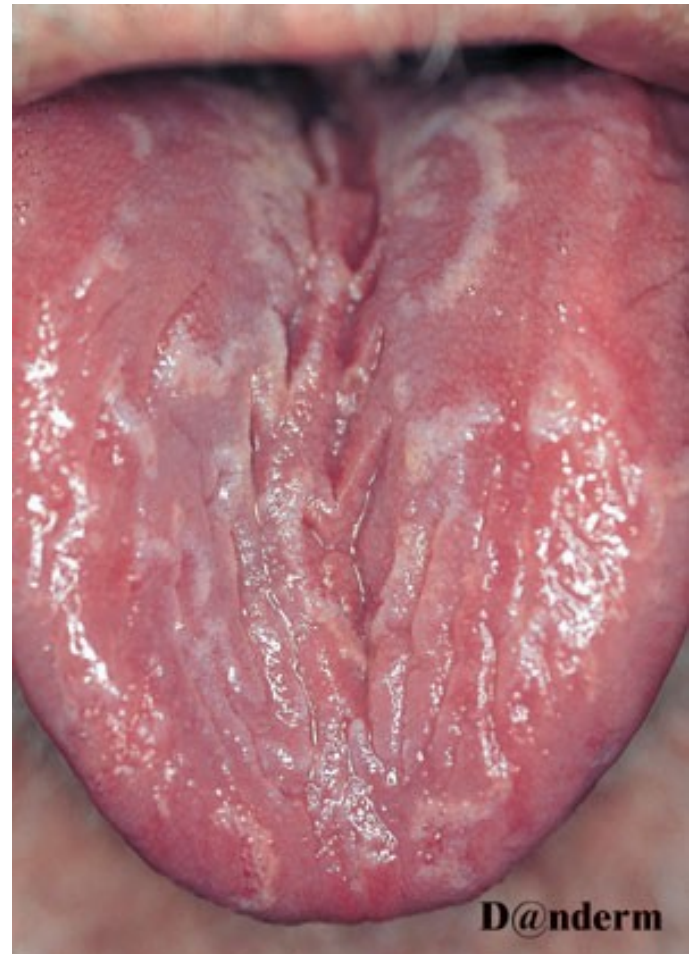
Glossitis

- Lingua plicata
 - Lingua geographica (psoriasis)
 - Lingua villosa nigra
 - Oral hairy leucoplakia (EBV infection in HIV)
 - Moeller Hunter glossitis – pernicious anemia
 - Iron deficiency anemia
-

Lingua villosa nigra

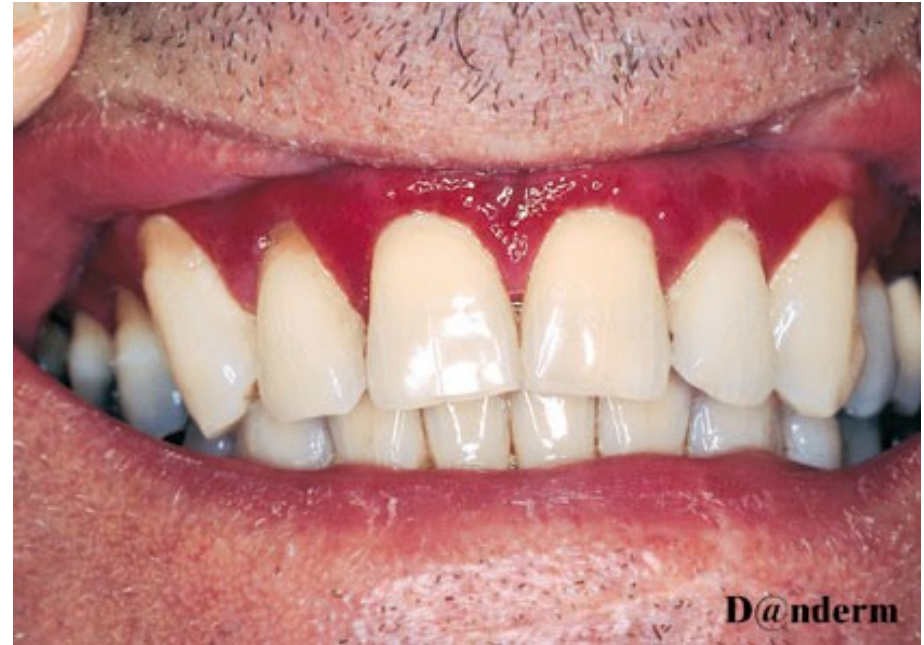

Lingua geographica



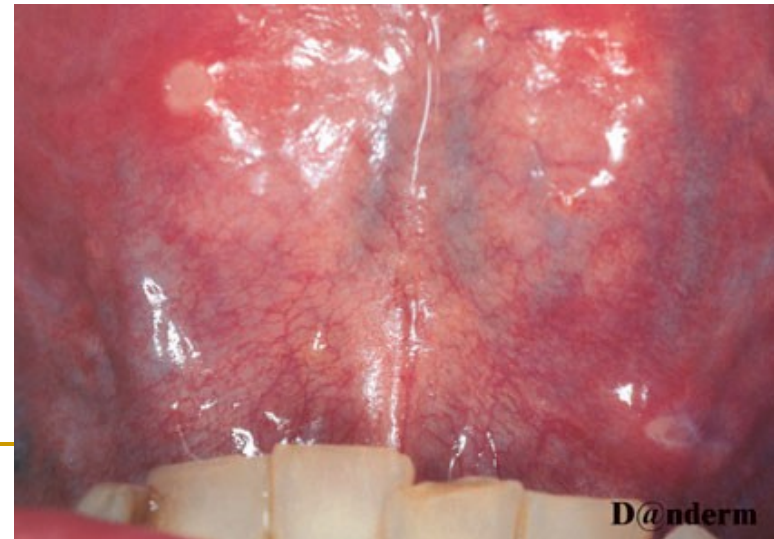
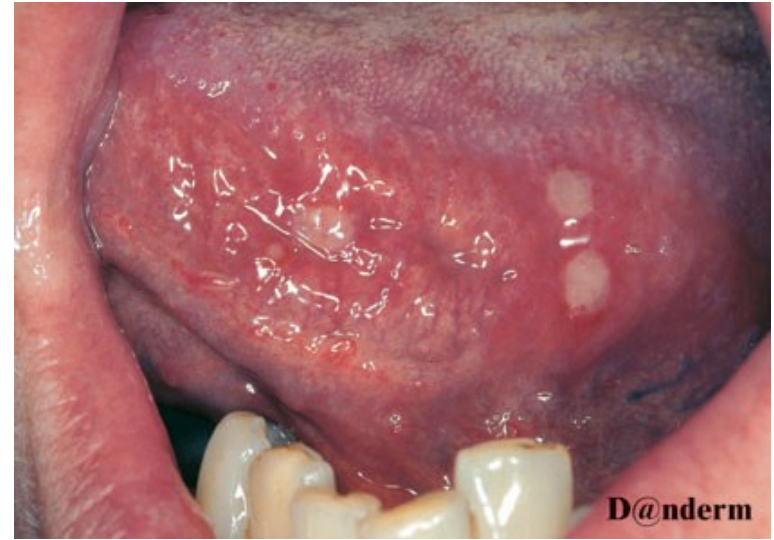
Gingivitis

- Gingivitis hyperplastic
 - leukemia
 - pregnancy - epulis
 - drugs (fenytoin, cyclosporine)



Stomatitis a gingivitis

- Sjögren syndrome – sicca syndrome
- Gingivostomatitis herpetica
- Aphthous stomatitis – solitary – trauma,
- Recurrent aphthous ulcers – allergy, gastritis, malabsorption, IBD, anemia, neutropenia, HIV



Morbus Behcet - inflammatory disorder

Aphthous ulcers - mouth, genitals, iritis, uveitis, conjunctivitis, vasculitis, pathergy
HLA B27, HLA B51

