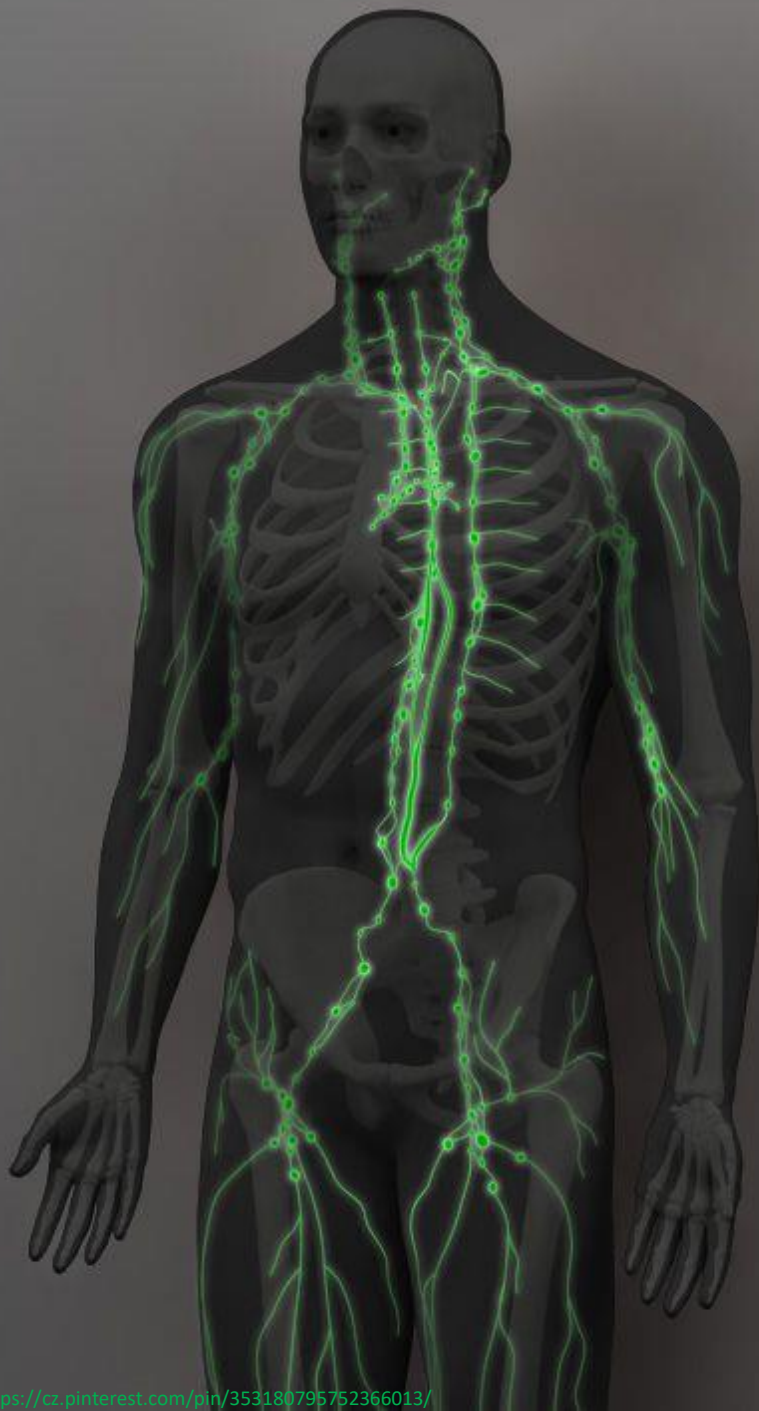

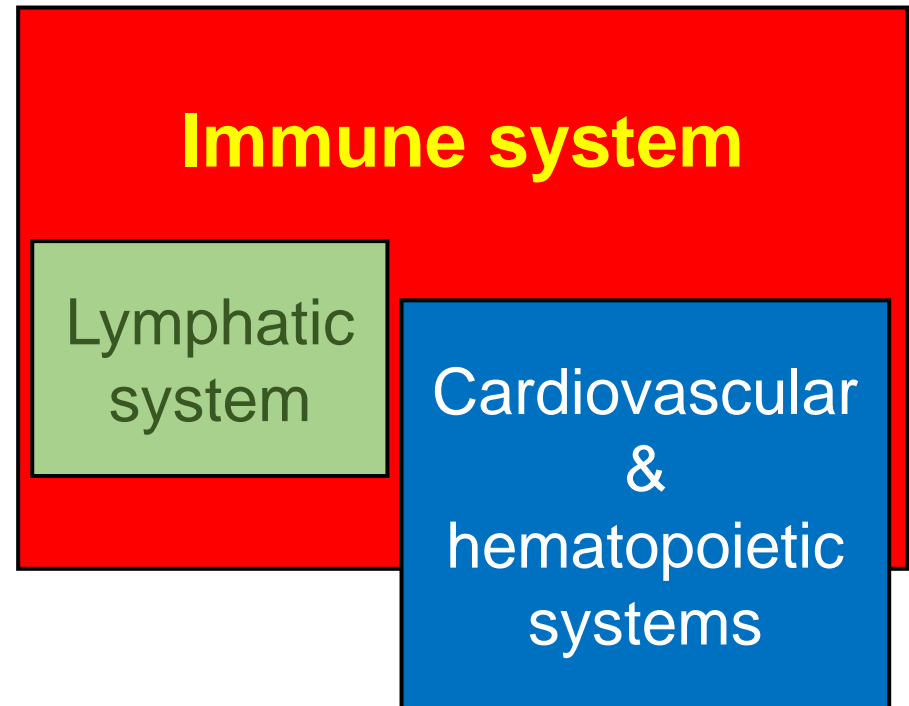
LYMPHATIC SYSTEM

Petr Vaňhara

MUNI Department
of Histology
and Embryology
MED

LECTURE CONTENT

- Principles of immune response
 - Innate and acquired immunity
 - Humoral and cellular immunity
- Structures essential for development and activation of immune cells
 - Lymphatic circuitry
 - Lymphatic follicles
 - Lymph nodes
 - Spleen
 - Thymus
 - MALT
- Development of lymphatic system



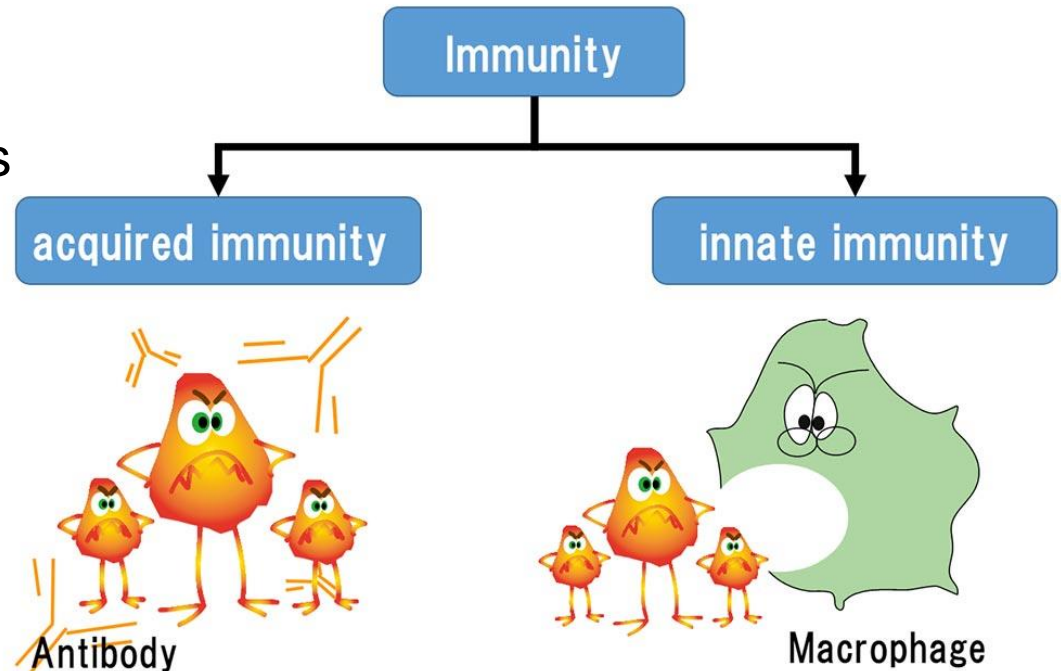
IMMUNE SYSTEM

Immunity = self defense

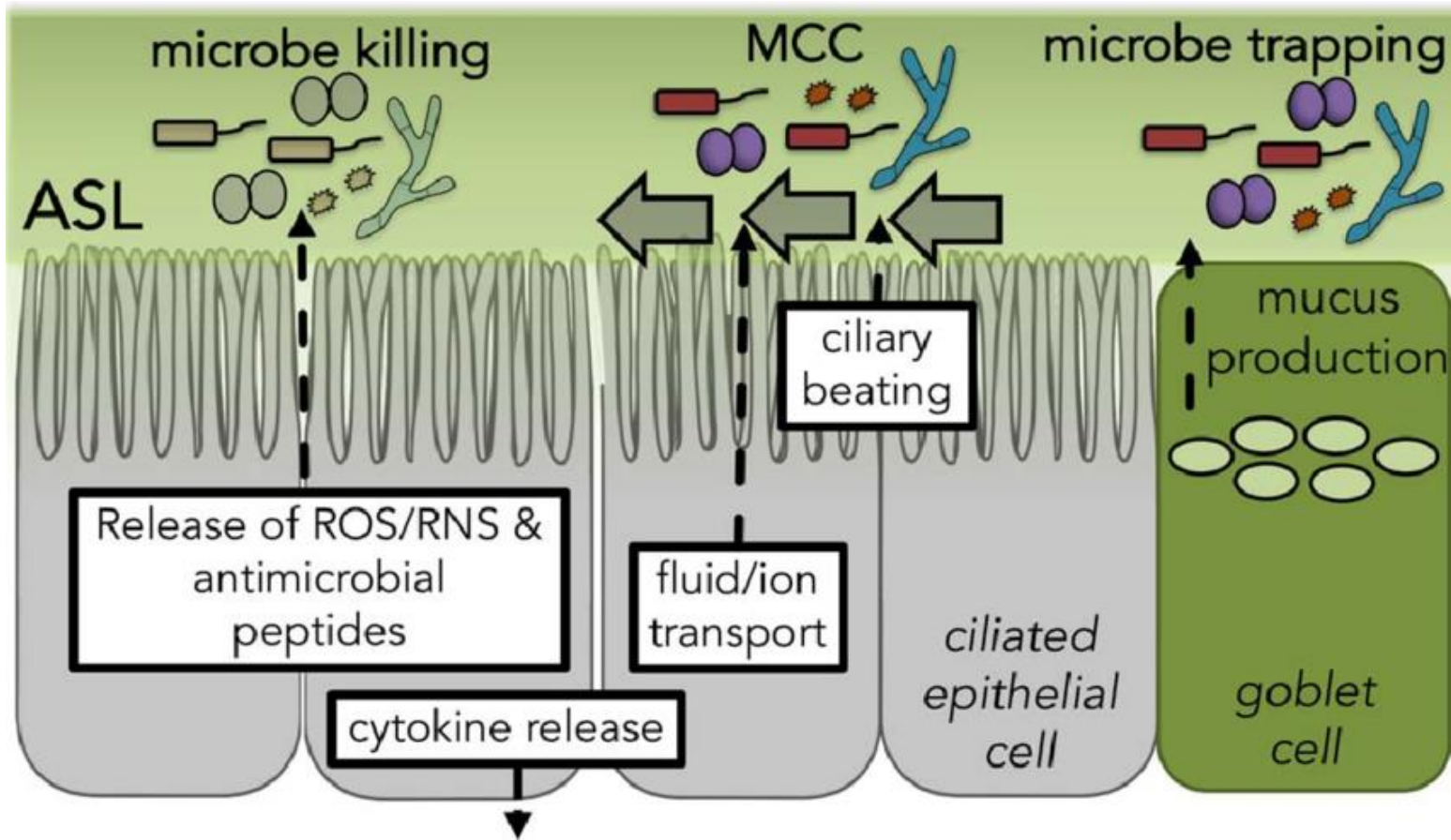
- **Epithelial:** epithelial barriers equipped with antimicrobial substances
- **Innate:** complement, macrophages and neutrophils, natural killers
- **Acquired:** T and B lymphocytes

Clinical relevance

- Autoimmune disorders
- Immunodeficiency

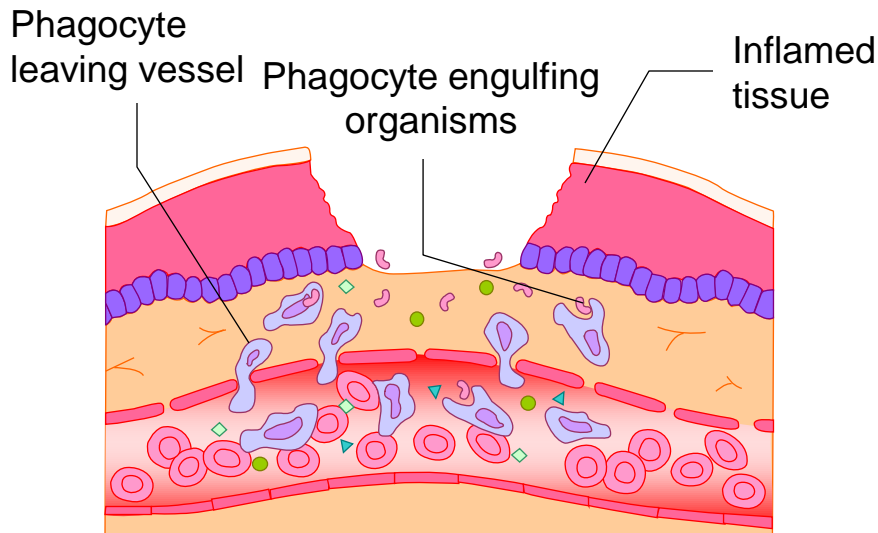
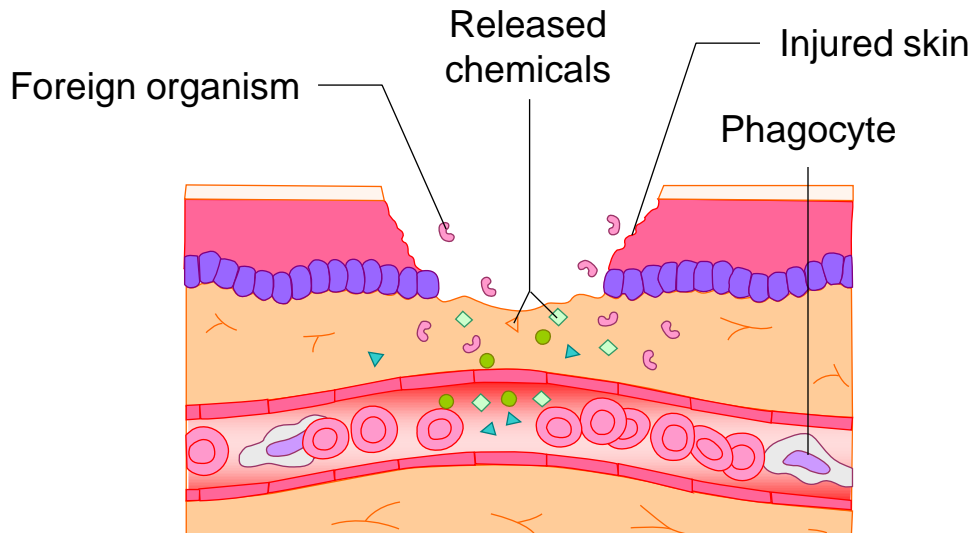


EPITHELIAL IMMUNE RESPONSE



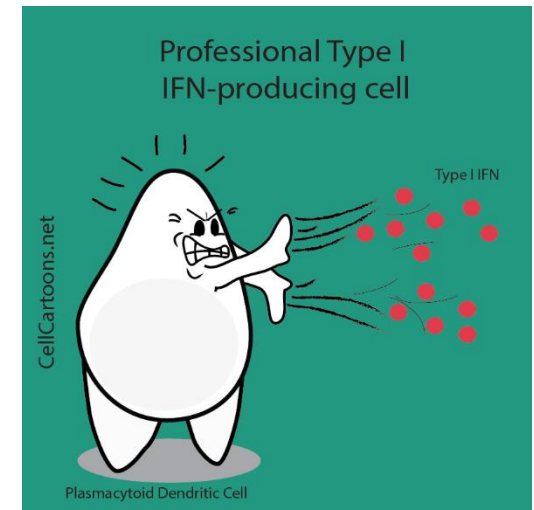
EPITHELIUM OF RESPIRATORY PASSAGES

EPITHELIAL INFLAMMATORY RESPONSE




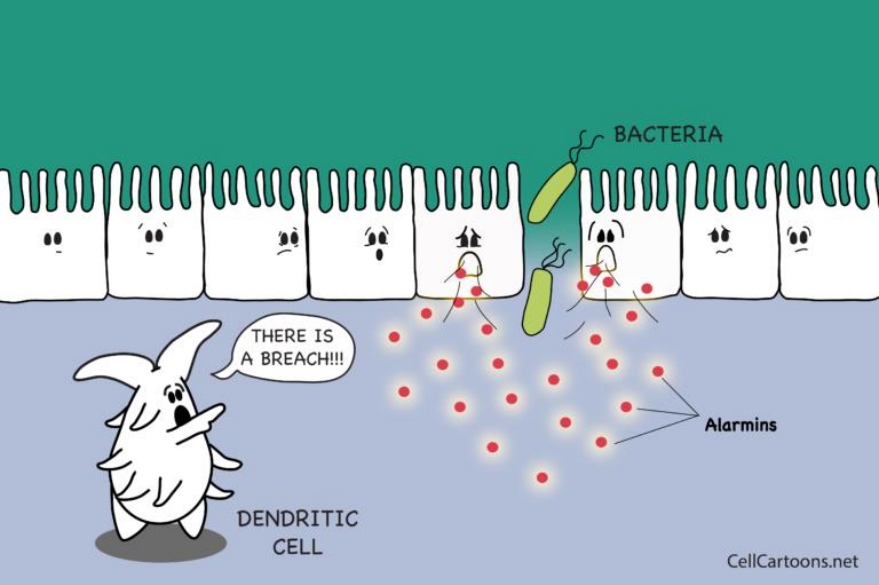
- Chemotaxis and extravasation of leukocytes, mostly neutrophils, monocytes and dendritic cells to the site of inflammation
- Pro-inflammatory cytokines
 - interleukins (e.g. IL-1, IL-8)
 - TNF α , TGF β
 - interferons
- Other signaling molecules
 - prostaglandins
 - GM-CSF, M-CSF

and many others

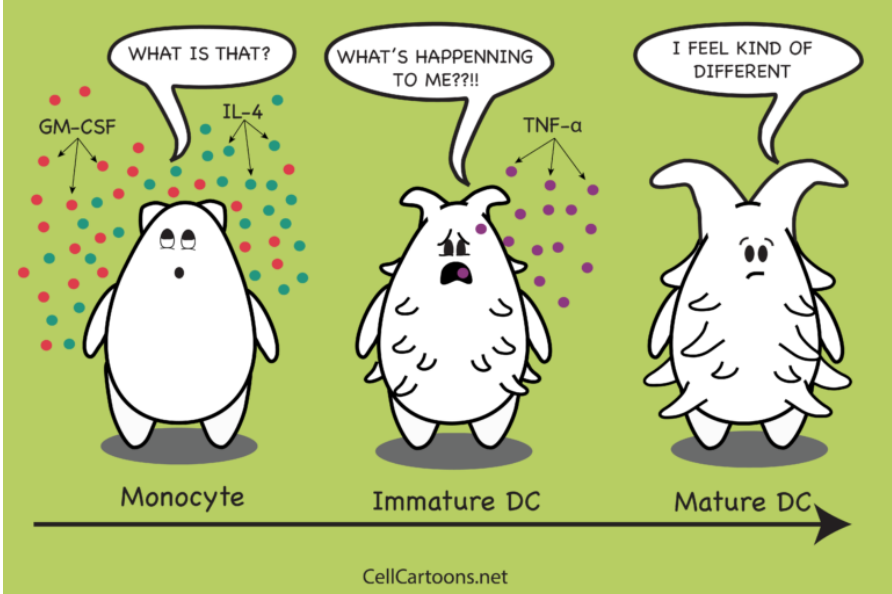


EPITHELIAL IMMUNE RESPONSE

Damage-associated molecular patterns (DAMPs)



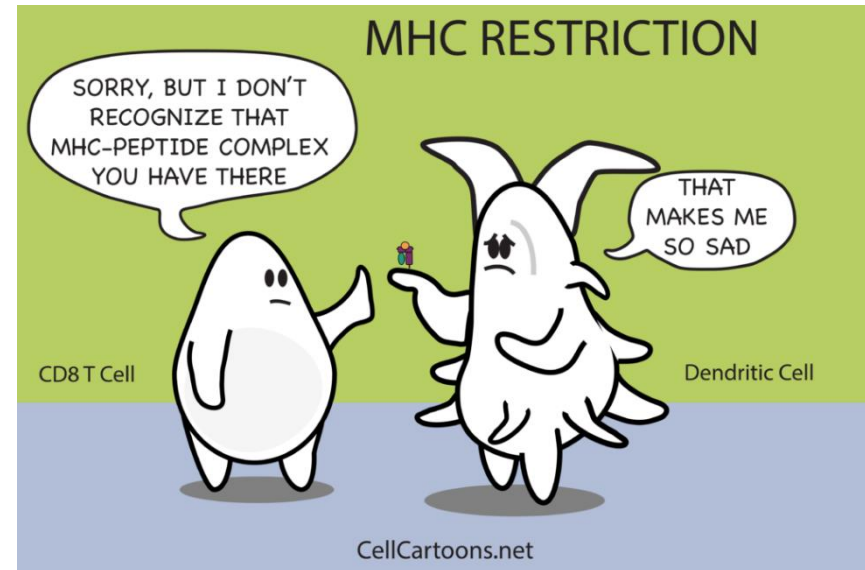
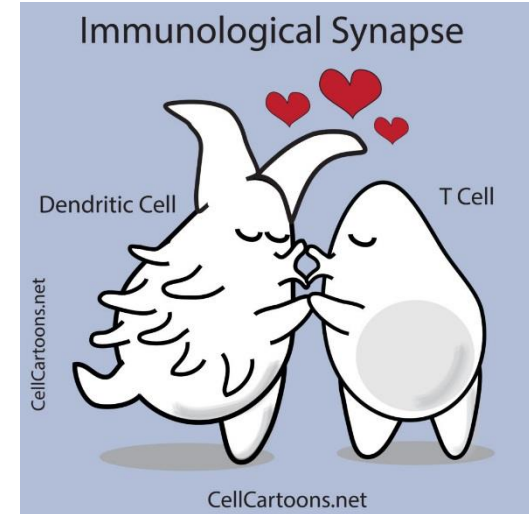
Activation of immune response



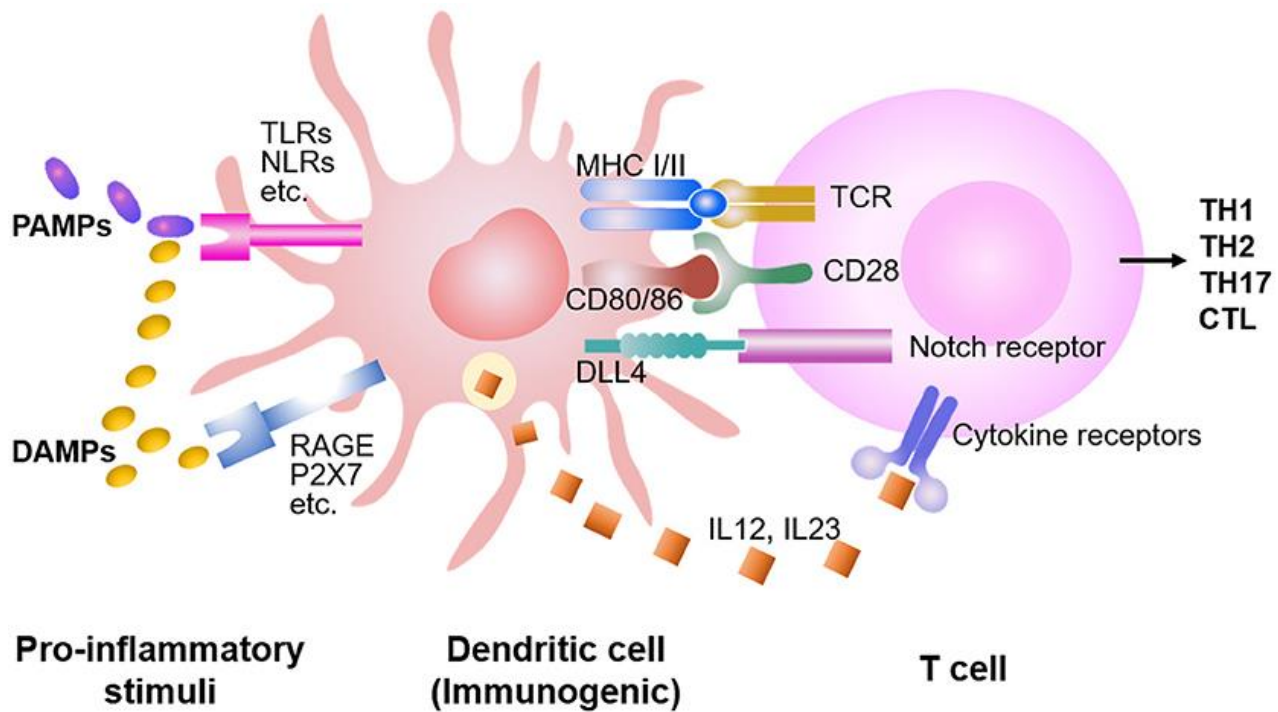
DENDRITIC CELLS

- „professional“ antigen presentation = activation of immune cells with high efficiency
- antigen processing – MHC II
- cytokine production
- component of monocyte-macrophage system
- lymphatic organs, epithelia, connective tissue

TCR recognizing antigen presented in **MHC complex** is essential for activation of **T-cells**



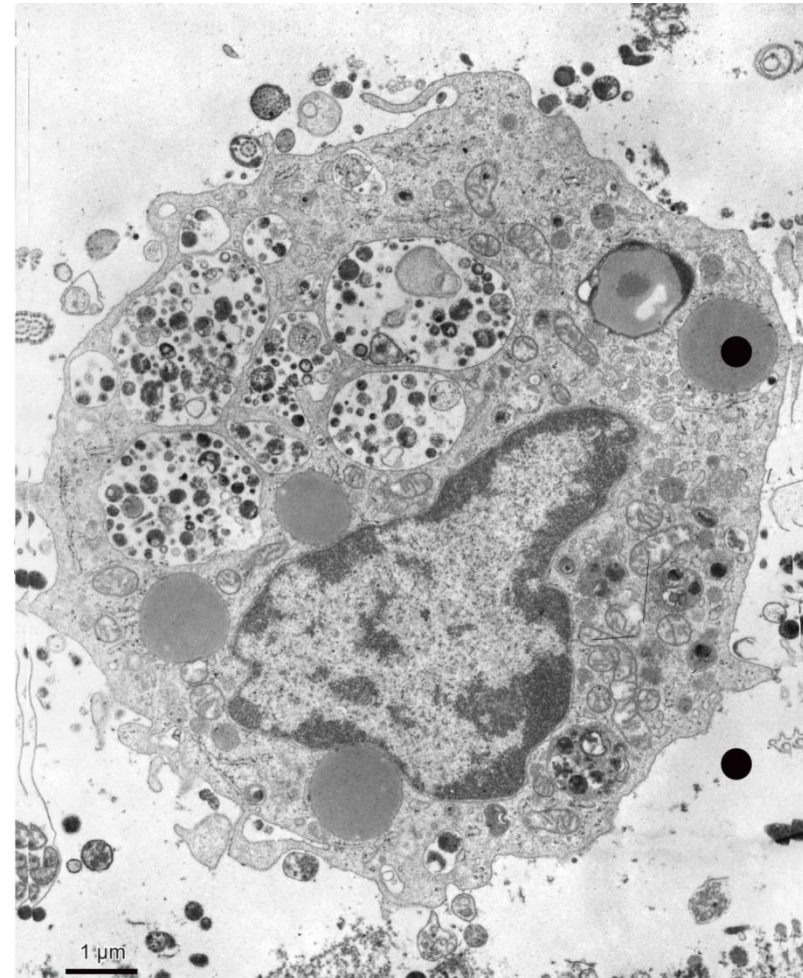
DENDRITIC CELLS



MONOCYTE-MACROPHAGE SYSTEM

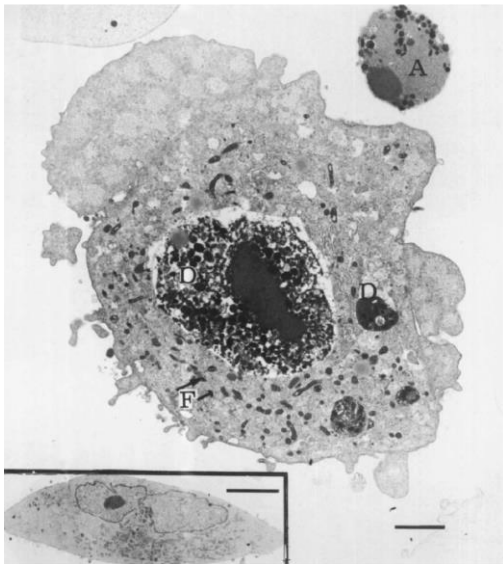
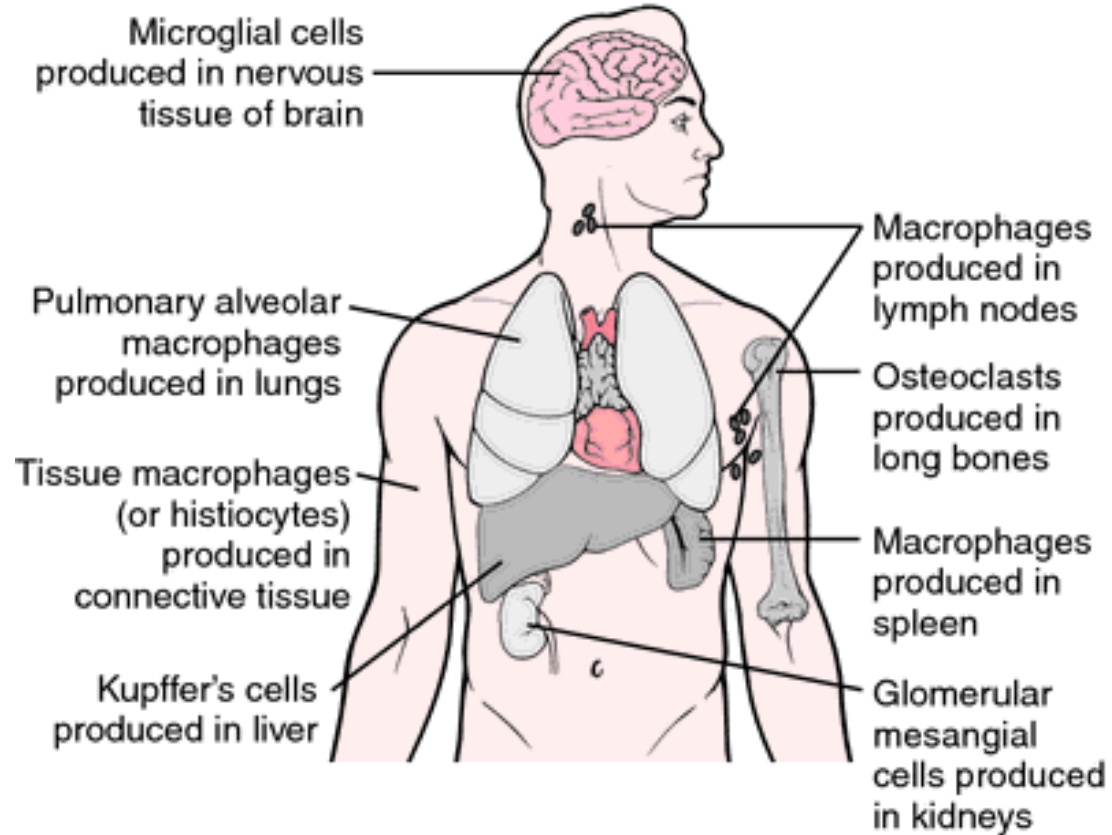
- mononuclear phagocytic system, reticuloendothelial system
- originate in bone marrow: monoblasts → monocytes
- after extravasation → **macrophages**
- irregular surface (hallmark of phagocytosis)
- numerous lysosomes
- Golgi apparatus and rER
- long-living cells (months)
- phagocytosis (large particles)

- Dendritic cells share common progenitor with macrophages




MONOCYTE-MACROPHAGE SYSTEM

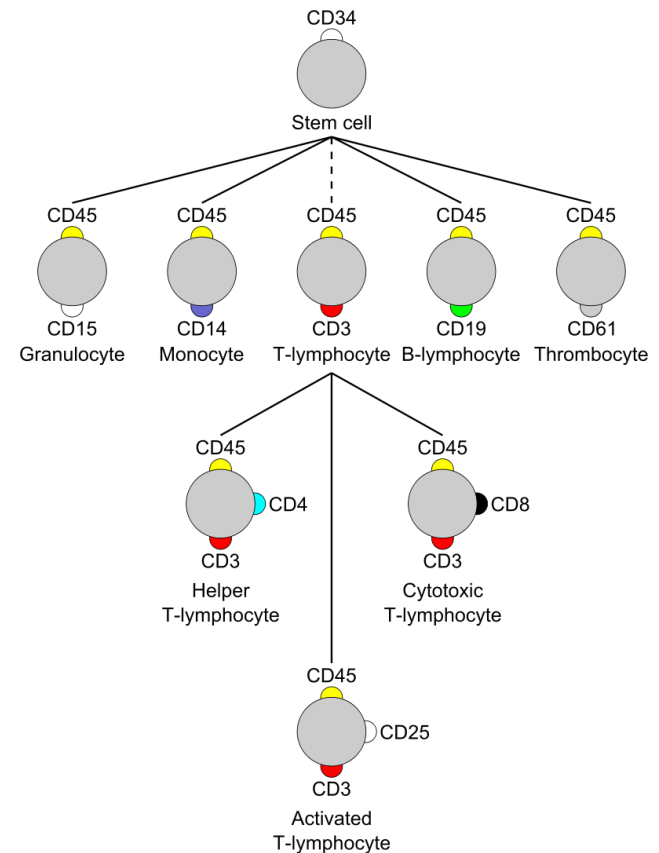
- monocytes (circulation)
- macrophages (histiocytes) of c.t.
- Kupffer cells (liver)
- osteoclasts (bones)
- microglia (CNS)
- alveolar macrophages (lungs)
- macrophages and dendritic cells (lymphatic organs, epithelia, c.t.)
- Langerhans cells (skin)
- mesangial cells (kidney)



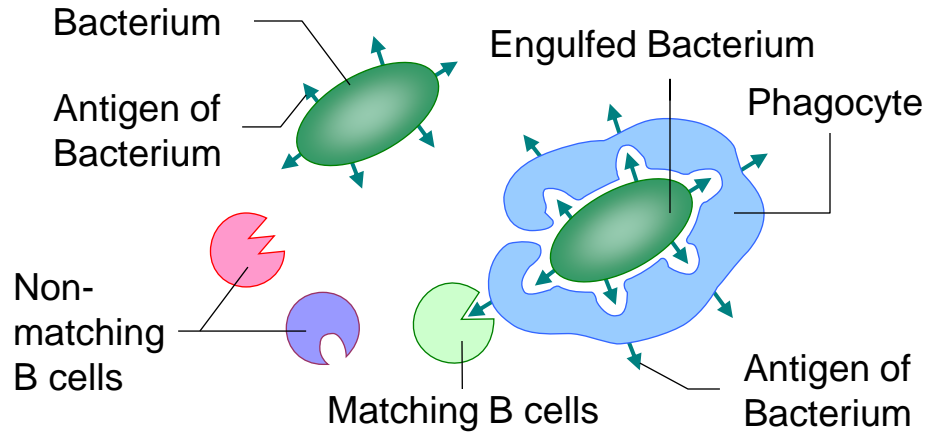
LYMPHOCYTES



- “Clusters of differentiation”, “CD”
- Surface molecules constituting immunophenotype
- Molecular signaling regulating immune response
- Clinically relevant in diagnostics and therapy

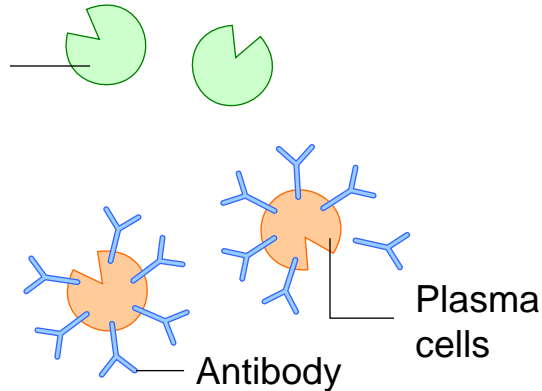


ANTIBODY (HUMORAL) RESPONSE

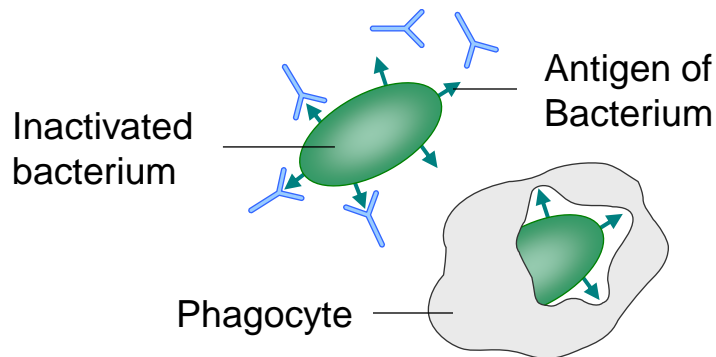


1. Antigen presentation and activation of B-cells

Memory B cell
Second exposure to the same bacteria activates this cell to rapidly produce plasma cells

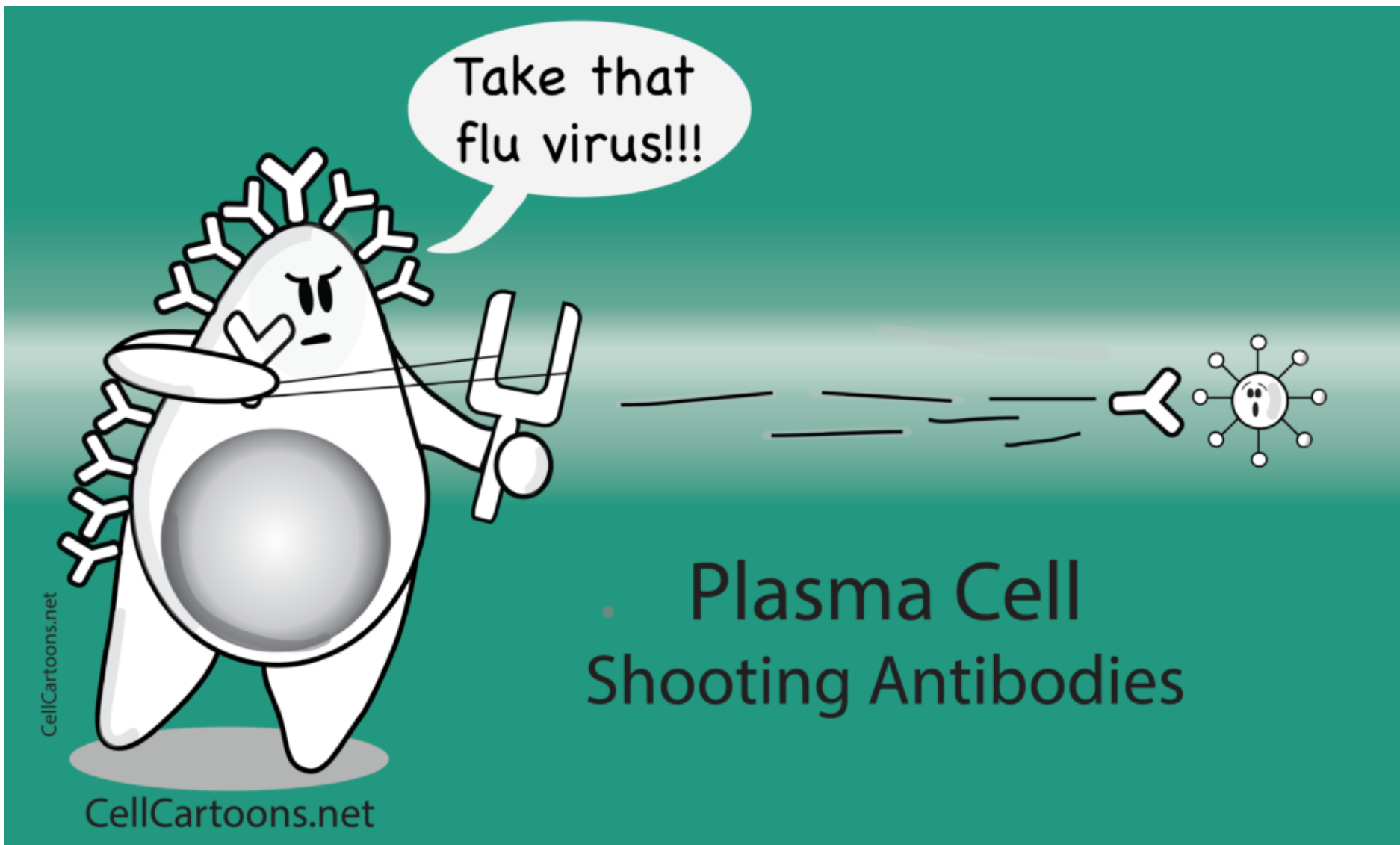


2. Activated B-cells proliferate and expand



3. Most of B-cells differentiate to plasma cells, some will convert to memory cells

ANTIBODY (HUMORAL) RESPONSE



Take that flu virus!!!

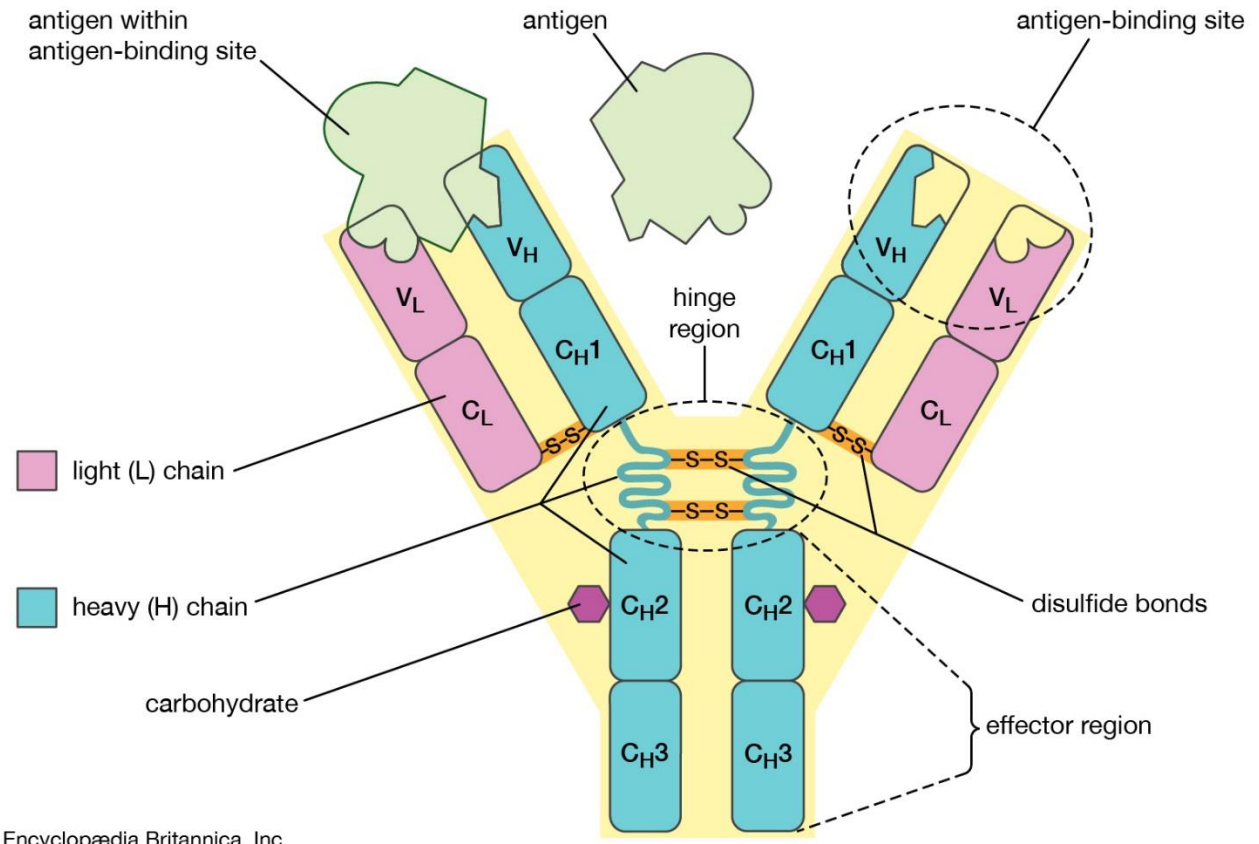
Plasma Cell Shooting Antibodies

CellCartoons.net

CellCartoons.net

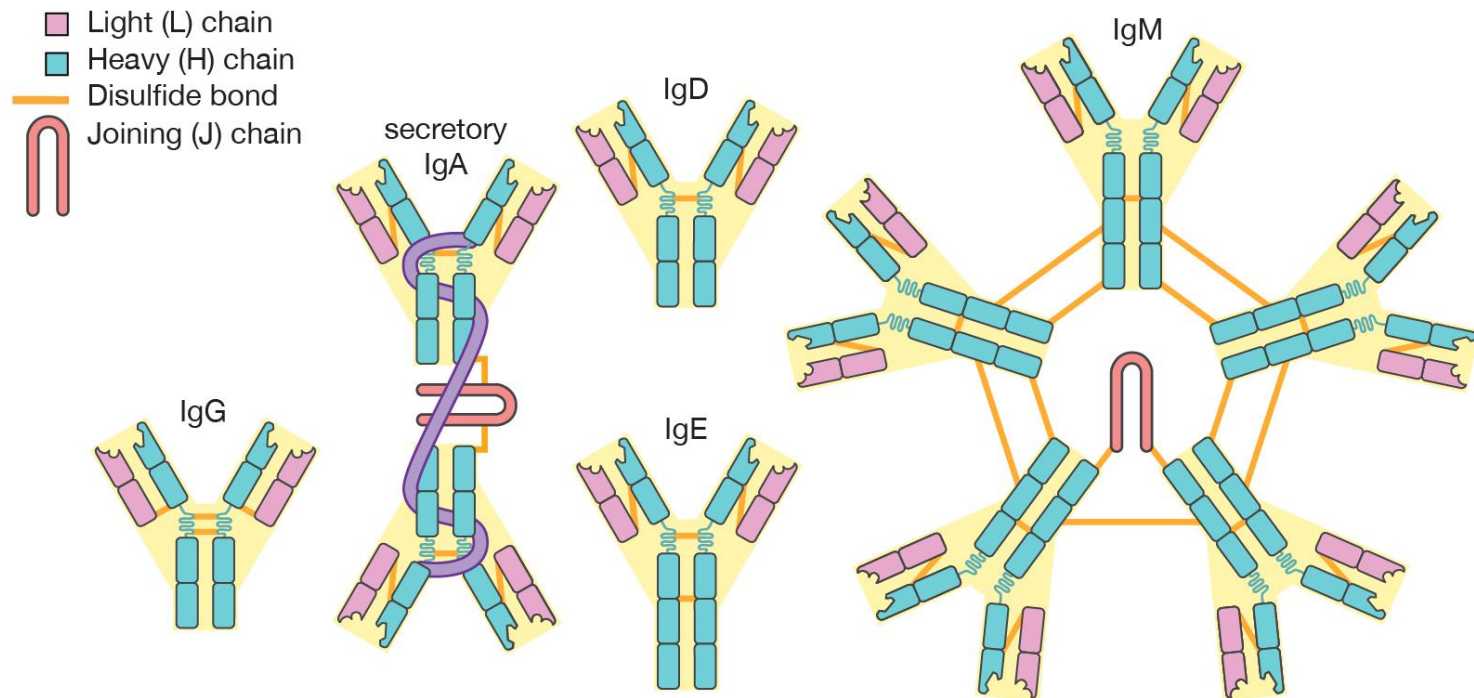
ANTIBODIES

- Immunoglobulins
- Large proteins with defined structure capable of binding antigens
- Variable and constant regions
- Fc region bound by Fc receptor on immune cells

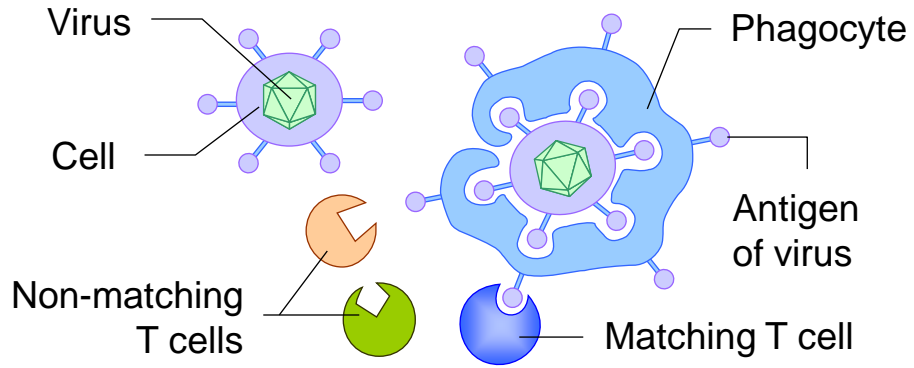


ANTIBODIES

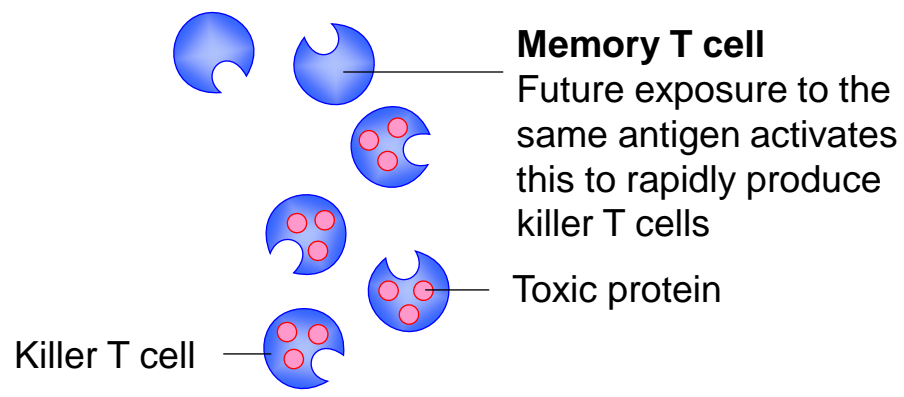
- Five principal classes
 - IgG: most common (>75%), soluble, stable
 - IgA: in exocrine secretions, mucosa
 - IgM: natural immunity, activator of complement
 - IgE: activator of mast cells
 - IgD: B-cells activators



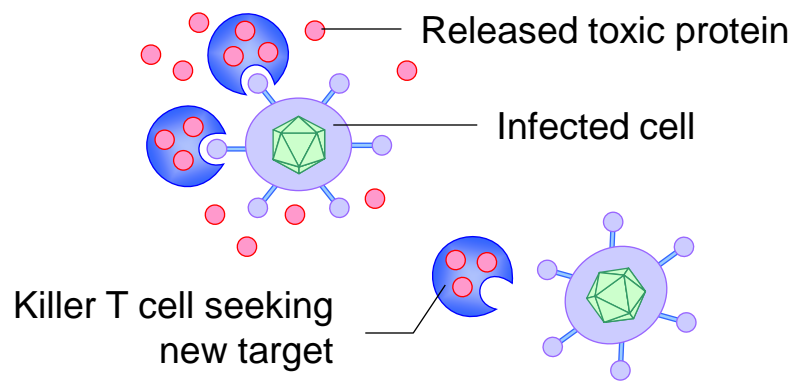
CELLULAR RESPONSE



1. Antigen presentation and activation of T-cells




2. T-cells differentiate to cytotoxic Tc cells, memory t cells or regulatory cells




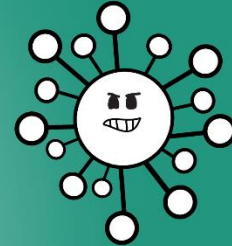
3. Cytotoxic Tc eliminate abnormal cells

CELLULAR RESPONSE



Oh nooo!
I'm shedding virus particles!
Does that mean I'm infected?
What will happen to me?


VIRAL PARTICLES



INFECTED CELL

CellCartoons.net

I'M READY TO FIND AND
KILL THOSE INFECTED CELLS!



CD8 Cytotoxic T Cell
a.k.a 'Killer T cell'

CellCartoons.net

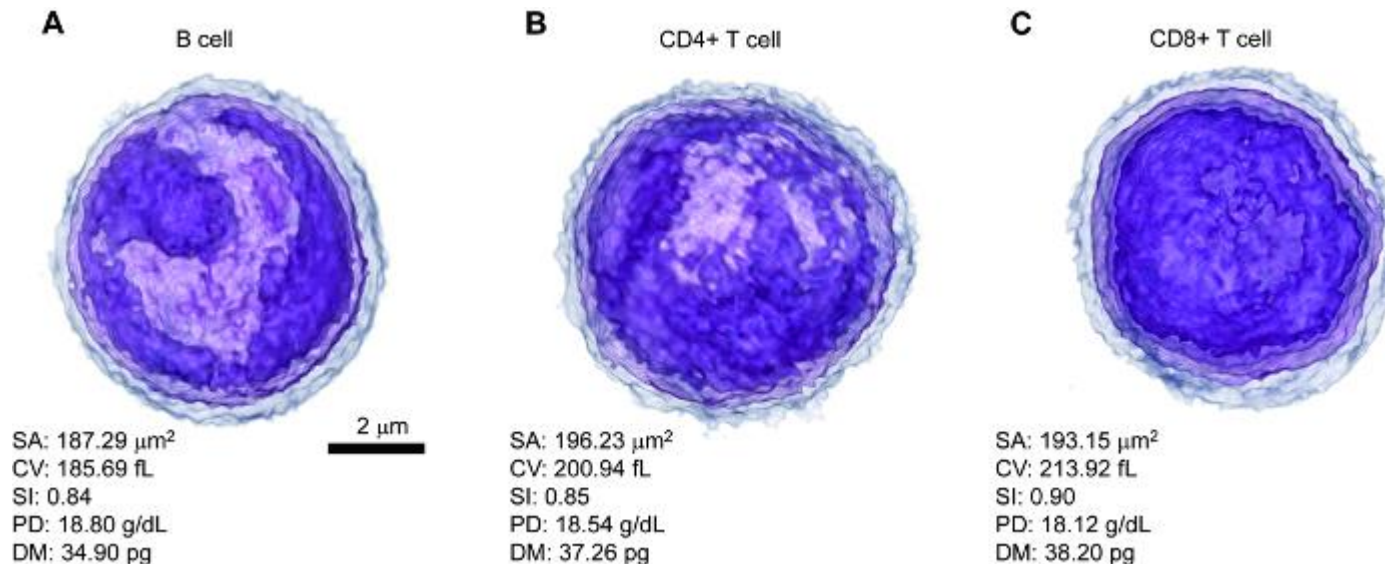
B- AND T- LYMPHOCYTES IN HUMAN BODY

T-lymphocytes

- paracortical zone of lymph nodes
- white pulp of spleen (periarteriolar sheath)
- interfollicular regions in other lymphatic organs (tonsils)

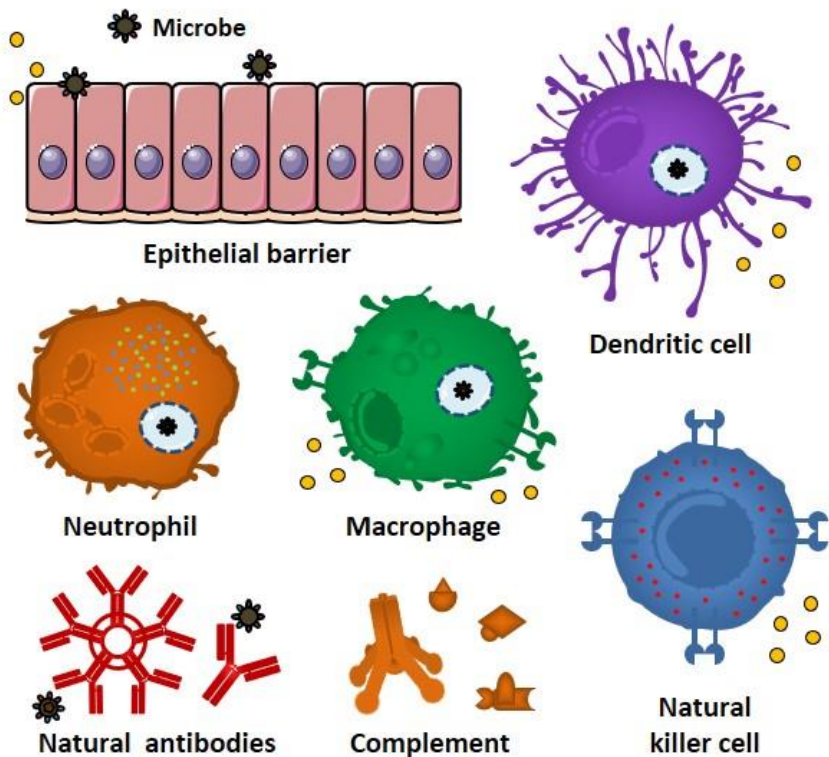
B-lymphocytes

- lymphatic follicles and medullary cords of lymph nodes
- Spleen follicles and marginal zone of white pulp
- lymphatic follicles in other organs

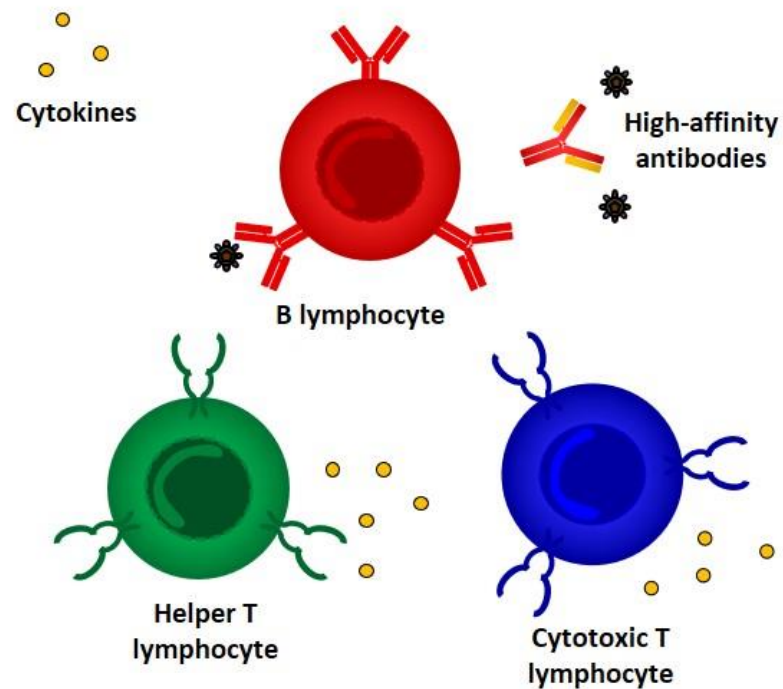


INNATE AND ACQUIRED IMMUNITY

Innate Immunity



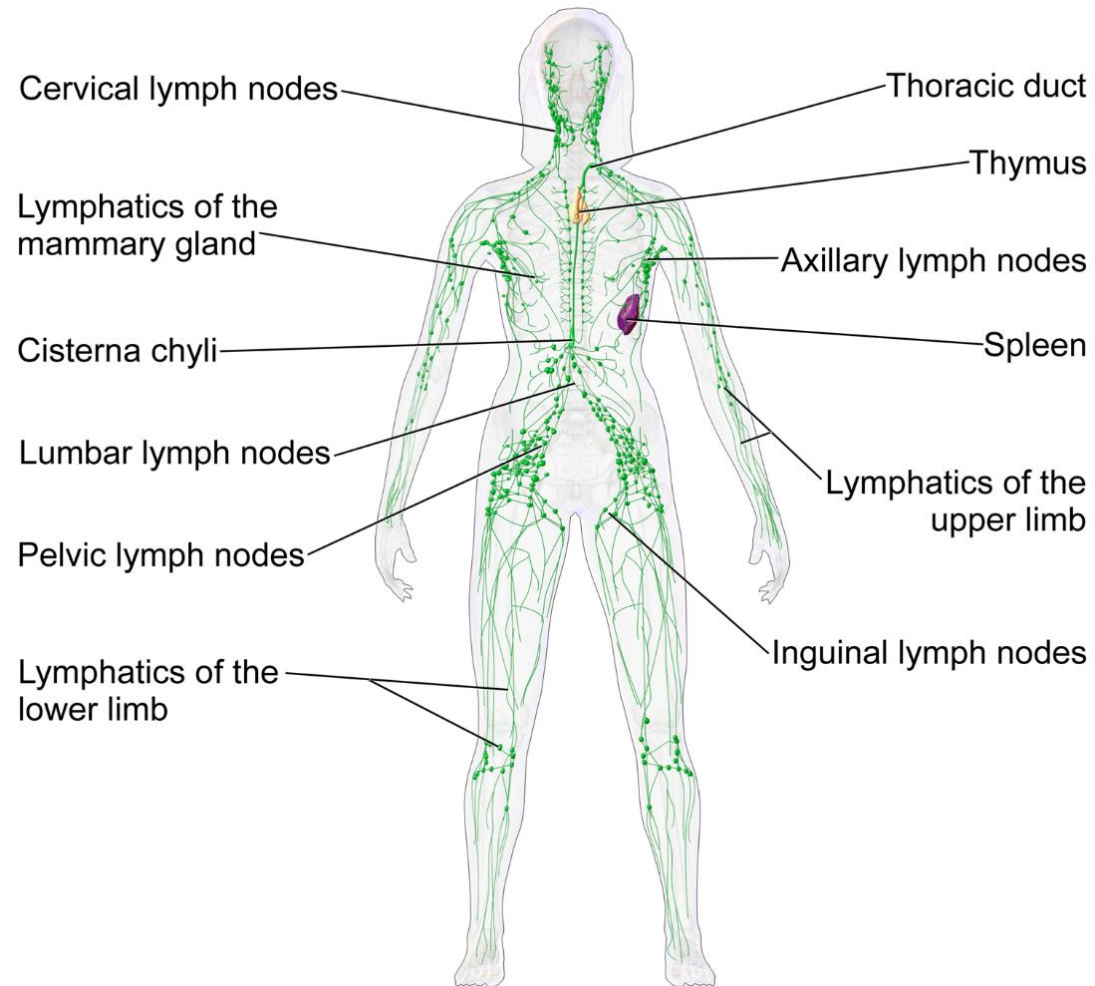
Adaptive Immunity



ACQUIRED IMMUNITY

Histology:

- Leukocytes
 - Lymphocytes
 - Antigen presenting cells
- Lymphatic organs



Development of lymphocytes and APC:

Primary lymphatic organs

- bone marrow
- thymus

Secondary lymphatic organs

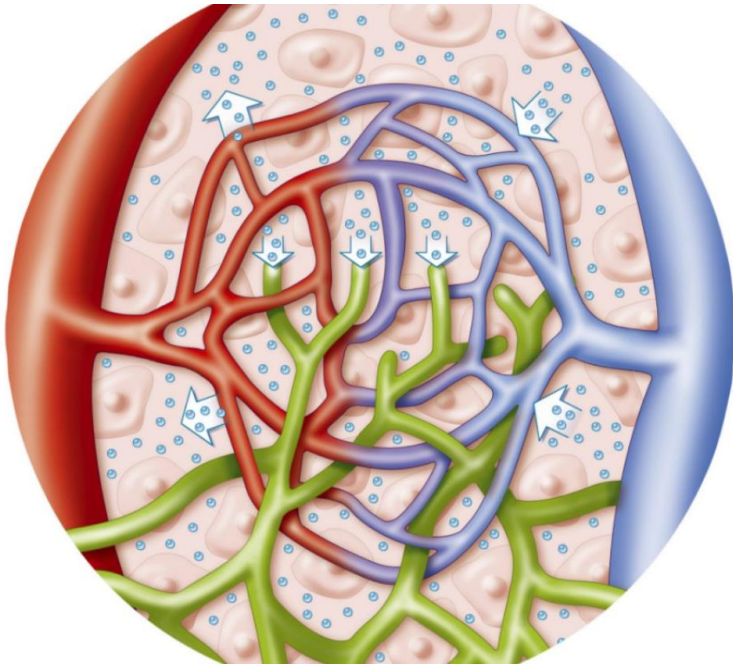
- lymph nodes
- spleen
- MALT including tonsils and appendix

Tissues

- blood
- lymph
- epithelia
- connective tissues

LYMPHATIC CIRCULATION

Lymph vessels



Function

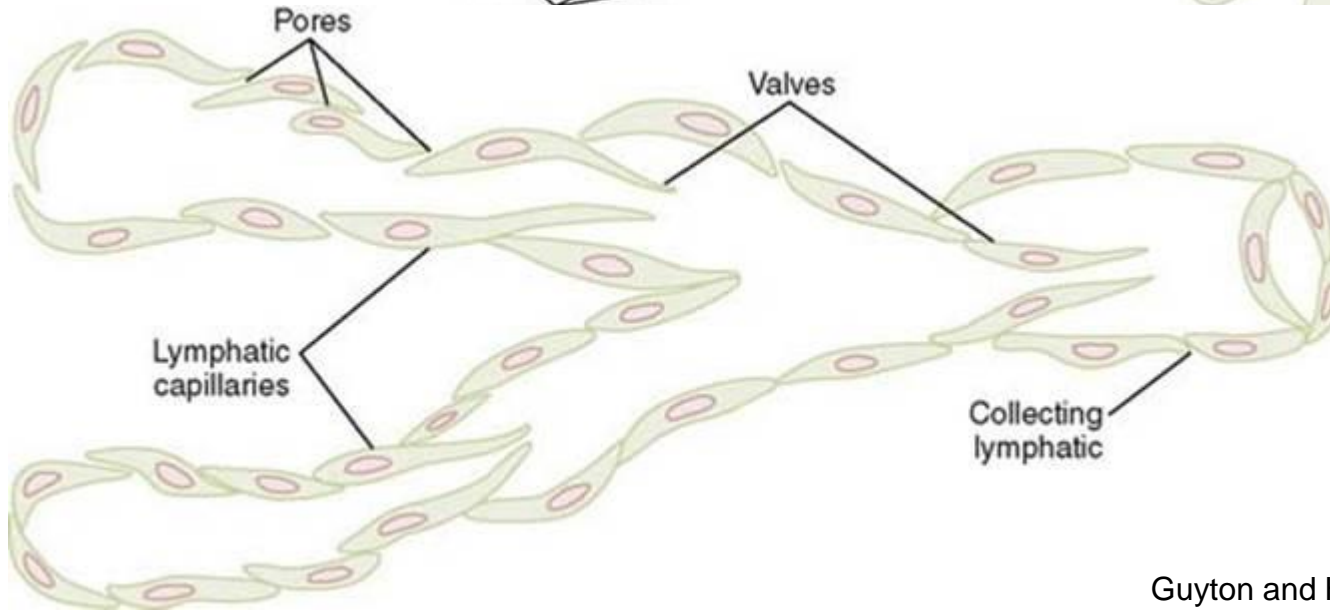
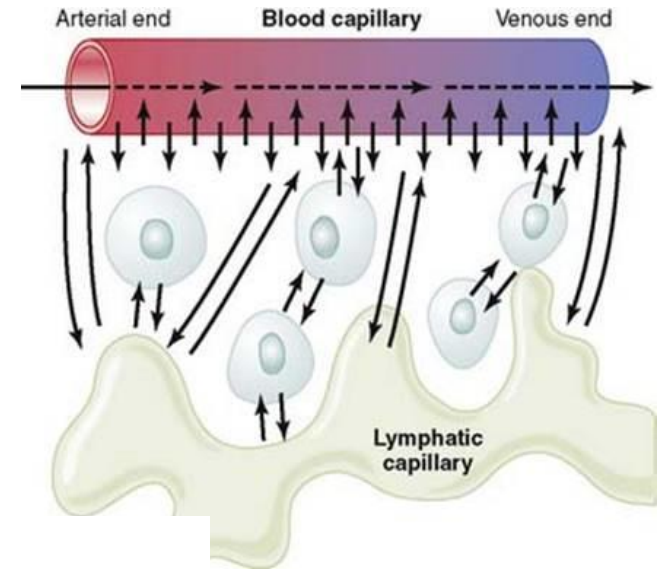
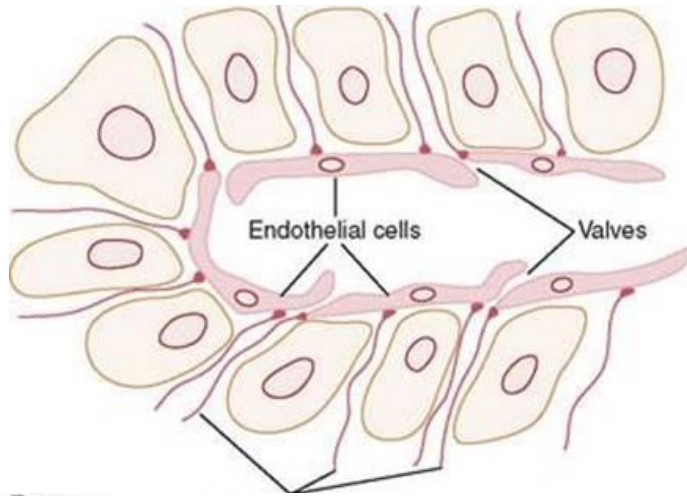
- Collect interstitial fluid
- Microenvironment for lymphocyte development and maturation
- Lipid transport (chylomicrons)

Histology

- Lymph capillaries
 - Thin walled, blunt ended vessels with irregular lamina basalis
 - Anchoring filaments, tiny valves
- Lymph vessels
 - T. intima – endothelium and subendothelial c.t.
 - T. media - few layers of smooth muscle cells
 - T. adventitia - collagen c.t.
- Similar to small veins
- Valves derived from t. intima
- Open to d. thoracicus and d. lymphaticus dx. → v. subclavia (at v. jugularis int.)

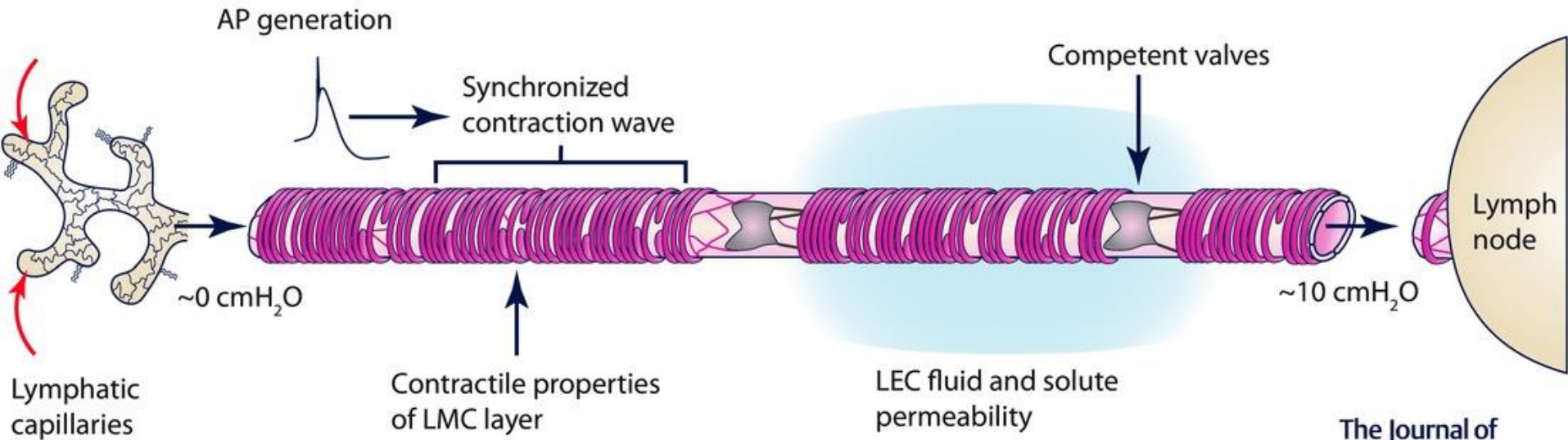
LYMPHATIC CIRCULATION

Lymph capillaries



LYMPHATIC CIRCULATION

Lymph flow is unidirectional

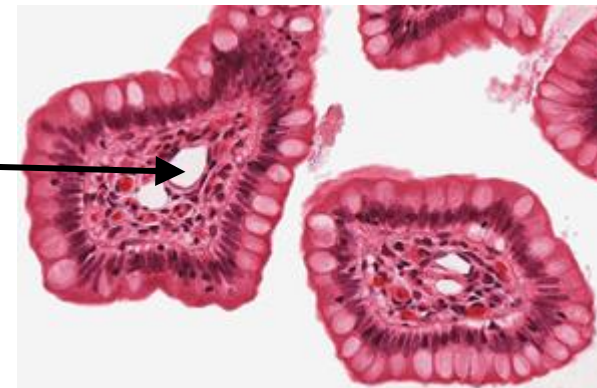


The Journal of
Physiology

<https://doi.org/10.1113/JP272088>

Lymph composition

- Contains similar concentration of ions to plasma, but lower levels of proteins
- Lipid-rich lymph from intestine - chylus
- Immune cells
- Volume in the circulation ca. 1L (2-2.5L new lymph from interstitial fluid per day)



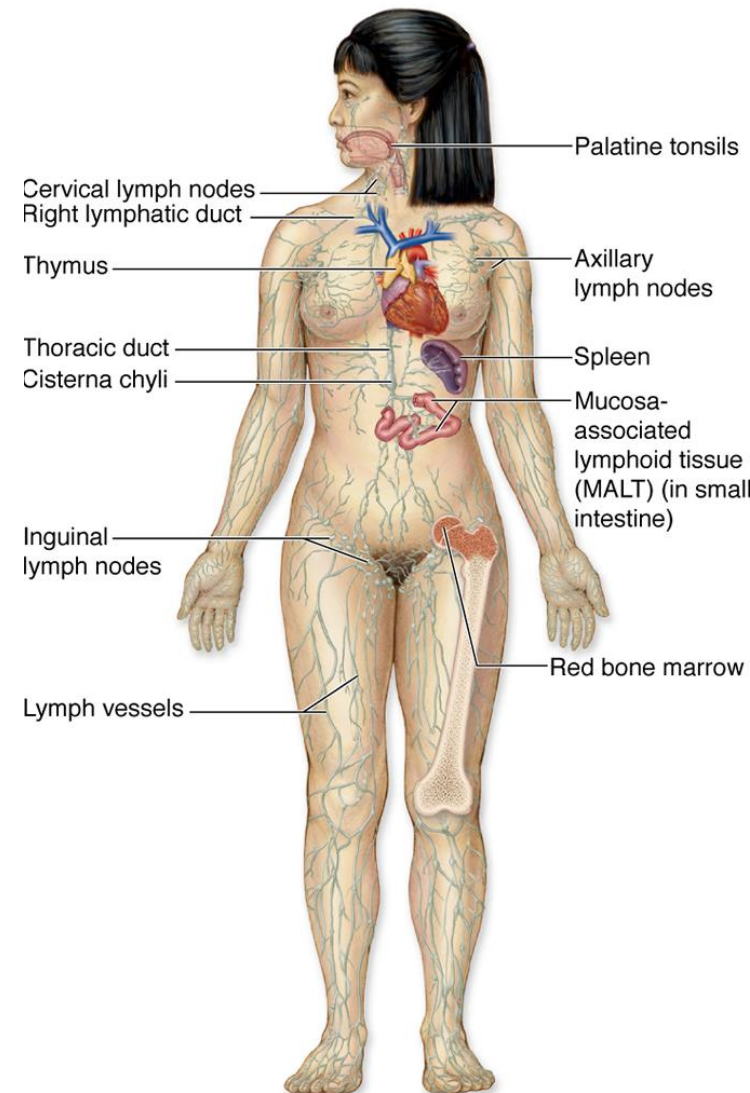
LYMPHATIC ORGANS

central:

- thymus
- bone marrow – also hematopoietic organ

peripheral:

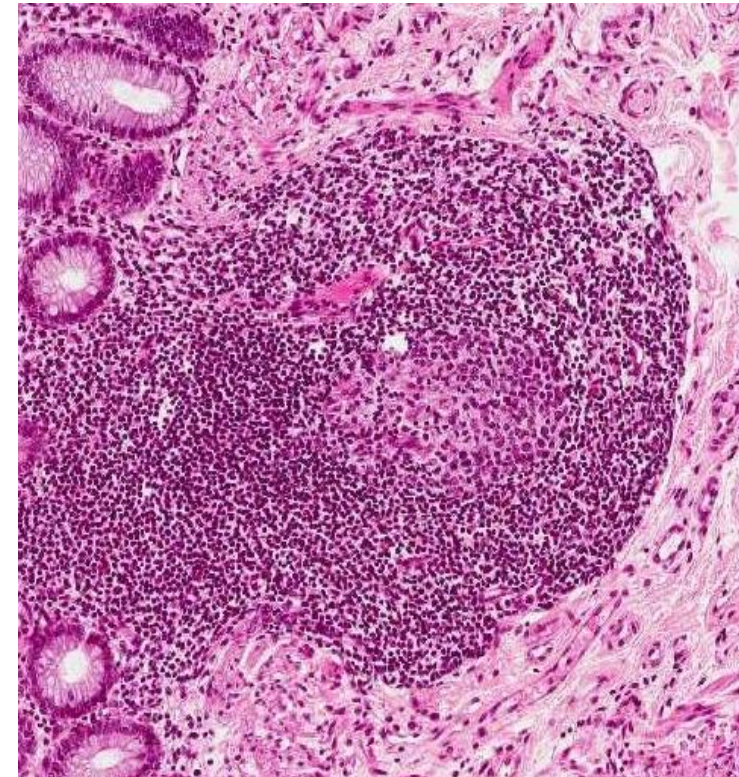
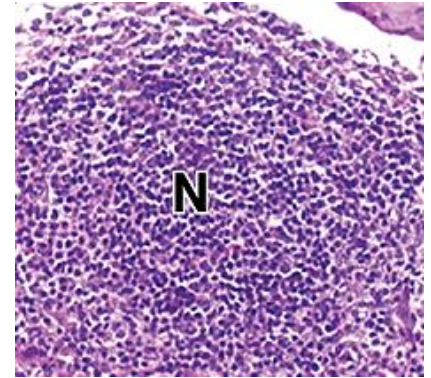
- encapsulated – lymph node, spleen
- mucosa associated lymphoid tissue – MALT
 - tonsils
 - lymphatic follicles in mucosa of hollow organs



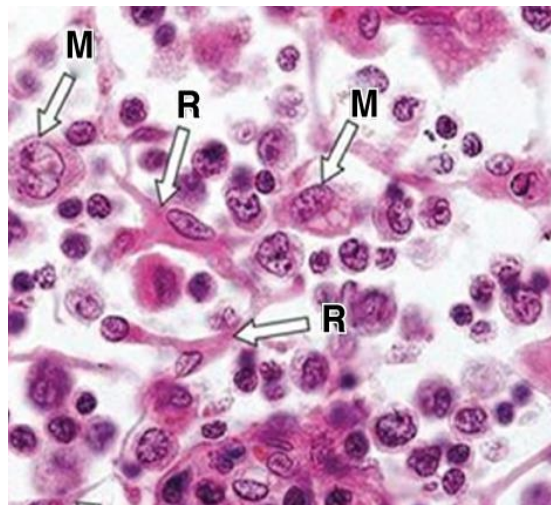
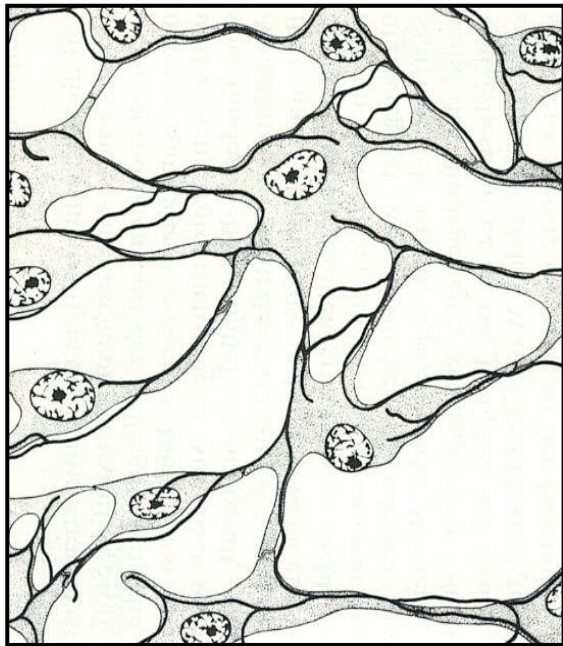
LYMPHATIC FOLLICLE

Lymphatic follicle - nodulus lymphaticus

- non-encapsulated aggregates of reticular connective tissue and lymphocytes
- peripheral lymphatic organs
- mucosa of hollow organs (GIT, respiratory, urinary, reproductive system)
- **primary** – prior any contact with antigen
- **secondary** – stimulated by antigen
 - pale germinative center
 - dark mantle zone

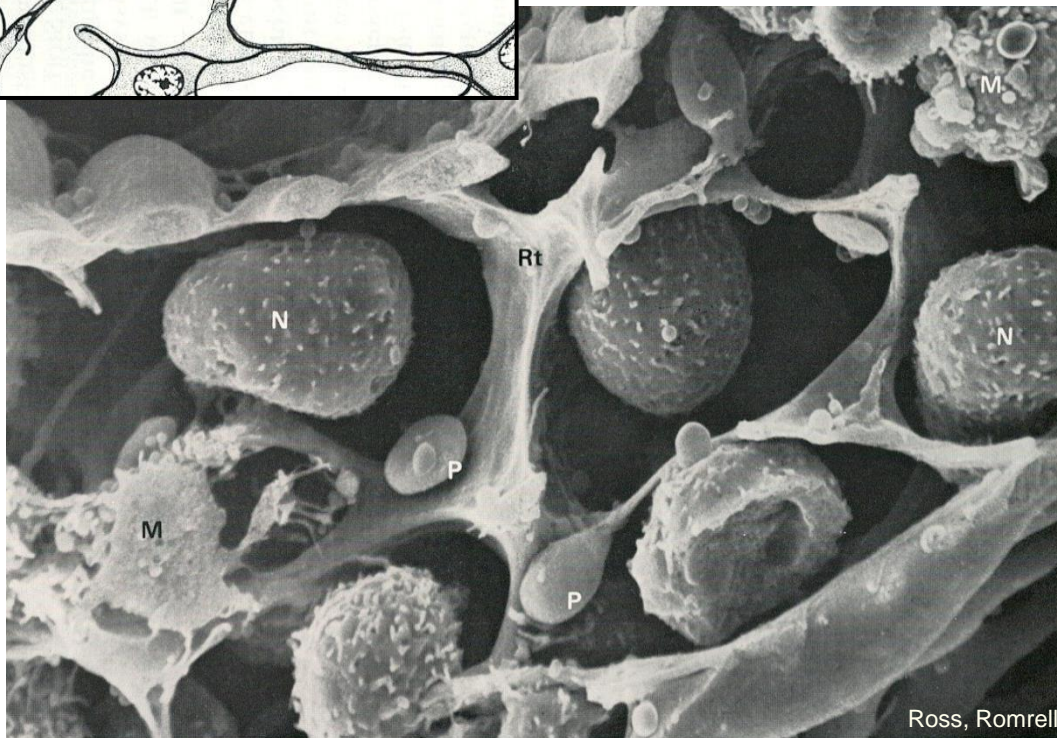


LYMPHATIC (LYMPHORETICULAR) TISSUE

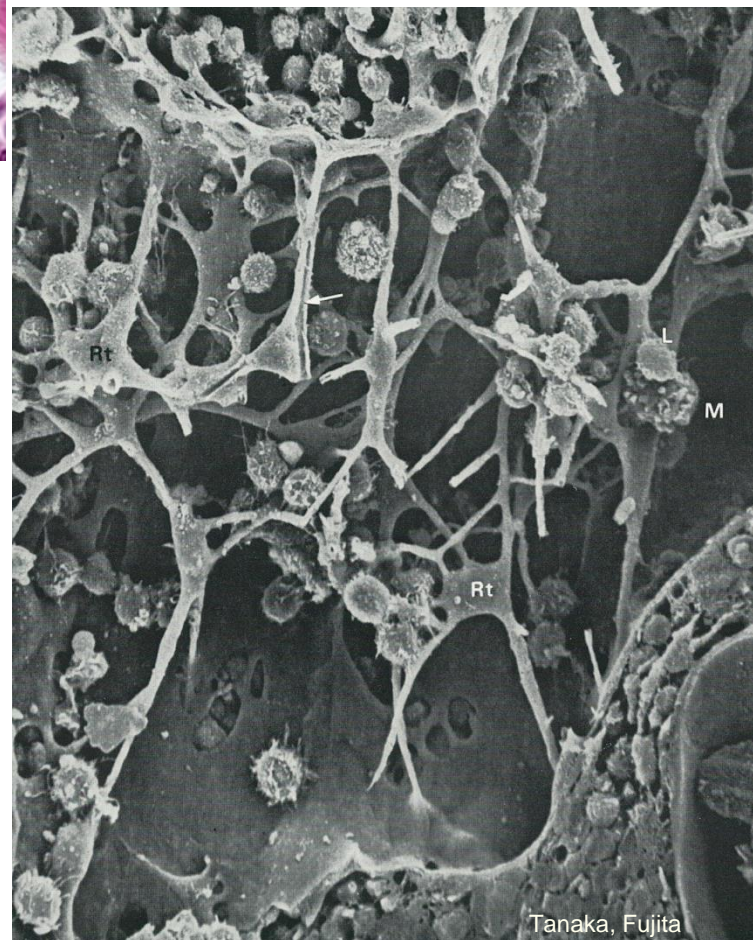


Mescher

- reticular connective tissue + lymphocytes



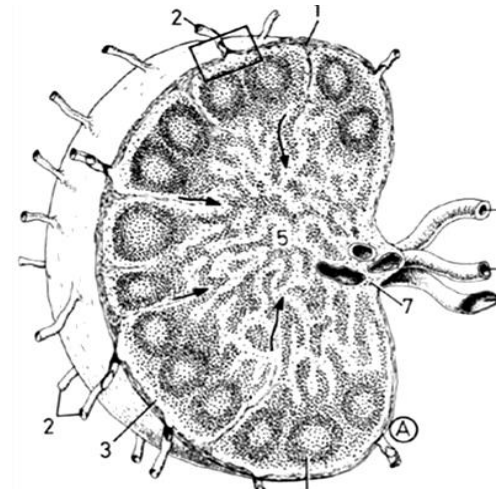
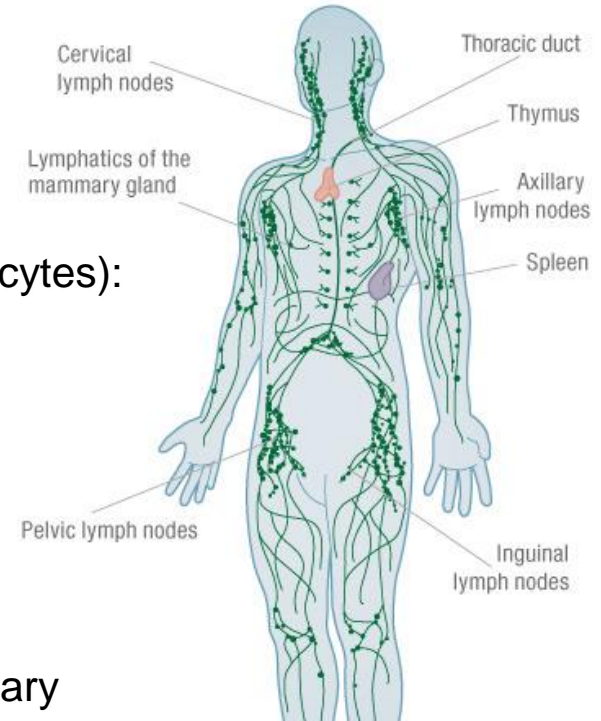
Ross, Romrell



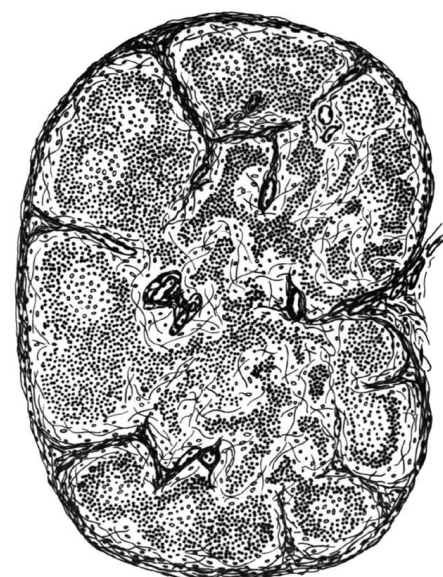
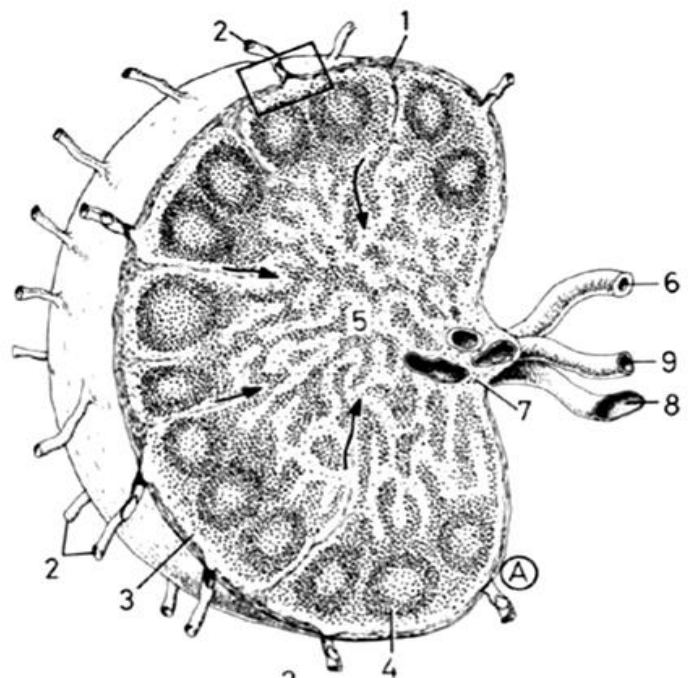
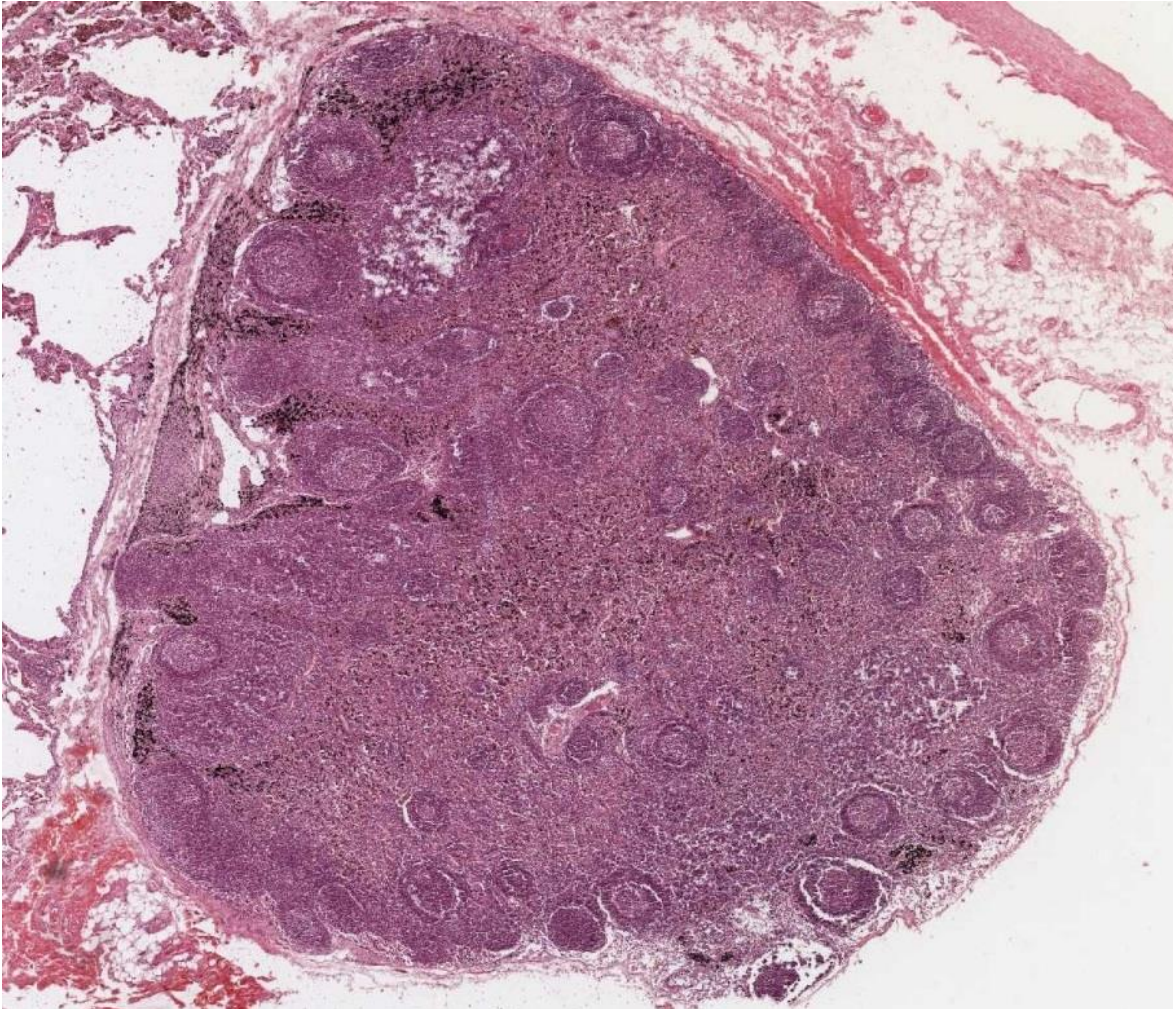Tanaka, Fujita

LYMPH NODE (nodus lymphaticus, lymphonodus)

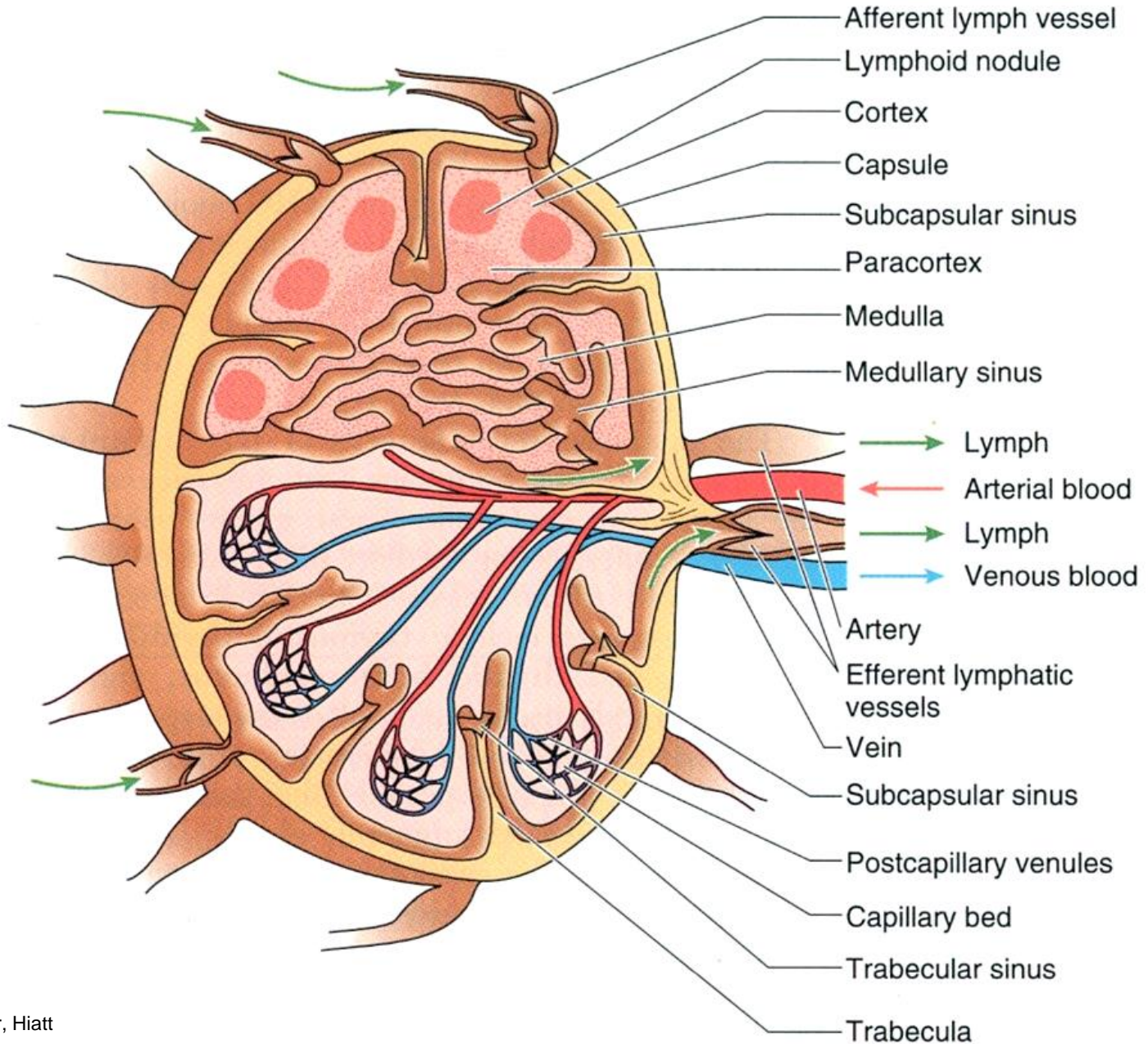
- C.t. capsule containing *hilus with vessels*
- parenchyma = lymphoreticular tissue (reticular c.t. and lymphocytes):
- cortex (lymphatic follicles and sinuses) (B-cells)
- medulla (cords and sinuses) (B-cells)
- paracortical region (T-cells)
- sinuses: subcapsular (marginal), perifollicular (cortical), medullary
- *Littoral cells* – lining of sinuses, phagocytosis



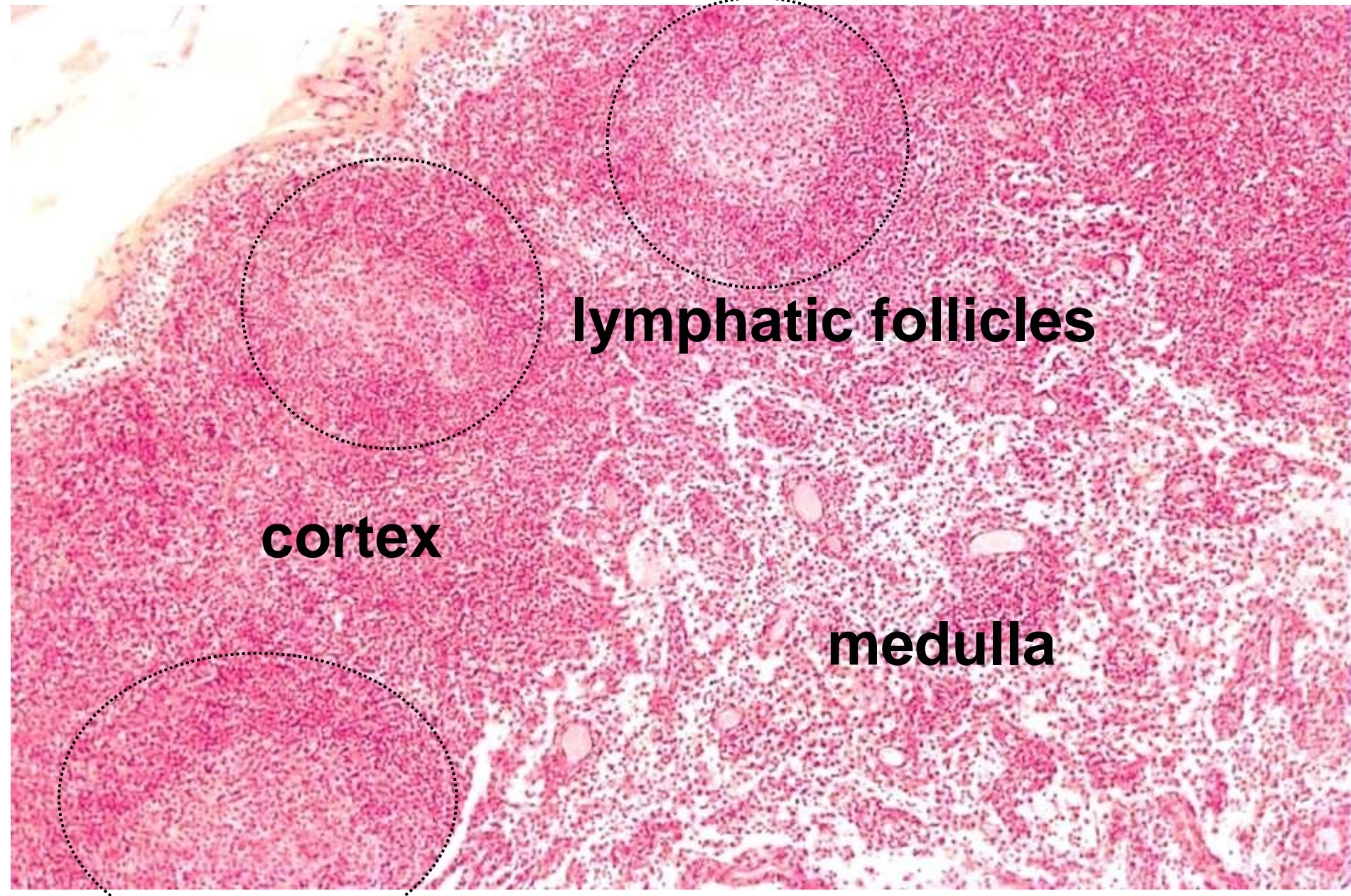
LYMPH NODE (nodus lymphaticus, lymphonodus)



LYMPH NODE CIRCULATION (BLOOD AND LYMPH)



LYMPH NODE (NODUS LYMPHATICUS, LYMPHONODUS)



cortex

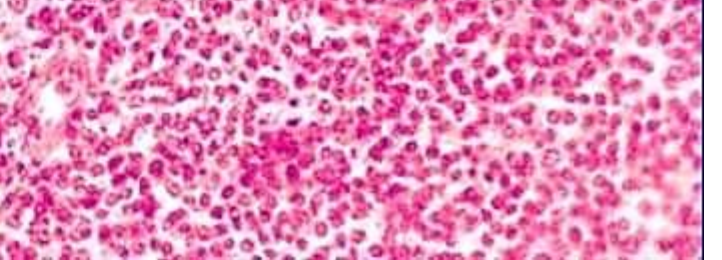
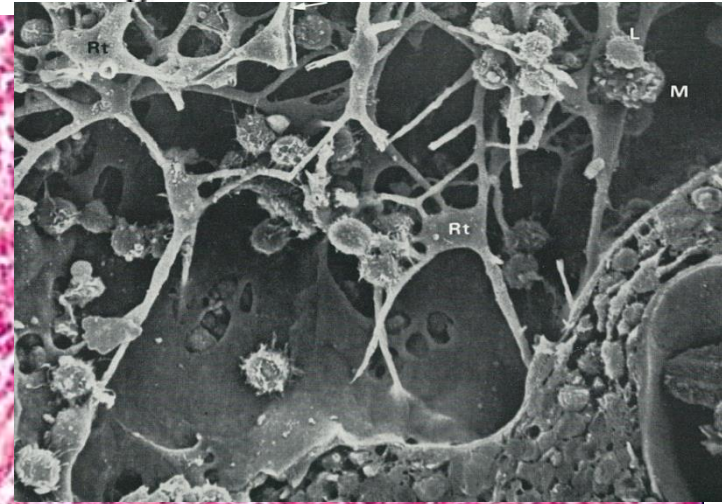
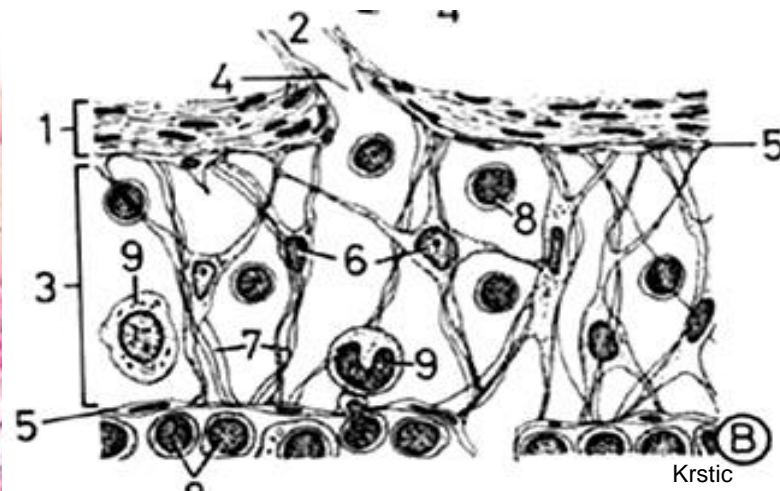
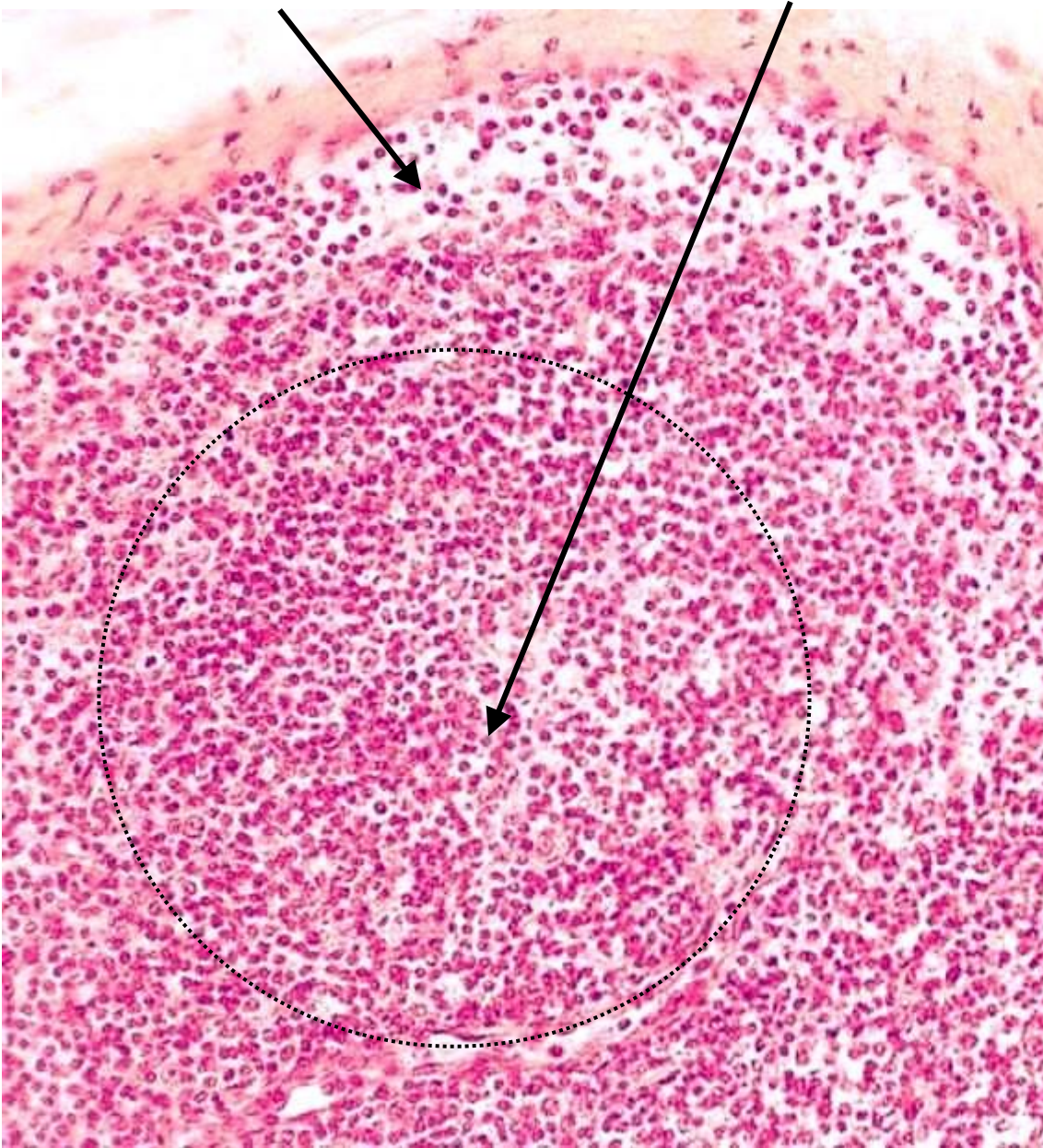
lymphatic follicles

medulla

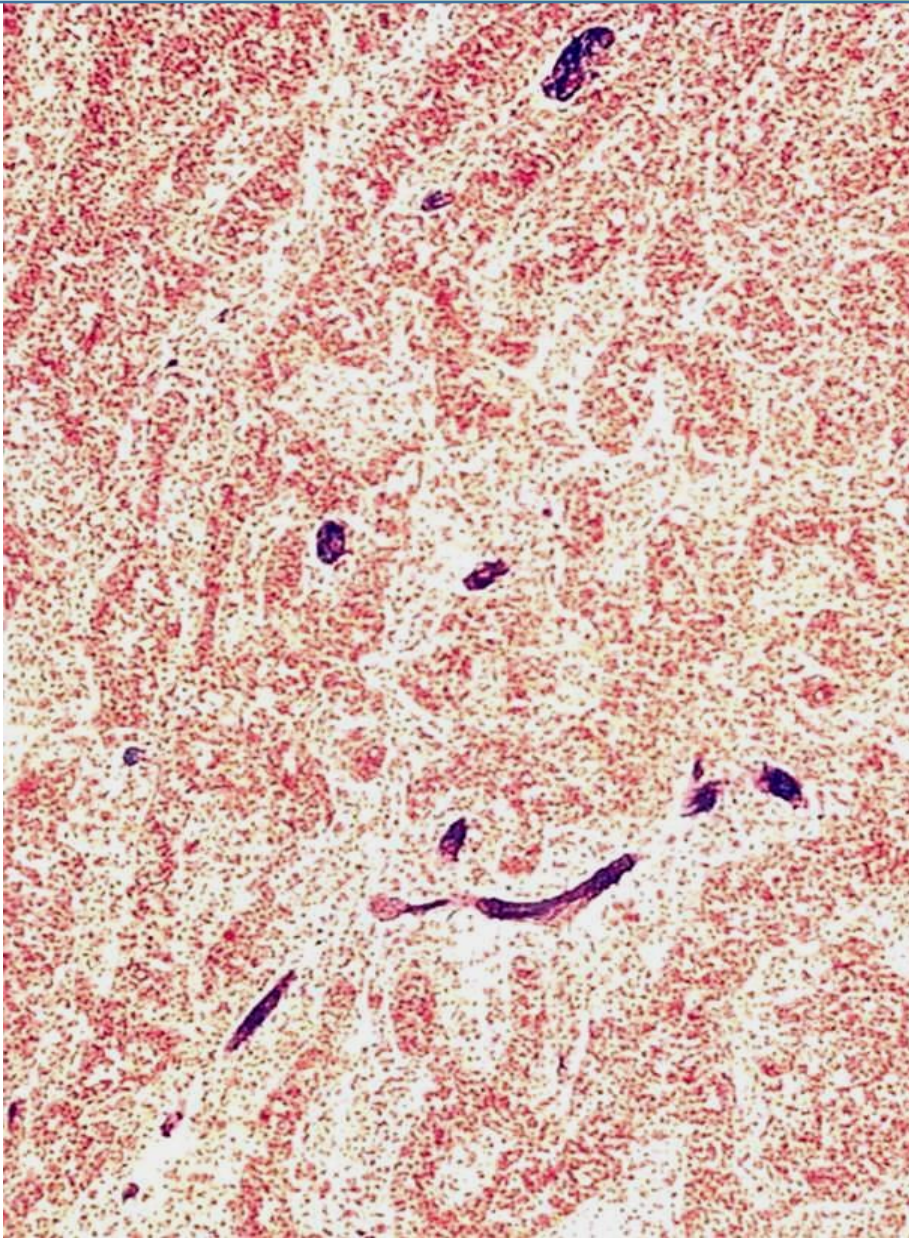
LYMPH NODE (NODUS LYMPHATICUS, LYMPHONODUS)

subcapsular sinus

lymphatic follicle

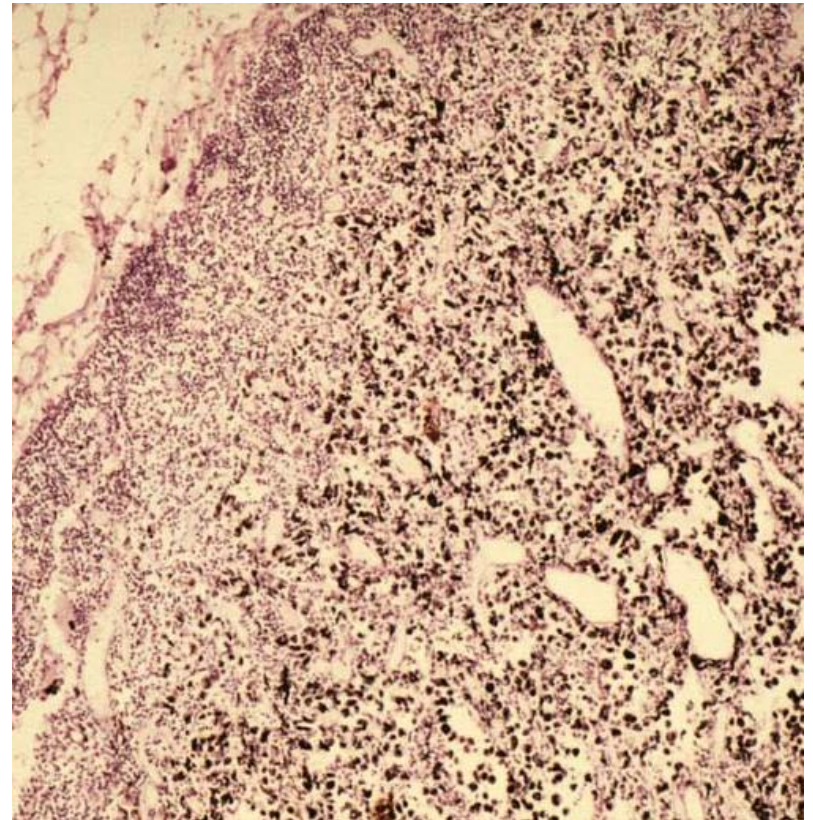


LYMPH NODE MEDULLA

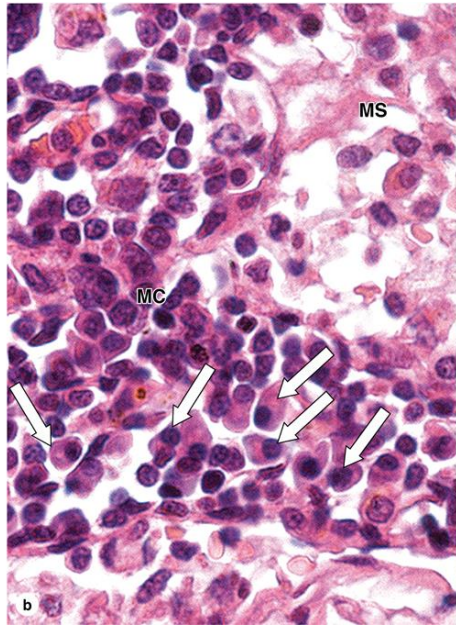
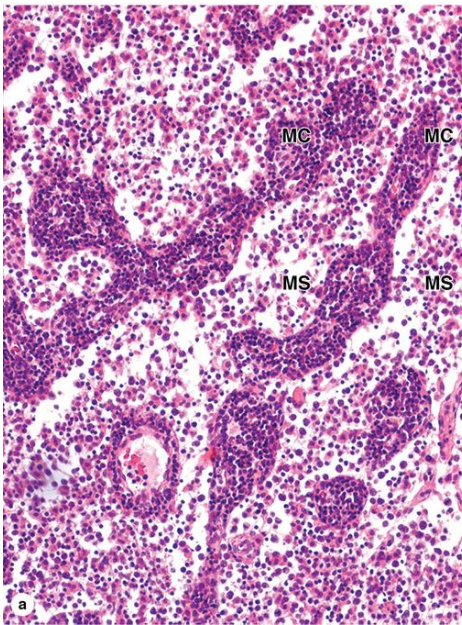


Medullary cords and sinuses

- Lymph node from lung hilus with dust (carbon) deposits
- Anthracosis



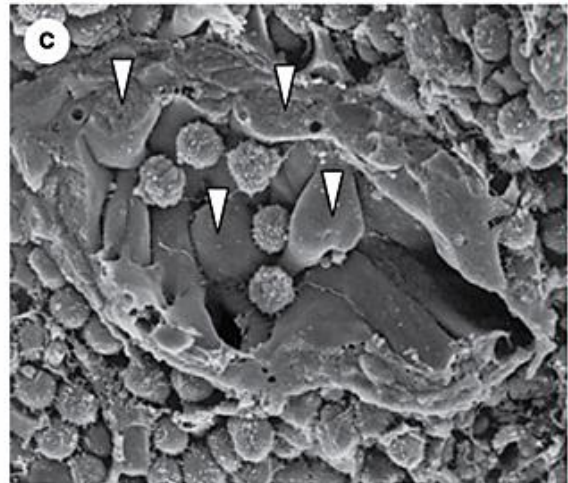
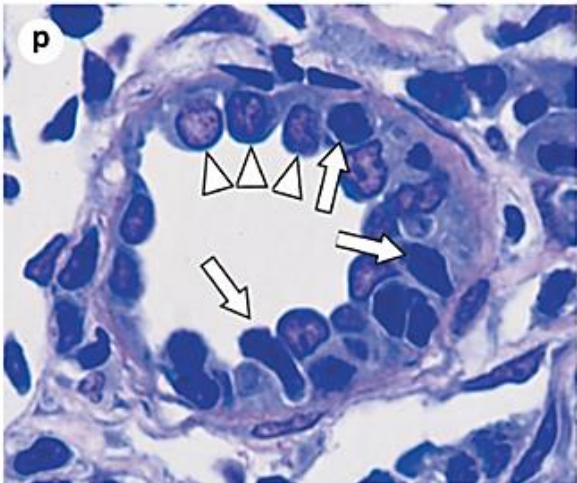
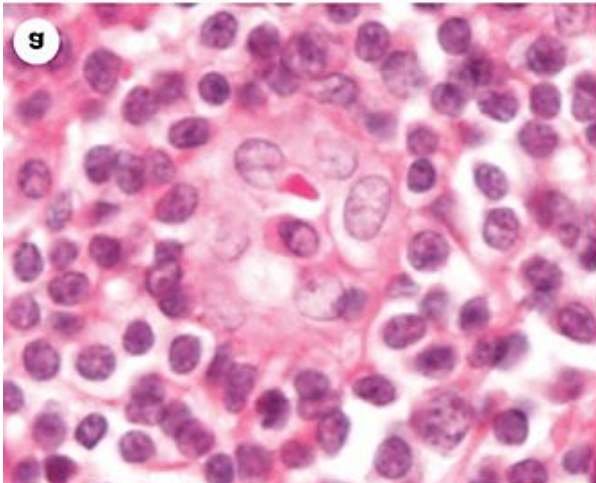
LYMPH NODE MEDULLA



Medullary cords and sinuses

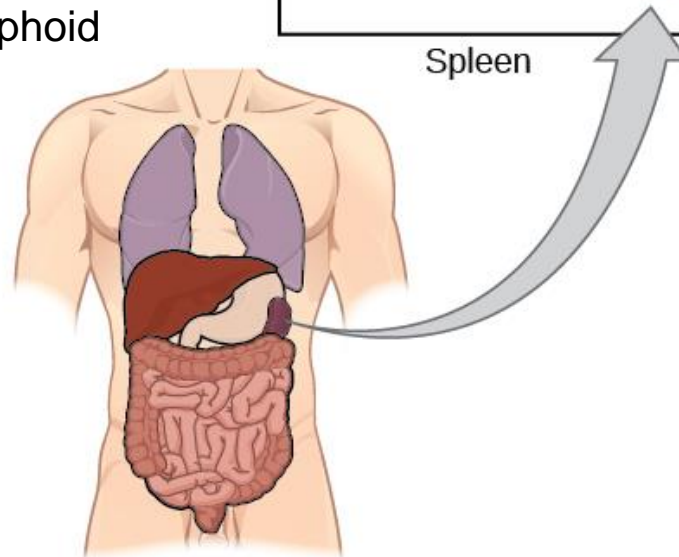
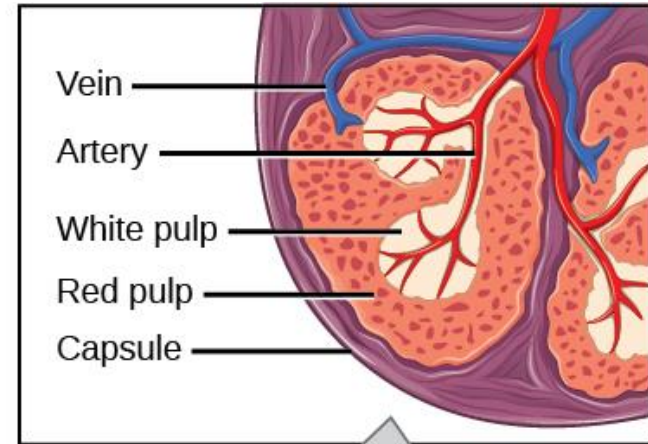
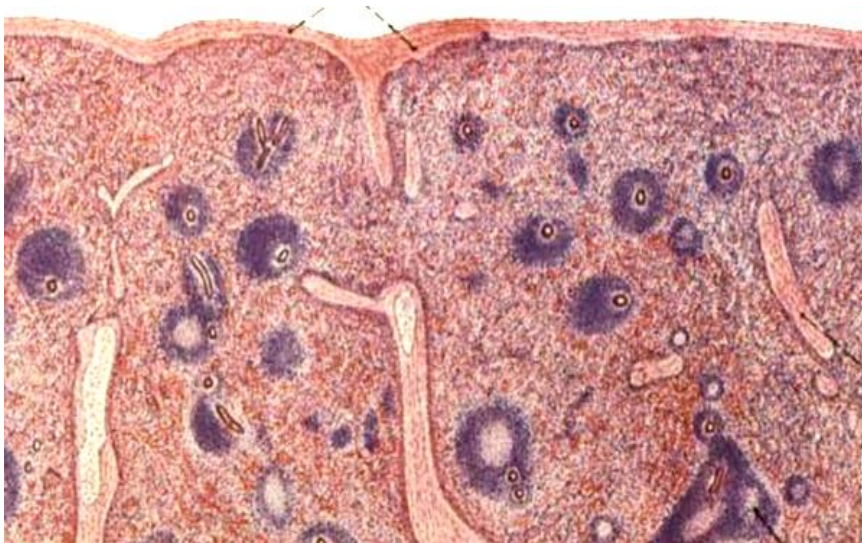
- Plasma cells in medullary cords
- High endothelium post-capillary venules – extravasation of leukocytes from blood to lymph node parenchyma

Mescher

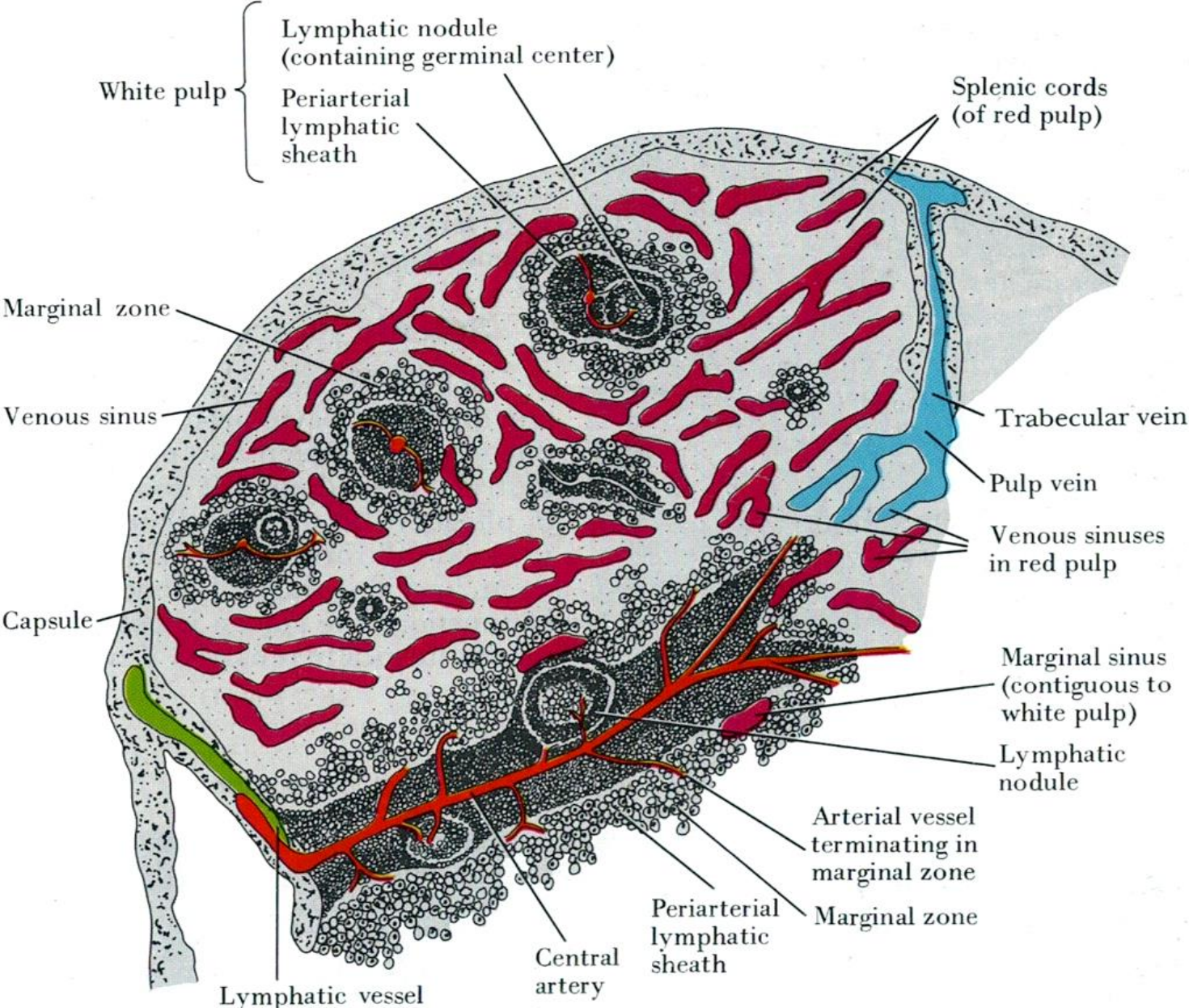


SPLEEN (LIEN)

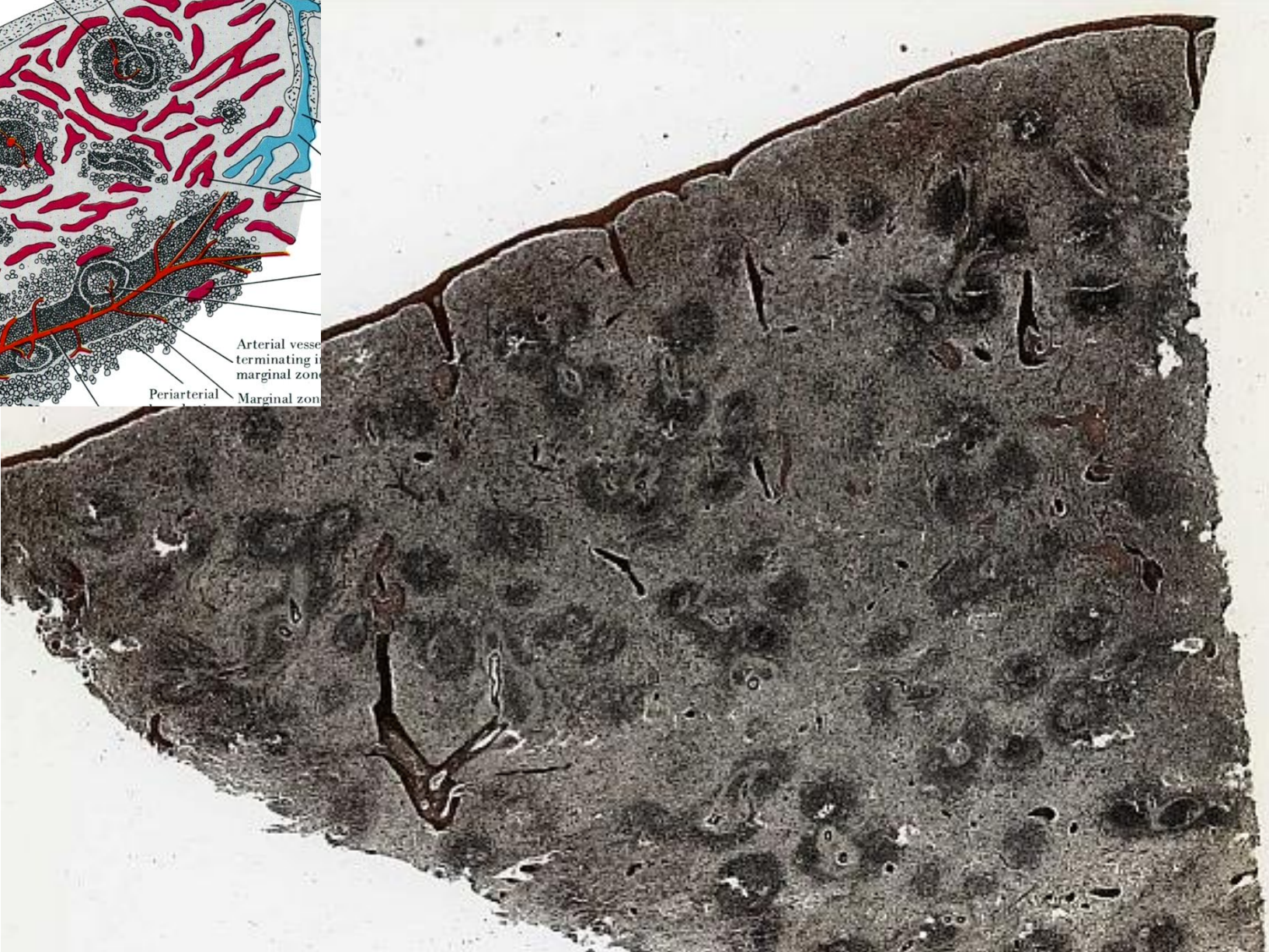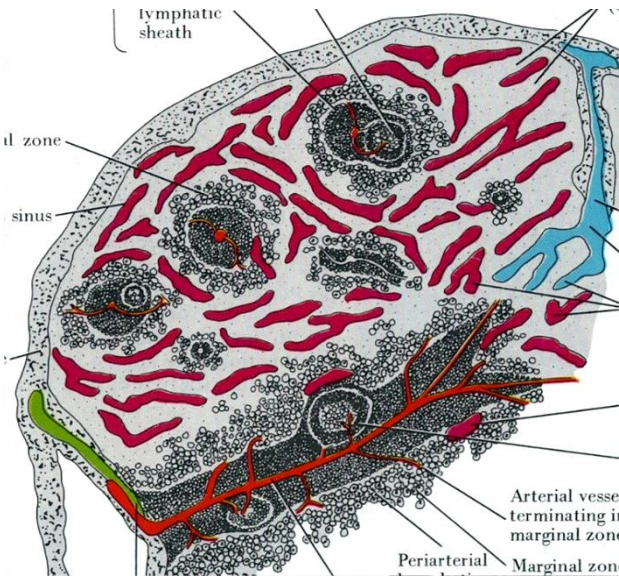
- C.t. capsule and trabecules
- Parenchyma = pulp
- **white** (lymphoid)
 - periarteriolar lymphatic sheath - PALS
 - Malpighian bodies - follicles)
- **red** (non-lymphoid)
 - cords of Billroth
 - venous sinuses
- **marginal zone** between lymphoid and non-lymphoid regions in the spleen



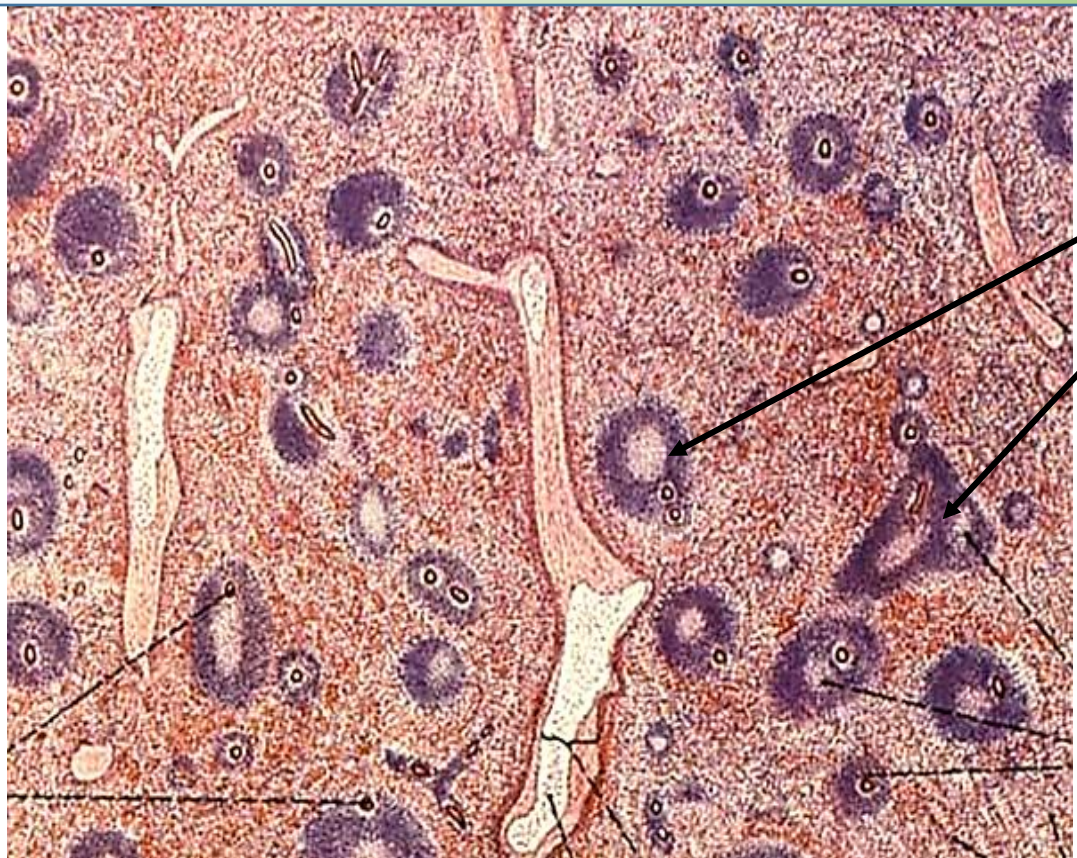
SPLEEN (LIEN)



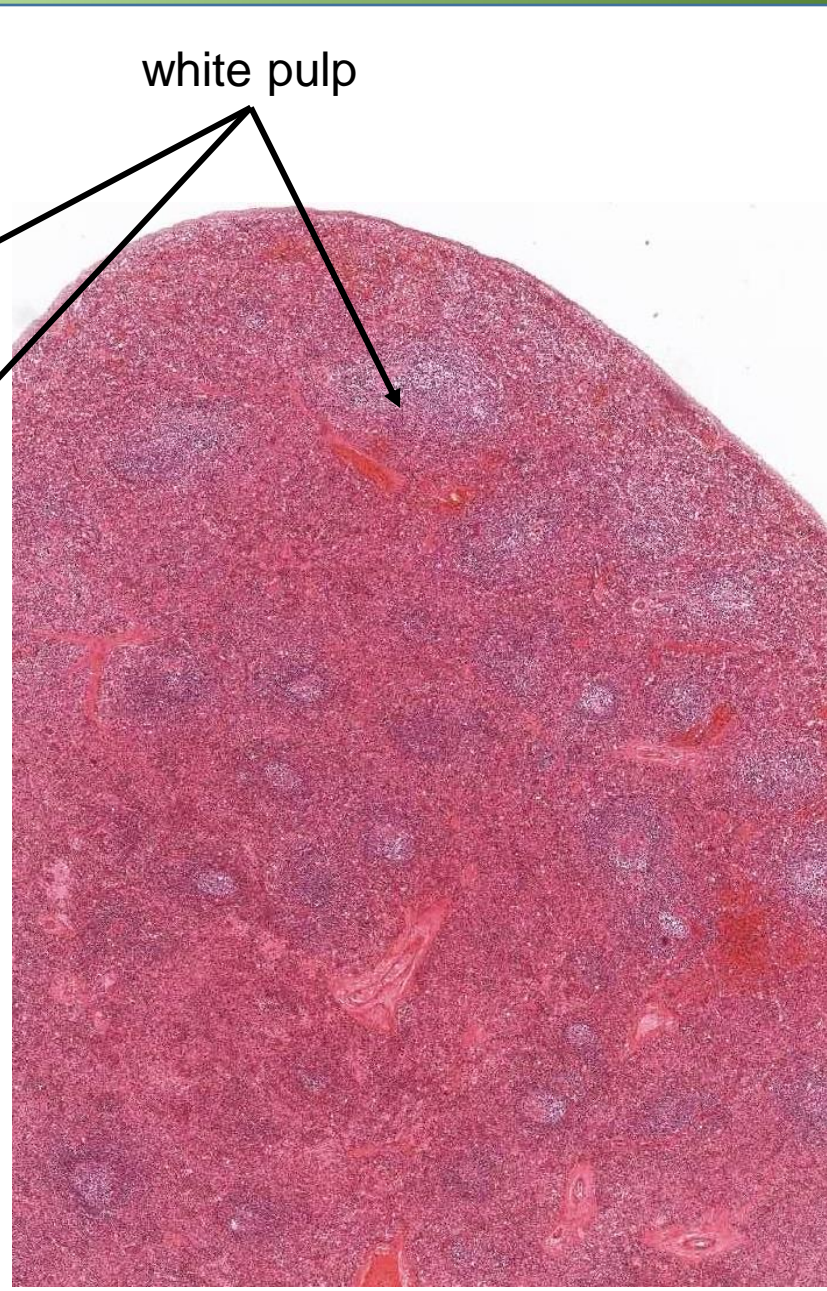SPLEEN (LIEN)



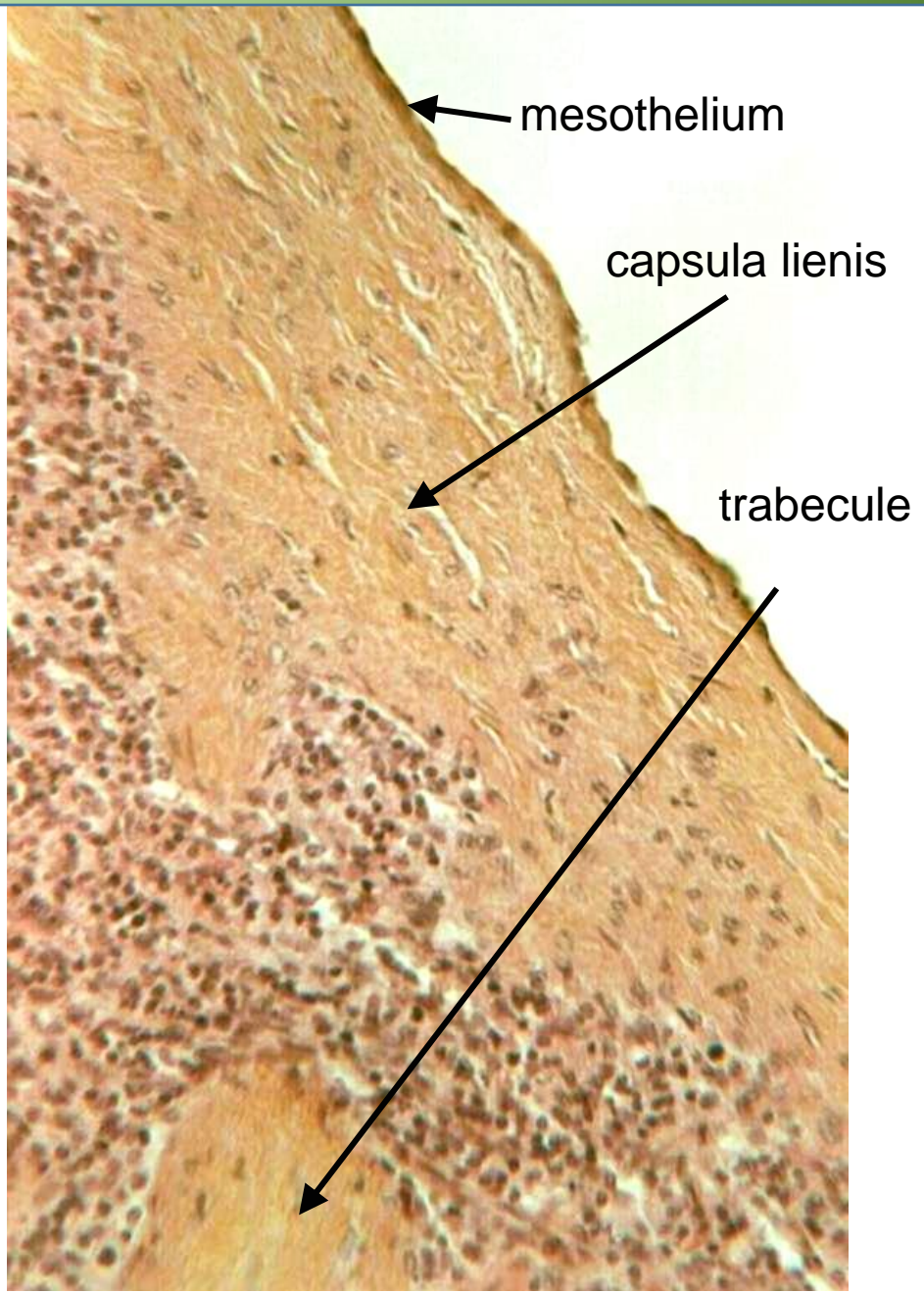
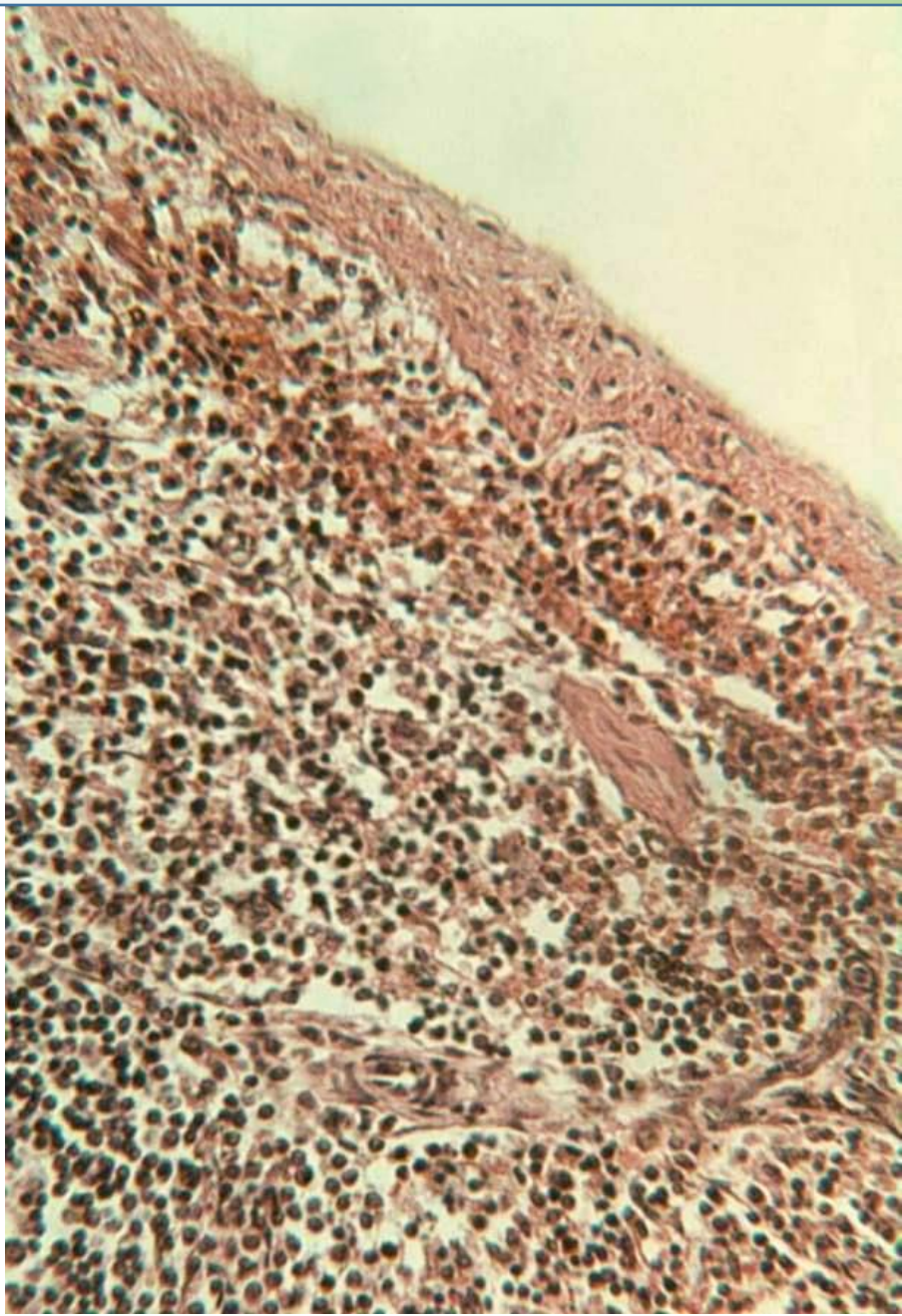
SPLEEN (LIEN)



Sobotta



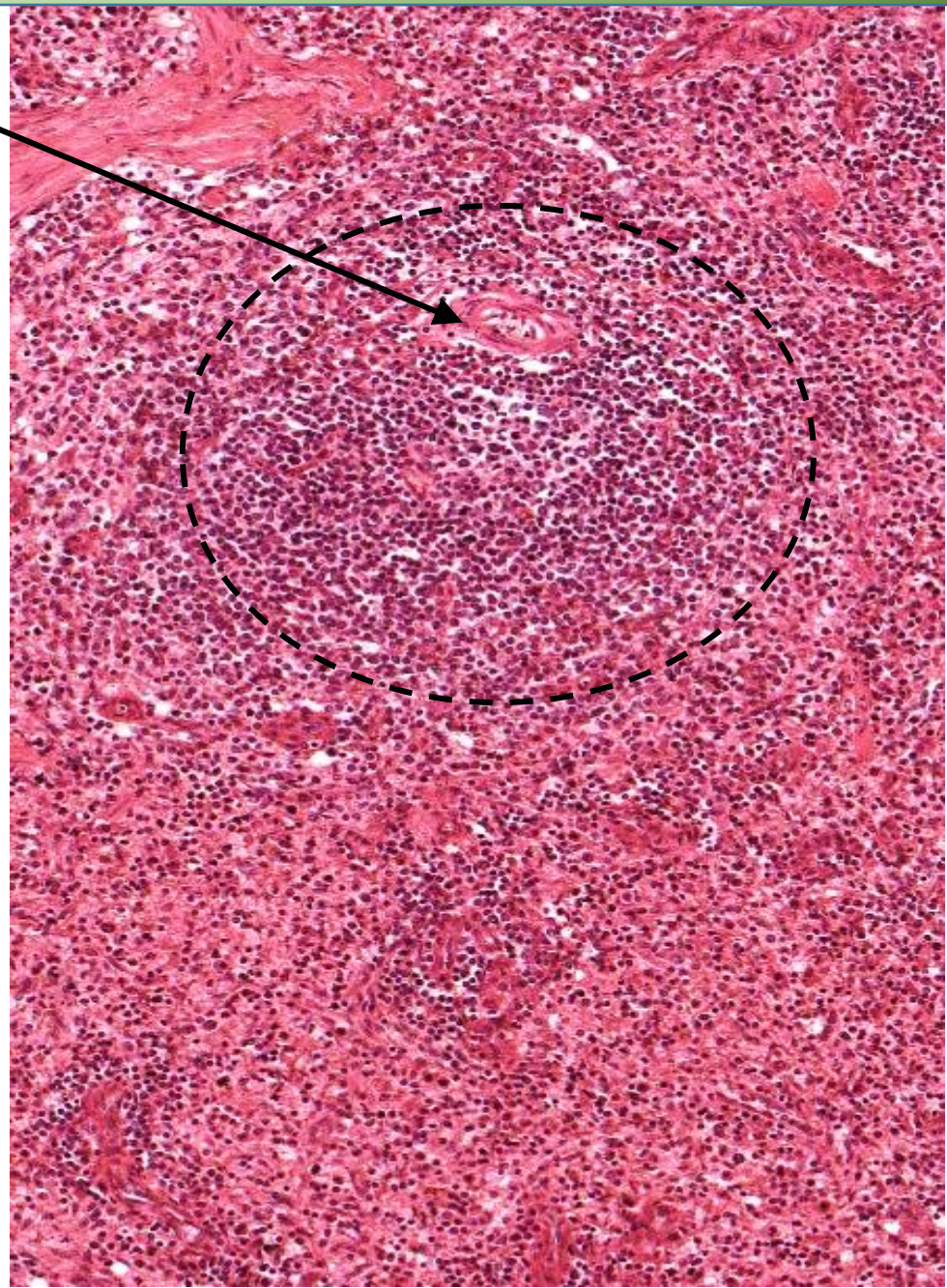
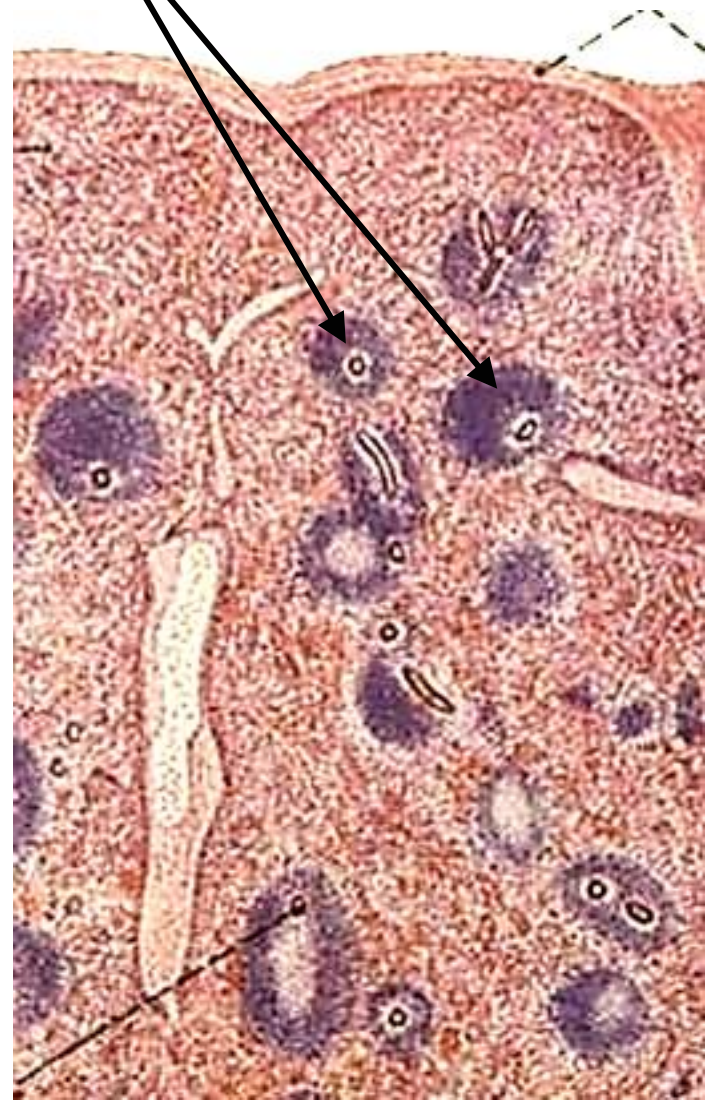SPLEEN (LIEN)



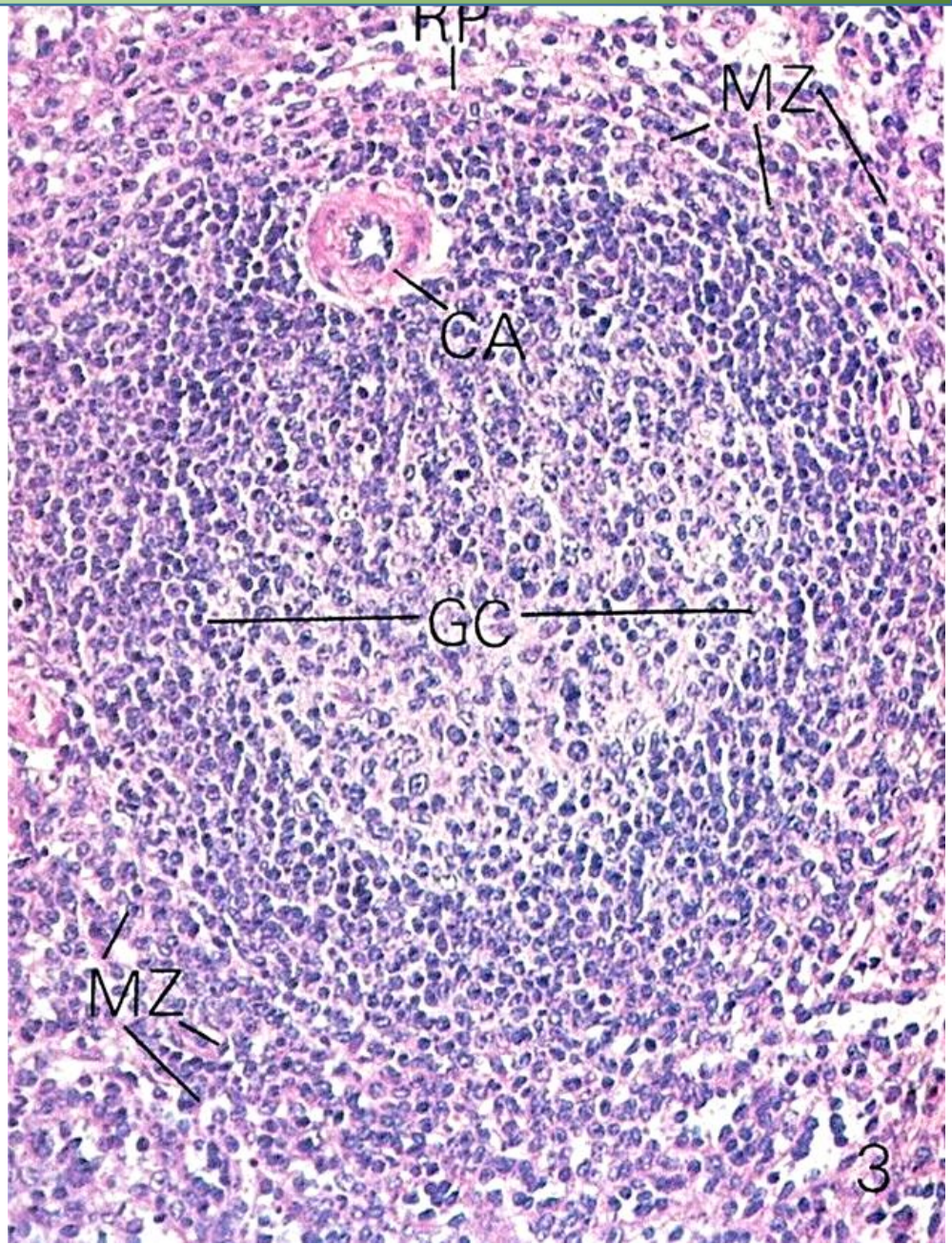
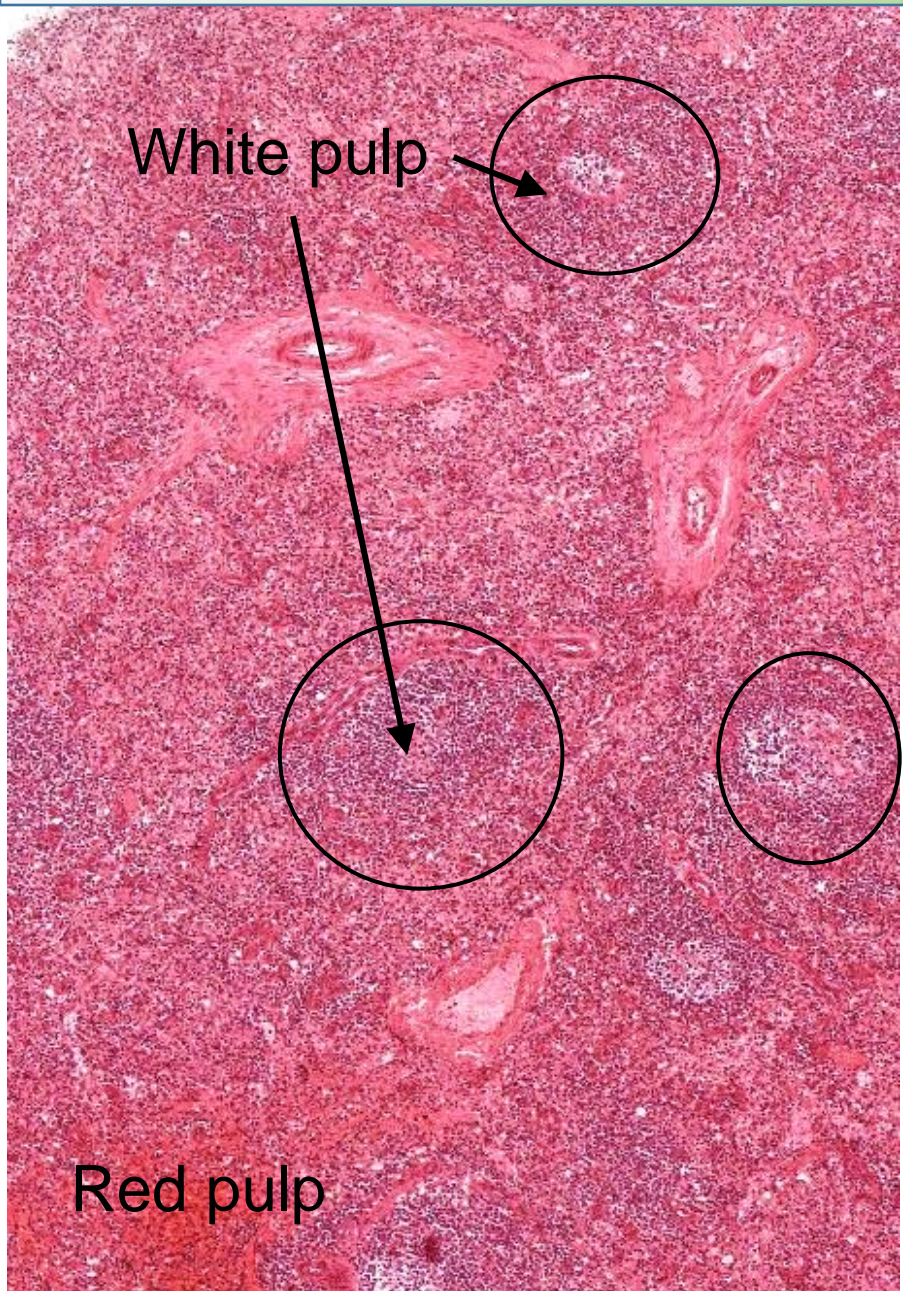
SPLEEN (LIEN)

White pulp

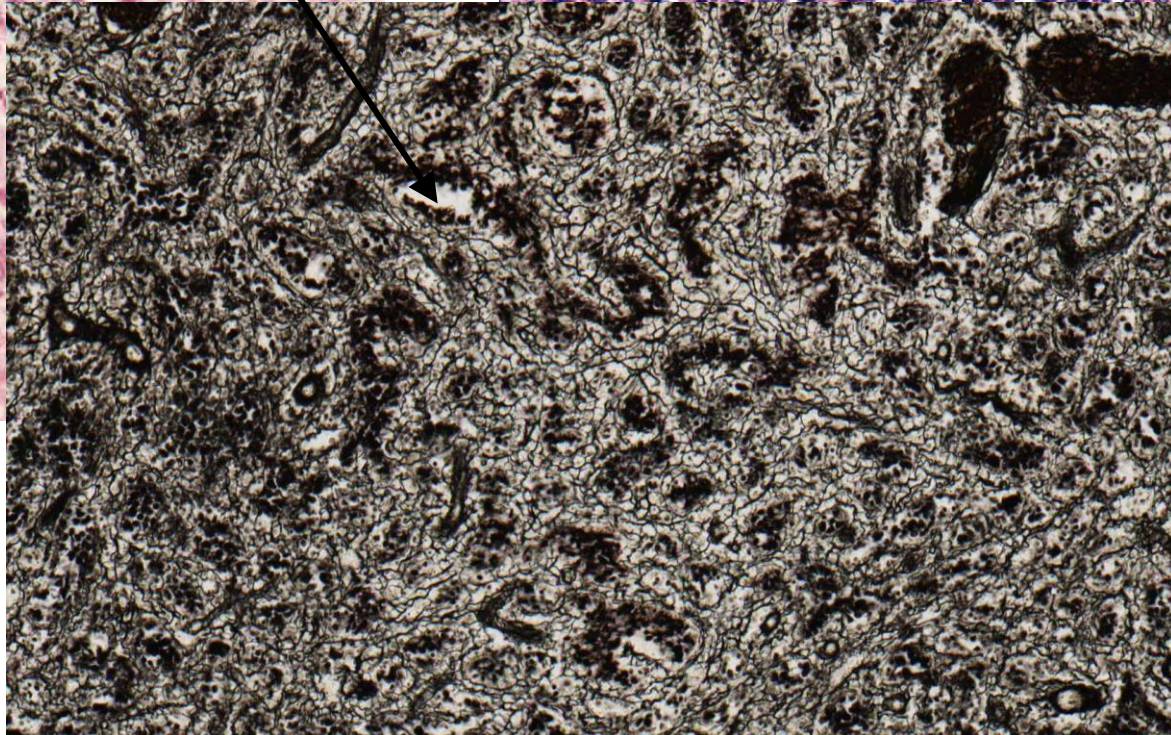
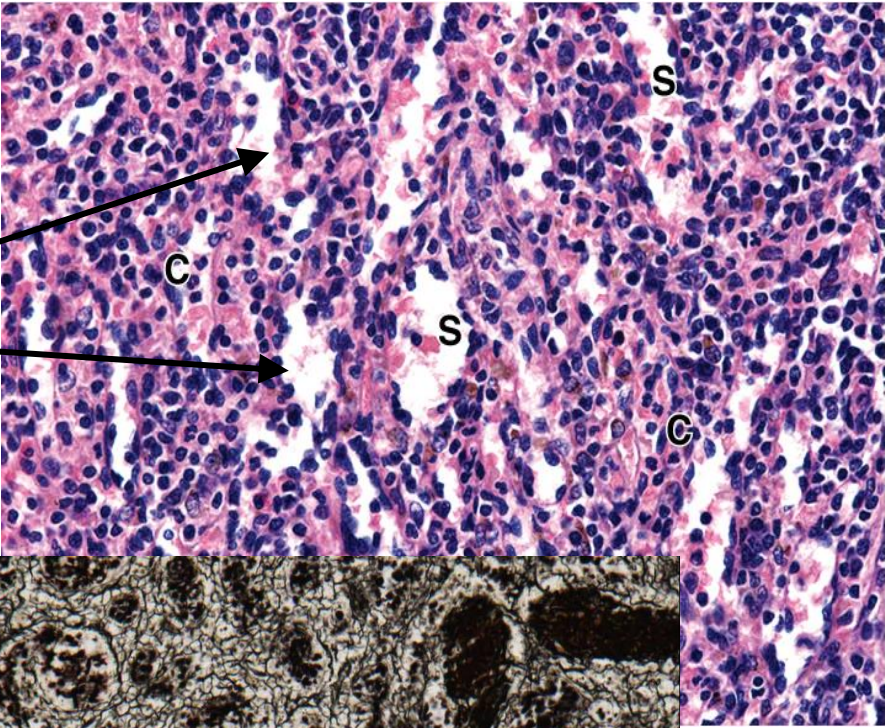
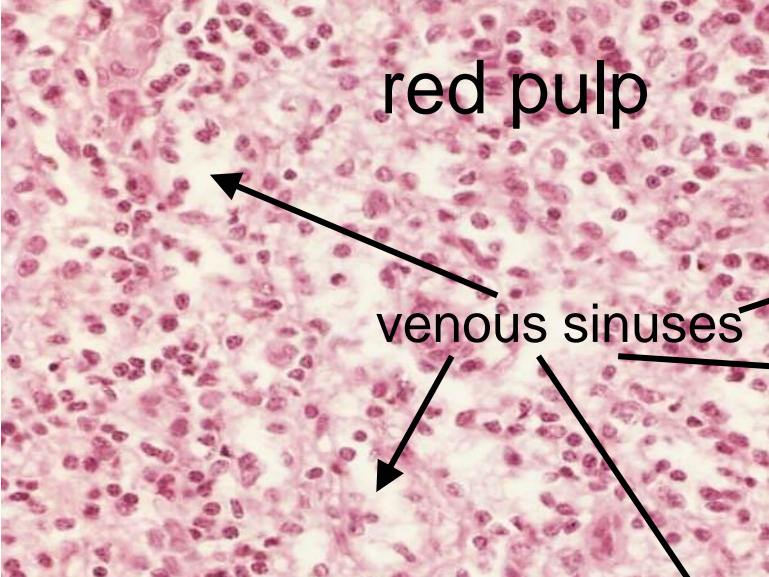
a. centralis



SPLEEN (LIEN)



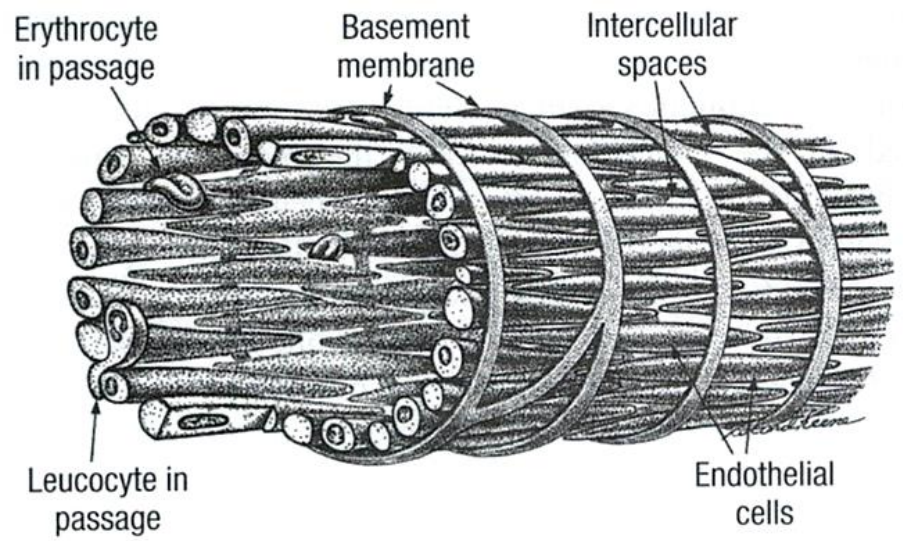
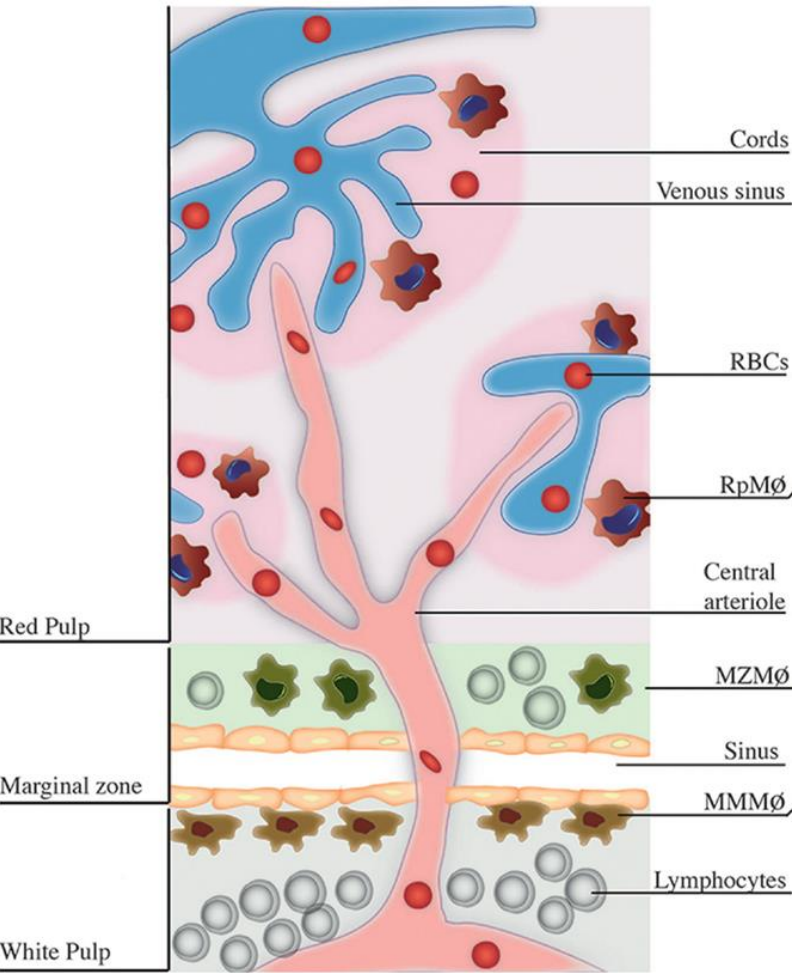
SPLEEN (LIEN)



Mescher

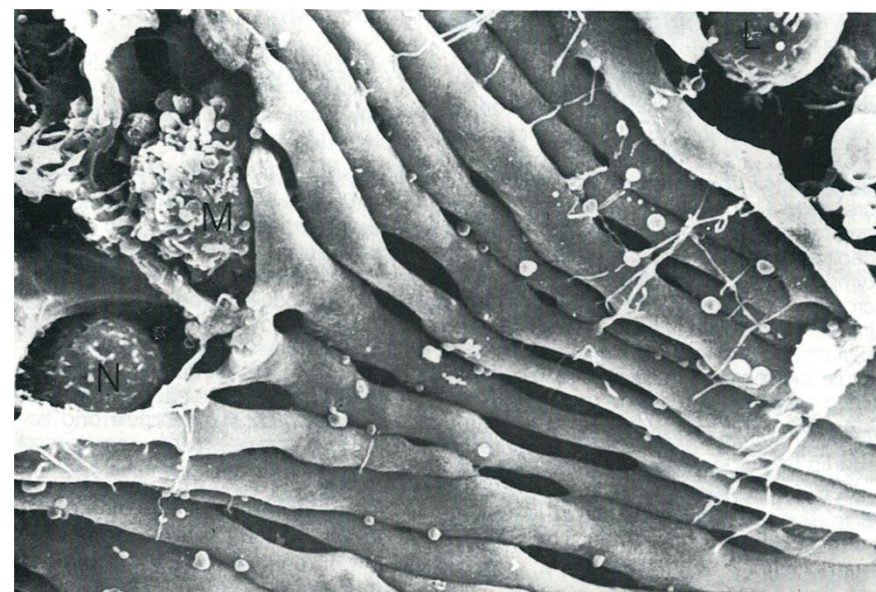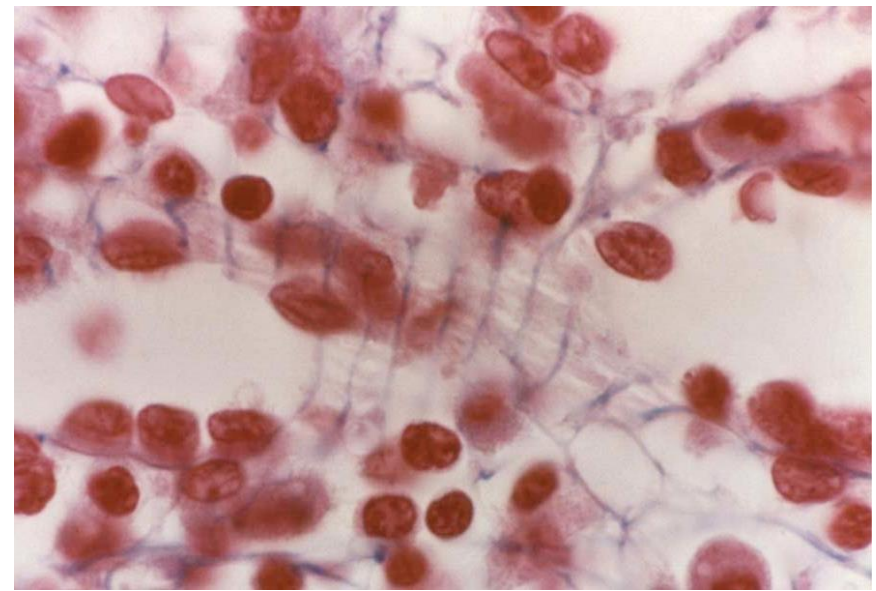
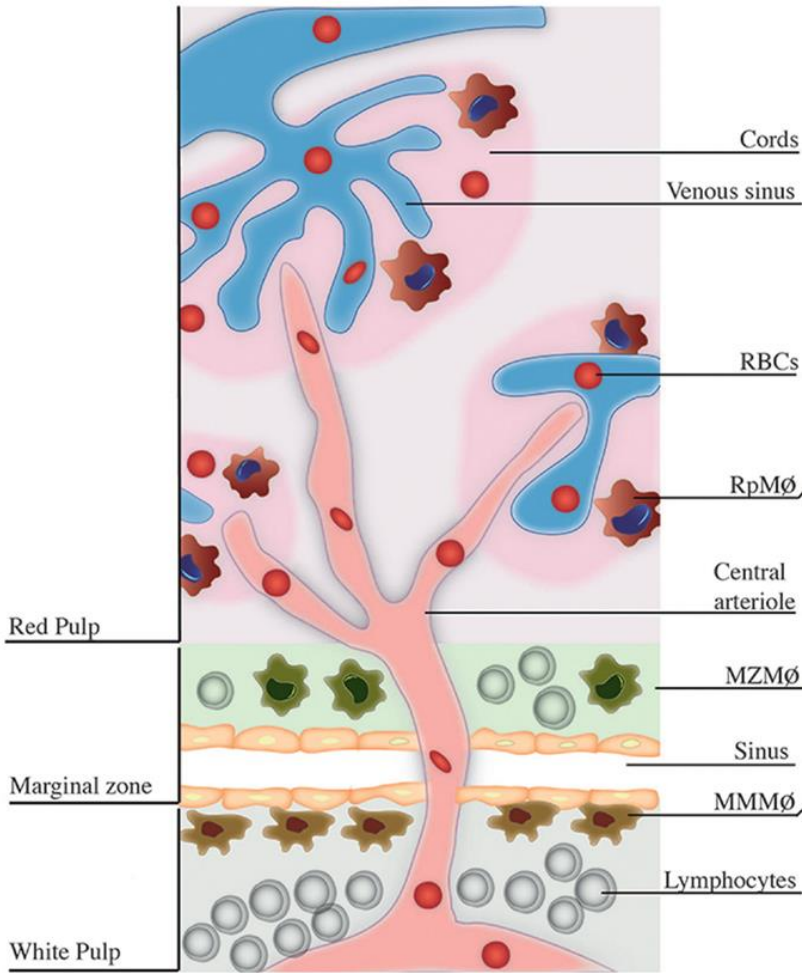
SPLEEN (LIEN)

- Venous sinuses of red pulp
- Removal of abnormal erythrocytes



SPLEEN (LIEN)

- Venous sinuses of red pulp
- Removal of abnormal erythrocytes

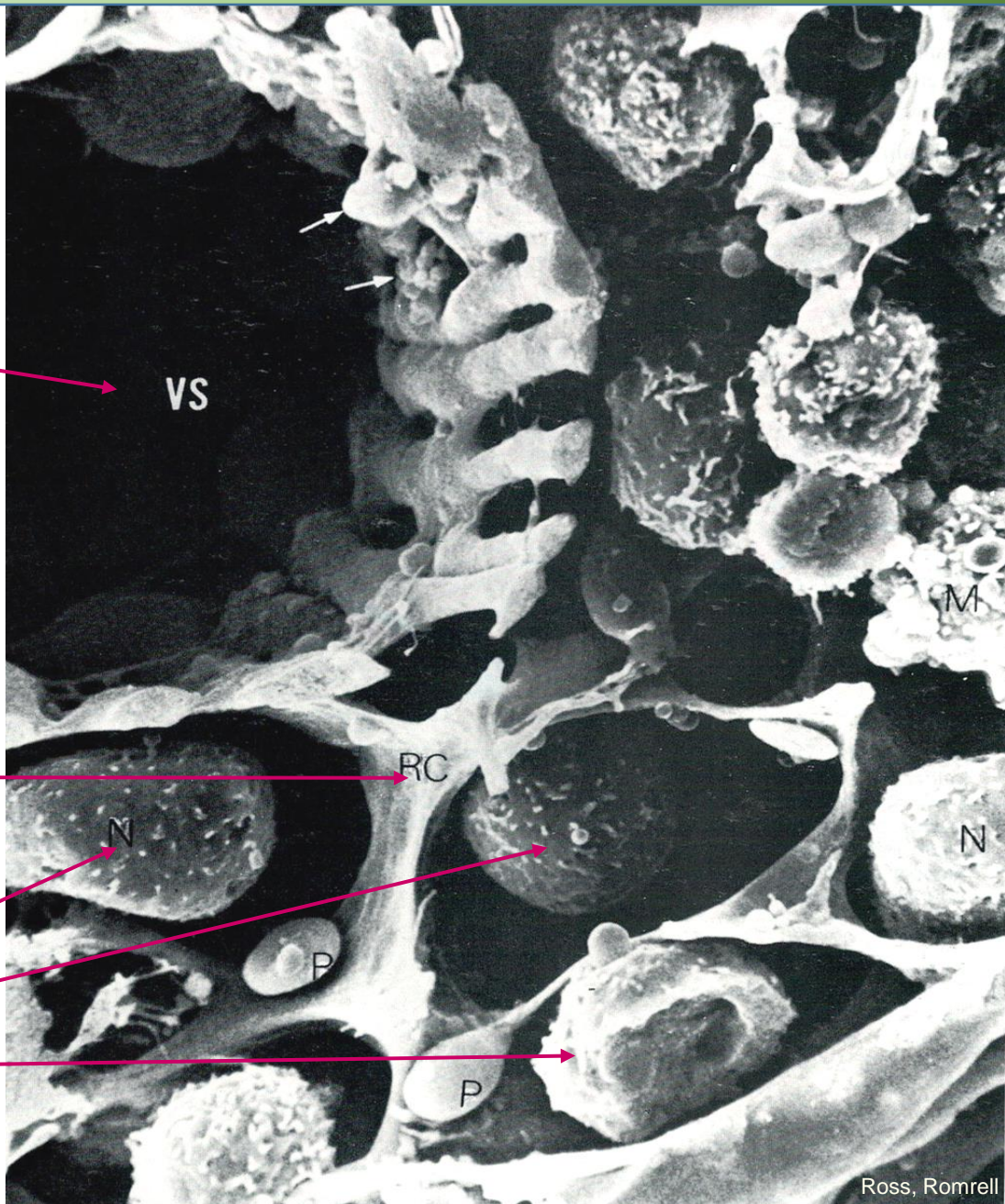


SPLEEN (LIEN)

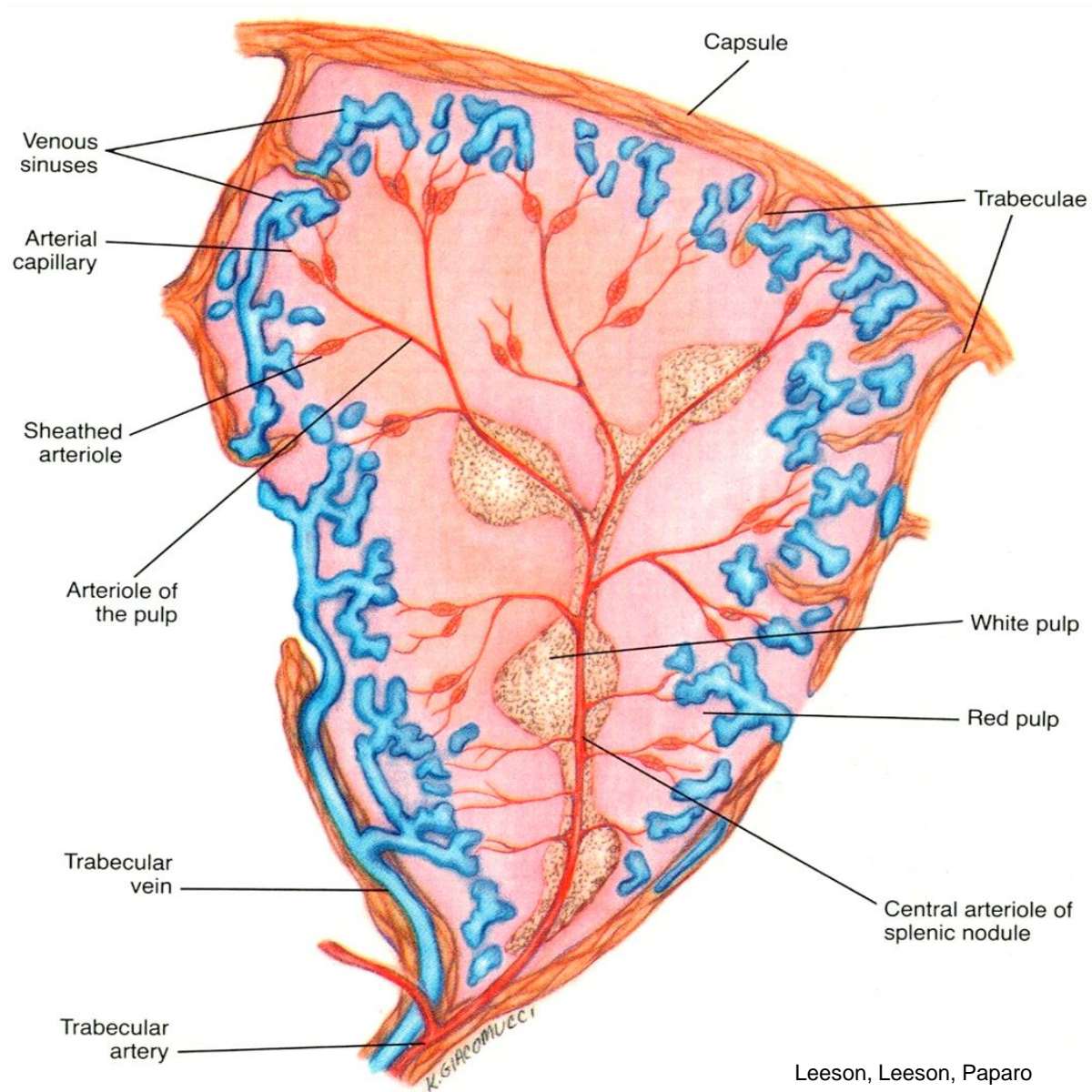
Venous sinus

Reticular cell

Cells in circulation



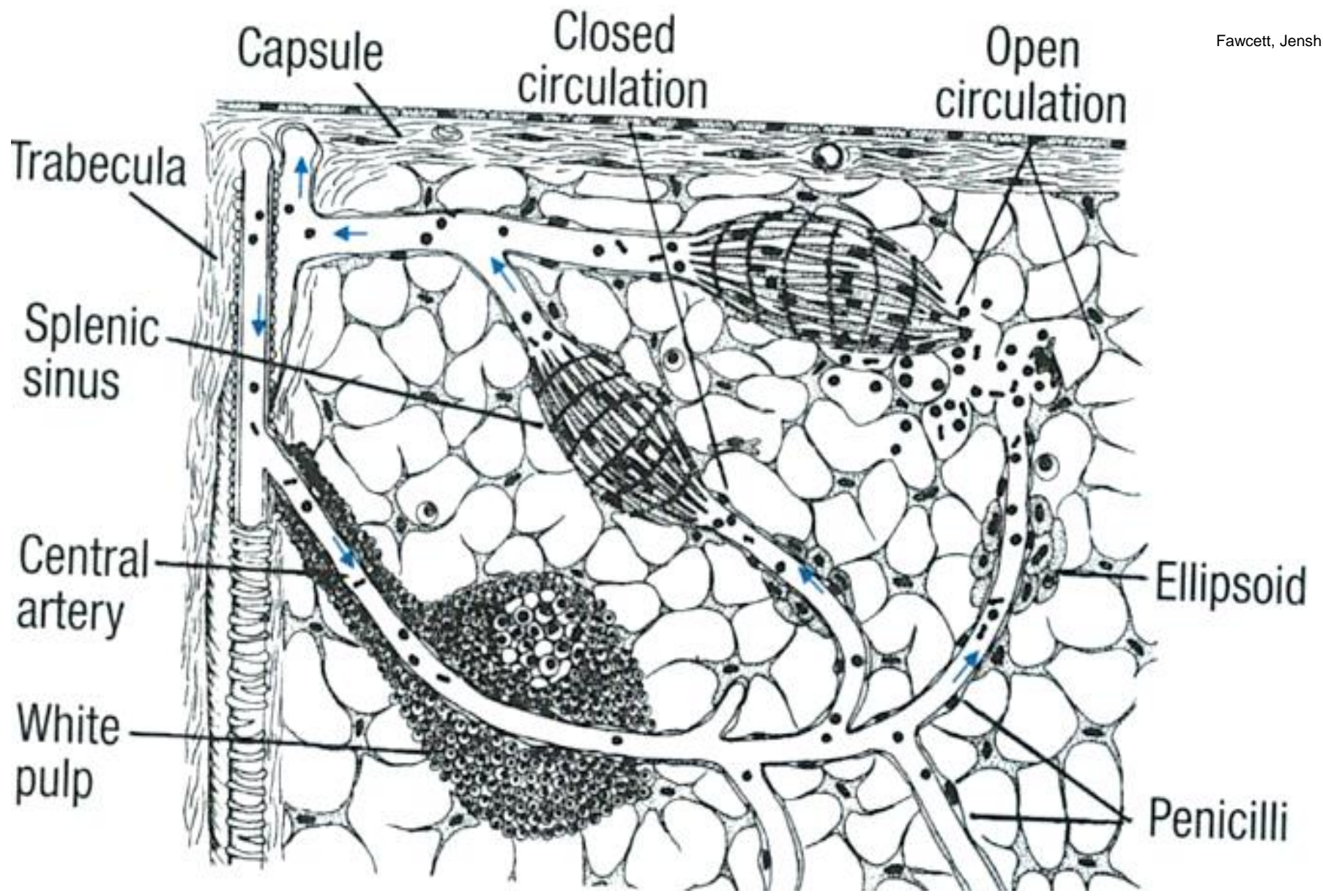
SPLEEN BLOOD CIRCULATION



- a. lienalis
- aa. trabeculares
- aa. centrales
- arteriolae penicillatae
- (*arteriole of the pulp, sheathed arteriole*)
- venous sinuses
- veins of the pulp
- vv. trabeculares
- v. lienalis

SPLEEN – OPEN AND CLOSED CIRCULATION

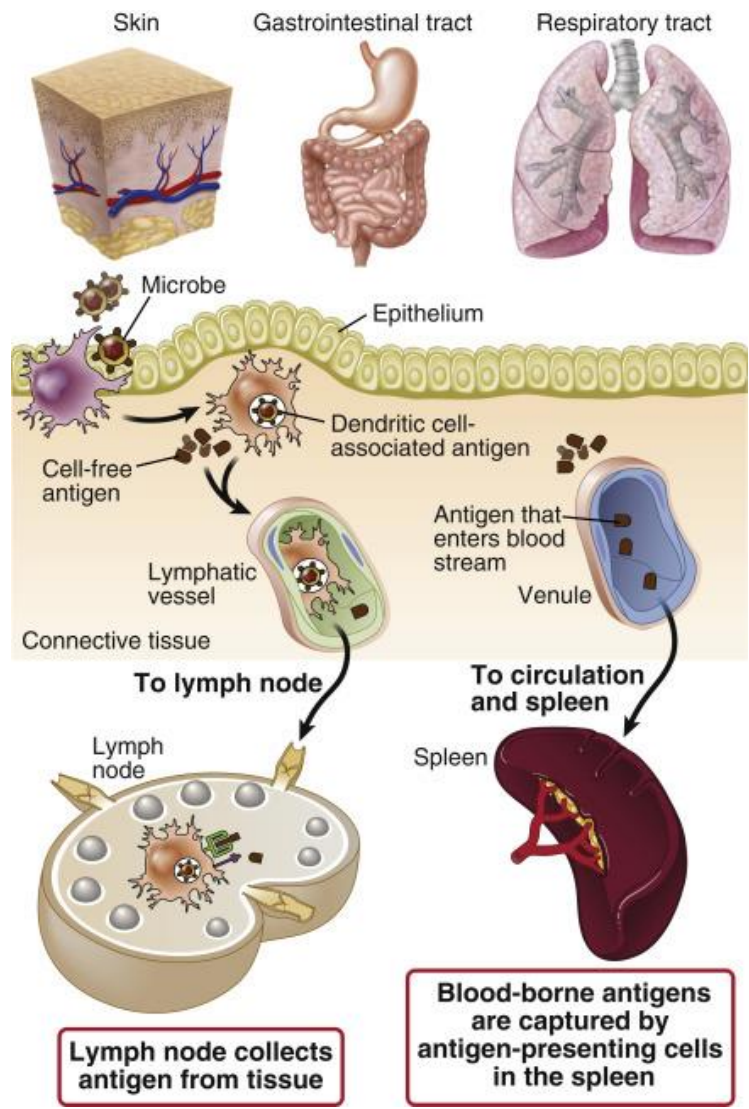
Fawcett, Jensch



SPLEEN AND LYMPH NODE IN ANTIGEN RECOGNITION

Lymph node

Spleen

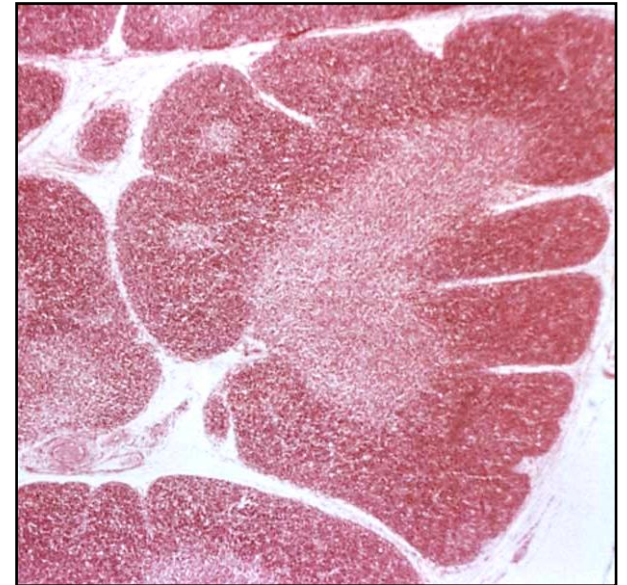
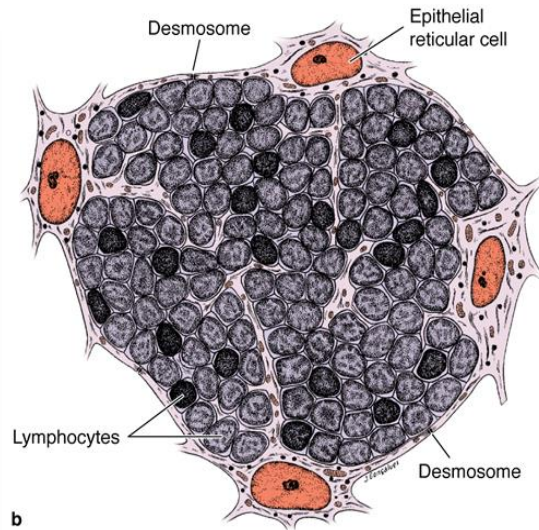
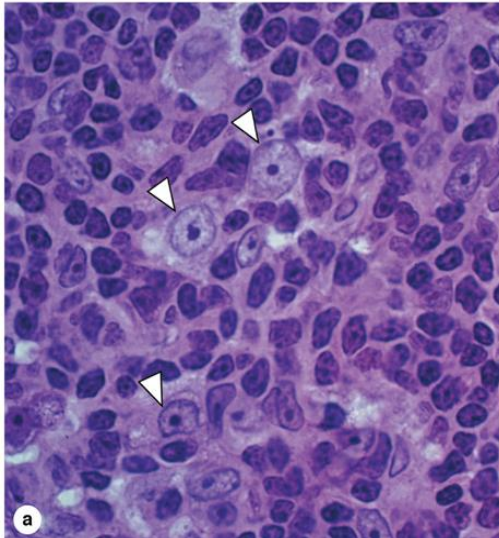
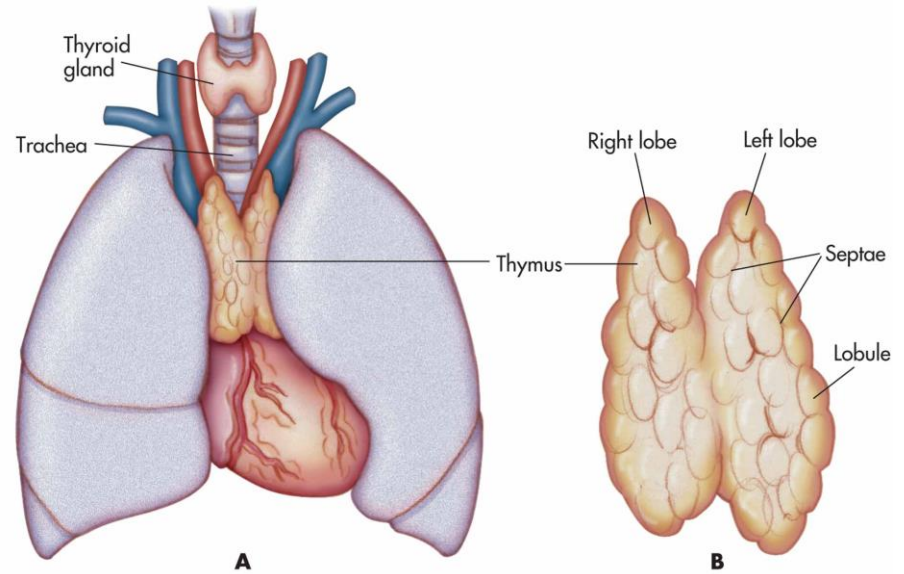


Lymph filter

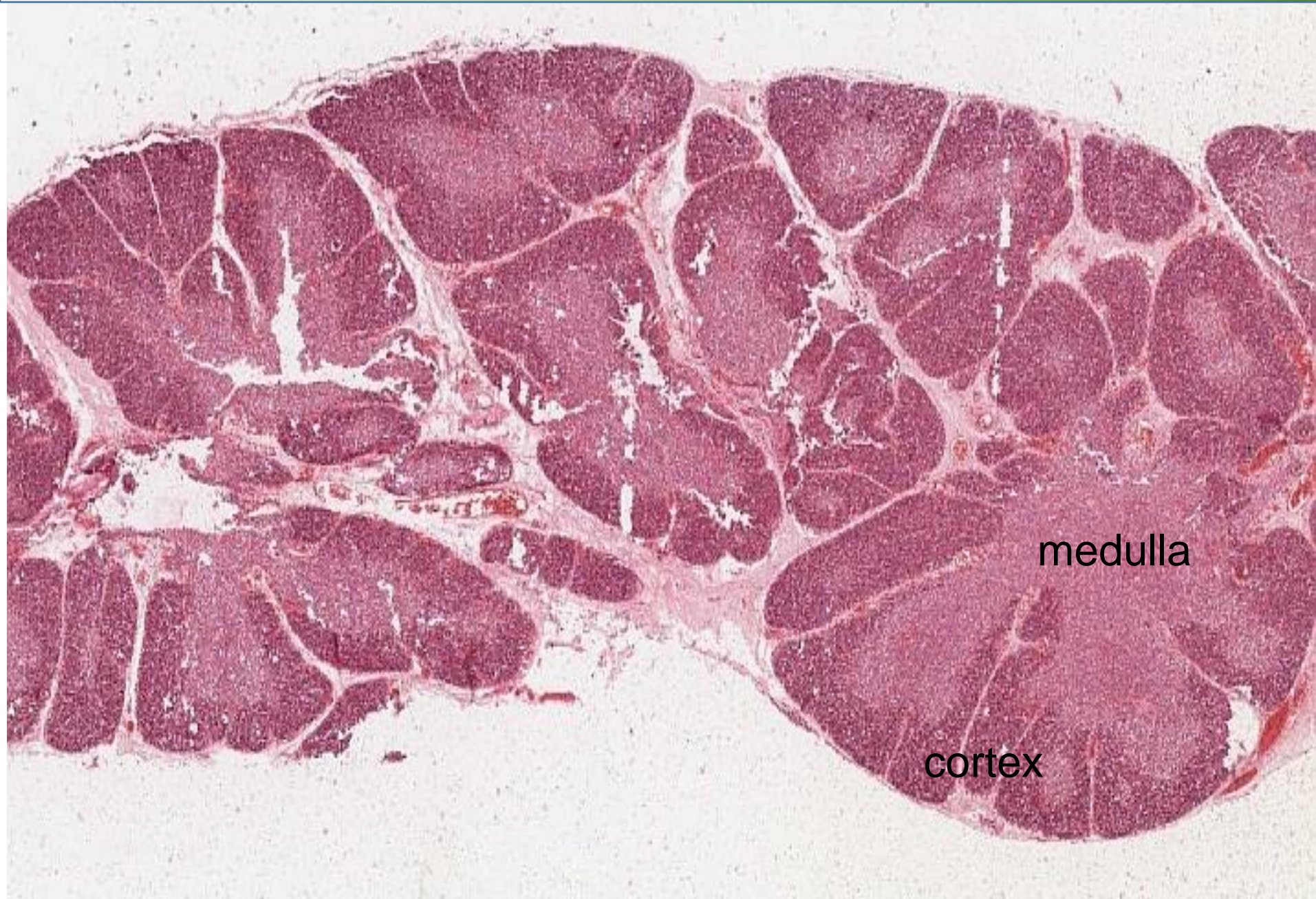Blood filter

THYMUS

- c.t. capsule
- parenchyma: cortex and medulla
- epithelial reticulum and T-cells
- Hassal bodies



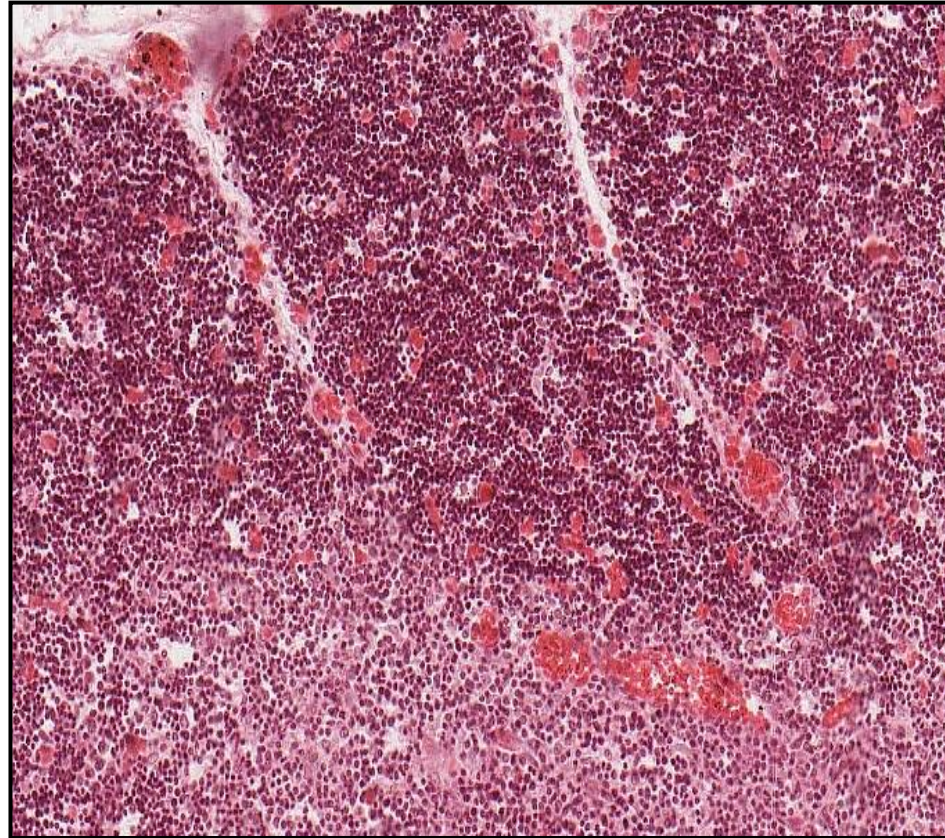
THYMUS (YOUNG)



THYMUS (CORTEX)

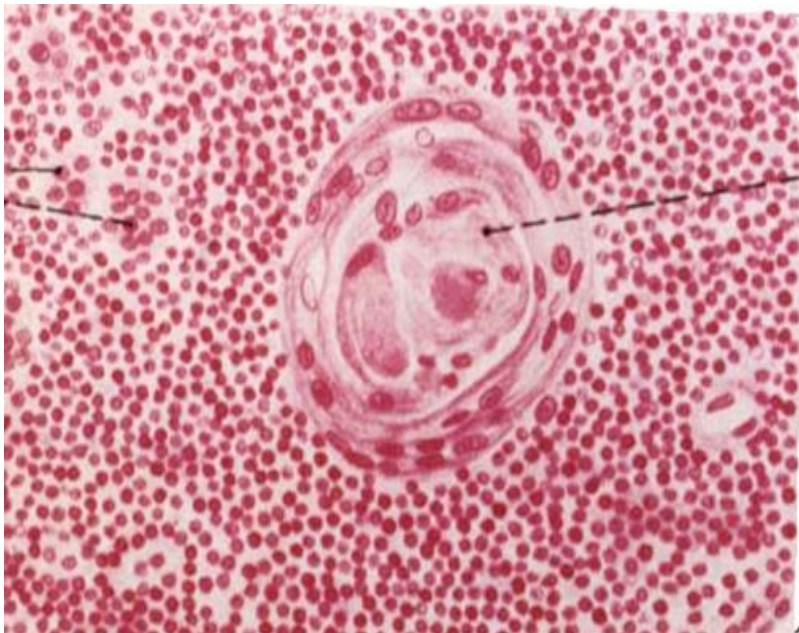
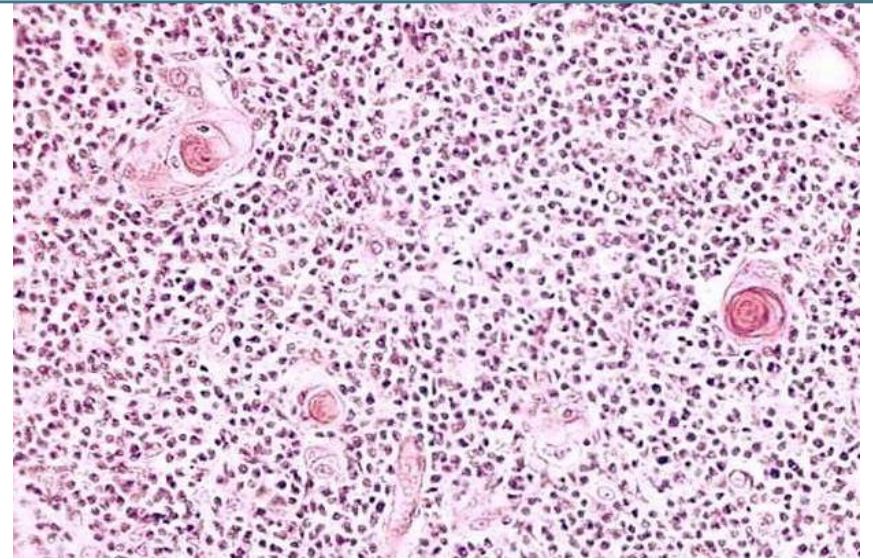
Cortex:

- T-cell proliferation, acquisition of **immunocompetence**
- **positive selection** (functional TCR → survival)
- **hemato-thymic barrier** (endothelium + basal lamina + cell of cytoteticulum)
- prevents premature contact with antigens

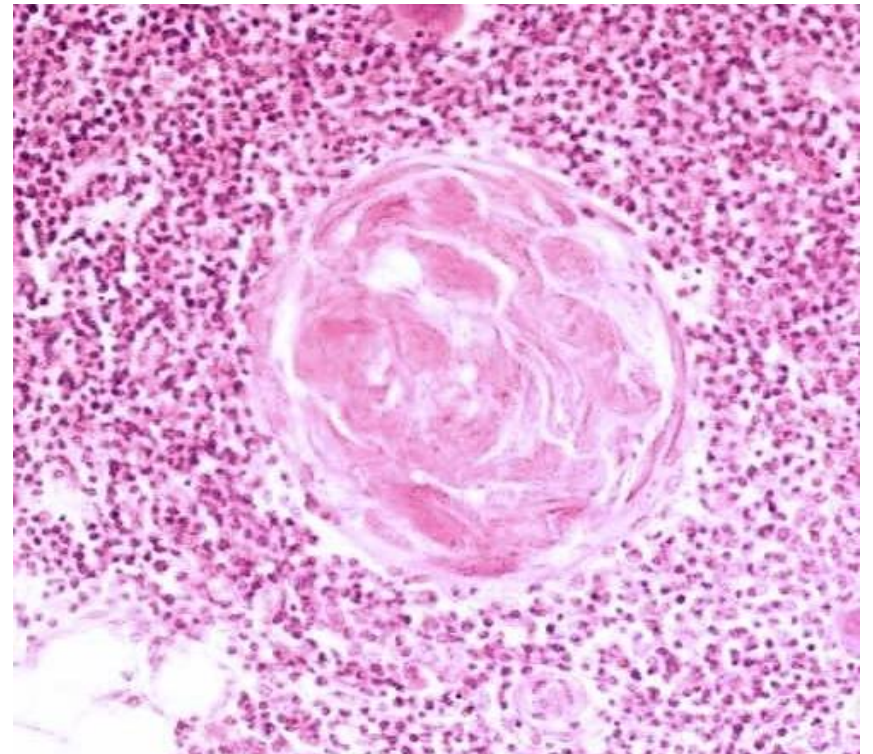


THYMUS (MEDULLA)

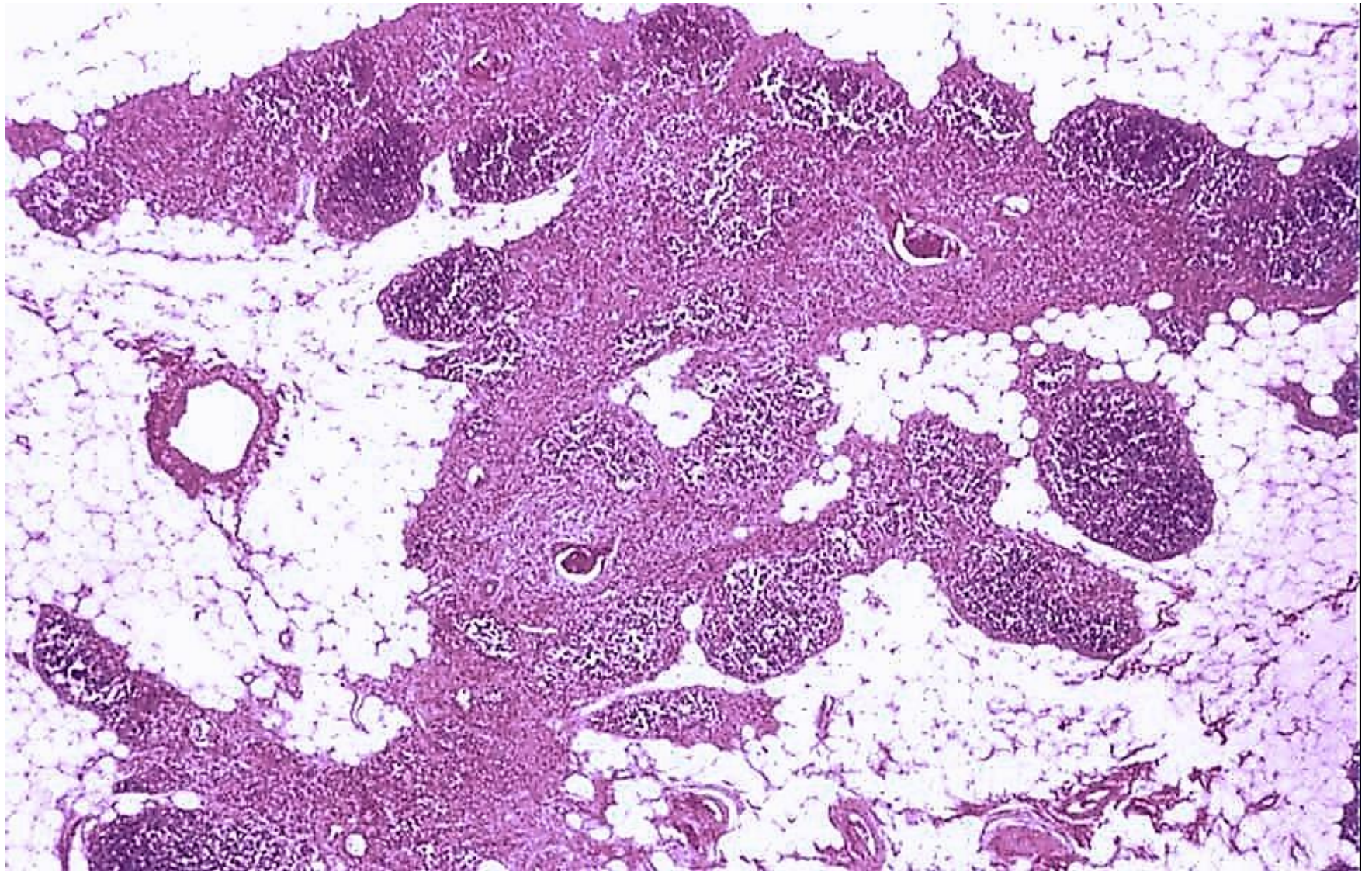
- negative selection – prevention of autoimmune reaction
- overall survival 2-3%
- cytotreticulum
- hemato-thymic barrier absent



Hassal bodies in medulla



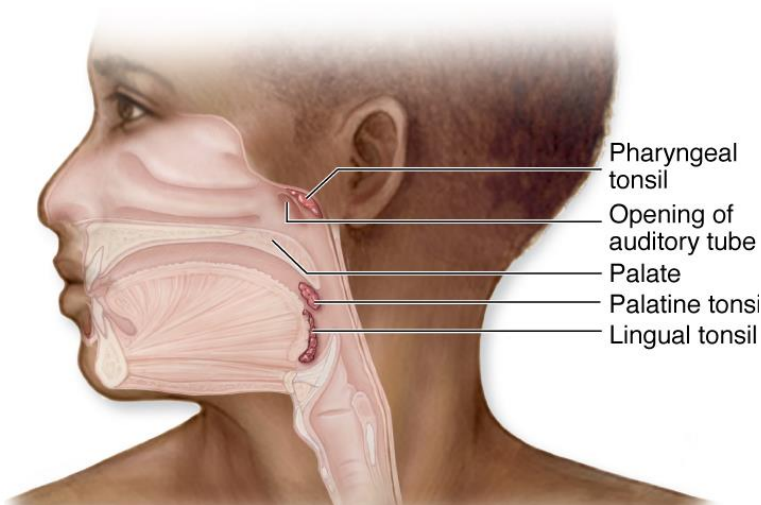
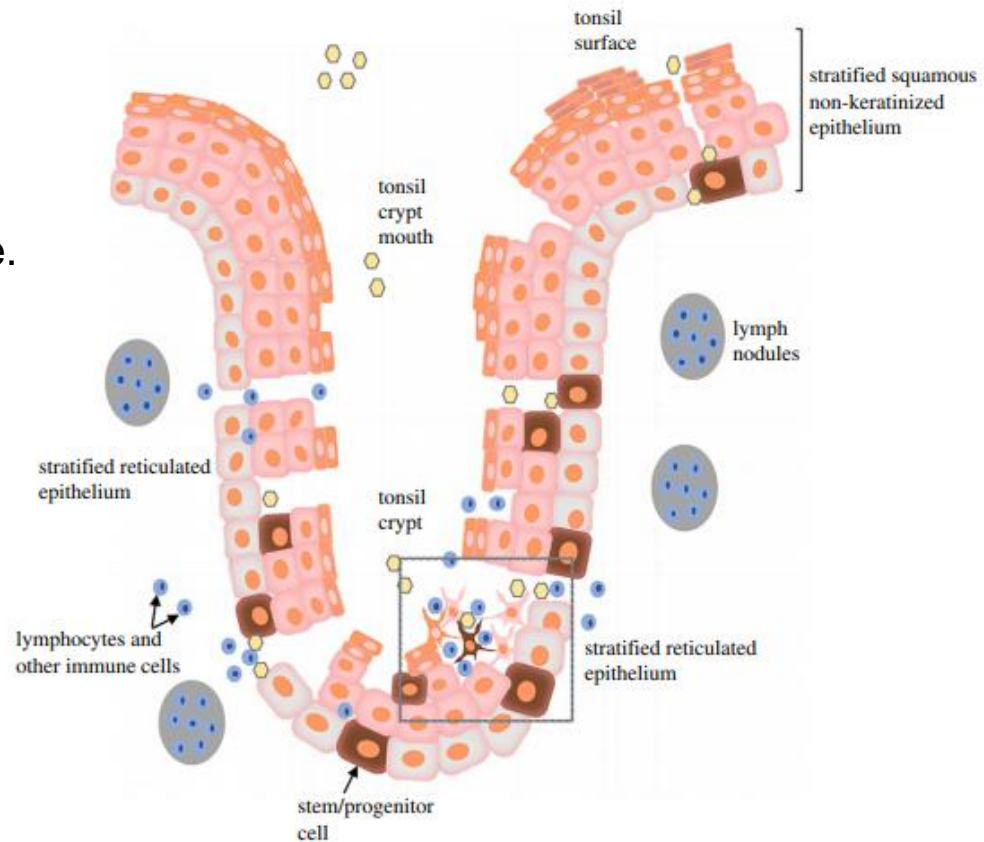
THYMUS (INVOLUTION)



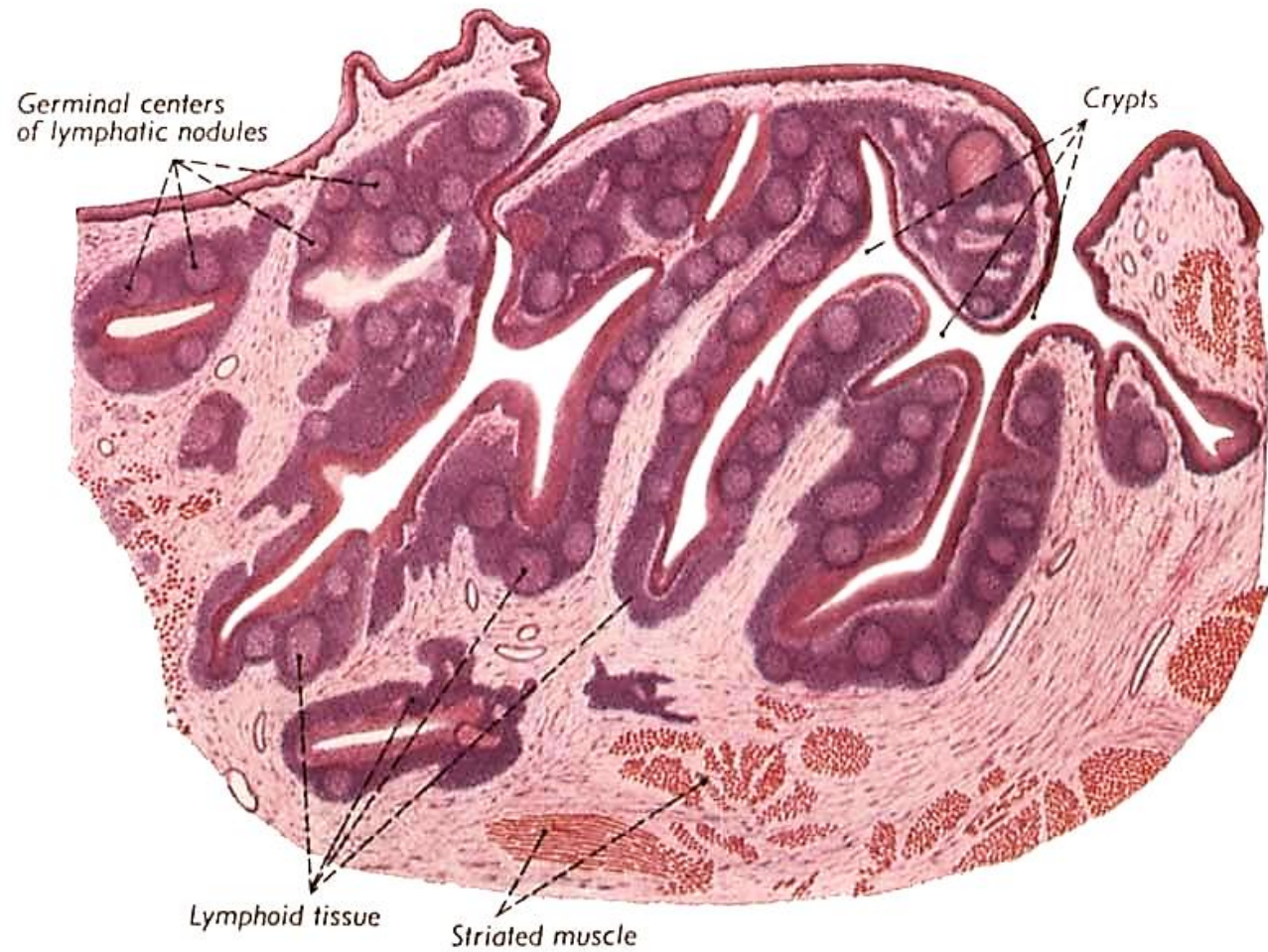
TONSILS

- incomplete encapsulation by connective tissue
- aggregations of lymphatic tissue (follicles) covered by epithelium of crypt
- crypts – deep and branched invaginations lined by epithelium
- reticulated (follicle associate) epithelium

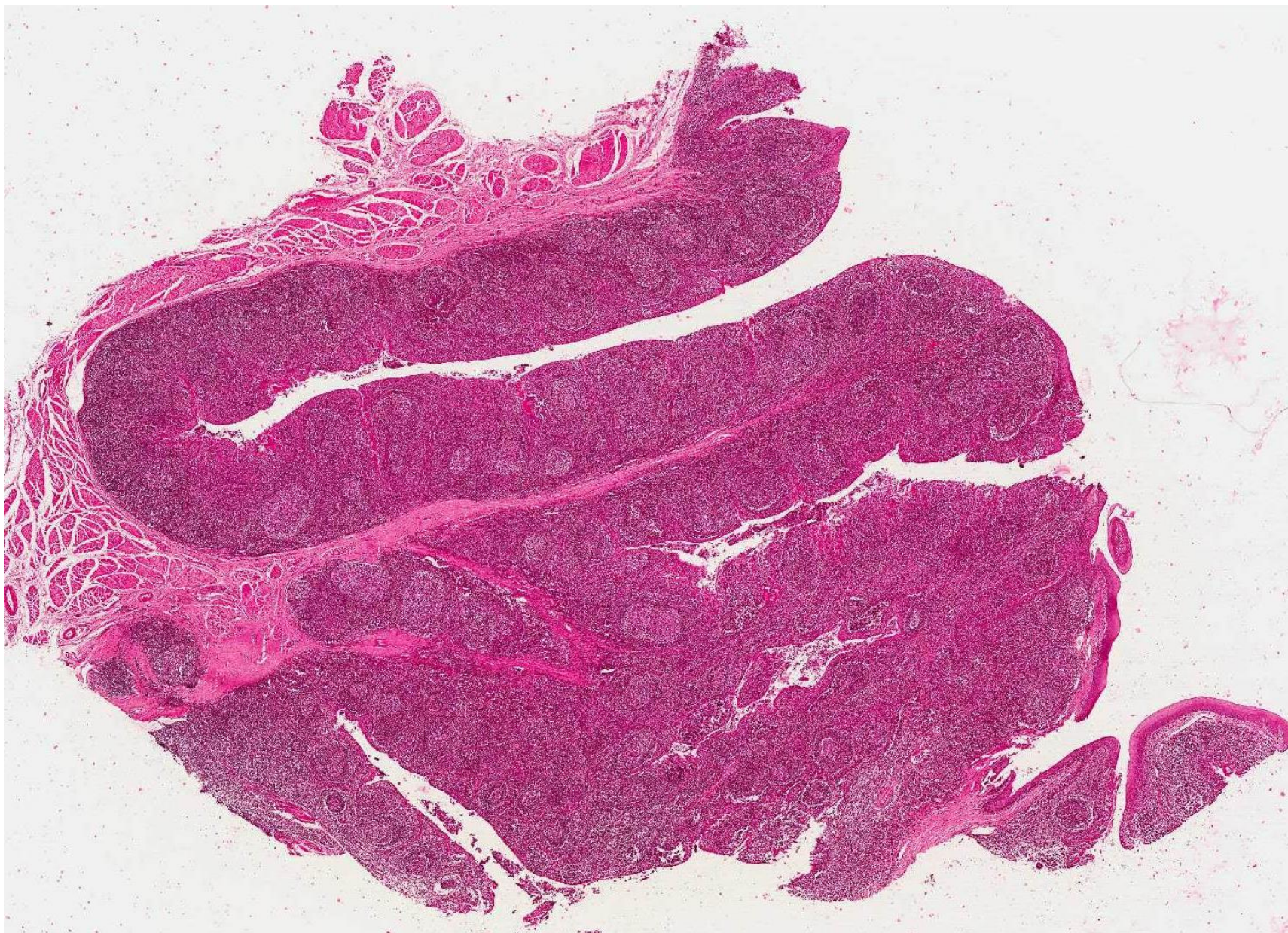
- **t. palatina** – stratified squamous e.
- **t. lingualis** – stratified squamous e.
- **t. pharyngea** – pseudostratified columnar e.
- **t. tubaria** – pseudostratified columnar e.



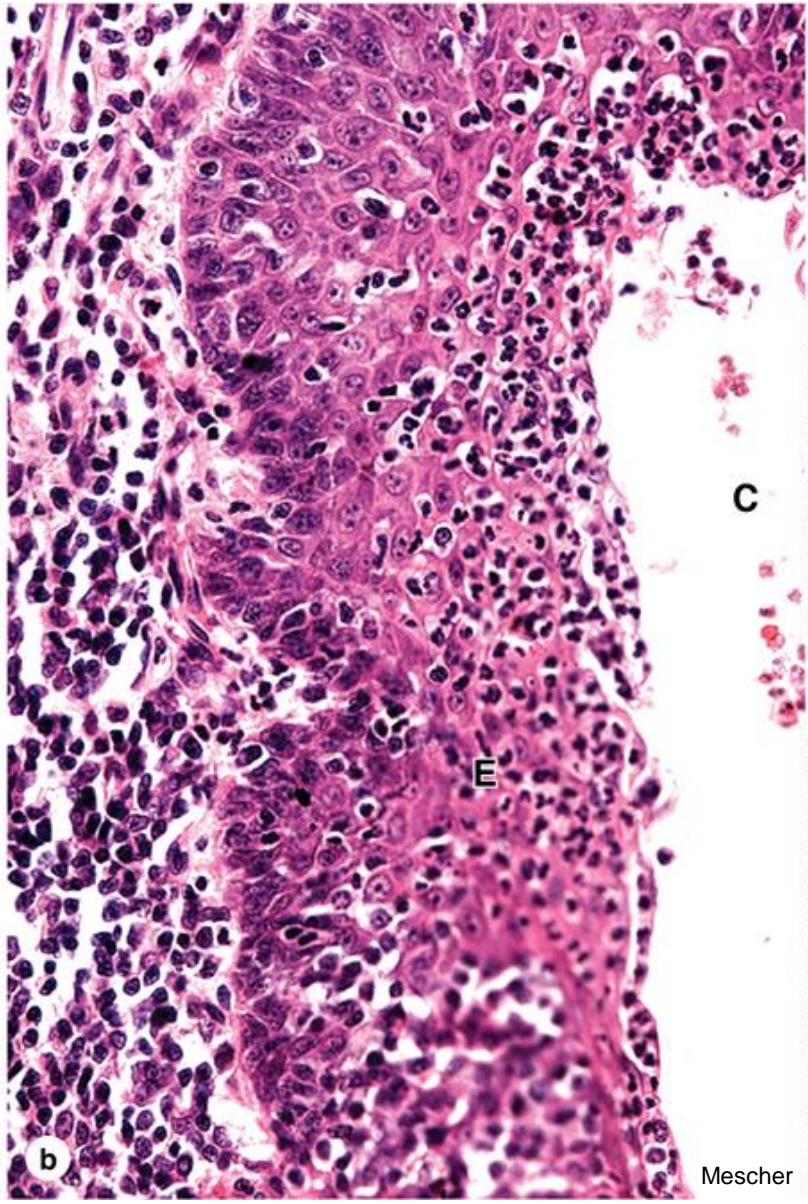
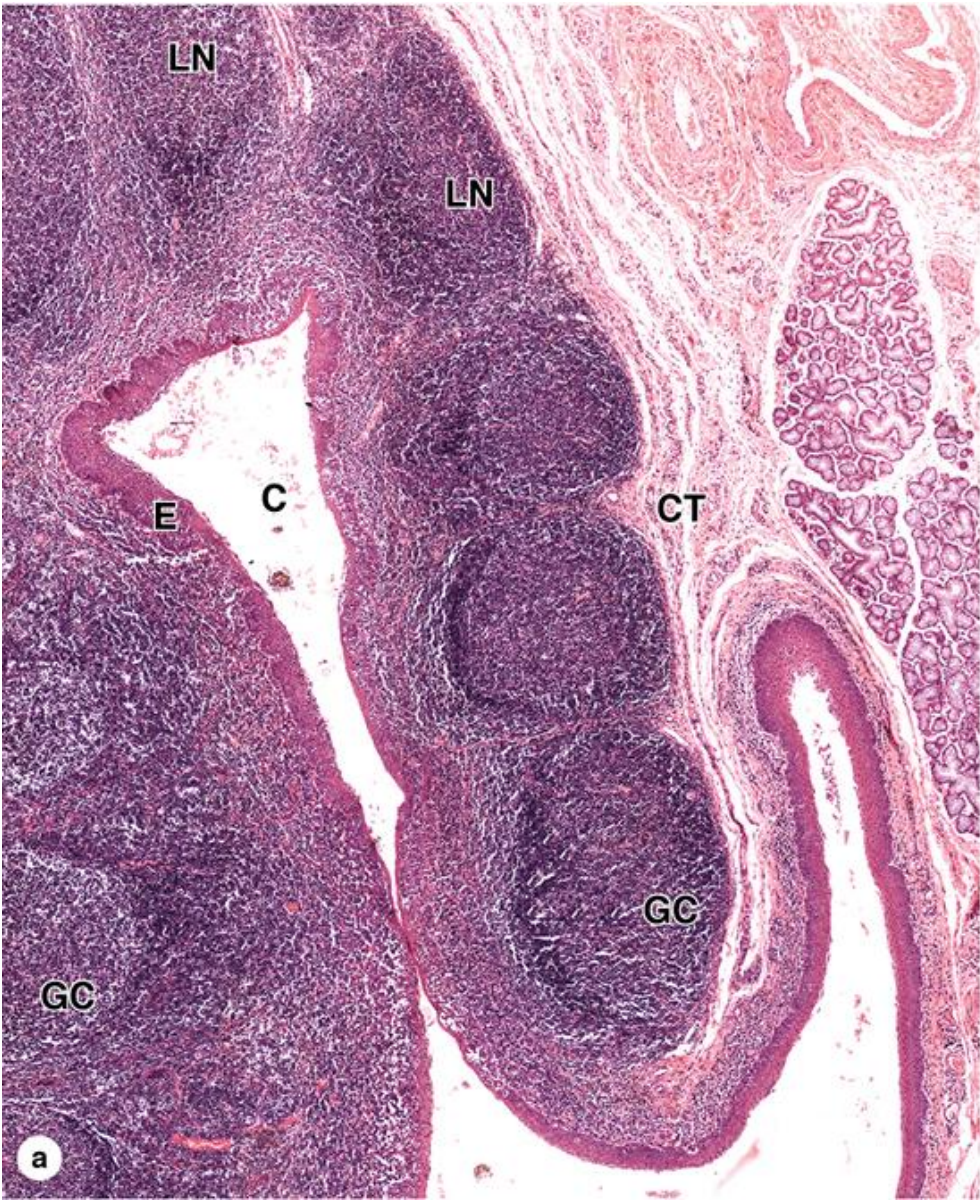
TONSILLA PALATINA



TONSILLA PALATINA



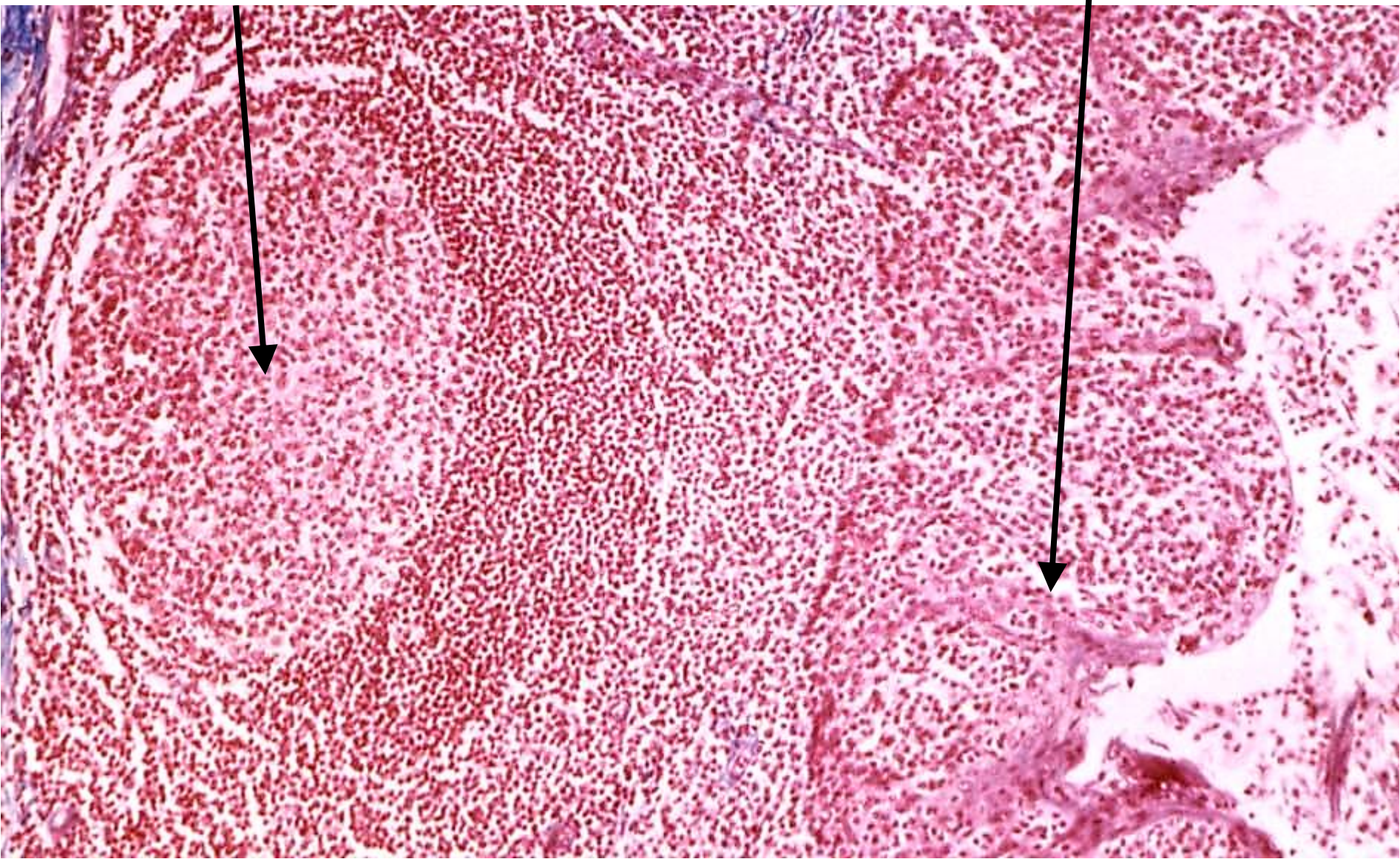
TONSILLA PALATINA



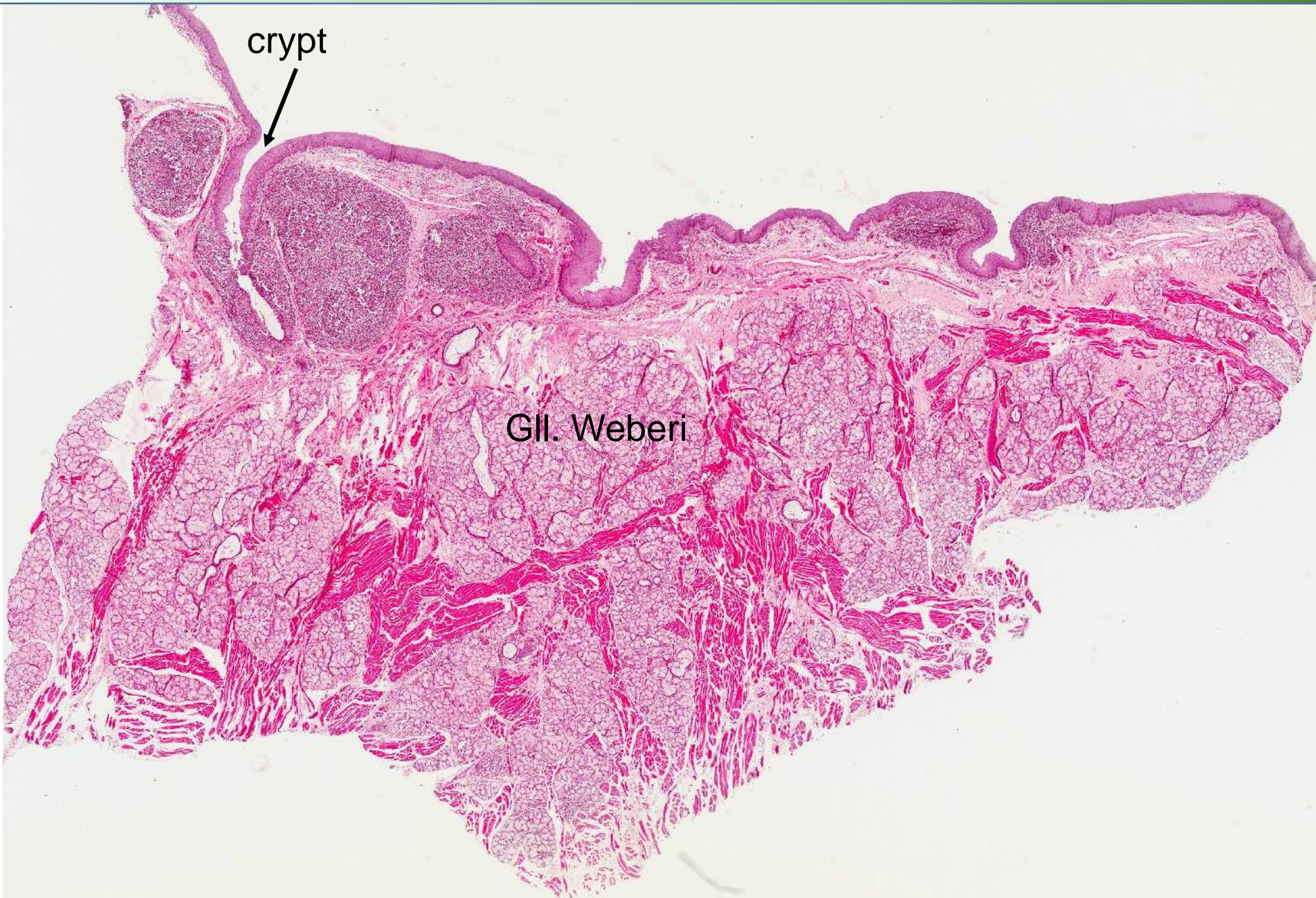
TONSILLA PALATINA

lymphatic follicle

reticulated epithelium



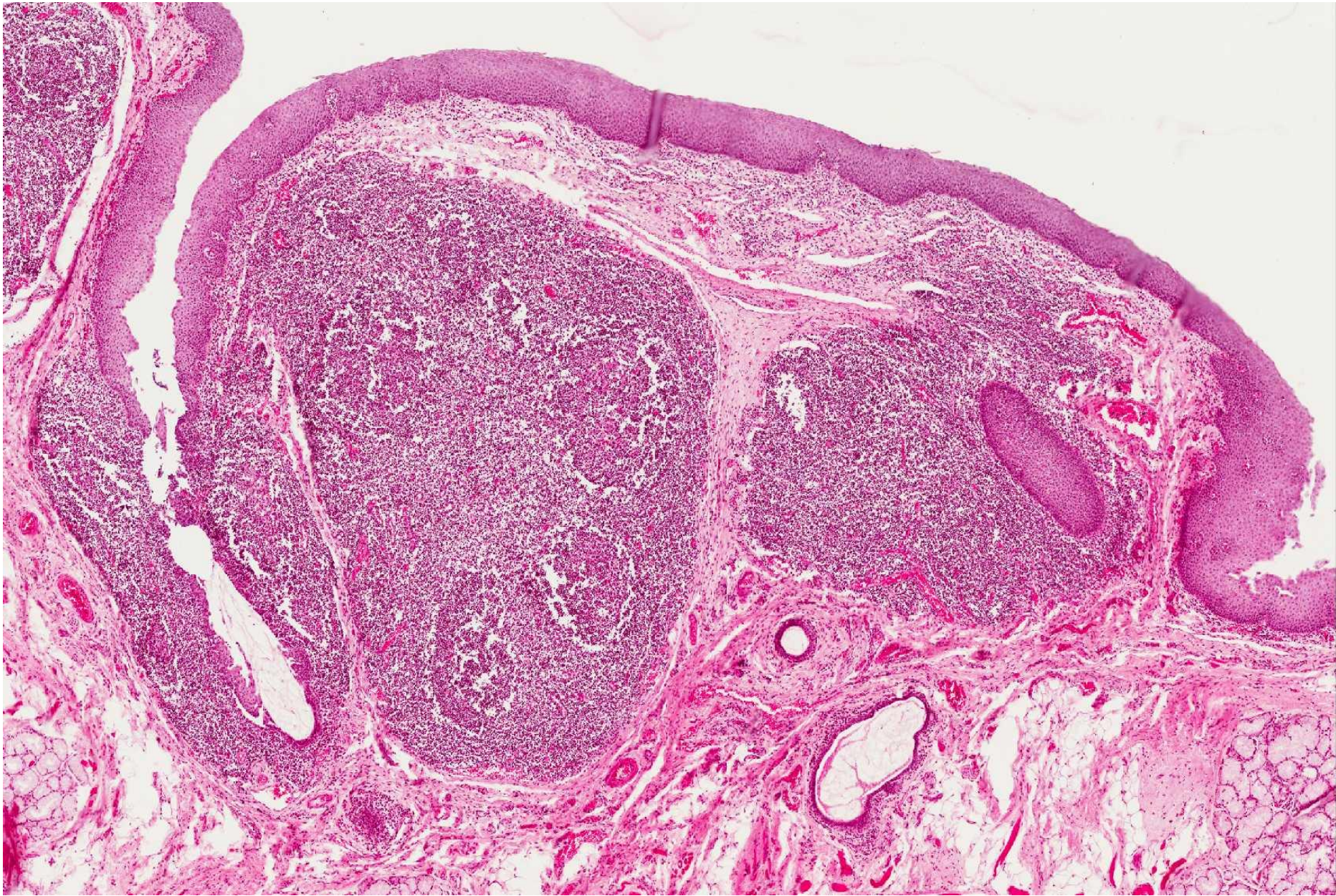
TONSILLA LINGUALIS



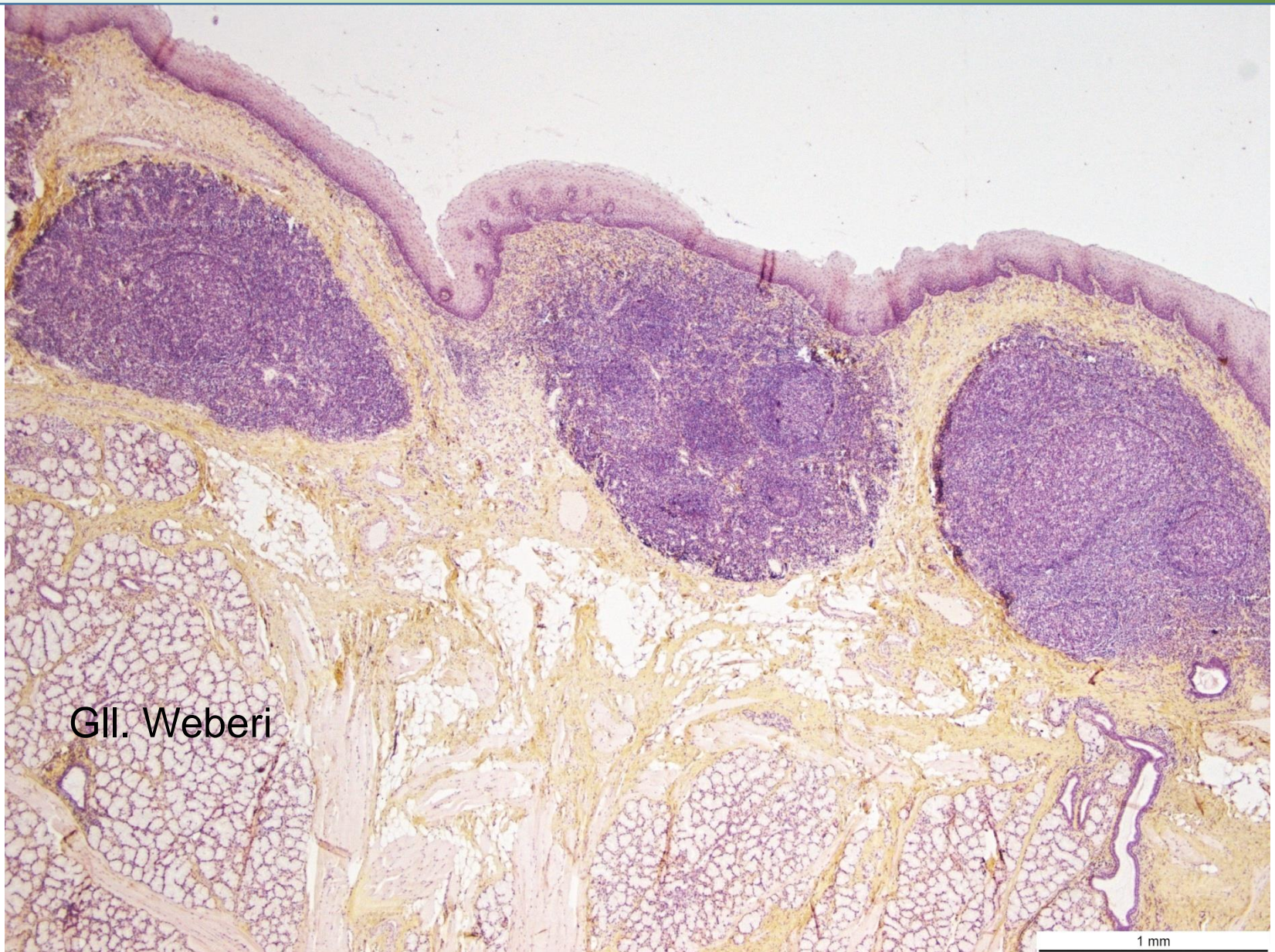
crypt

GII. Weberi

TONSILLA LINGUALIS

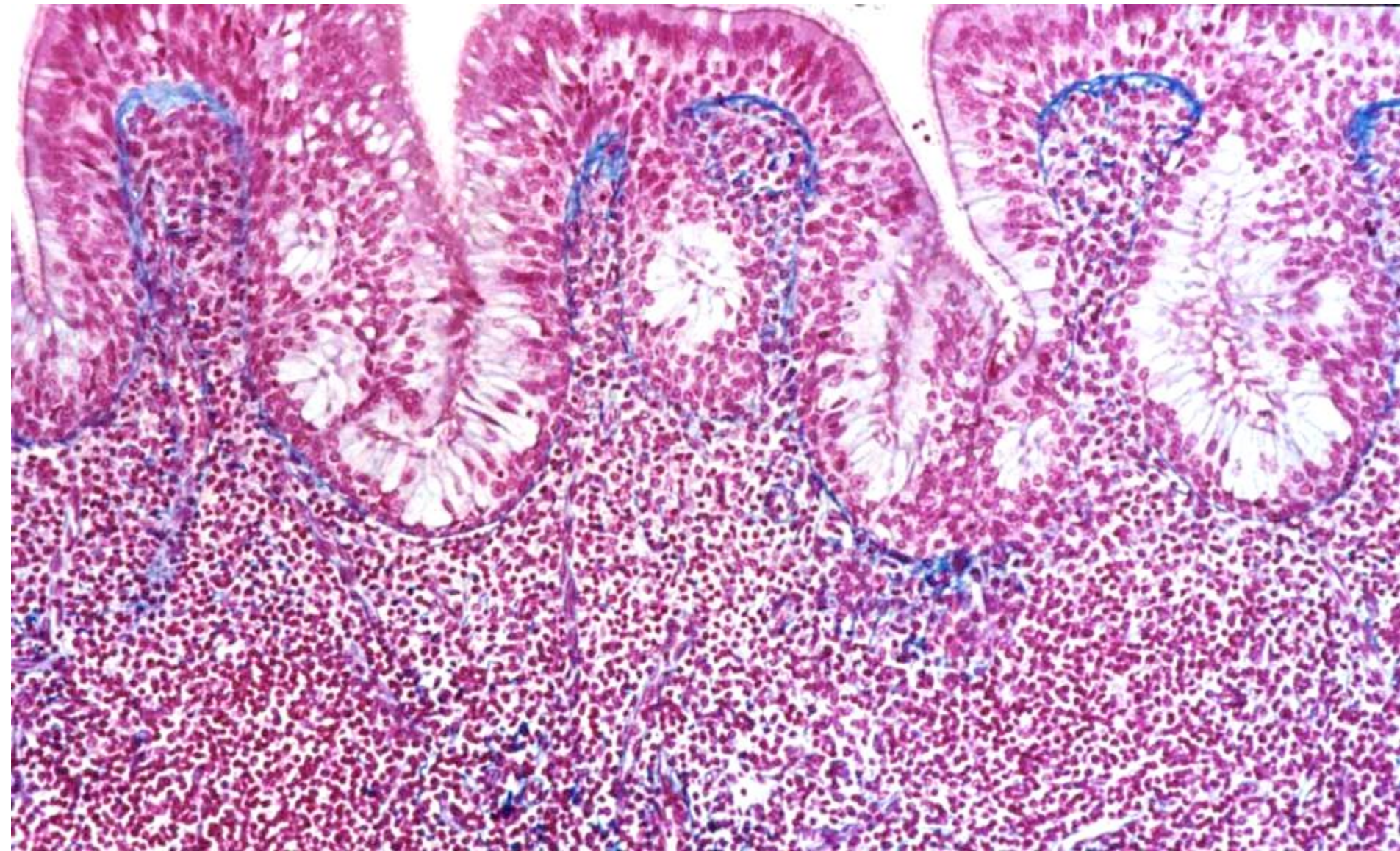


TONSILLA LINGUALIS



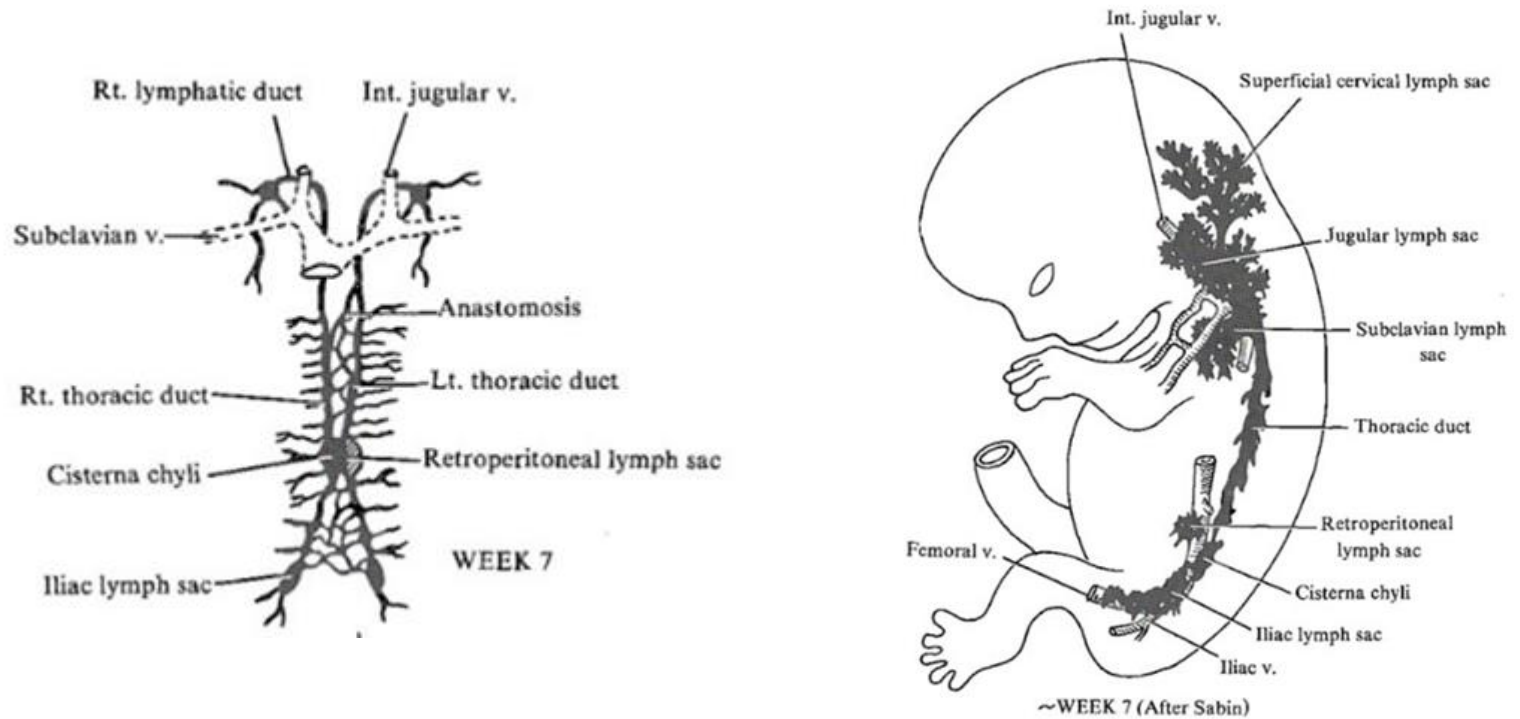
Gll. Weberi

TONSILLA PHARYNGEA



DEVELOPMENT OF LYMPHATIC SYSTEM

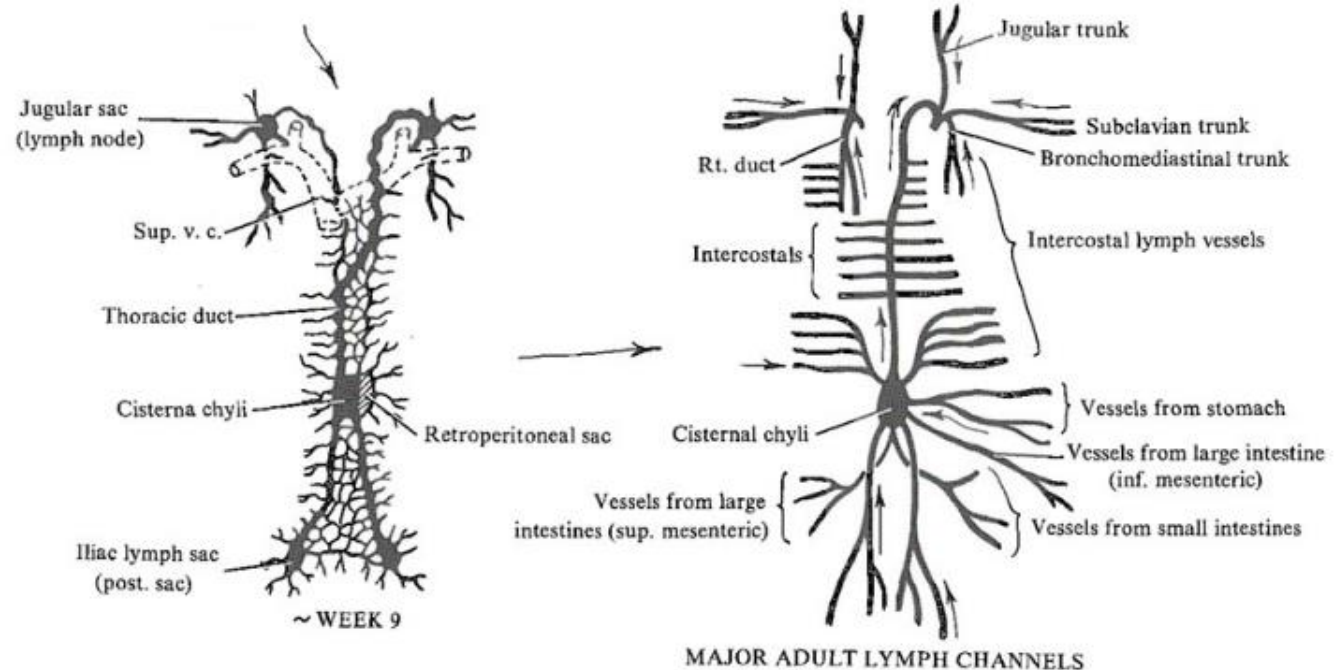
- Development starts at week 5
- Origin unclear, presumably from mesenchyme or as outgrowths of primitive endothelium



- **Week 6-9**, six primary lymph sacs from local dilatations
 1. **Two** jugular (junction of the subclavian veins with the v. precardinales (→ v. jugularis int.)
 2. **Two** iliac lymph sacs near the junction of the iliac veins with the v. postcardinales
 3. **Single** retroperitoneal lymph sac
 4. **Single** cisterna chyli dorsal to the retroperitoneal lymph sac

DEVELOPMENT OF LYMPHATIC SYSTEM

- **Lymph vessels grow from lymph sacs**
 - jugular: head, neck, thorax, upper limbs
 - iliac: trunk, lower limbs
 - retroperitoneal and cisterna chyli: intestine
- **Development of lymphatic ducts**
 - left and right thoracic duct connecting c. chyli and jugular sacs
 - anastomoses
 - D. thoracicus: caudal part of right thoracic duct, cranial part of left thoracic duct
 - D. lymphaticus dx.: cranial part of right thoracic duct



DEVELOPMENT OF LYMPHATIC SYSTEM

• Development of lymph nodes

- lymph sacs (except for c. chyli) are invaded by mesenchymal cells and constitute apparent clusters of lymph nodes
- B-cell compartments (follicles) develop around birth, lack germinative centers (naive)
- lymph nodes develop along lymph vessels by similar mechanism

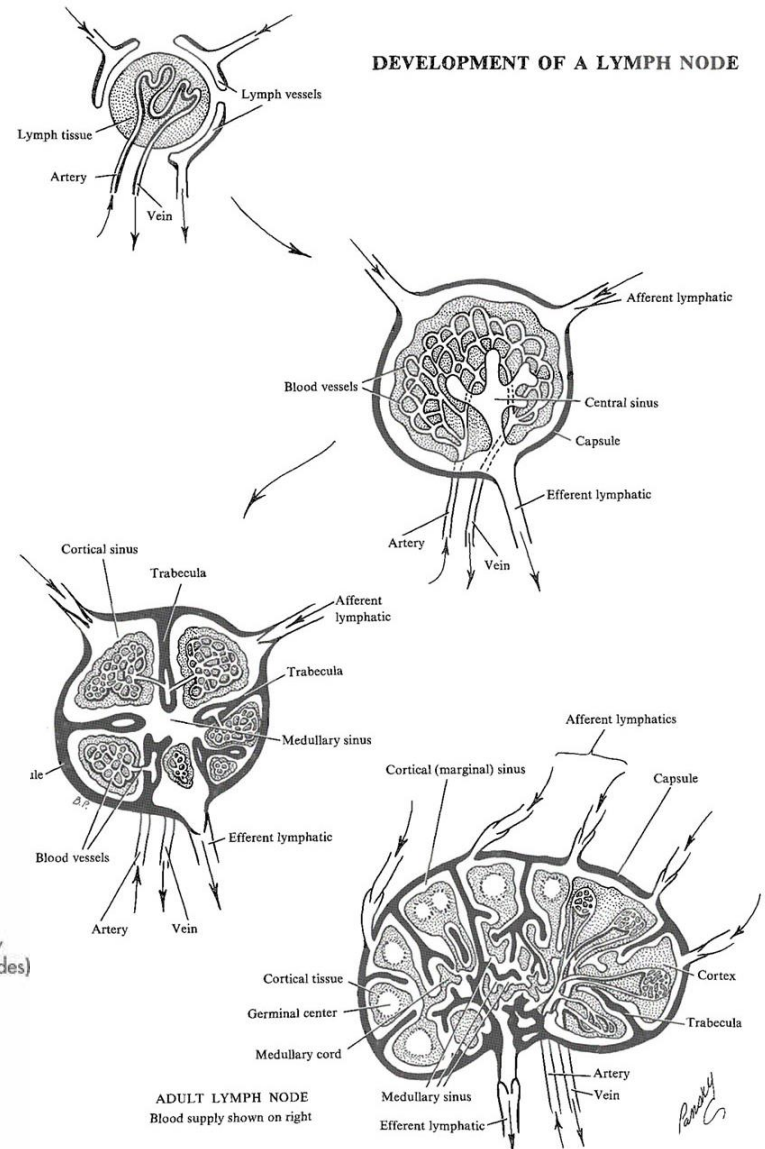
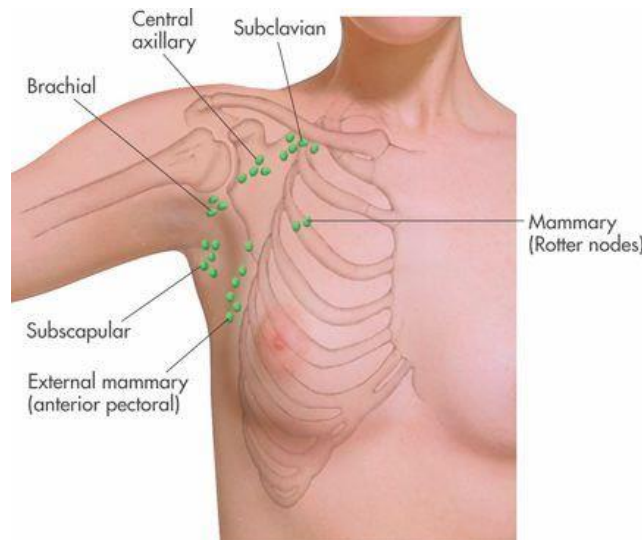
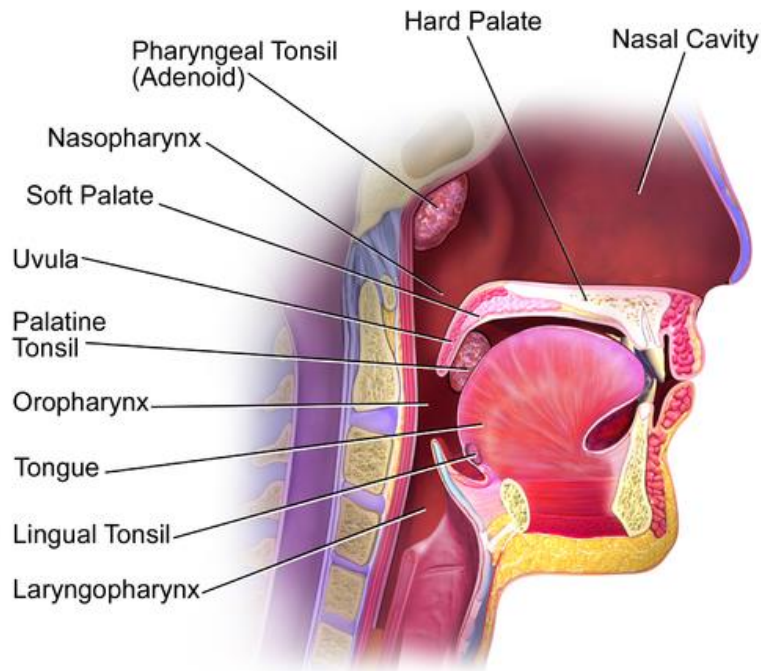


FIGURE 55. Development of a lymph node.

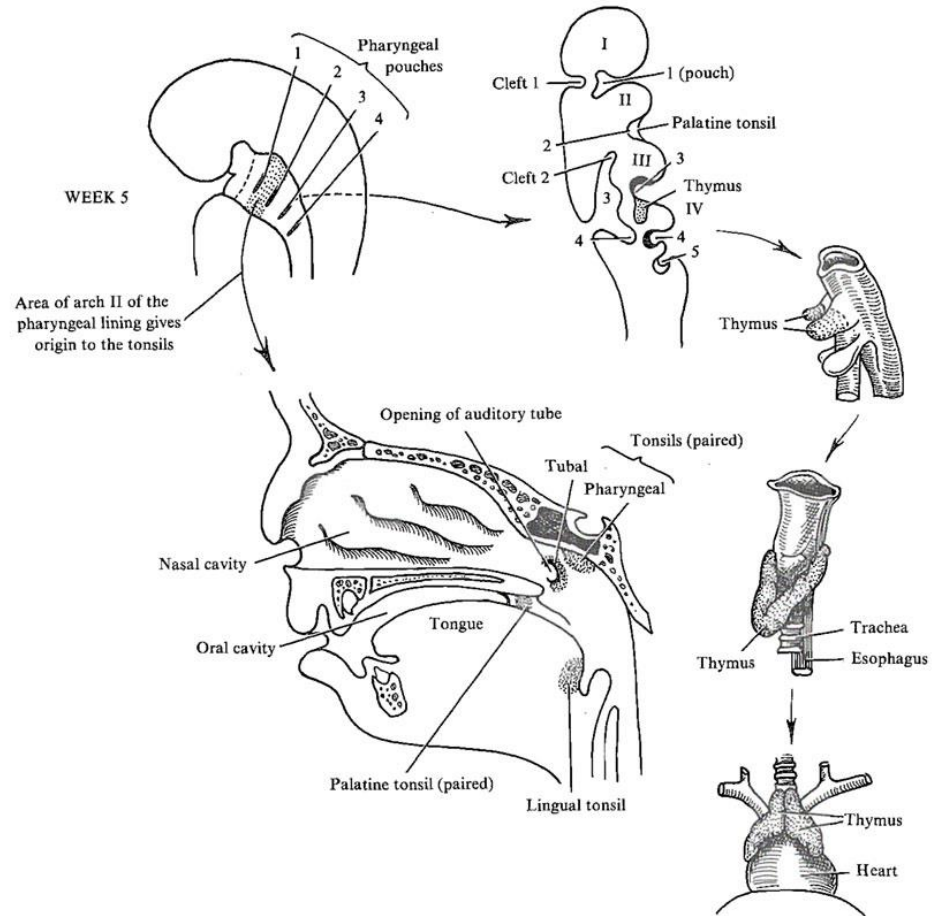
DEVELOPMENT OF TONSILS AND THYMUS

- **Tonsilla palatina**
 - second pharyngeal pouch (fossa)
- **Tonsilla pharyngea, tubaria and lingualis**
 - aggregation of lymph nodules in the nasopharyngs, by opening of tuba auditiva or lingual root
- **Thymus**
 - third pharyngeal pouch



Tonsils and Throat

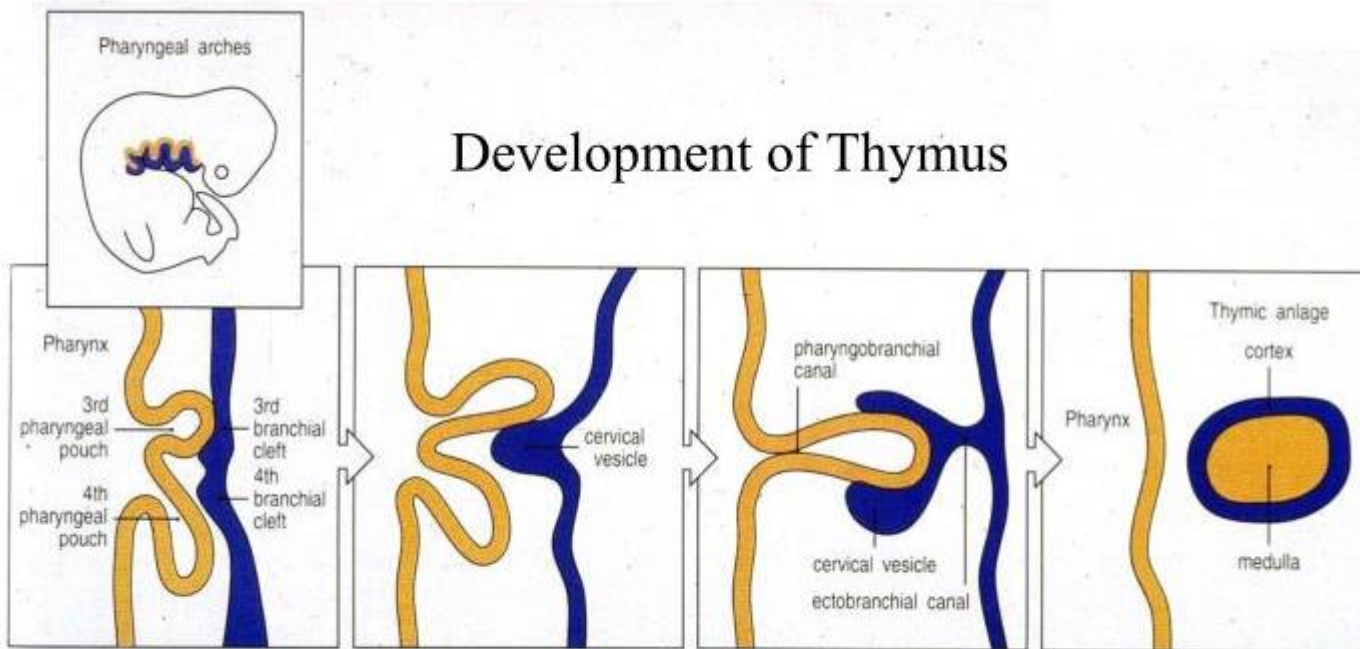
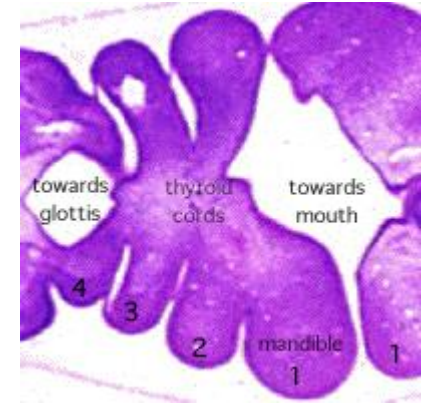
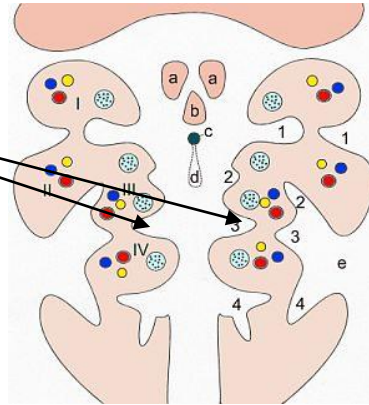
DEVELOPING TONSILS AND THYMUS GLAND



DEVELOPMENT OF THYMUS

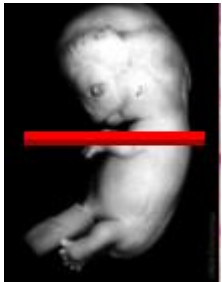
- **Thymus**

- third pharyngeal pouch



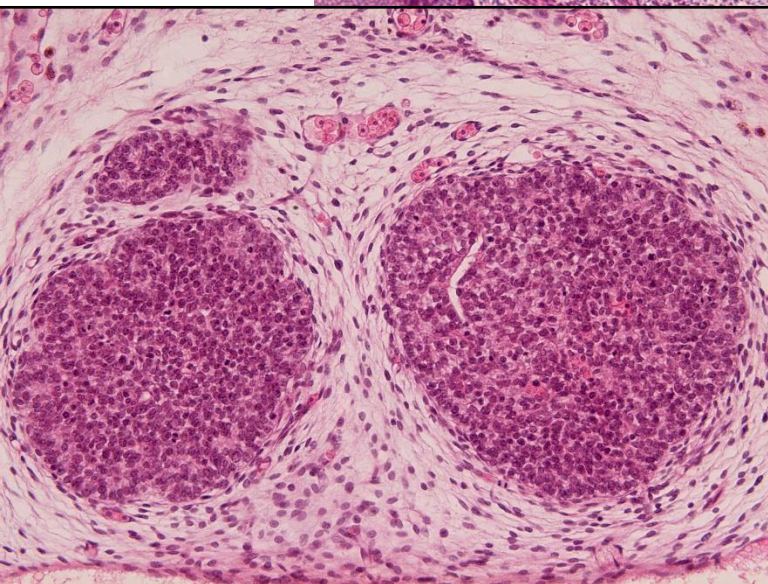
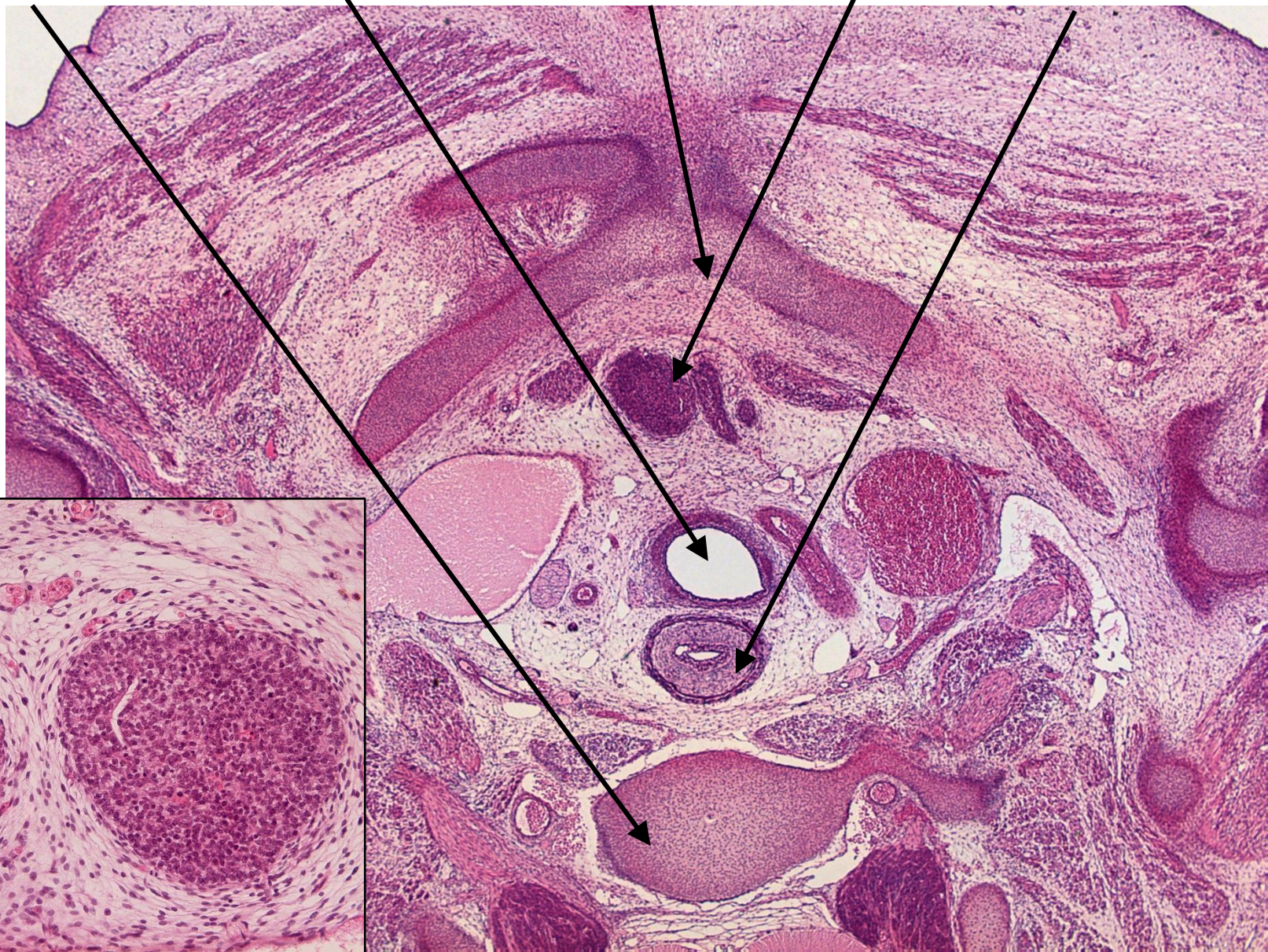
Bone marrow cells colonize thymic anlage in fetus

DEVELOPMENT OF THYMUS



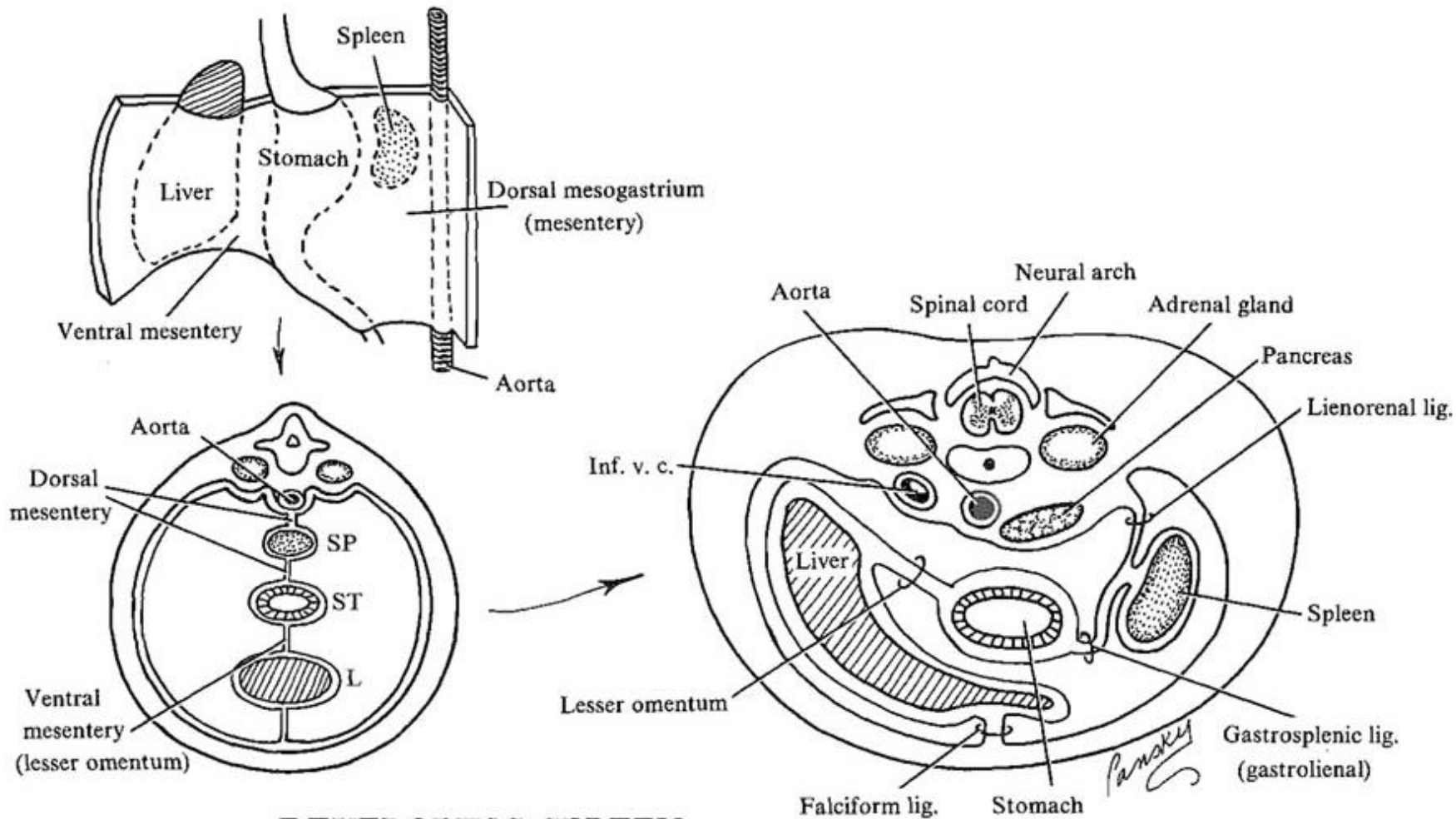
Week 8

Vertebral cartilage trachea sternum and ribs thymus esophagus



DEVELOPMENT OF SPLEEN

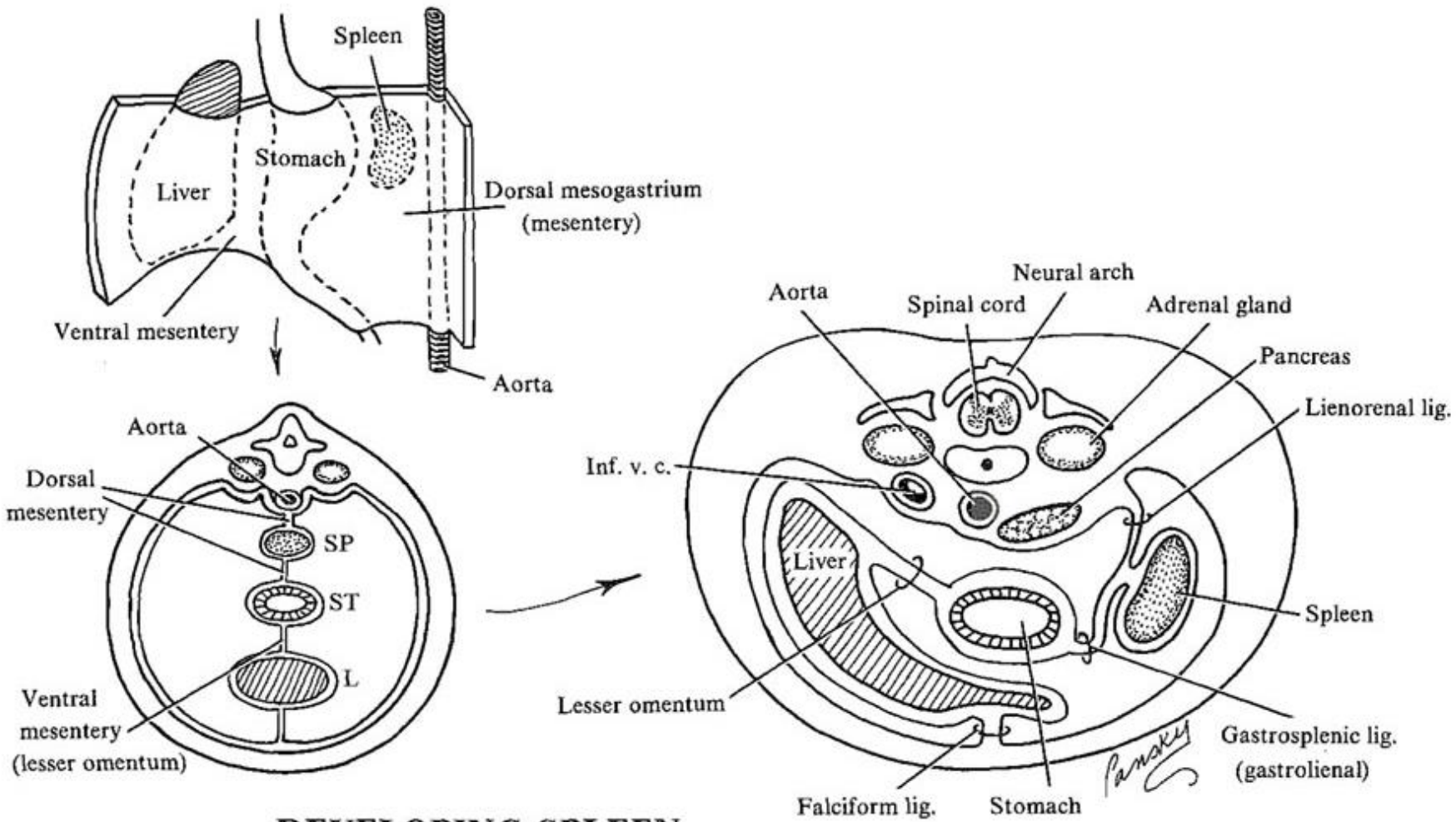
- Dorsal mesentery of stomach
- Mesenchymal origin



DEVELOPING SPLEEN

DEVELOPMENT OF SPLEEN

- Dorsal mesentery of stomach
- Mesenchymal origin



DEVELOPING SPLEEN

DEVELOPMENT OF SPLEEN

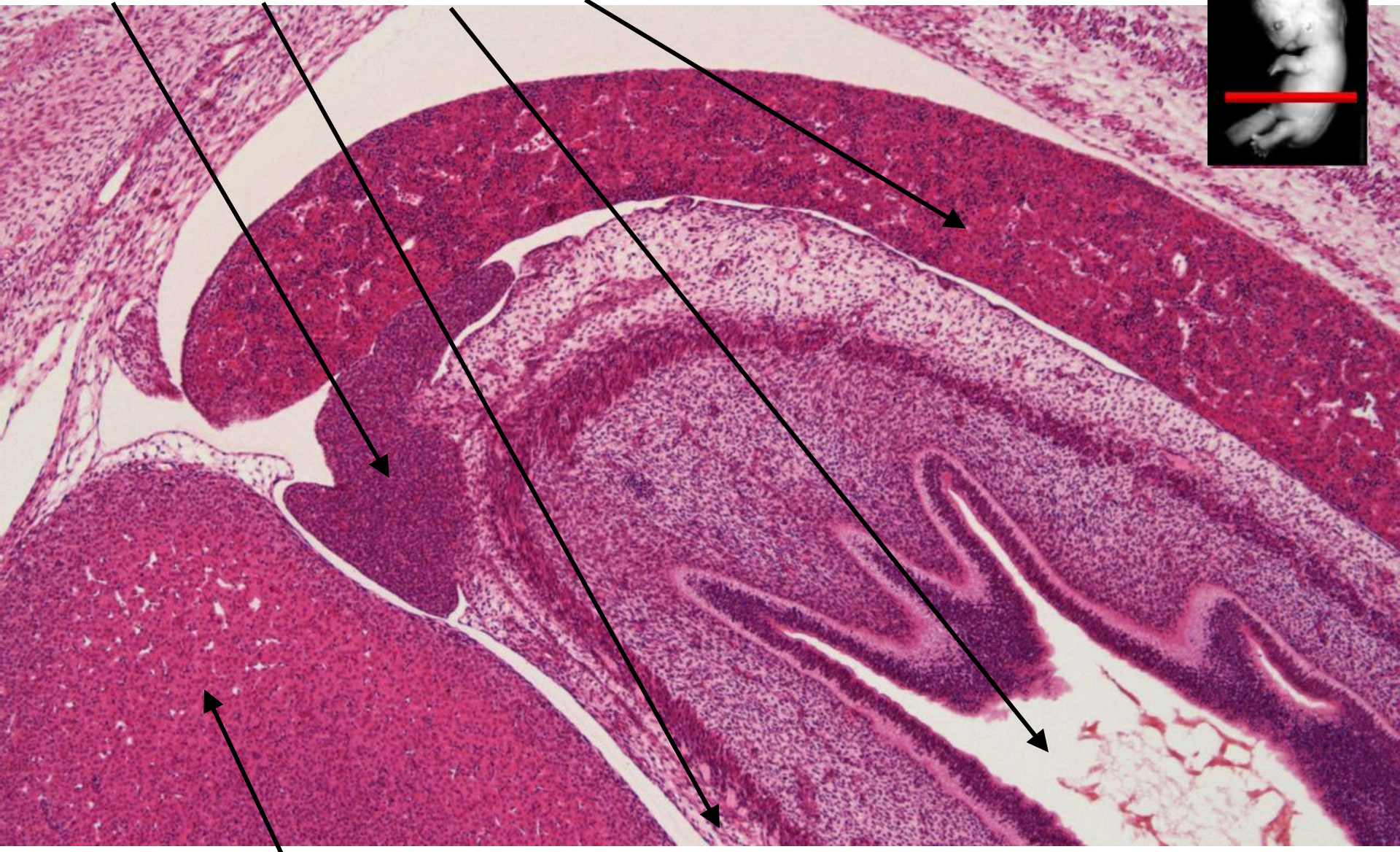
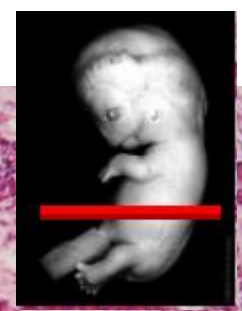Spleen

Pancreas

Stomach

Liver


Week 8



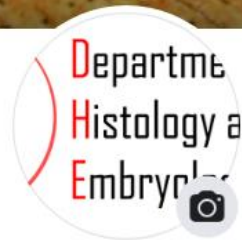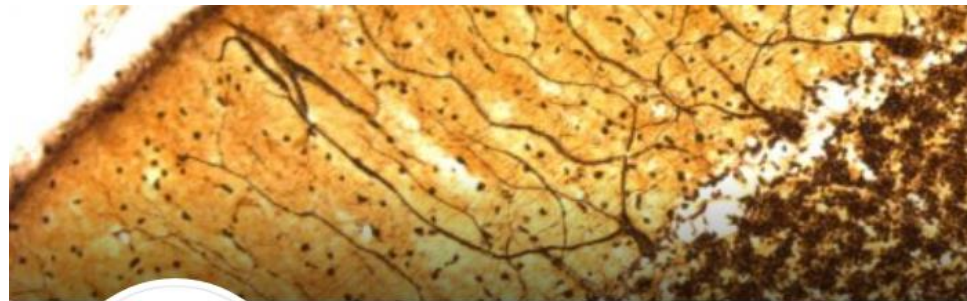
Gl. suprarenalis sin.

Thank you for attention

Questions? Comments?



pvanhara@med.muni.cz



HistoKlub MED MUNI

@HistoKlubMEDMUNI · Vzdělávací web

Special thanks to CellCartoons.net

