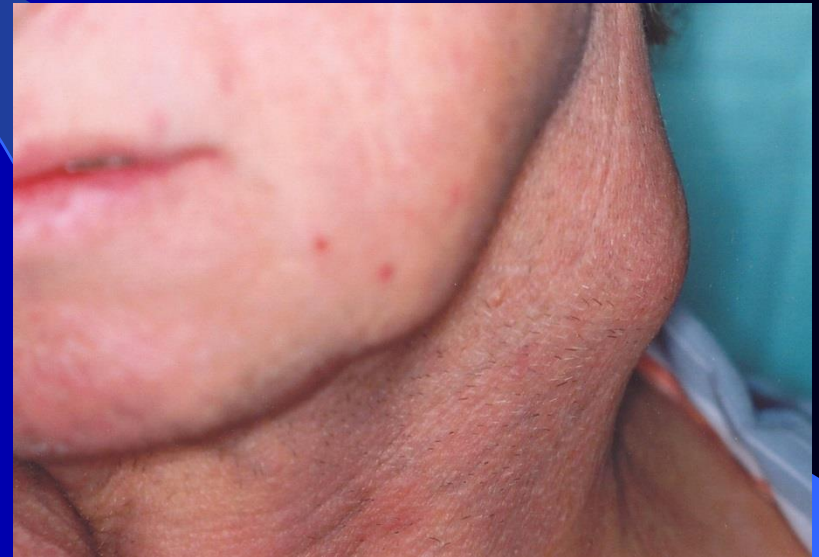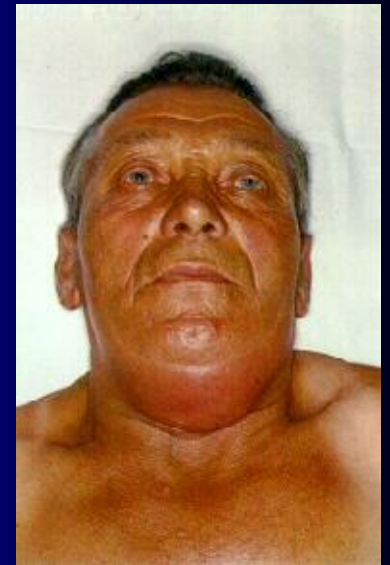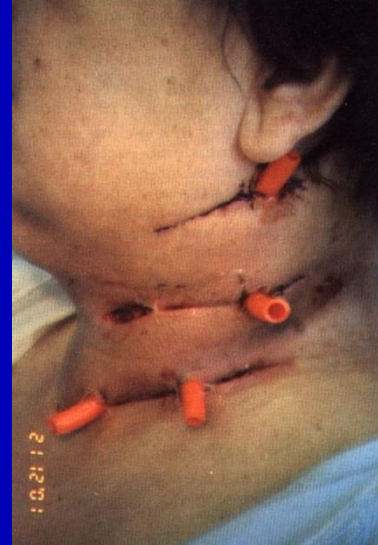
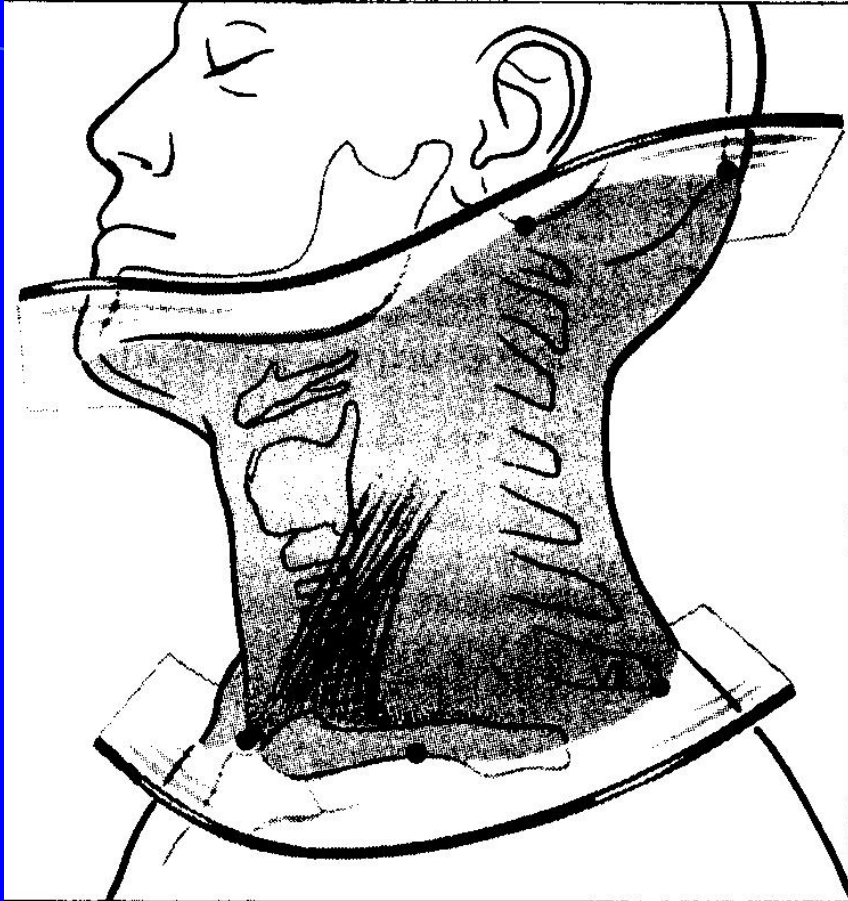
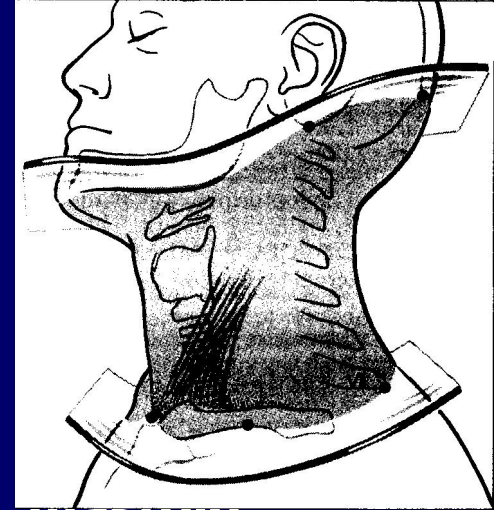


# Neck



# Neck - anatomy



***Superior boundary*** – inferior edge of mandibula, mastoid process and protuberatina occipitalis ext.

***Inferior boundary*** – plain formed by the suprasternal notch, clavicle and the spinous process of the seventh cervical vertebra.

**Osteomuscular system** is adapted to the upright human posture.

**Visceral part of the neck** contains upper aerodigestiv tract, the carotic sheath and its contents on each side and cervical lymphatic systém

There is on the neck cca 200 lymphnodes

# Lymphnodes of the neck

## Nodi cervicales superficiales

- Along v. jug. ext. Tributary zone: parotis, retraurik. krajinu, intraparotické uzliny, okcipitální uzliny.

## Nodi lymphatici cervicales profundi

- They are in the carotid sheath.

### Superior group (subdigastric)

- Lymph channels lead to this regional lymph nodes (group) from the tributary tissue area: soft palate, tonsils, radix linguae, supraglotis, sinus piriformis.
- *Nodus jugulodigastricus = Woodova uzlina = Küttnerova uzlina = Chassegnacova uzlina* je v

### Middle group

- Tributary tissue area: supraglotis, glandula thyreoidea, sinus piriformis. Boundary to the crossing of m. omohyoideus and carotid sheath.

### Inferior group

- Tributary tissue area: subglottis, trachea, cervikální jícn, glandula thyreoidea. „Great venous angle“ = the left jugulosubclavian angle. In this area is Troisier-Wirchow lymph node. Ductus thoracicus (thoracic duct) receive afferents from the lower half of the body, the cranial area.

## Lymphatic chain at n. accessorius

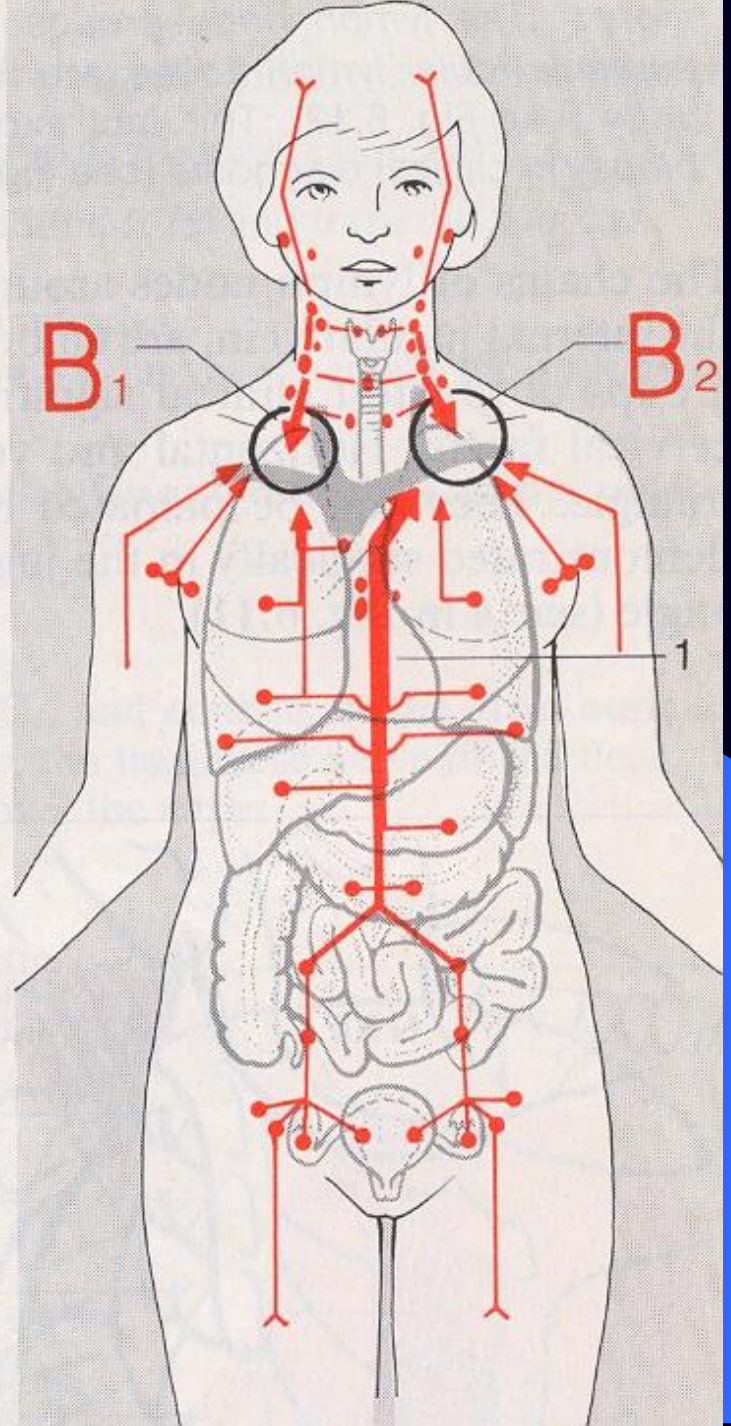
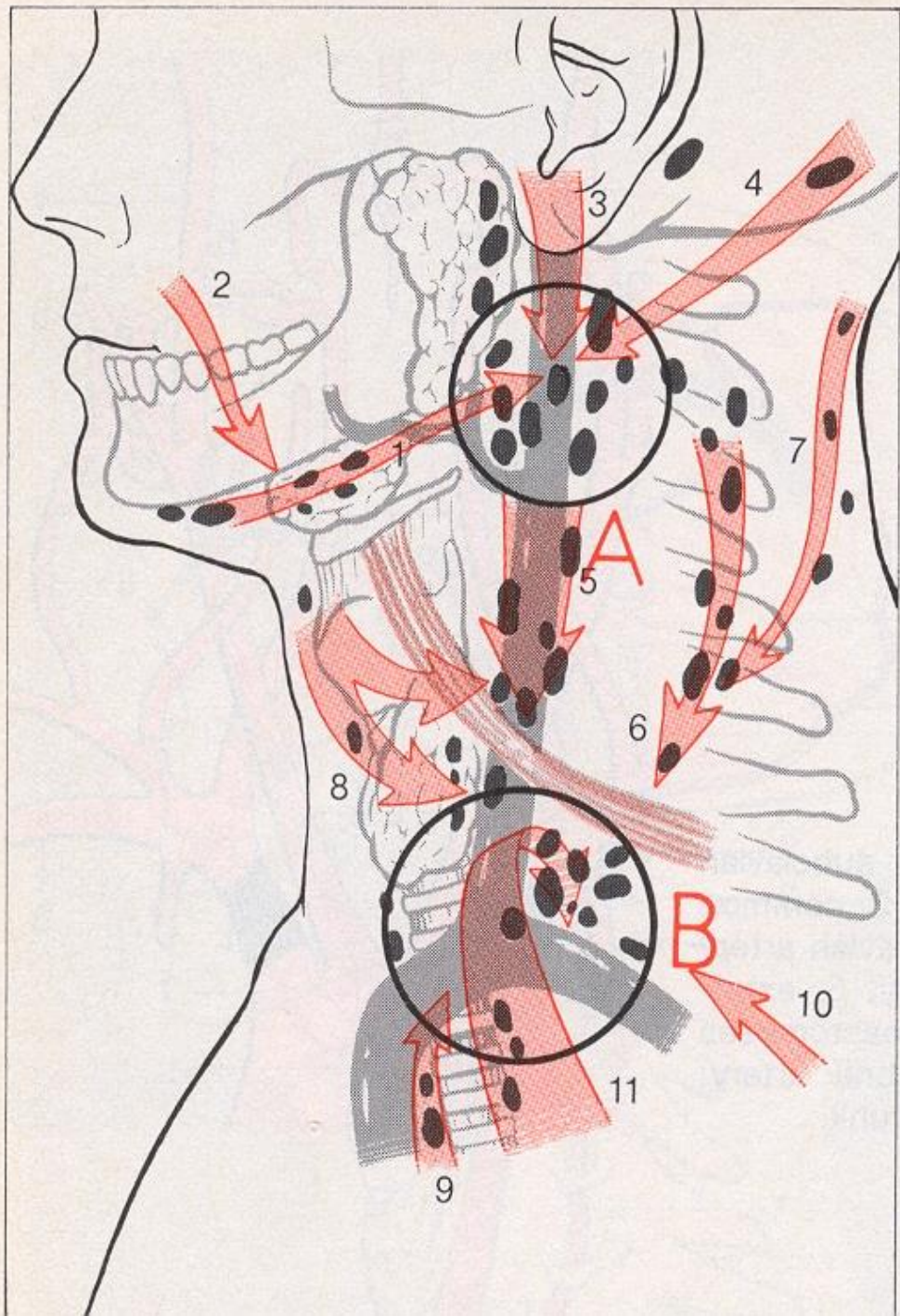
- Tributary tissue area: nasopharynx, orofarynx, paranasal sinuses..

## Lymphatic chain along vasa transversa colli

- nodi supraclaviculares - těsně nad klíční kostí.

## Special groups of lymphnodes

- Nodi submentales, retropharyngei (největší z nich je Rouvierova uzlina), paratracheales, nodus praelaryngicus (Poirierova uzlina).



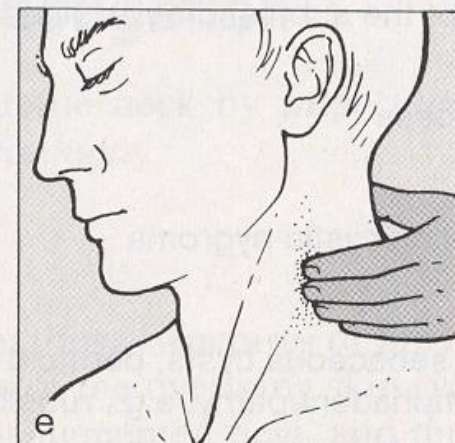
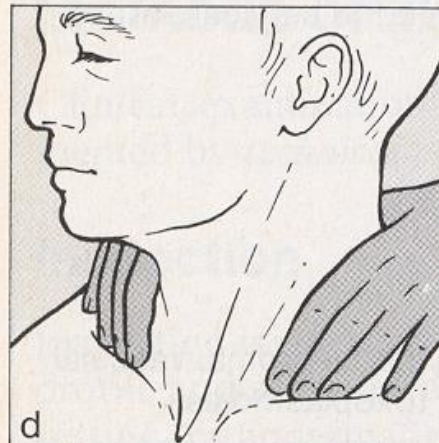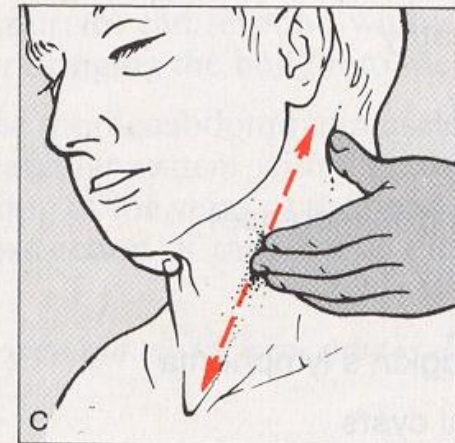
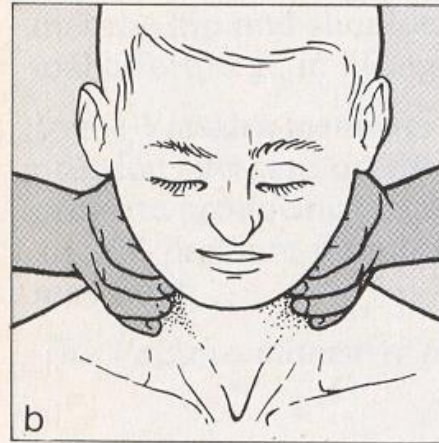
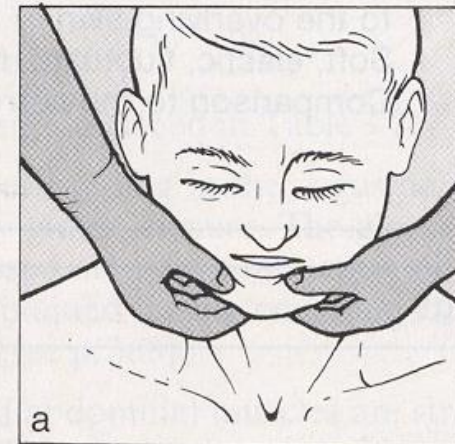
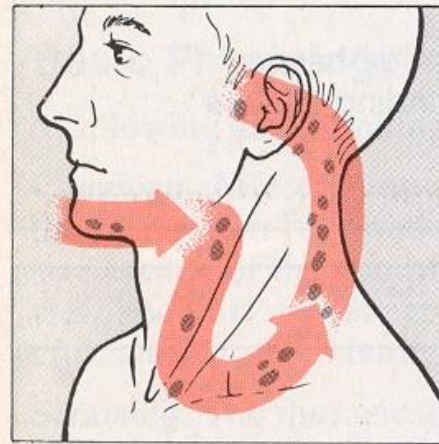


# *Investigation*

- **aspection**
- **palpation**
- **ultrasound, Doppler technique - provide information about vascular lesions, distinguish between cyst and solid tumor**
- **computed tomography - allows greater differentiation : vascular lesion, tumors, cysts - including their position and extent**
- **biopsy**
- **cervical lymphography - is of little clinical value when compared with other methods of investigation.**
- **MRI**
- **scintigraphy**

# Summary of findings

- form and size in cm,
- site (lokalizaci), topographic description
- consistency - soft, elastic, fluctuant, firm or hard
- mobility - vertically or horizontally, fixed or adherent
- pulsation, skin - appearance of the skin, comparison to the surrounding tissues



# „Sentinell lymphnode“

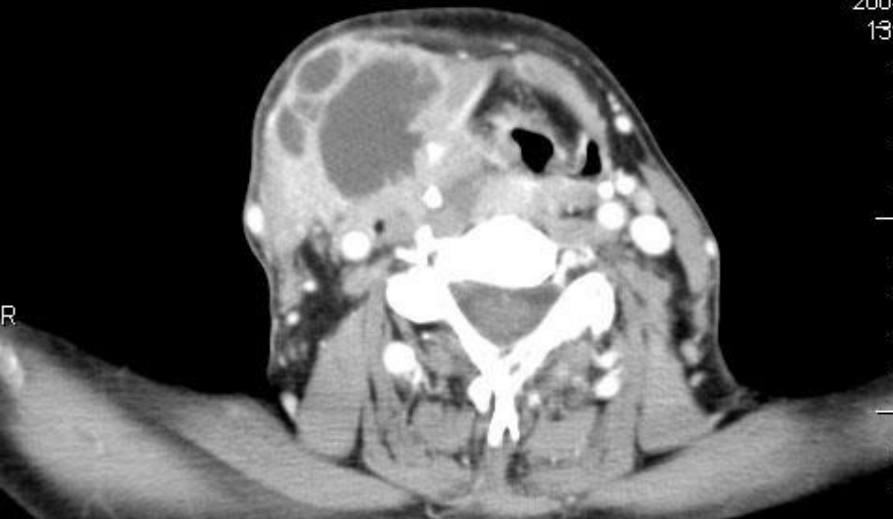- **First lymphnode to which the lymph is coming from primary tumor. If there are no metastasis, the probability of metastatic spread is low.**
- **Identification –**
  - **Through surgery - peritumoral application of lymphotropic agent (colloid solutions labeled with radioactive technetium, dye).**
  - **Before surgery – lymphoscintigraphy 1 day before surgery.**



- **Palpation**- až 1/3 of cases fals negative or fals positive.
- **UZ** - senzitivita 94 % a specifita 91 % (závisí na zkušenosti interpreta)
- **FNAB fine needle aspiration cytology and biopsy** guided by ultrasound - až 76 % senzitivita a 100 % specifita
- Reliability od **CT scan** k průkazu metastatického postižení krčních uzlin bývá udávána mezi 72 % - 93 %
- **PET** jeví vyšší senzitivitu, ale má nižší specifitu než CT vyšetření.
- **Combination** of evaluation methods shows presence of neck metastasis approx. v 70 % případů, to znamená, že asi 30 % nemocných bez klinických známek metastáz je ohroženo lokoregionálním relapsem z mikrometastáz ve spádových krčních uzlinách.

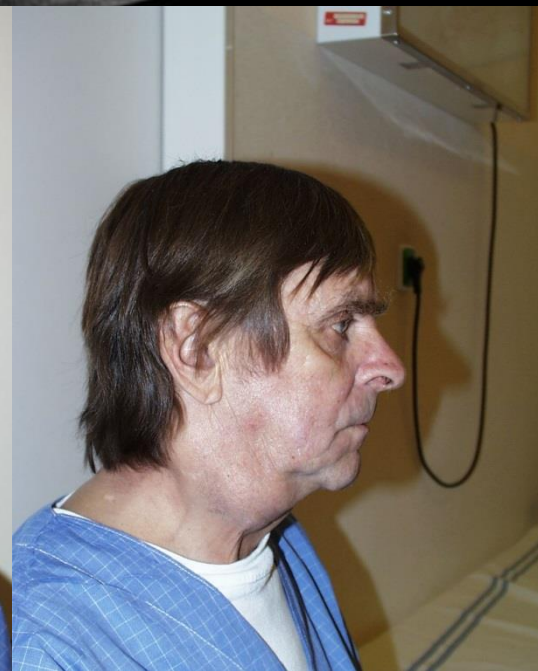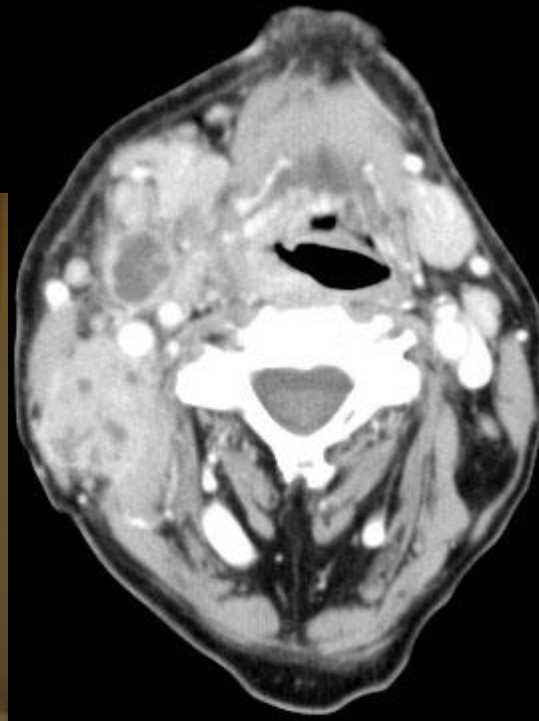
500110/091  
M  
4284-7367/04  
2004/12/6  
13:03:29

# Metastasis of cancer into neck lymphnode



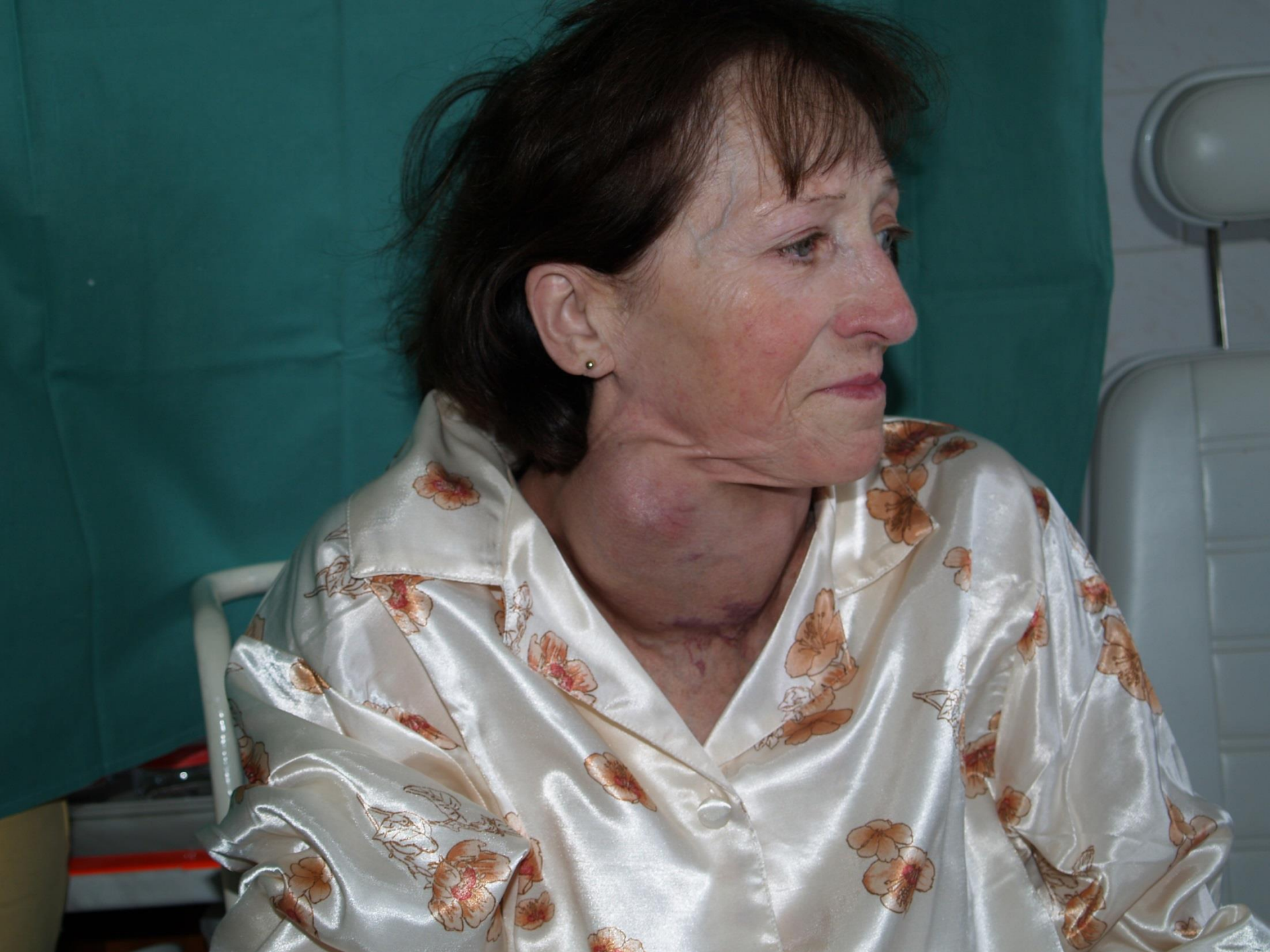
CT/2778/15  
Axial F->H

500110/091  
M  
4284-7367/04  
2004/12/6  
13:03:29



Pixel size: 0.488 mm  
Position: -715.0 mm  
W: 250 L: 25

DFOV: 25.00 x 25.00cm

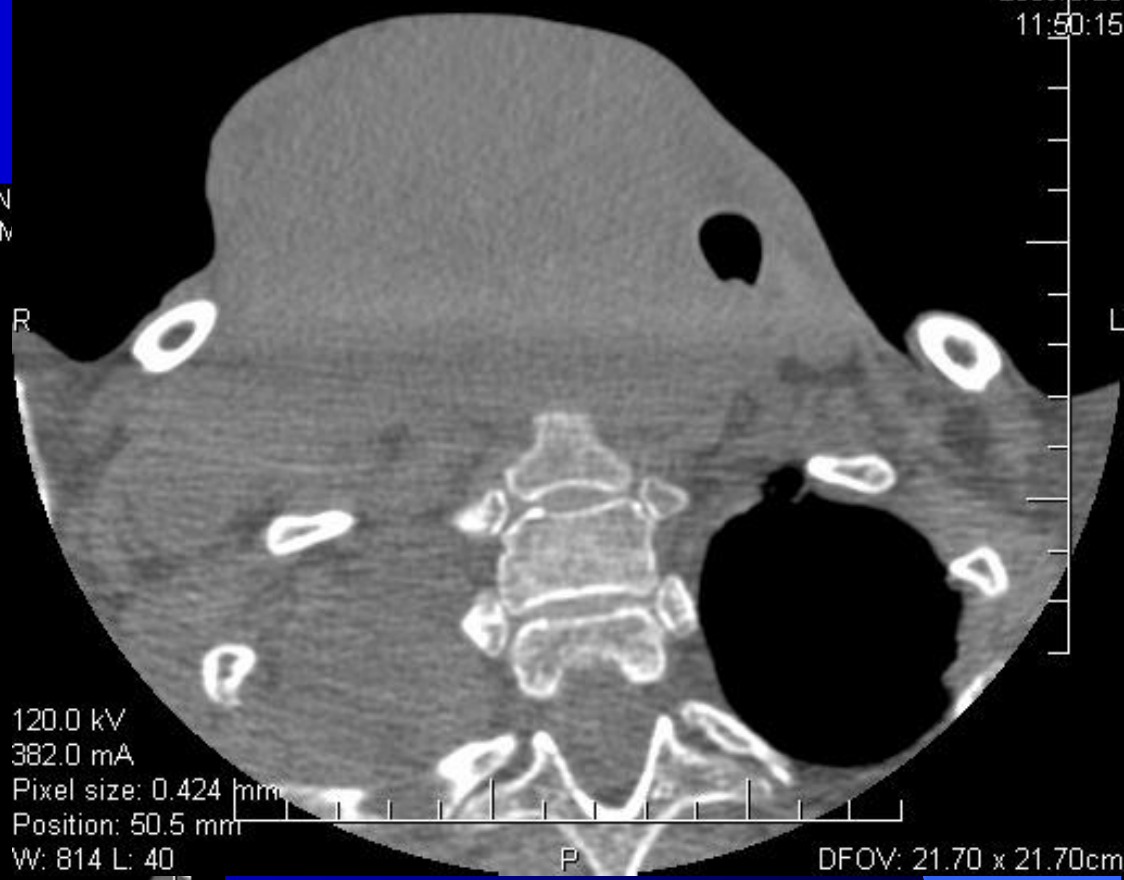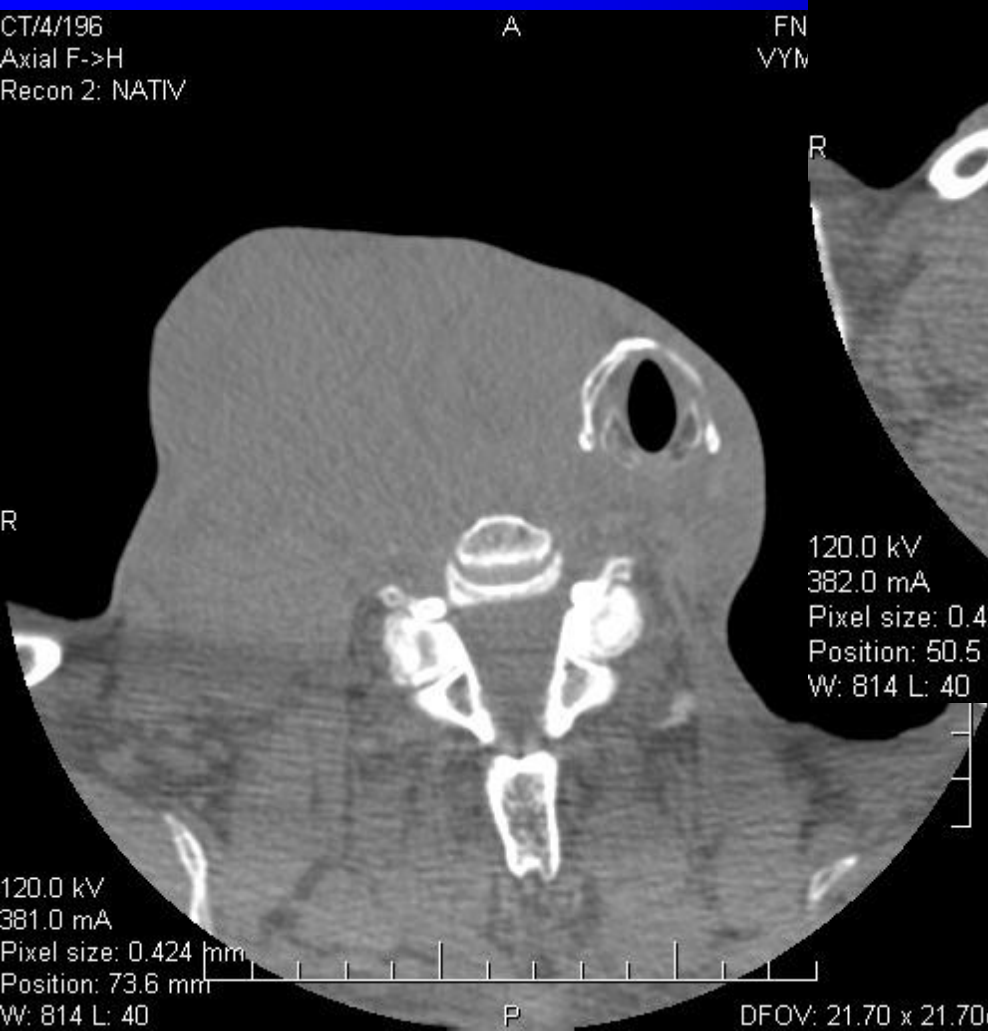


# Ca gl. thyreoidea

CT/4/233  
Axial F->H  
Recon 2: NATIV

FN U sv. Anny v Brne  
VYMAZALOVA IRENA  
415115/090  
1941/1/15  
68Y F  
4284-4113/09  
2009/5/20  
11:50:15

CT/4/196  
Axial F->H  
Recon 2: NATIV



CT/450/2  
Sagittal L->R  
Reformatted

FN U sv. Anny v Brne  
VYMAZALOVA IRENA  
415115/090  
1941/1/15  
68Y F  
4113/09  
2009/5/20  
11:50:15

A

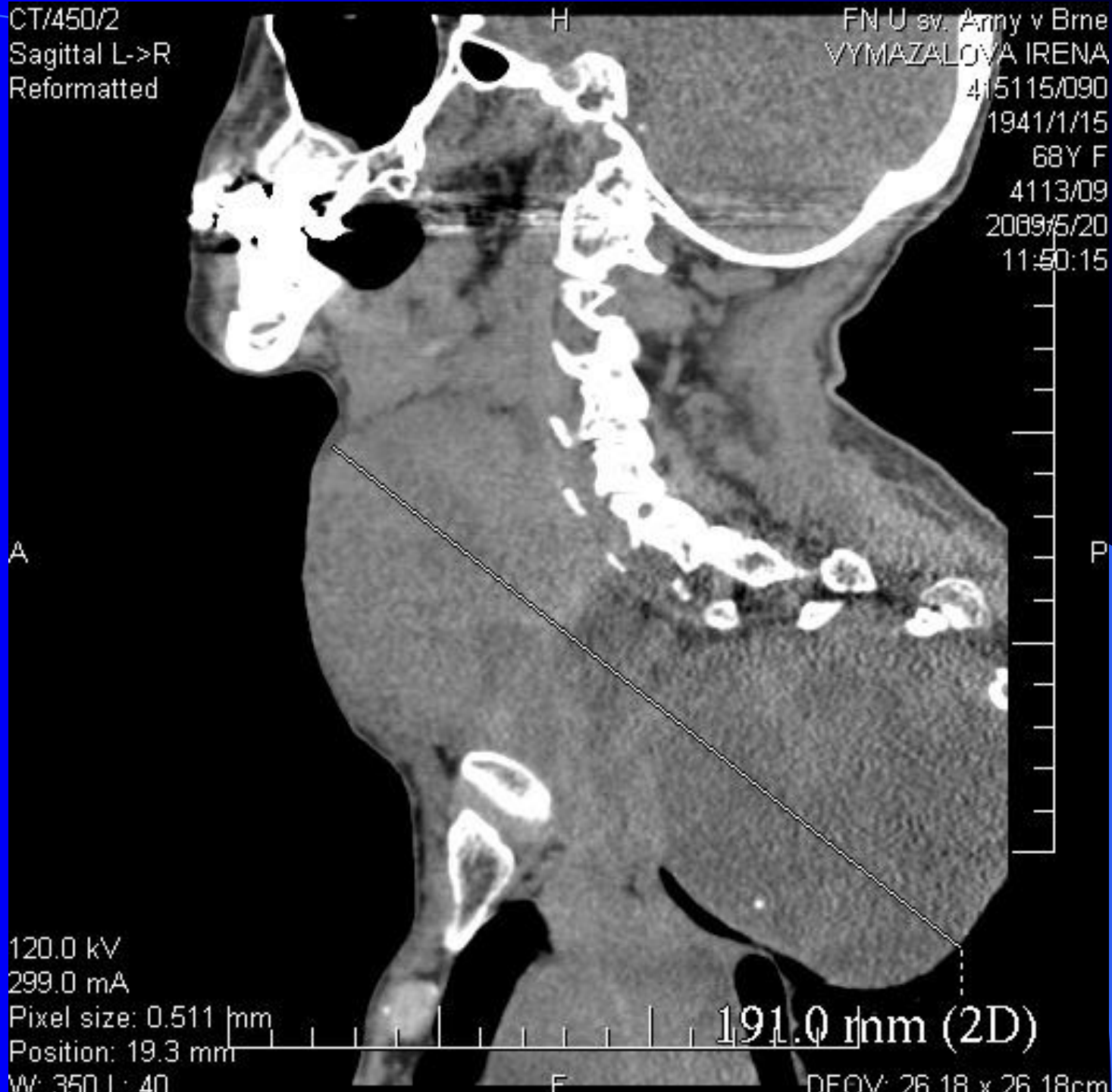
P

120.0 kV  
299.0 mA  
Pixel size: 0.511 mm  
Position: 19.3 mm  
W: 350 L: 40

191.0 mm (2D)

F

DEGV: 26.18 x 26.18cm



# *Differential diagnosis of tumors of the neck*

**Lymphnodes X Extra lymphnodes**

- **Inflammatory Cervical Lymphadenopathy**
- **Tumors**
- **Congenital Anomalies**

# Inflammatory Cervical Lymphadenopathy

acute - lymph nodes are painful

## **Chronic non specific lymphadenitis**

shows on repeated infections in the region of pharynx in past. Persistent or recurrent lymph node swellings are not compatible with a diagnosis of nonspecific lymphadenitis.

## **Chronic specific lymphadenitis -**

tuberkulóza, sarkoidóza.

Lymphadenitis retikulocullaris abscedens

**Cat Scratch Fever** the pustulous primary focus, which tends to ulcerate, occurs in the skin, . This is followed 1 to 5 weeks later by a regional lymphadenopathy. In one third of cases a fistula forms. Is caused by the cat scratch virus.

*Tularemie.*

## **Lymphadenitis with changes in blood account**

mononucleosis infectiosa, rubeola, adenovirosis, hepatitis epidemica, viral pneumonia, listeriosis, toxoplasmosis, lymphadenitis after hydantoin

## **Rare lymphadenitis**

kolagenózy, lues, mykózy.

# Tumors

## Benign

hemangiomas, lymphangioma (Cystic Hygroma), chemodectoma, lipomas (Morbus Madelung - benign symmetric lipomatosis of the neck)

## Malignant lymph node tumors

Malignant lymphomas Hodgkin's disease, Non - Hodgkin's lymphoma. Treatment according to oncologist - actino- and chemotherapy.

## Primar neck cancer

Thyroid gland , tzv. „branchiocarcinoma“ from lateral Branchial Fistulae and Cysts.

## Lymph Node Metastases

treatment - surgery.

## TNM classification:

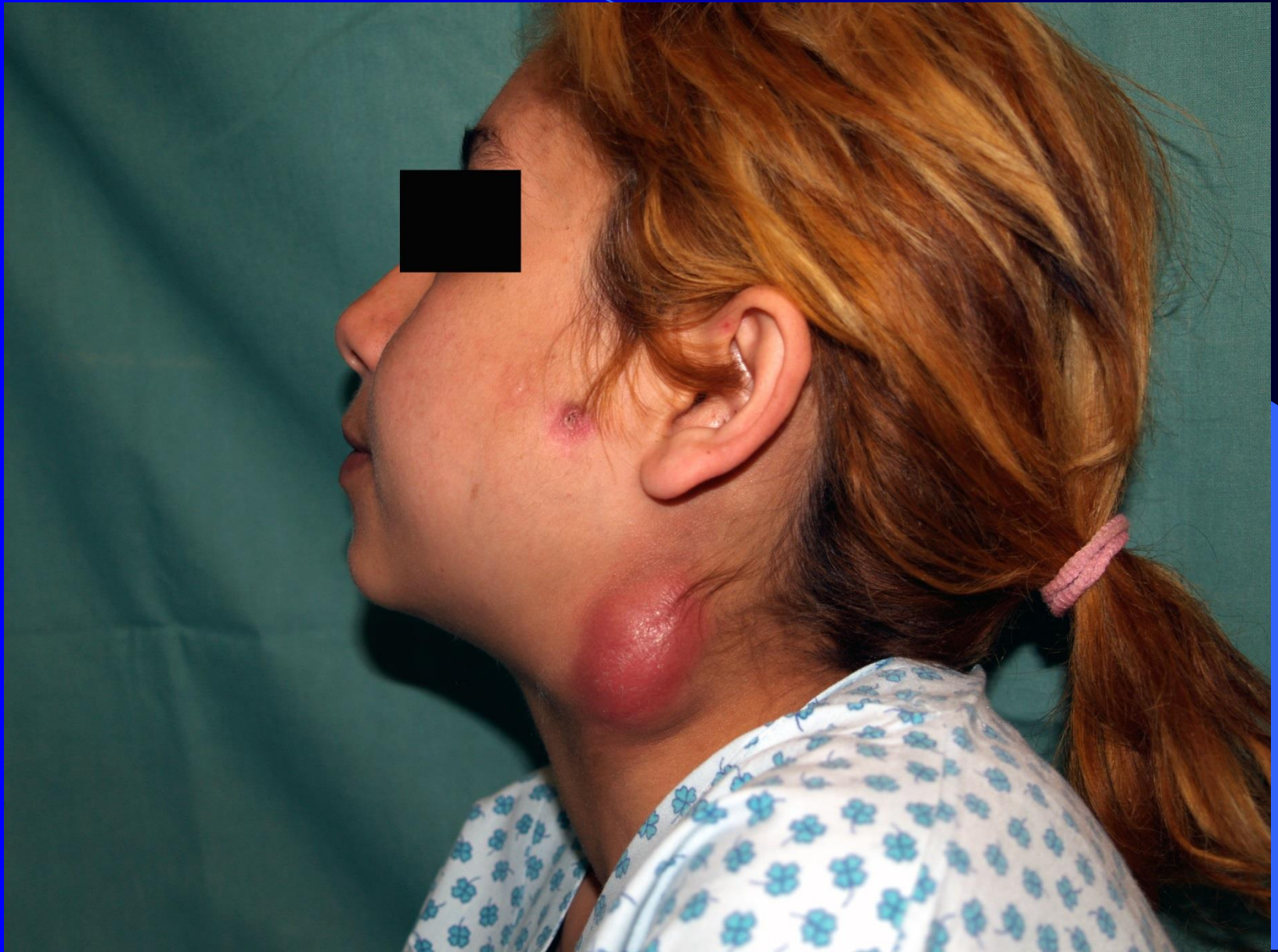- N1 single homolateral less than  $< 3$  cm;
- N2 single homolateral  $> 3$  cm  $< 6$  cm  
more homolateral lymph nodes  $< 6$  cm  
bilateral or contralateral  $< 6$  cm
- N3  $> 6$  cm



# Congenital Anomalies

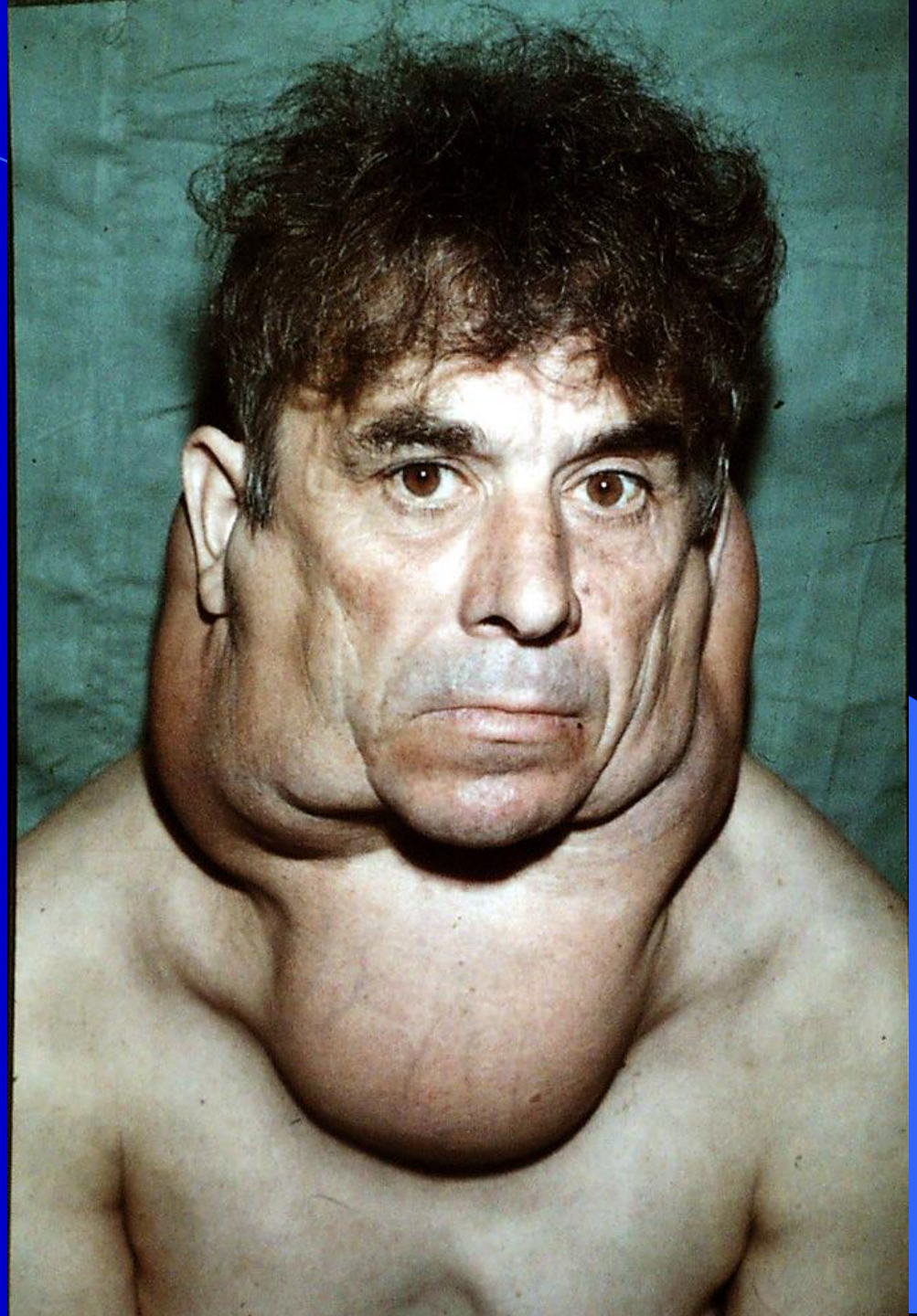
- **lateral Branchial Fistulae and Cysts**
- **thyreoglossal Duct cysts and fistulae (medial)**

# Inflammatory neck swelling - actinomycosis

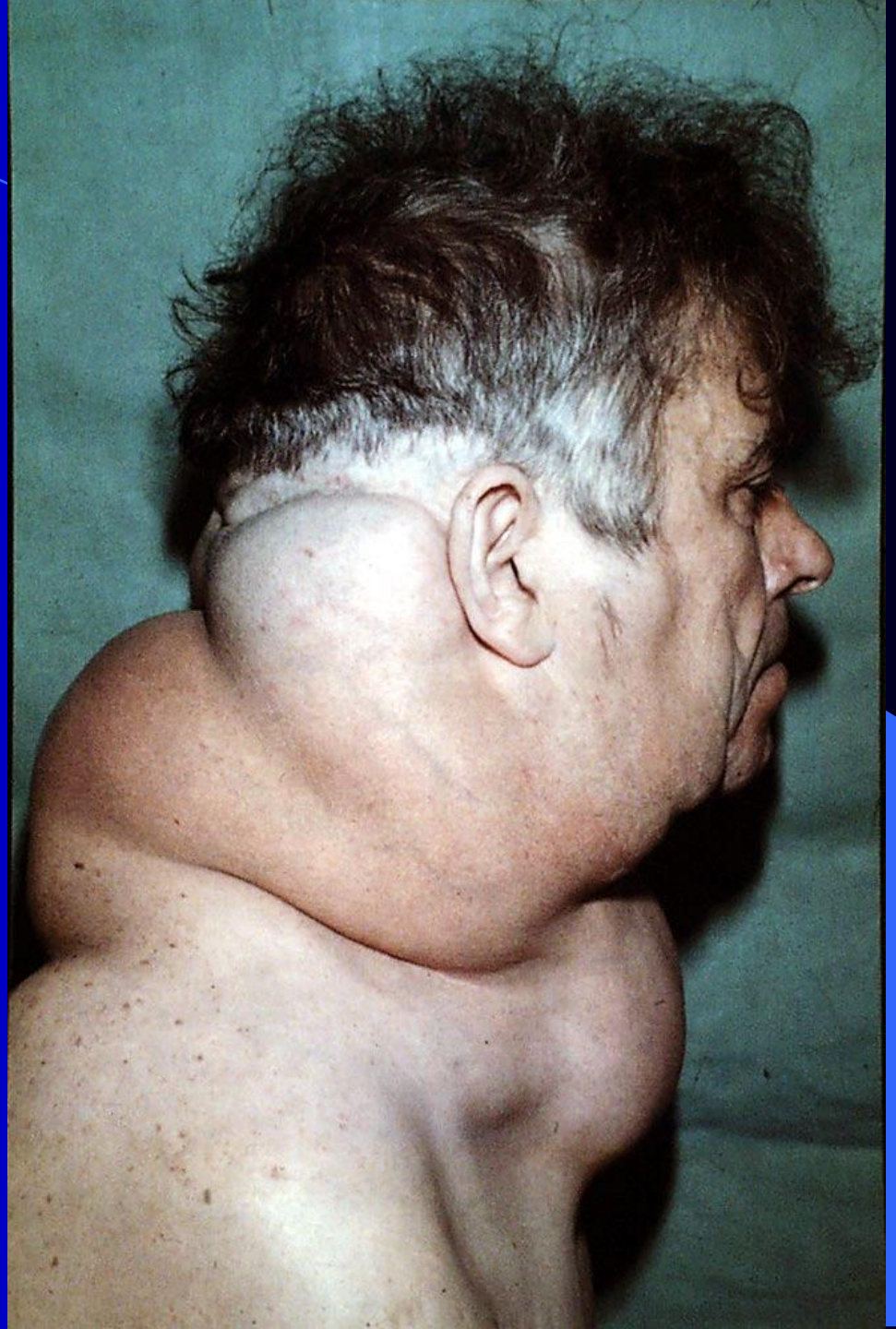


# **Morbus Madelung**

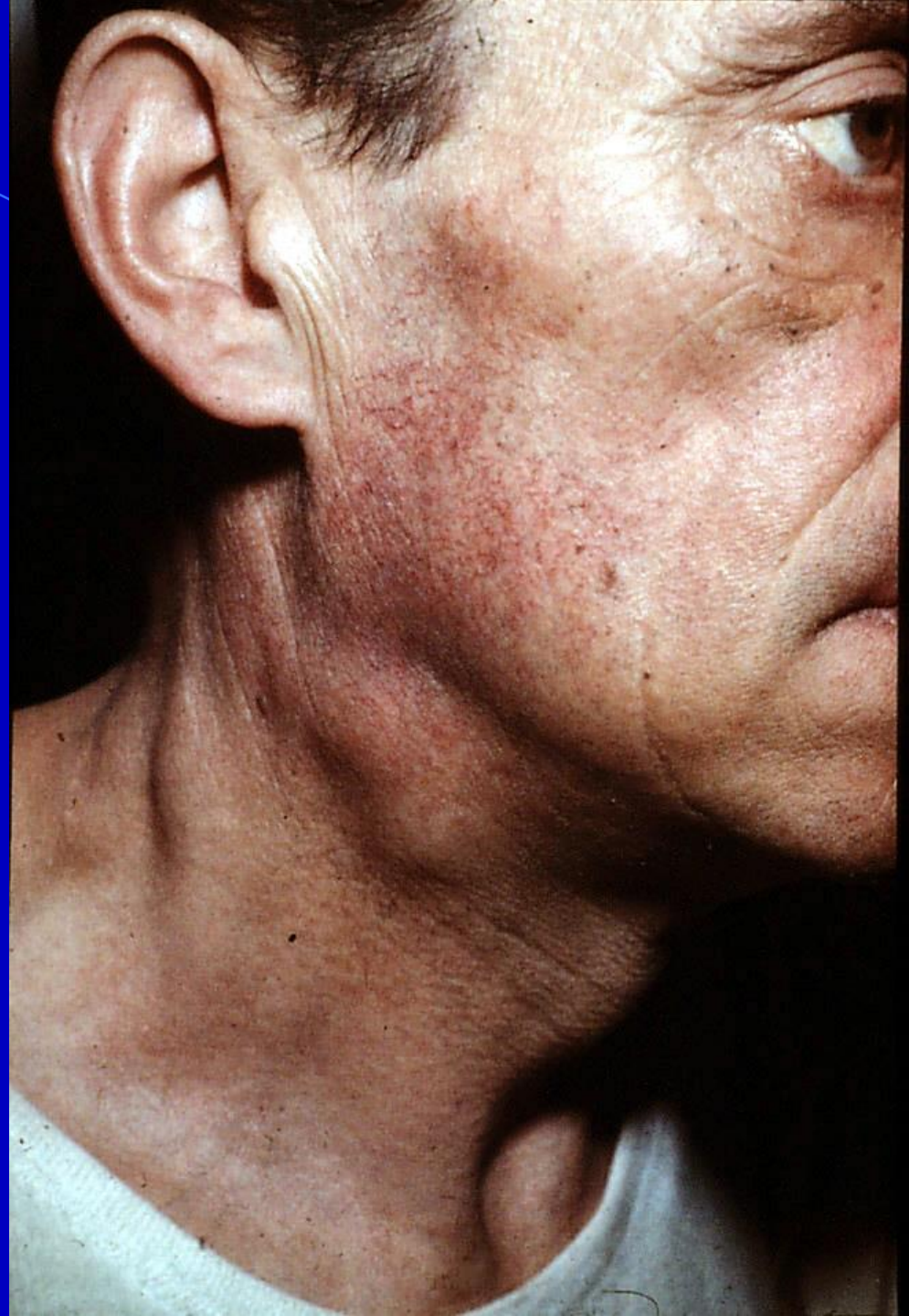**benign symmetrical  
lipomatosis**



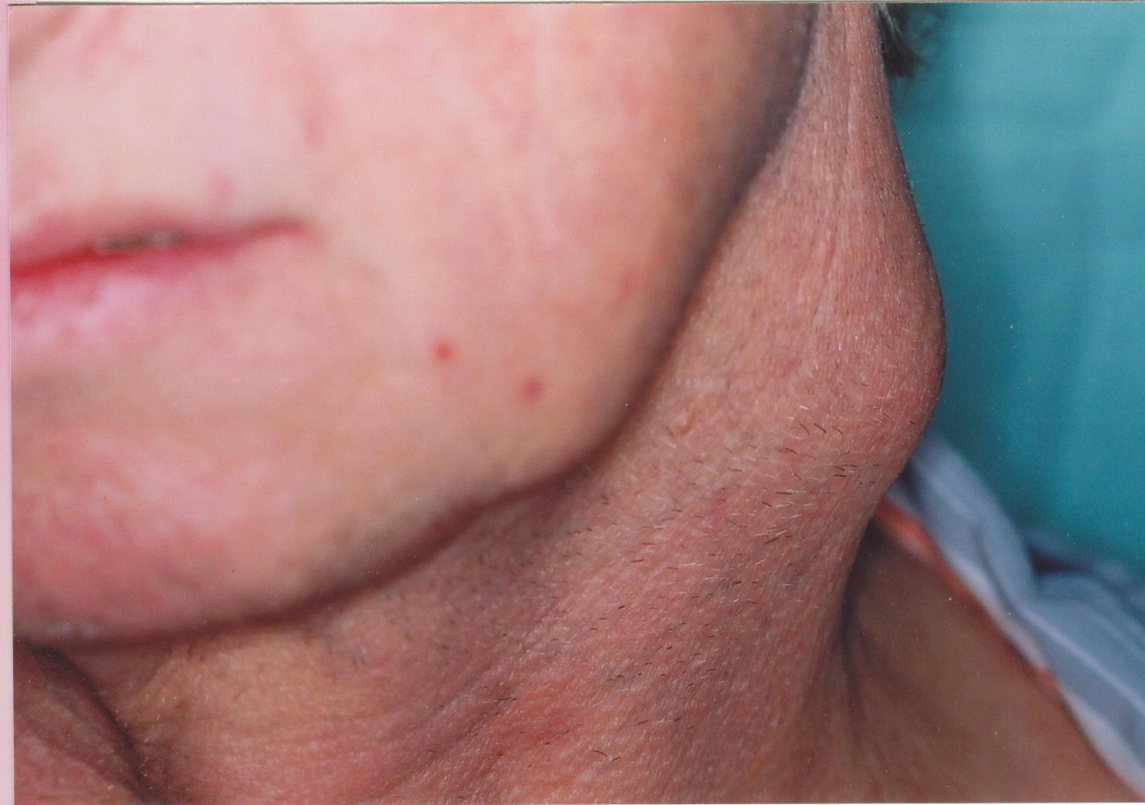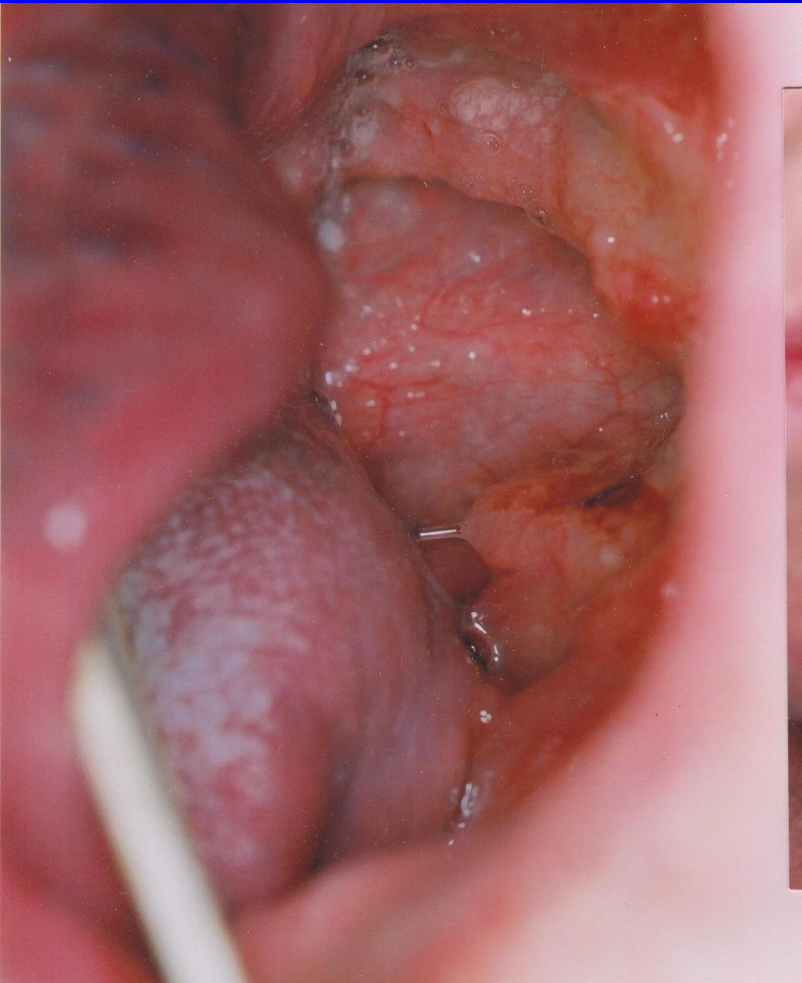
# Morbus Madelung

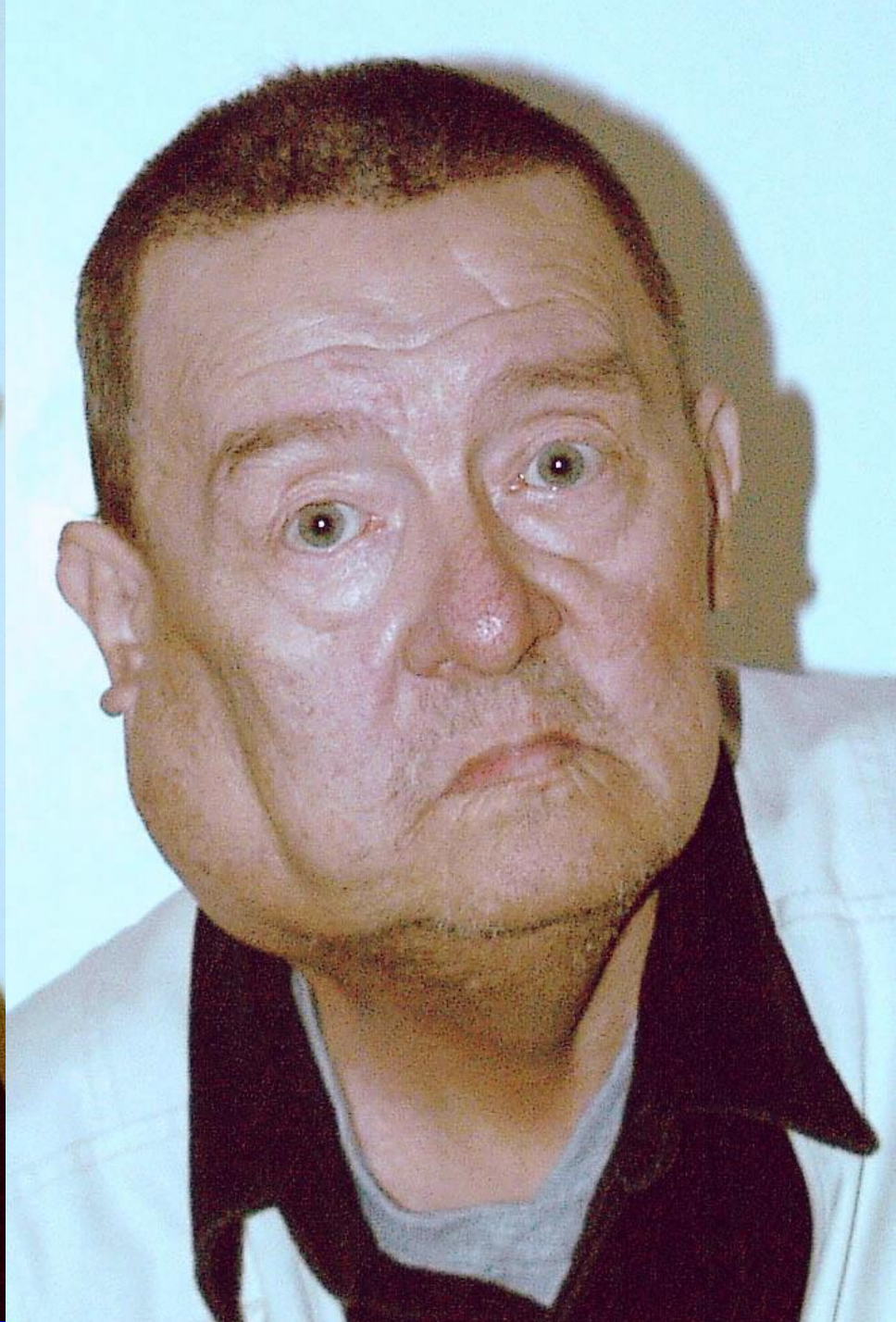
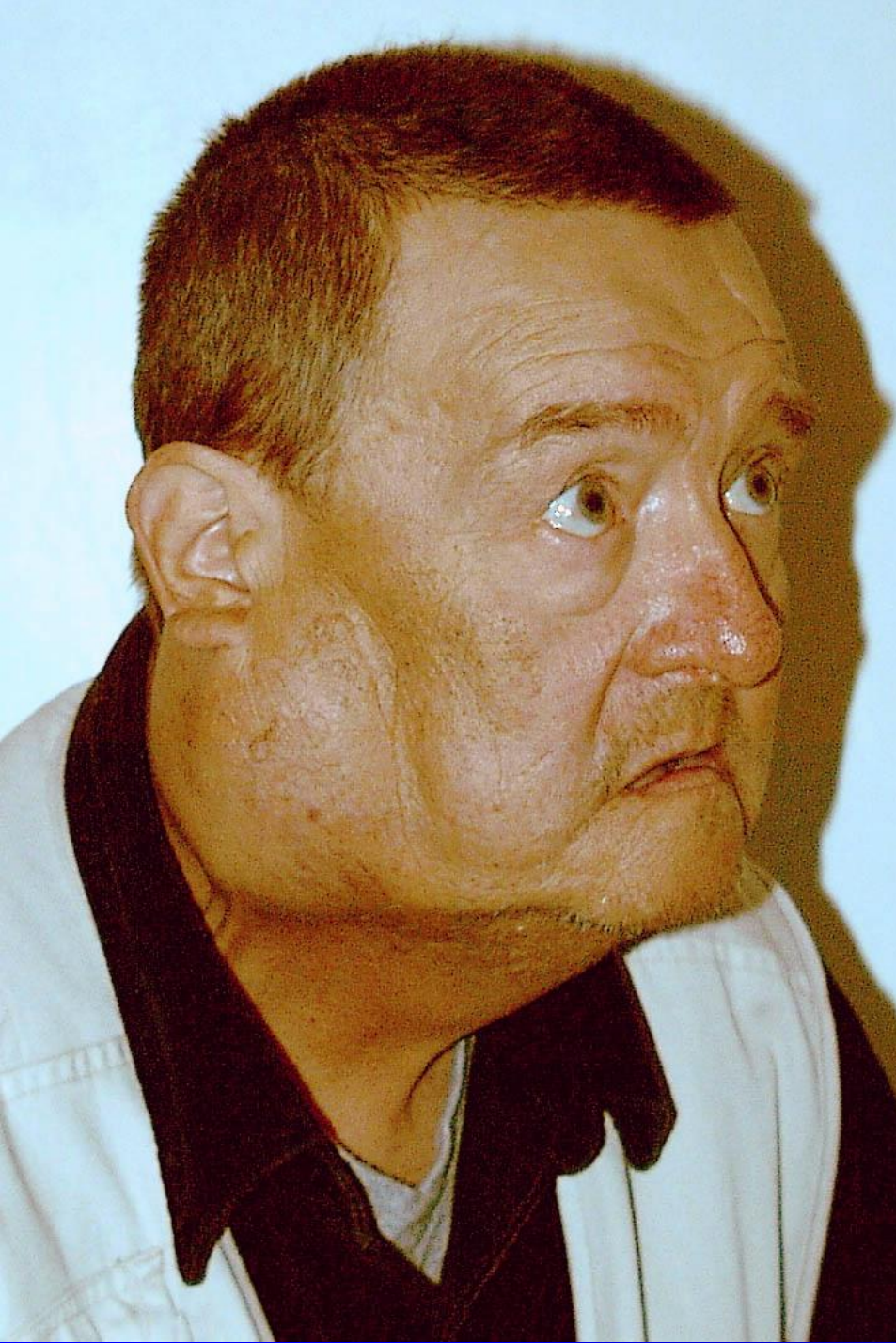
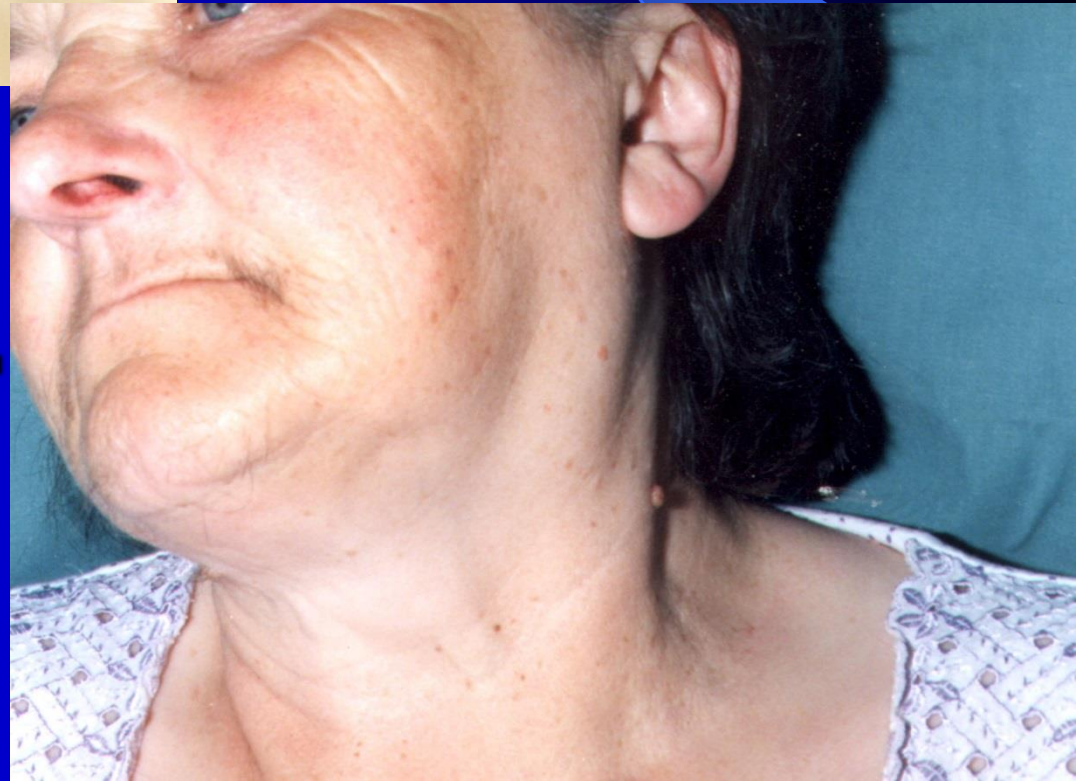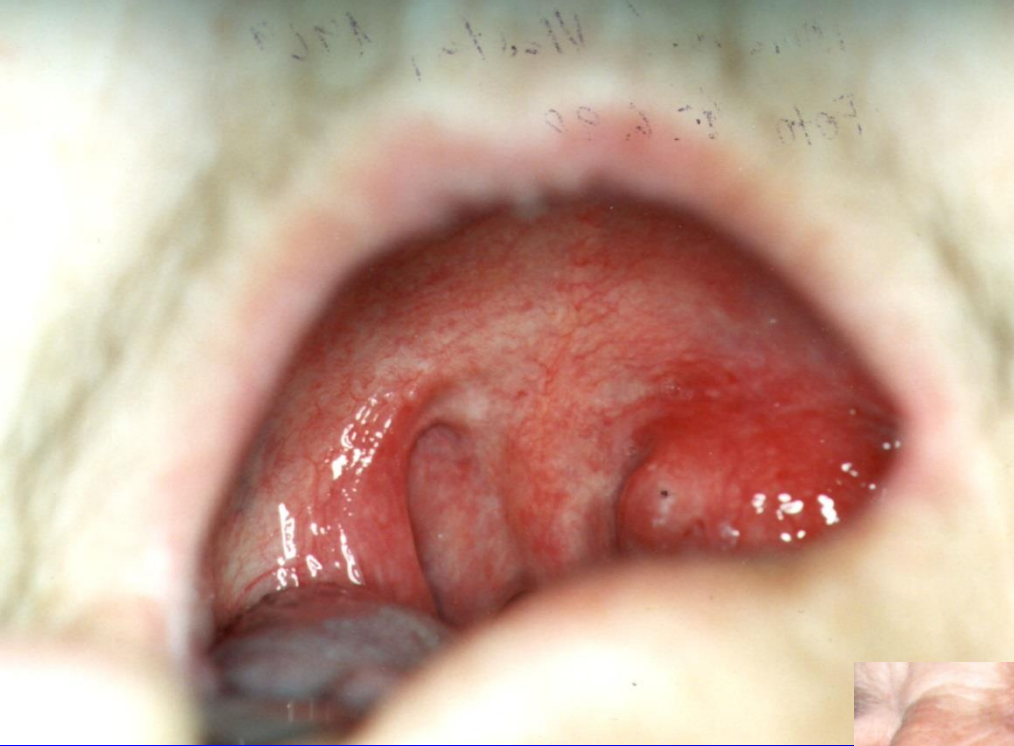**Metastasis  
of  
oropharyngeal  
cancer**



# Karcinom orofaryngu s metastázou na krku vlevo

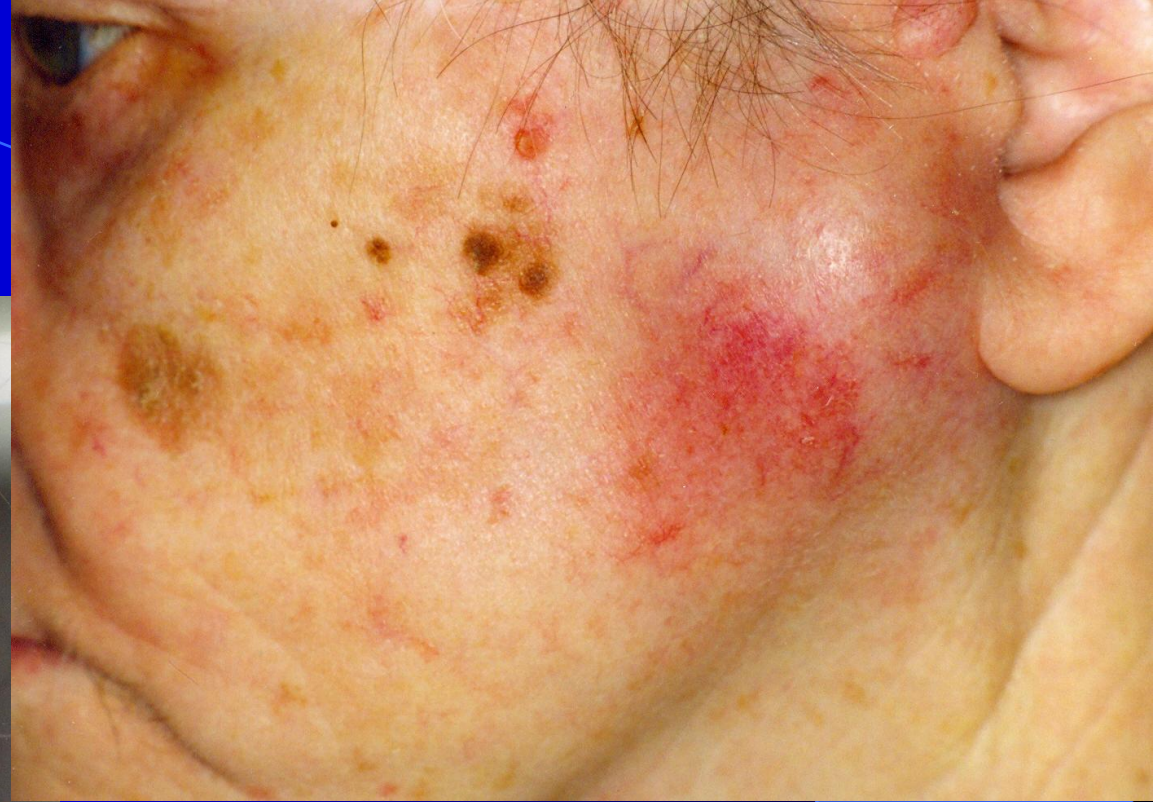
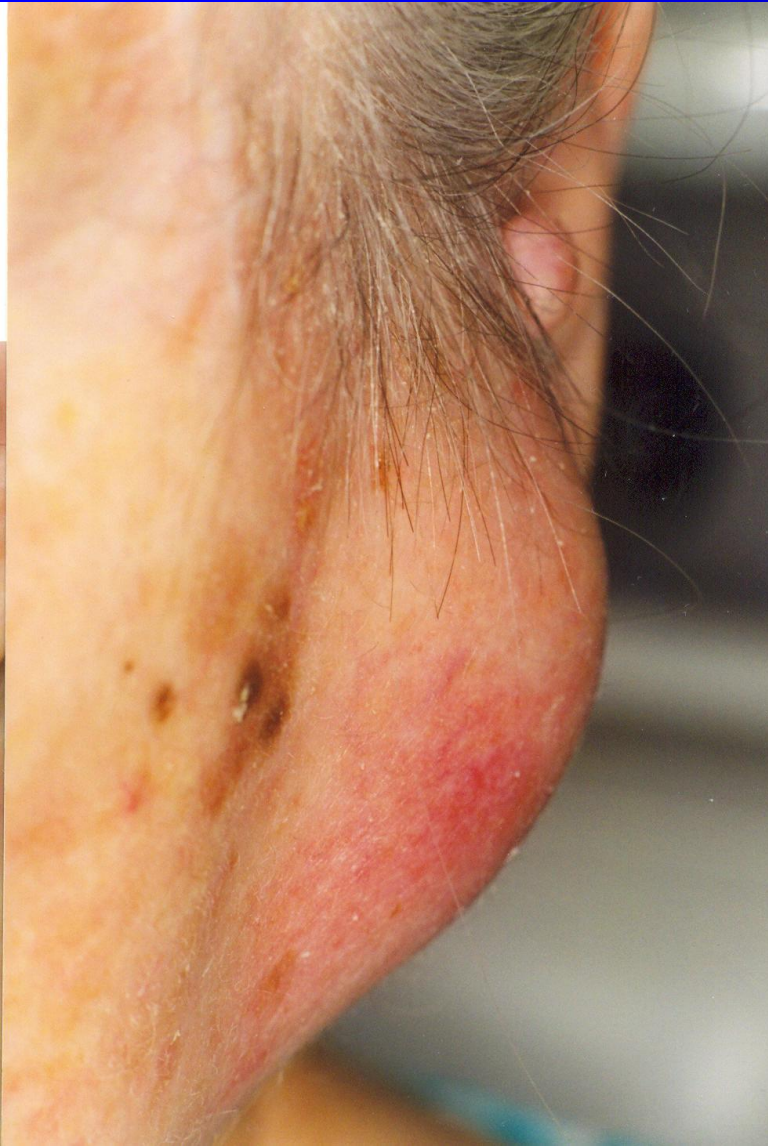




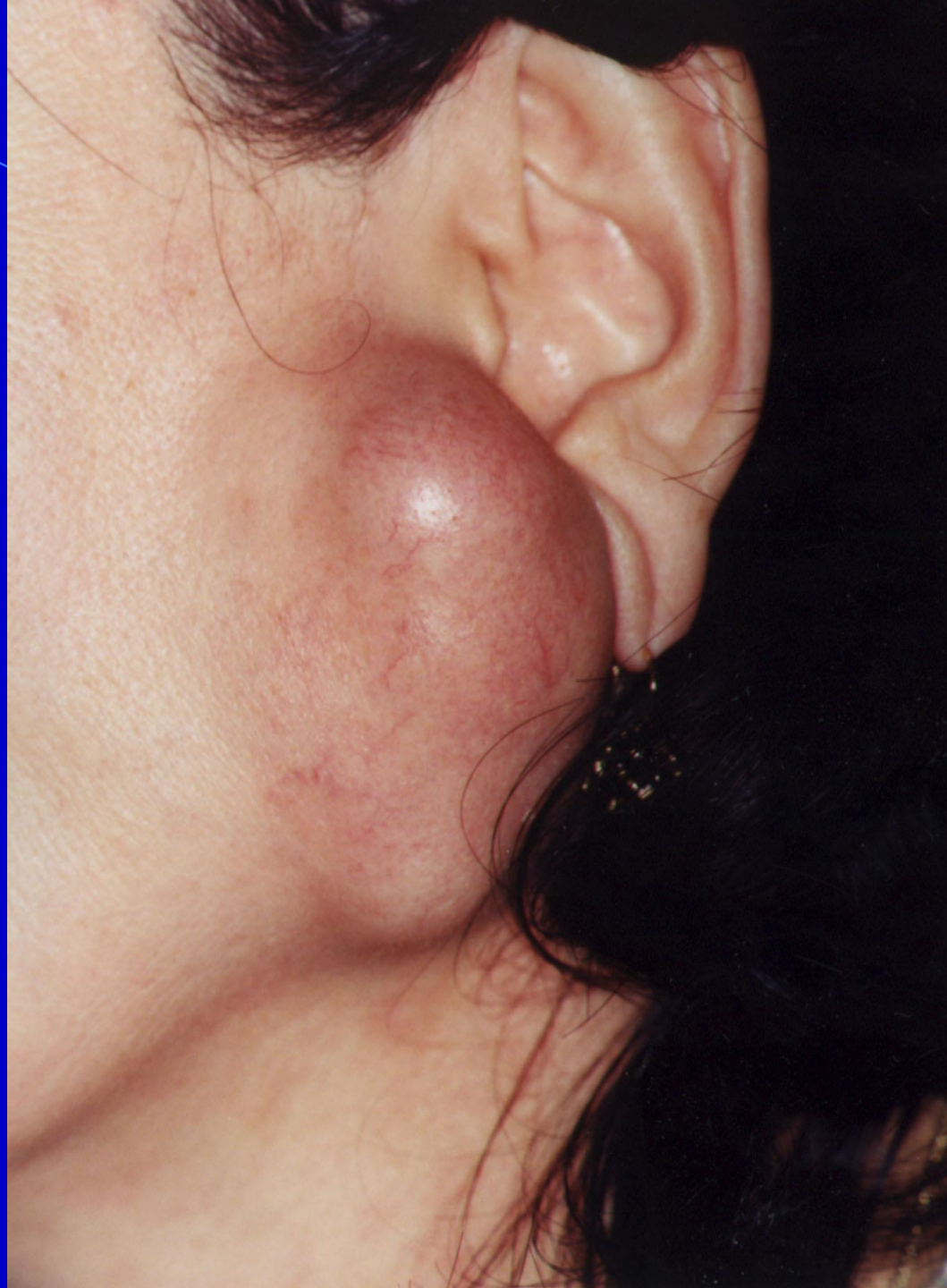**Glomus tumor  
left**





**Tumor  
parotis**

# Mixtumor parotis



# Nádor parafaryngeálního prostoru

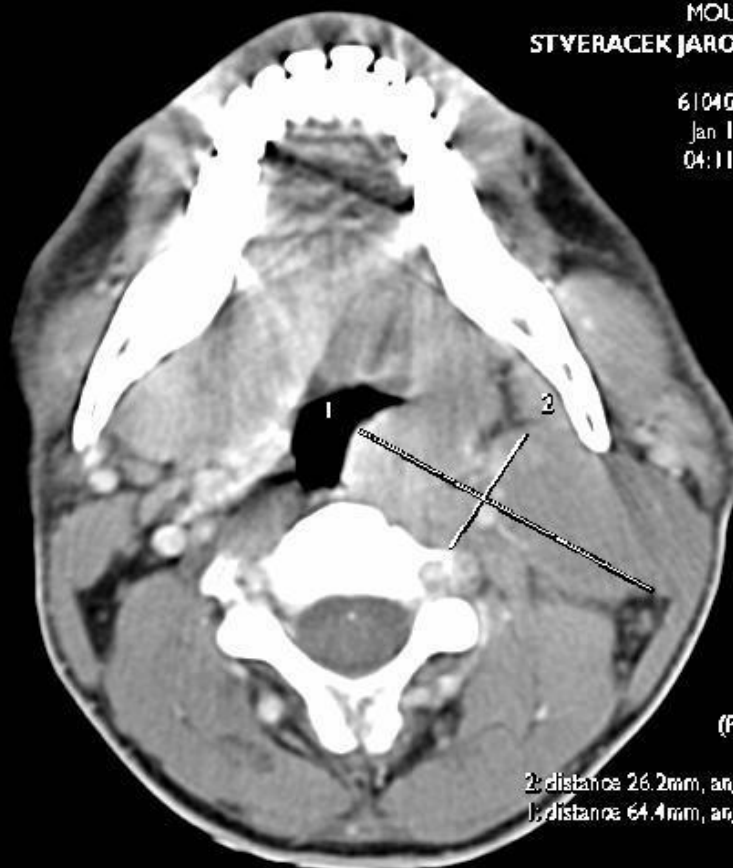STVERACEK, JAROSLAV  
5031

Ex: 8838 | 1.VYS  
Ser: 104  
Im: 11+C

MOU Brno  
STVERACEK JAROSLAV

KRK  
1.VYS.

610405/0876  
Jan 13 2008  
04:11:23 PM



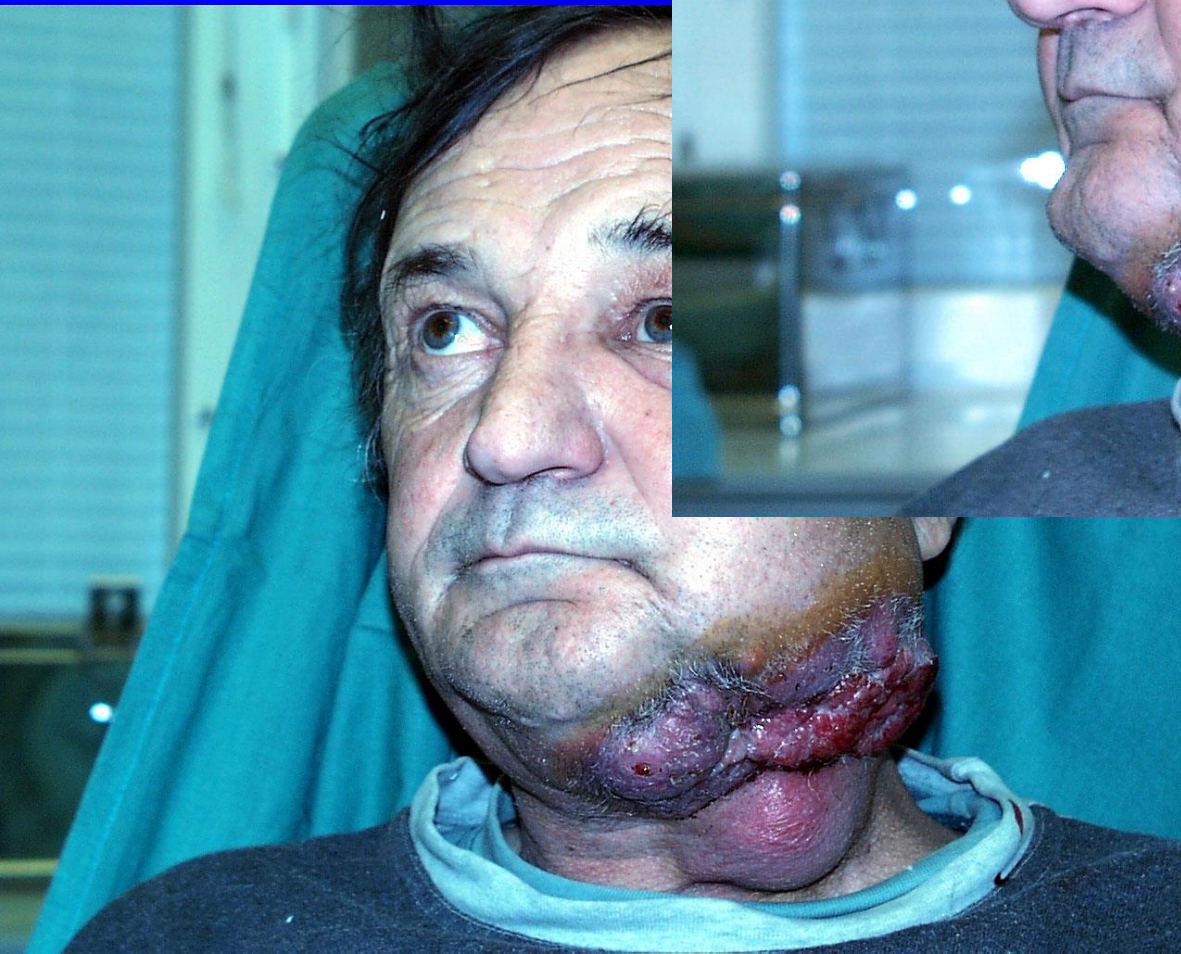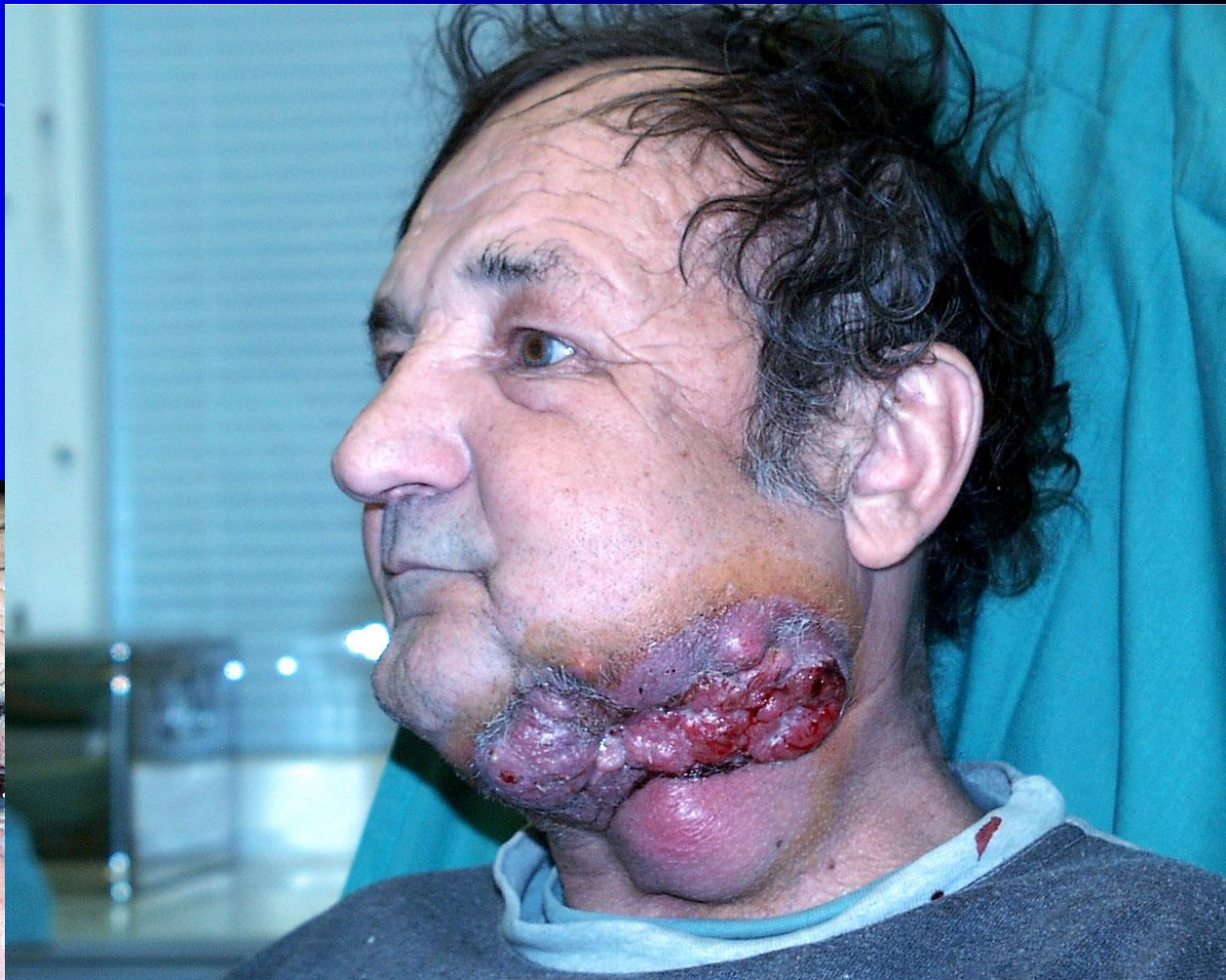SP:mm  
ST:mm  
C35  
W300

Not for diagnostic use

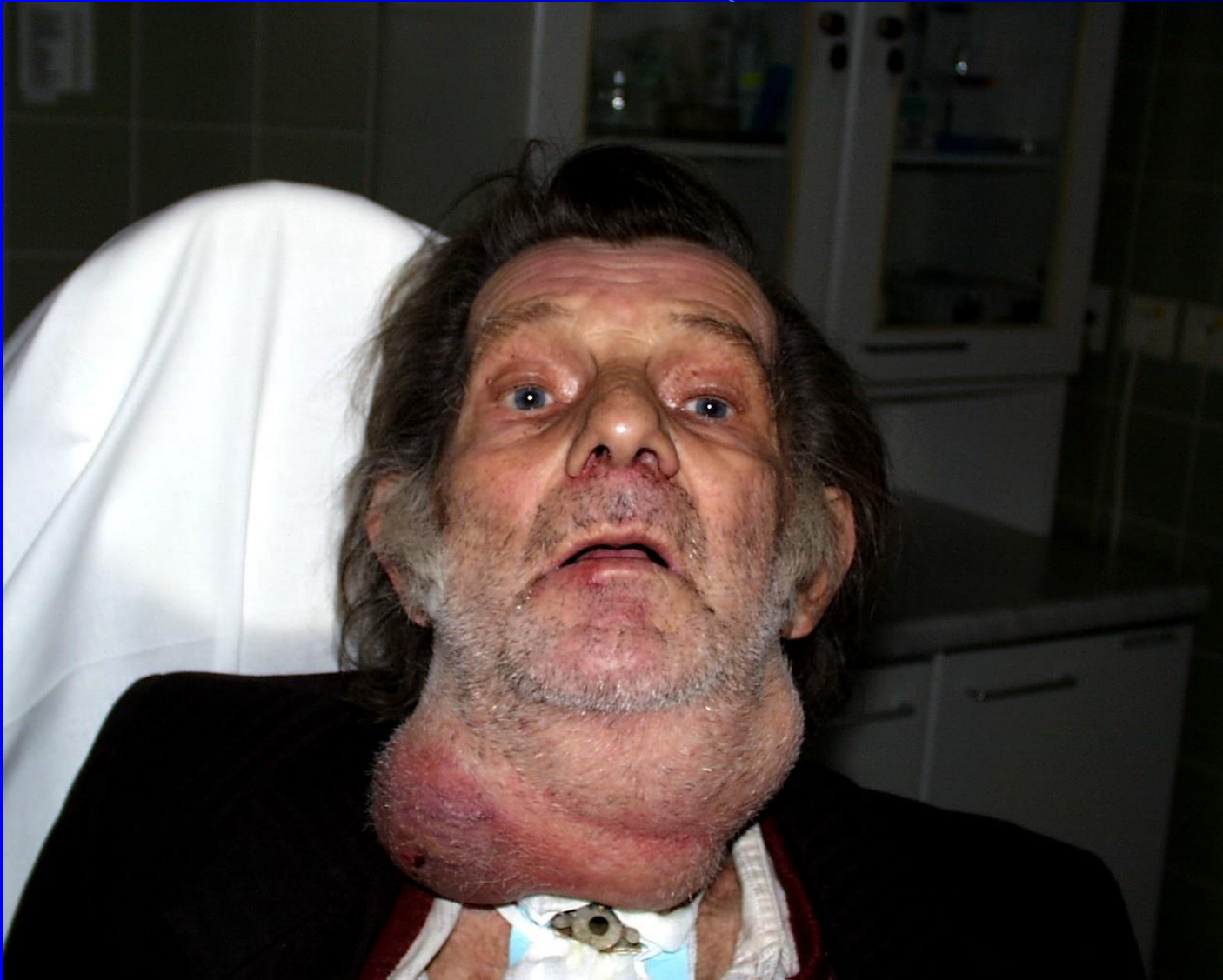(FLT:e2)

2: distance 26.2mm, angle 33°  
1: distance 64.4mm, angle 60°

# Pokročilý karcinom slinné žlázy



# **Pokročilý karcinom hrtanu s metastázami na krku – pacient před rokem odmítl léčbu**



# **The methods of surgical treatment of lymph node metastases**

**Surgery from external approach  
Combinated with  
Radiotherapy**

# The methods of treatment

Prescalene node biopsy (Daniels operation)

**The radical curative neck dissection** (**Resectio venae jugularis internae en bloc sec. Crile 1906**) - the upper boundary of the operation is the base of the skull and the lower boundary lies at the level of the clavicle. The sternocleidomastoid muscle, the internal jugular vein are removed.

The goal of neck dissection is complete removal of lymph nodes and vessels between the superficial and deep cervical fascia.

**Functional deck dissection**- the sternocleidomastoid muscle, the internal jugular vein, the accessory nerve are preserved.

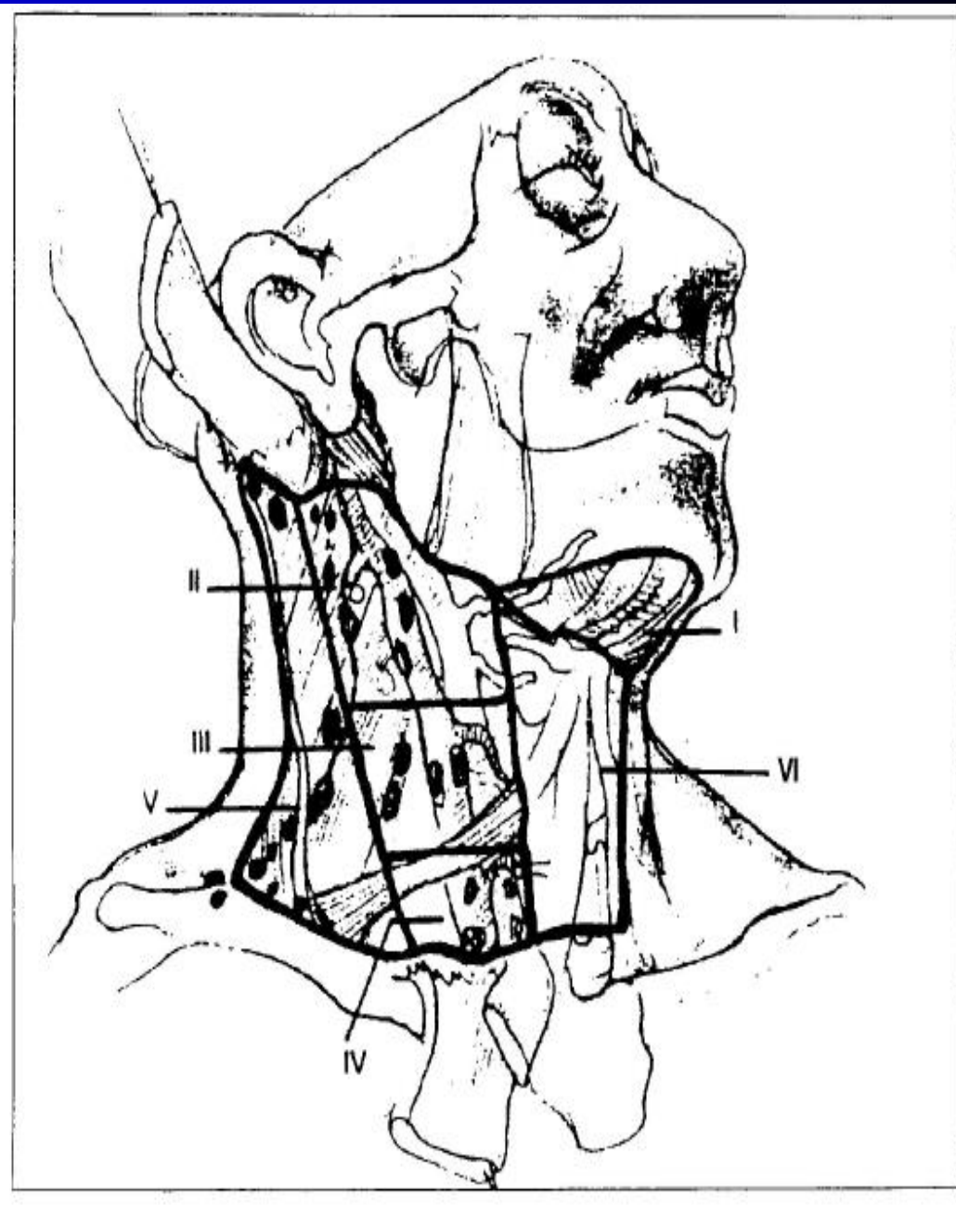
An **elective neck dissection** is a neck dissection carried out in the absence of palpable lymph nodes for a primary tumor which experience has shown to have a high metastatic rate - oropharynx, hypopharynx, supraglottic larynx, the base of the tongue. The purpose of this operation is to deal with micrometastases. In treatment for metastasis there is used a combination with actinotherapy.

# The Memorial Sloan Kettering Cancer Center classification

- **Oblast I** - submentální a submandibulární trojúhelník
- **Oblast II** - ohraničena ventrálně zadním bříškem m. digastricus, kraniálně bazí leabní, dorsálně zadní hranou kyvače a kaudálně jazykou a bifurkací a. car. communis.
- **Oblast III** - kraniálně ohraničena jazykou a bifurkací, ventrálně skeletem hrtanu, dorsálně zadní hranou kyvače a kaudálně m. omohyoideus, který ji odděluje od oblasti IV.
- **Oblast IV** - končí nad klíčkem.
- **Oblast V** - laterální krční trojúhelník ohraničený zadním okrajem kyvače, hranou m. trapesius a klavikulou.
- **Oblast VI** – přední krční trojúhelník



- I** submandibulární a submentální uzliny
- II** horní jugulární uzliny
- III** střední jugulární uzliny
- IV** dolní jugulární uzliny
- V** uzliny v zadním krčním trojúhelníku a oblast
- VI** uzliny v předním krčním trojúhelníku.





# Classification of neck dissections (Ferlito 2011)

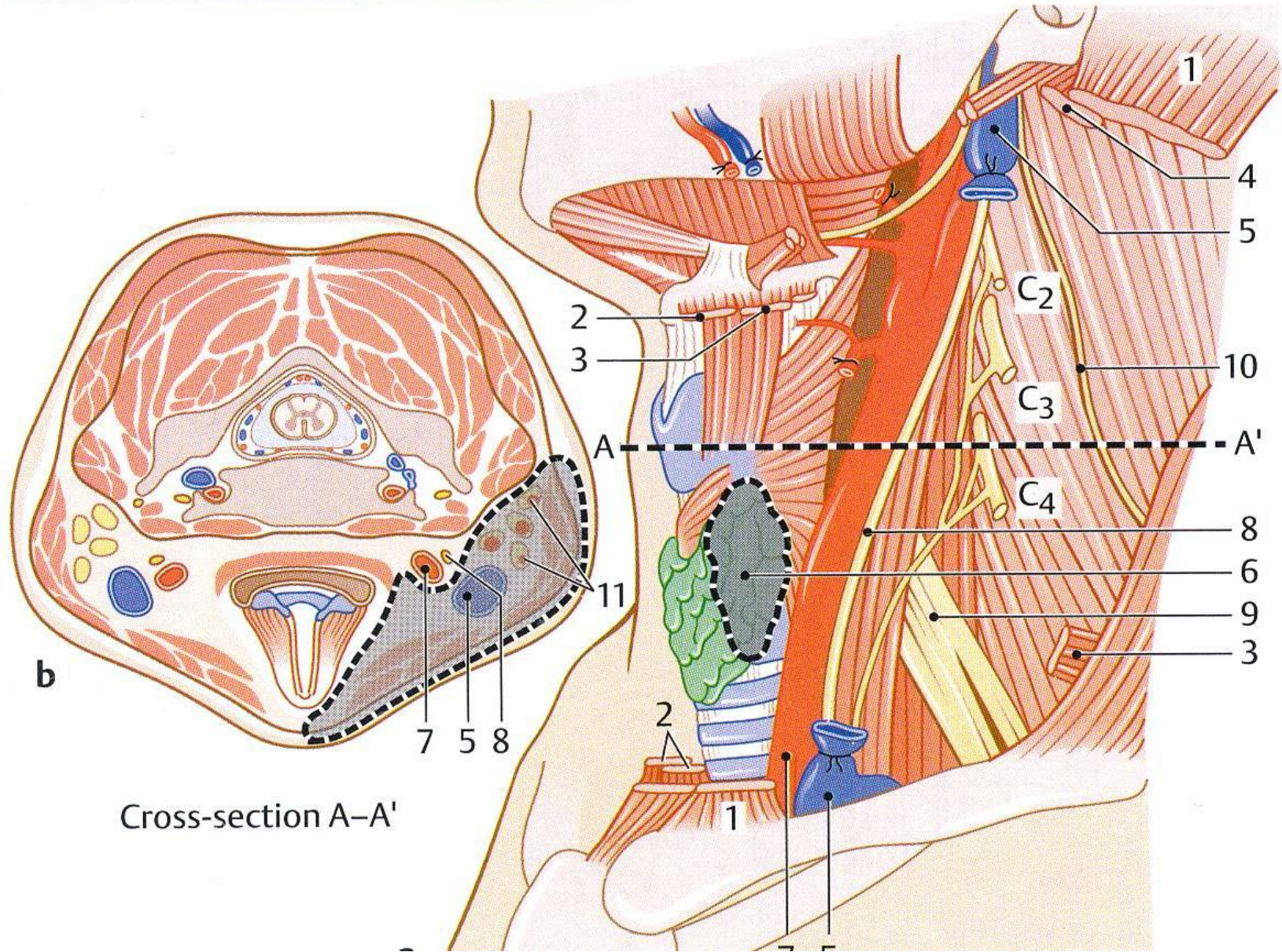
---

- **ND** – symbol for neck dissection
- Letter L,R – description of side
- Removed regions of neck lymph nodes, described by number I-VII (incl. A,B u obl. I,II a V)
- Removed non lymphatic structures n.XI, IJV, MSC)

Example:

**ND R (I-V, SCM, IJV)** = modified radical neck dissection right with sparing of n. XI a m. sternocleidomastoideus

# Modified radical neck dissection right with sparing of n. XI (ND L (I-V, SCM, IJV) )



# Neck block dissection





