

**MUNI
MED**

Preclinical dentistry I.

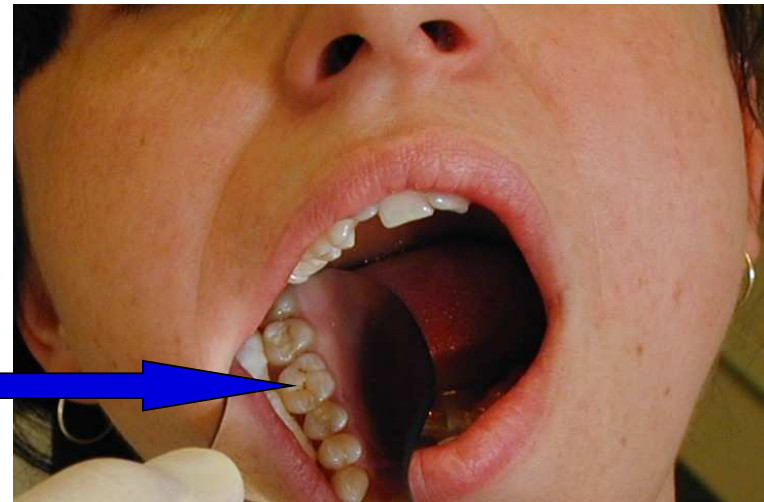Class I.



Classification acc. to Black

- Class I.

Pit and fissure caries

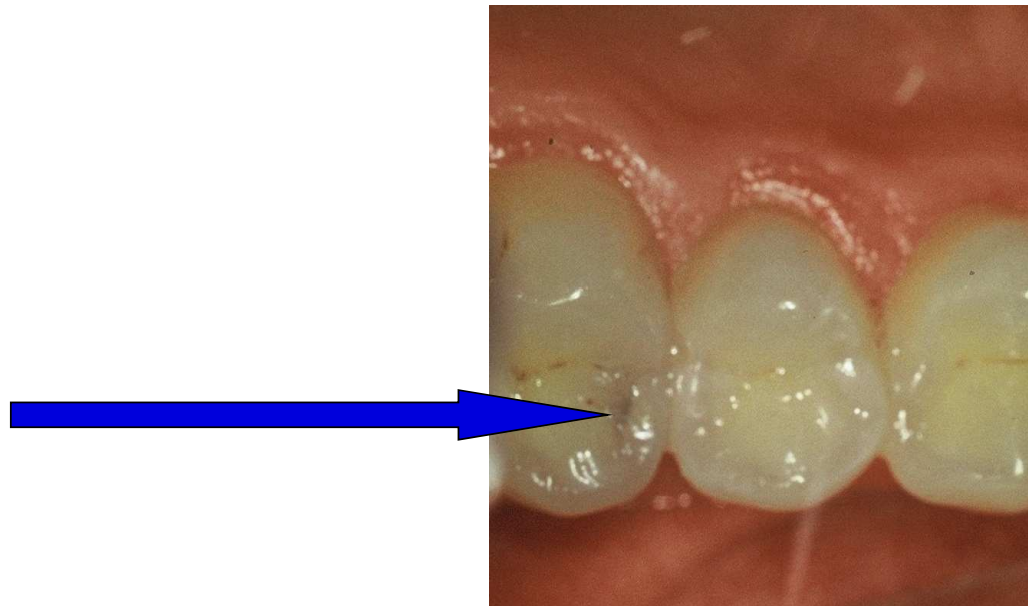


2

Classification acc. to Black

- Class II.

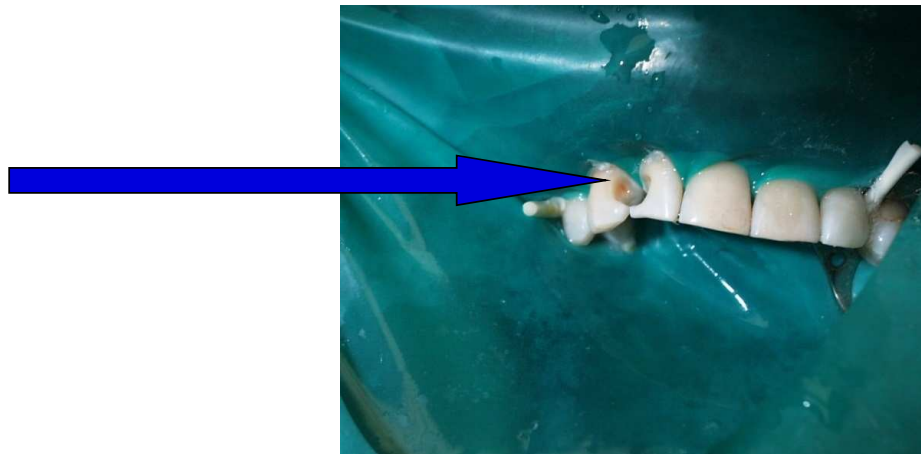
Proximal surfaces in premolars and molars



Classification acc. to Black

- Class III.

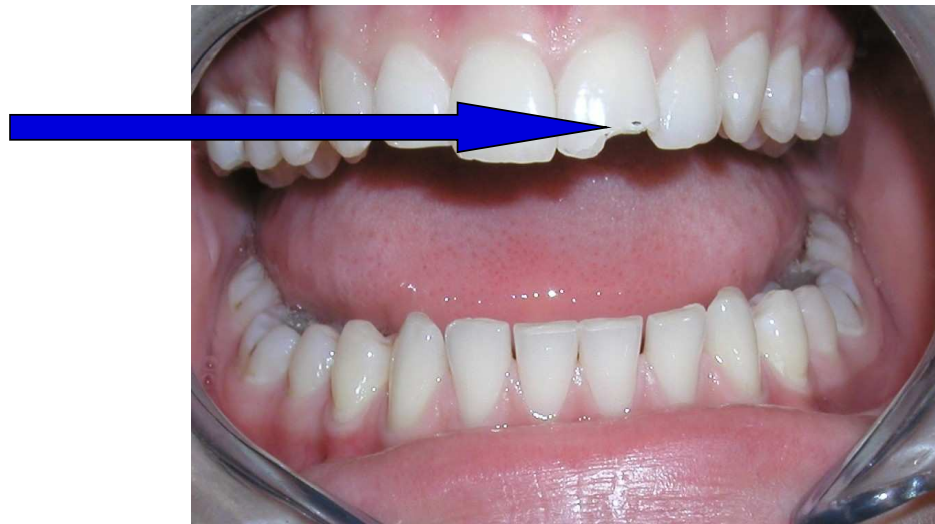
Proximal surfaces of incisors and canines without lost any part if incisal edge



Classification acc. to Black

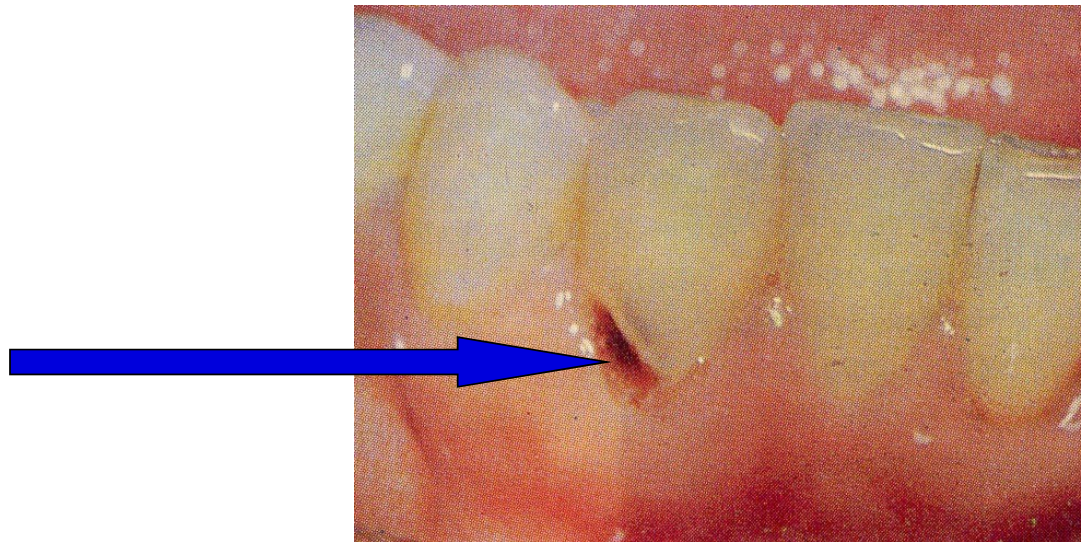
- Class IV.

Proximal surfaces of incisors and canines with
lost an incisal ridge



Classification acc. to Black

- Class V. cervical lesions



Preparation of cavities

Access to the cavity

Outlines – cavosurface margin (**extention for prevention**)

Principles of **retention**

Principles of **resistance**

Excavation of carious dentin

Preparation of borders – finishing

Control

Protection of dentin wound

- Dentin wound should be covered – protection of dental pulp against irritation

Physical

-thermal

-osmotic

Chemical

Combination

Protection of dentin wound

Isolation

Filling (small cavities)

Base (moderate – large cavities- depth 2mm and more approx.)

Adhesive systems (composite materials)

Filling

- Filling replaces lost hard dental tissue anatomically and functionally
- Always different properties in comparison to hard dental tissues.

Preparation of the cavity I.st class acc. to Black

- Cavities in fissures and pits
- (Occlusal surfaces of premolars and molars and in f. caeca)

F. Caeca: buccal surfaces of lower molars,

Palatal surfaces of lower molars, palatal surfaces of upper incisors

(mostly lateral)

All pit and fissure restorations (fillings)

They are assigned in to three groups.

R. on occlusal surface of premolars and molars

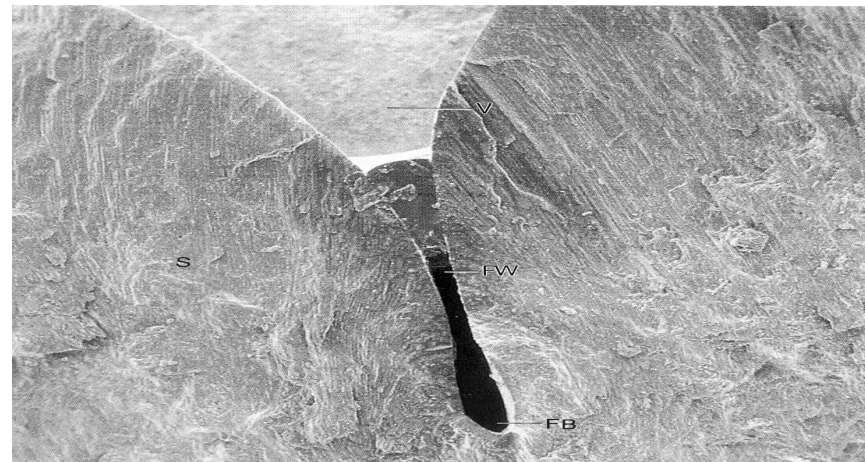

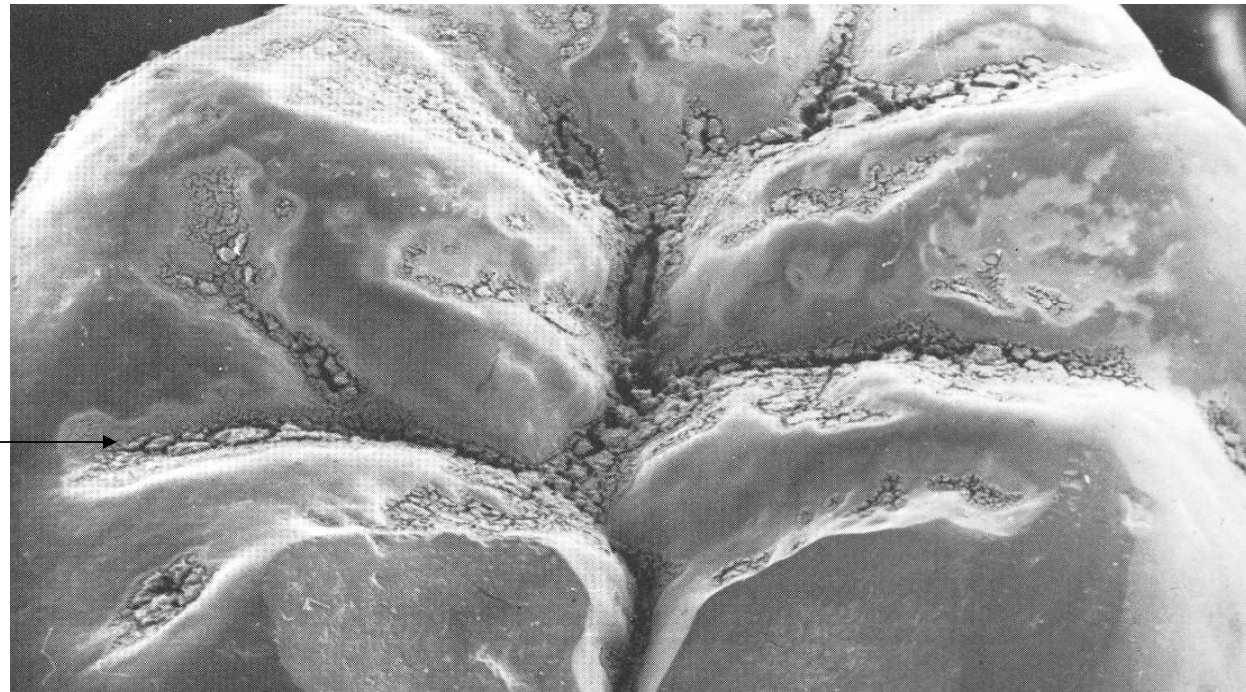
R. in foramina caeca – usually on occlusal two thirds of the facial and lingual surfaces of molars.

R. on lingual surface of maxillary incisors.

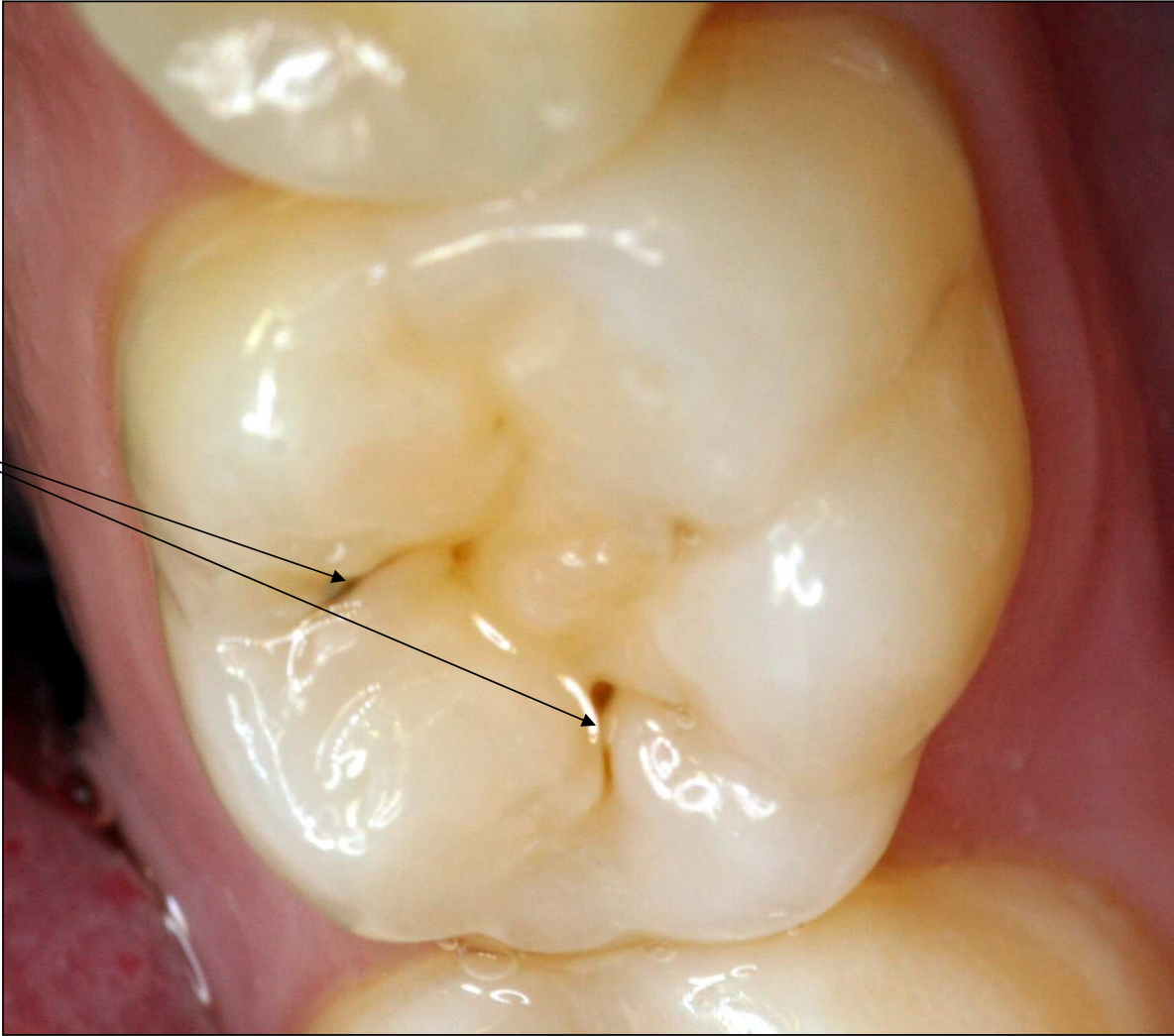


Morphology
of fissures

Biofilm



Caries



Materials: Amalgam, composite.

Amalgam:

Pertinent material qualities and properties

Strength

Longevity


Easy of use

Clinically proven success



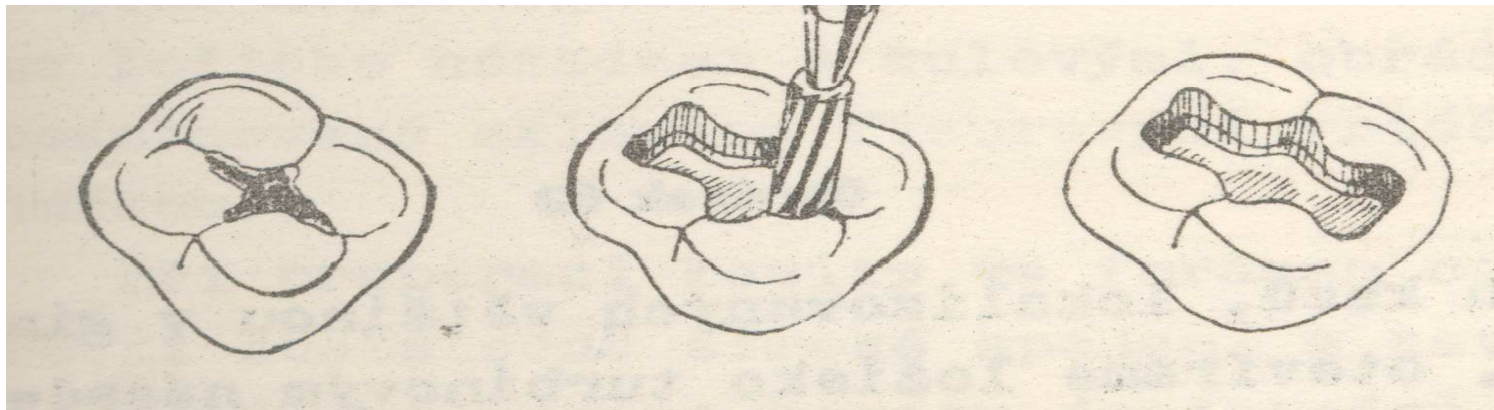
Access to the cavity

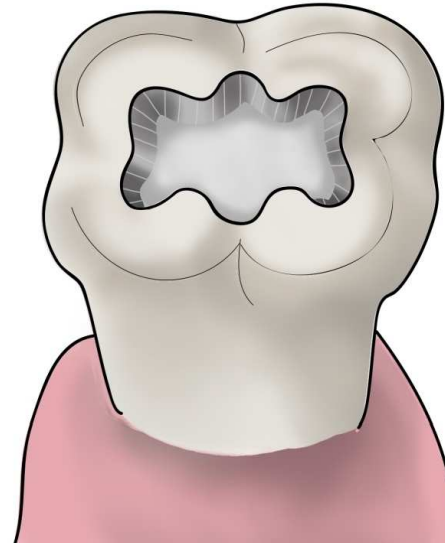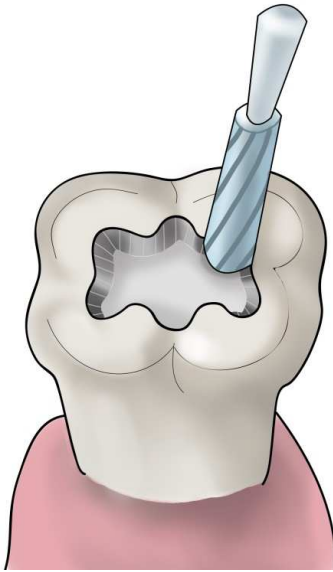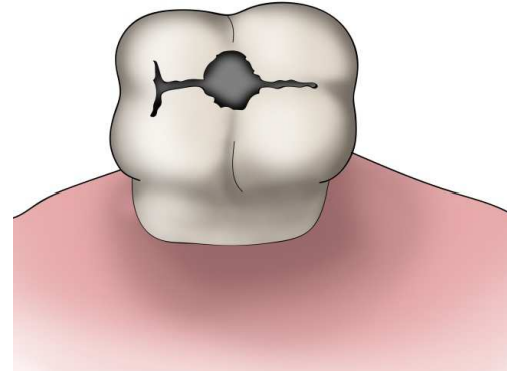
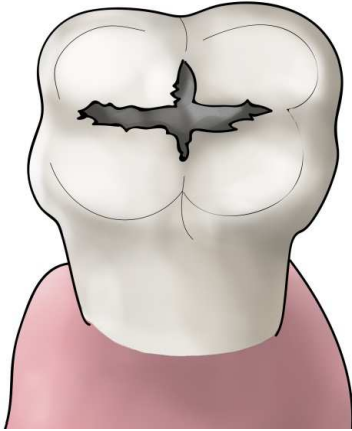
- From the occlusal surface using the fissure bur (or diamond burs, see below).

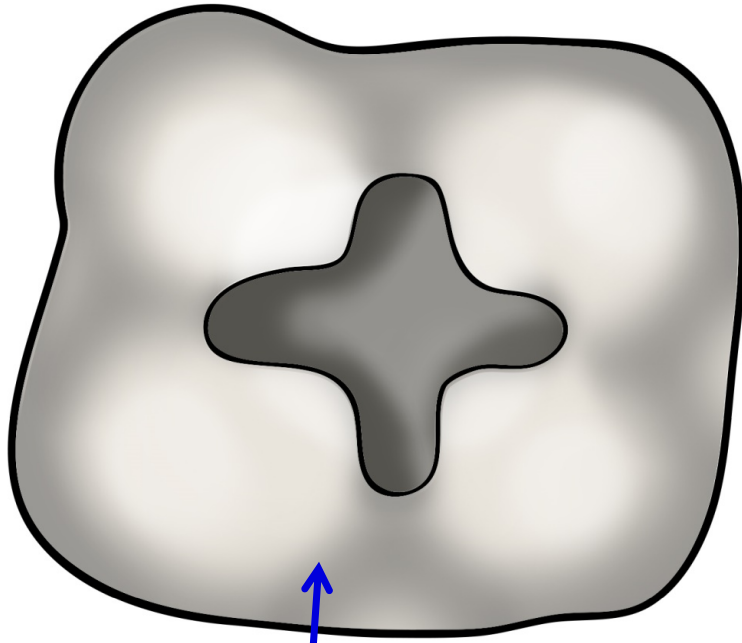


Cavosurface margin

- Ideal outline includes all occlusal pits and fissures. If transvers ridge (1st lower premolar) or oblique ridge (1st and 2nd upper molar) are not affected, it is strongly recommended not to prepare them.



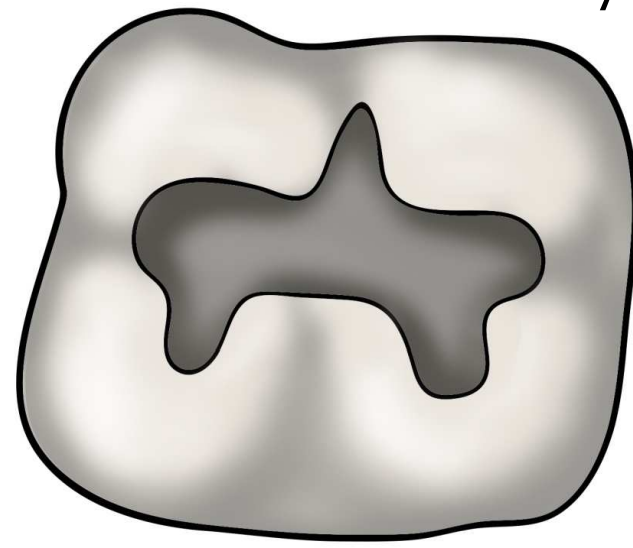




Mandibular 7



Mandibular
6

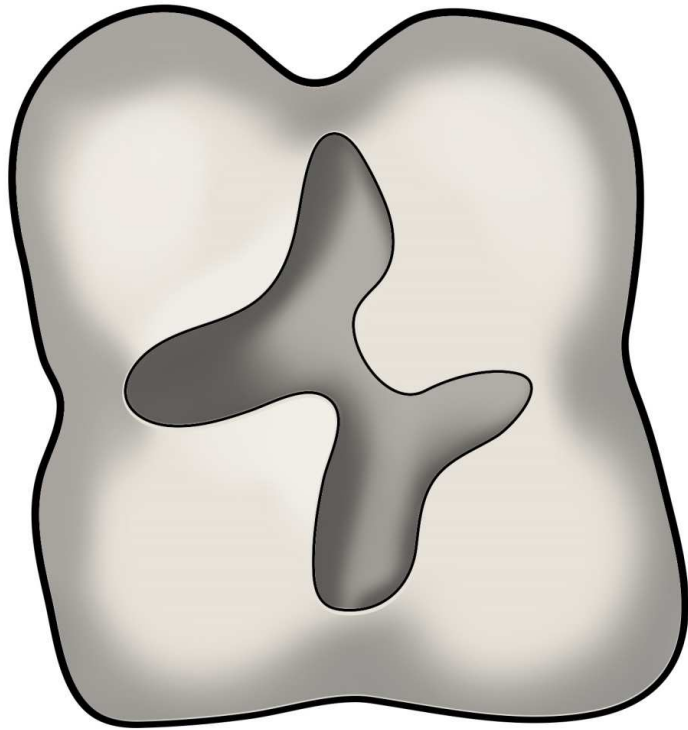


orally

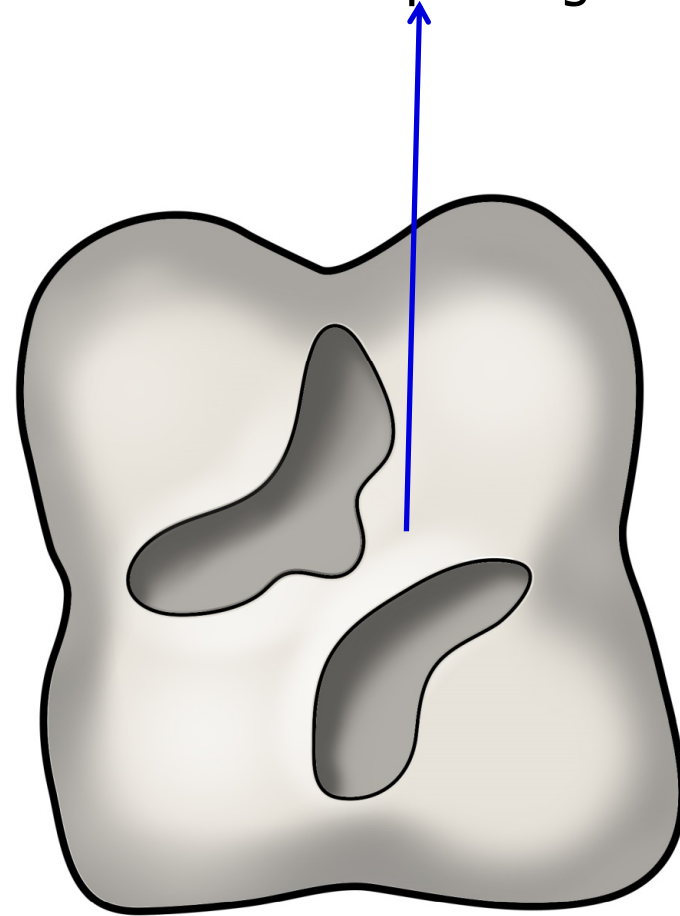
vestibulary



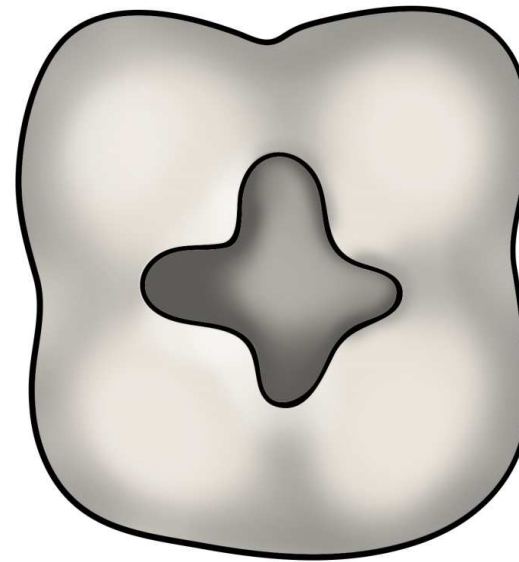
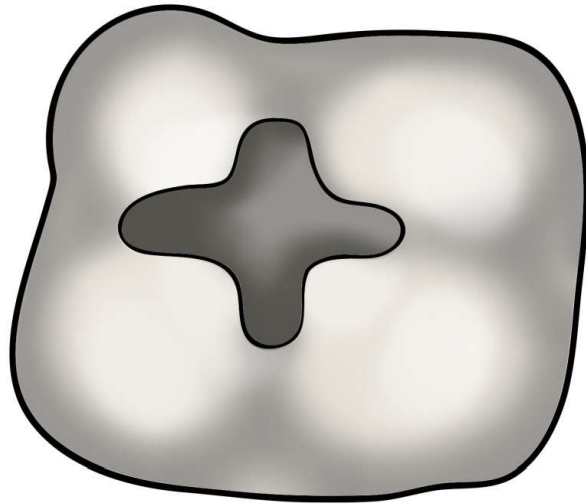
First upper molar



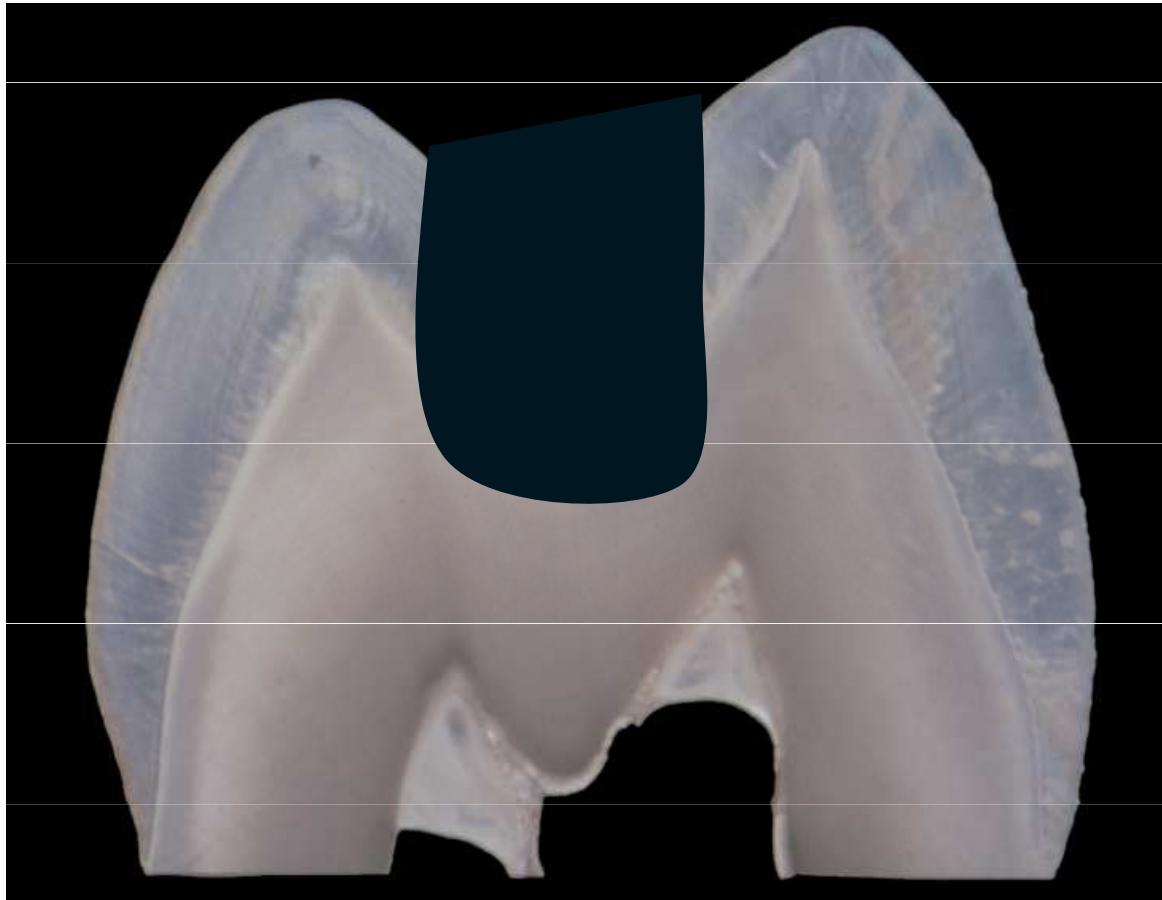Oblique ridge



Third molars - variable



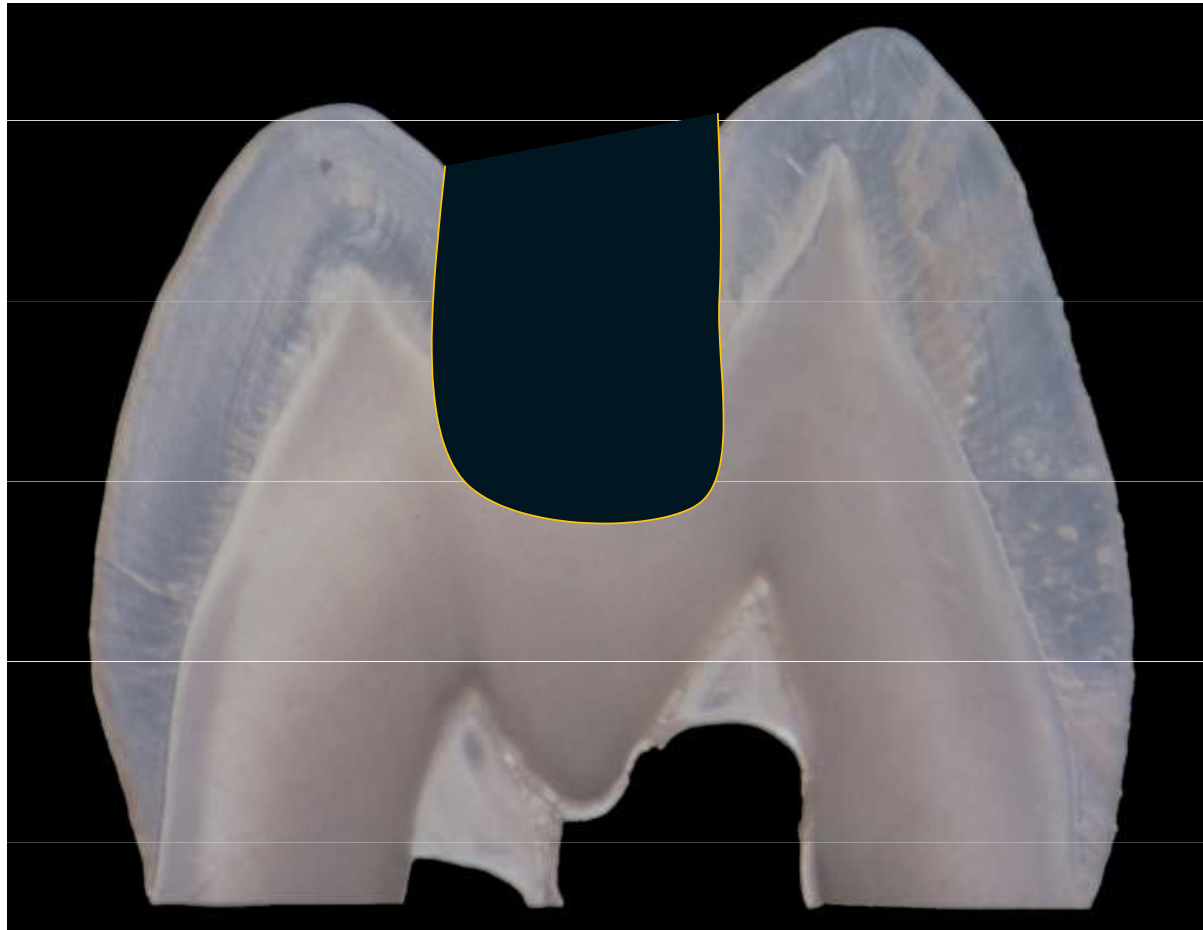**$\frac{1}{2}$ distance between the bottom of the fissure
and the cusp**



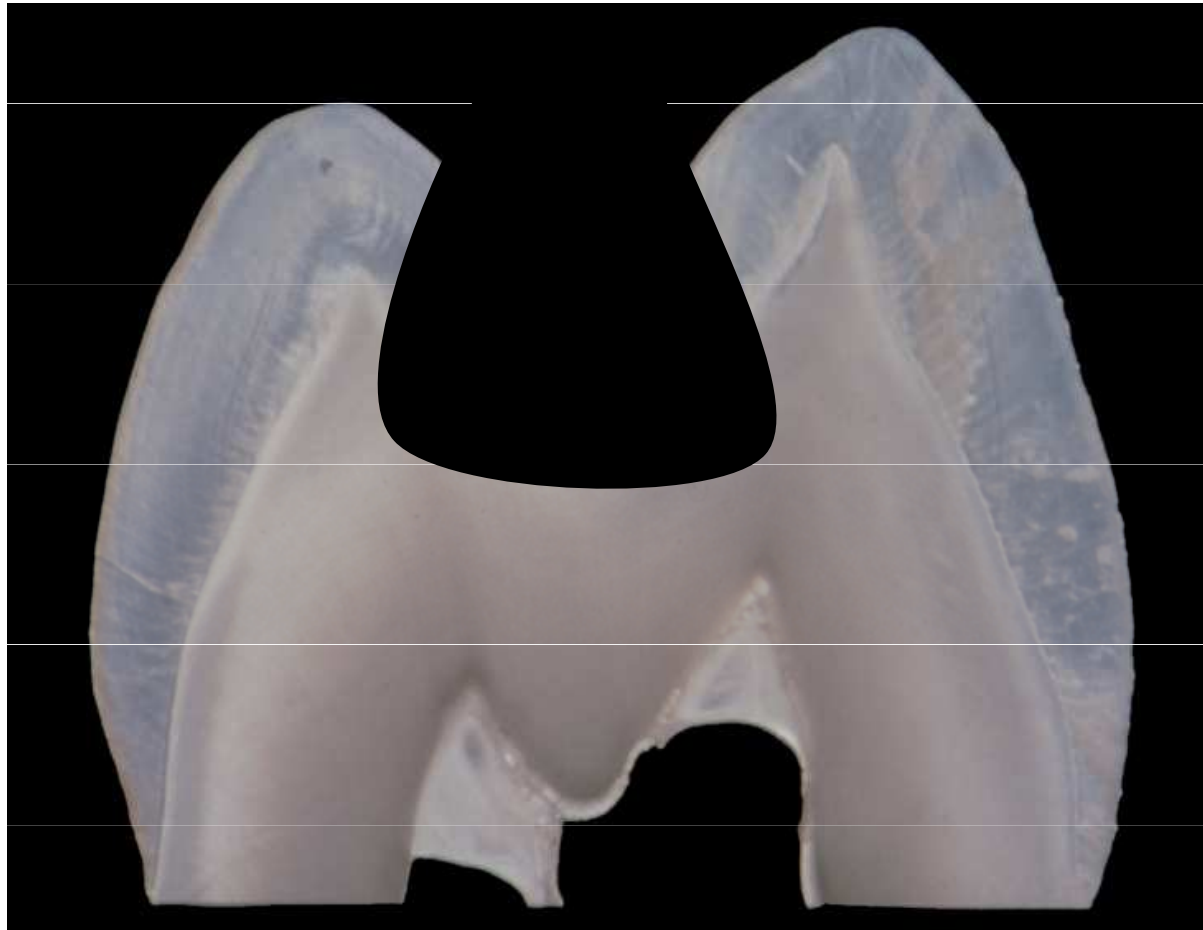
Retention

- Box – undercut (1,5 – 2 mm deep).

Box



Undercut



Resistance

Depth 1,5 – 2 mm

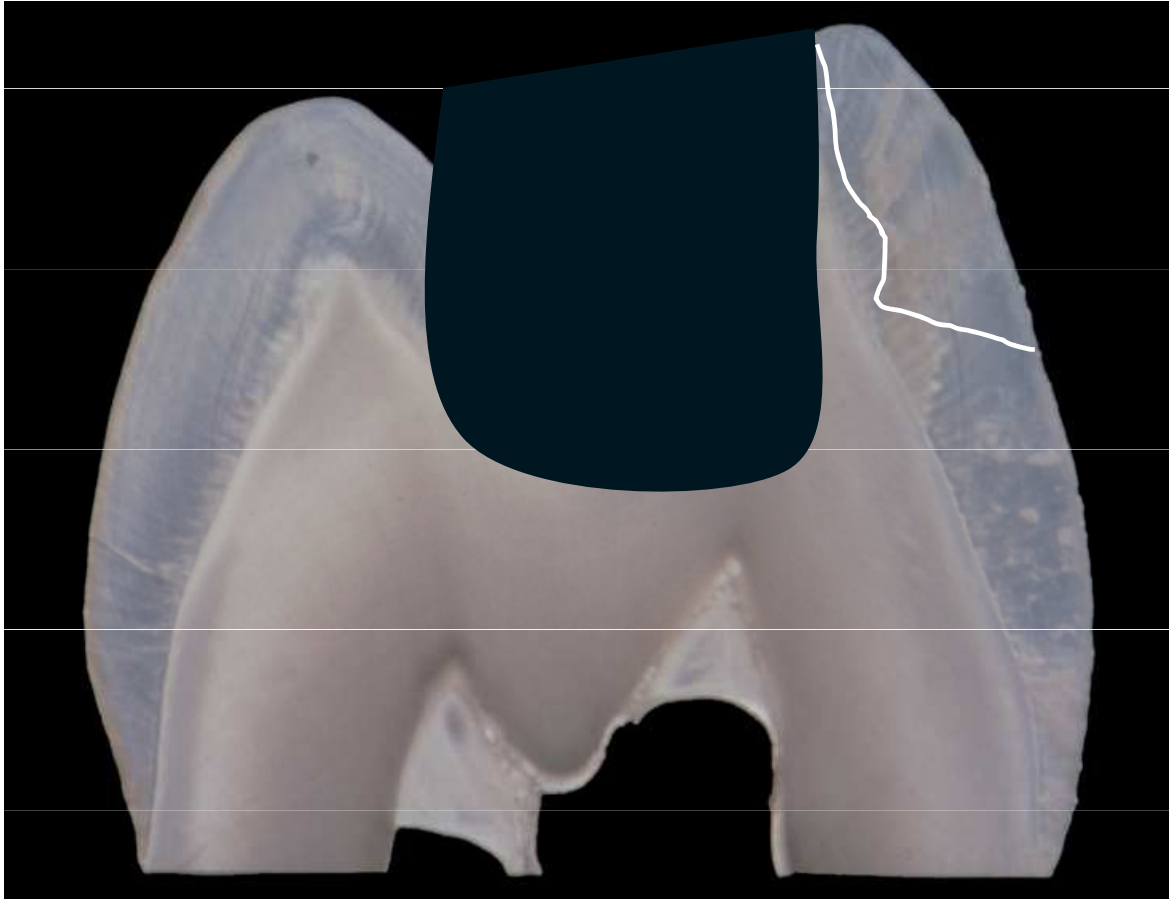
The enamel is always supported with dentin

The cavosurface margin till $\frac{1}{2}$ distance of the bottom of the fissure and the cusp

No sharp edges

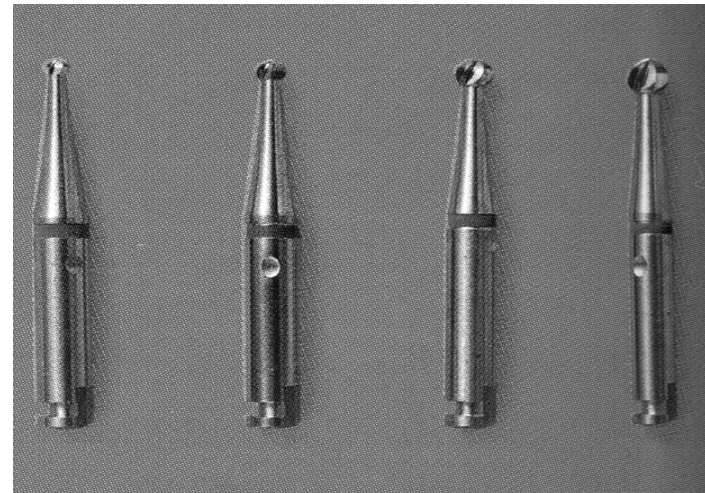
Resistance

- Proximal ridges must not be undermined!

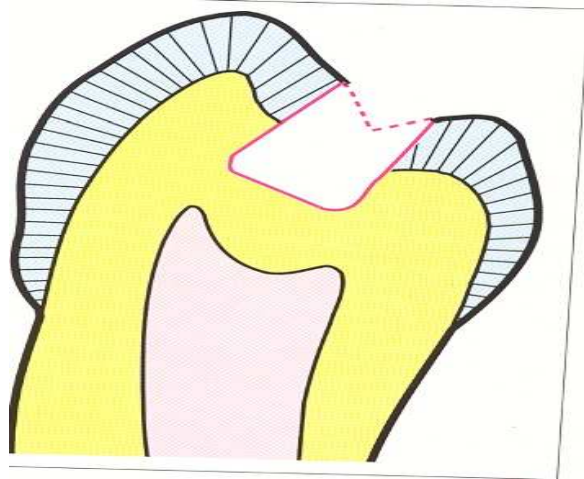


Excavation of carious dentin

- Round burs : 3000/min
↓
- Excavators




Orientation of the pulpal wall



Finishing

Fine diamonds



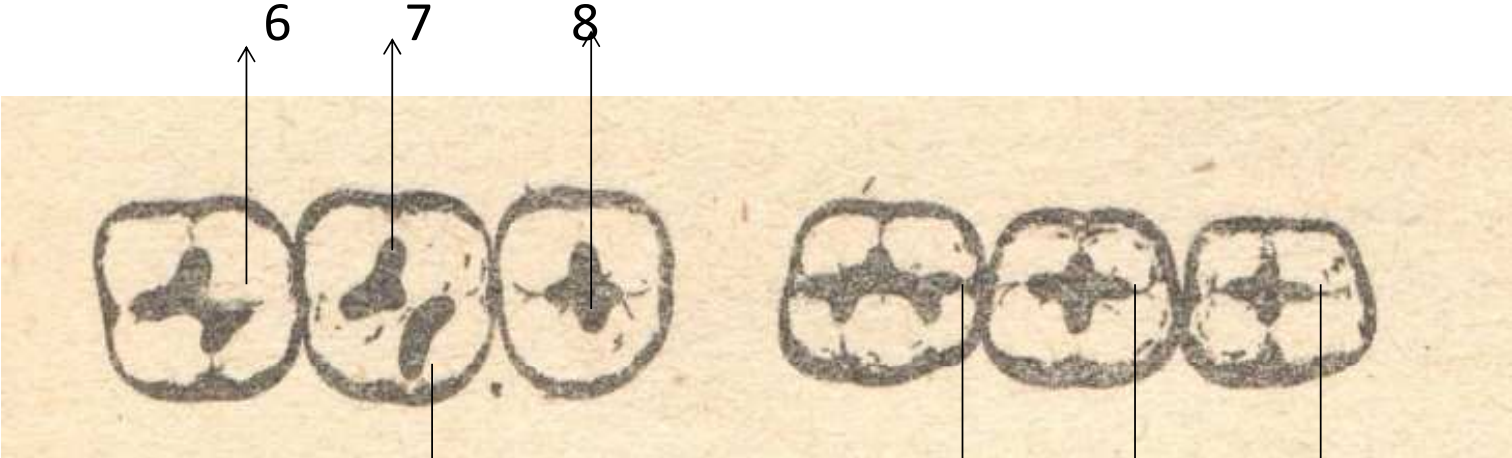
Final check

Good illumination, dry field, magnification.

Direct and /or indirect view

Probe

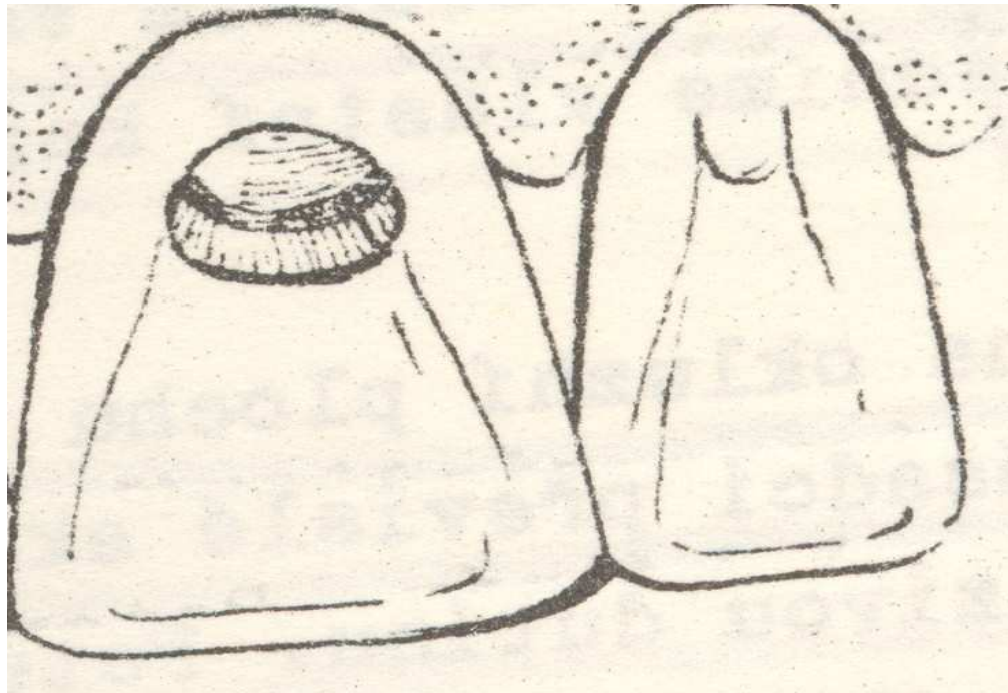
Molars



Oblique ridge

6 7 8





Foramen caecum:

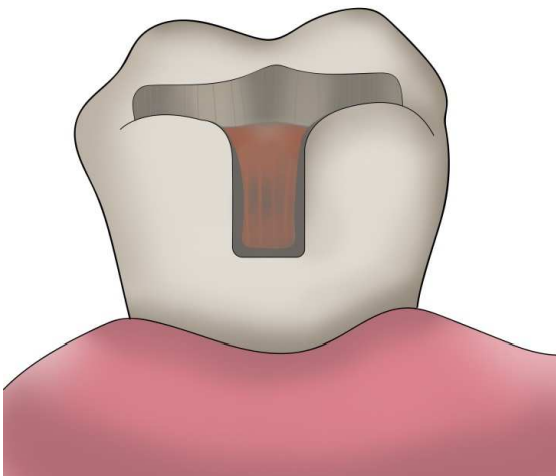
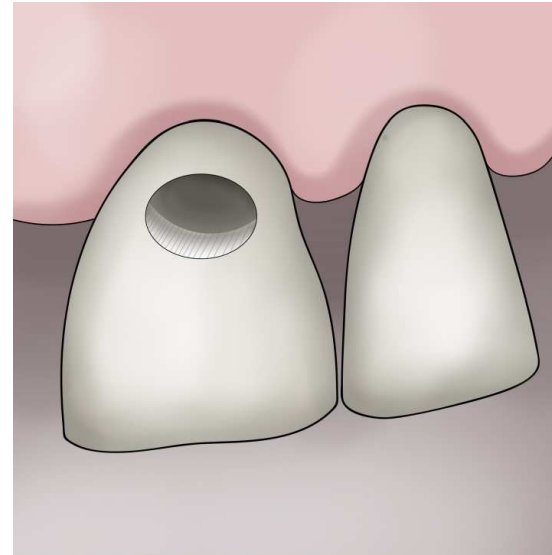
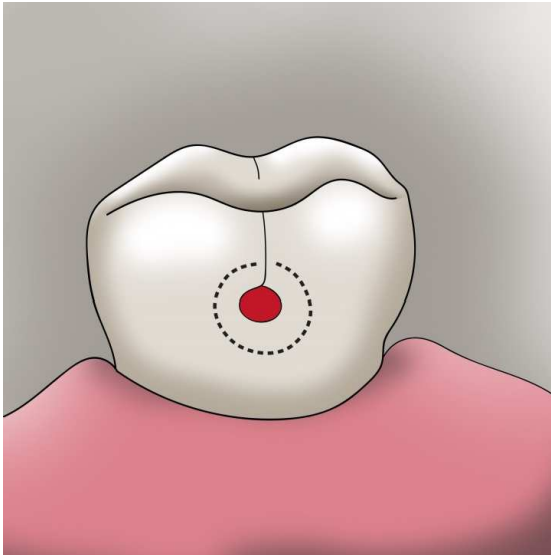
Preparation is limited on carious lesion

The bottom is located in dentin

Undercuts

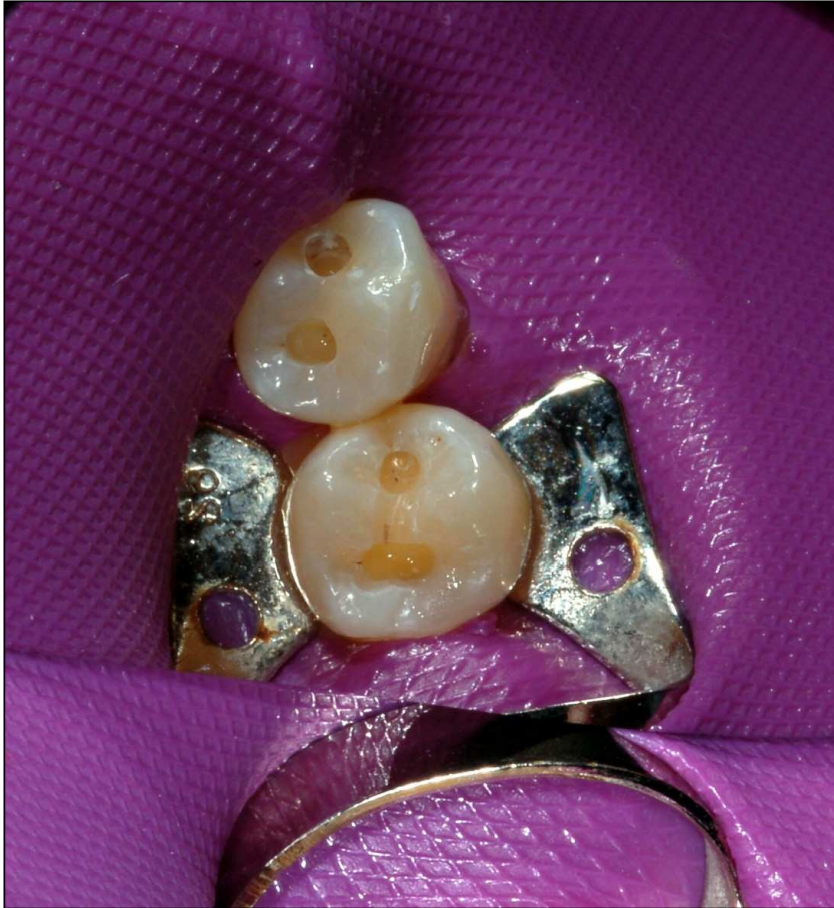Finishing of cavity borders





If the enamel is undermined occlusally – extension on occlusal surface

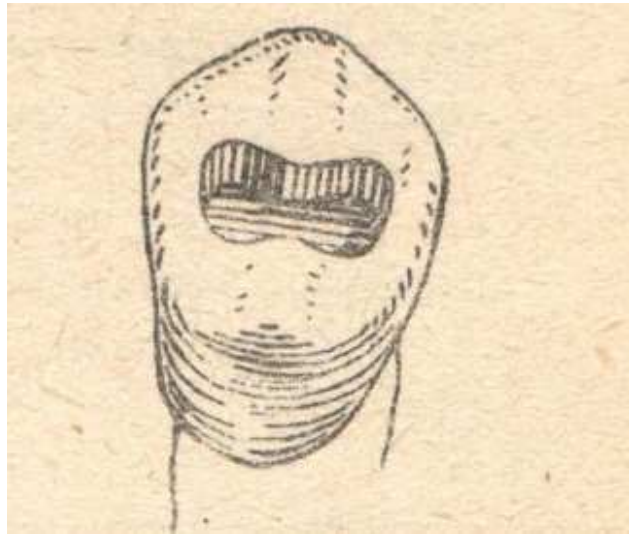




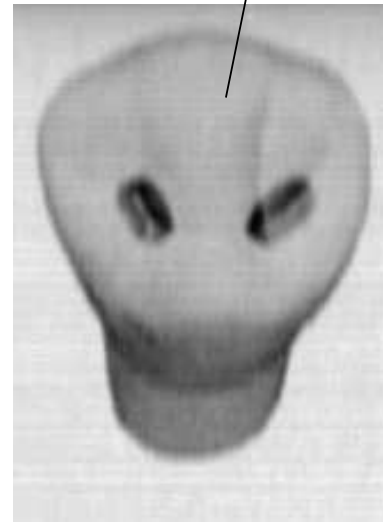
Preparation with
preservation of the
transverse ridge

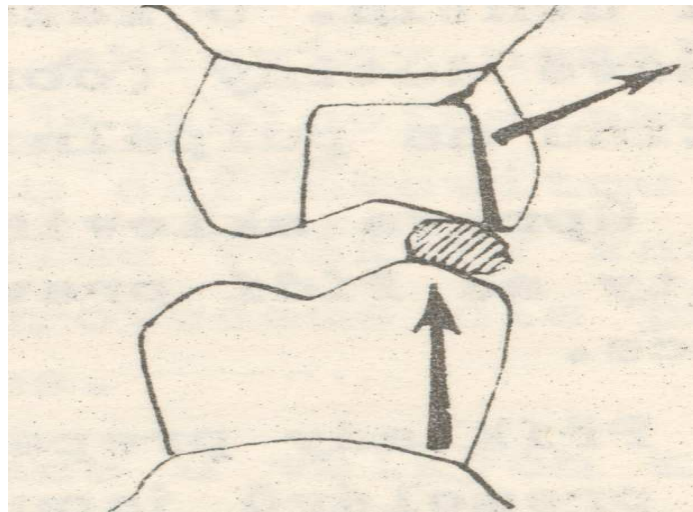
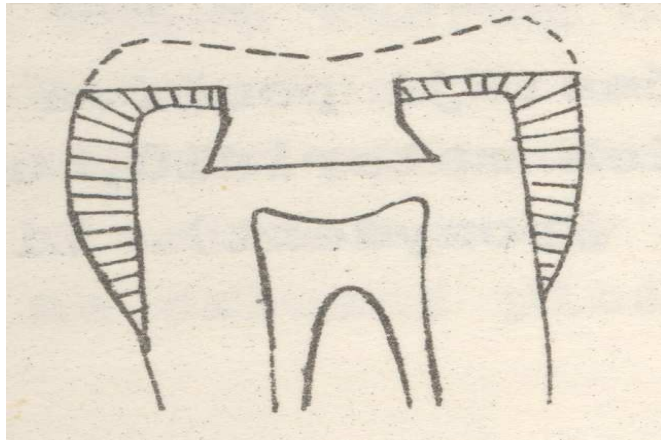


Premolars



Crista transversa (transvers ridge)
Lower P1





**Base is made usually
of zinkoxidphosphate cement
It is placed only on pulpal wall**

