



Mužský pohlavní systém

gonády – testes

vývodní cesty

- epididymis
- ductus deferens
- ductus ejaculatorius
- mužská urethra

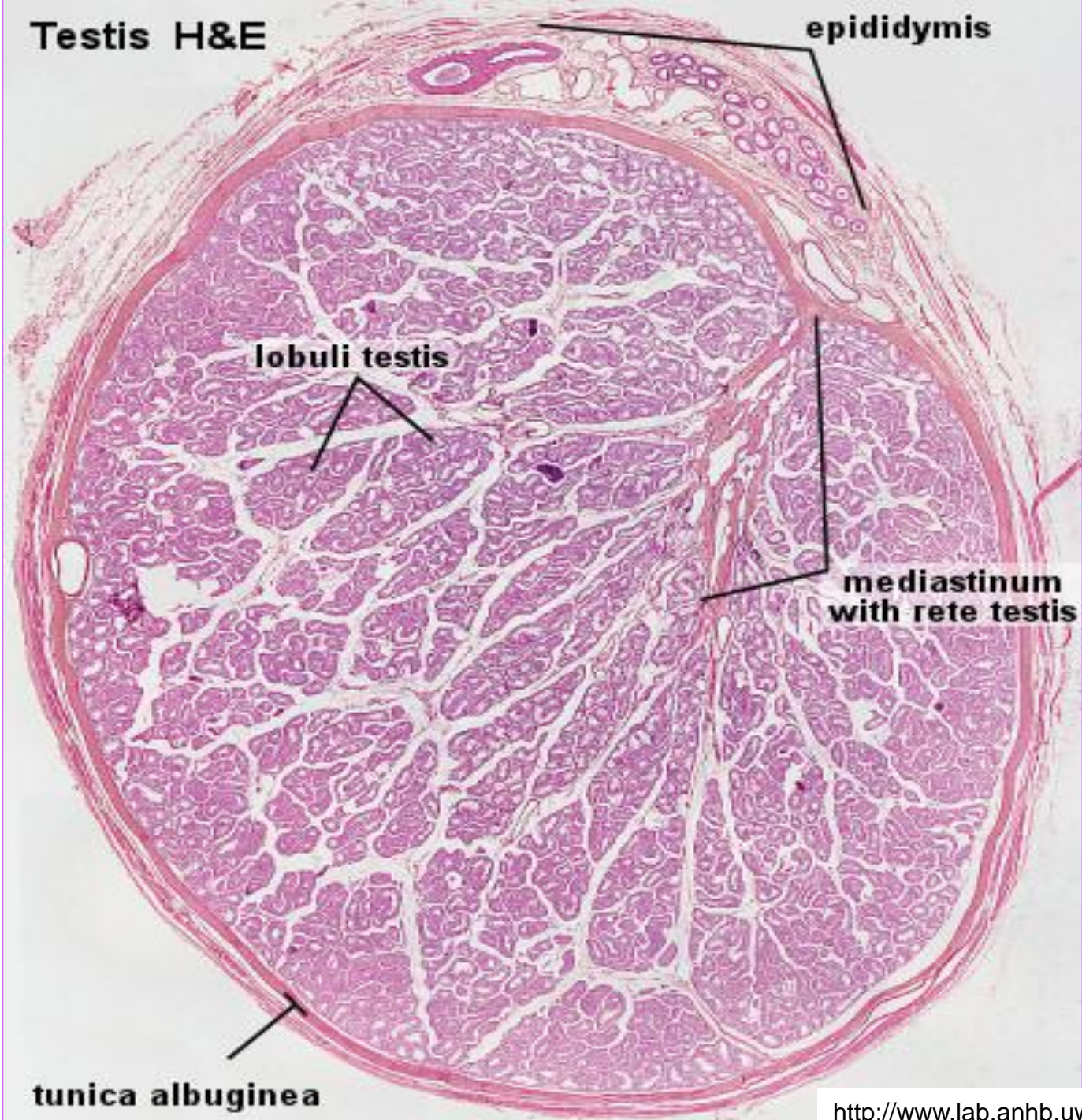
akcesorní žlázy

- prostata
- vesiculae seminales (gll. vesiculosae)
- gll. bulbourethrales

zevní pohl. orgány

- penis

Testis H&E



epididymis

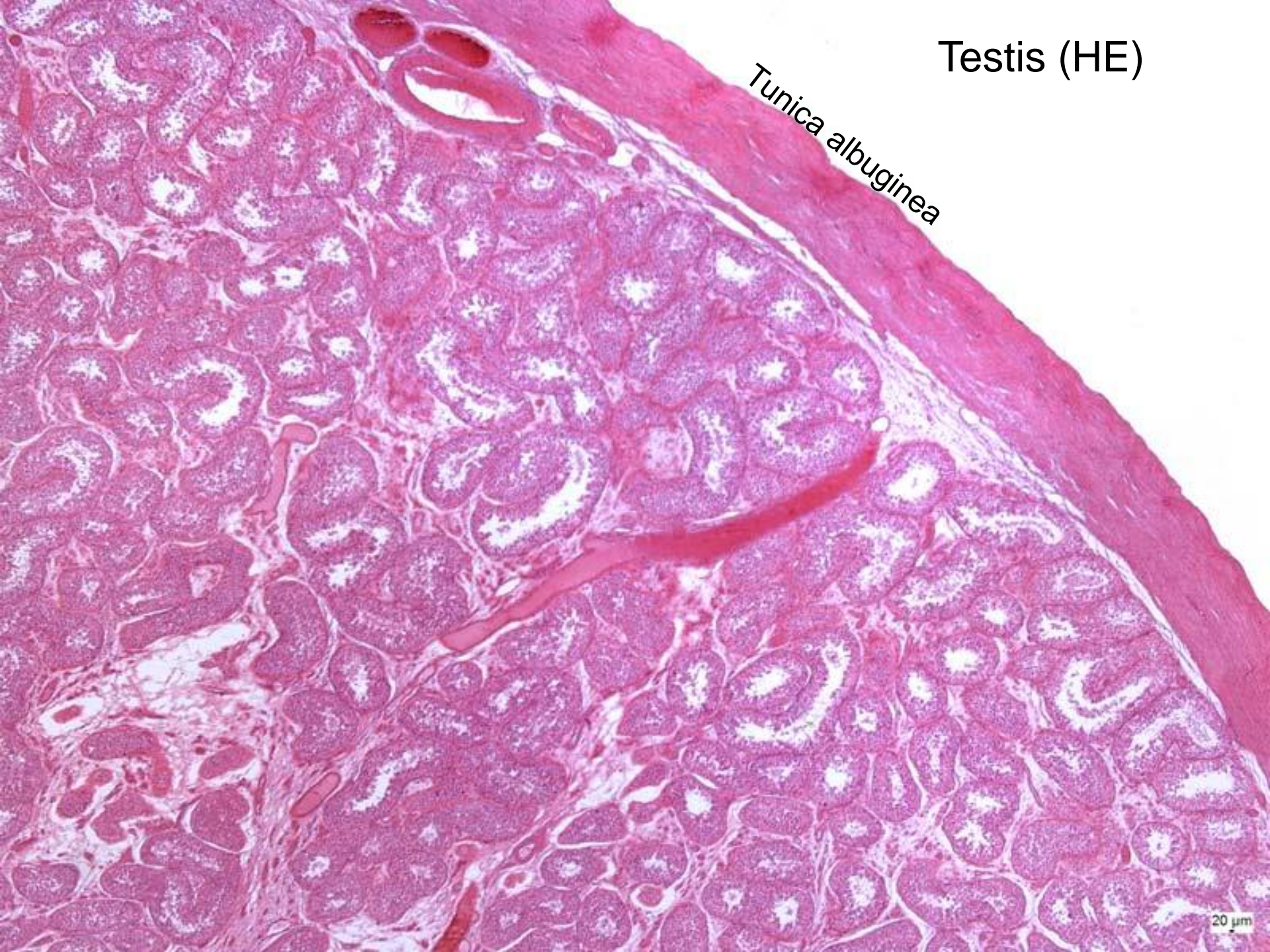lobuli testis

**mediastinum
with rete testis**

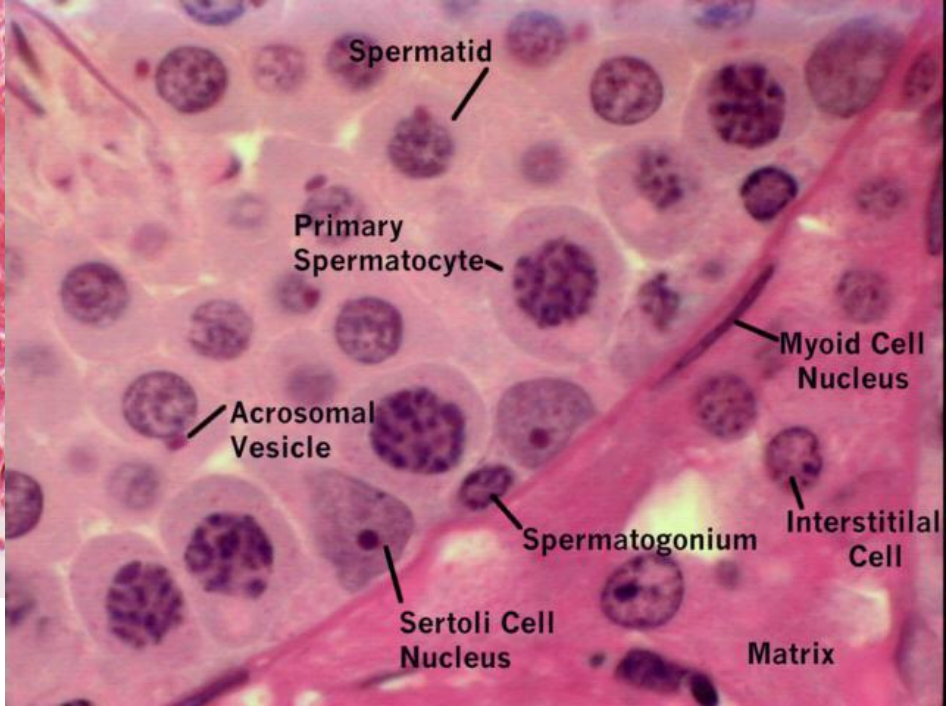
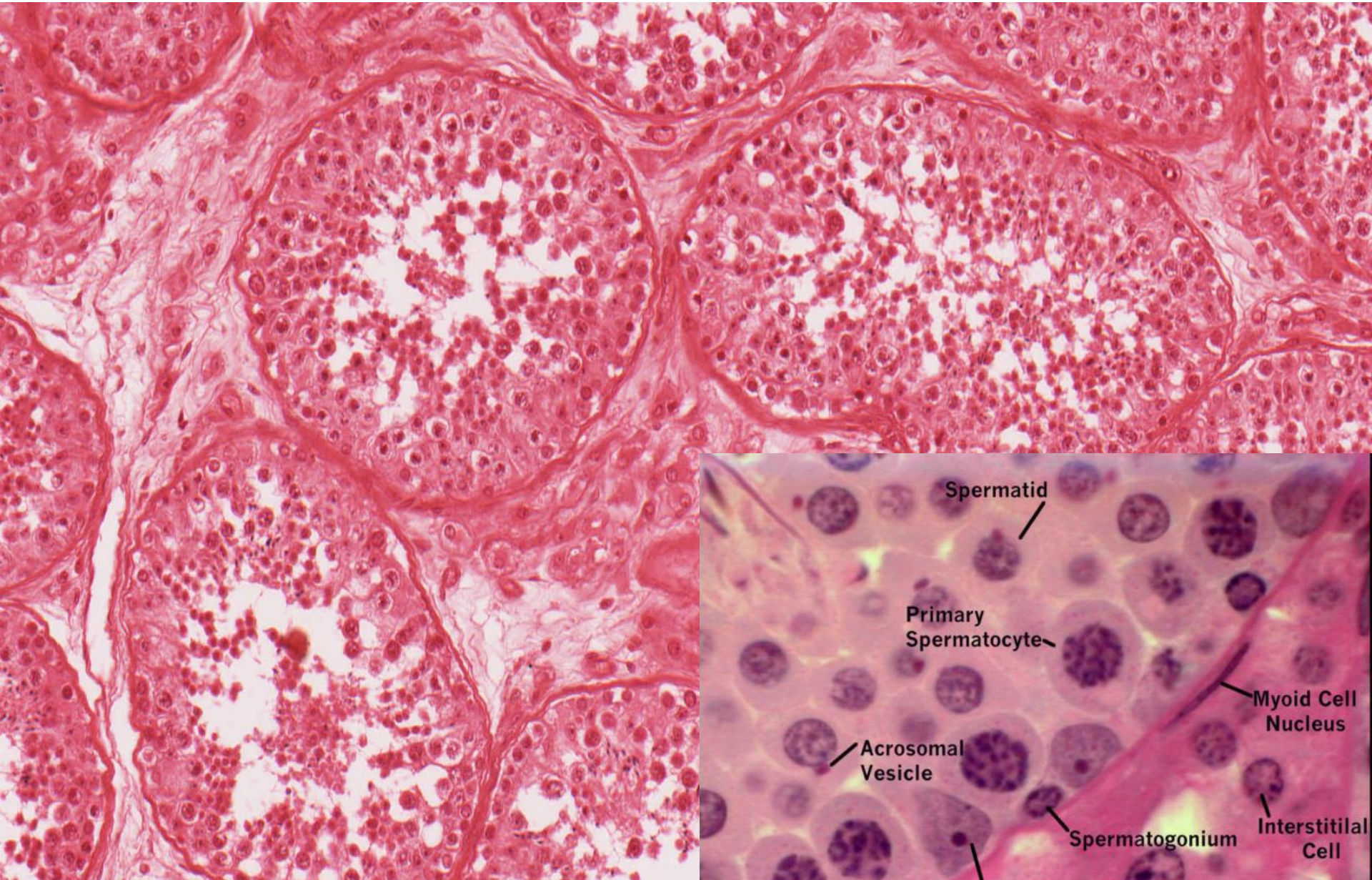
tunica albuginea

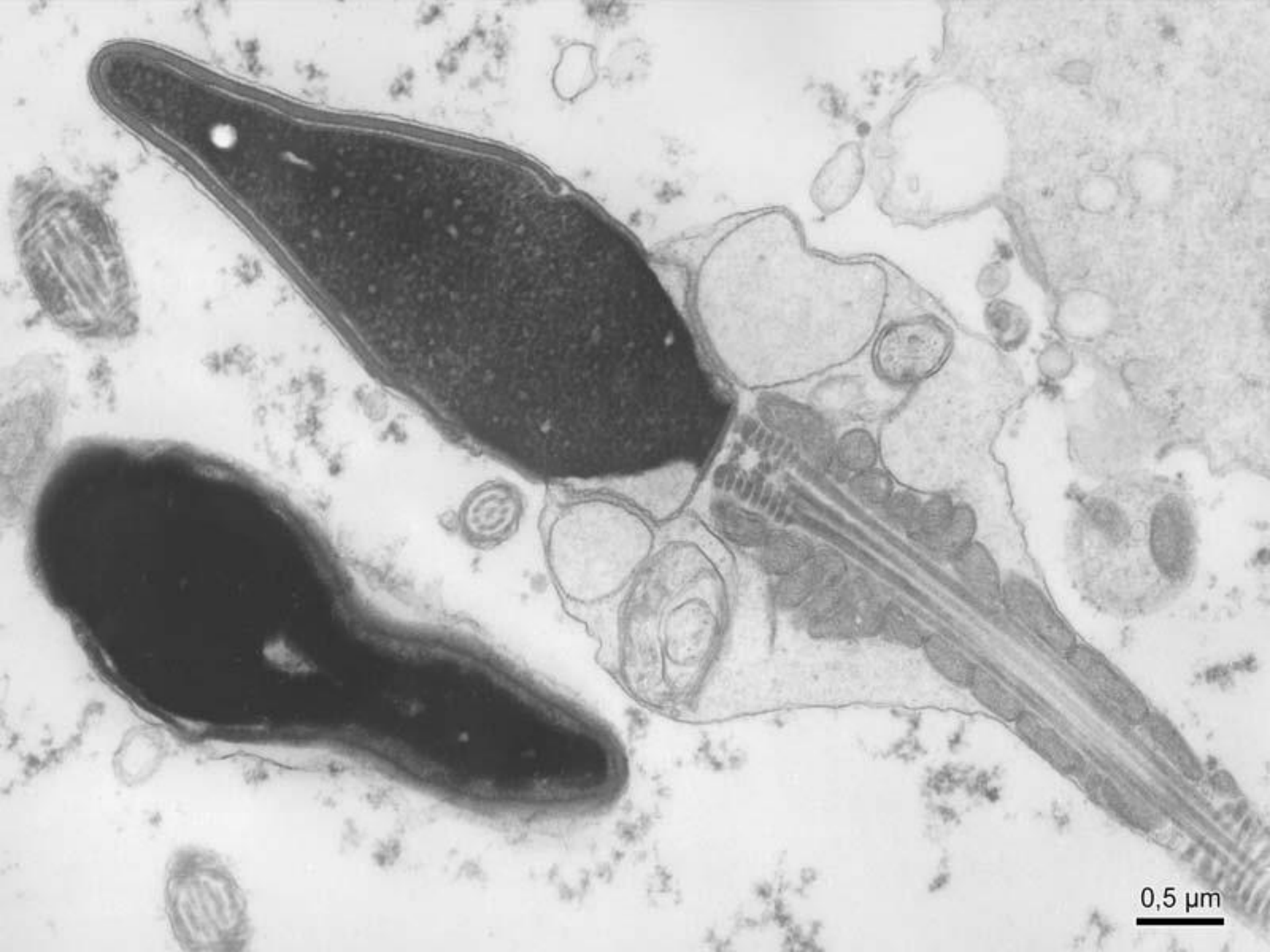
Testis (HE)

Tunica albuginea



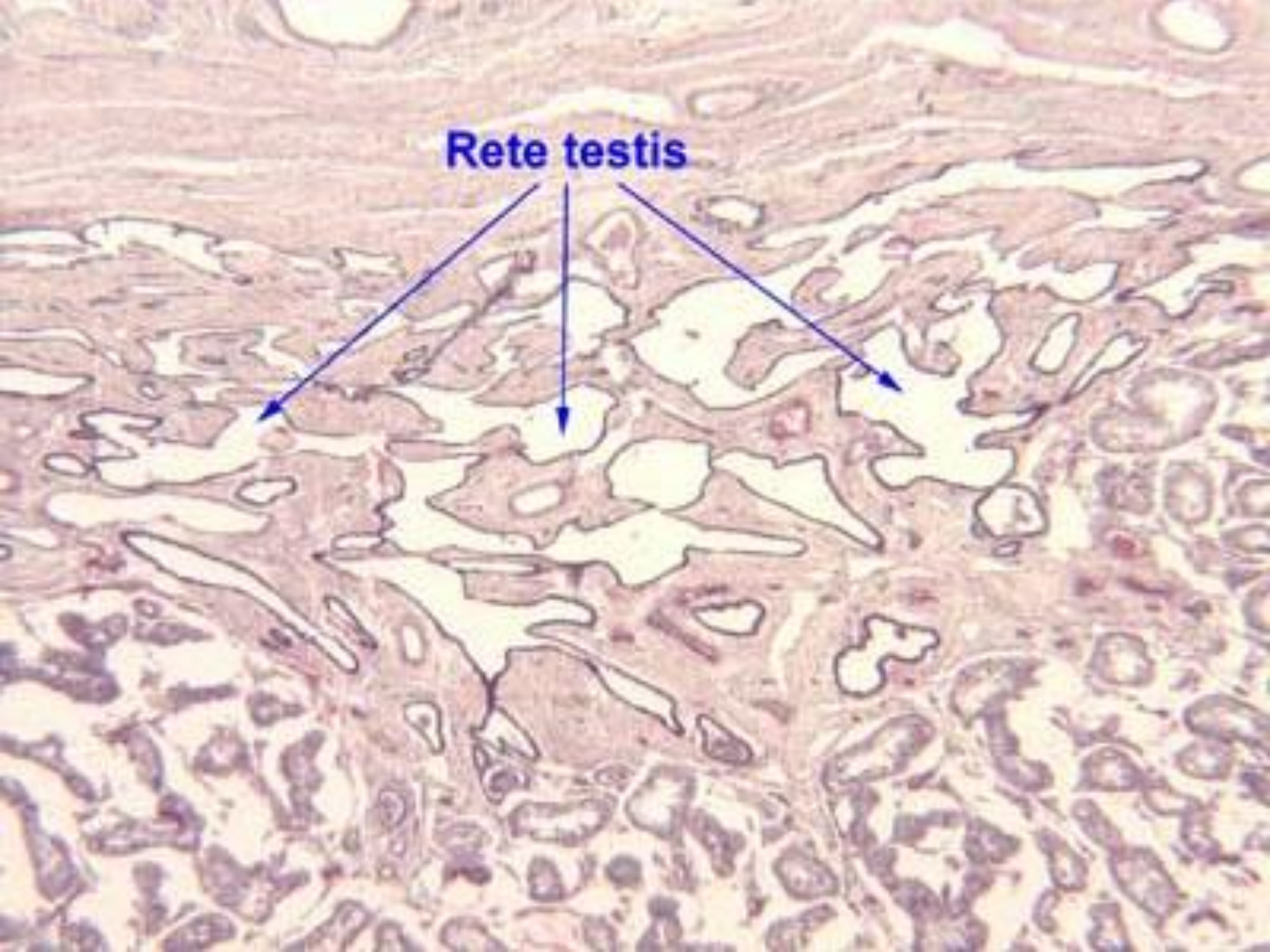
Tubuli seminiferi contorti - spermatogeneze



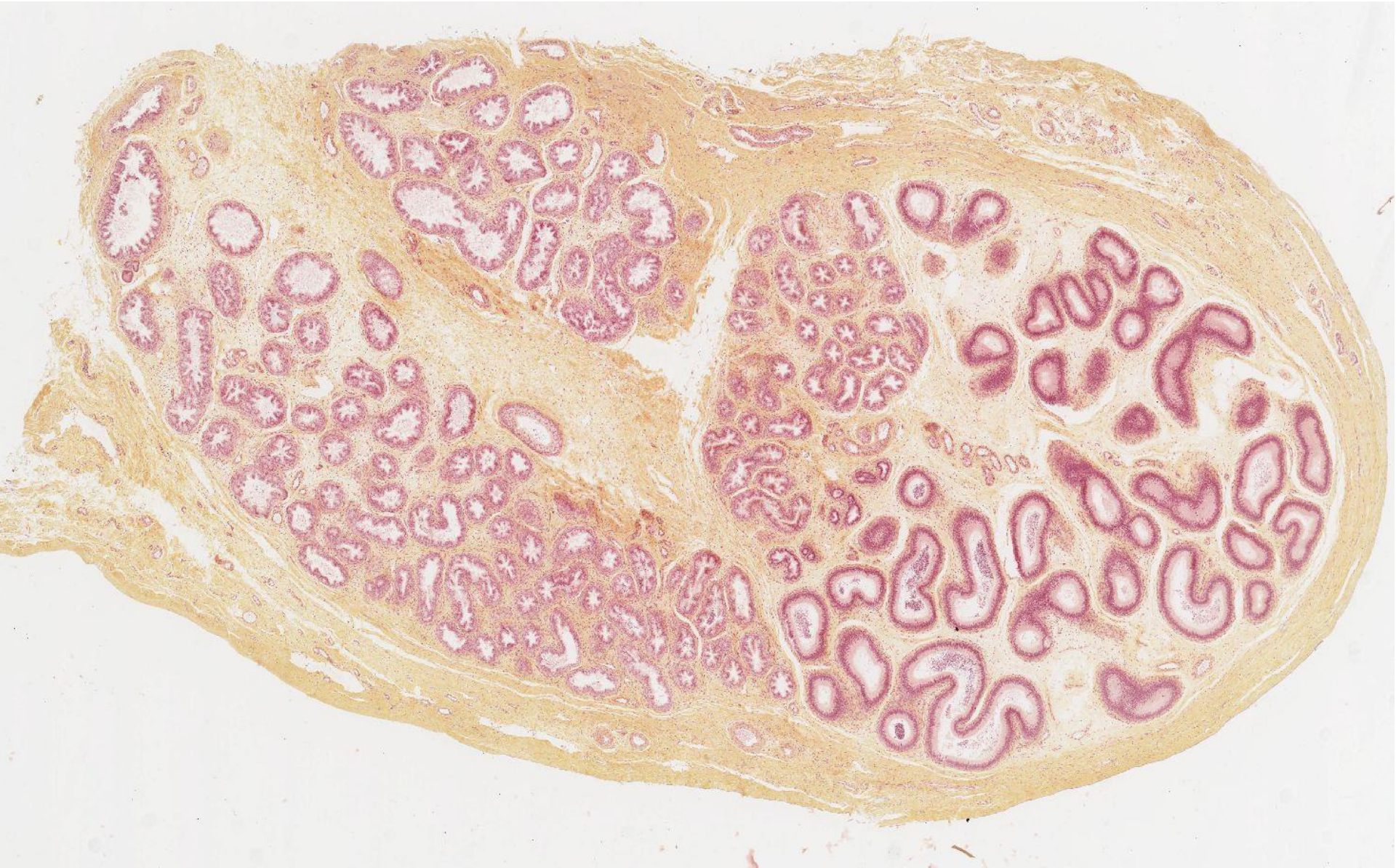

0,5 μm

Rete testis

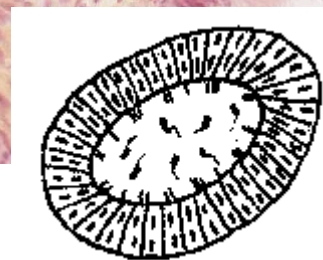
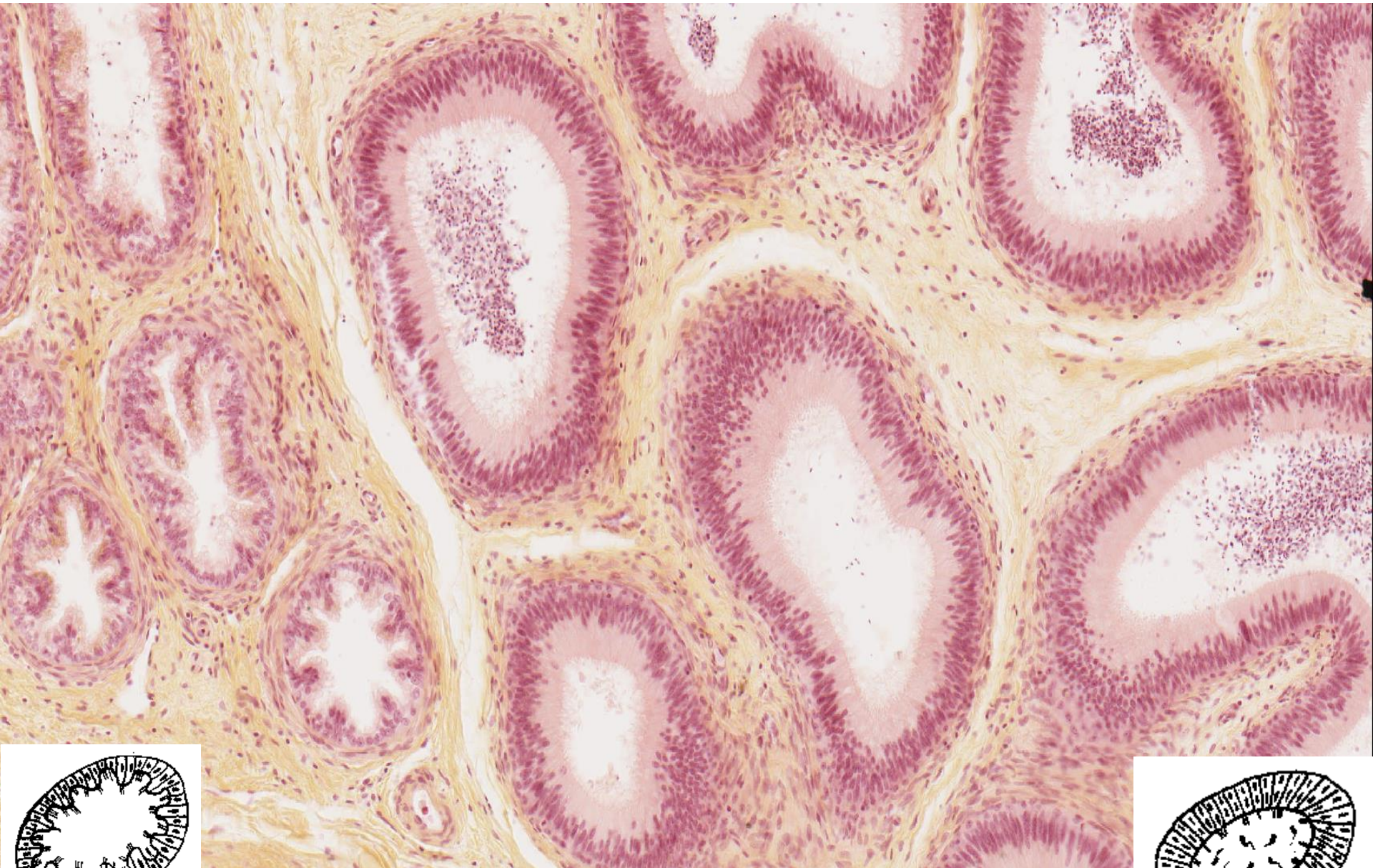


Epididymis (HEŠ)

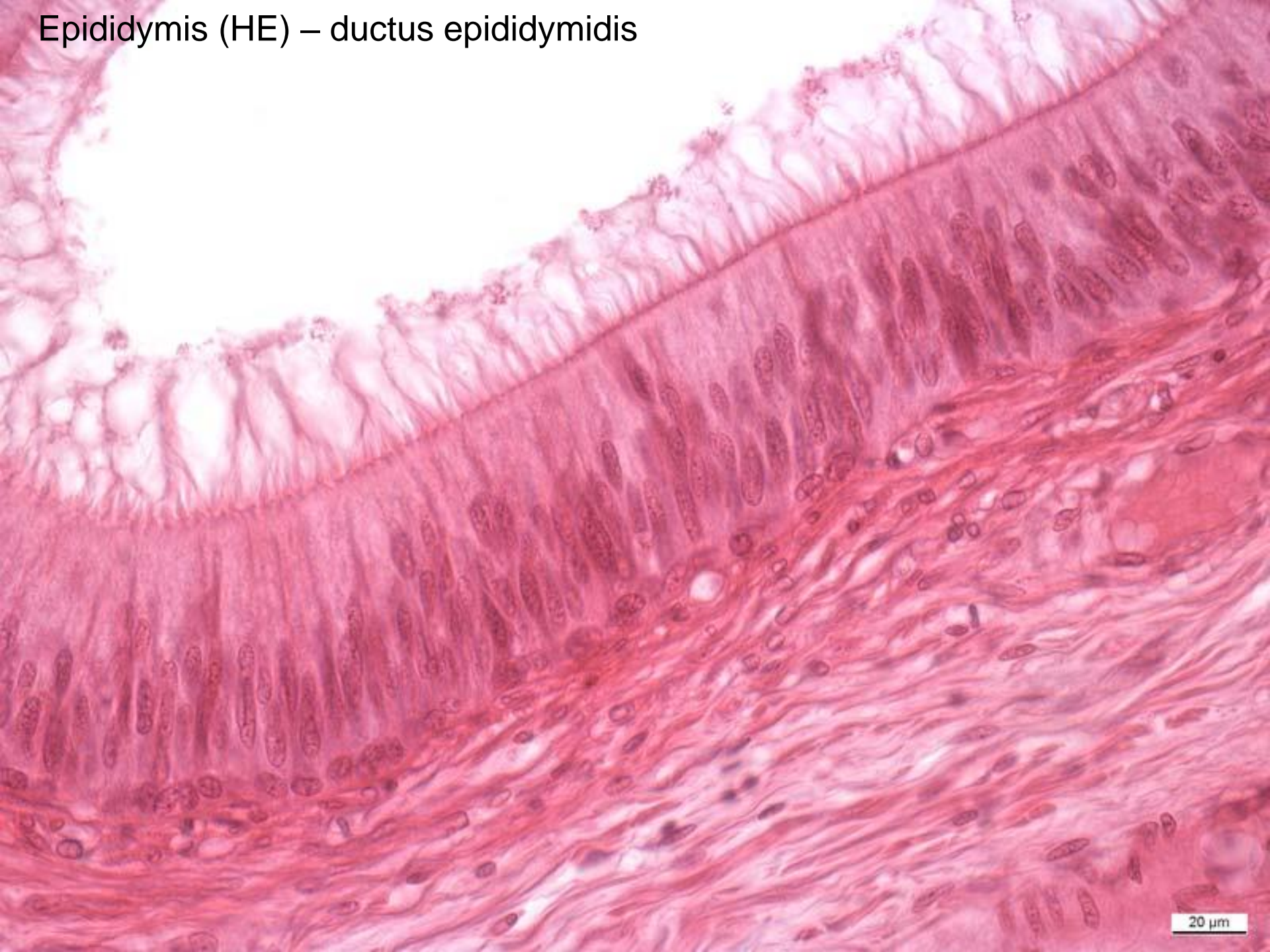

Ductuli efferentes

Ductus epididymidis

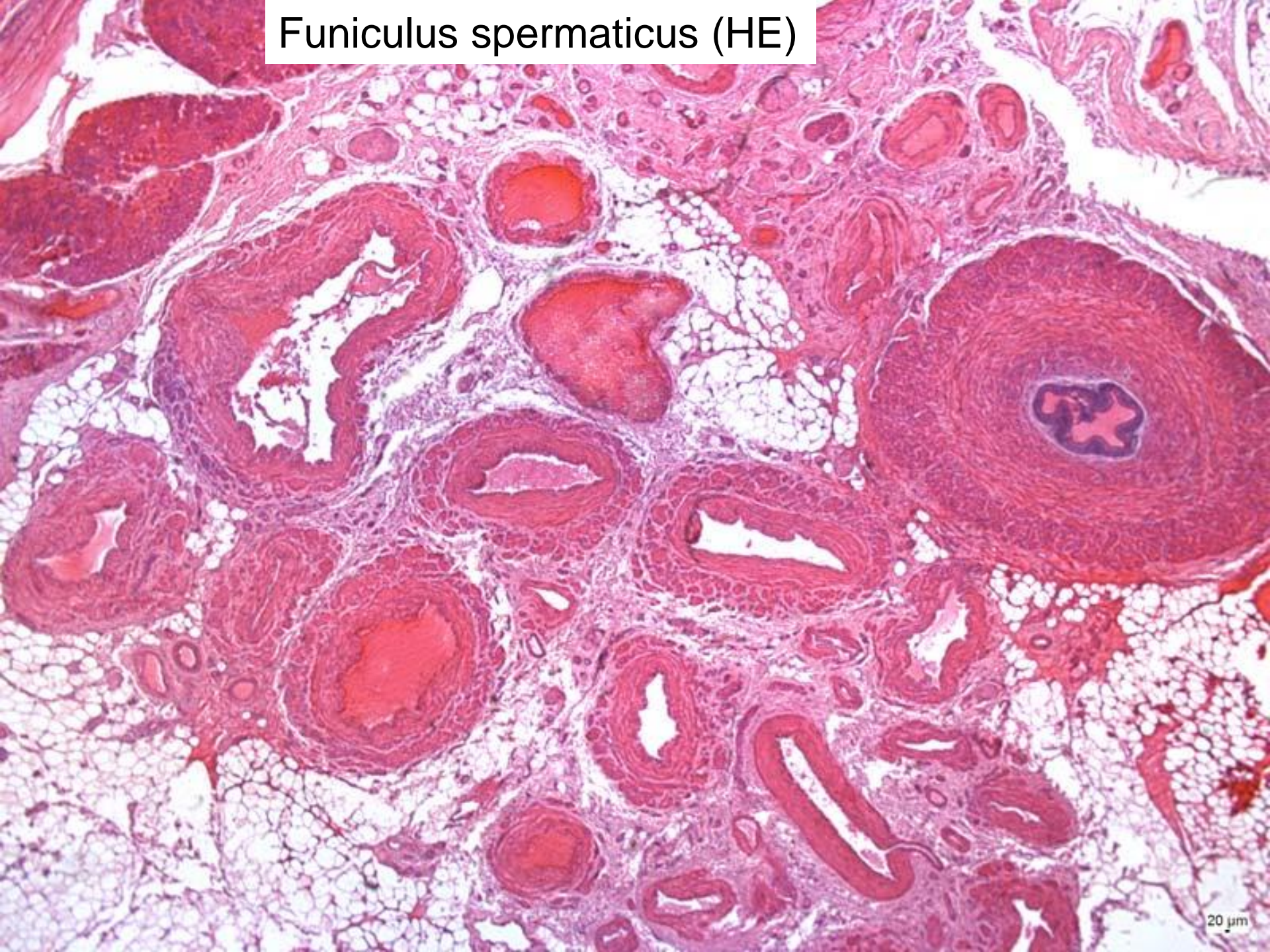


Epididymis (HE) – ductus epididymidis

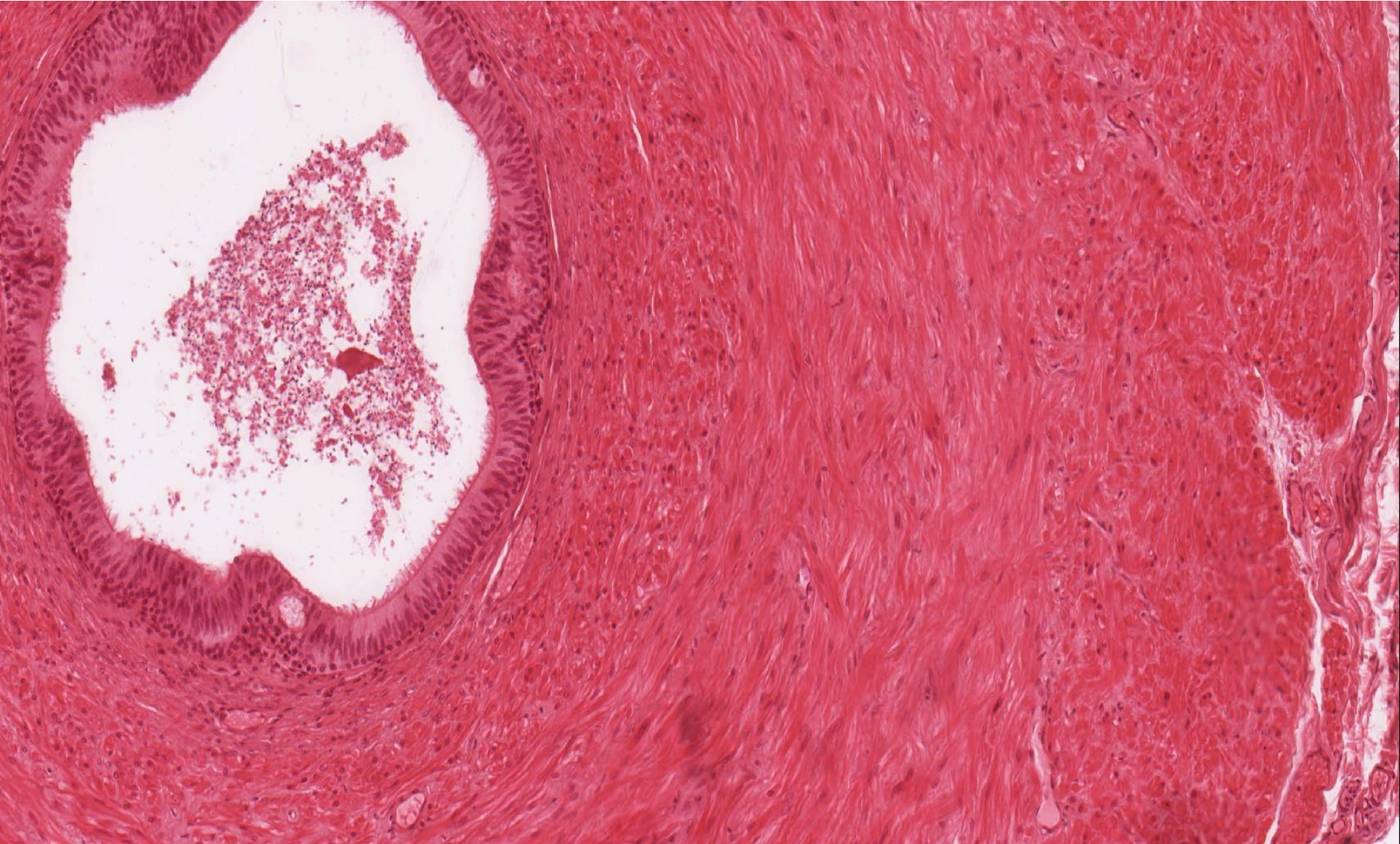


20 μ m

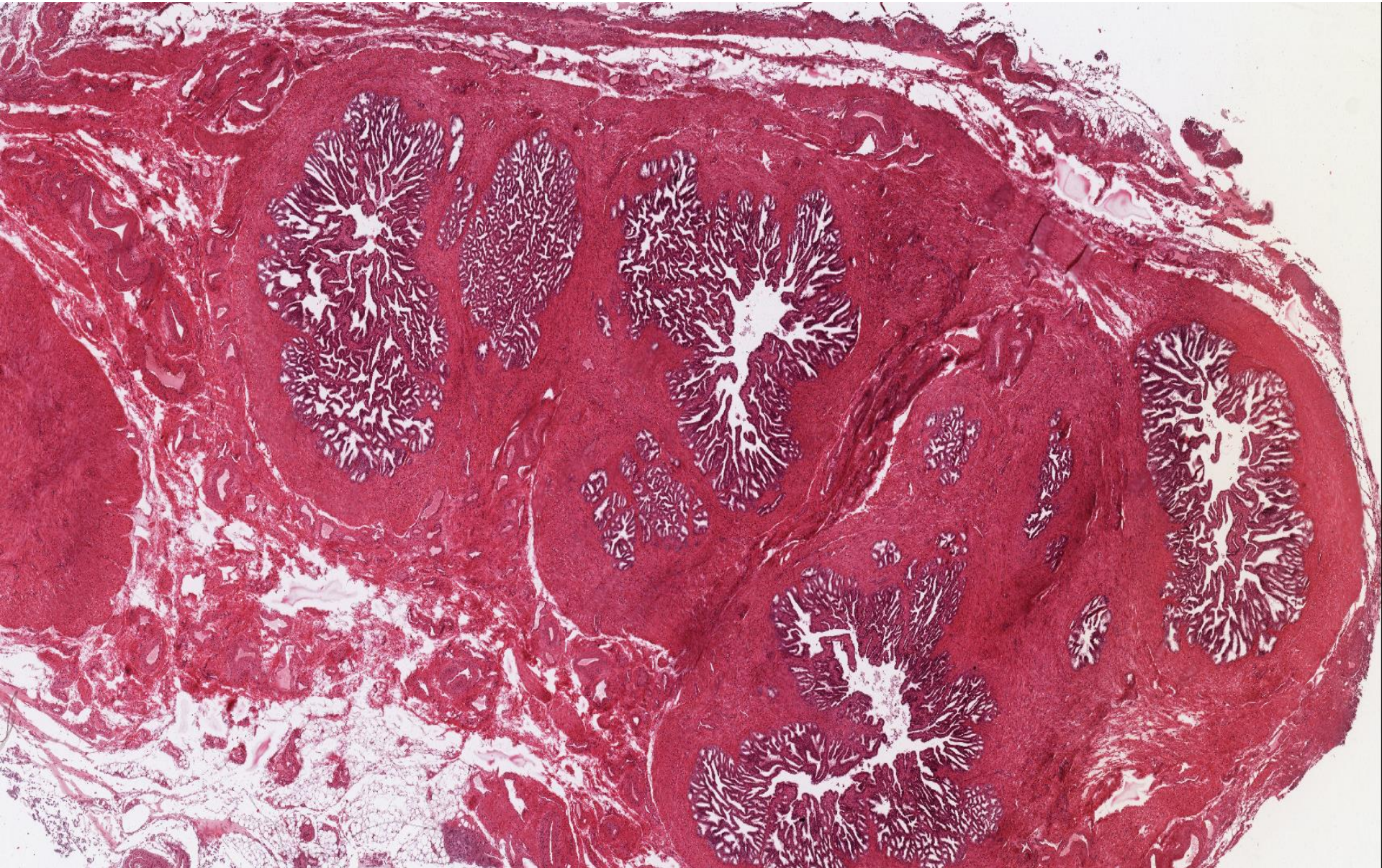
Funiculus spermaticus (HE)



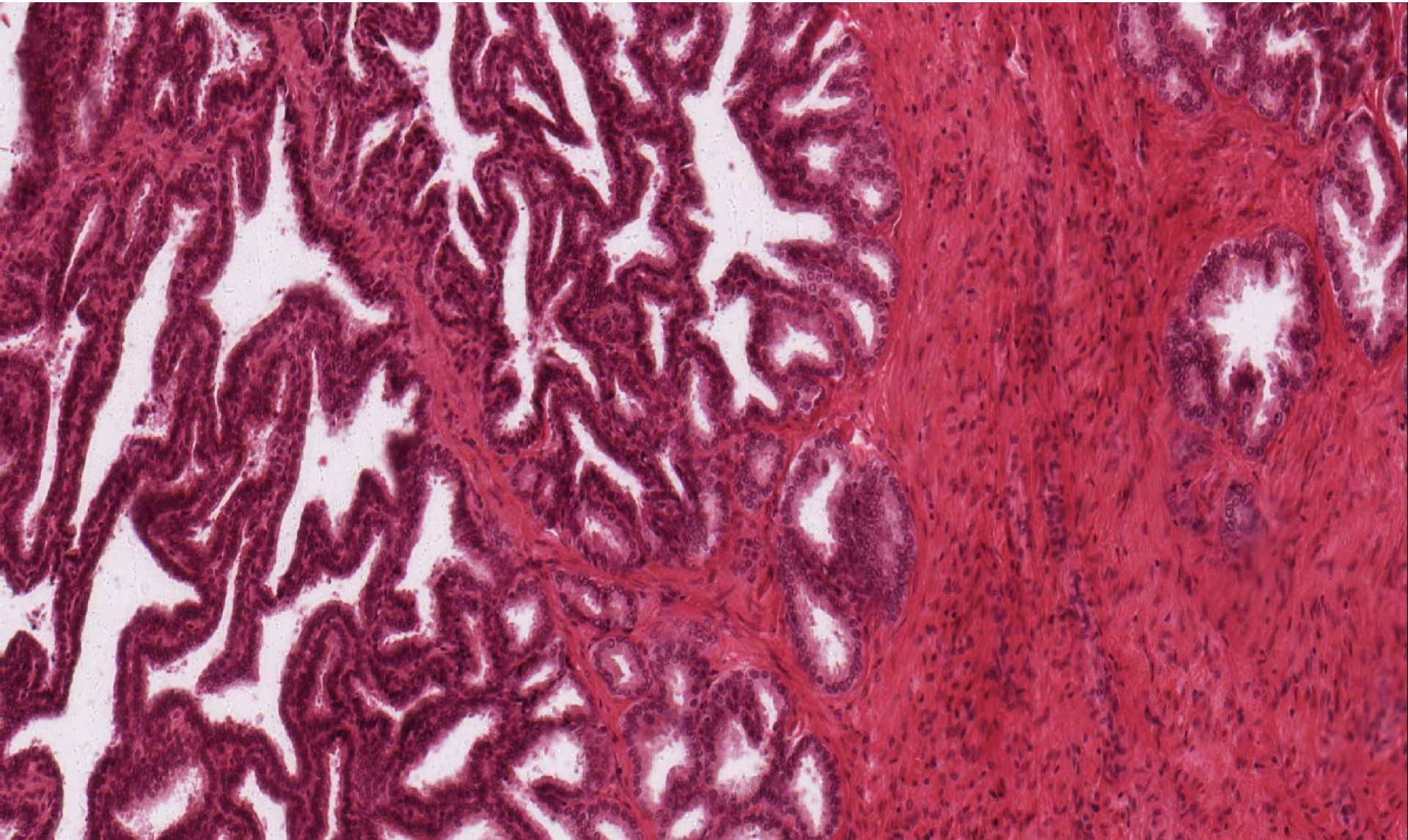
Funiculus spermaticus (HE) – ductus deferens



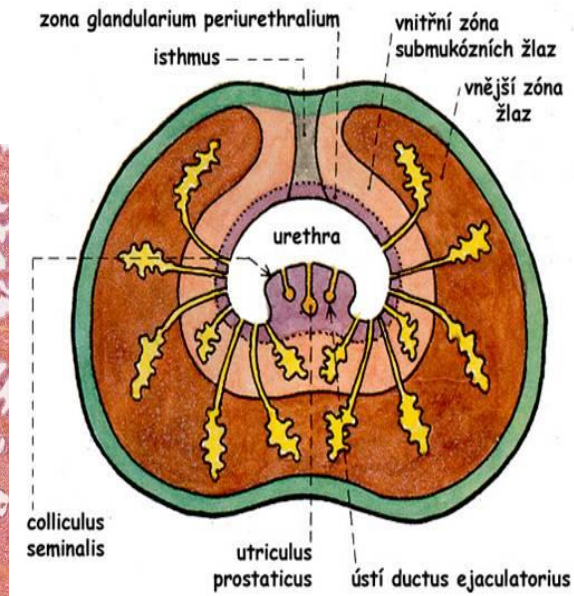
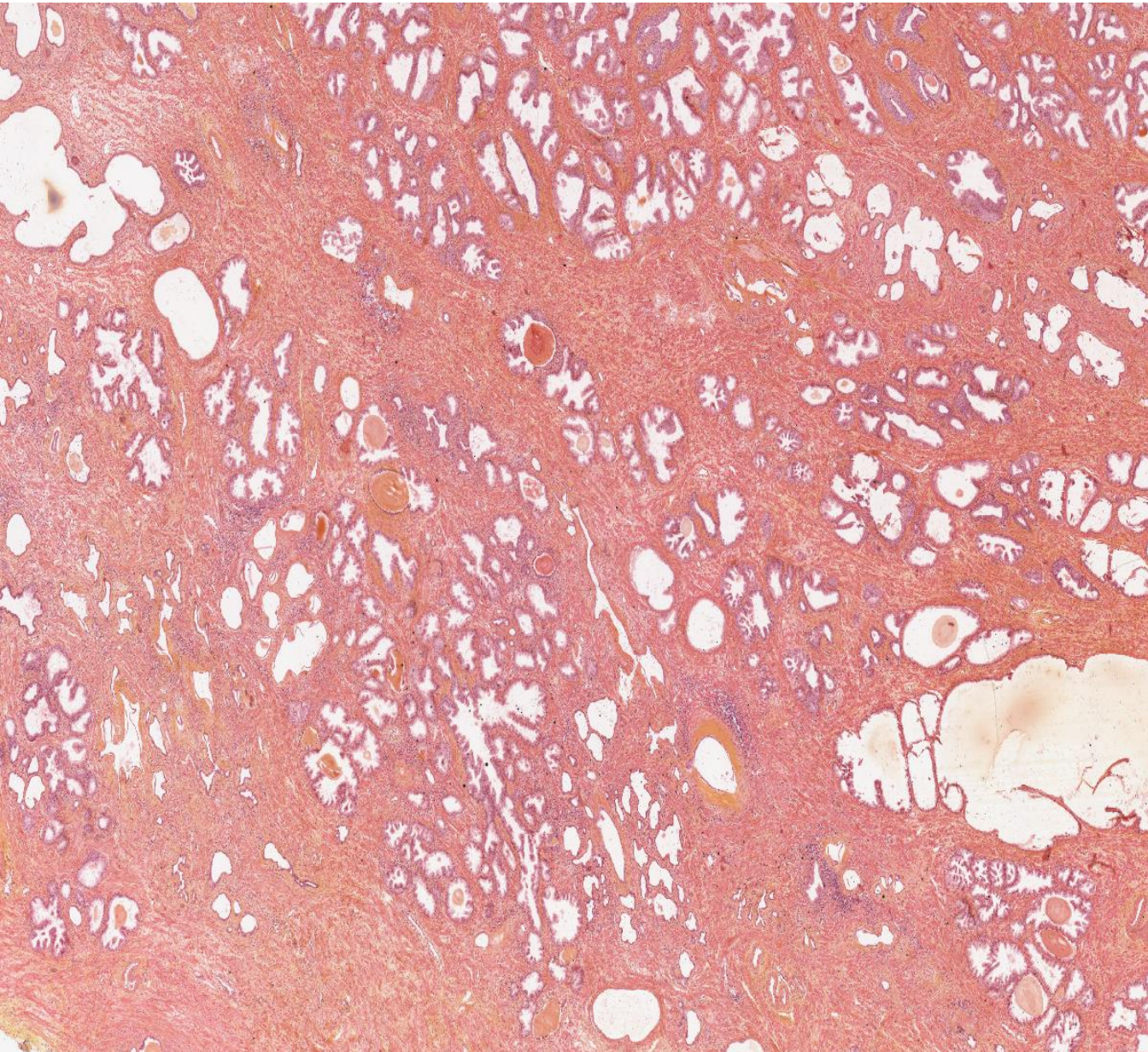
Glandula vesiculosa (HE)



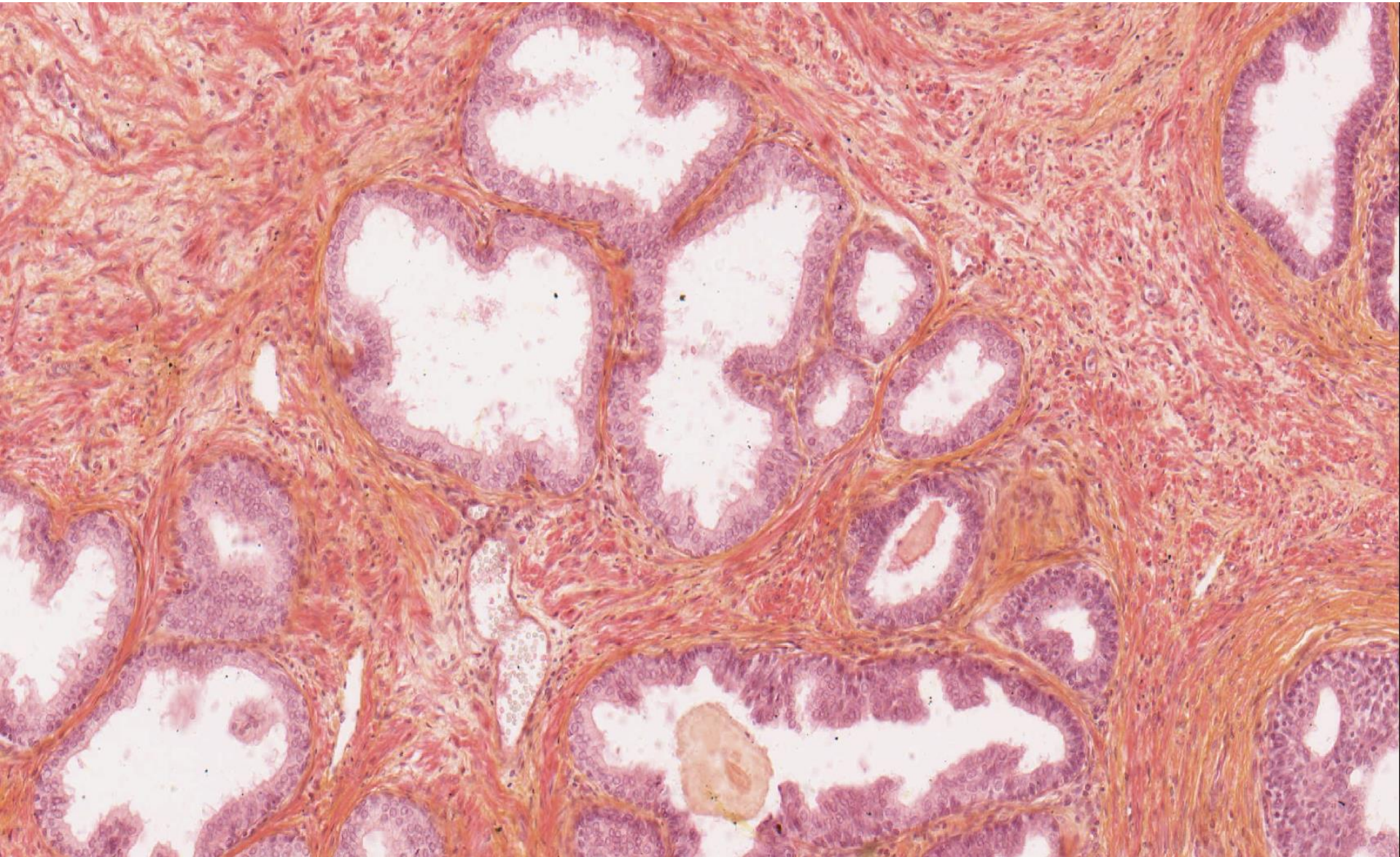
Glandula vesiculosa (HE)

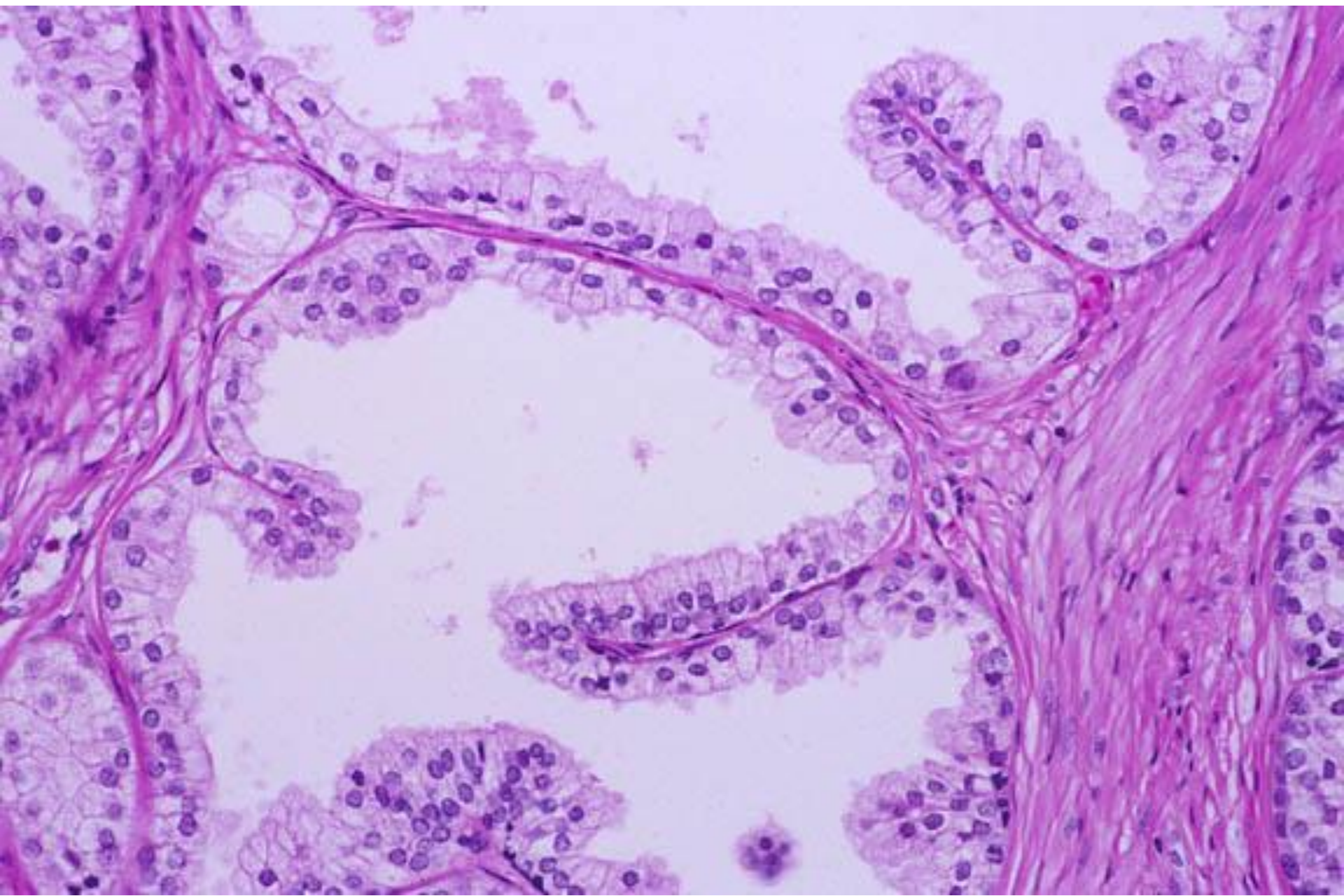


Prostata (HEŠ)

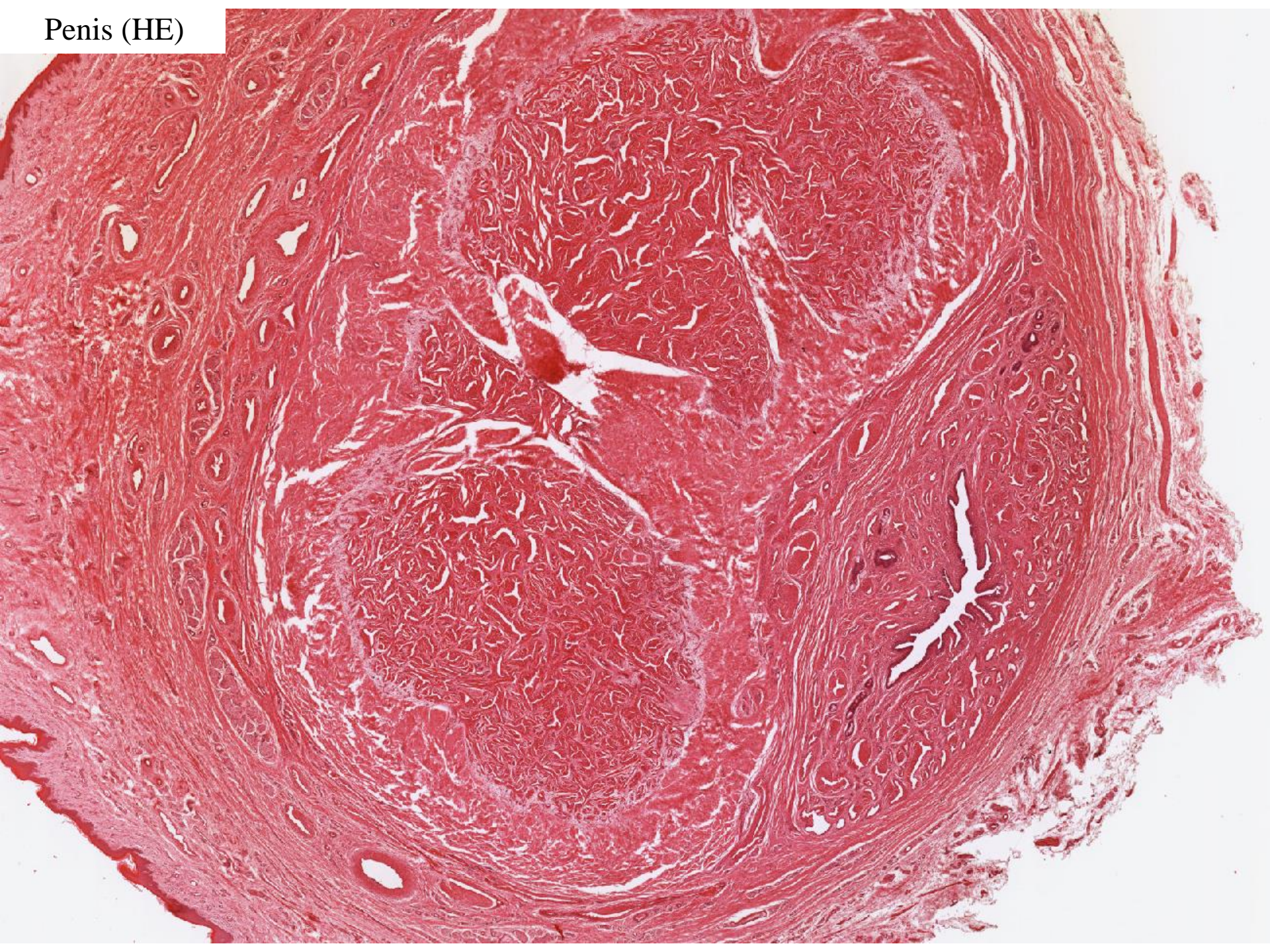


Prostata (HEŠ)

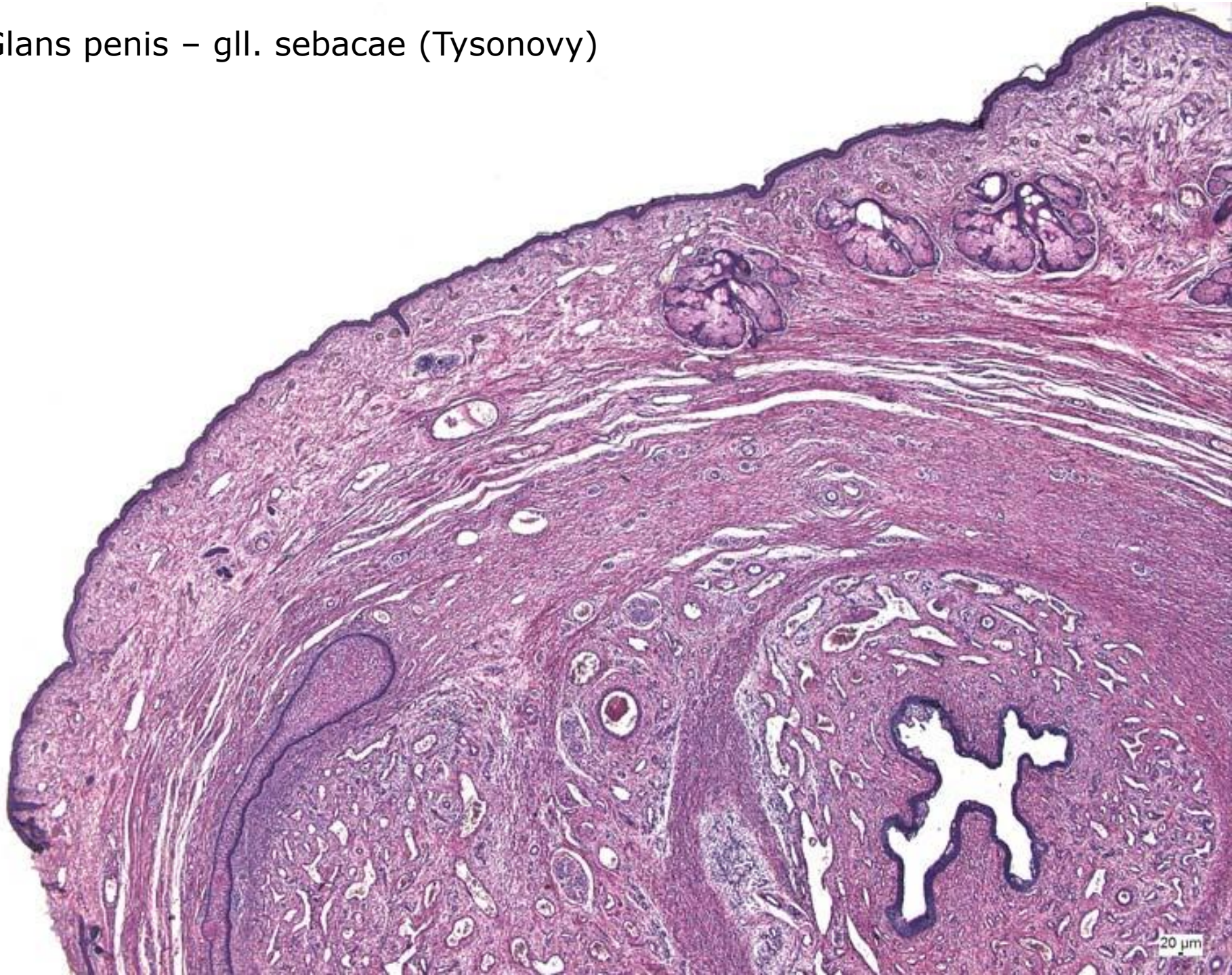



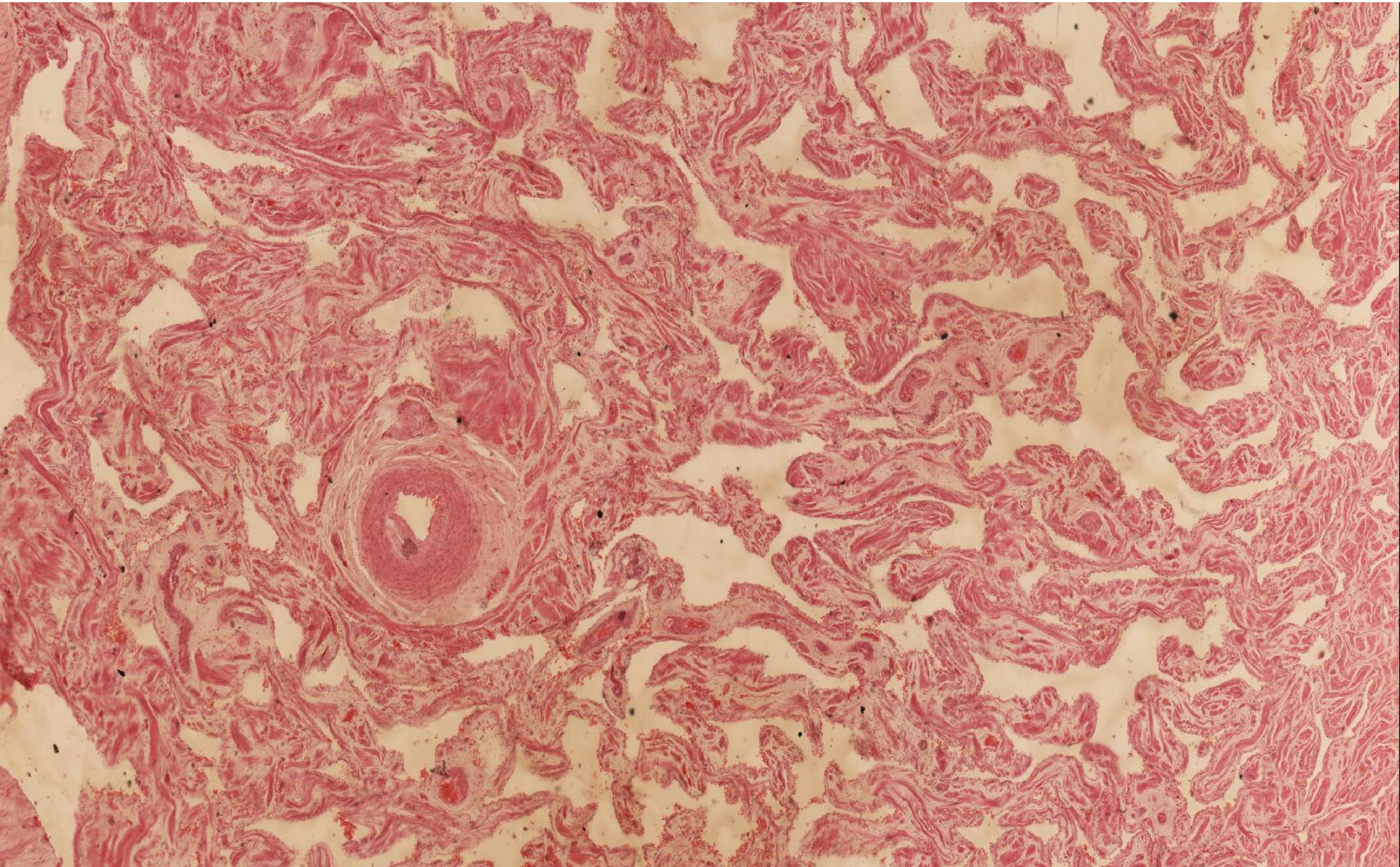
Penis (HE)



Glans penis – gll. sebaciae (Tysonovy)



Penis – corpus cavernosum



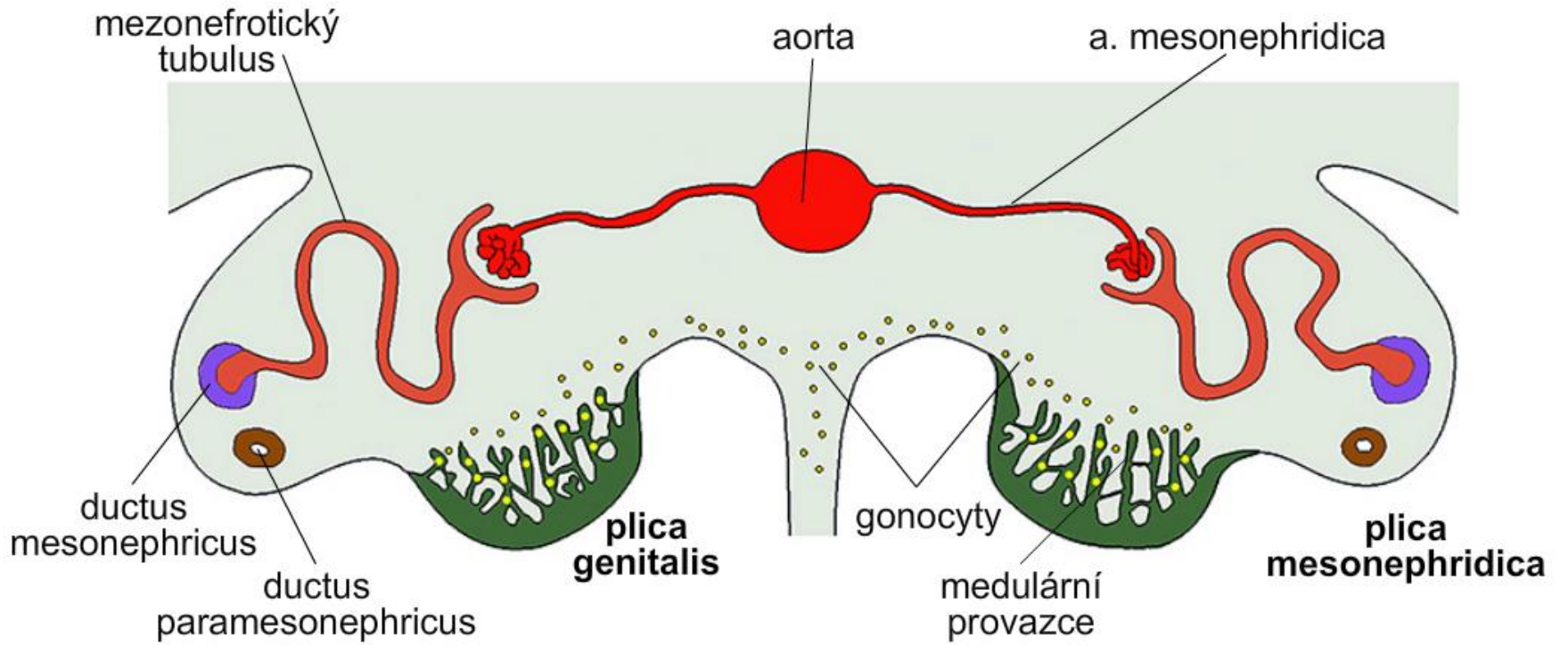
Mužský pohlavní systém

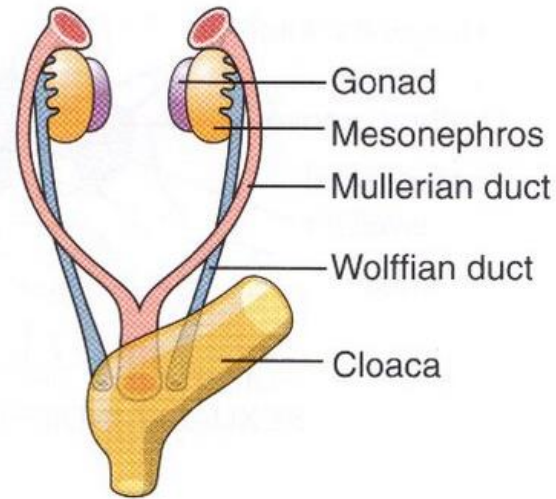
Preparáty:

- 36. Testis (HE)
- 37. Epididymis (HE, HEŠ)
- 38. Funiculus spermaticus (HE)
- 39. Glandula vesiculosa (HE)
- 40. Prostata (HE)
- 41. Penis (HE)

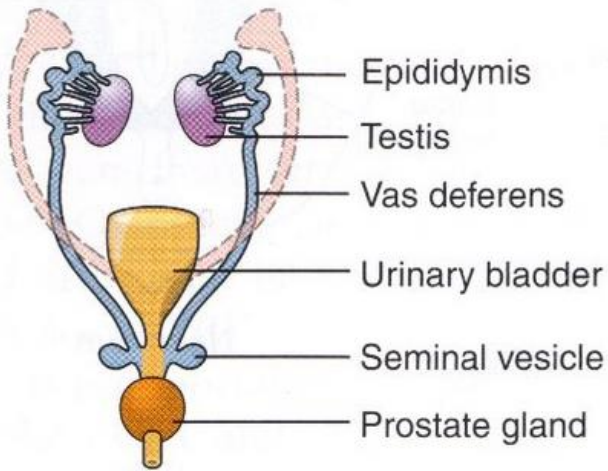
Atlas EM:

- Lidská spermie (71)
- Vývoj gonád (95)
- Vývoj vývodních pohlavních cest a zevních genitálií (96)

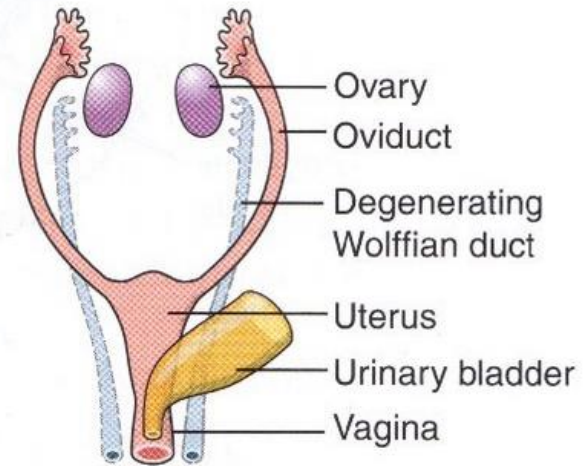




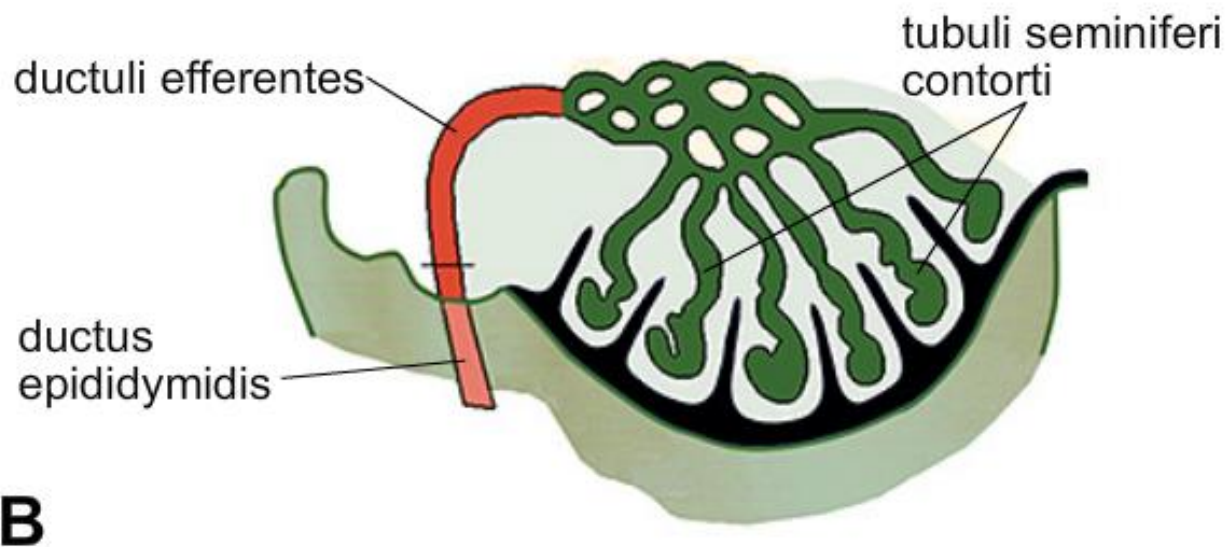
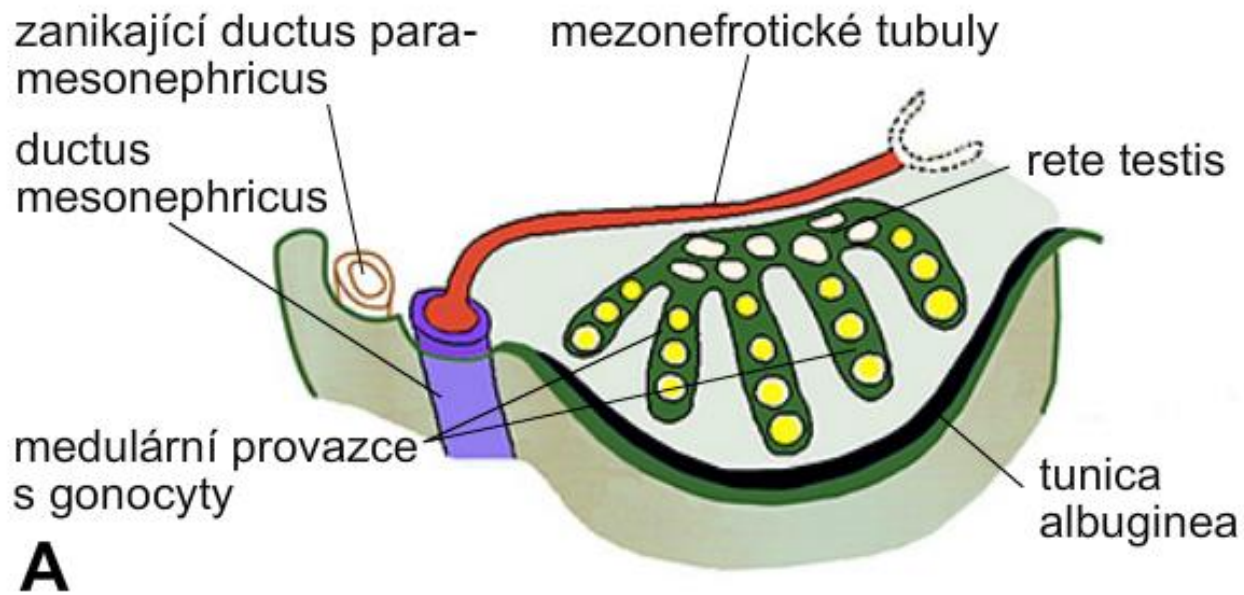
INDIFFERENT STAGE

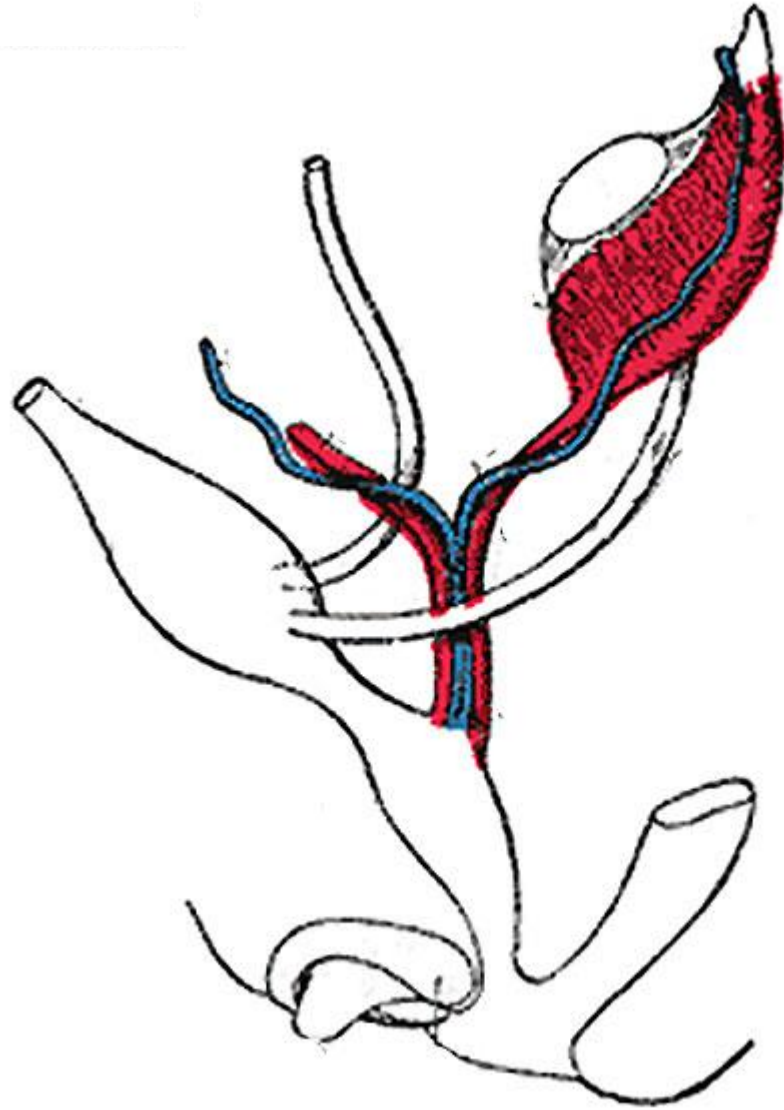


MALE



FEMALE





Gray, Henry. Anatomy of the Human Body. Philadelphia: Lea & Febiger, 1918.

