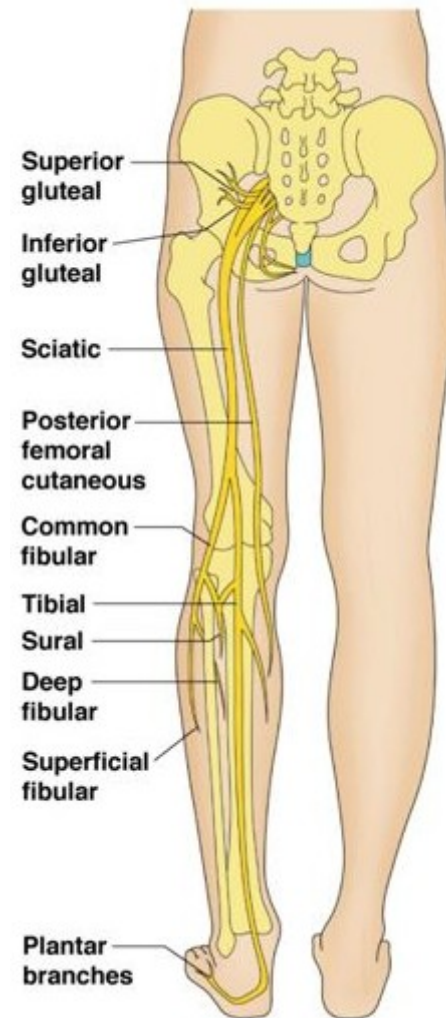


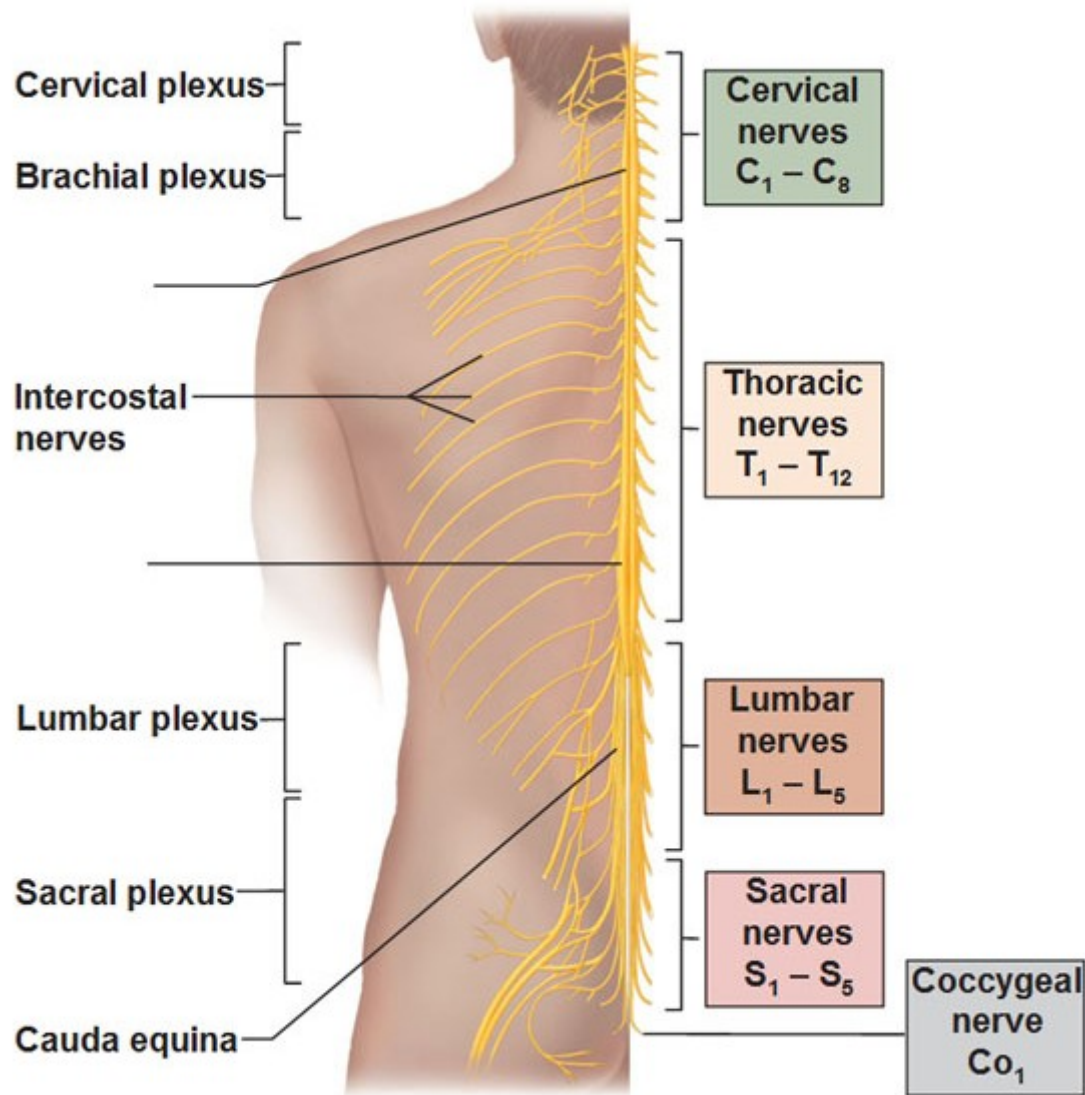
# Nerves of the Lower Limb



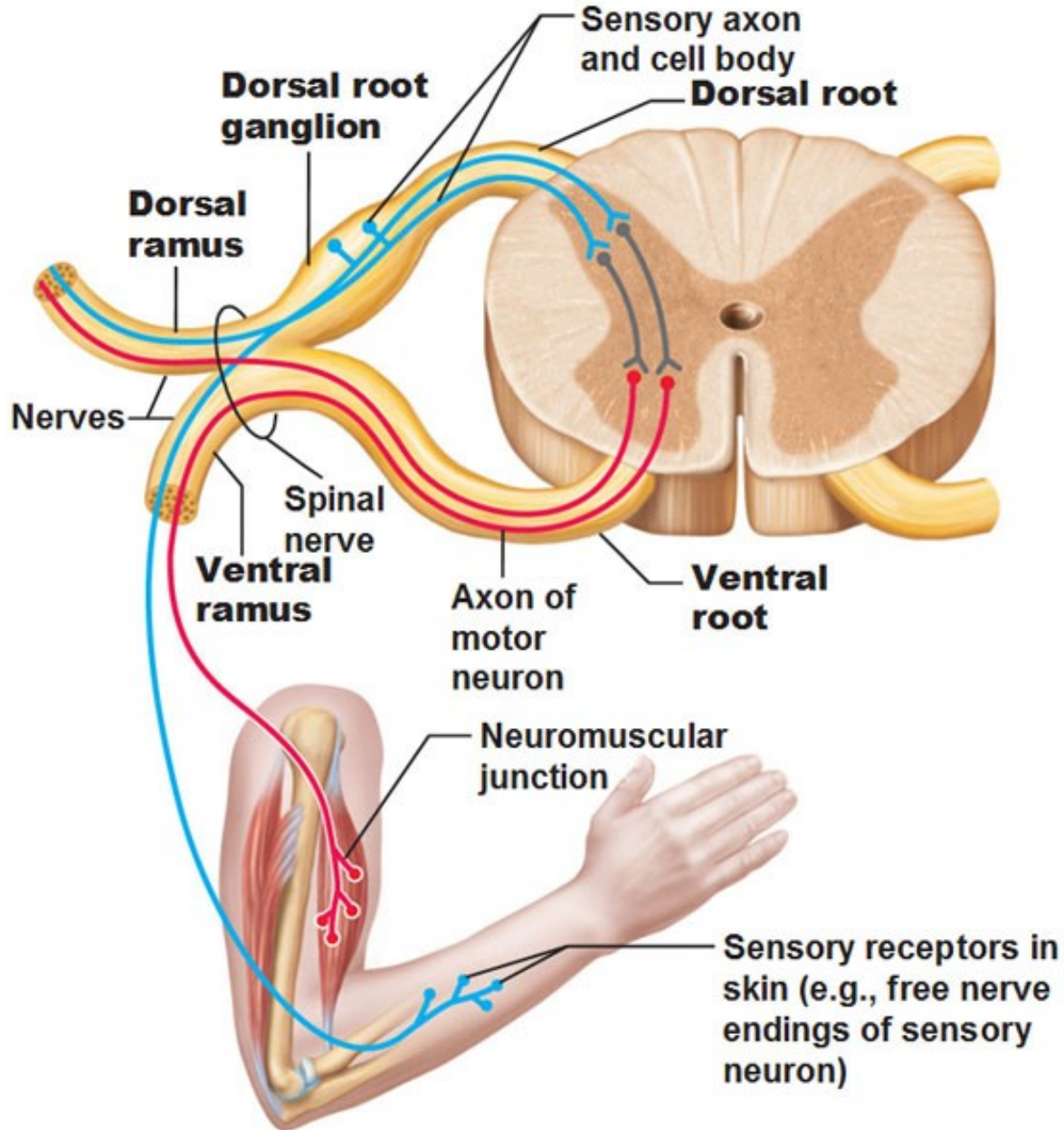
# Nerves of the Lower Limb

- The Lumbar Plexus
  - Iliohypogastricus nerve
  - Ilioinguinalis nerve
  - Lateral Cutaneous Femoral nerve
  - Obturator nerve
  - Femoral nerve
- The Sacral Plexus
  - Sciatic nerve
  - Tibial nerve
  - Common Peroneal nerve

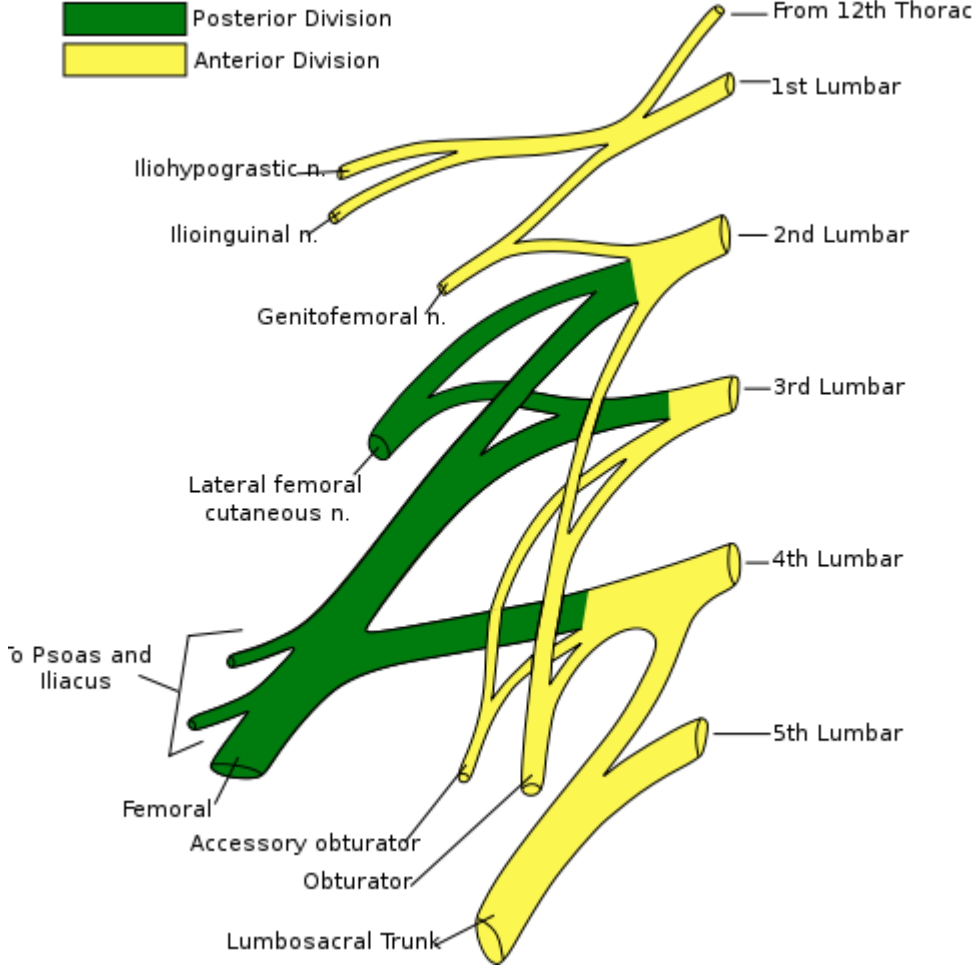
# Spinal Nerves



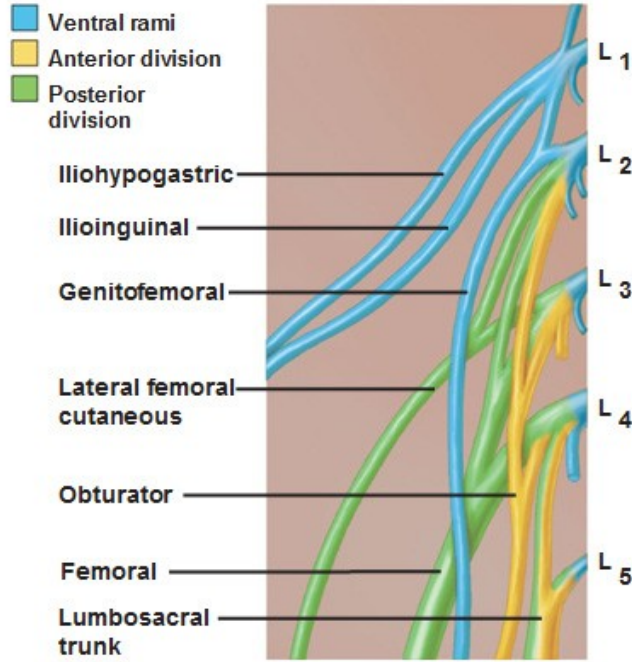
# Spinal Nerves



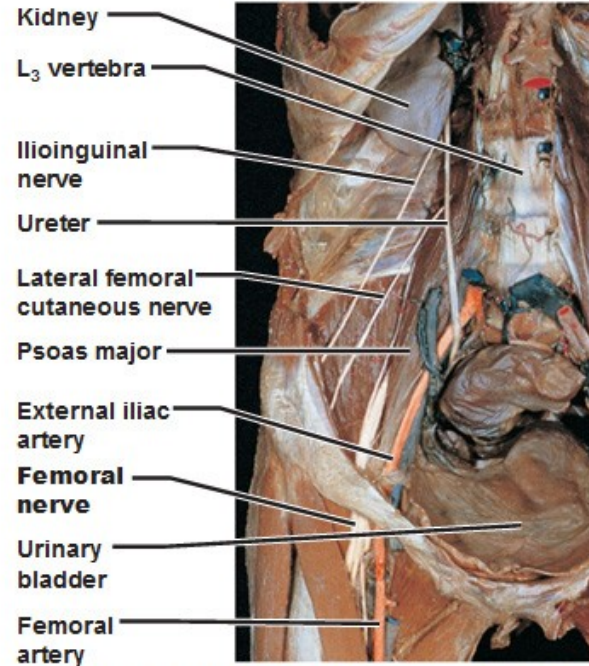
# The Lumbar Plexus



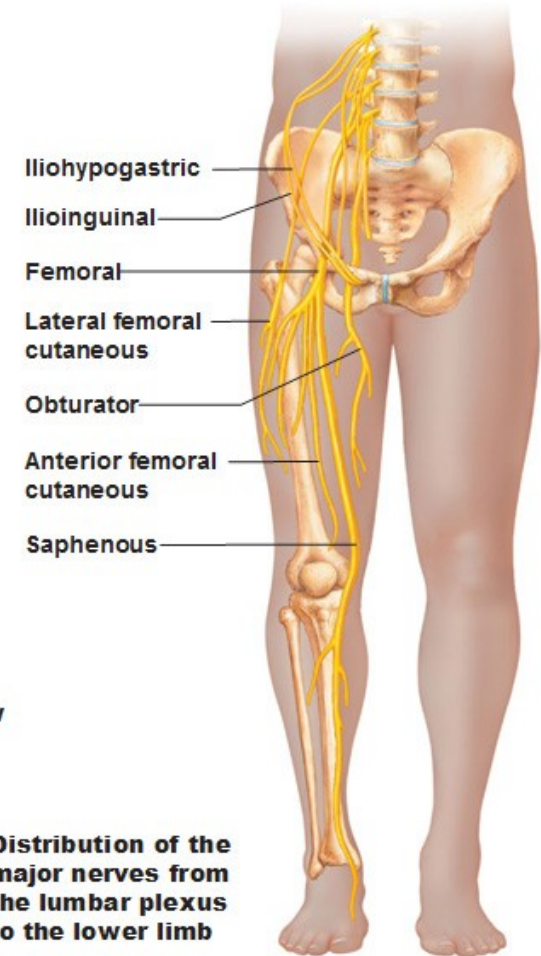
# The Lumbar Plexus



**(a) Ventral rami and major branches of the lumbar plexus**



**(b) Nerves of the lumbar plexus, anterior view**



**(c) Distribution of the major nerves from the lumbar plexus to the lower limb**

# The Lumbar Plexus

Muscular innervation of anterior thigh

Muscular innervation of medial thigh

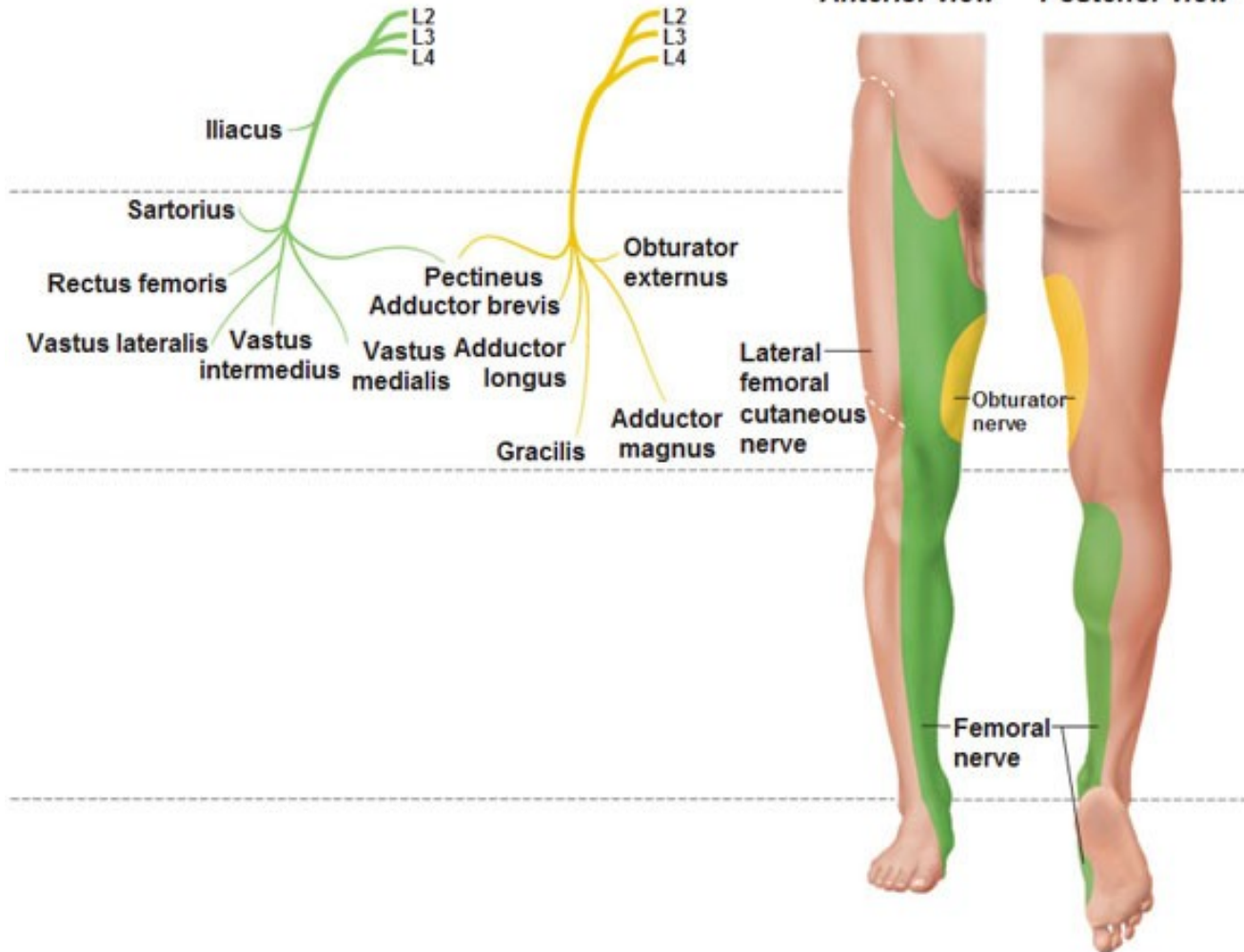
Cutaneous innervation

Femoral nerve

Obturator nerve

Anterior view

Posterior view



# The Lumbar Plexus

- a nervous plexus in the lumbar region of the body which forms **part of the lumbosacral plexus**
- it is formed by the divisions of the four lumbar nerves (L1-L4) and from contributions of the subcostal nerve (T12)
- additionally, the ventral rami of the fourth lumbar nerve pass communicating branches, the lumbosacral trunk, to the sacral plexus
- the nerves of the lumbar plexus pass in front of the hip joint and mainly support **the anterior part of the thigh**



# The Lumbar Plexus

- it is formed lateral to the intervertebral foramina and passes through psoas major
- its **smaller motor branches** are distributed directly to psoas major
- while **the larger branches** leave the muscle at various sites to run obliquely downward through the pelvic area to leave the pelvis under the inguinal ligament
- with the exception of the obturator nerve which exits the pelvis through the obturator foramen

# The Iliohypogastric Nerve

- it runs anterior to the psoas major on its proximal lateral border to run laterally and obliquely on the anterior side of quadratus lumborum
- lateral to this muscle, it pierces the transversus abdominis to run above the iliac crest between that muscle and abdominal internal oblique
- it gives off several **motor branches** to these muscles and a **sensory branch** to the skin of the lateral hip
- its **terminal branch** then runs parallel to the inguinal ligament to exit the aponeurosis of the abdominal external oblique above the external inguinal ring where it supplies the skin above the inguinal ligament (i.e. the hypogastric region) with the **anterior cutaneous branch**

# The Ilioinguinal Nerve

- it closely follows the iliohypogastric nerve on the quadratus lumborum, but then passes below it to run at the level of the iliac crest
- it pierces the lateral abdominal wall and runs medially at the level of the inguinal ligament where it supplies **motor branches** to both transversus abdominis
- and **sensory branches** through the external inguinal ring to the skin over the pubic symphysis and the lateral aspect of the labia majora or scrotum

# The Genitofemoral Nerve

- it pierces psoas major anteriorly below the former two nerves to immediately split into two branches that run downward on the anterior side of the muscle
- **the lateral femoral branch** is purely sensory. It pierces the vascular lacuna near the saphenous hiatus and supplies the skin below the inguinal ligament (i.e. proximal, lateral aspect of femoral triangle)
- **the genital branch** differs in males and females
- in males it runs in the spermatic cord and in females in the inguinal canal together with the teres uteri ligament
- it then sends **sensory branches** to the scrotal skin in males and the labia majora in females. In males it supplies motor innervation to the cremaster

# Genitofemoral nerve paralysis

- most commonly caused by surgical trauma
  - other causes reported include direct trauma to the inguinal region and tight clothing

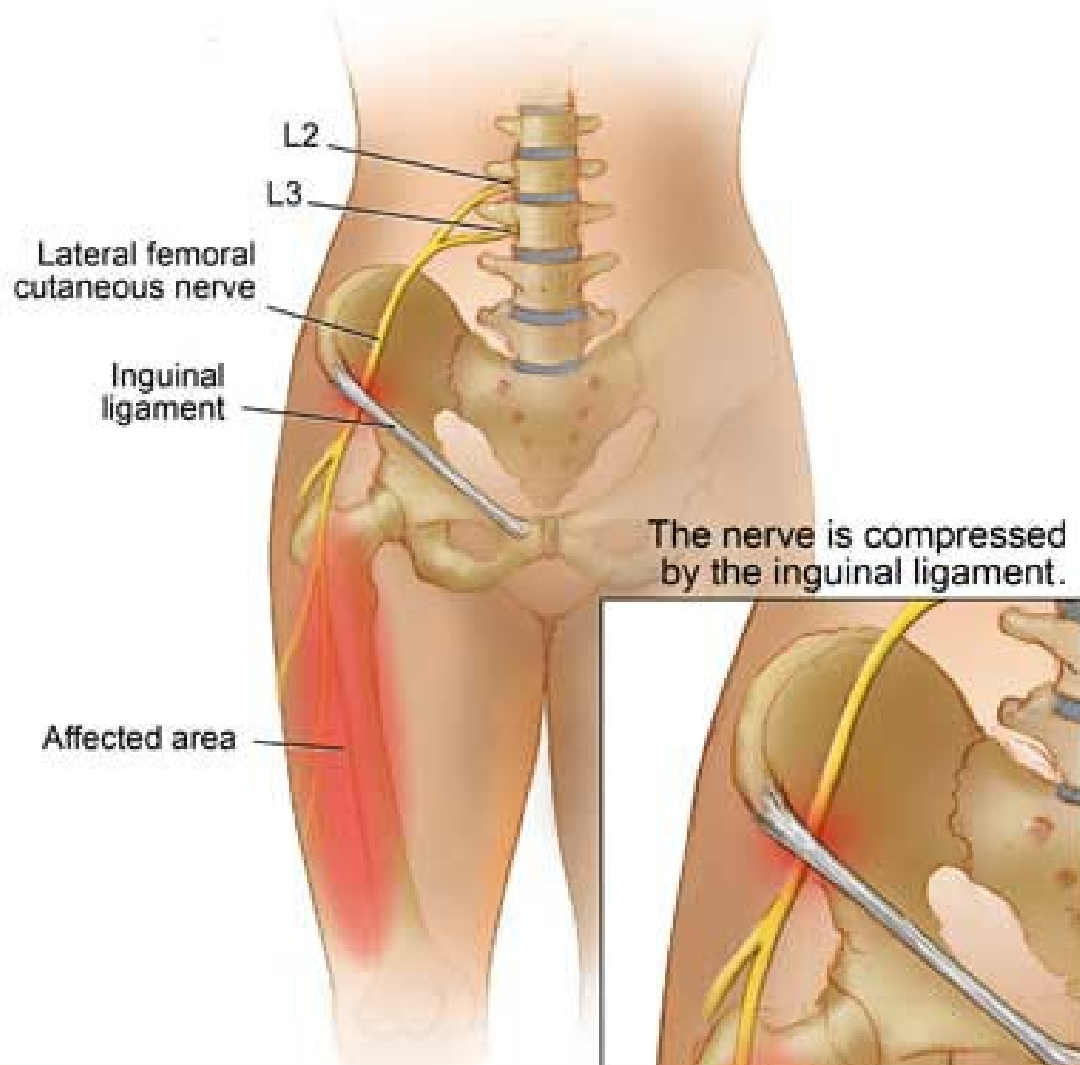
## Symptoms

- a pain and a burning sensation in the groin, which radiates to the inner thigh (aggravating factors including walking, stooping and hyperextension of the hip)
- tenderness and possible hyperaesthesia along the inguinal canal
- provocative testing involves internal or external rotation of the hip joint

# The lateral cutaneous femoral nerve

- it pierces psoas major on its lateral side and runs obliquely downward below the iliac fascia
- medial to the anterior superior iliac spine it leaves the pelvic area through the lateral muscular lacuna it enters the thigh by passing behind the lateral end of the inguinal ligament
- in the thigh it briefly passes under the fascia lata before it breaches the fascia and supplies **the skin of the anterior thigh**

# The lateral cutaneous femoral nerve



Involvement of the lateral cutaneous branch of the nerve may produce:

- **painful paraesthesiae of the thigh** (meralgia paraesthetica)
- mild pain near the inguinal ligament may be experienced

# The obturator nerve

- it leaves the lumbar plexus and descends behind psoas major on its medial side, then follows the linea terminalis into the lesser pelvis, and finally leaves the pelvic area through the obturator canal
- in the thigh, it sends **motor branches** to obturator externus before dividing into an **anterior and a posterior branch**, both of which continue distally
- these branches are separated by adductor brevis and supply **all thigh adductors with motor innervation**: pectineus, adductor longus, adductor brevis, adductor magnus, adductor minimus, and gracilis
- the anterior branch contributes a terminal, **sensory branch** which passes along the anterior border of gracilis and supplies the skin on the medial, distal part of the thigh

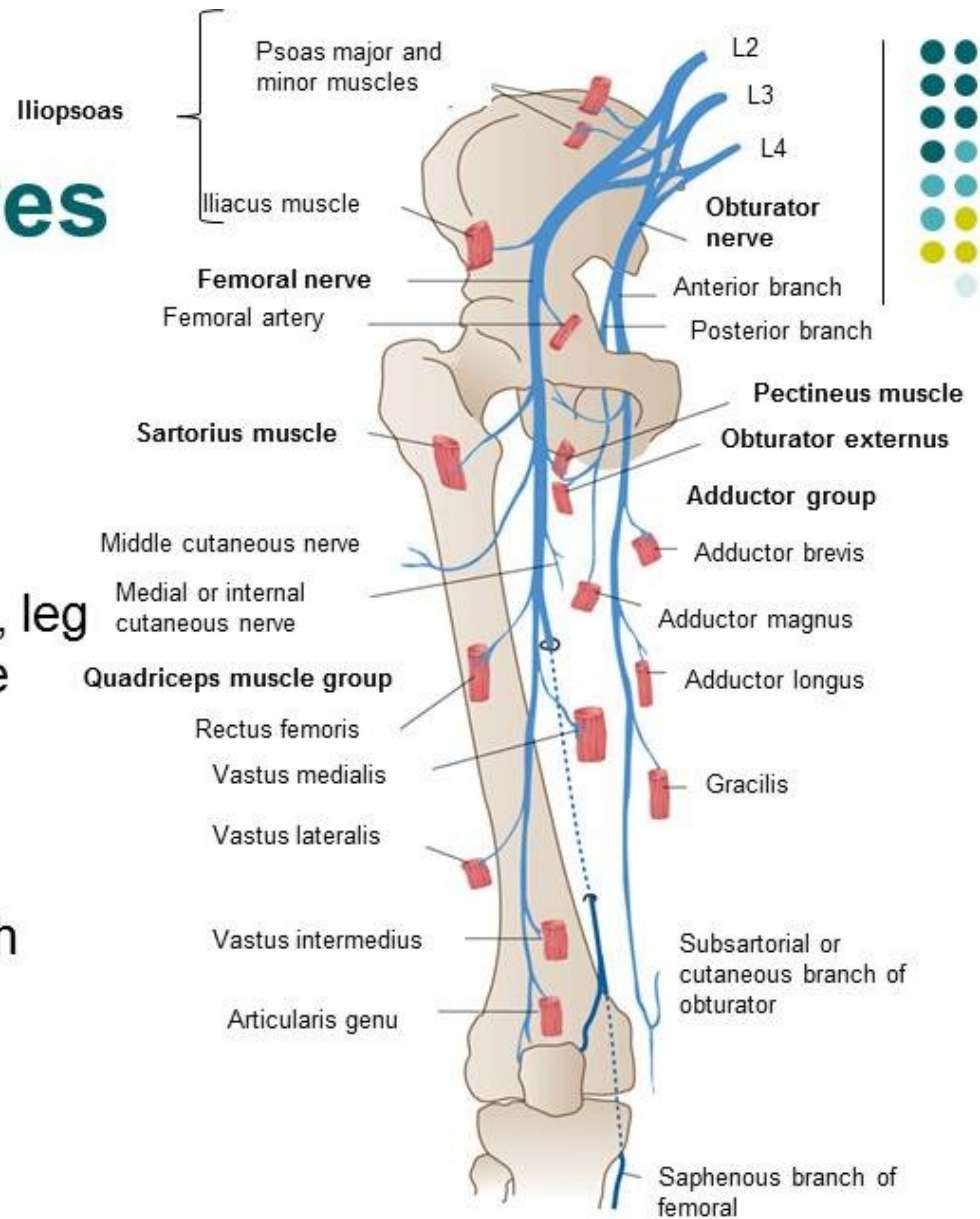


# The femoral nerve

- it is the largest and longest of the plexus' nerves
- it gives **motor innervation** to iliopsoas, pectineus, sartorius, and quadriceps femoris
- and **sensory innervation** to the anterior thigh, posterior lower leg, and hindfoot
- in the pelvic area, it runs in a groove between psoas major and iliacus giving off branches to both muscles, and exits the pelvis through the medial aspect of muscular lacuna
- in the thigh it divides into **numerous sensory and muscular branches** and the **saphenous nerve**, its long sensory terminal branch which continues down to the foot

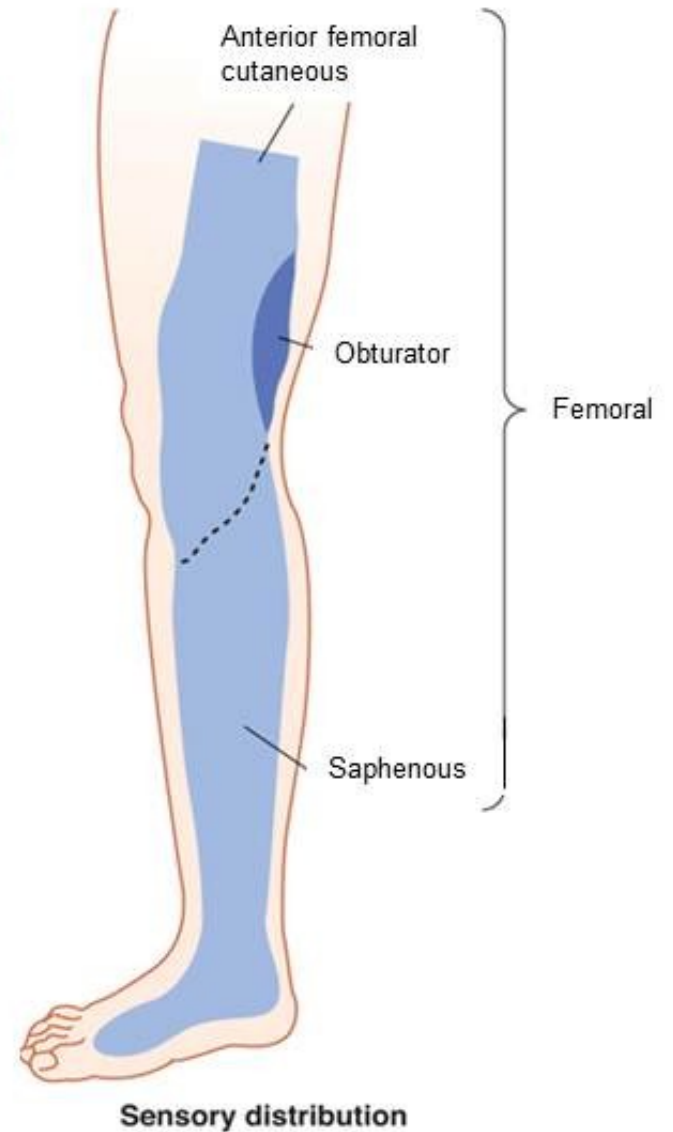
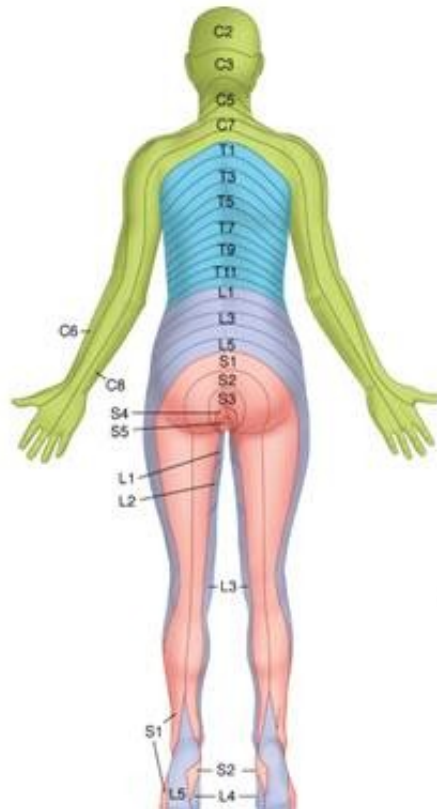
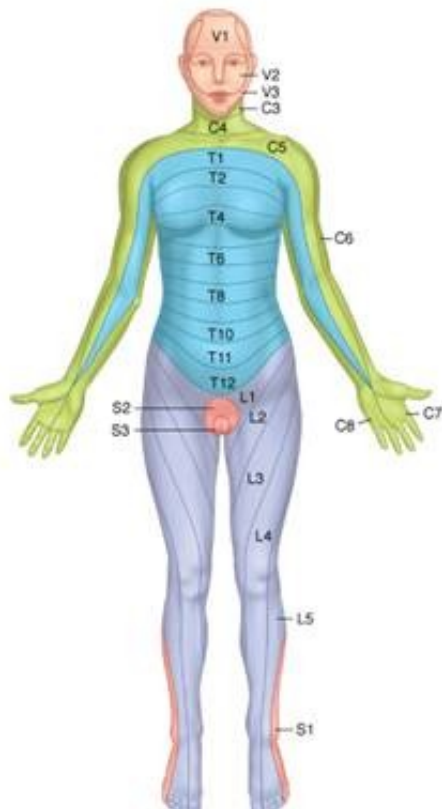
# Femoral and Obturator Nerves

- Femoral nerve
  - Motor functions
    - Leg flexion at the hip, leg extension at the knee
- Obturator nerve
  - Motor functions
    - Adduction of the thigh



# Femoral and Obturator Nerves

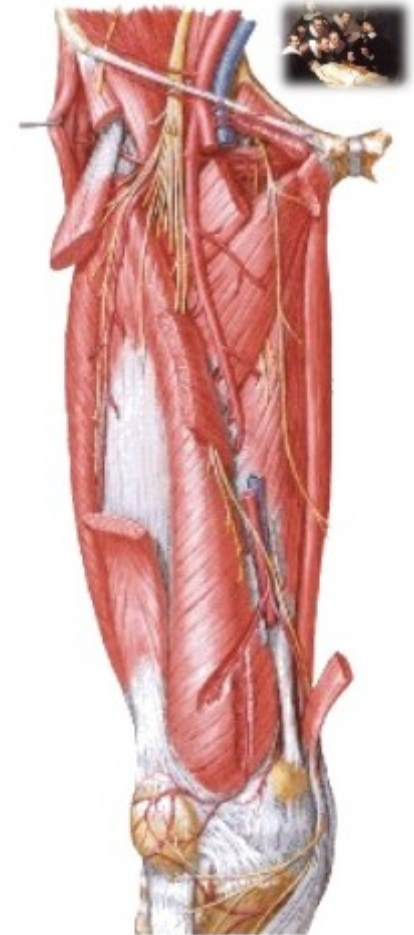
- Sensory distribution



# Femoral nerve paralysis

## Symptoms:

- Loss of knee extension
- Loss of quadriceps reflex
- Atrophy of quadriceps
- Weakness of hip flexion
- Loss of cutaneous sensation on anterior thigh and medial side of the leg and foot.
- Pain may be felt over the femoral nerve distribution due to compression of the L2,3,4 nerve roots by an intervertebral disc.

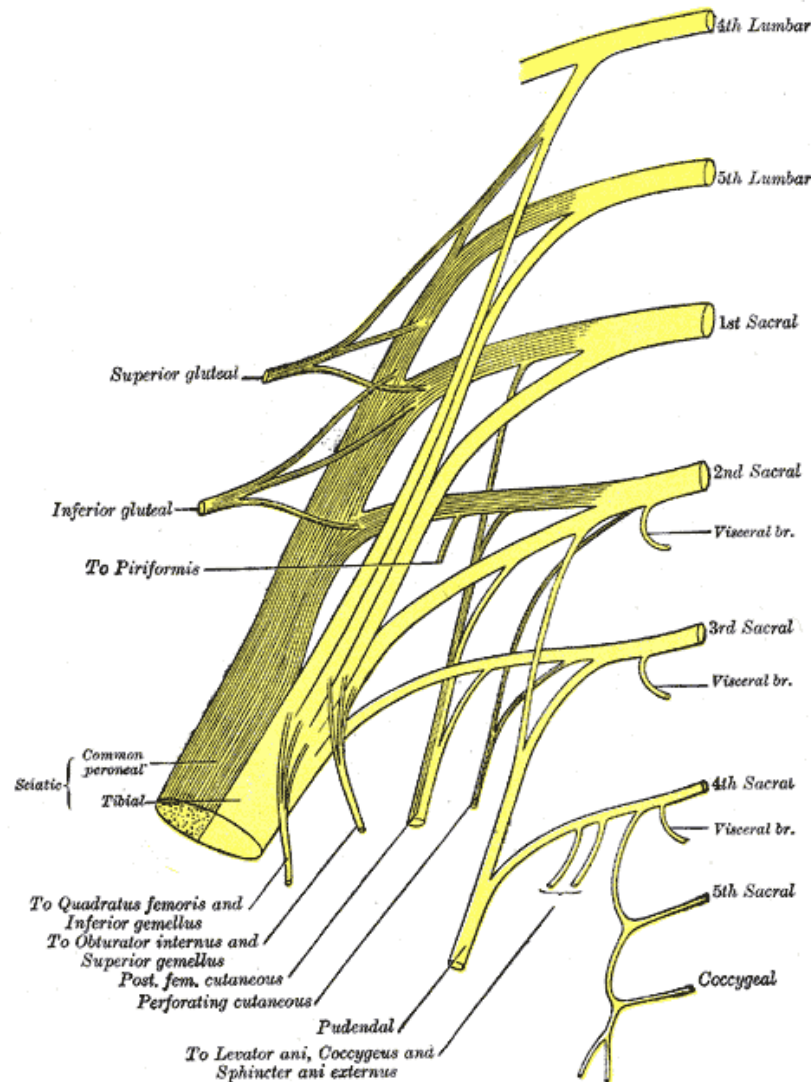


# Obturator nerve paralysis

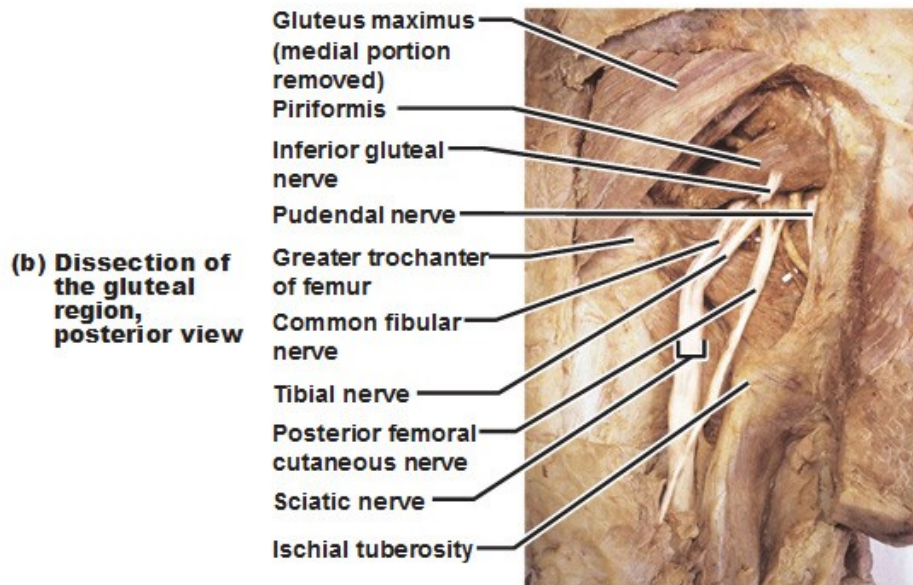
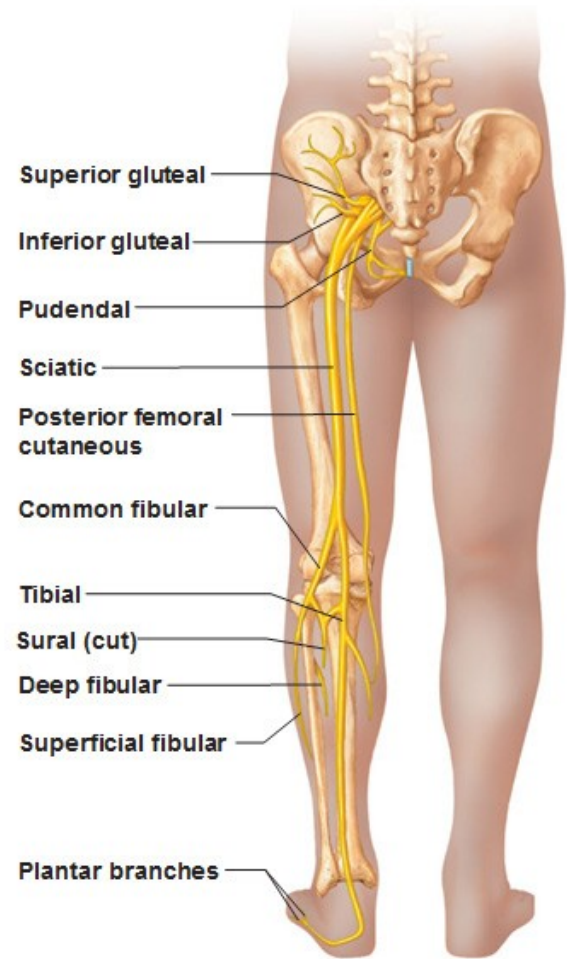
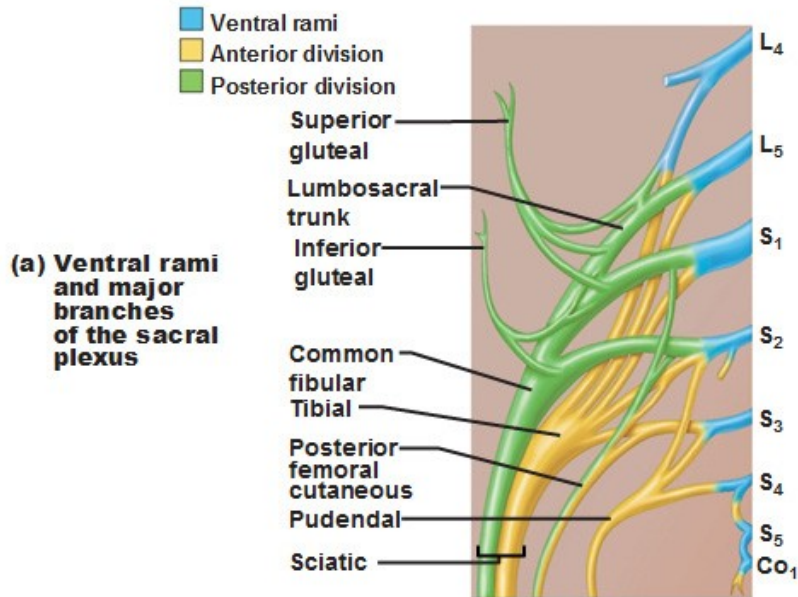
## Symptoms:

- hypoaesthesia, paraesthesia or pain in the medial thigh, groin or pubic bone
- weakness and a feeling of leg instability
- weakness or wasting of the adductor muscles and a decrease in hip adduction and internal rotation of the hip
- a circumducting gait secondary to an externally rotated hip

# The Sacral Plexus



# The Sacral Plexus



**Muscular innervation of posterior thigh and leg**

**Muscular innervation of lateral and anterior leg**

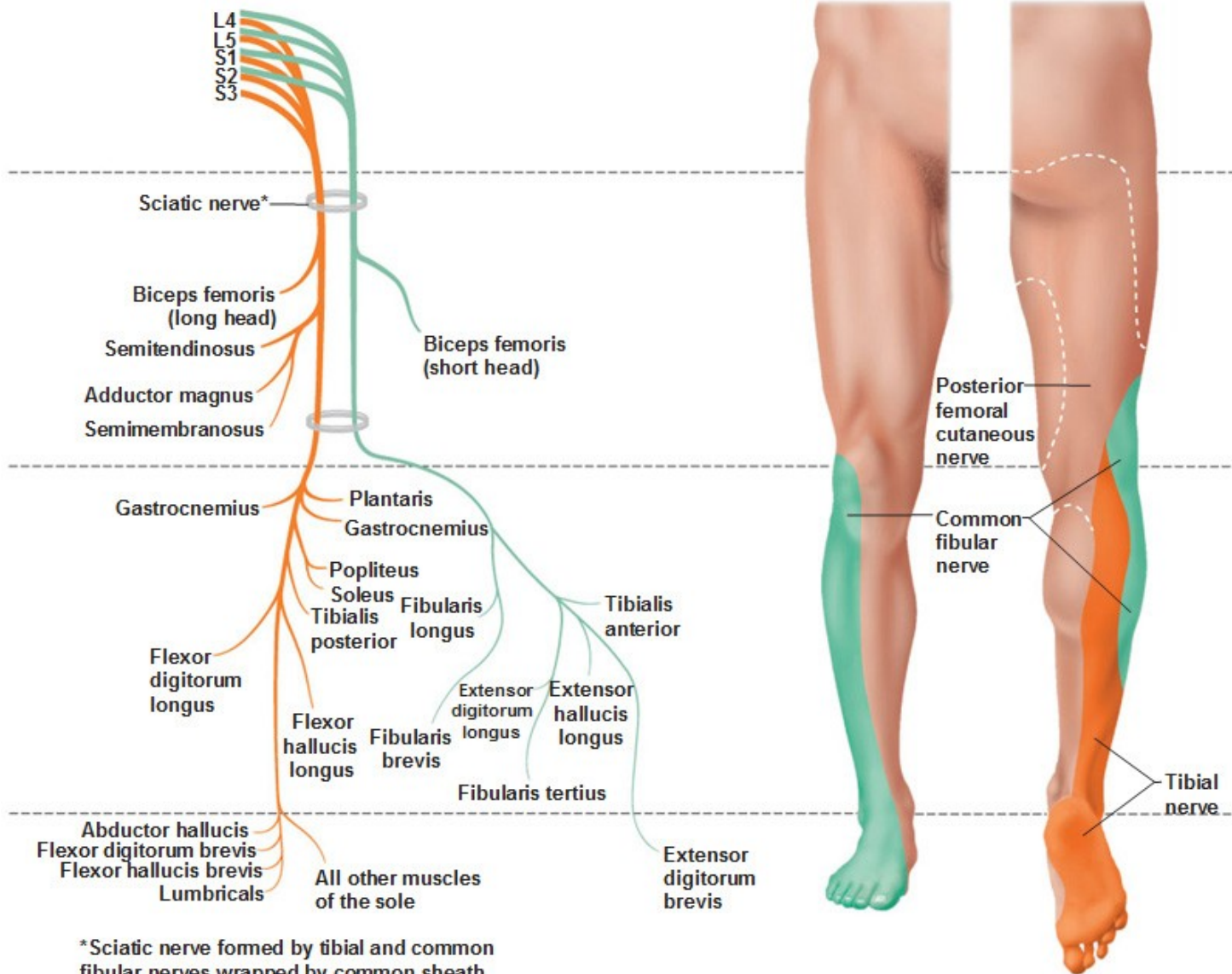
**Cutaneous innervation**

**Tibial nerve**

**Common fibular nerve**

*Anterior view*

*Posterior view*



\*Sciatic nerve formed by tibial and common fibular nerves wrapped by common sheath.



# The Sacral Plexus

- it is a nerve plexus which provides motor and sensory nerves for the posterior thigh, most of the lower leg and foot, and part of the pelvis
- it is part of **the lumbosacral plexus** and emerges from the lumbar vertebrae and sacral vertebrae (L4-S4)
- a **sacral plexopathy** is a disorder affecting the nerves of the sacral plexus, usually caused by trauma, nerve compression, vascular disease, or infection. Symptoms may include pain, loss of motor control, and sensory deficits

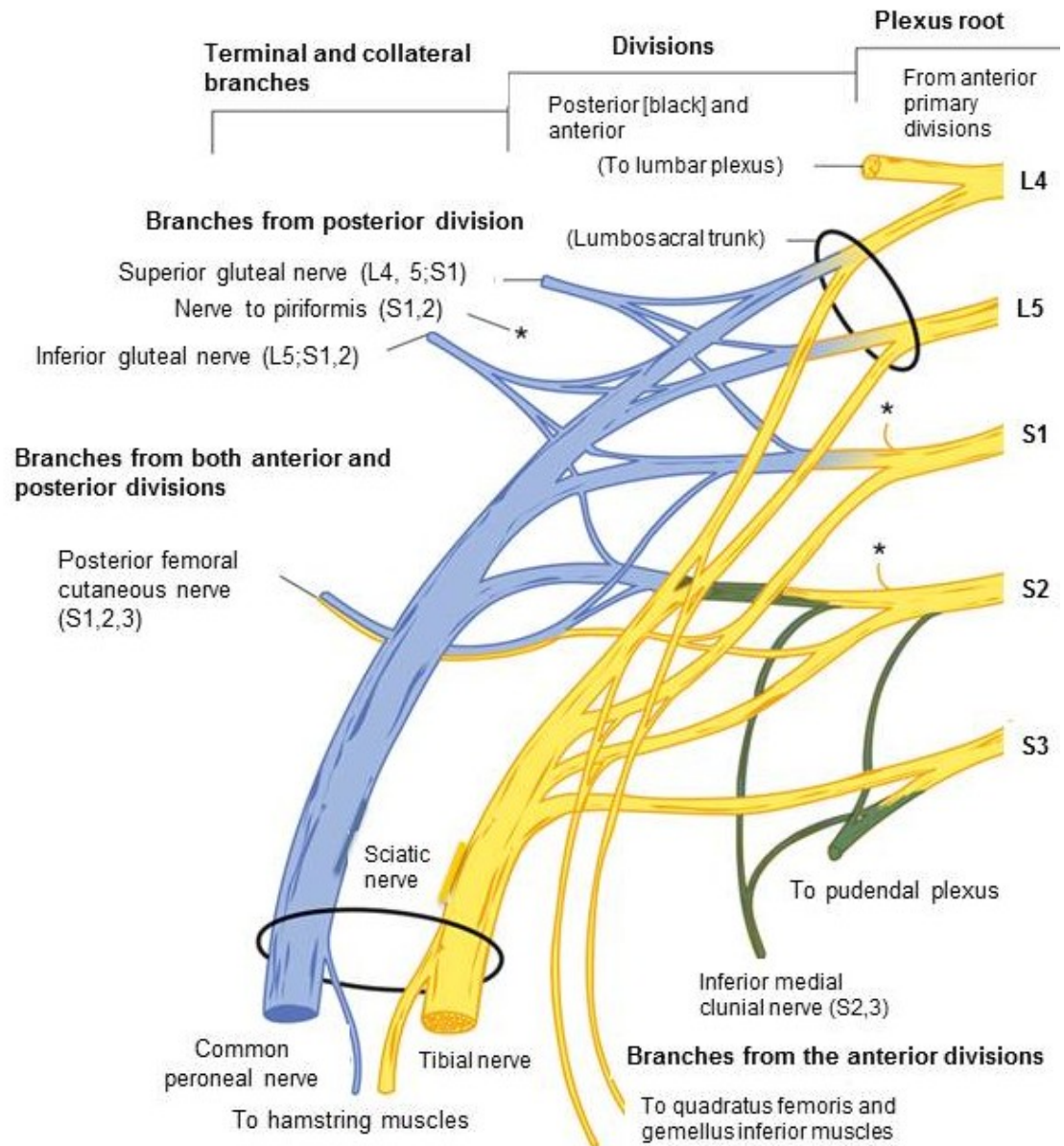
# The Sacral Plexus

The sacral plexus is formed by:

- the lumbosacral trunk
- the anterior division of the first sacral nerve
- portions of the anterior divisions of the second and third sacral nerves
- The nerves forming the sacral plexus converge toward the lower part of the greater sciatic foramen, and unite to form a flattened band, from the anterior and posterior surfaces of which several branches arise
- The band itself is continued as **the sciatic nerve**, which splits on the back of the thigh into **the tibial nerve** and **common fibular nerve**; these two nerves sometimes arise separately from the plexus, and in all cases their independence can be shown by dissection

# The Sacral Plexus

- Provides motor and sensory nerves for the posterior thigh, most of the lower leg, the entire foot, and part of the pelvis



# The Sciatic Nerve

- Motor functions
  - Leg flexion at the knee (see also tibial and peroneal nerves, which are the two most important branches clinically of the sciatic nerve)
  - The hamstring muscles (semitendinosus, semimembranosus, biceps femoris) are innervated by the sciatic nerve itself before it divides into the tibial and common peroneal nerve

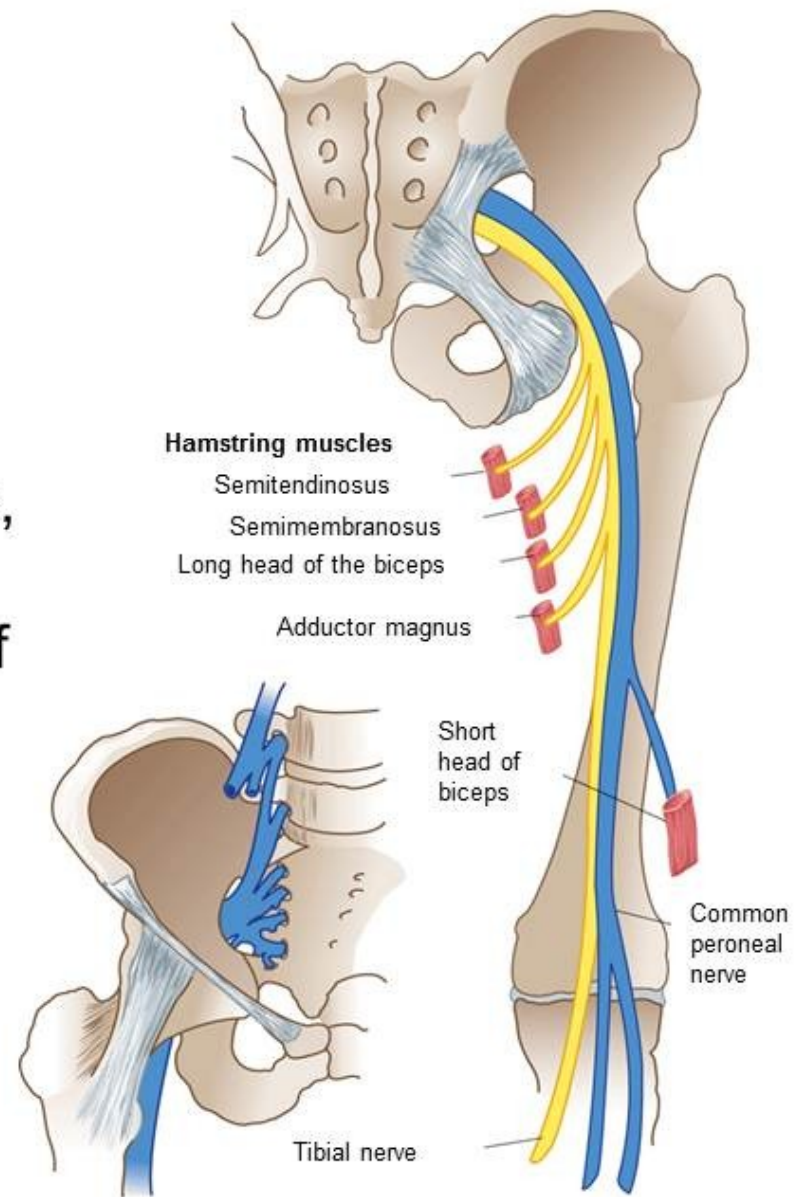
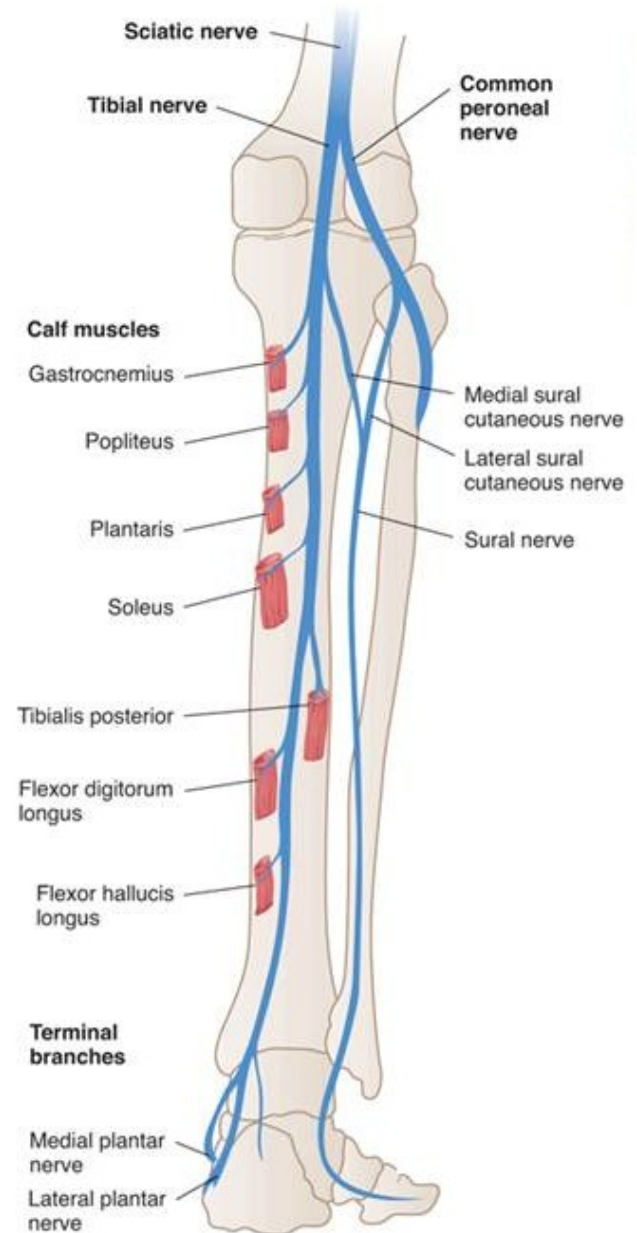
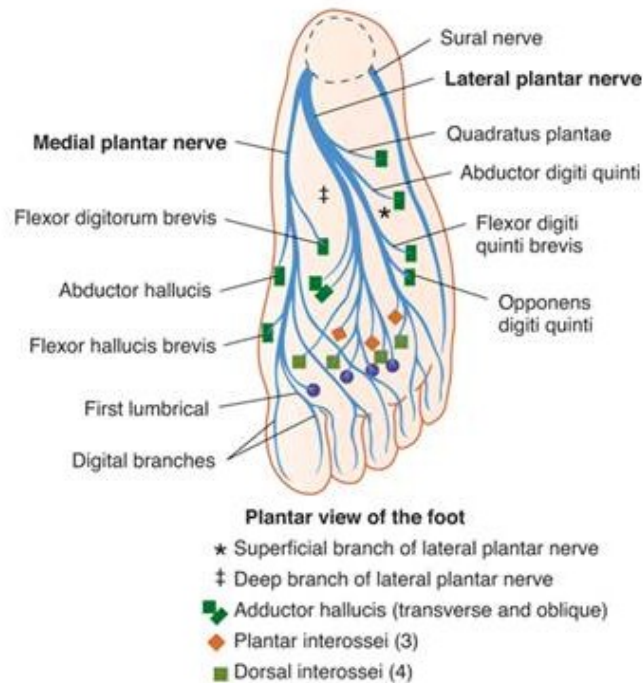


Figure 28-15. The Sciatic nerve (L4, 5; S1-3\_In: Waxman SG. *Clinical Neuroanatomy*. 26<sup>th</sup> ed. New York, NY: McGraw-Hill; 2010. <http://www.accessphysiotherapy.com>. Accessed March 22, 2012.

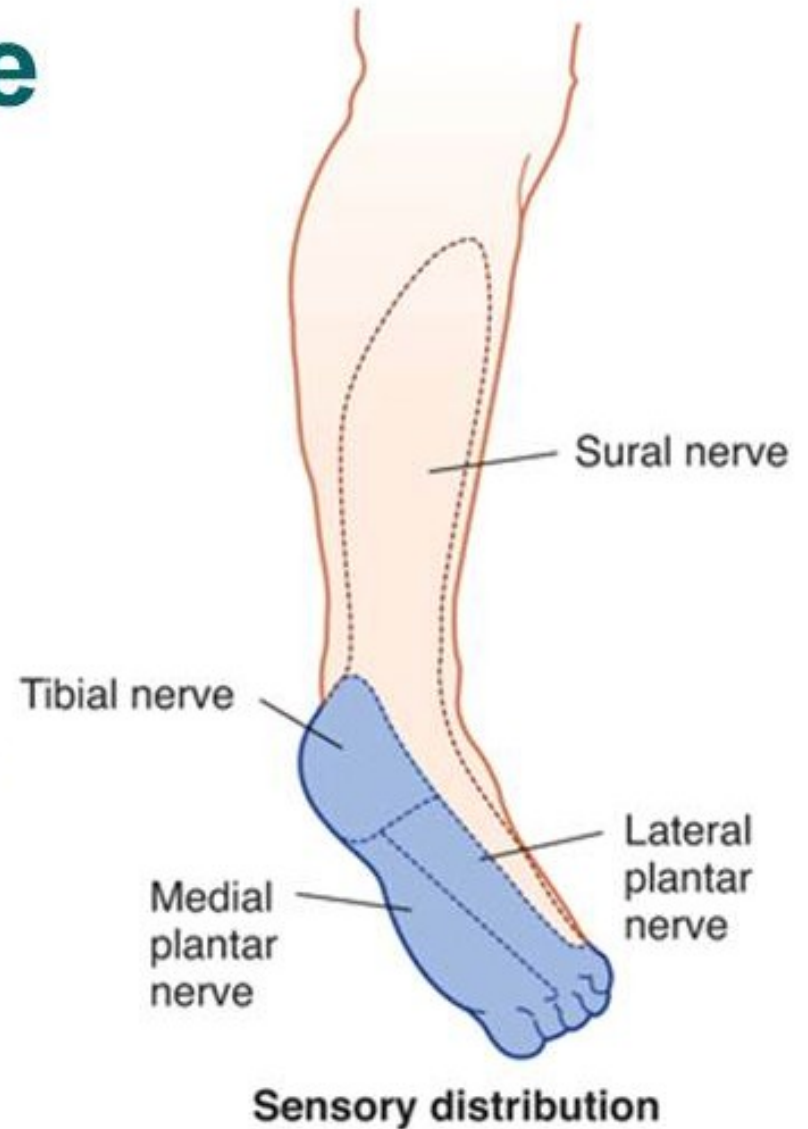
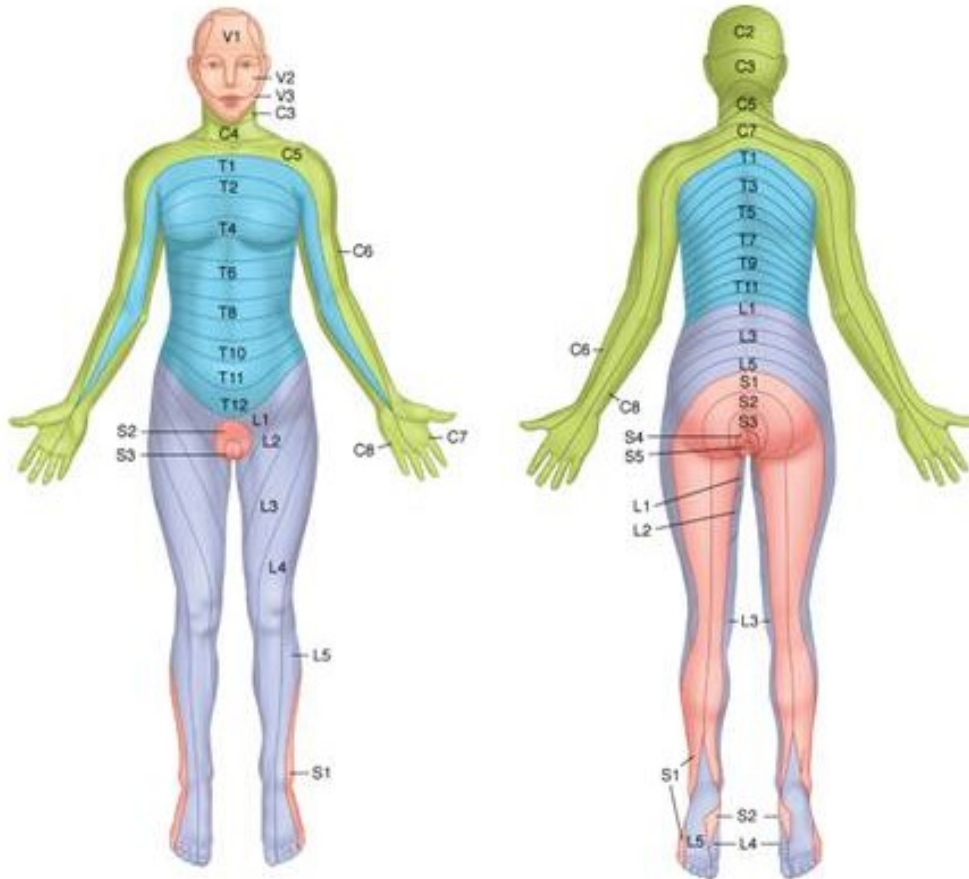
# The Tibial Nerve

- Motor functions
  - Foot plantar flexion and inversion, toe flexion



# The Tibial Nerve

- Sensory distribution



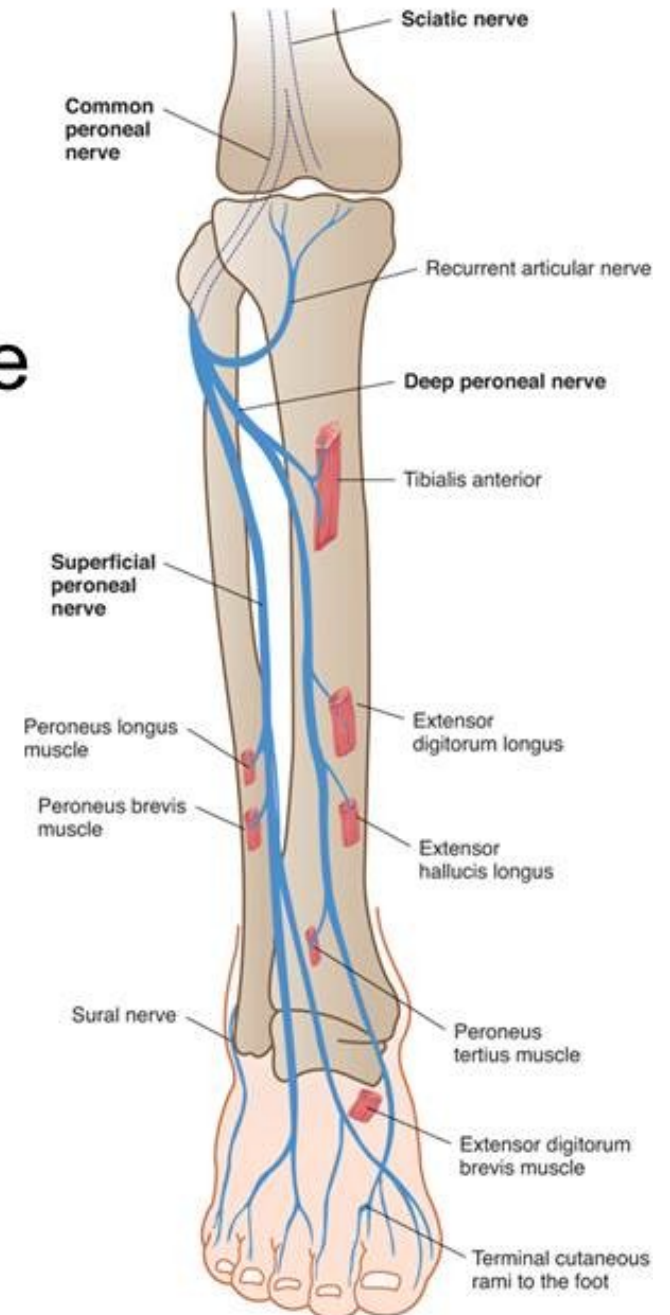
# Tibial nerve paralysis

## Symptoms:

- Sensation changes on the bottom of the foot
- Numbness, tingling, or other abnormal sensations
- Burning sensation
- Pain
- Weakness of the knee or foot, difficulty with walking

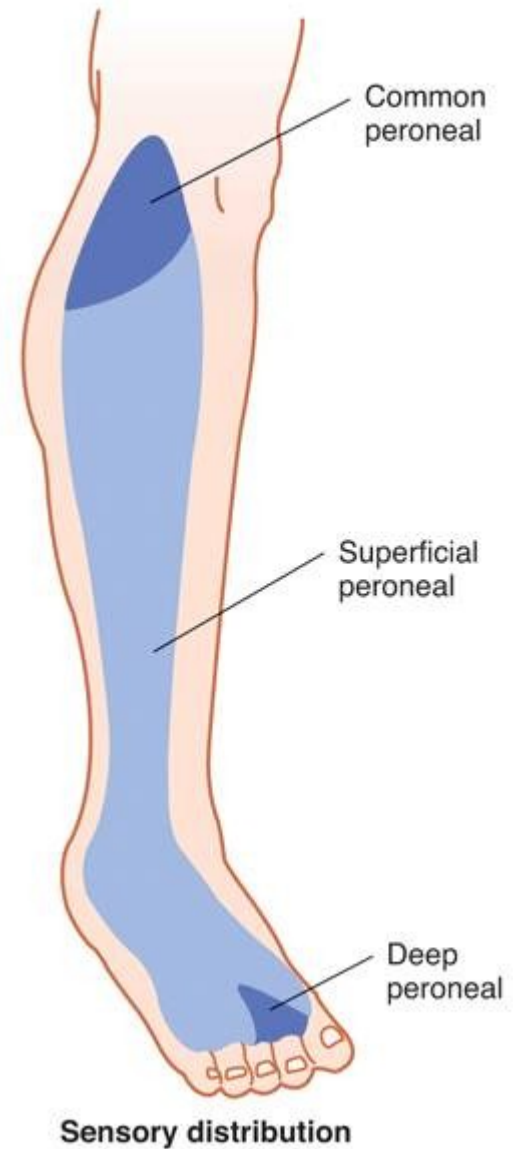
# The Common Peroneal Nerve

- Superficial peroneal nerve
  - Motor functions
    - Foot eversion
- Deep peroneal nerve
  - Motor functions
    - Foot dorsiflexion, toe extension

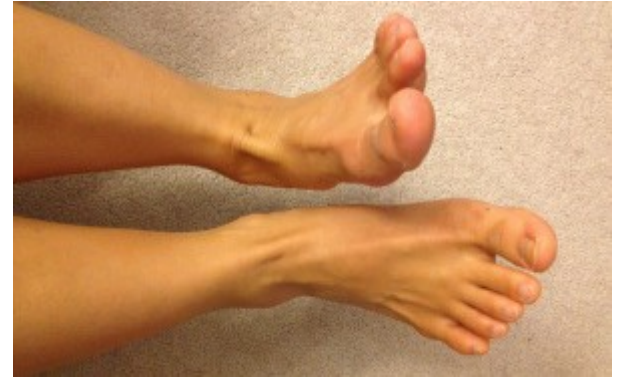



# The Common Peroneal Nerve with Superficial and Deep Peroneal Sensory Distribution



# Peroneal nerve paralysis



## Symptoms

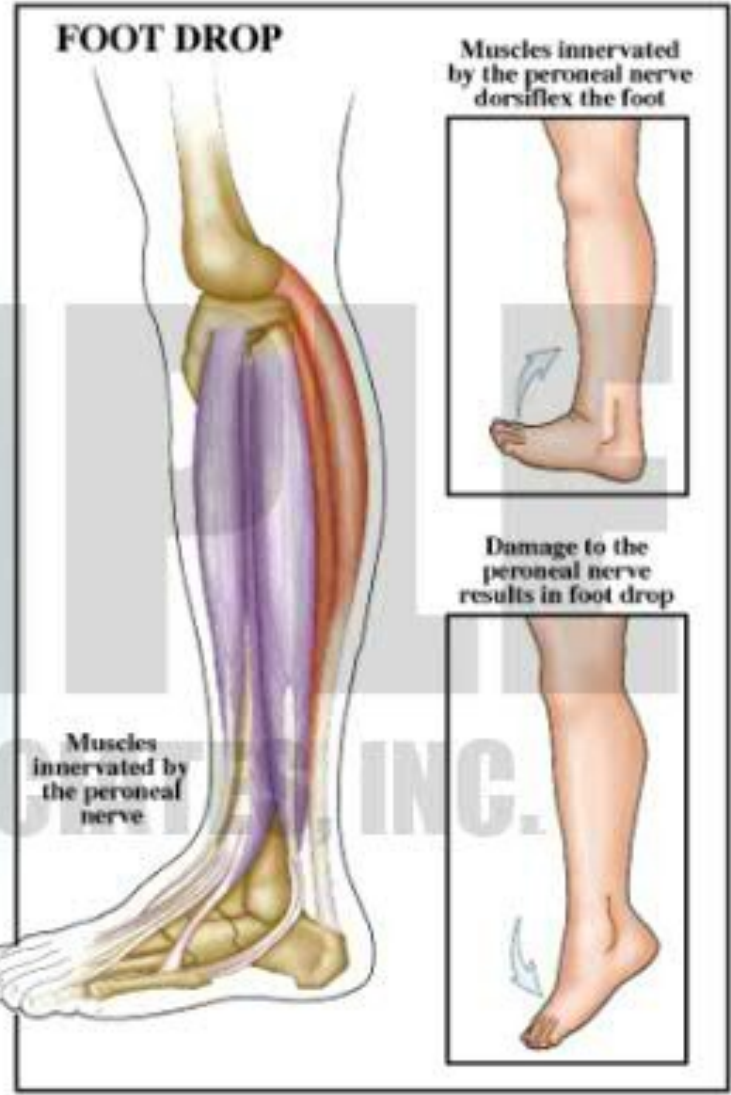
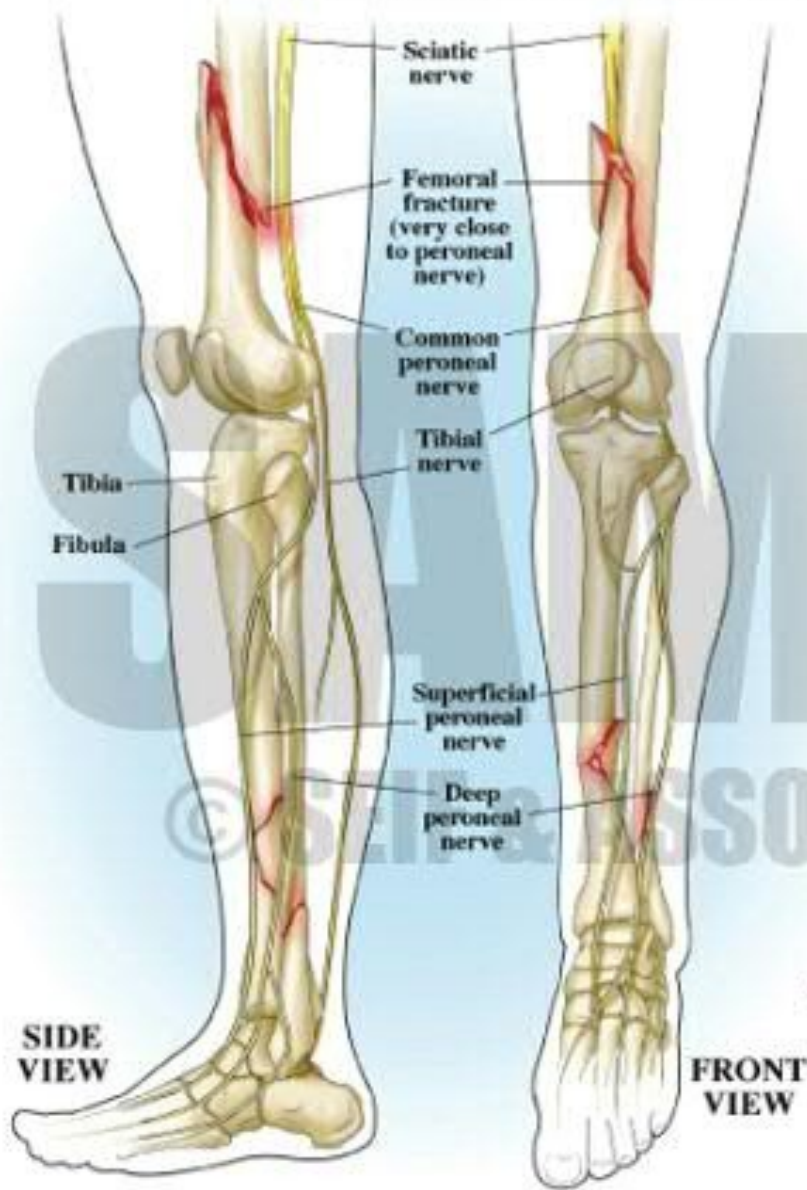
- Numbness or tingling on the anterior side or on top of the foot
- Reduced sensation to touch
- Weakness with lifting the foot in an upward direction and turning it outwards
- Loss of function of the foot
- Severe cases of peroneal nerve injury results in **footdrop** meaning the inability of a person to lift the foot up when ambulating
- Presence of a slapping gait where the foot slaps on the ground during ambulation due to inadequate control over muscles

# Peroneal nerve paralysis

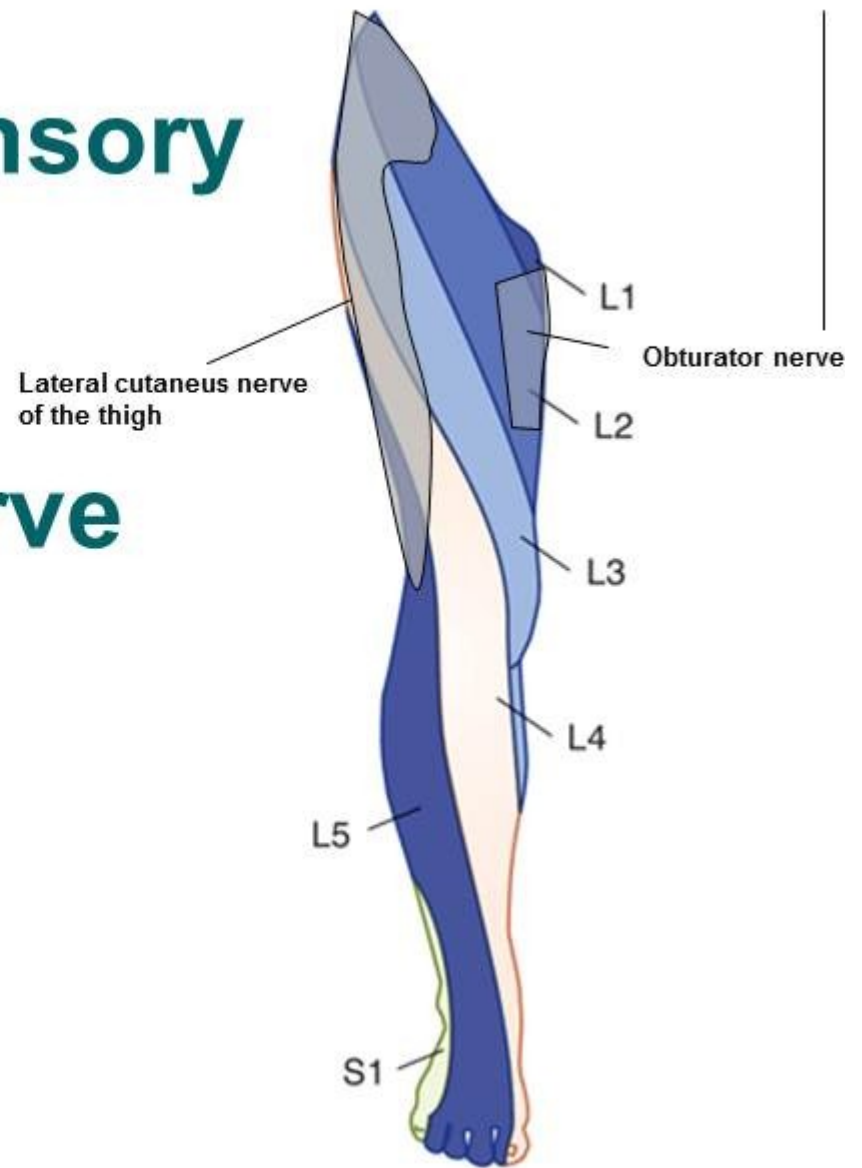
Examination of the legs may show:

- Loss of muscle control in the lower legs and feet
- Atrophy of the foot or foreleg muscles
- Difficulty lifting up the foot and toes and making toe-out movements

# PERONEAL NERVE AND FOOT DROP



# Regions of Sensory Innervation Supplied by Cutaneous Nerve Branches



# E-sources, literature:

- [https://en.wikipedia.org/wiki/Lumbar\\_plexus](https://en.wikipedia.org/wiki/Lumbar_plexus)
- [https://en.wikipedia.org/wiki/Sacral\\_plexus](https://en.wikipedia.org/wiki/Sacral_plexus)
- [http://accessphysiotherapy.mhmedical.com/data/Multimedia/grandRounds/lumbar/media/lumbar\\_print.html](http://accessphysiotherapy.mhmedical.com/data/Multimedia/grandRounds/lumbar/media/lumbar_print.html)
- <http://antranik.org/peripheral-nervous-system-spinal-nerves-and-plexuses/>
- <http://www.gpnotebook.co.uk>

Thank you for your attention 😊

