

Skin lesions - terminology

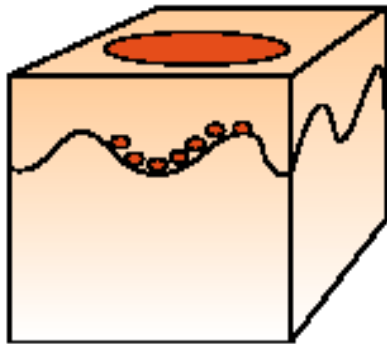


Skin lesions

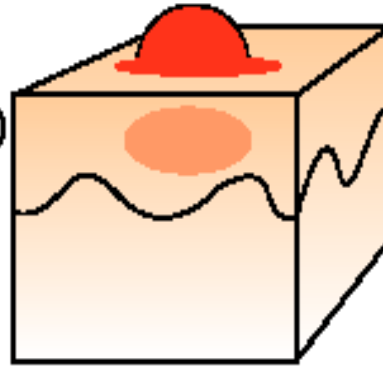
- A **lesion** is any single area of altered **skin**
 - **Primary** - macule, papule, nodule, wheal, vesicle, bulla, pustule
 - **Secondary** – scale, crust, fissure, erosion, excoriation
 - Other –plaque, cyst
-
- A rash is a widespread eruption of **lesions**
 - Exanthema - generalized, symmetric
 - Enanthema – mucous membranes

Macule –papule- pustule – vesicle –bulla –blister- pomphus-wheal- tuber- nodule

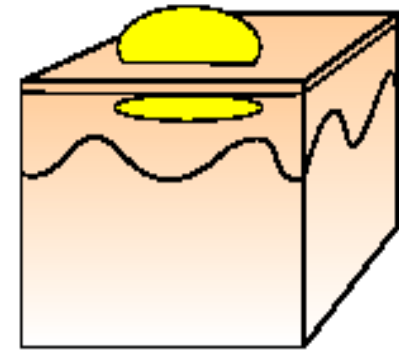
Makula
(Lentigo)



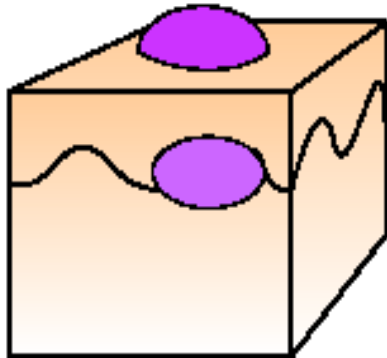
Papula
(Ekzémová)



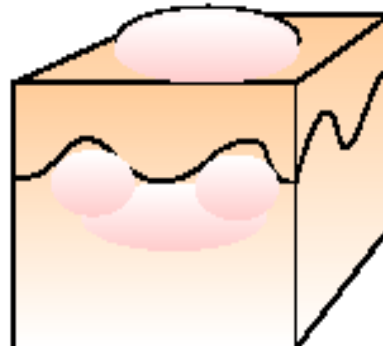
Pustula
(Subkorneální)



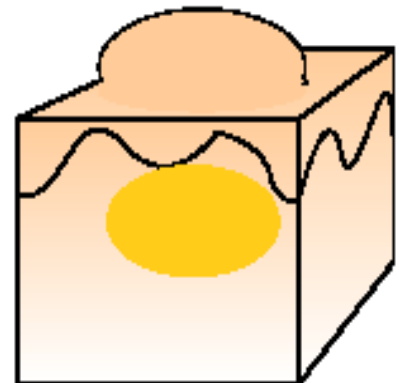
Vezikula

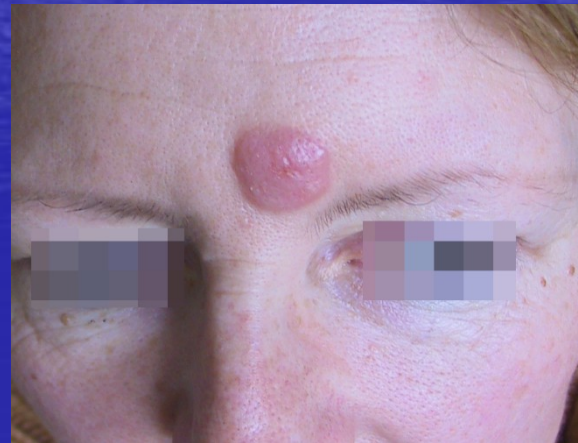
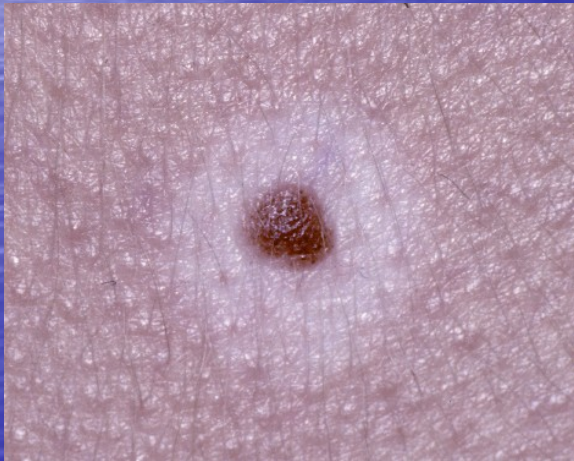
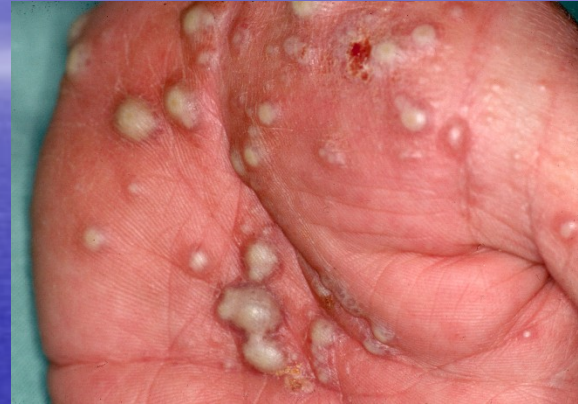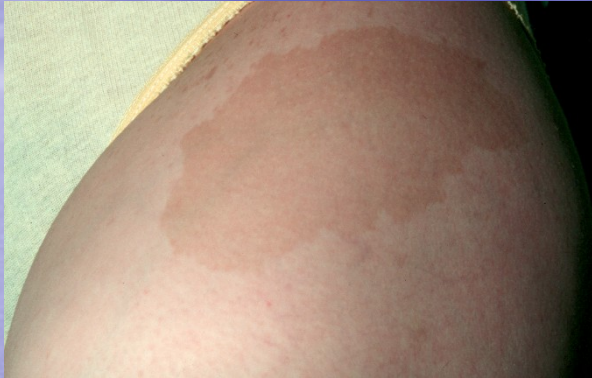Pomphus



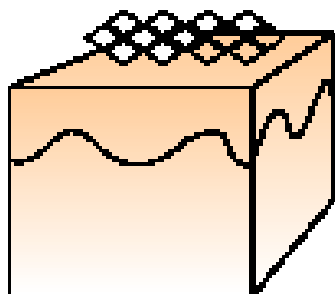
Tuber



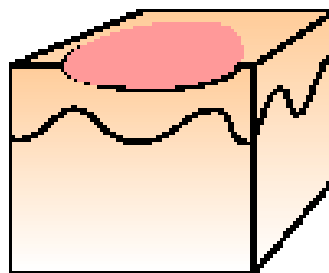


Scale – erosion - excoriation – fissure – ulcer –crust - necrosis

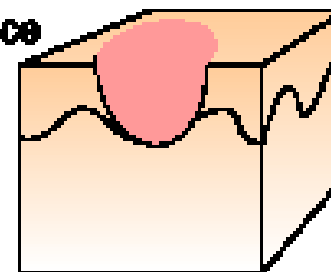
Šupina



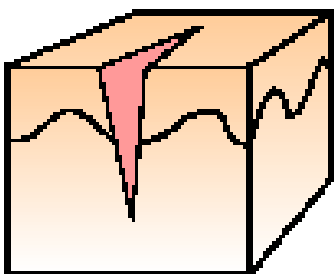
Eroze



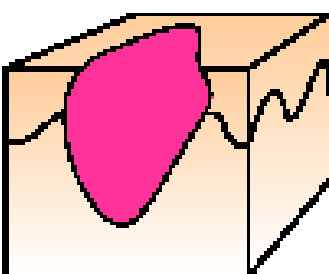
Exkorlace



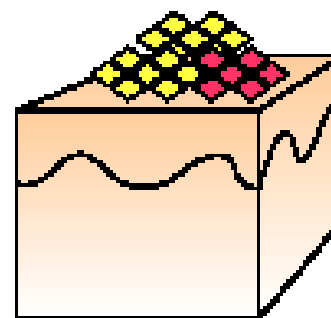
Razgáda



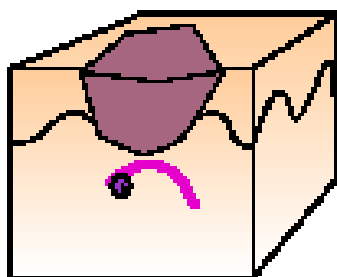
Ulkus

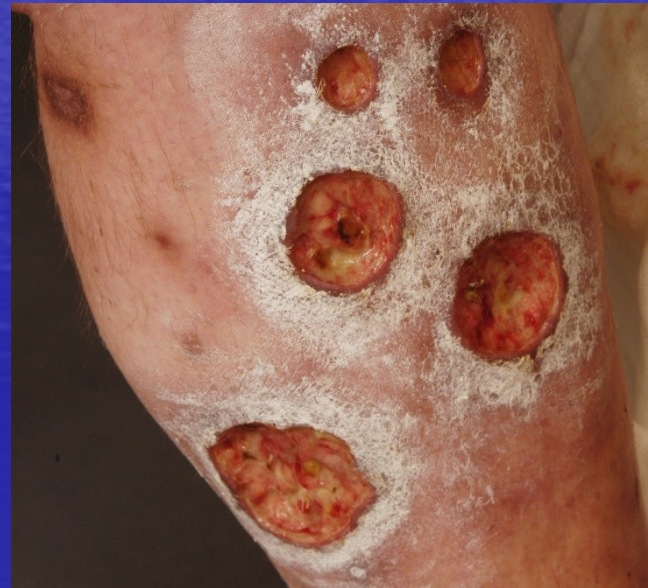
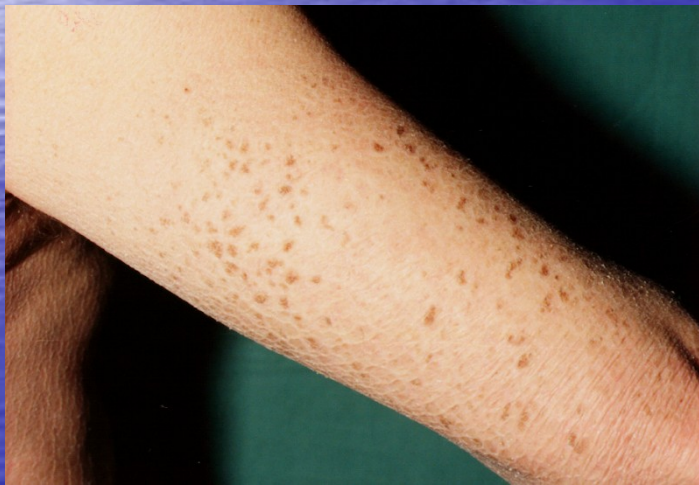
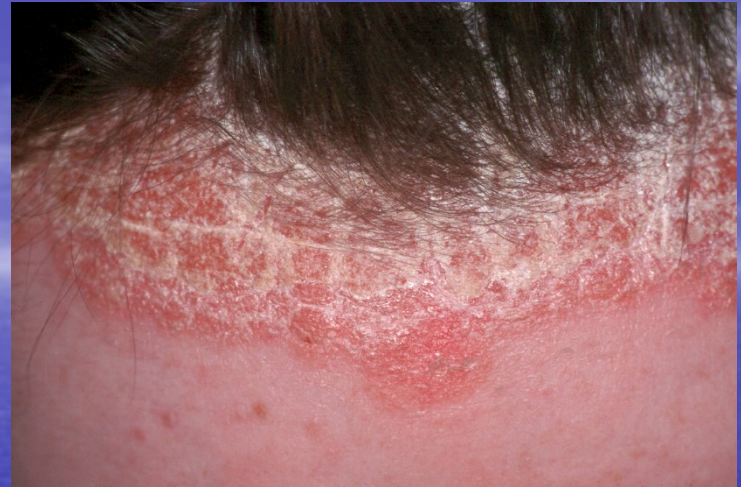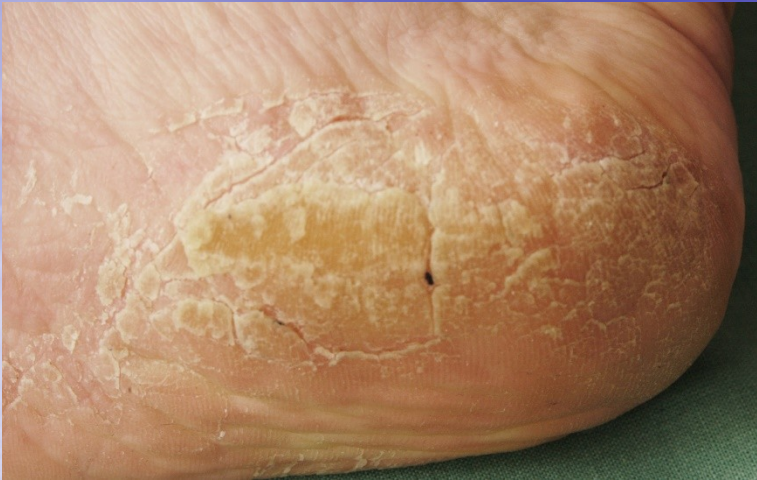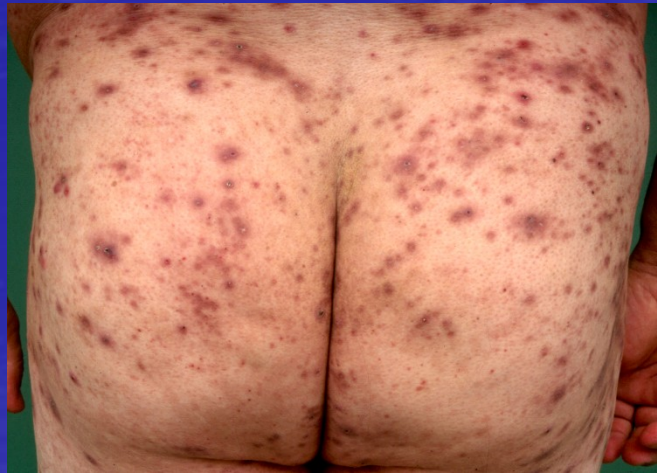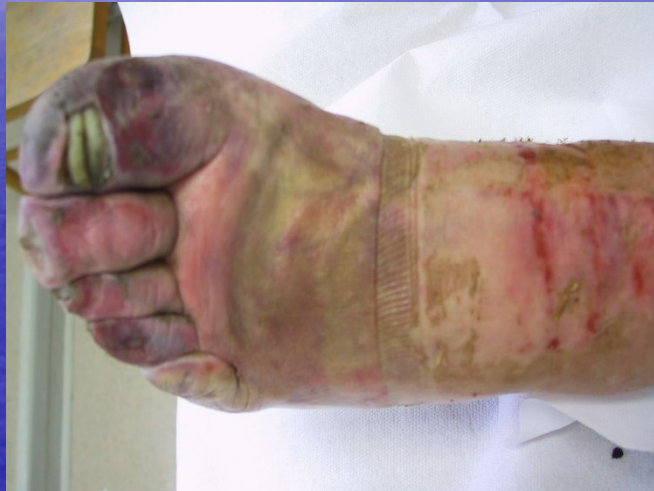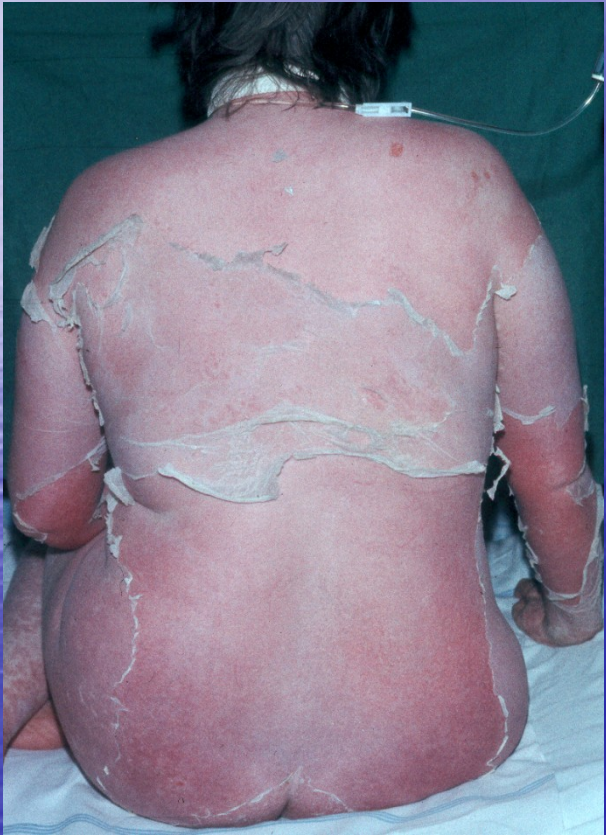Krusta



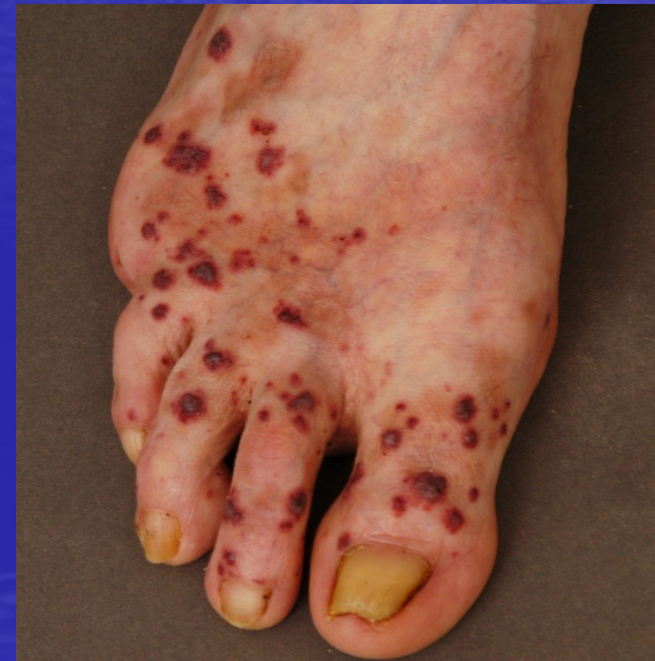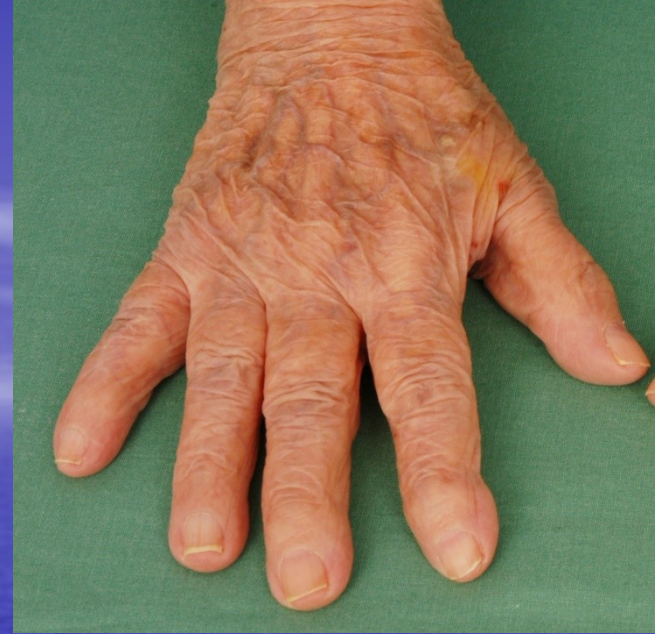Eschara



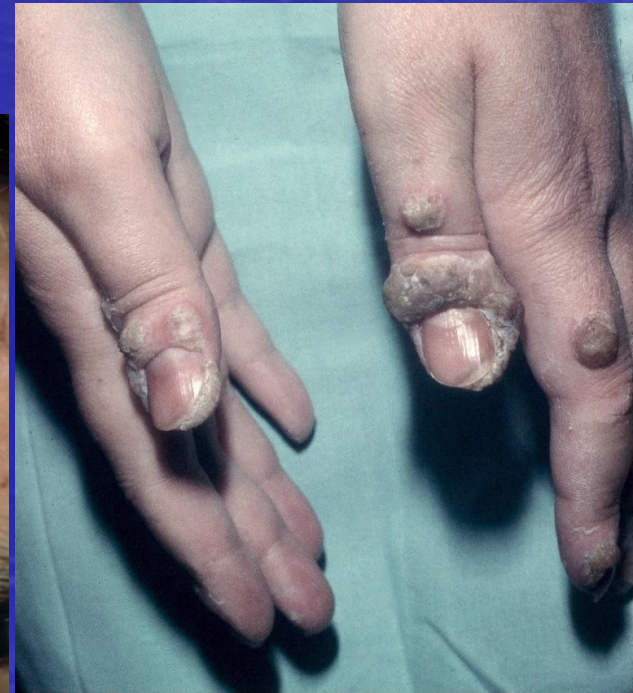
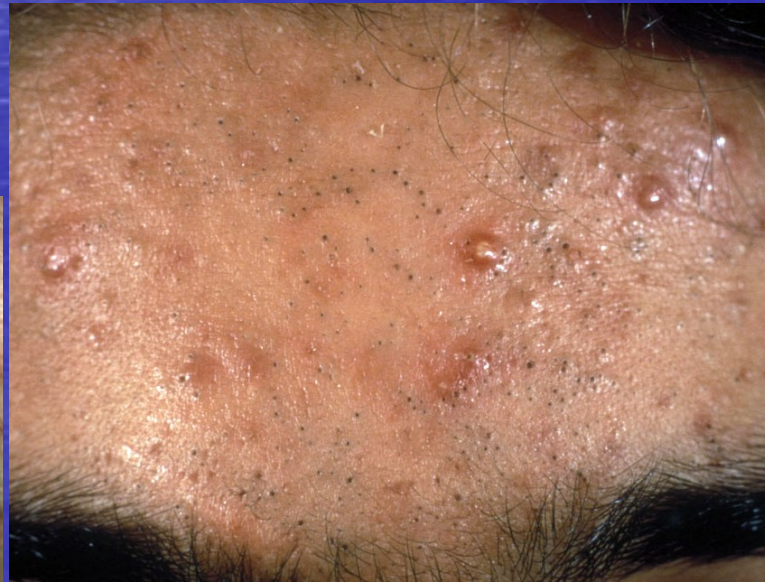
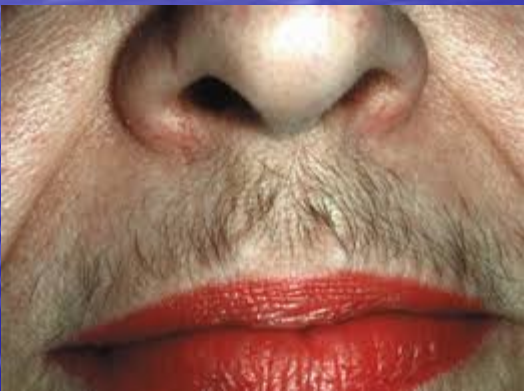
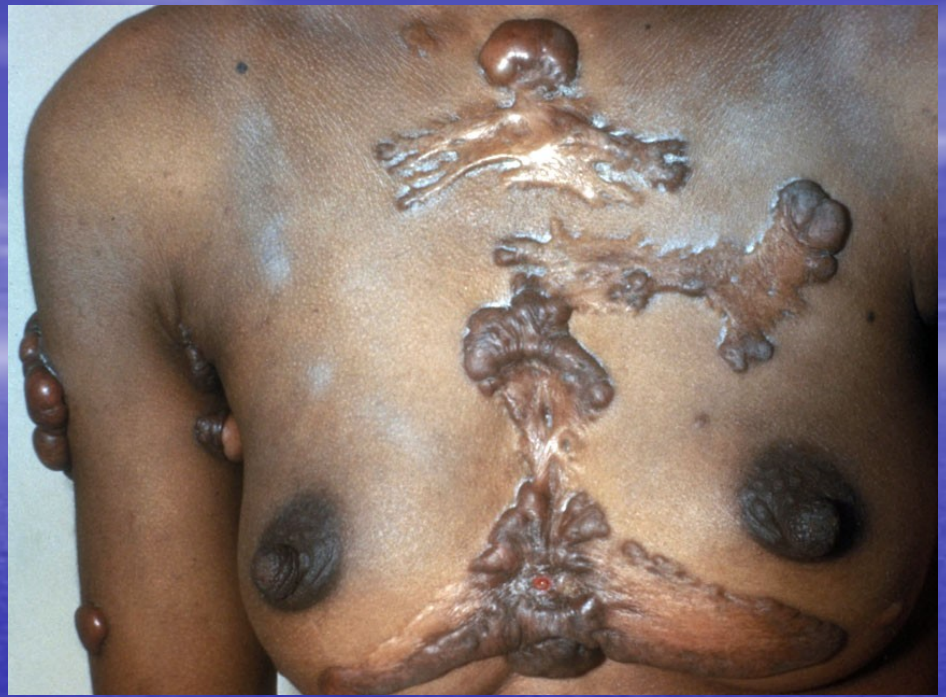
- Erythema
- Hyperpigmentation, freckle, lentigo
- Depigmentation
- Sclerosis, scleroderma
- Purpura, ecchymosis, petechia
- Telangiectasia
- Alopecia
- Effluvium diffuse

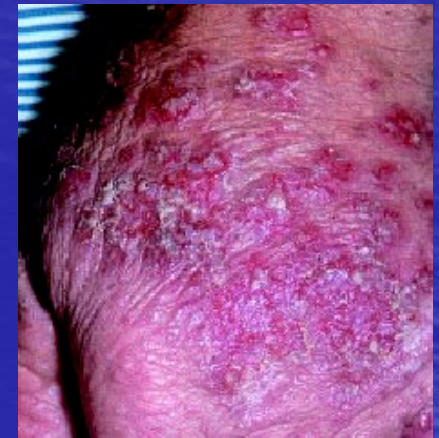
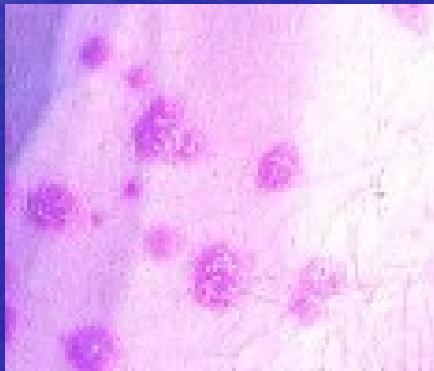
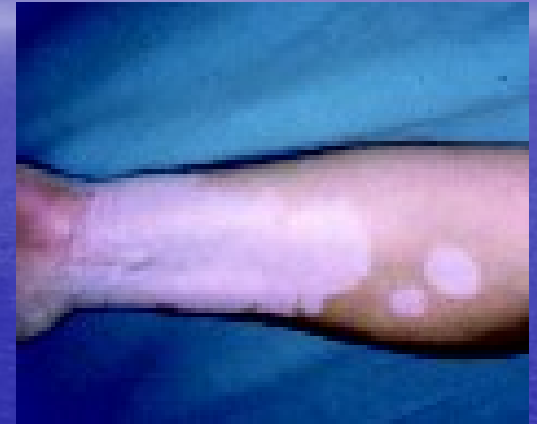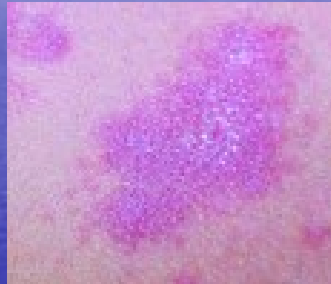- Comedo
- Atrophy, hypertrophy, scar, keloid, stria
- Folliculitis
- Cellulitis
- Hypertrichosis
- Hirsuties
- Lichenification
- Keratosis
- Wart

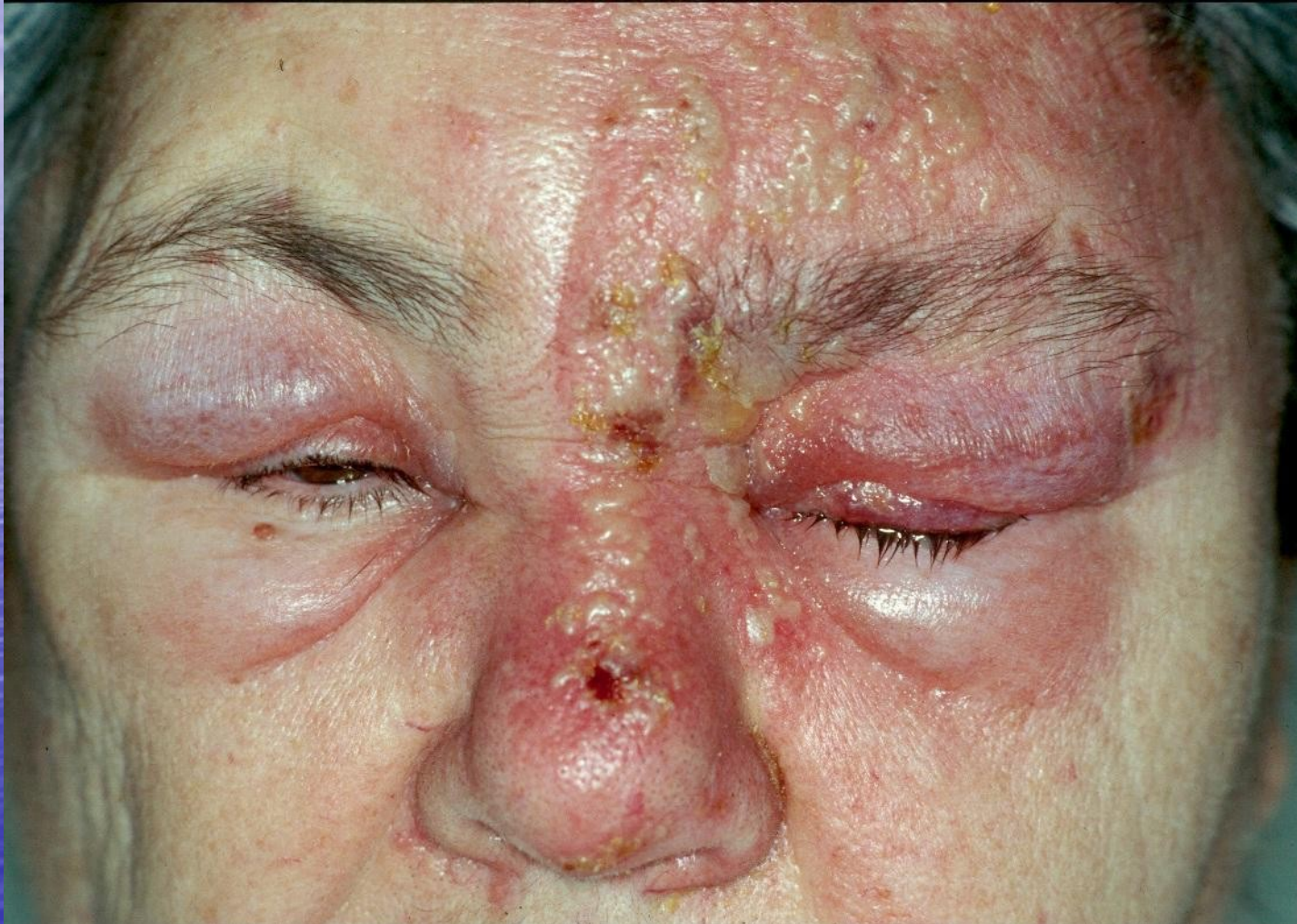

Lesions

- Size
- Colour
- Texture
- Border
- Surface
- Symmetry
- Symptoms

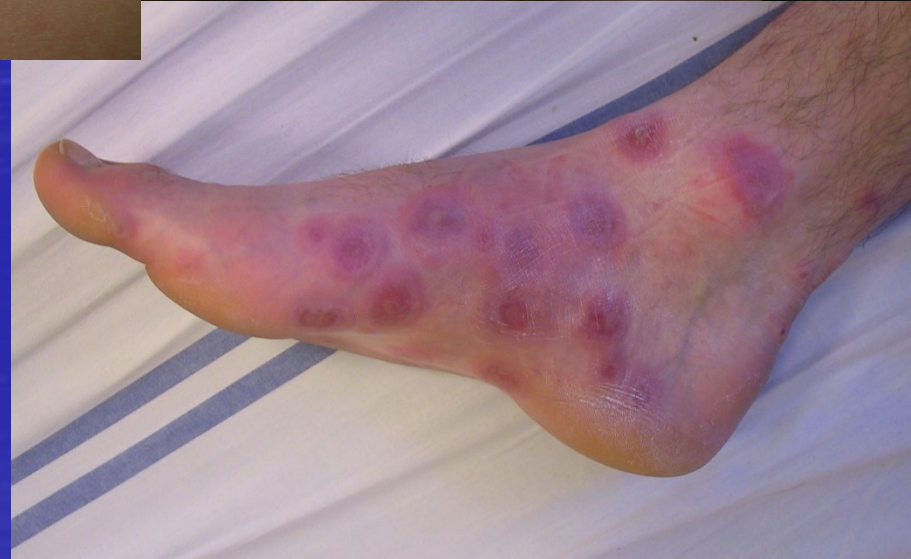
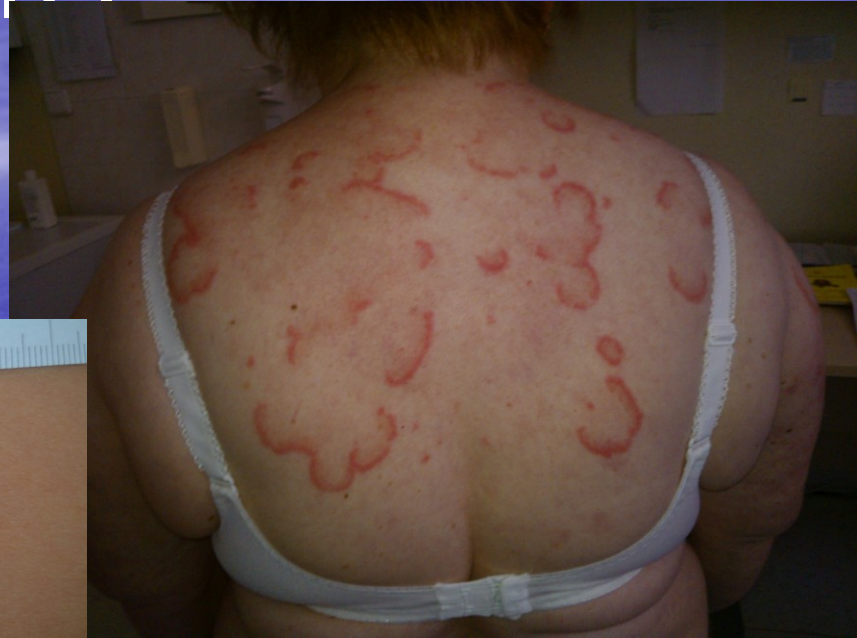
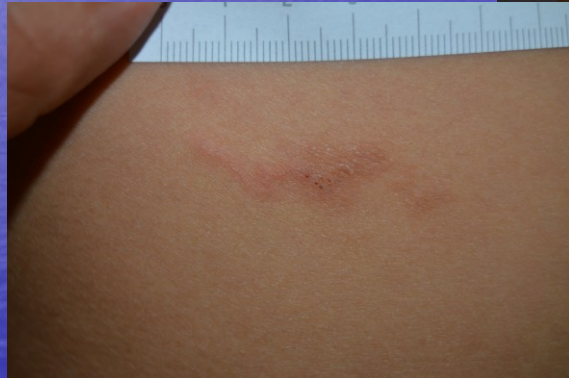Herpes zoster ophthalmicus

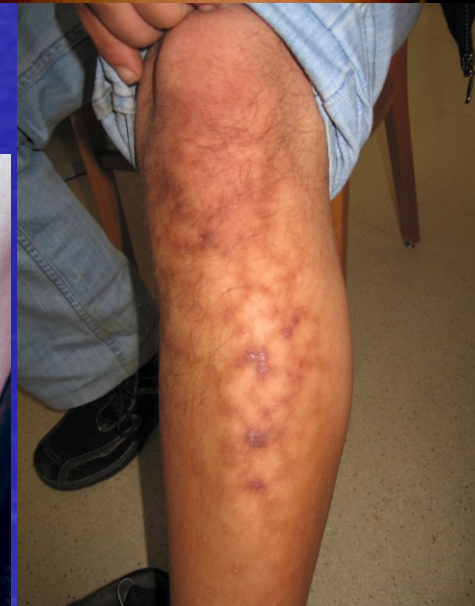
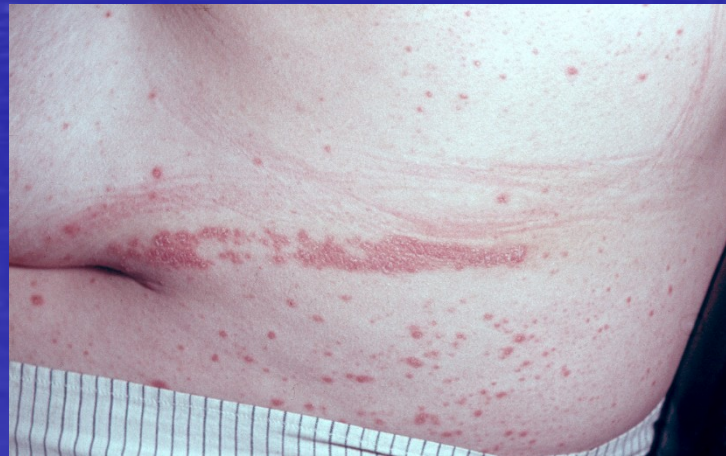
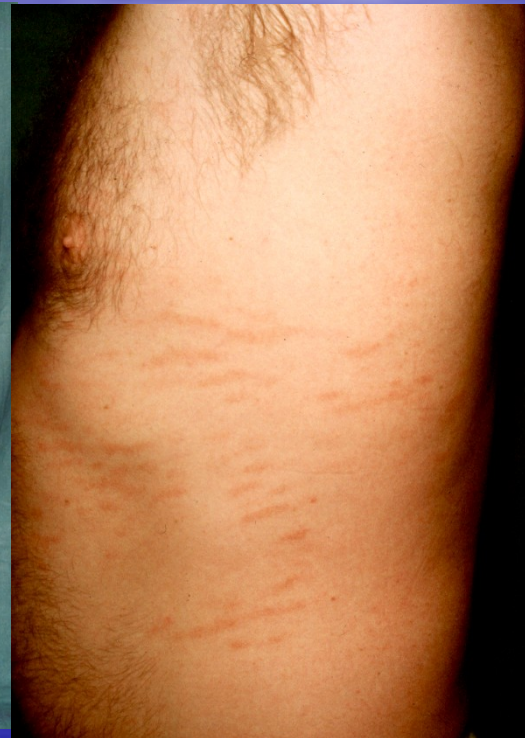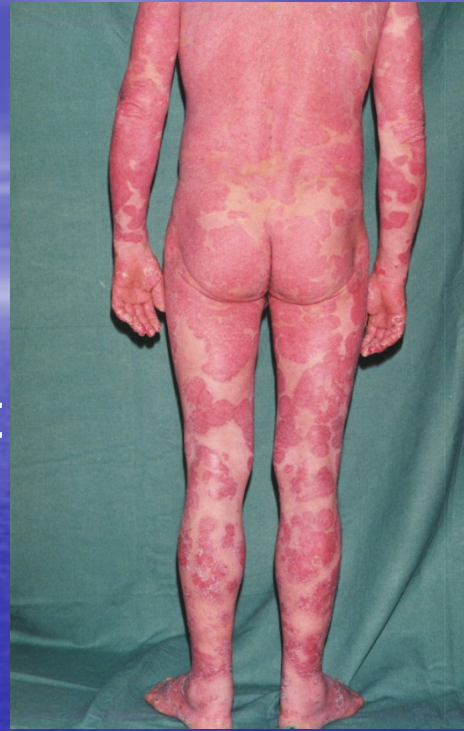Shapes and patterns

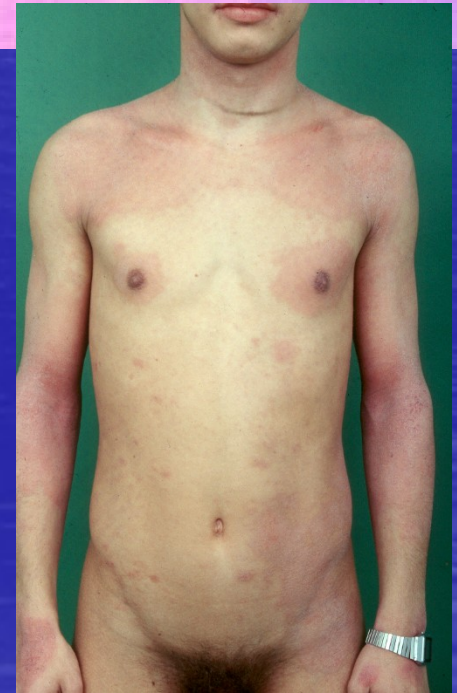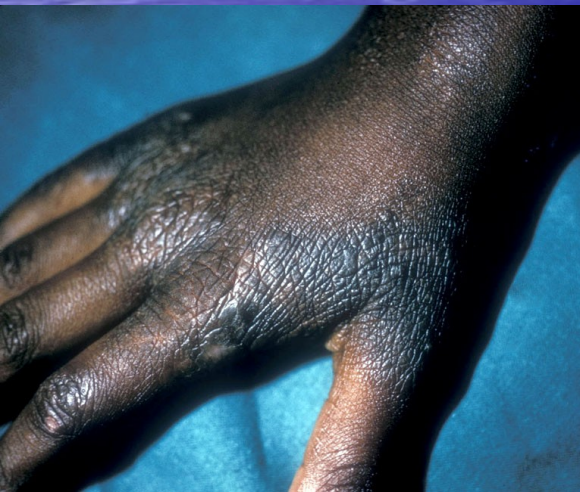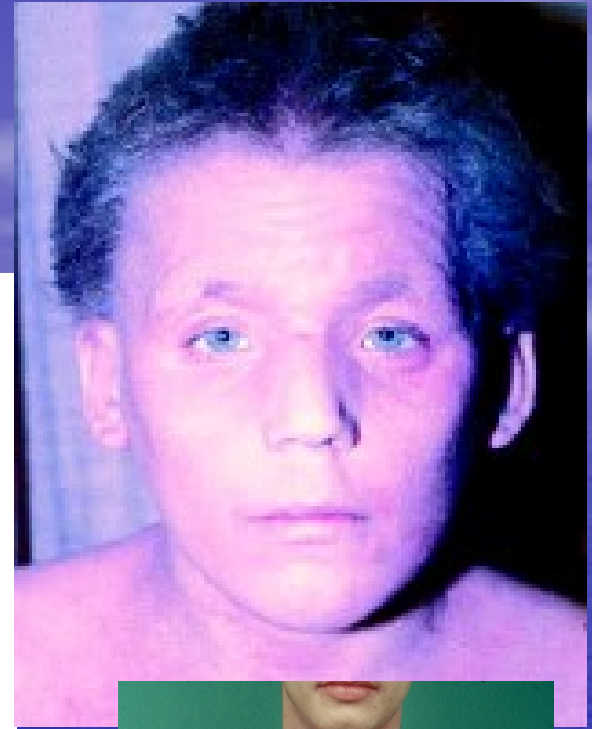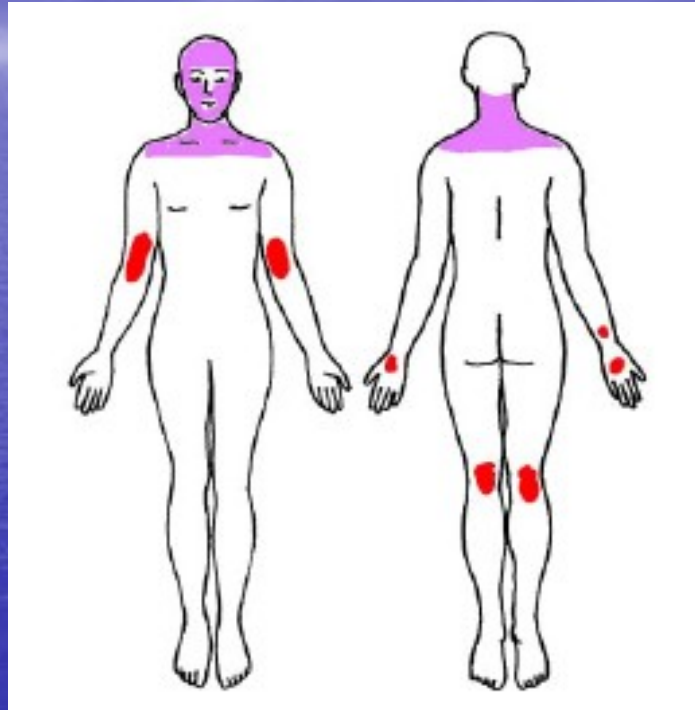
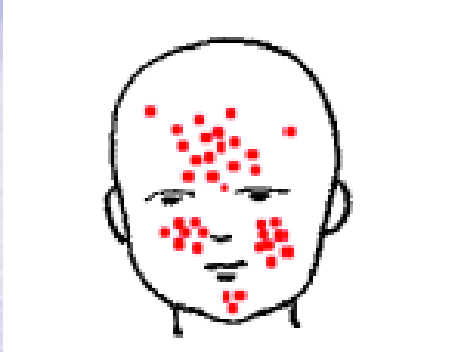
- Annular, circinate, arcuate, polycyclic
- Disseminated
- Follicular
- Geographic
- Herpetiform
- Target
- Linear
- Cribriform
- Nummular and discoid
- Serpiginous
- Zosteriform - dermatomal



- Generalized – exanthematous, confluent
- Morbilliform
- Oval, digitate –fir tree pattern
- Lymphatic spread
- Koebner phenomenon
- Reticulate
- Livedo
- Erythroderma

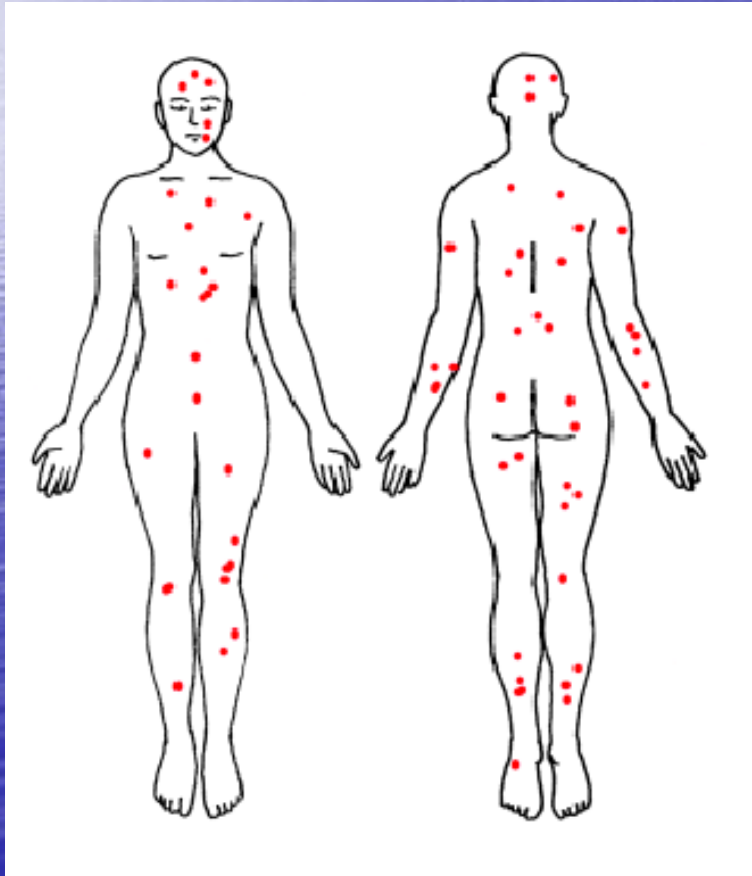


Atopic dermatitis

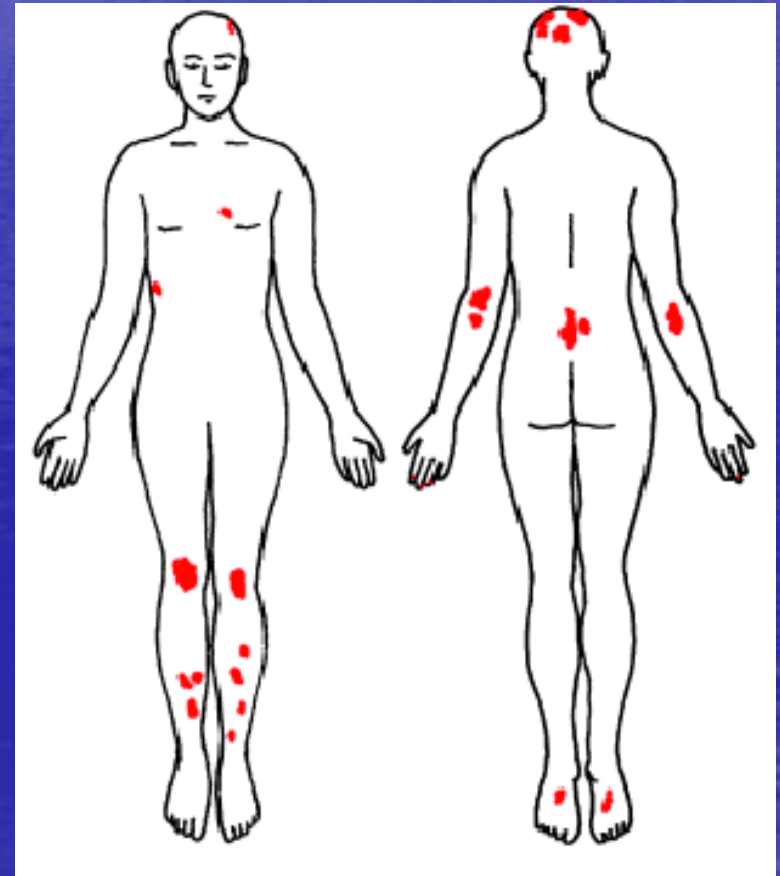


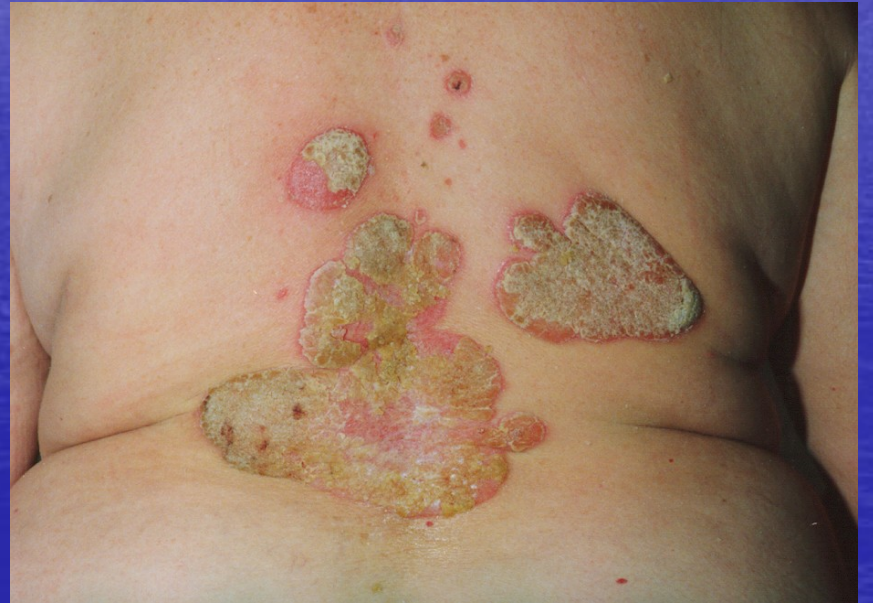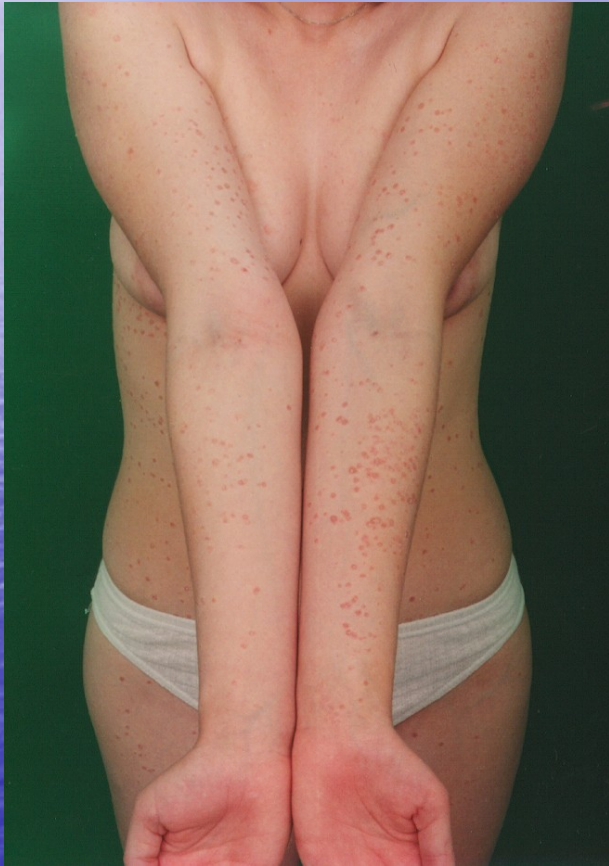Psoriasis

- acute

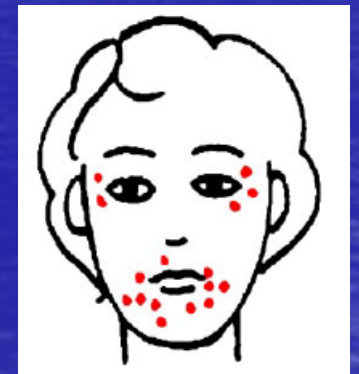
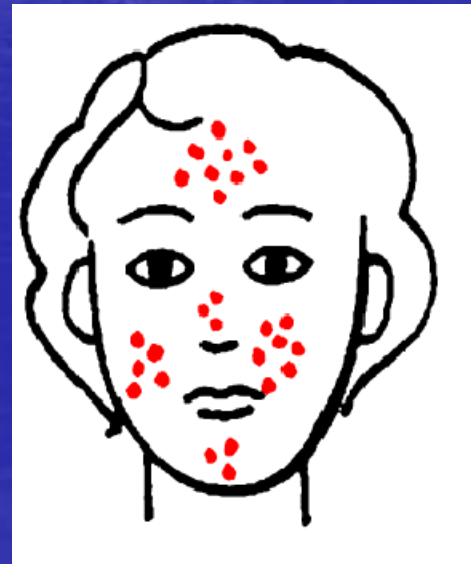
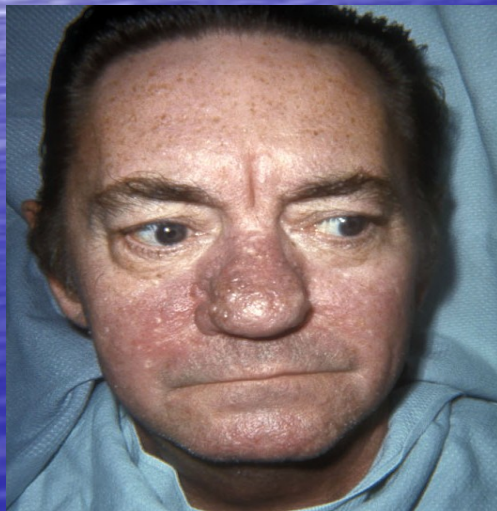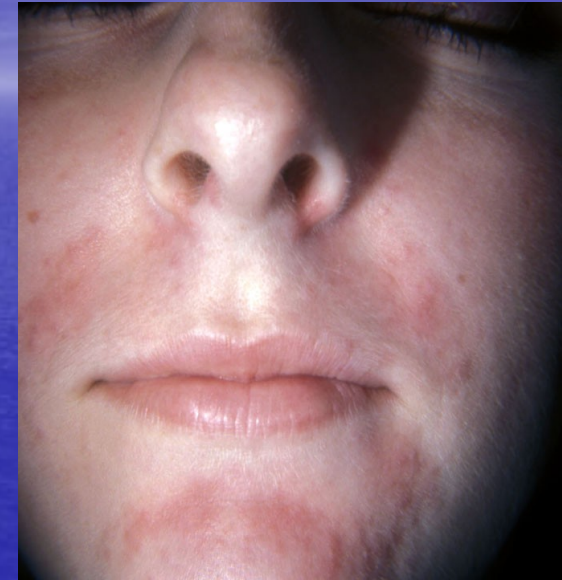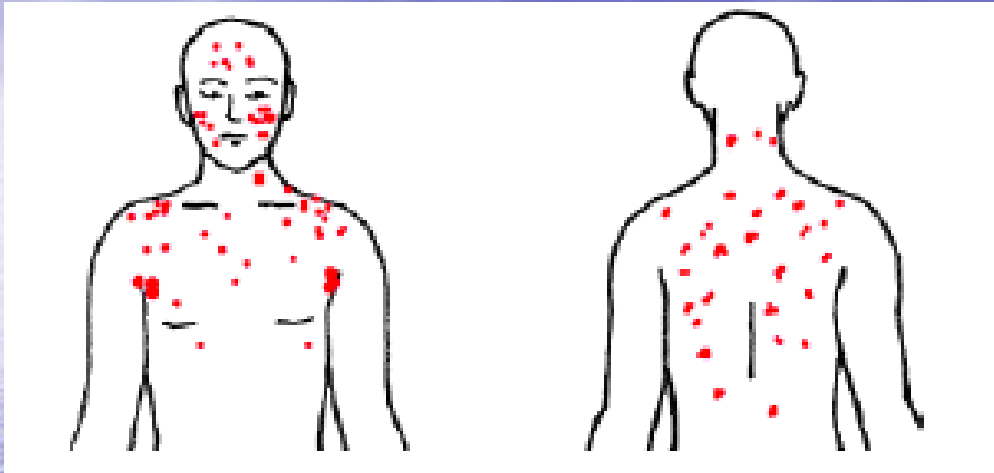


- chronic

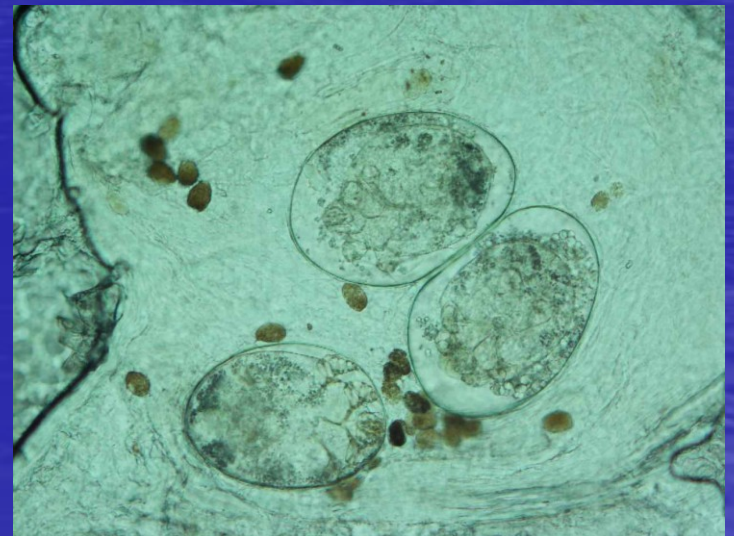
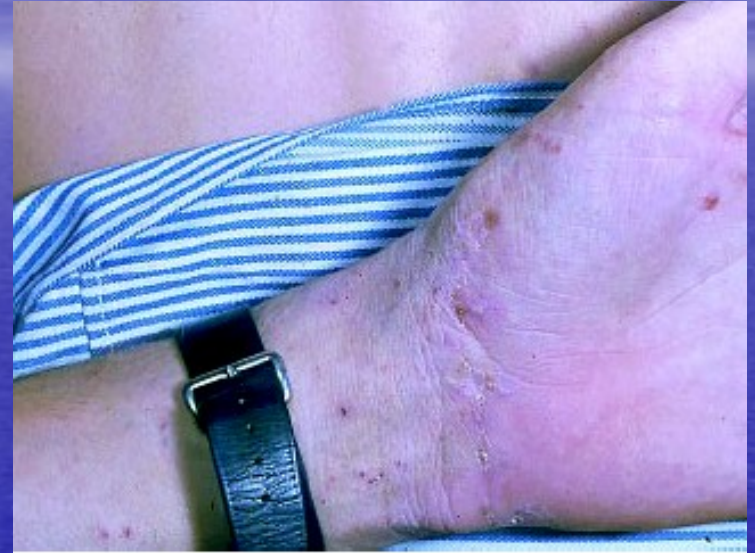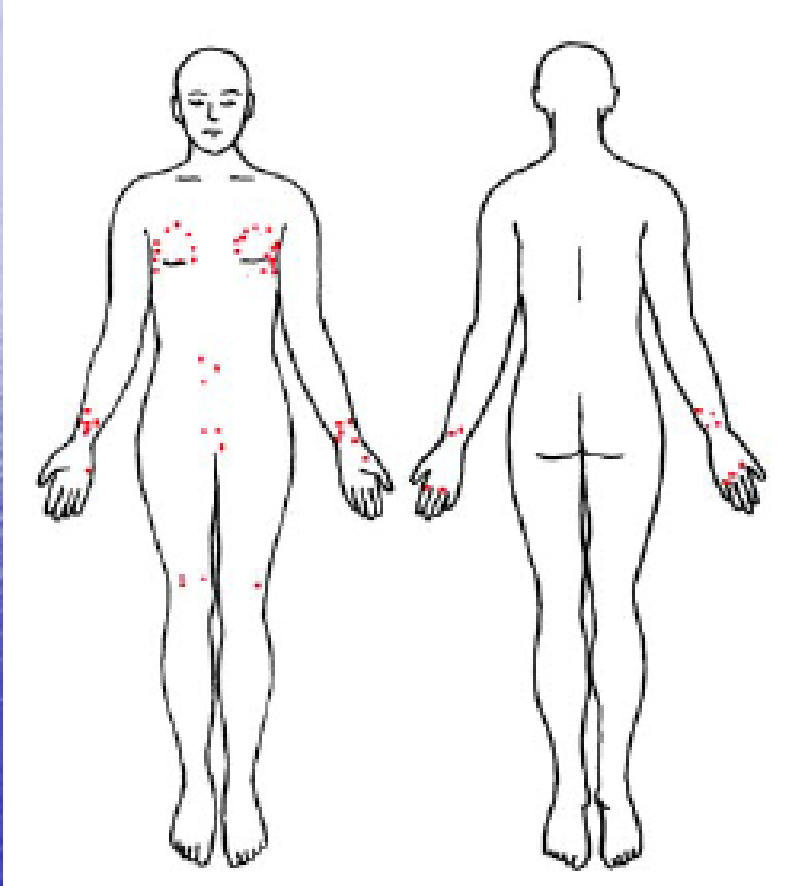




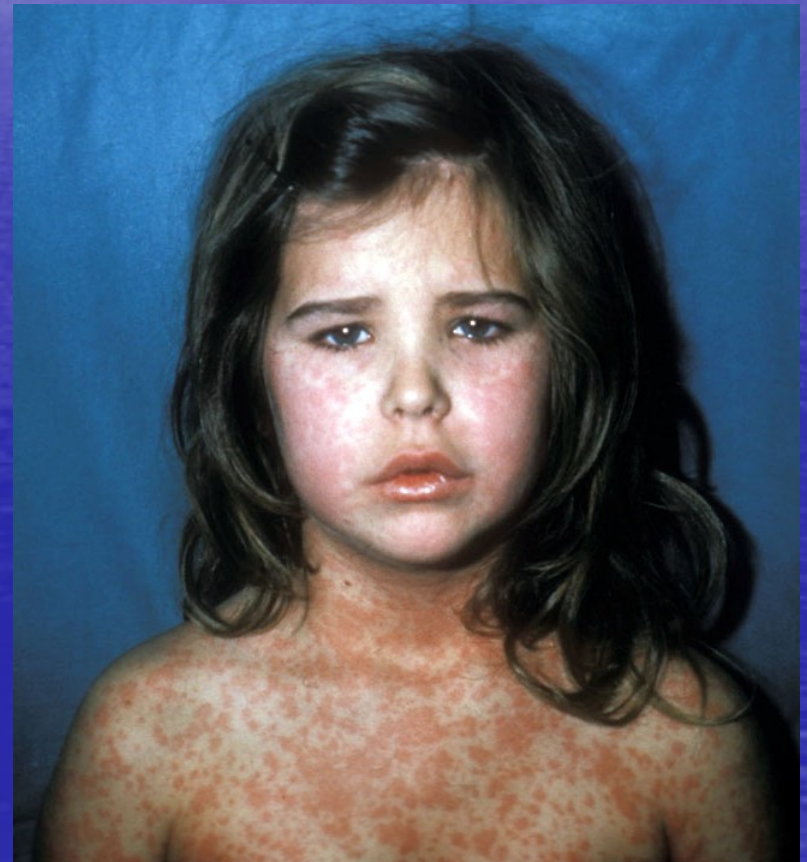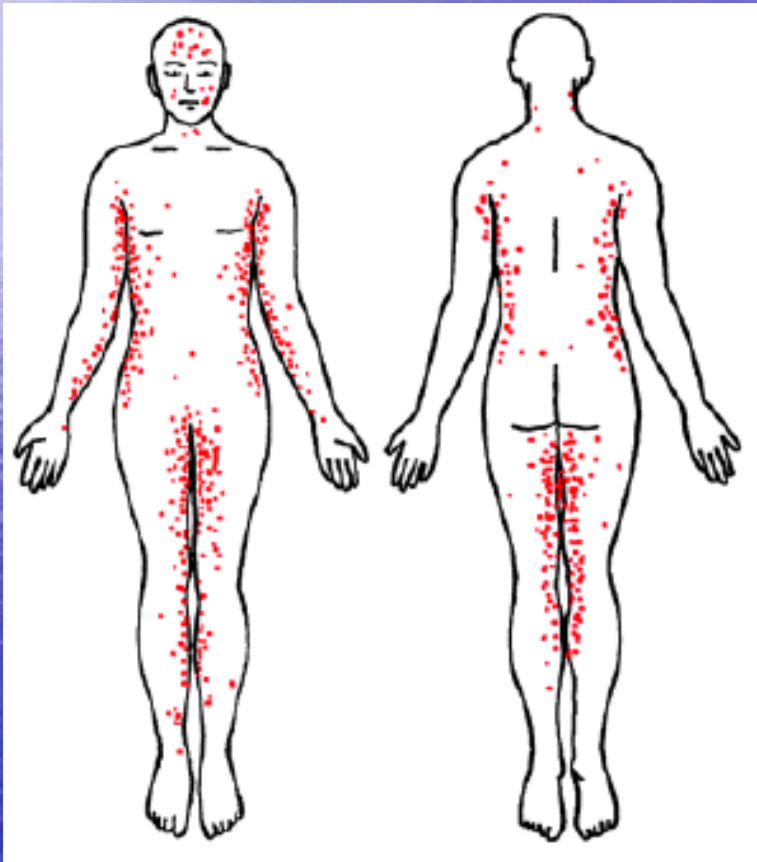
Acne – rosacea * perioral dermatitis



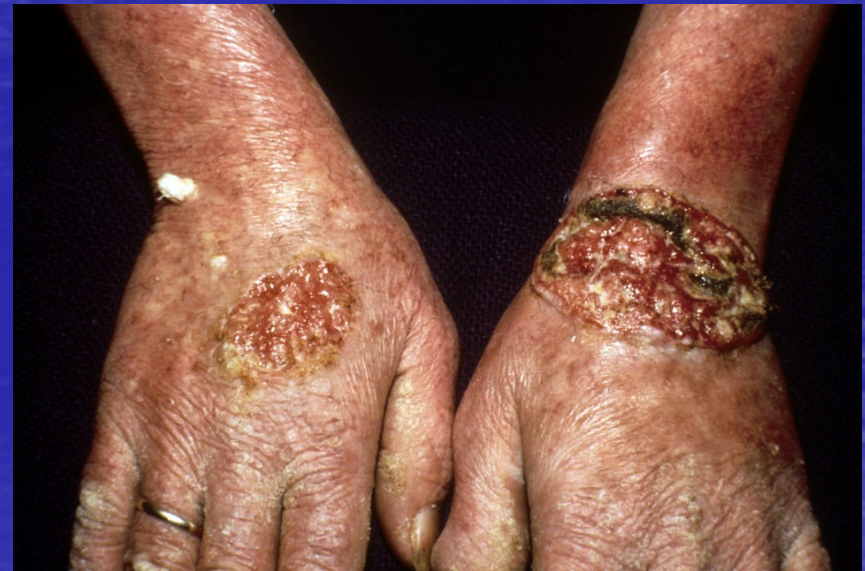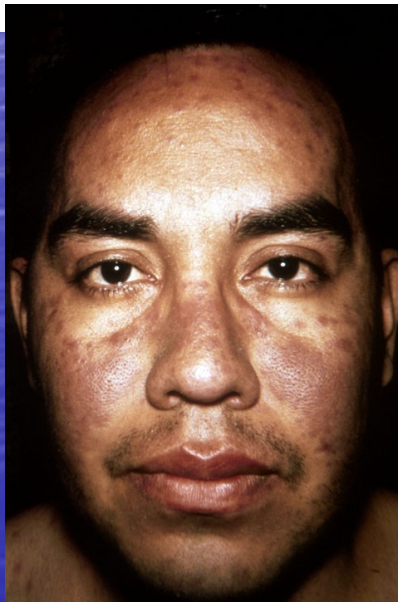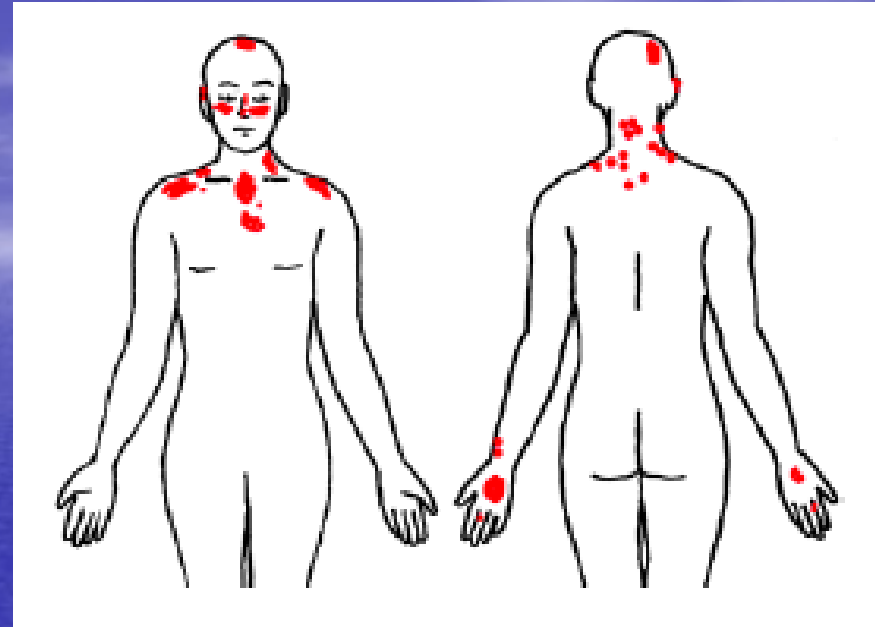
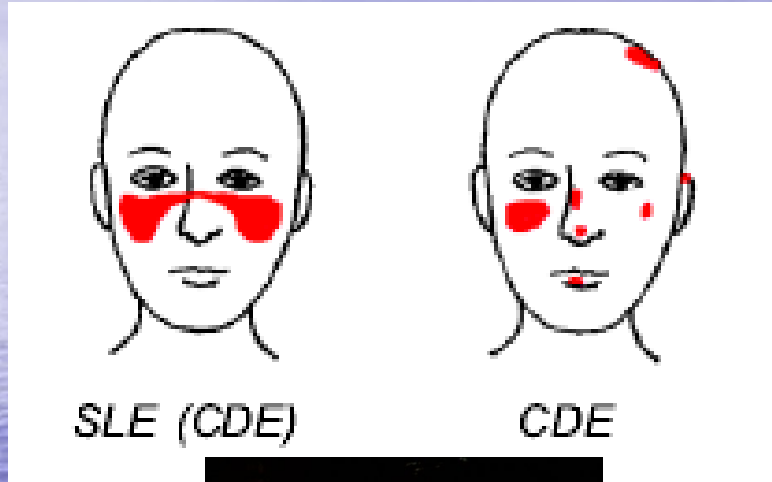
Scabies



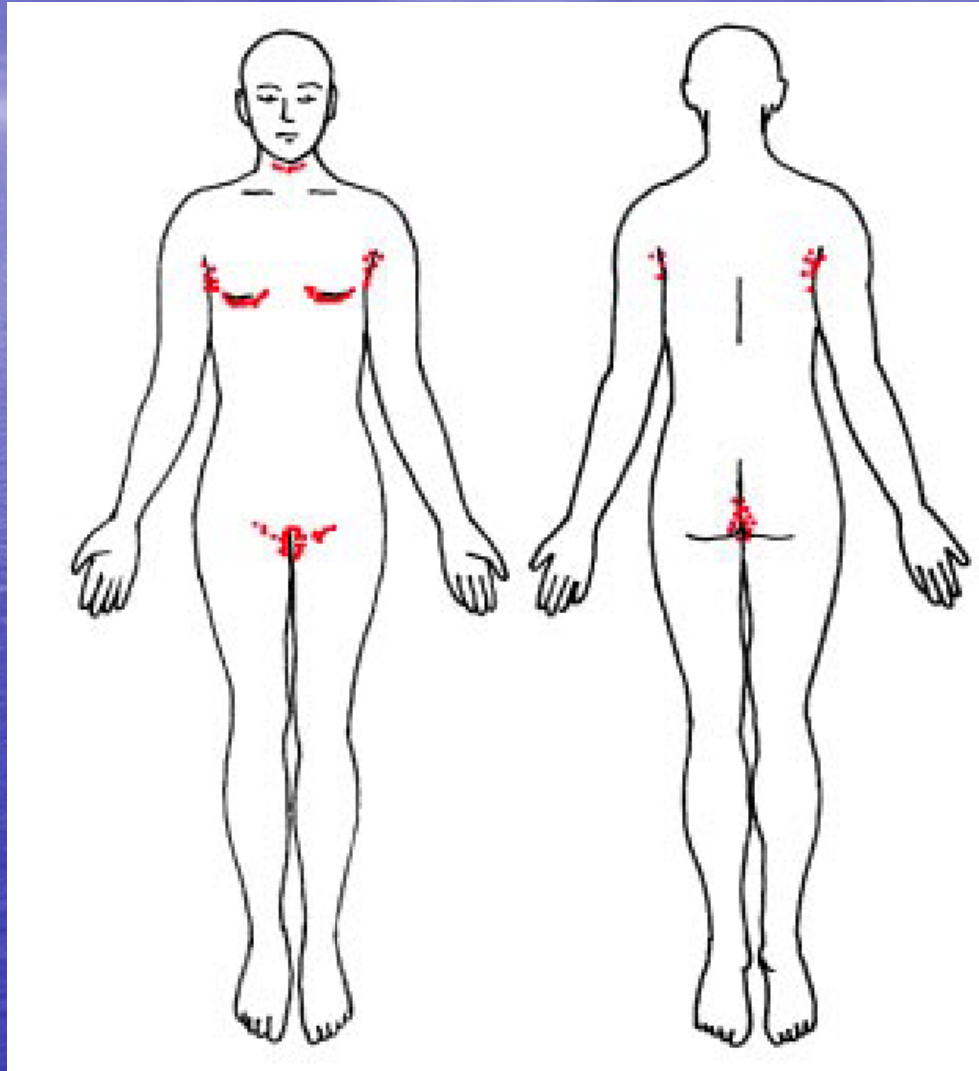
Drug eruptions



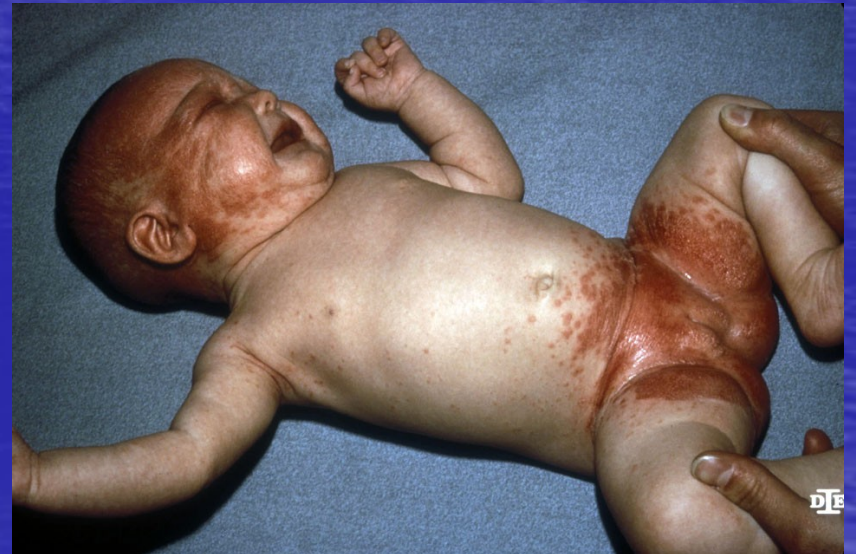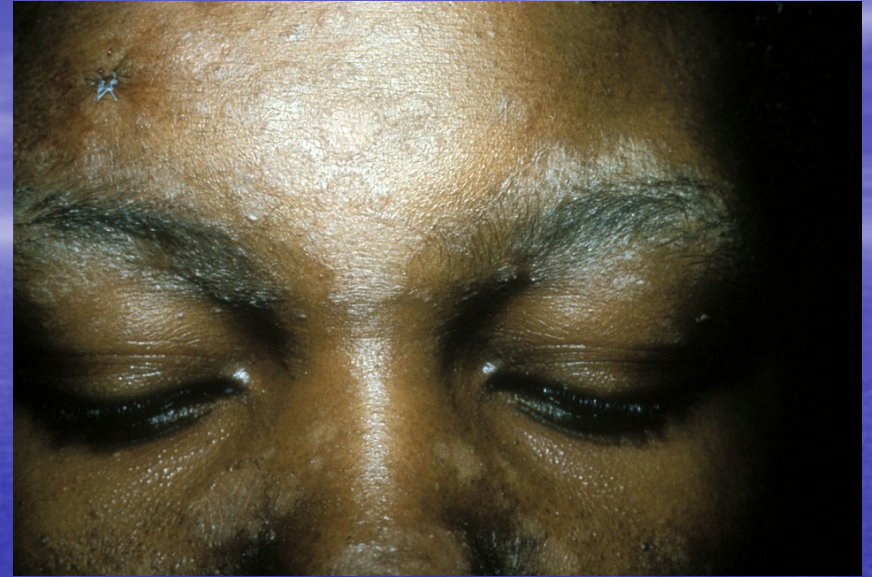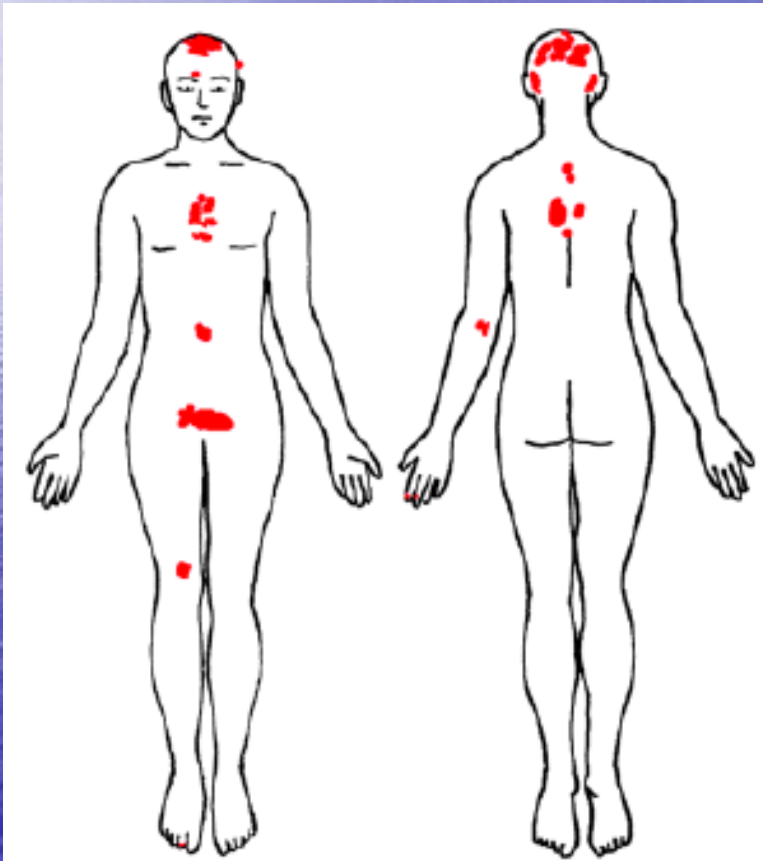
Photosensitive



Intertrigineous



Seborrhoeic



Ulcers

