

Fungal skin infections



M. Nečas, H. Charvátová
I. dermatovenerologická klinika
FN u sv. Anny, LF MU Brno

Skin infection

- Bacterial

- **Fungal**

- Viral

Fungi imperfecti

- Dermatophytes
- Yeasts /candida, cryptococcus/
- Dimorphic fungi (deep fungal inf.)
- Opportunistic fungi (aspergillus aj.)

Fungi - mycetes

- 100 thousand of species, ubiquitous
- Aerobic organisms
- Do not manufacture chlorophyll

classes: Zygomycetes

Ascomycetes

Basidiomycetes

Deuteromycetes (fungi imperfecti)

(pathogenic for human)

nomenclature

- Mycosis = any fungal infection,
incl. Yeast, deep mycosis

>

- Tinea = dermatophytoses

>

- Trichofytia, epidermophytia, microsporia

I. Dermatophytoses

- Antropophilic: *T. rubrum*, *T. interdigitale*

fungi *T. tonsurans*, *T. schoenleinii*

Microsporon audouinii

Epidermphyton floccosum

- Zoophilic : *T. verrucosum*, mentagrophytes, equinum

Microsporon canis, *persicolor*, *nanum*

- Geophilic: *T. ajelloi*, *terrestre*

Microsporon gypseum

Tinea pedis

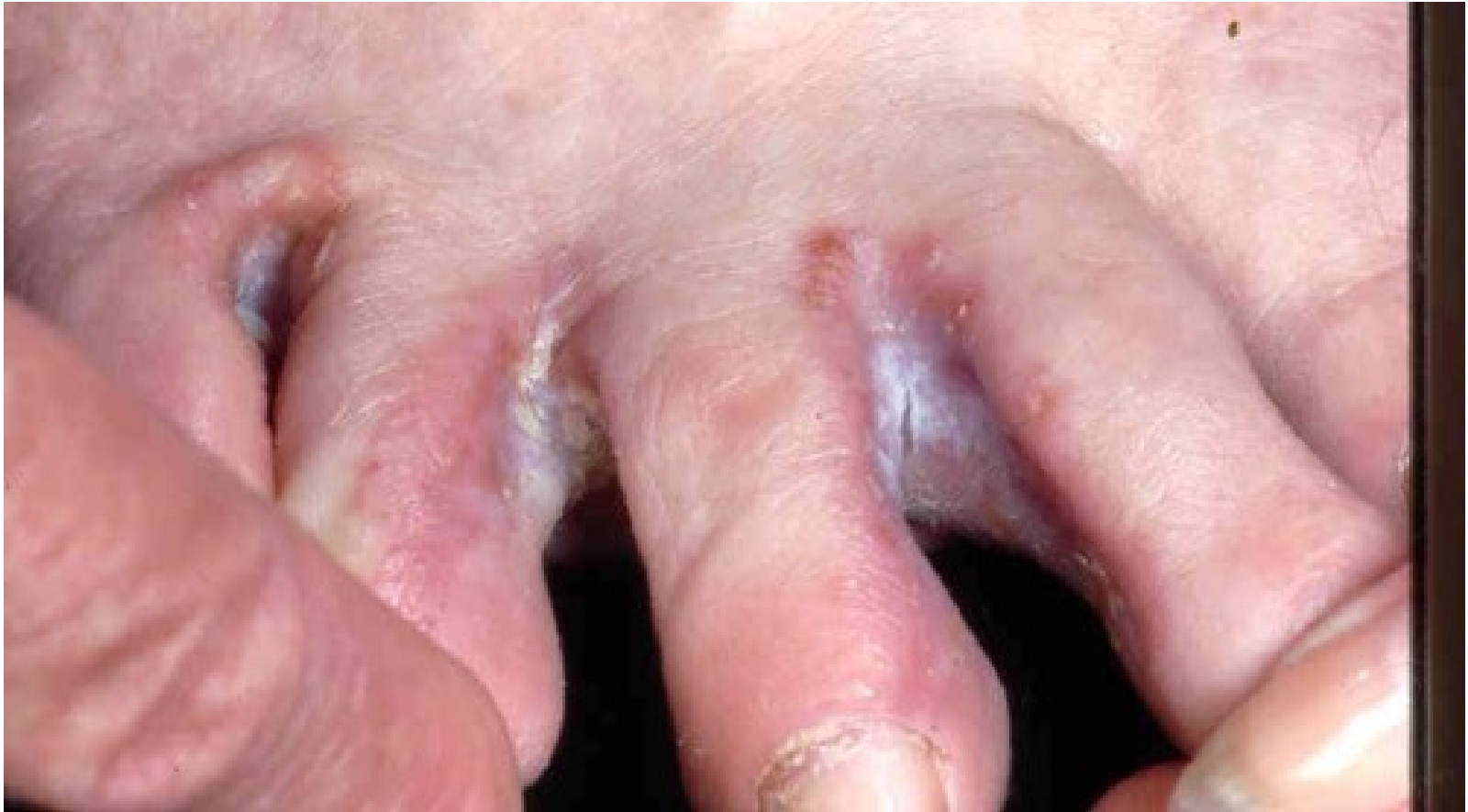- C. agens: *Trichophyton rubrum*

- clinical variants : interdigital

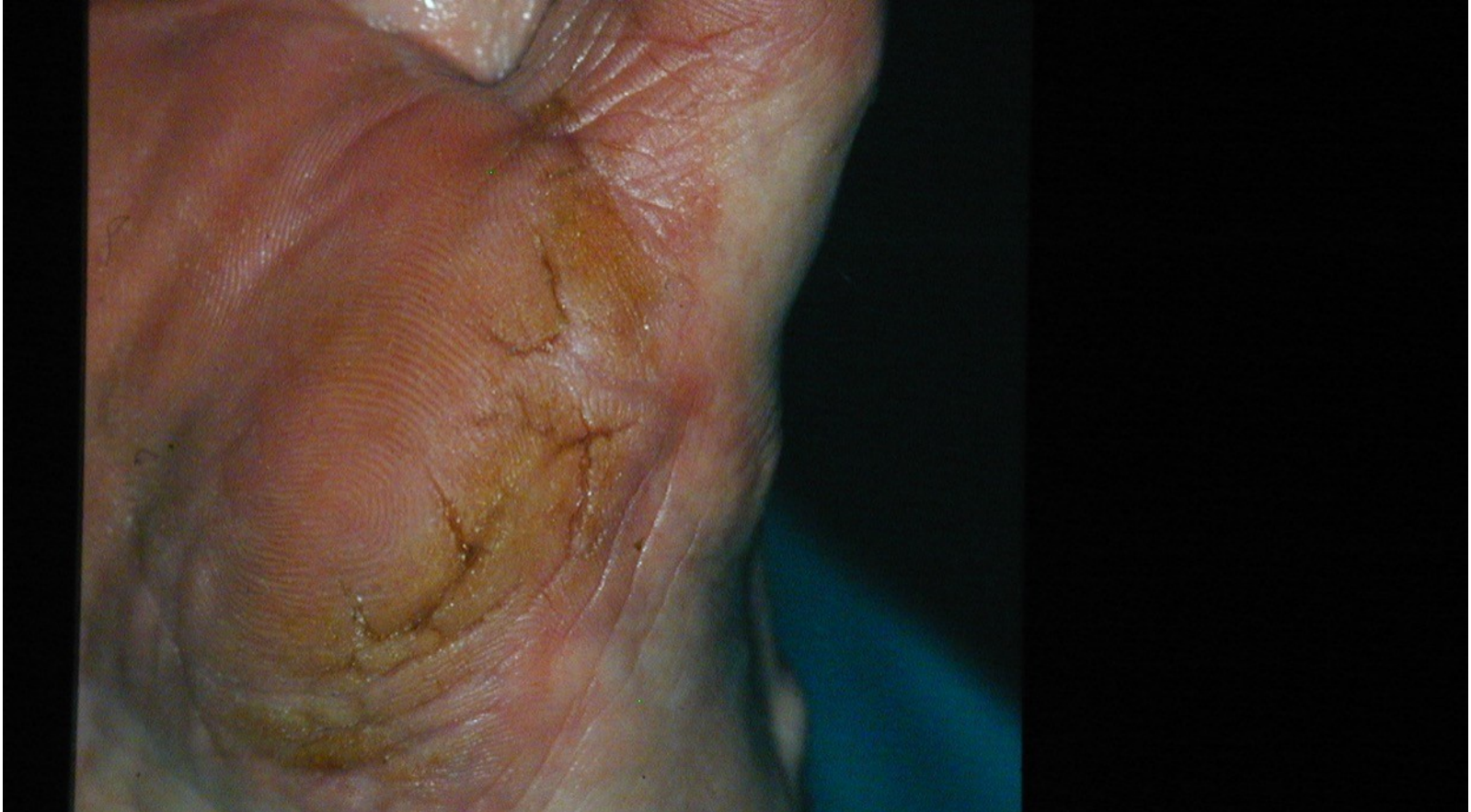hyperkeratotic

dyshidrotic

interdigital tinea



hyperkeratotic tinea



Tinea unguium-onychomycosis

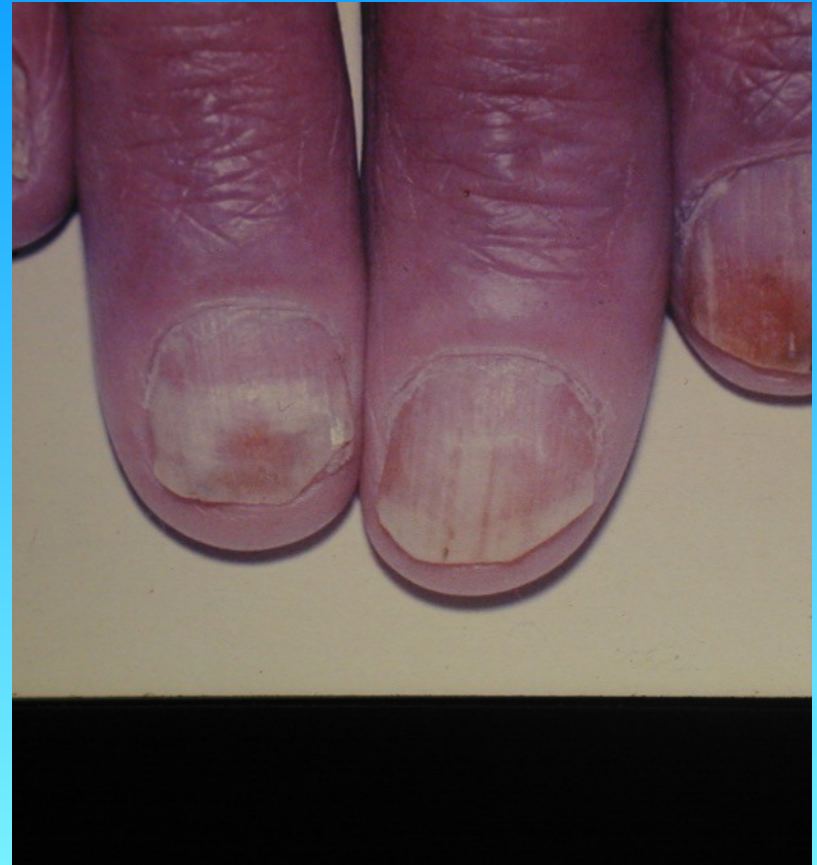- C.agens:

T. rubrum

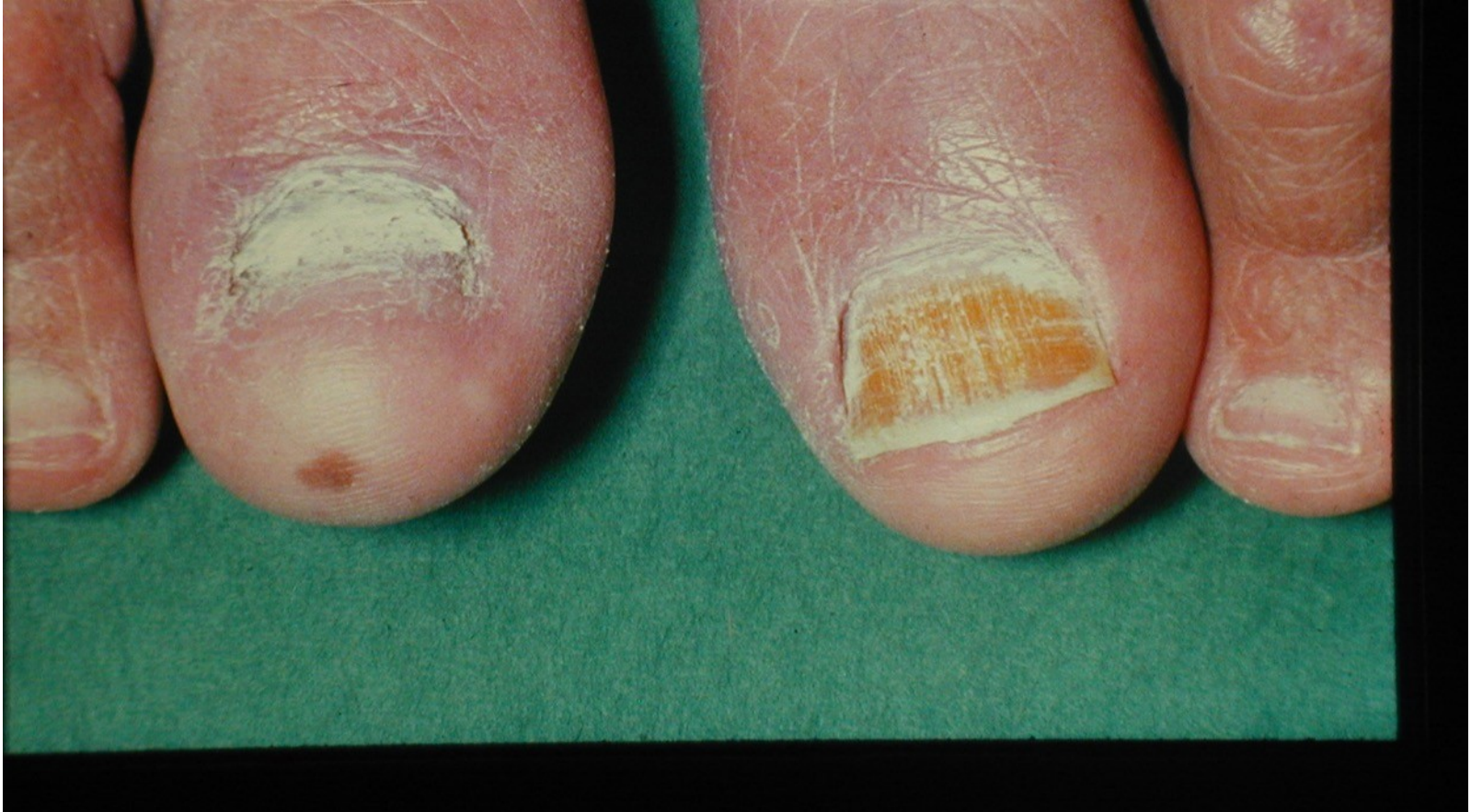T. interdigitale

Epidermophyton

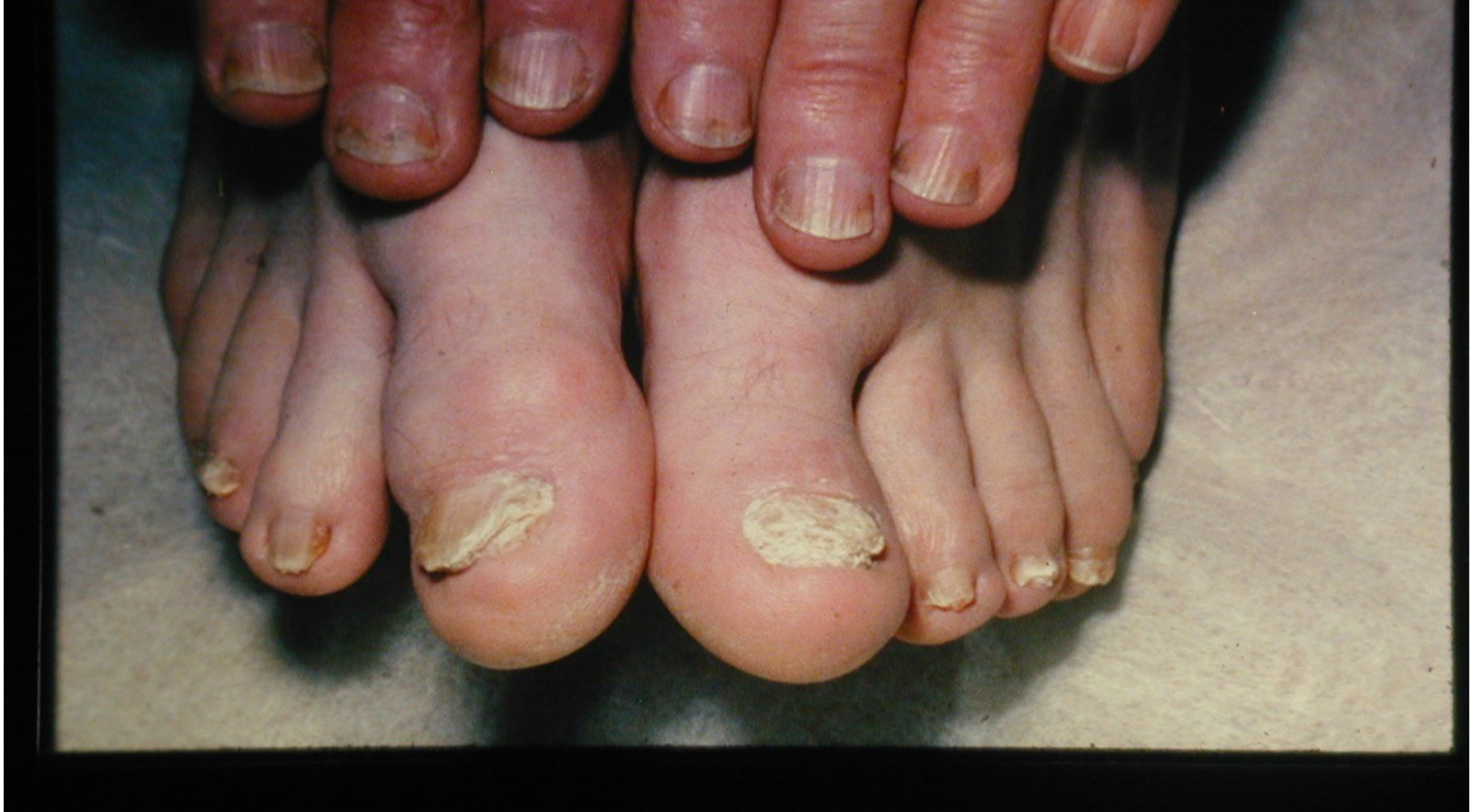floccosum



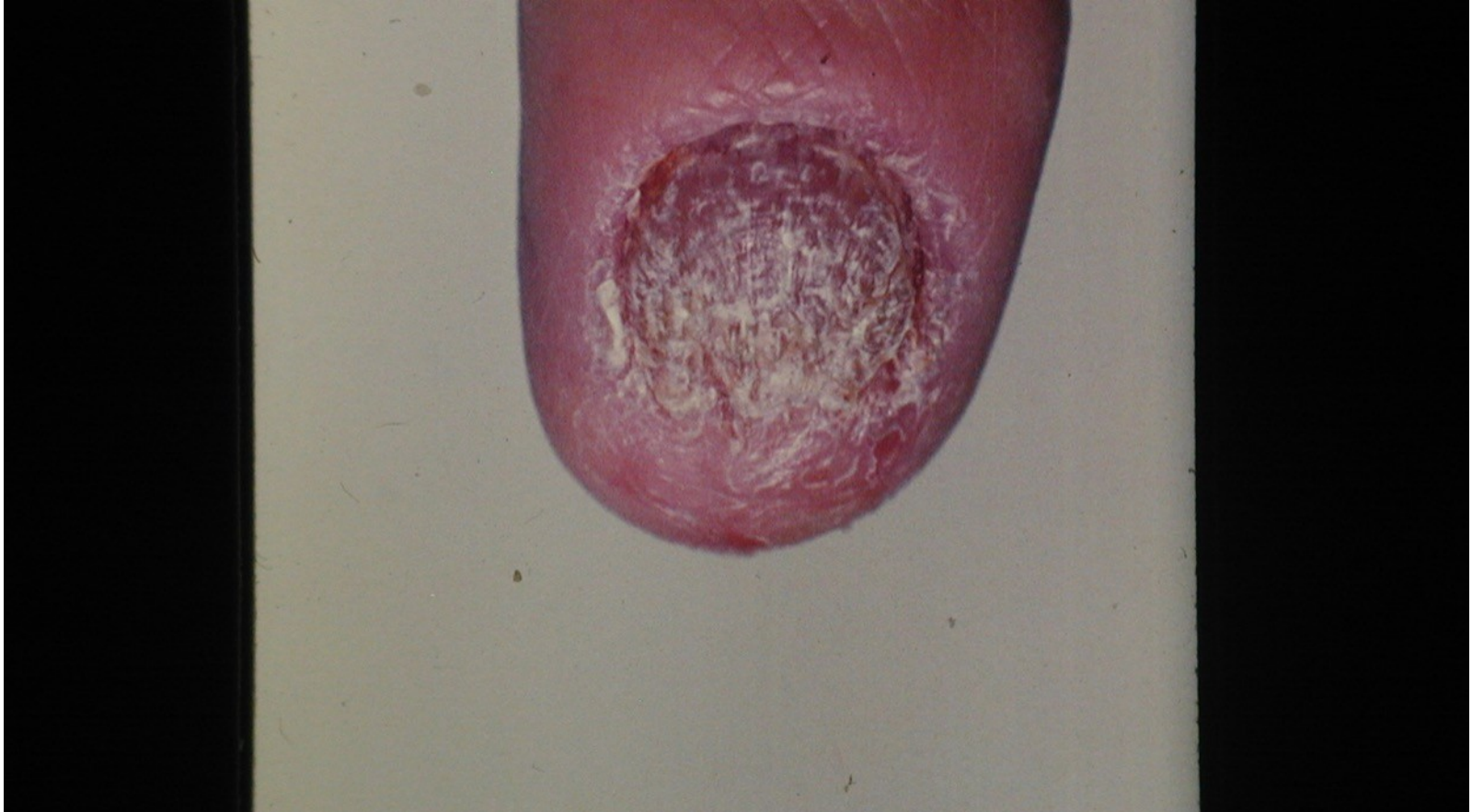Tinea unguium-onychomycosis



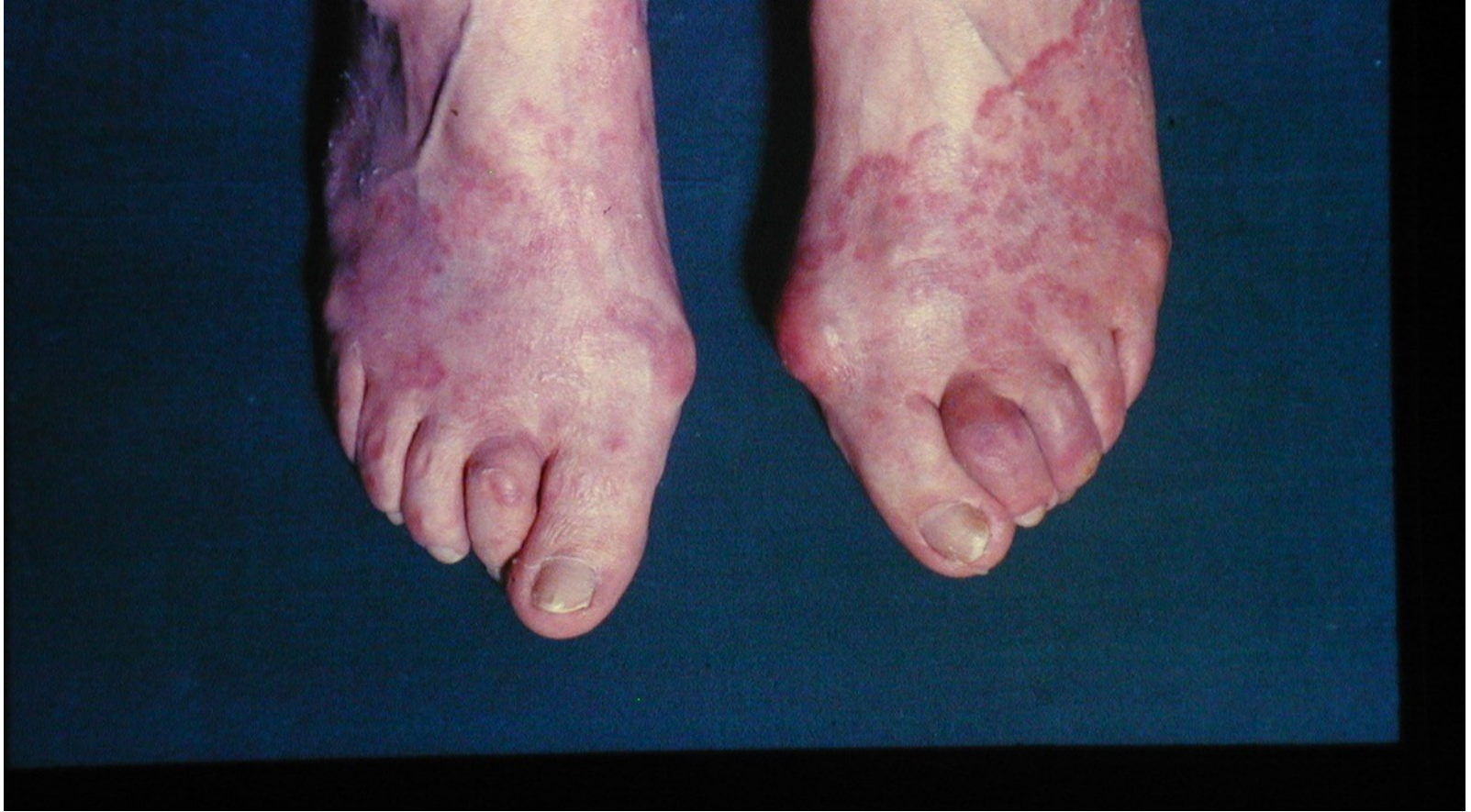Tinea unguium-onychomycosis



Tinea unguium-onychomycosis

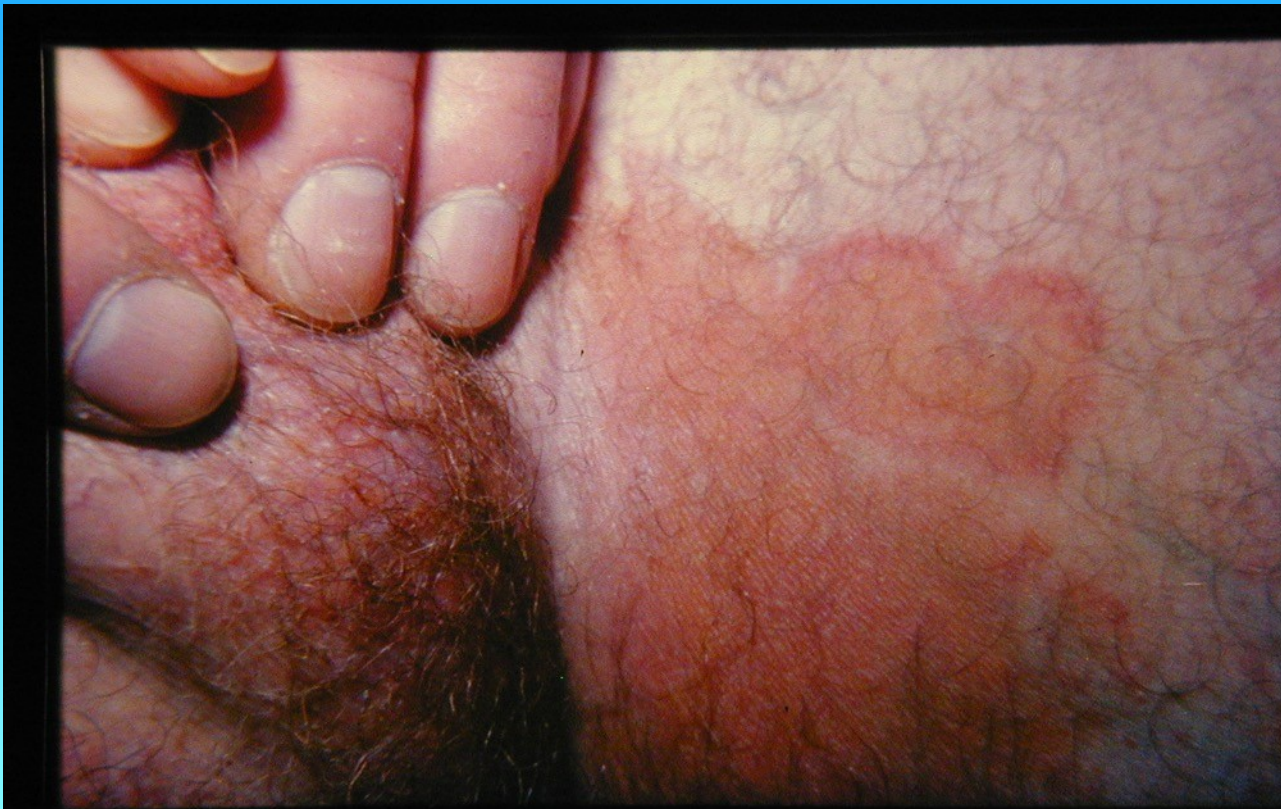

Tinea unguium-onychomycosis

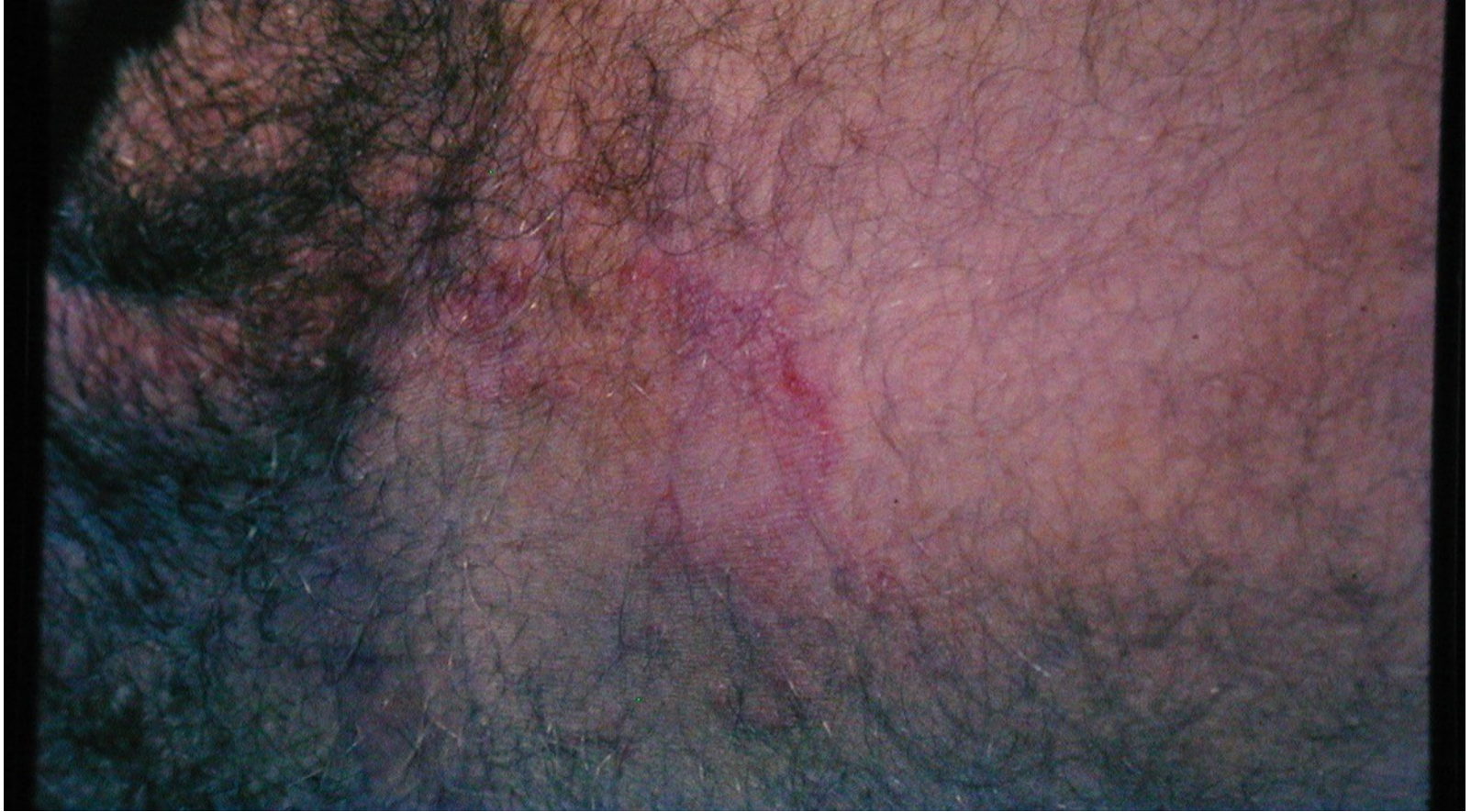

Tinea inguinalis

- C. agens: *E. floccosum*, *T. rubrum*, *T. interdigitale*



Tinea inguinalis



Tinea manum

- etiol: T. rubrum

T. interdigitale

E. floccosum



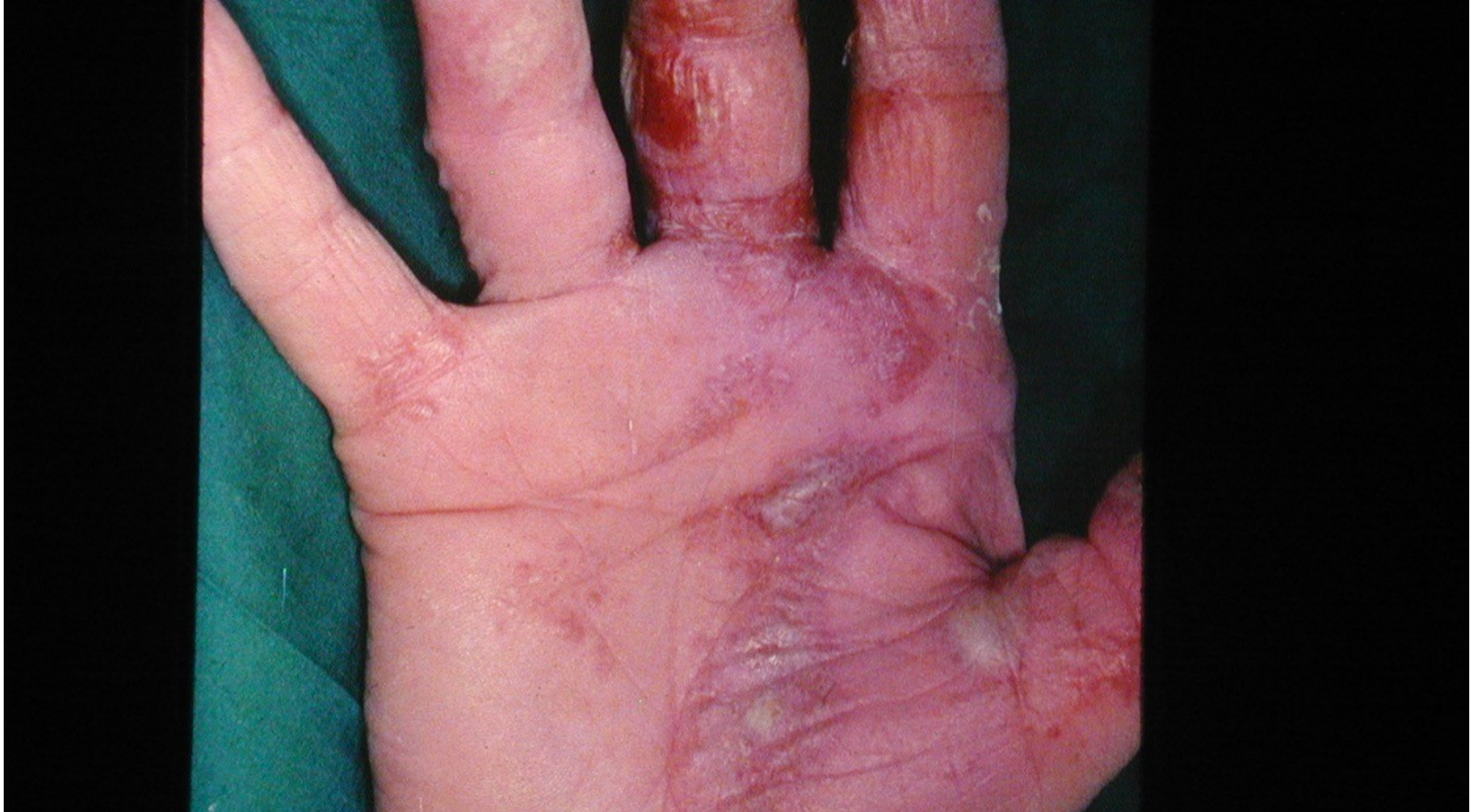T. verrucosum

- forms: hyperkeratotic

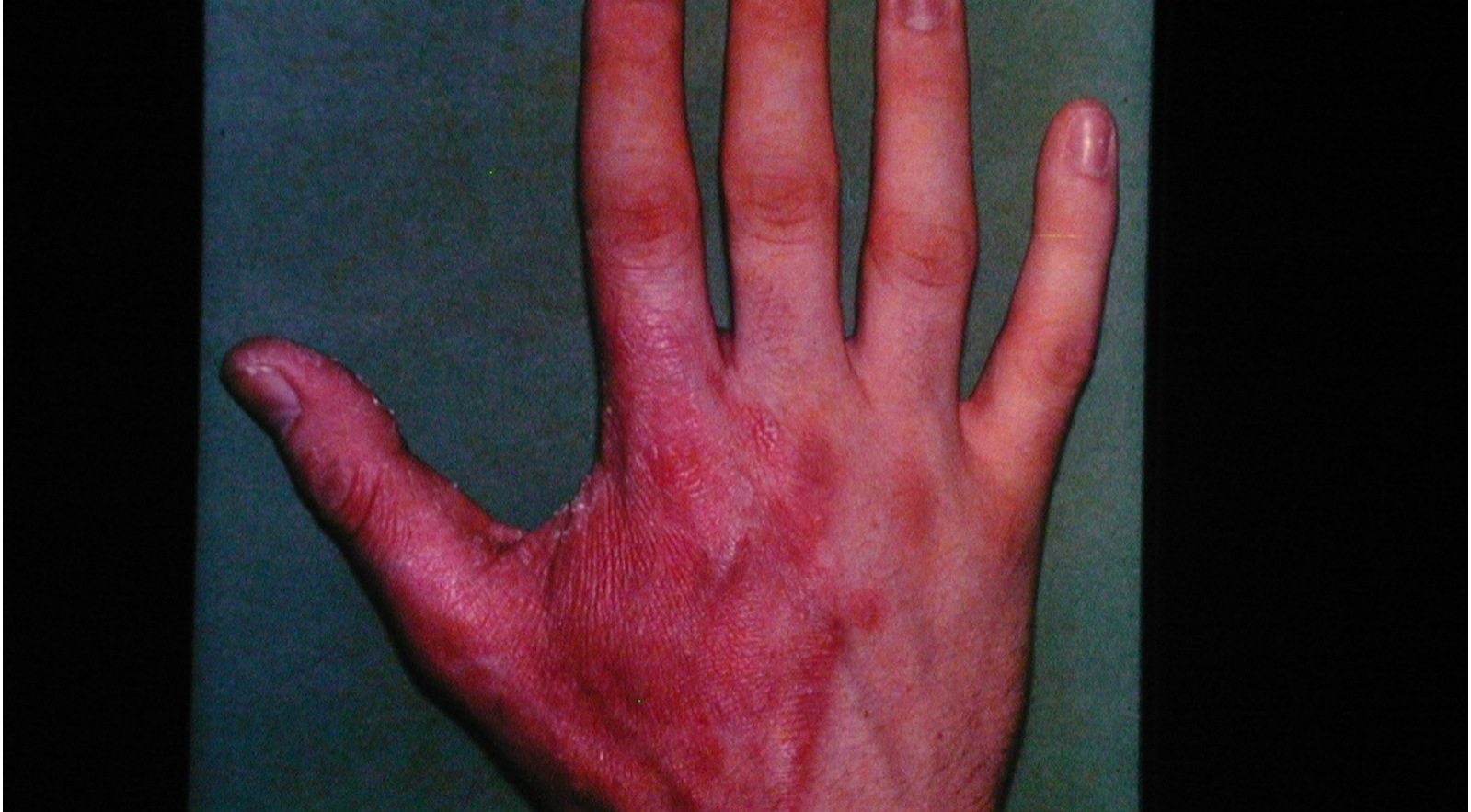dyshidrotic

erythemosquamous

Tinea manum-dyshidrotic form



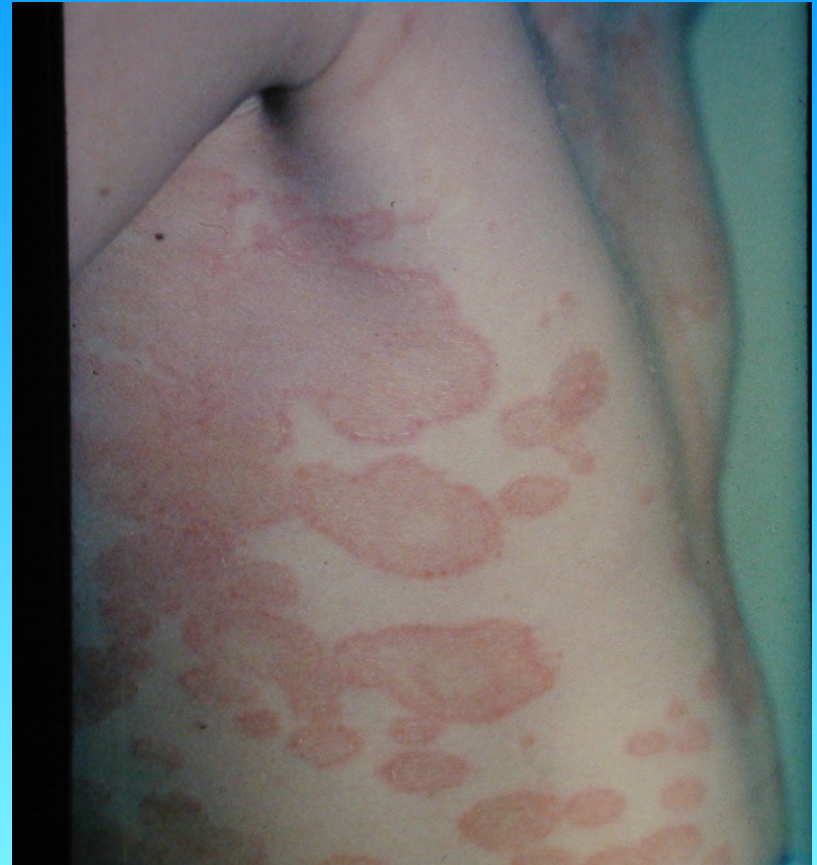Tinea manum erythemosquamous form



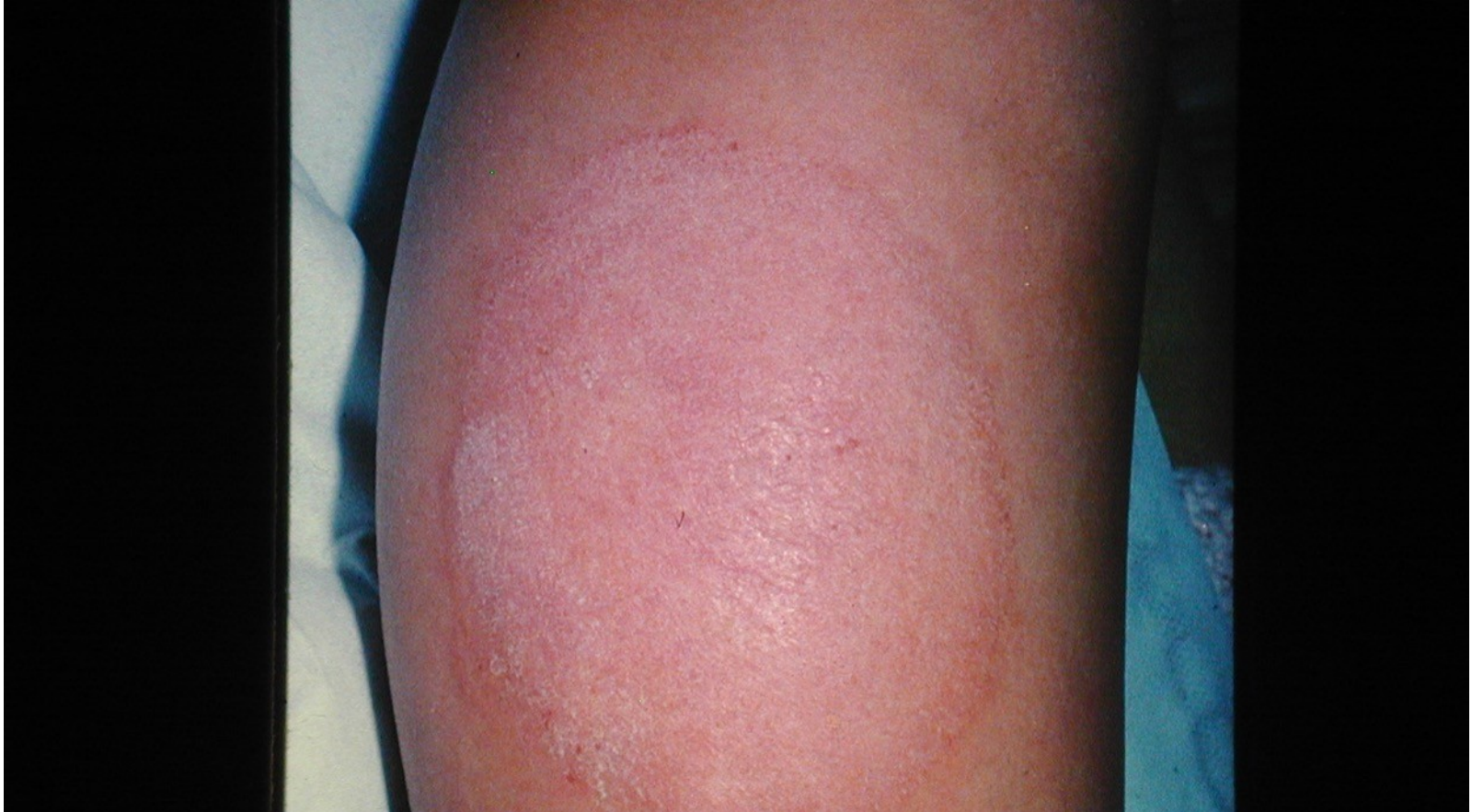Tinea corporis

- *T. verrucosum*
- *T. mentagrophytes*
- *M. canis*

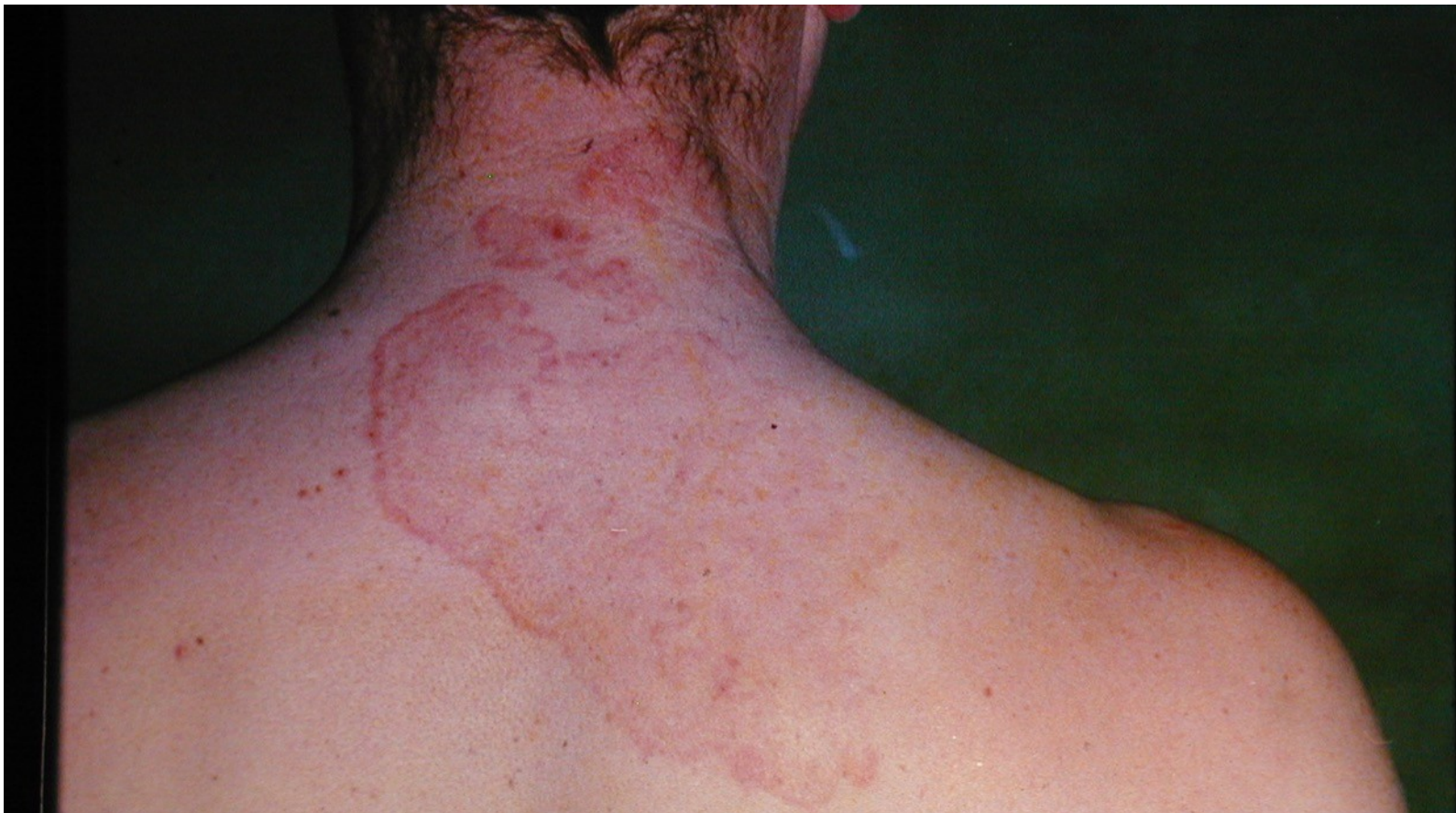- *T. rubrum*
- *E. floccosum*



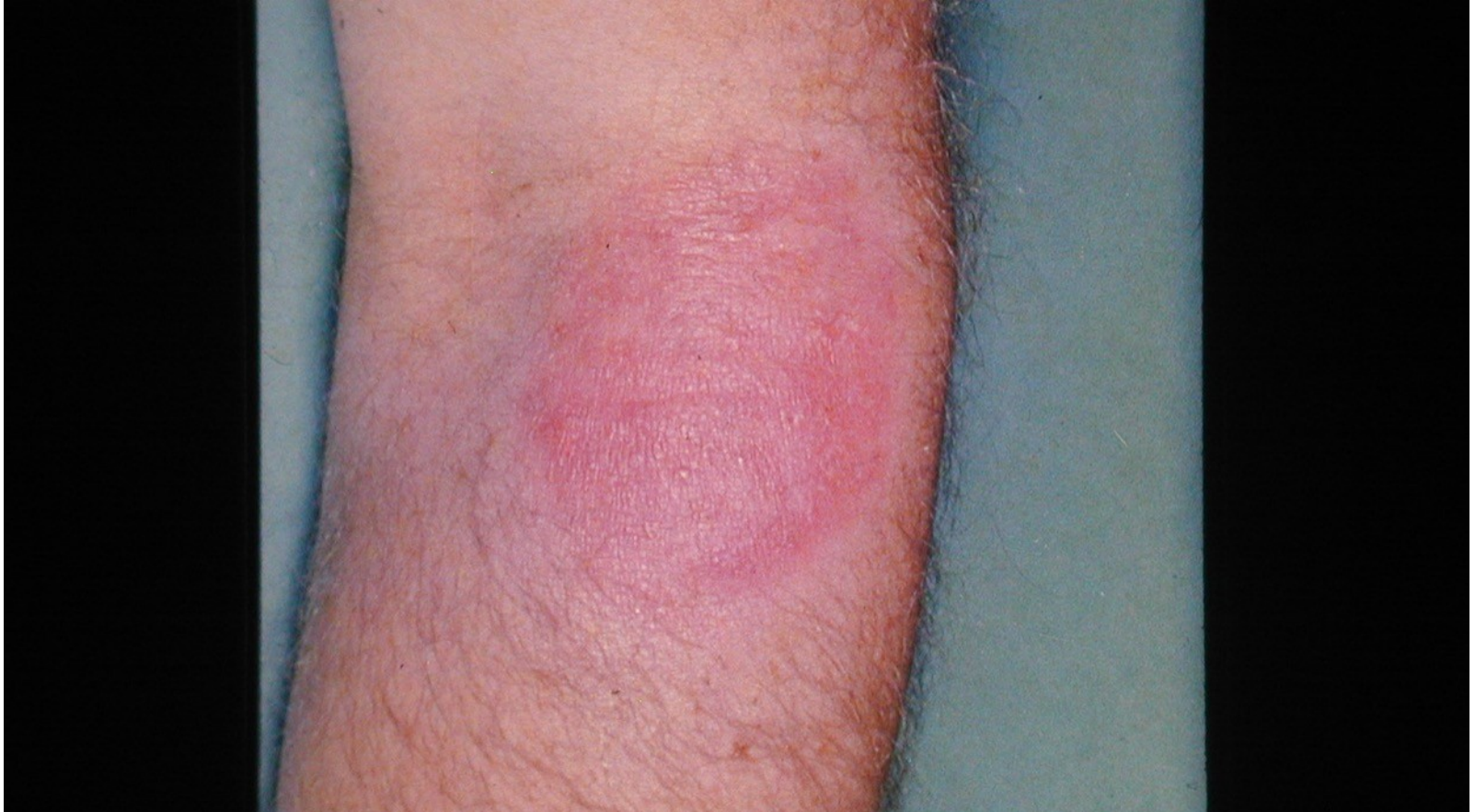Tinea corporis -superficial



Tinea corporis - erythemosquamous

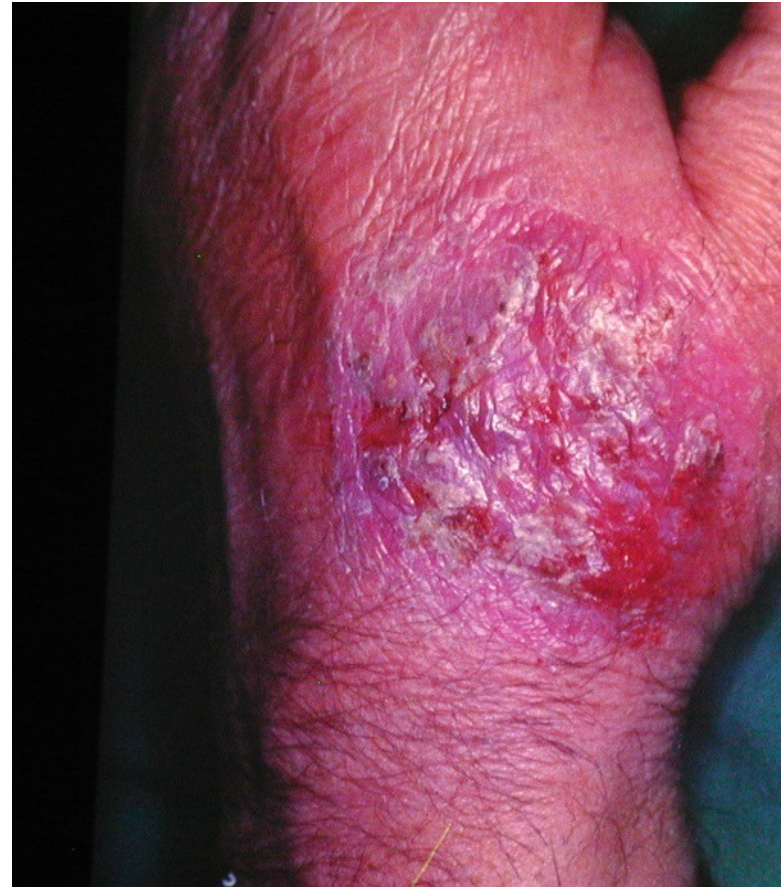

Tinea corporis erythemovesiculous



Tinea corporis - deep

- *T. verrucosum*
- *T. mentagrophytes*



Tinea faciei

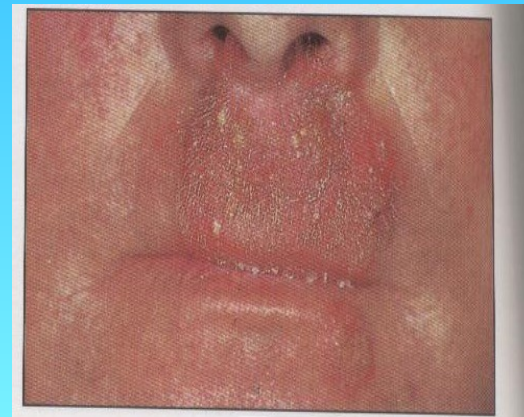
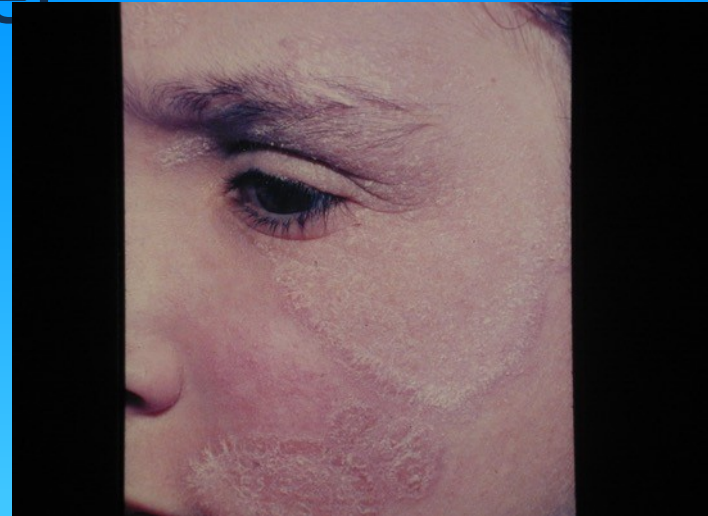- M. canis
- T. verrucosum
- T. mentagrophytes

Ddg: atop. dermatitis

seborrhoic

dermatitis

CDE



Tinea capitis

- C.agens: Trichophyton (ecto/endothrix)

growth along the hair

Microsporon (ectothrix)

invasion of the hair

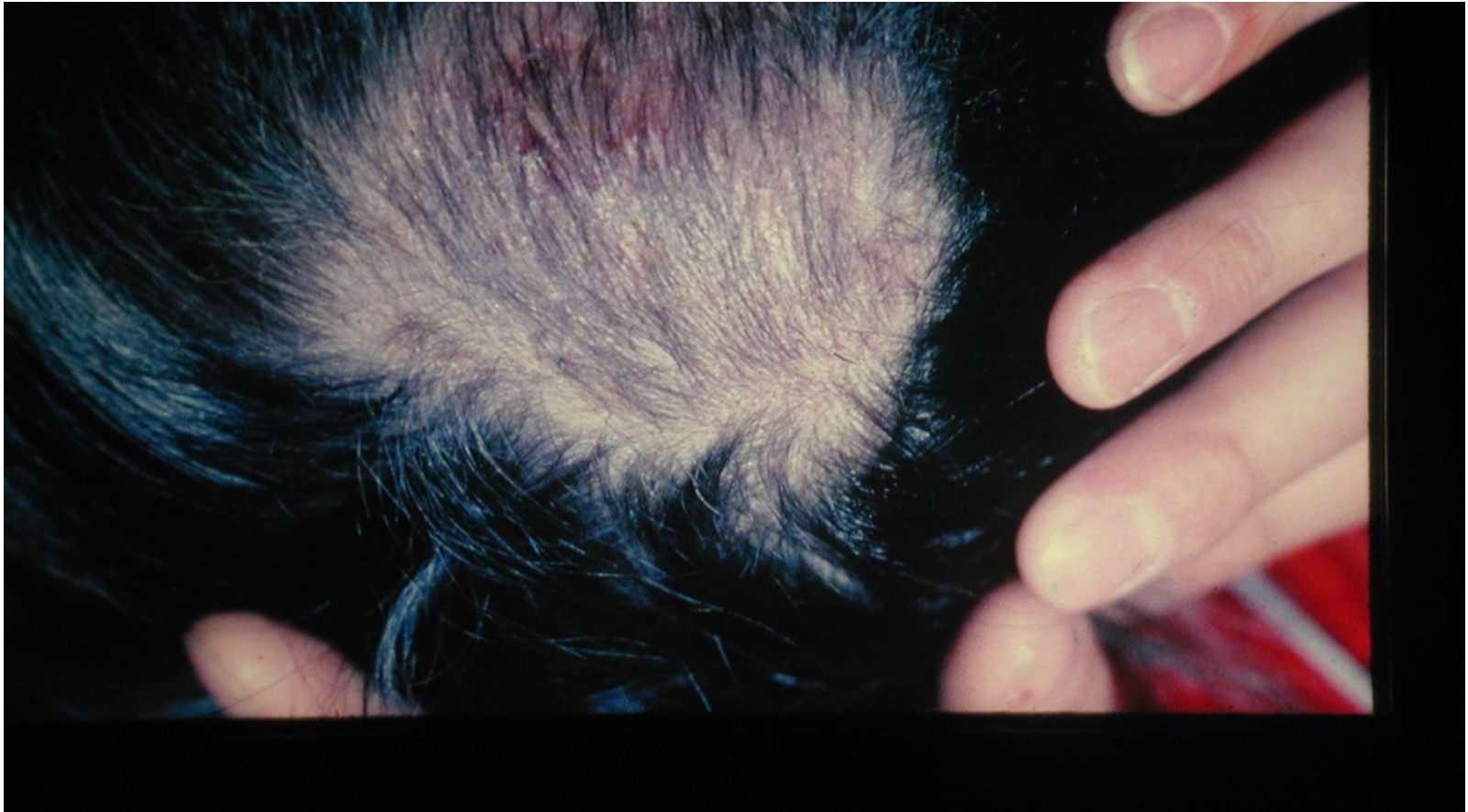- clinical variants: superficial

(non-inflammatory)

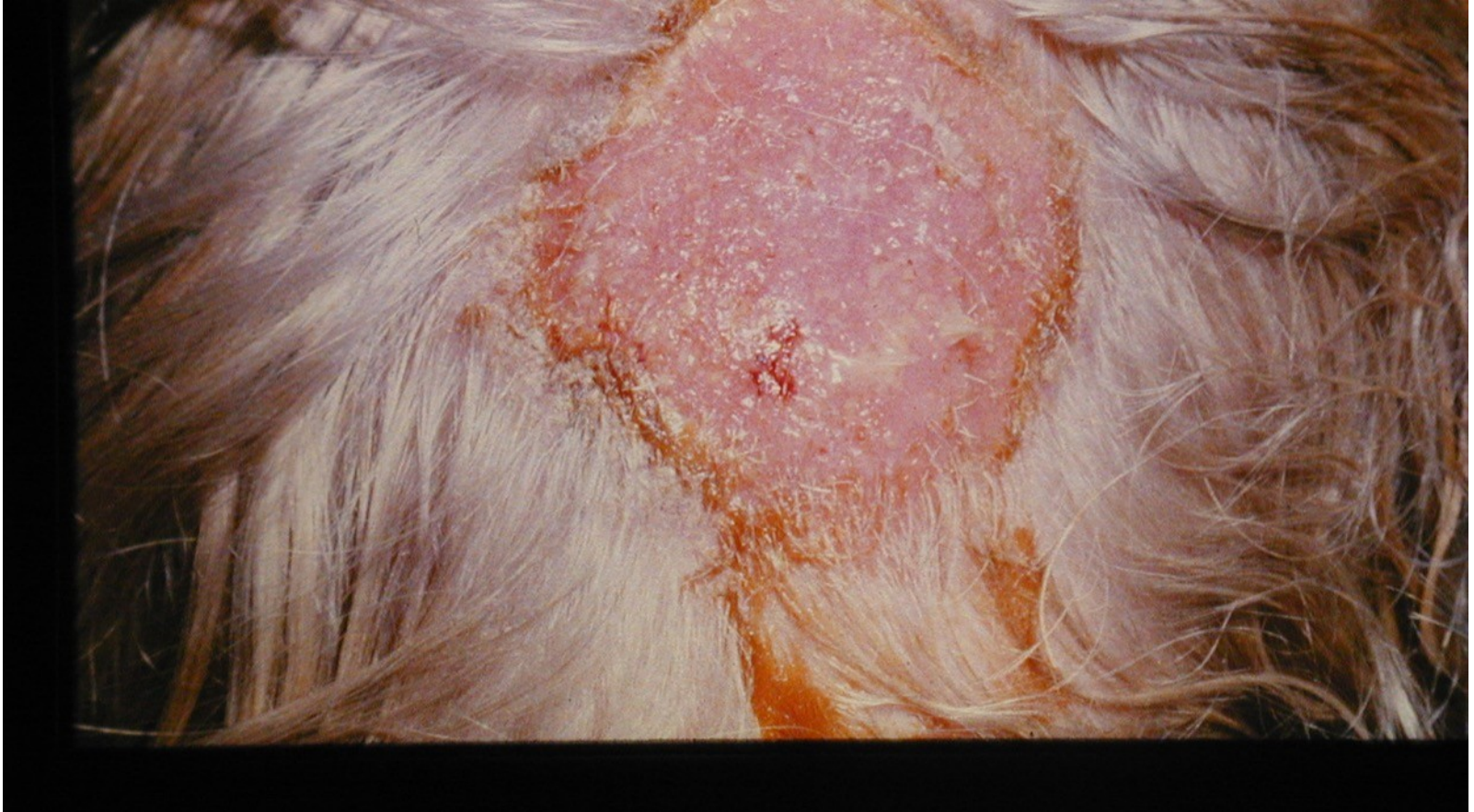
deep (inflammatory) - Kerion Celsi

favus

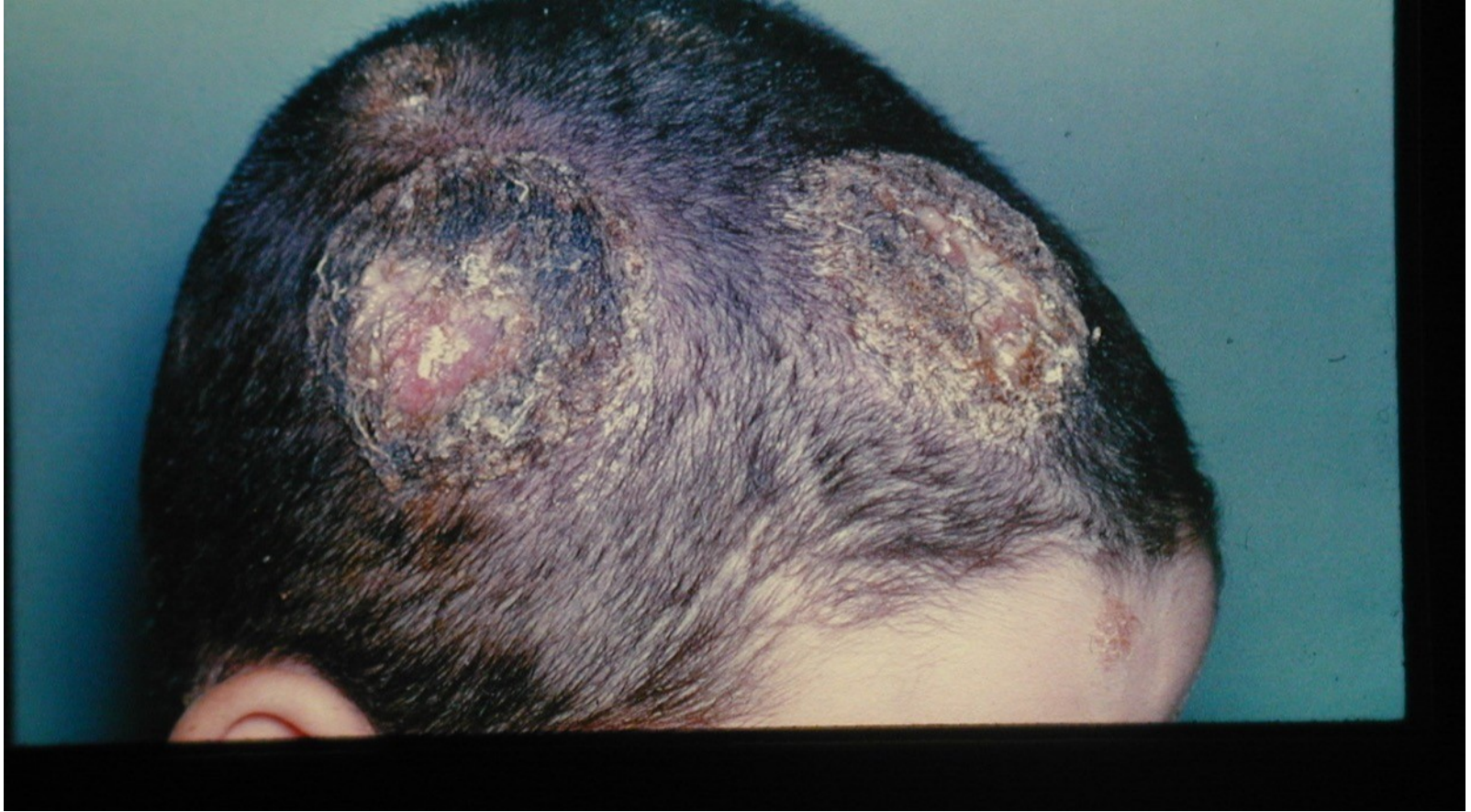Tinea capitis - superficial



Tinea capitis - deep



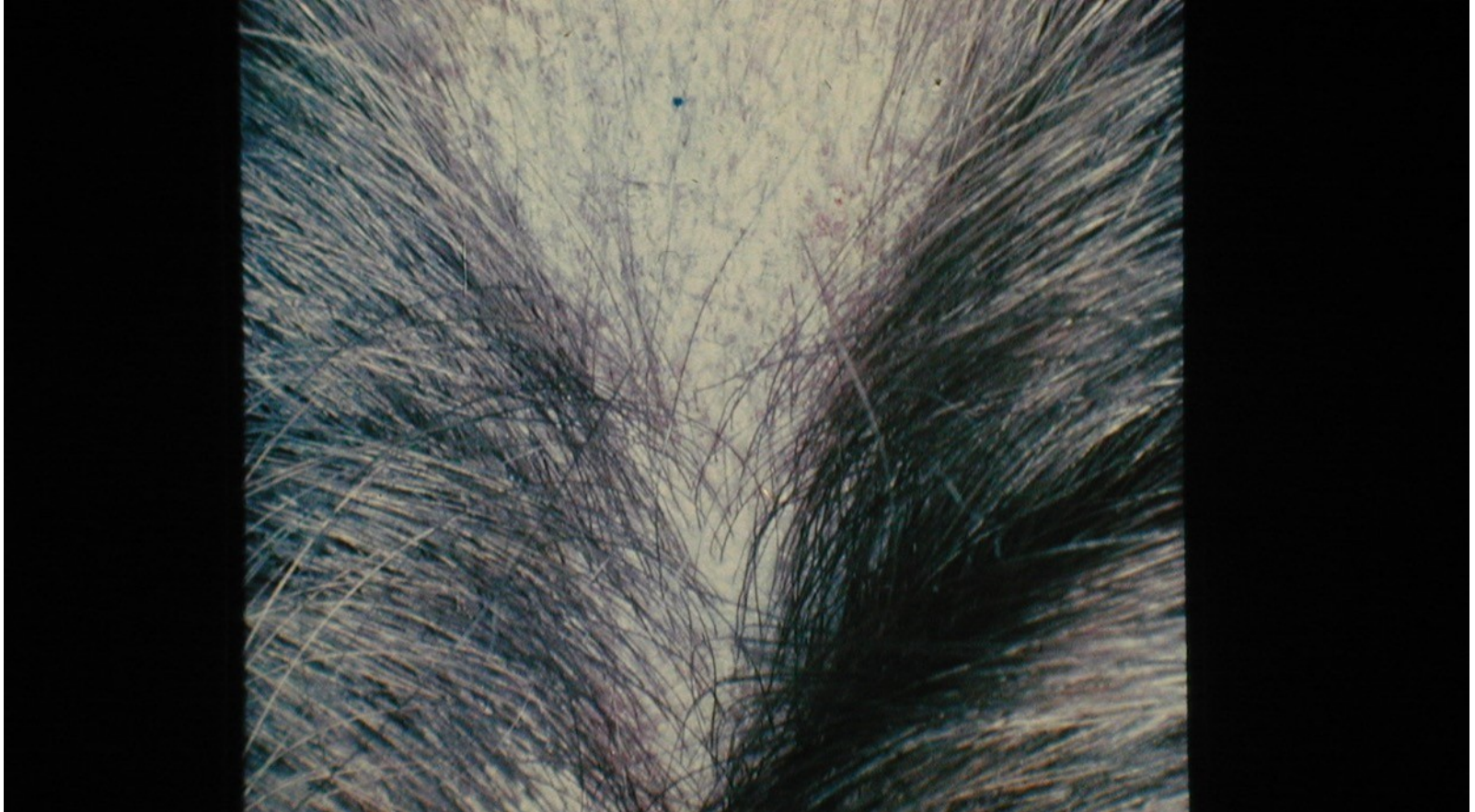Tinea capitis - deep



Tinea capitis - favus

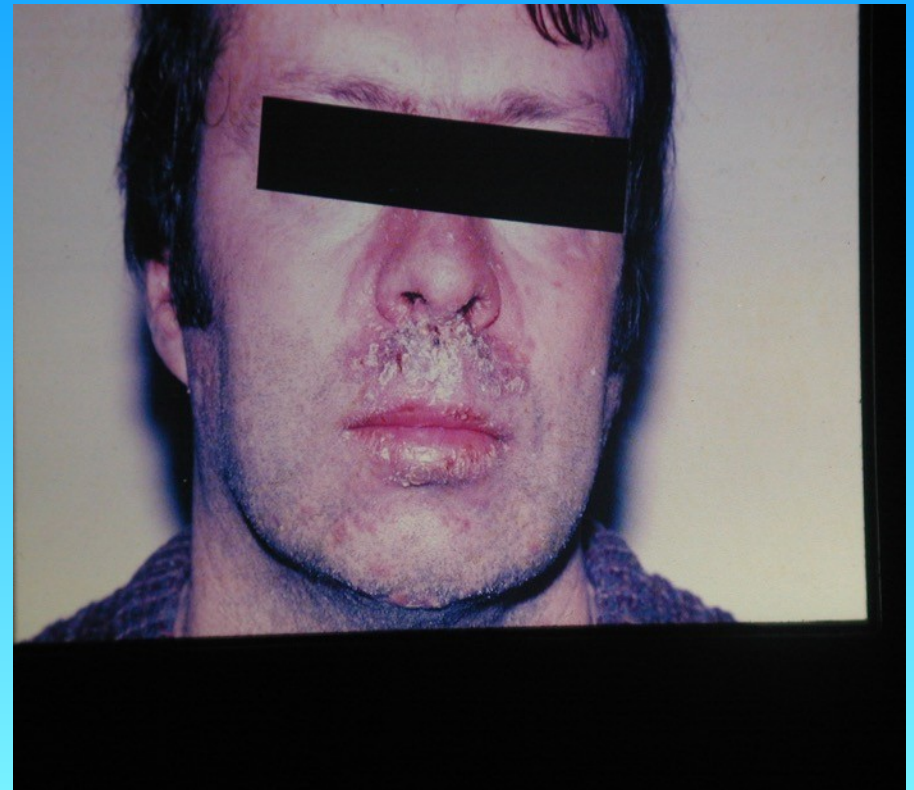- C.agens: Trichophyton Schoenleinii
- Most often in children, very rare in W. and C. Europe
- Occurrence in Middle East region
- Scutulum (little shield) – yellowish dish-like crusts
- mixture of hyfi and spores, smells like a mouse urine
- Rarely trunk and nails affected

Tinea capitis - favus



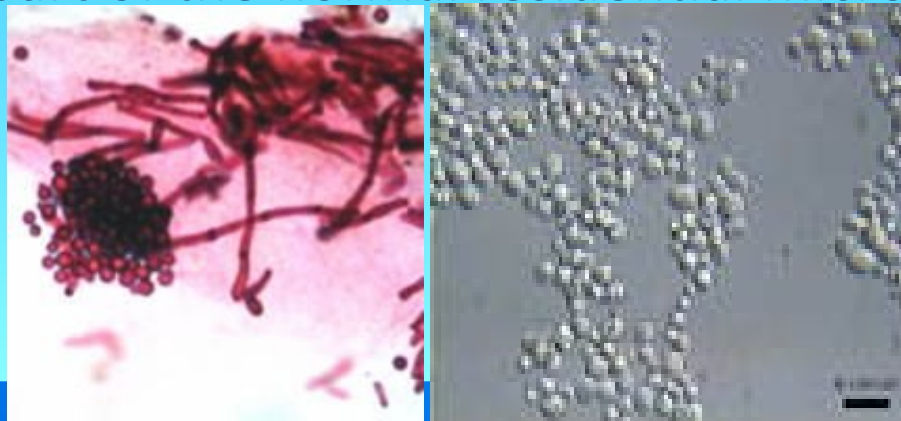
Tinea barbae (sycosis barbae parasitaria)

- C.agens:
 - T. verrucosum
 - M. canis
- Clinical picture:
 - folliculitis,
 - infiltrates, nodules
- Ddg: sycosis barbae
 - nonparasitaria
 - (staphylogenes)

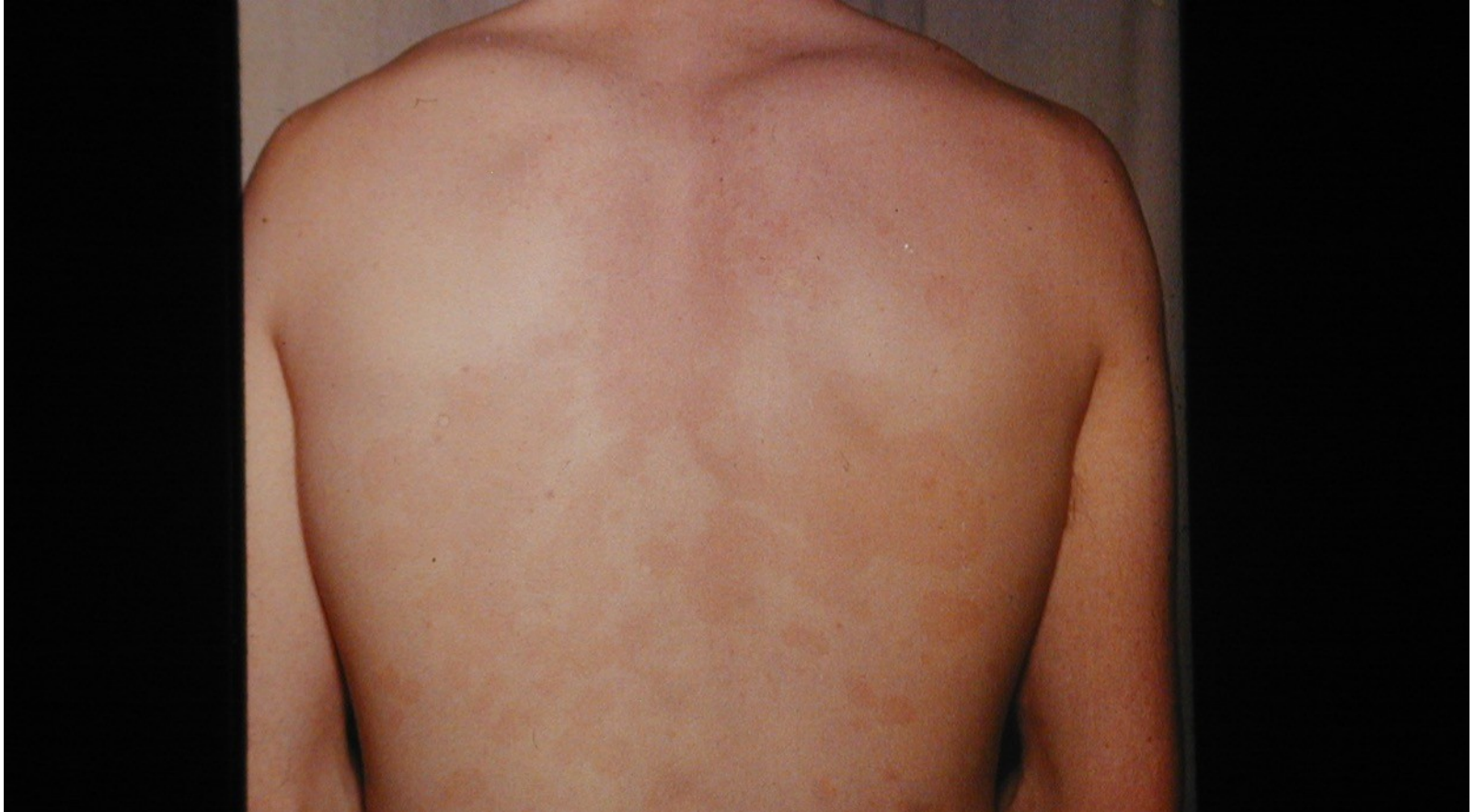

Pityriasis versicolor

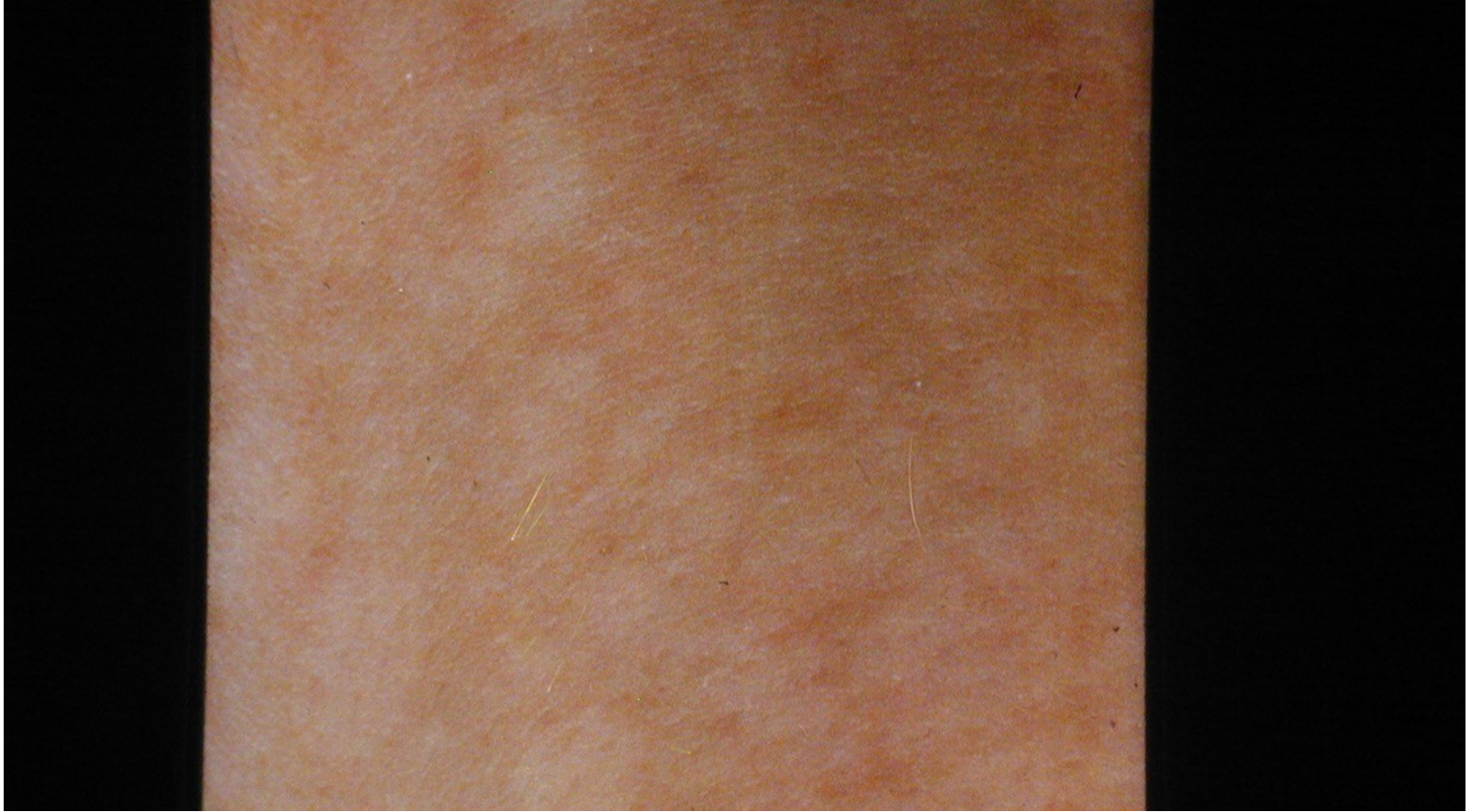- Causative agents – *Malassezia furfur*
- dimorphism of malassezia yeasts: able form both hyfi and round/oval yeasts
- Lipophilic, utilize human lipids
- Component part of the normal residential microflora of the skin



Pityriasis versicolor



Pityriasis versicolor



II. Yeast infections

yeasts: reproduce by budding

Candidosis:

- Candida albicans
- C.non albicans: glabrata

krusei

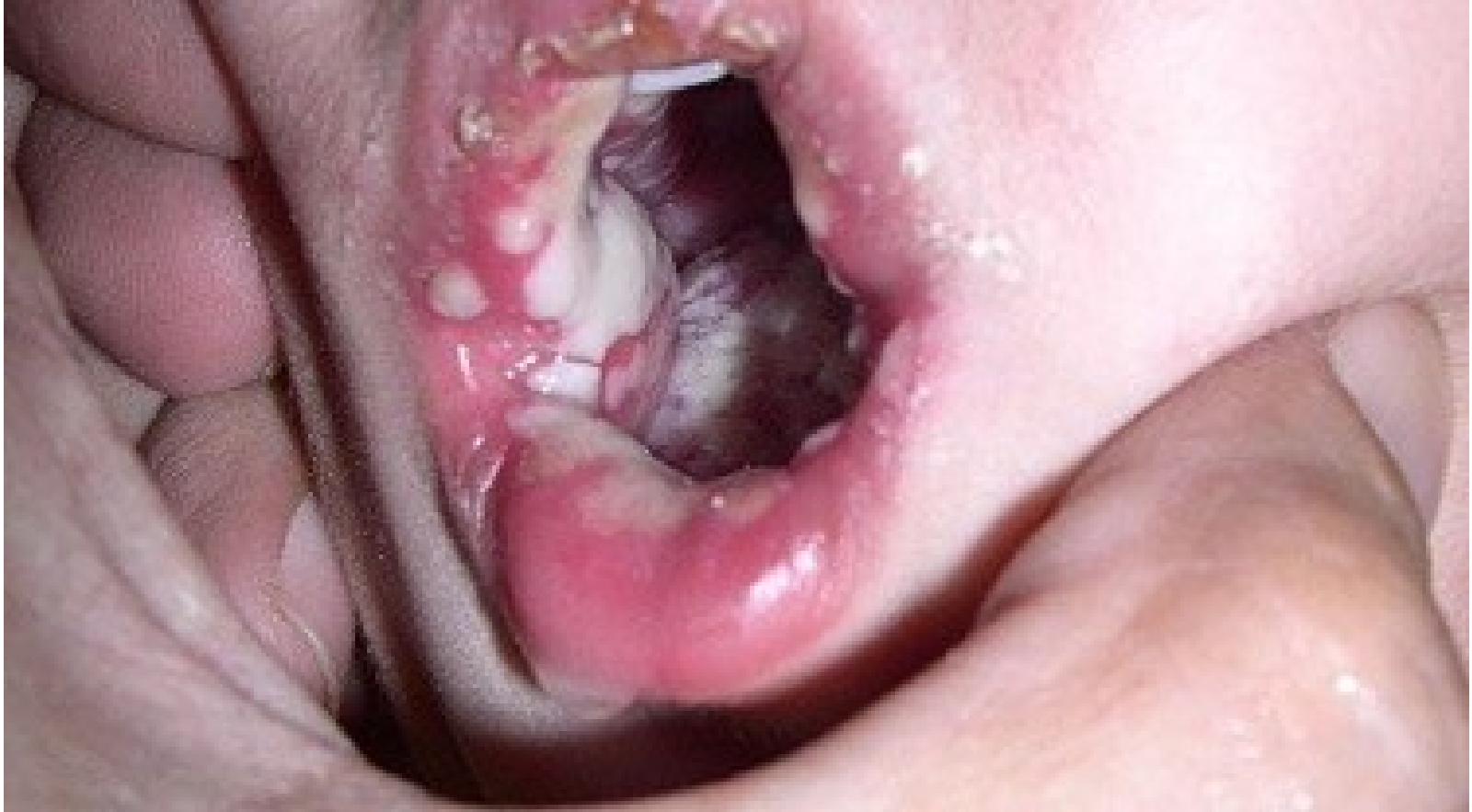kefyr

parapsilosis

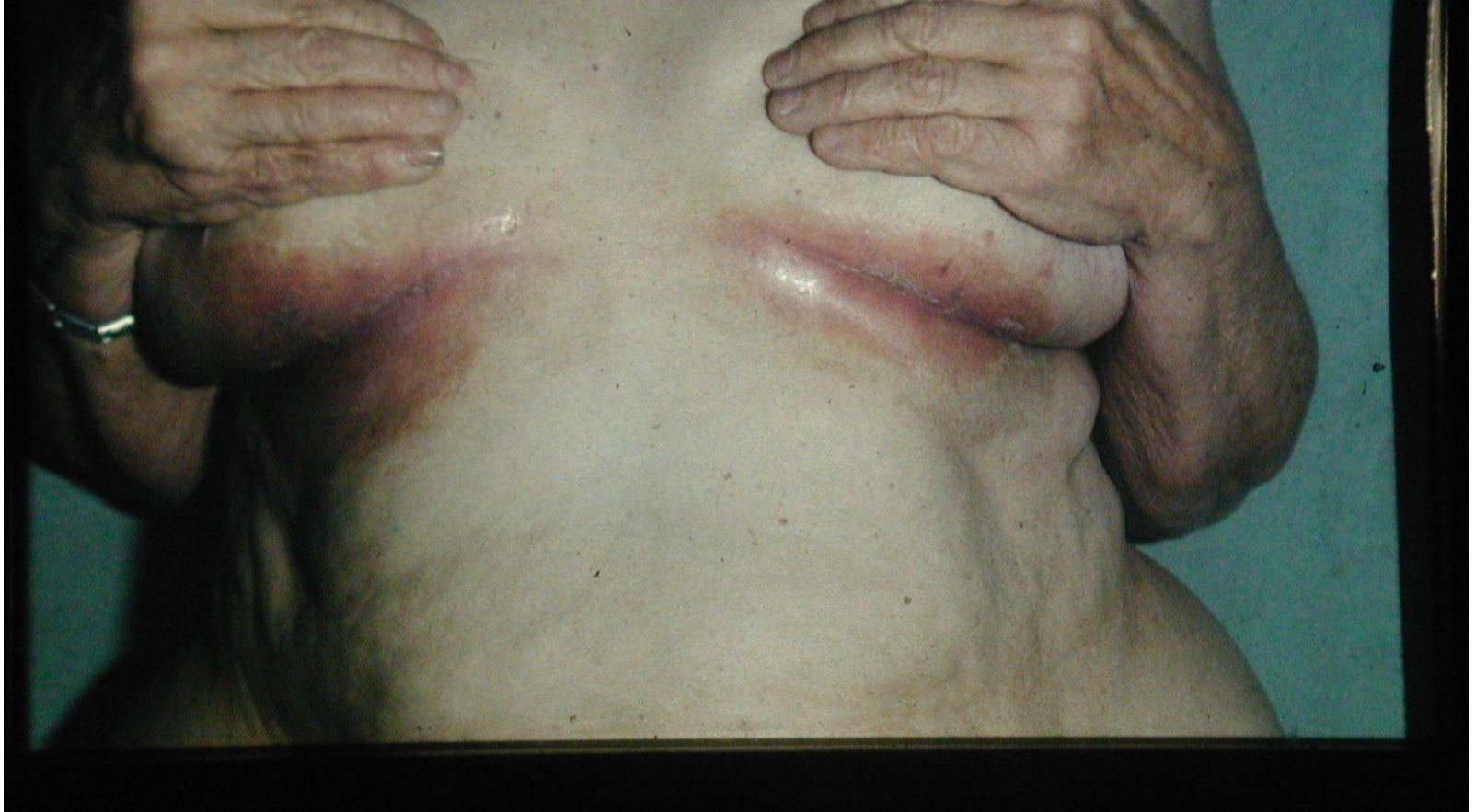tropicalis

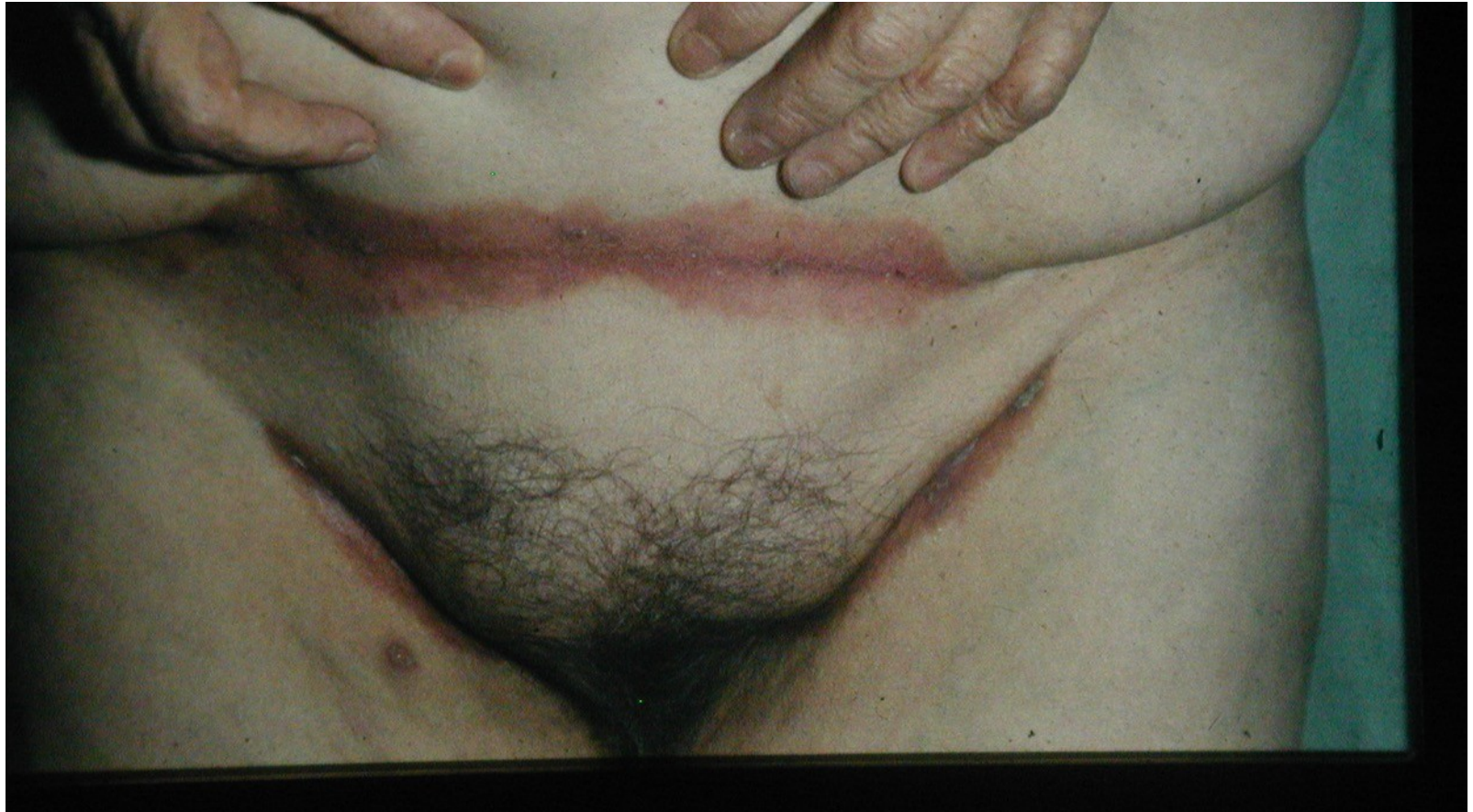Cryptococcosis

1) oral candidosis – soor

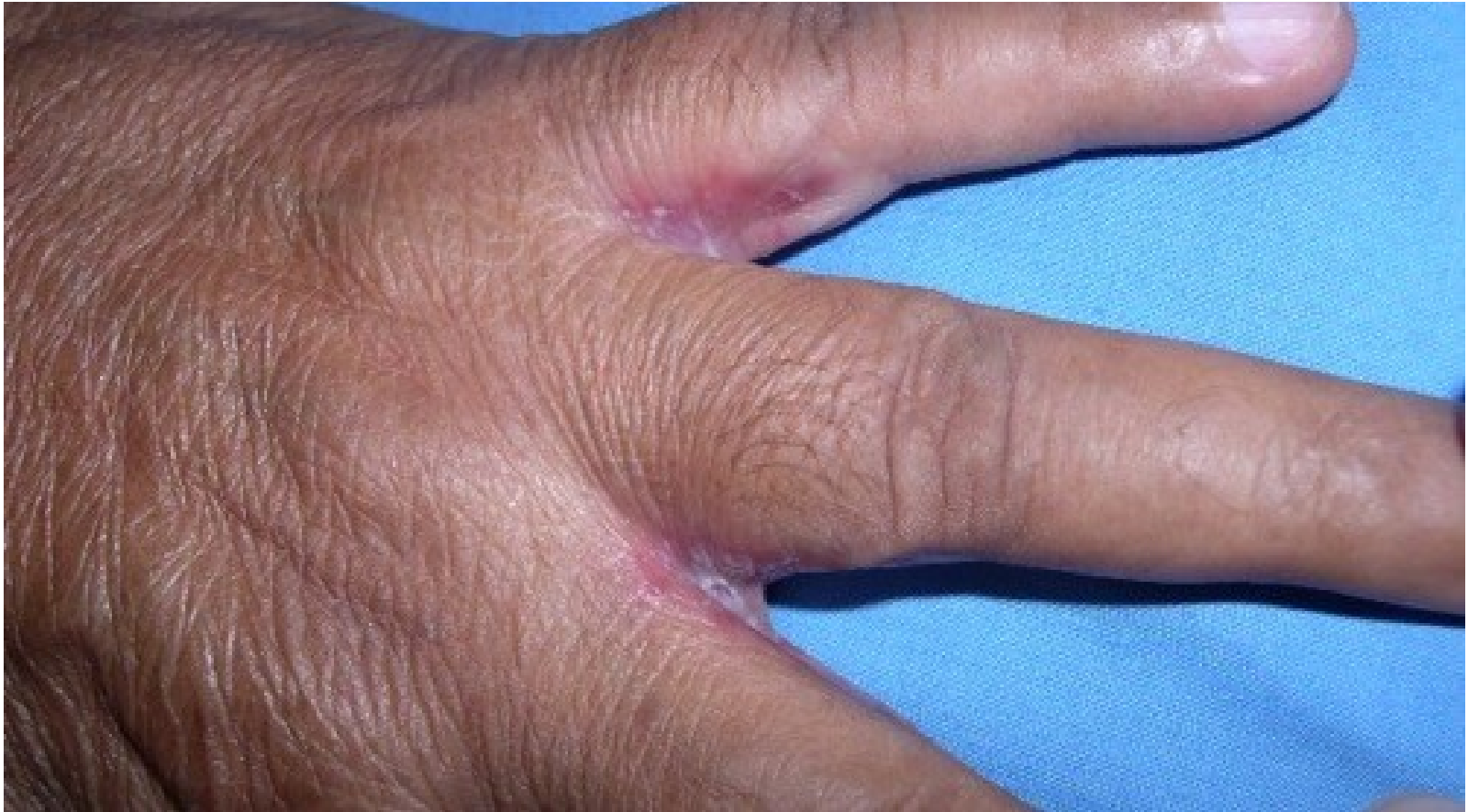

2) intertriginous candidosis



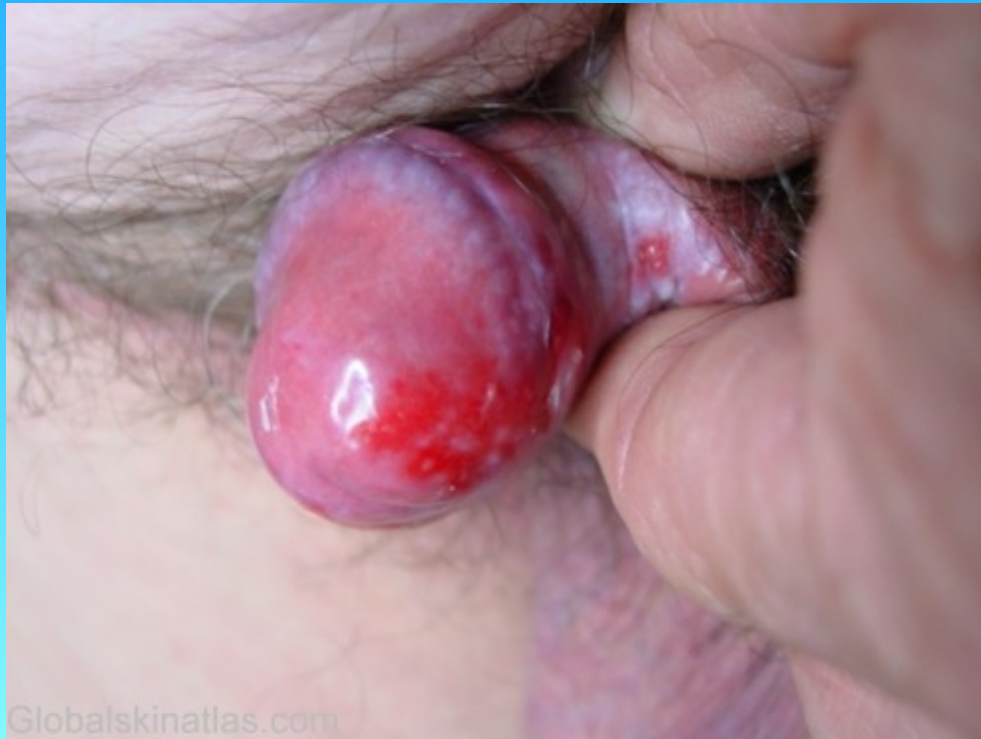

Candidosis interdigitalis erosiva

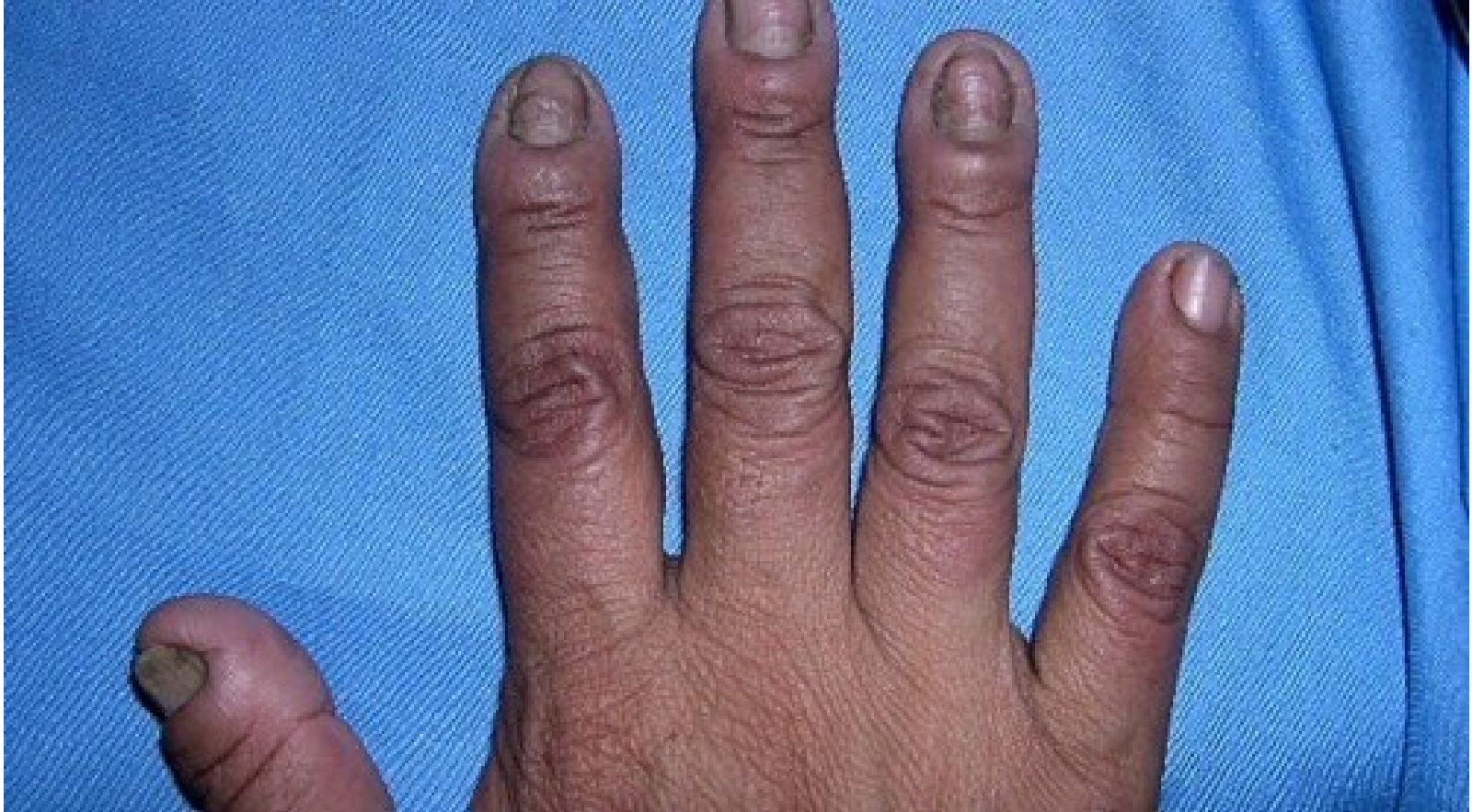

3) vaginal candidosis (MOP VI)

4) *candidal balanitis*

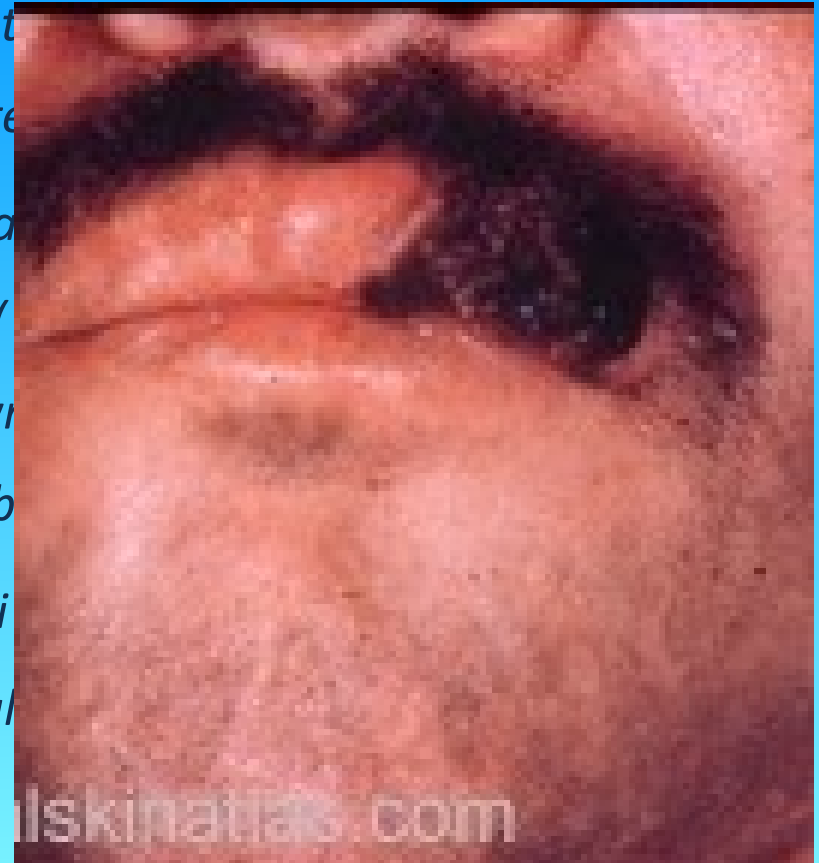

5) paronychia, onychomycosis



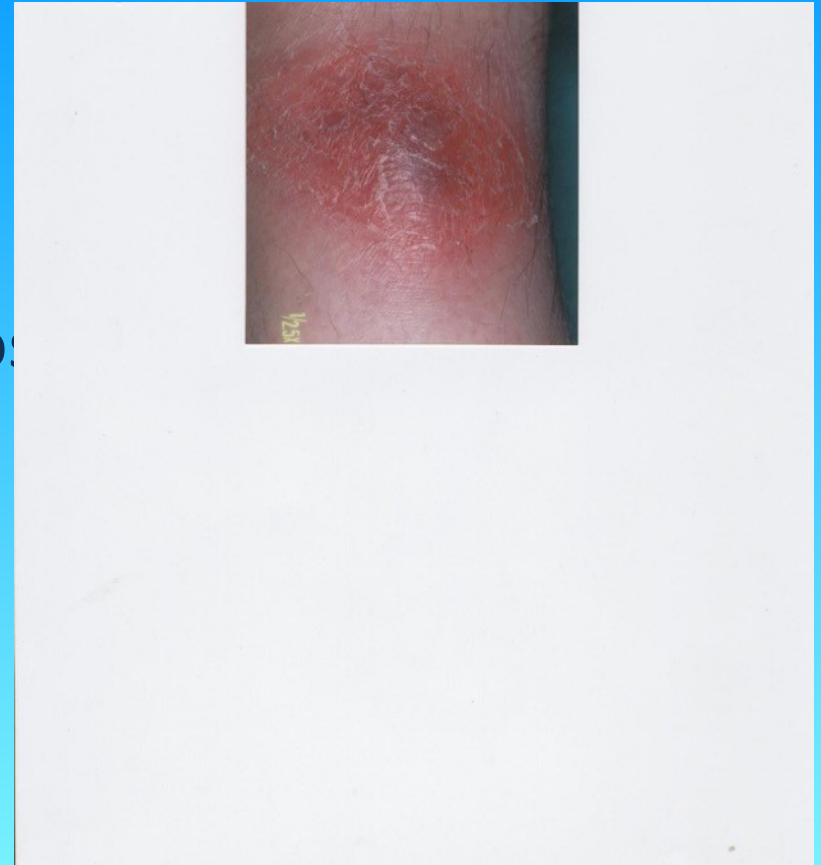
Deep fungal infections

- Blastomycosis: *blastomyces dermatitidis*
skin, pulmonary, and disseminated
- Histoplasmosis: *H. capsulatum*
H.duboisii (South America)
osteoarticular, lymphatic
skin: nodules, abscesses
- Lobomycosis: *Loboa Loboii*
tumoriform nodules



Deep fungal infections

- Coccidiomycosis
- Paracoccidiomycosis
- Aspergillosis Sporotrichosis
- Chromomycosis
- Geotrichosis
- Maduramycosis



Diagnosis of fungal infections

1) Obtaining specimens – disinfection of the lesion with 70%

ethanol

scraping the scales from the border,

or hyperkeratotic material from

beneath the nail's free end

2) Microscopic investigation:

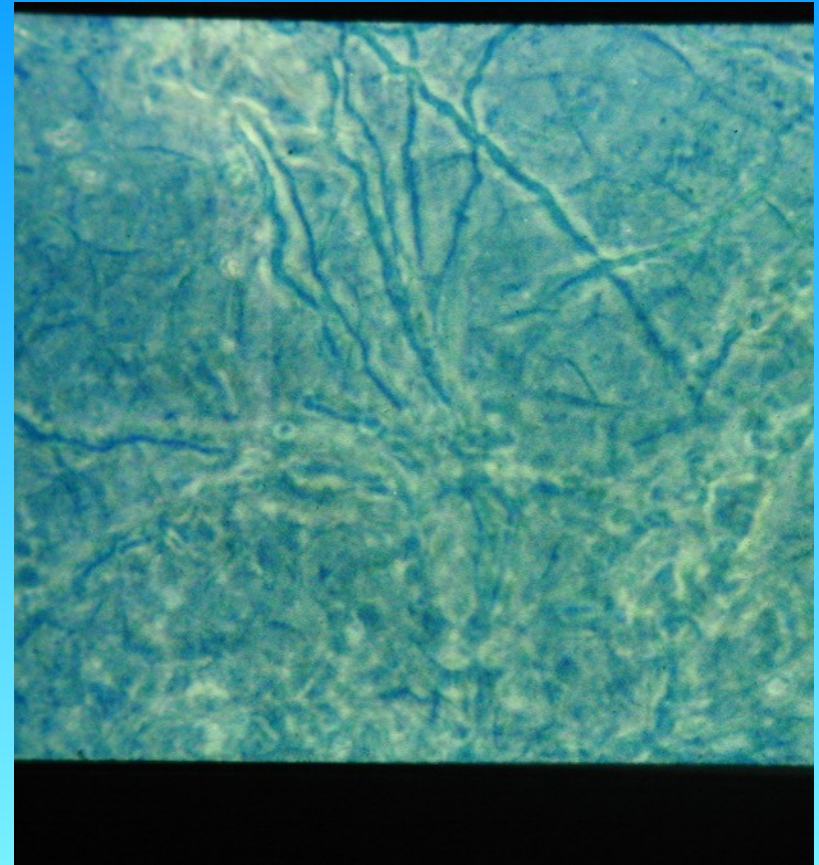
- native preparation

(10-30% KOH, 30min.-3h)

- possible to stain with

Parker's ink

Branched septed fibres (hyphae)

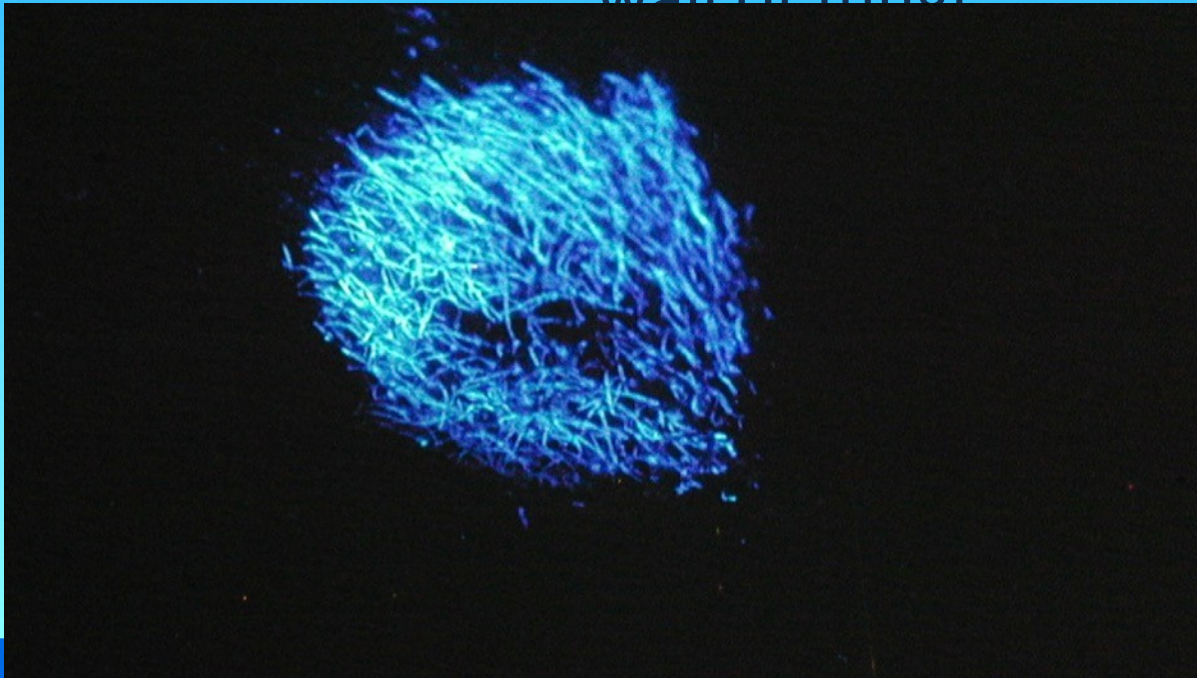


Diagnosis of fungal infections

3) fluorescent microscopy

with blankophore – binds to chitin of the cell

wall of fungi



Diagnosis of fungal infections

4) Wood's lamp (high pressure flash light lamp emittingd UV A 320-400 nm)

UV investigation → fluorescence

Pityriasis versicolor: yellow/orange

Mikrosporium: green

Favus: white/grey

Diagnosis of fungal infections

5) culture – on Sabouraud agar

evaluation: after 3-5 days - yeasts (at 37 st C)

2w rapidly growing f. - *E. floccosum*

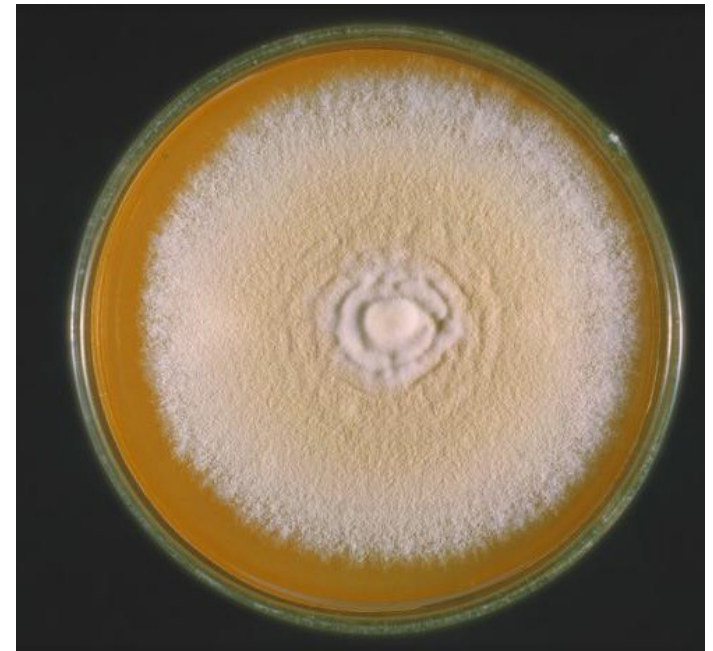3w *T. rubrum*

4w slowly growing - *T. verucosum*

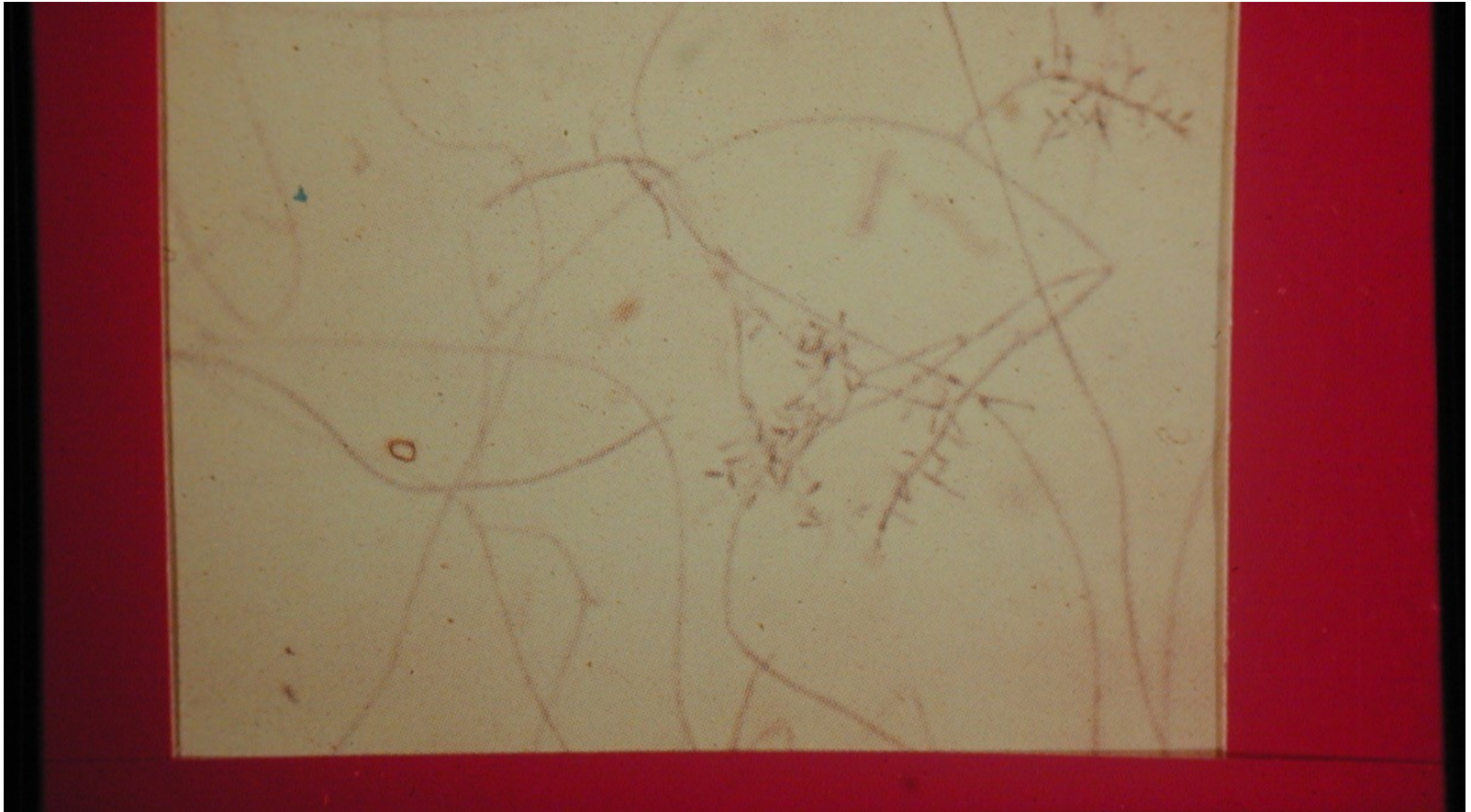
Only after 6 weeks if nt appears, the culture can be concluded as negative

Diagnosis of fungal infections

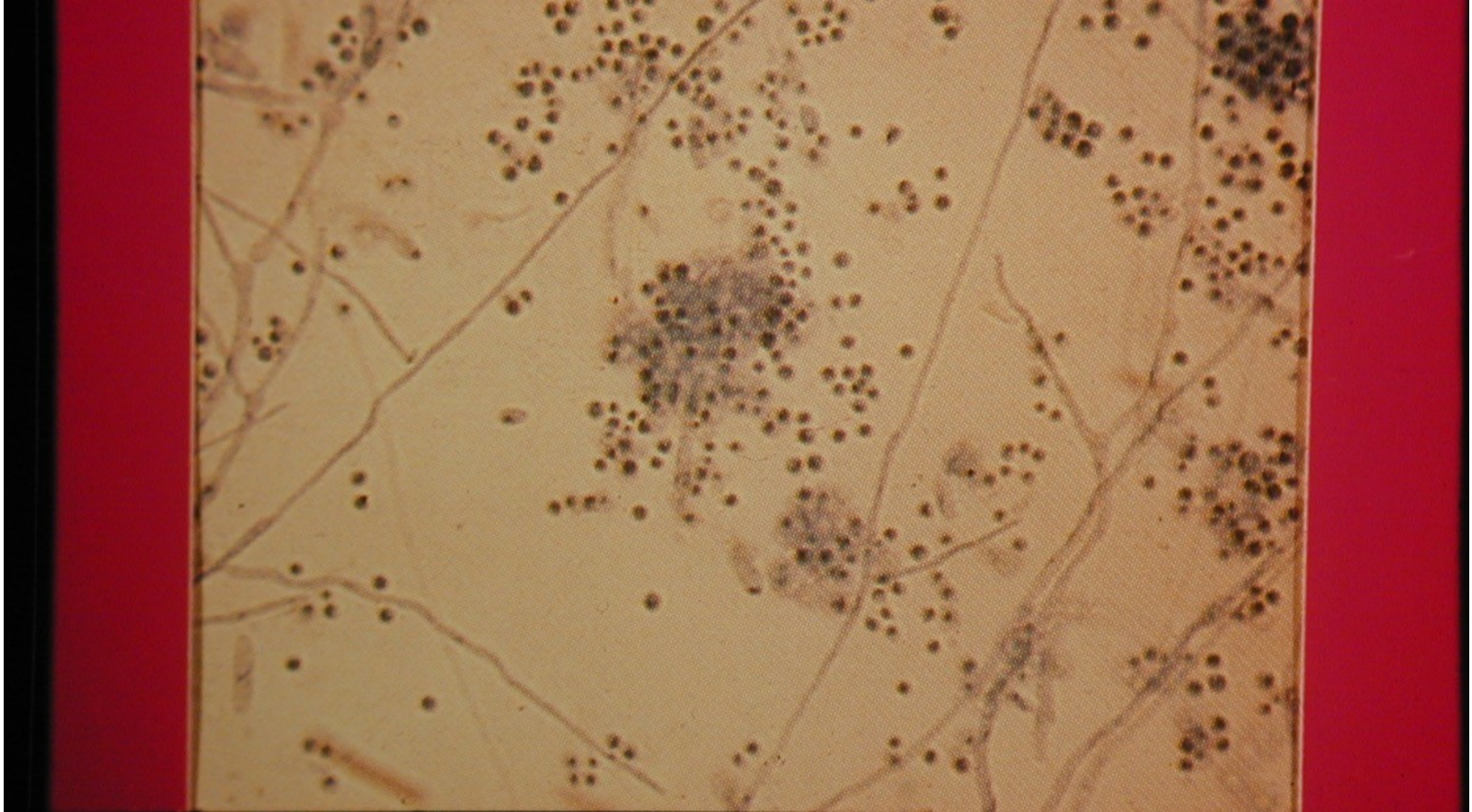
- Evaluation of the macromorphology of the colonies
- Manufacturing of the microculture
- Physiologic tests
 - ureaze test ...
 - zymograms, auxanograms..



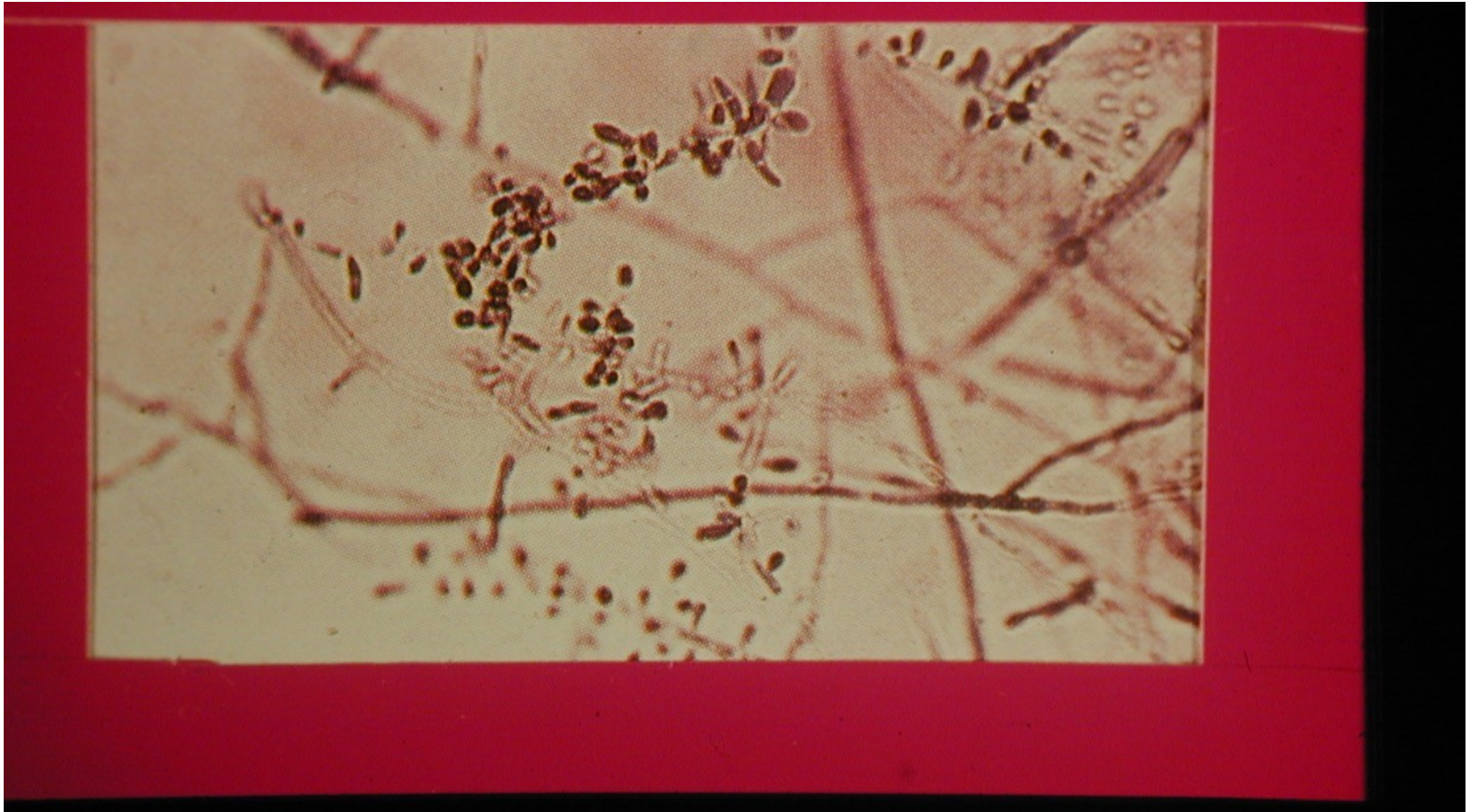
T.rubrum



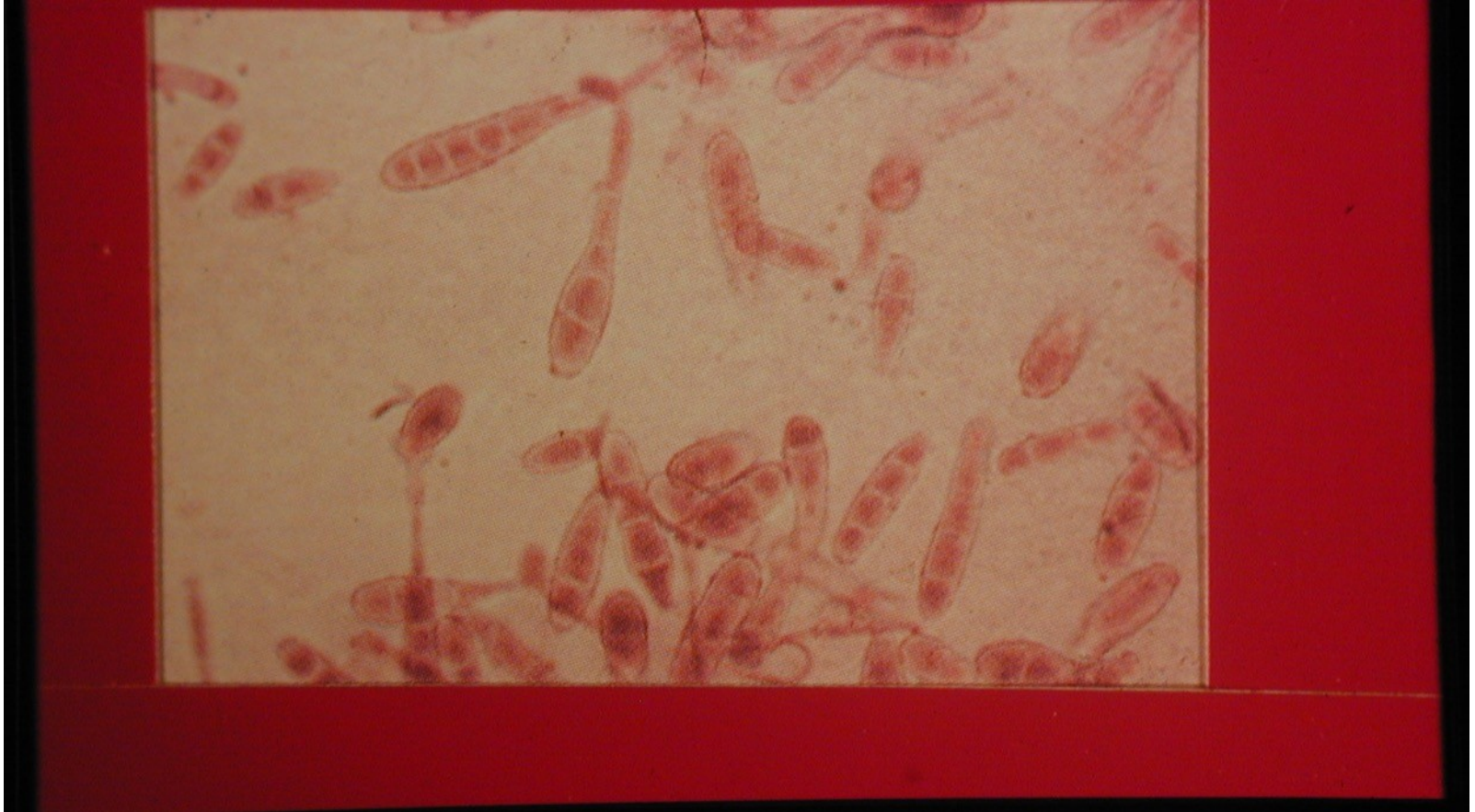
T.mentagrophytes



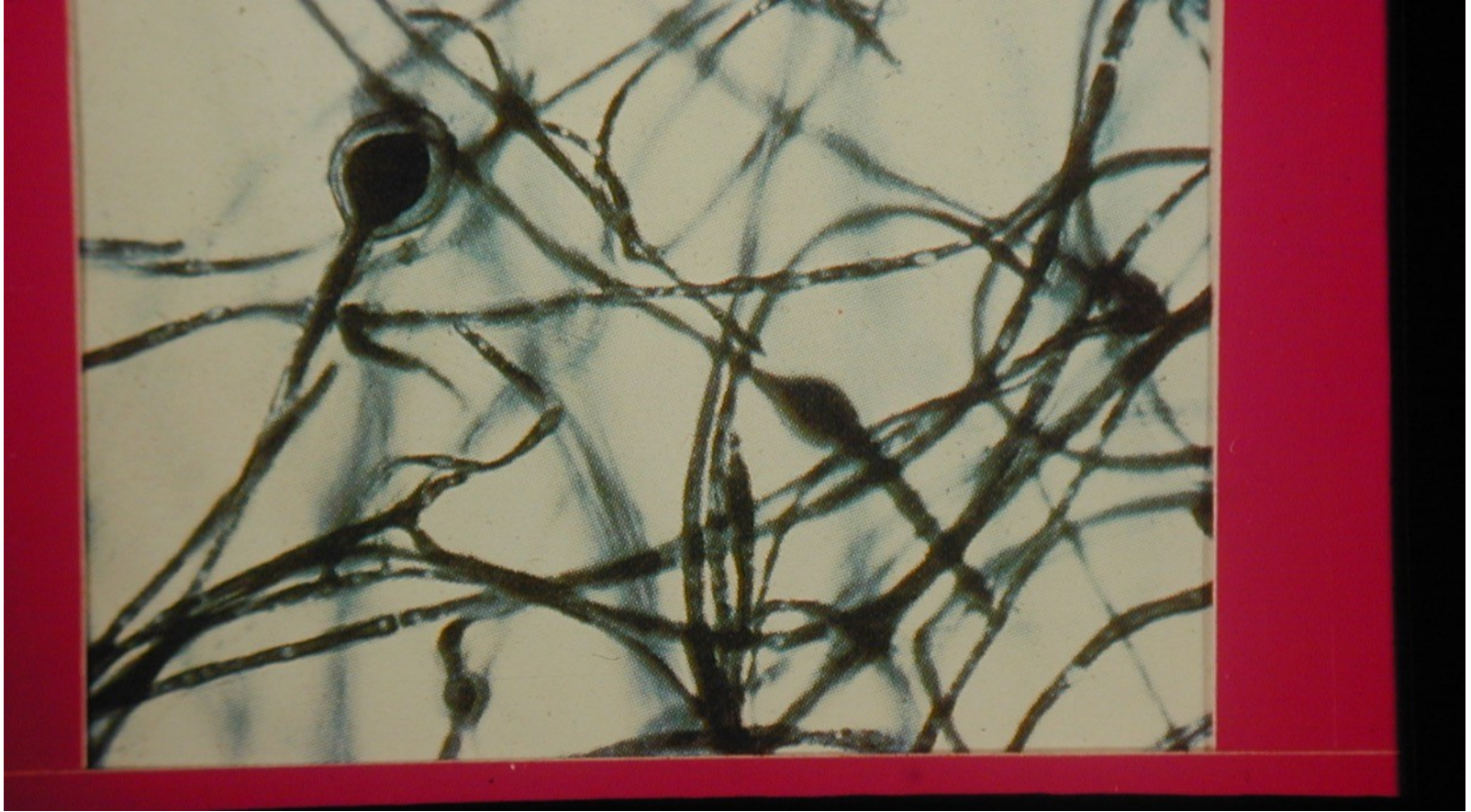
T. tonsurans



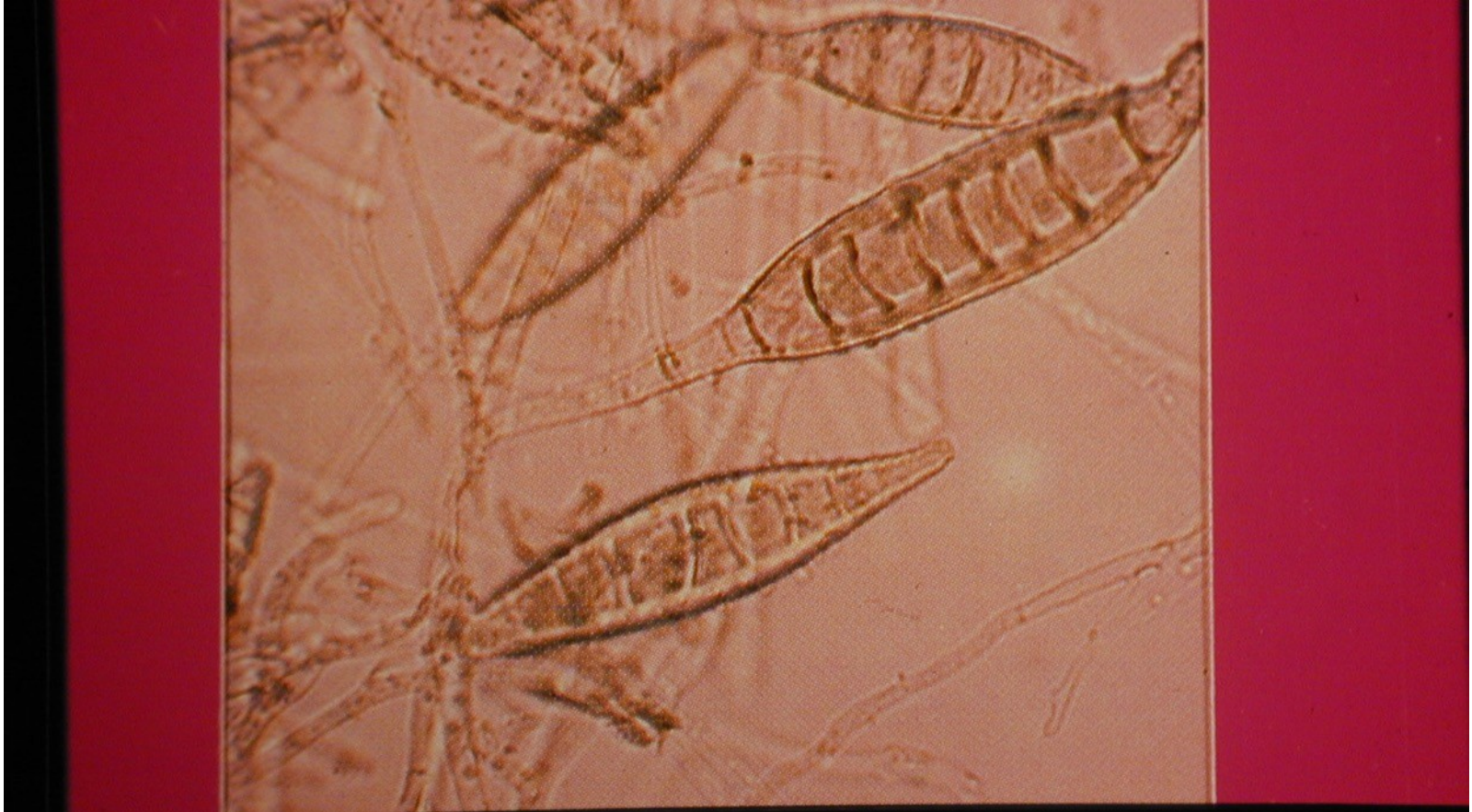Epidermophyton floccosum



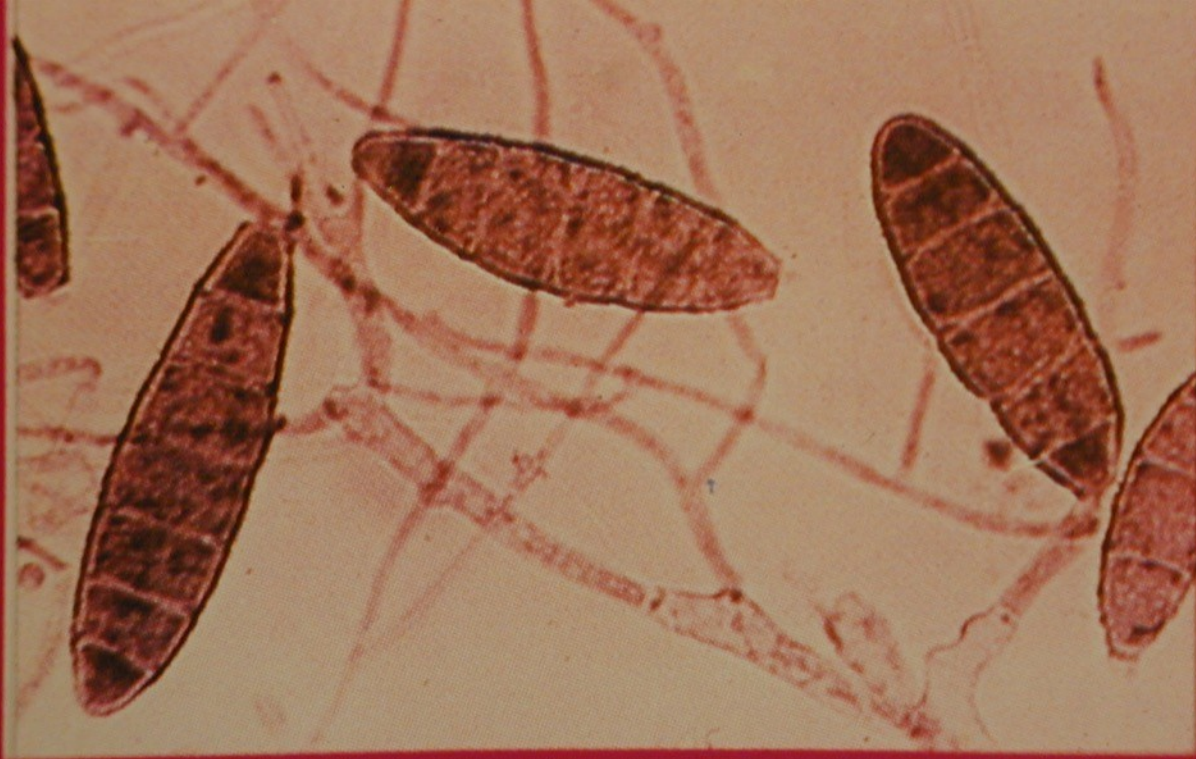
M.audouinii



Microsporon canis

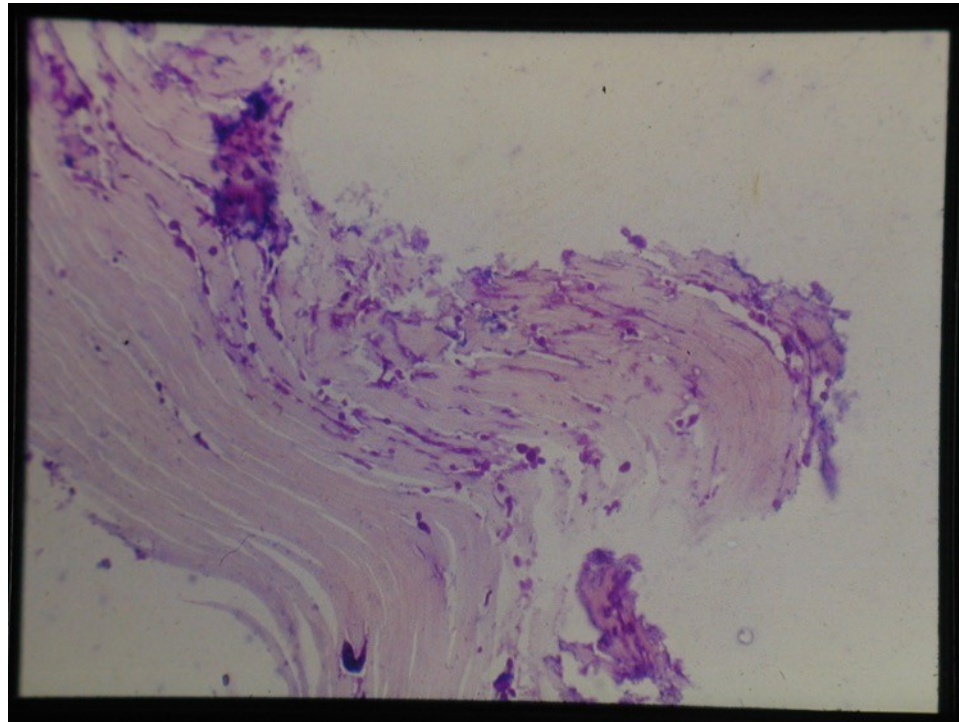


Microsporon Gypseum



Diagnosis of fungal infections

- 5) histologic examination with PAS staining (periodic acid Schiff)



Antifungal therapy

- Antifungals:
 - 1) polyenic
 - 2) azoles
 - 3) alylamines
 - 4) other

Antifungal therapy

systemic treatment - indications

- Deep fungal infections
- Deep tinea capitis
- Extensive onychomycosis
- Recalcitrant superficial tinea

Antifungal therapy

Parenteral application:

1) Amphotericin B

systemic and deep fungal infections

intravenous appl., serious AE

2) Voriconazole (VFEND)

3) Posakonazole (Nofaxil, Posatex)

4) Kaspofungine (Candidas)

Antifungal therapy

Oral application:

1) fluconazole vaginal candidosis

2) ketokonazole yeast infection, dermatopytoses,
malassezia

3) itrakonazole yeast infection, dermatophytoses,
malassezia

onychomycosis: 3m/5m

4) terbinafine

onychomycosis: 6t/3m

Antifungal therapy

topical therapy:

ekonazole - Pevaryl crm, pst

ketokonazole - Nizoral crm

clotrimazole - Canesten crm

oxikonazole – Myfungar crm.

terbinafin - Lamisil crm

cyklopiroxolamine – Batrafen crm, sol.