

# Lecture 11

## Nervous system

- **Reminder on composition of nerve tissue**
- **Structure of gray matter of spinal cord, cerebellum, and telencephalon (iso- and allocortex)**
- **Peripheral nervous system - ganglia and peripheral nerves**
- **Earliest phases of development of nervous system**
- **Histogenesis of neural tube**
- **Development of brain and spinal cord**

**Brno, November 2021**

# **Nervous system - Histologically**

**Made of 3 structurally different components:**

## **The nerve tissue**

### **Blood vessels**

**capillaries, arterioles and venules that densely penetrate the nerve tissue**

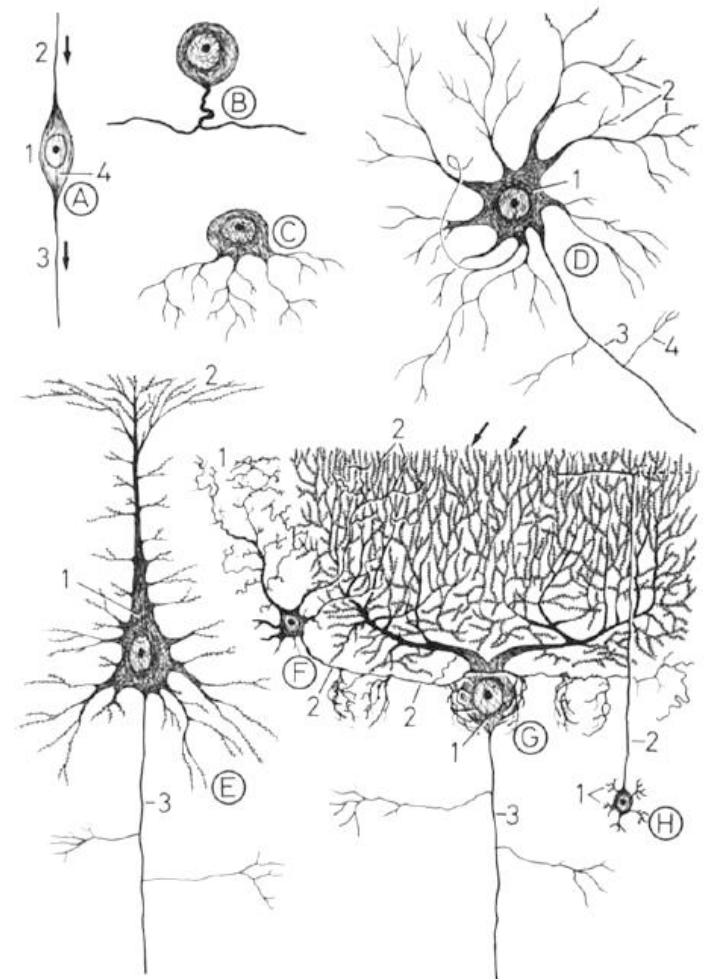
## **The connective tissue**

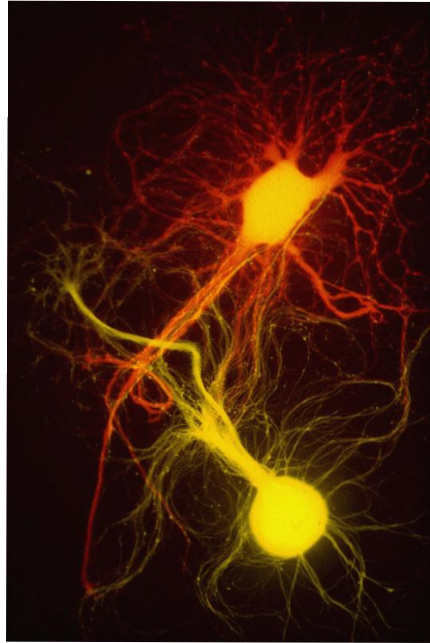
- provides protection of both previous components is organized into:
  - meninges - envelope the brain and spinal medulla
  - epi-, peri- and endoneurium - connective tissue within nerves or on their surfaces
  - thin capsules - surround the cerebrospinal and autonomic ganglia

# Nerve tissue – General features

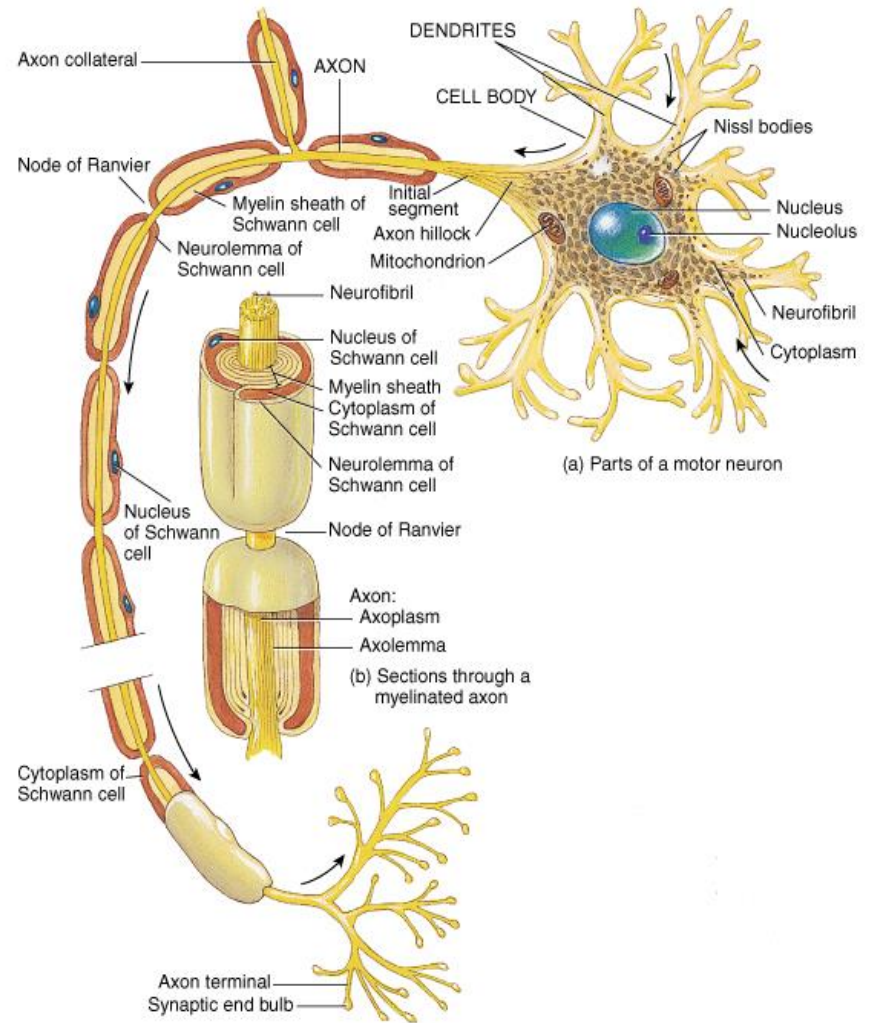
Nervous tissue is made up of **just 2 types of cells**:

- **Neurons**
- **Neuroglia - glial cells** (supporting cells)
- Neurons are the basic functional units of nervous tissue.
- They are highly specialized to transmit nerve impulses.





# Neuron



1. **Perikaryon (neurocyte)**
2. **Processes:**  
(one-way signal conduction)
  - **axon**  
(always only one; centrifugal conduction)
  - **dendrit(es)**  
(centripetal conduction)



# Neuron - Perikaryon

## Position:

CNS – grey matter

PNS – ganglia

## Shape:

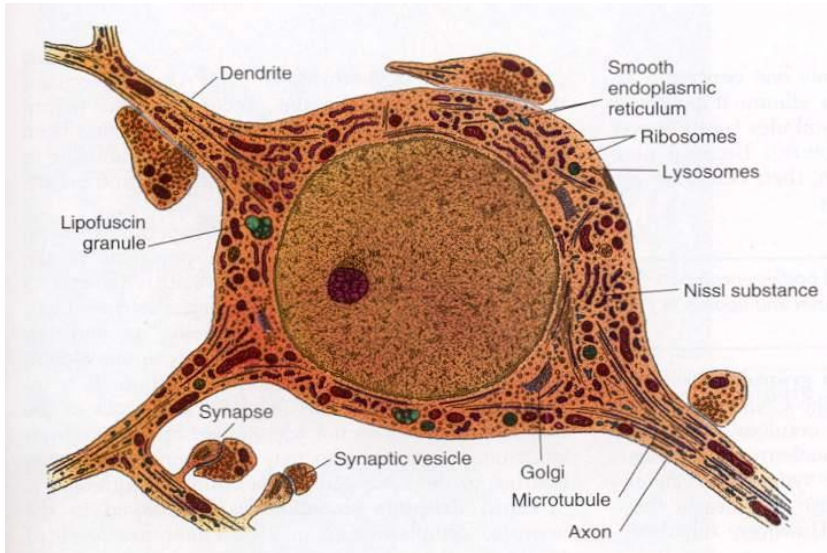
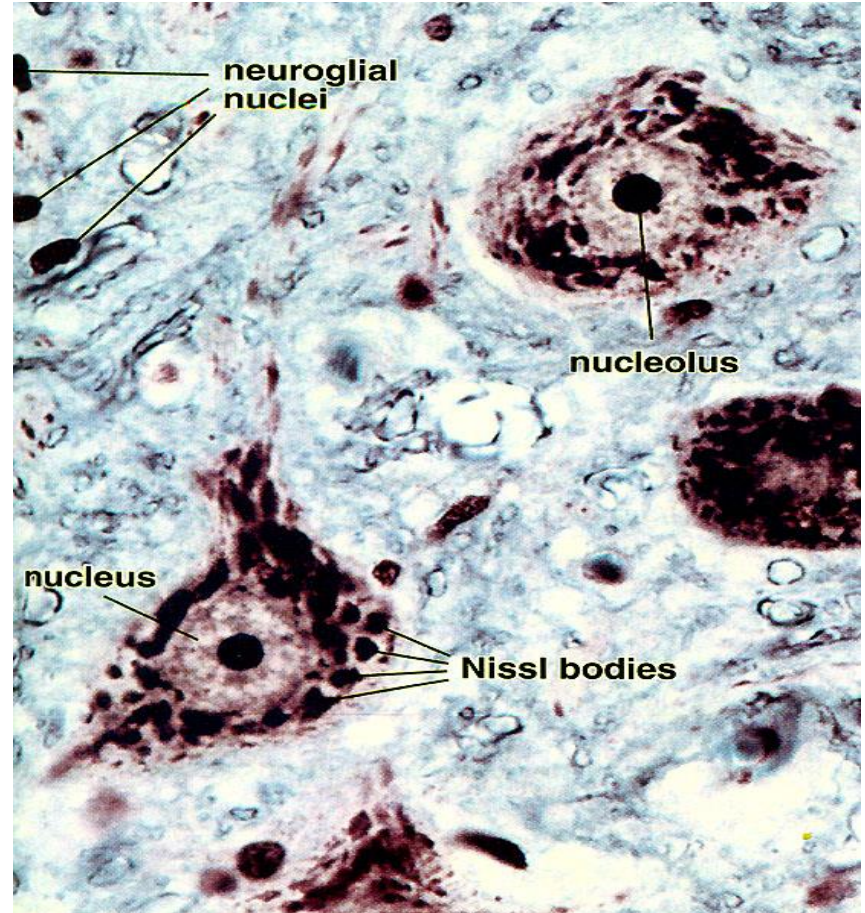
pyramidal, spherical, ovoid, pear-shaped

## Size:

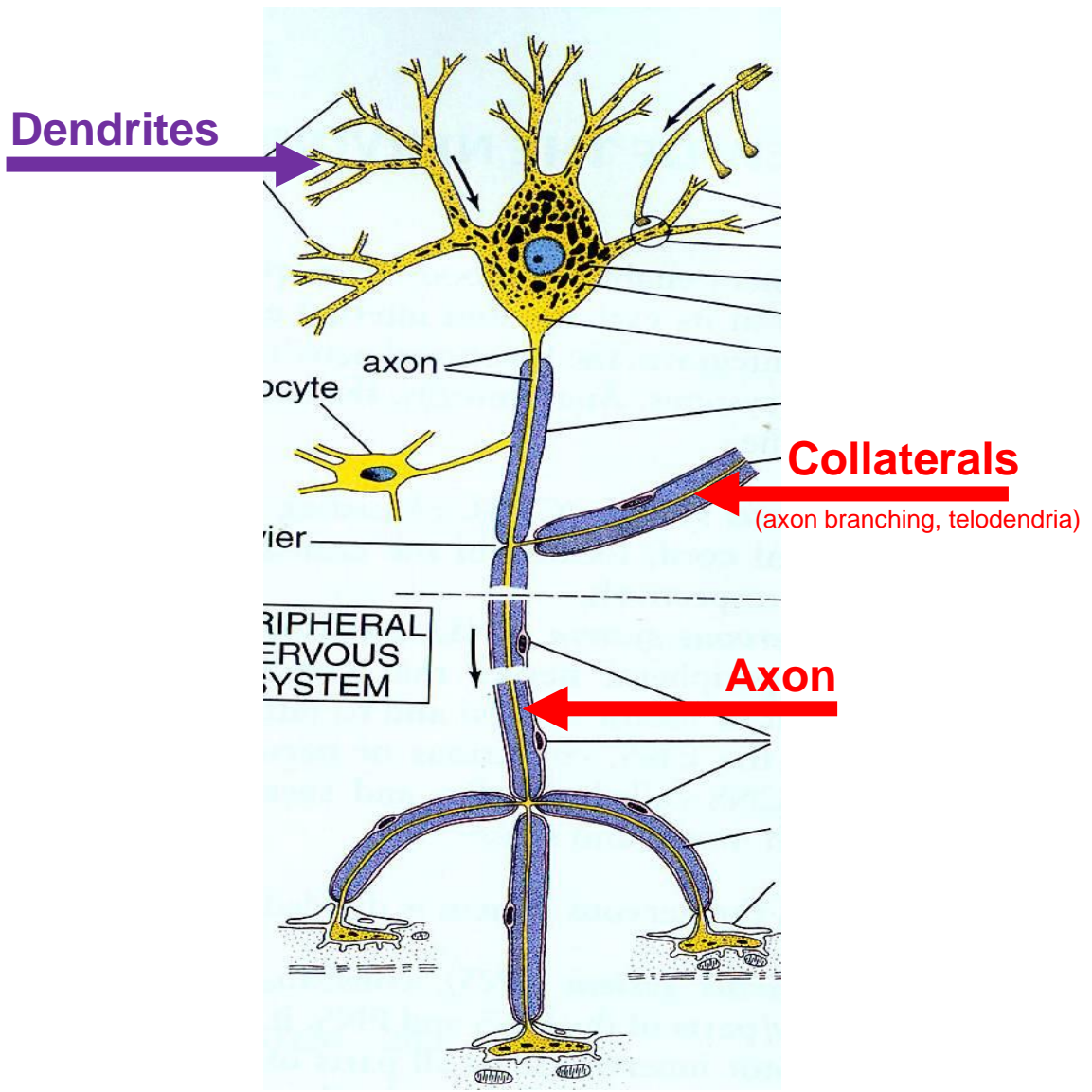
5 to 150  $\mu\text{m}$

## Organelles:

- Nucleus – large + pale + prominent nucleoli
- Nissl substance – rough ER
- Neurofibrils (neurofilaments + neurotubules + actin)
- Lipofuscin pigment clumps



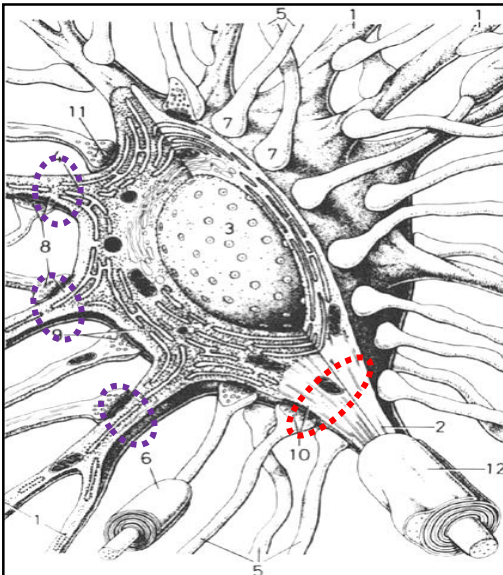
# Neuron – Neurites / Processes



# Neuron – Neurites / Processes

## Dendrites

- Conducts impulses **towards the cell body**
- Typically **short, highly branched & unmyelinated**
- Surfaces specialized for contact with other neurons
- Contains **neurofibrils & Nissl bodies**
- Receptive surface for synaptic junctions
- Contain **MAP-2** (distinction from axon)
- Tens of thousands of synapses on large dendrites
- **Dendritic spines** located on surface of some dendrites
- Spines diminish with age and poor nutrition



## Axon (nerve fiber)

- 1 axon projects from cell body at axon hillock
- **Axon hillock** - pyramid shaped region of the soma that is **devoid of RER**
- Some axons are up to **100 cm**
- **Initial segment = Spike trigger zone** (a portion of axon from its origin to the beginning of myelin sheath)
- **At spike trigger zone** trigger zone summation of excitatory and inhibitory impulses occurred
- Collateral branches, Terminal arbor
- **Myelinated** or **Unmyelinated**
- Conduct impulses **away from cell body**
- Swollen tips called **synaptic knob (terminal button)** contain **synaptic vesicles** filled with neurotransmitters
- Cell membrane = **axolemma**
- Cytoplasm = **axoplasm**

**White matter:** areas of myelinated axons

**Gray matter:** areas of unmyelinated axons, cell bodies, and dendrites

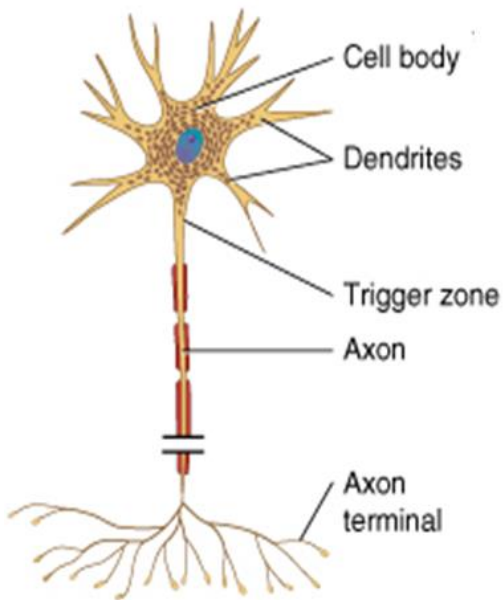


# Neuron – Classification 1

According to the **number of the processes**

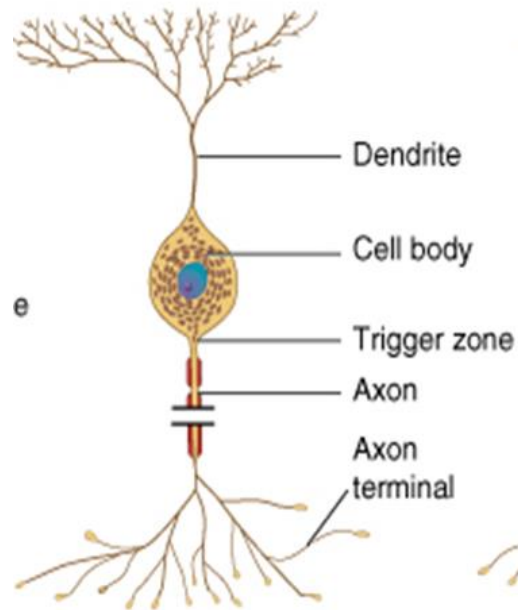
## Multipolar

several dendrites & one axon  
*(most common cell type)*



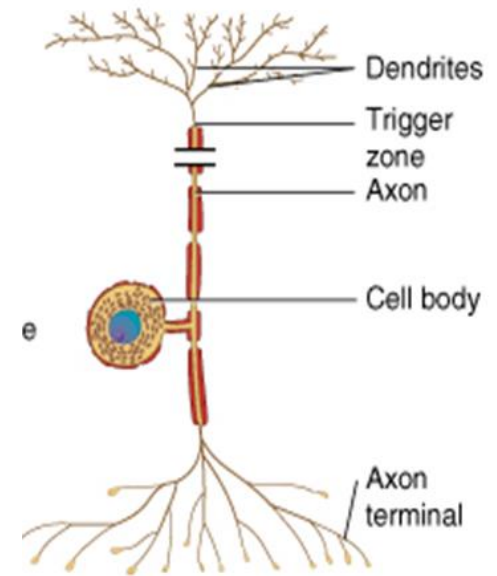
## Bipolar

one main dendrite & one axon  
*(in retina, vestibular and cochlear ganglion)*



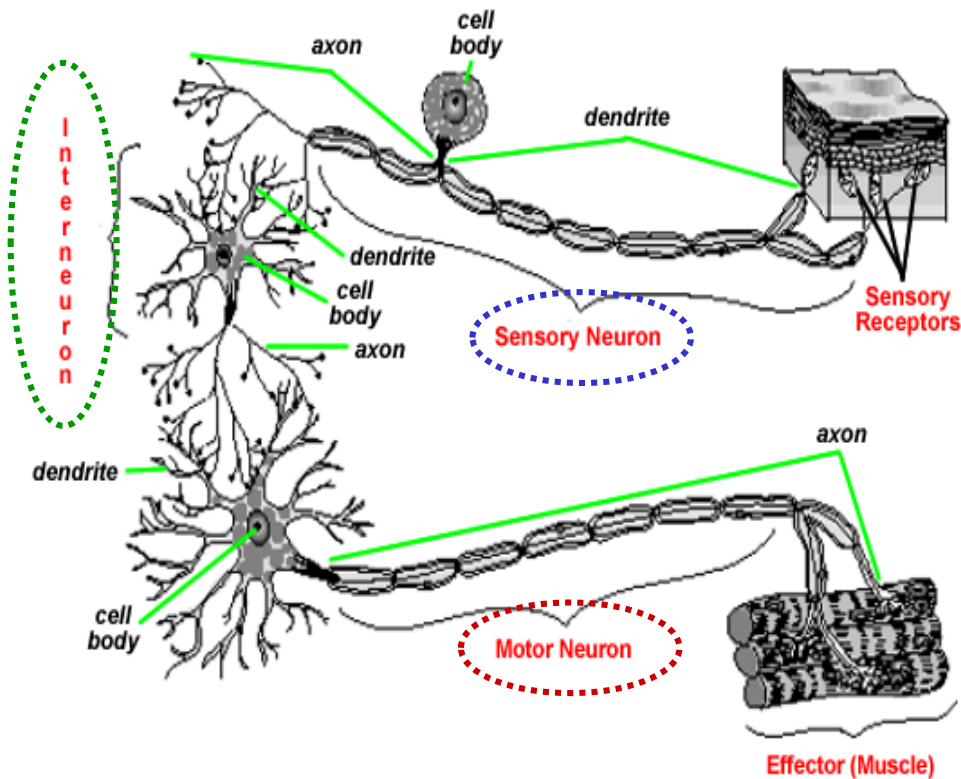
## Unipolar (pseudounipolar)

one process only  
*(develop from a bipolar)*  
*(always sensory, in spinal ganglia)*



# Neuron – Classification 2

According to the **function**



## Motor (efferent) neurons:

- conduct impulses to muscles, neurons, glands

## Sensory (afferent) neurons:

- receive sensation

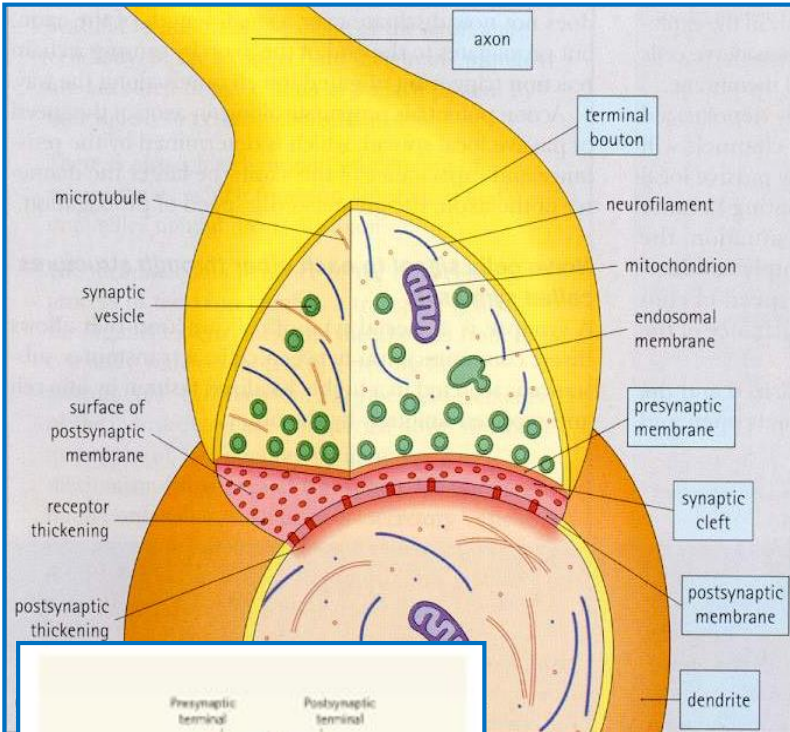
## Interneurons:

- local circuit neurons

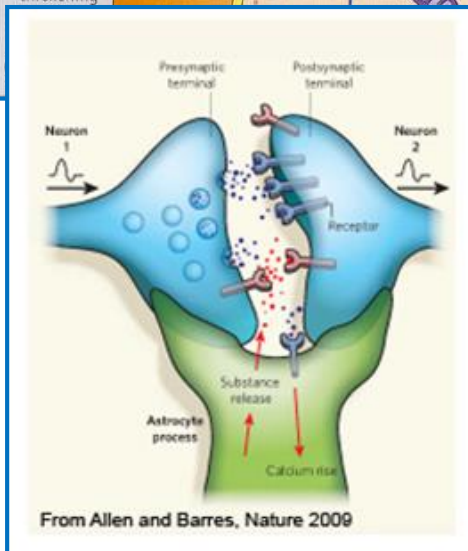
# Synapse

## Definition

Synapses are highly specialized intercellular junctions, which link the neurons of each nervous pathway

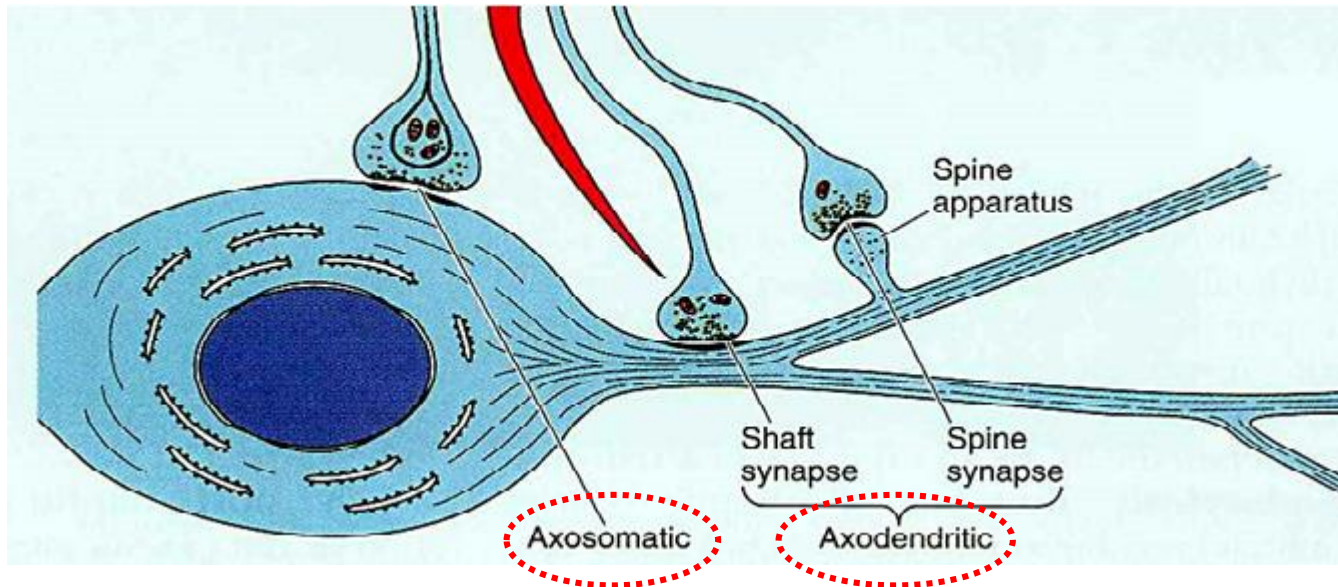


- **Axon terminal** forms **bouton terminal**
- **Presynaptic membrane** - contains mitochondria, and an abundance of **synaptic vesicles with neurotransmitter**
- **Presynaptic dense projections** - are associated with synaptic vesicles form active sites of synapse
- **Synaptic vesicles** (smaller + larger – storage)
- **Postsynaptic membrane** - contains receptors and some dense materials
- **Synaptic cleft** - 20-30 nm width, occupied by fine filaments
- **Glial cells** increase synaptic efficacy
- **Asymmetric synapses are excitatory** (a thick postsynaptic membrane and a 30 nm synaptic cleft)
- **Symmetric synapses are inhibitory** (thin postsynaptic membrane and a 20 nm synaptic cleft)
- Need **special staining** to see by light microscopy



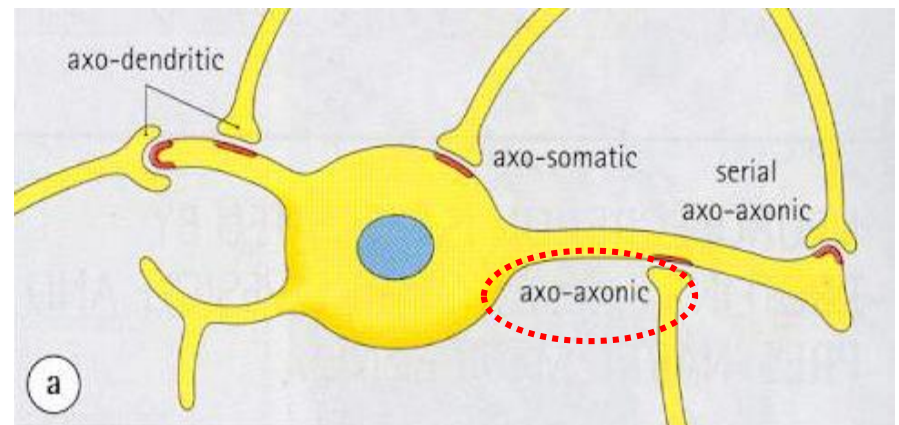
# Synapse

## Classification according to the constitution



**Axodendritic**  
**Axosomatic**  
**Axoaxonic**

**Note:**  
**Neuromuscular junction** – synapse between neuron and effector muscle fibre





# Neuroglia

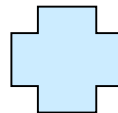
## General features

- **non-neuronal** cells of several types
- support and protect the neurons
- bind neurons together and **form framework for nervous tissue**
- in fetus, **guide migrating neurons** to their destination
- if mature neuron is not in synaptic contact with another neuron, it is covered by glial cells
- prevents neurons from touching each other
- gives **precision to conduction pathways**
- only nuclei visible by light microscopy without special staining
- there are several glial cells for each neuron

Number of **neurons**: about **100 billions to 1 trillion**  
Number of **glial cells**: **50x more** than neurons

## Central neuroglia

- Astrocytes
- Oligodendrocytes
- Microglia
- Ependymal cells

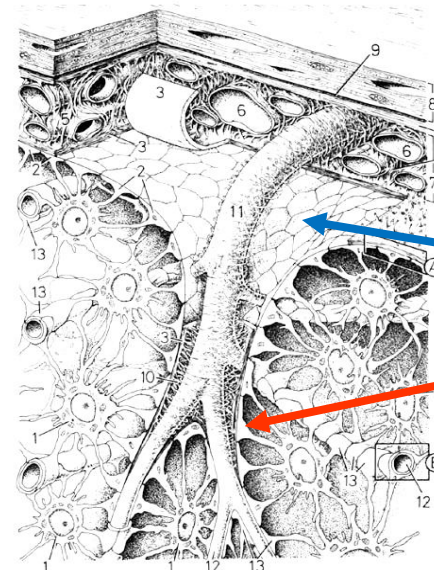
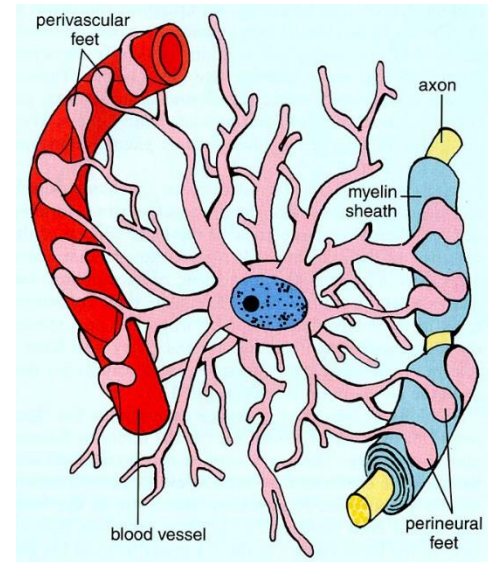


## Peripheral neuroglia

- Schwann cells
- Satellite cells

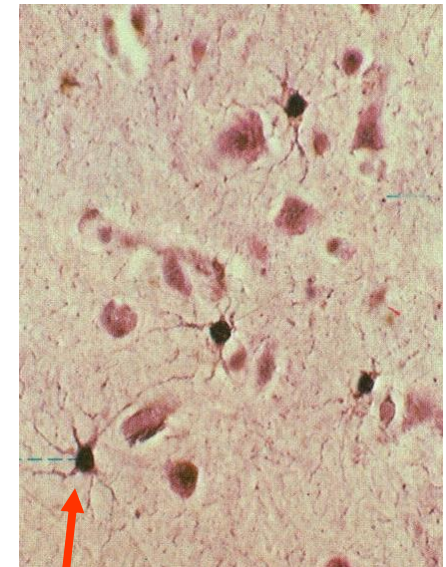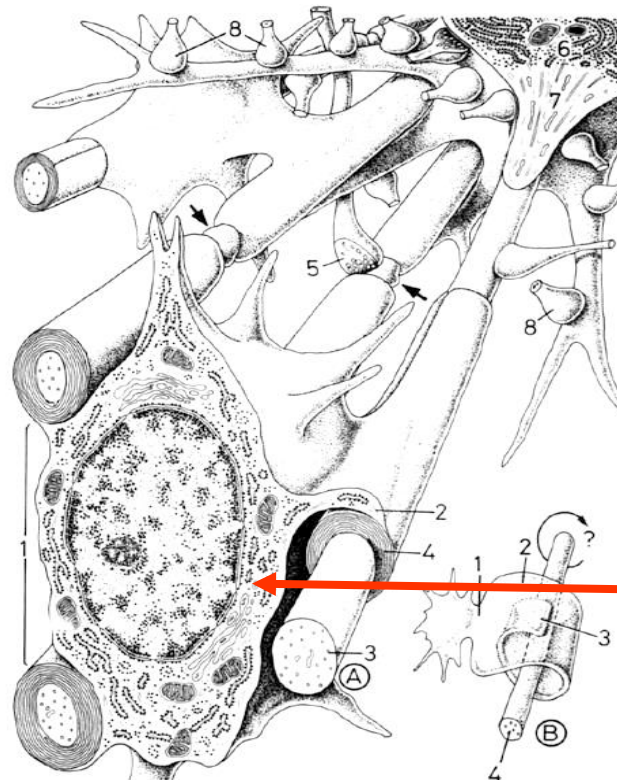
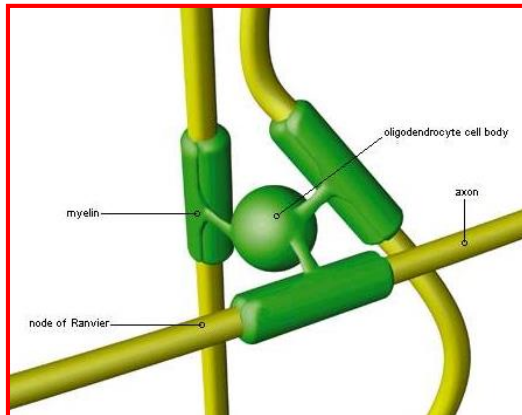
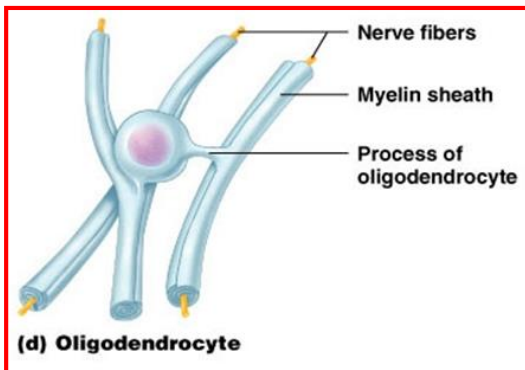
# Neuroglia - Astrocytes

- most abundant glial cell in CNS
- covers entire brain surface and most non-synaptic regions of the neurons in the gray matter of the CNS
- **diverse functions:**
  - ✓ form a **supportive framework** of nervous tissue
  - ✓ have extensions (**perivascular feet**) that contact blood capillaries that stimulate them to form a tight seal called the **blood-brain barrier**
  - ✓ convert blood glucose to **lactate** and supply this to the neurons for nourishment
  - ✓ **nerve growth factors** secreted by astrocytes promote neuron growth and synapse formation
  - ✓ communicate electrically with neurons and may **influence synaptic signaling**
  - ✓ regulate chemical composition of tissue fluid by absorbing excess neurotransmitters and ions
  - ✓ **astrocytosis** or **sclerosis** – when neuron is damaged, astrocytes form hardened scar tissue and fill space formerly occupied by the neuron
  - ✓ contains **GFAP**



# Neuroglia - Oligodendrocytes

- ✓ smaller than astrocytes; darker, round nucleus, abundant RER, well developed golgi apparatus
- ✓ form **myelin sheaths in CNS**
- ✓ one cell **serves more than one axon**
- ✓ **cannot migrate around axons** (unlike Schwann cells) must push newer layers of myelin under the older ones so myelination spirals inward toward nerve fiber
- ✓ nerve fibers in CNS have **no Schwann sheath (neurilemma) or endoneurium**
- ✓ each arm-like process wraps around a nerve fiber forming an **insulating layer** that speeds up signal conduction
- ✓ damaged in **multiple sclerosis**

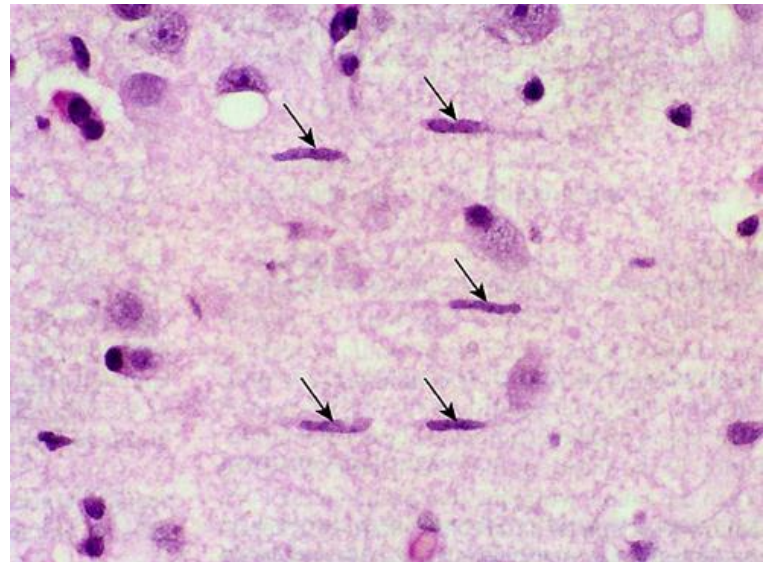
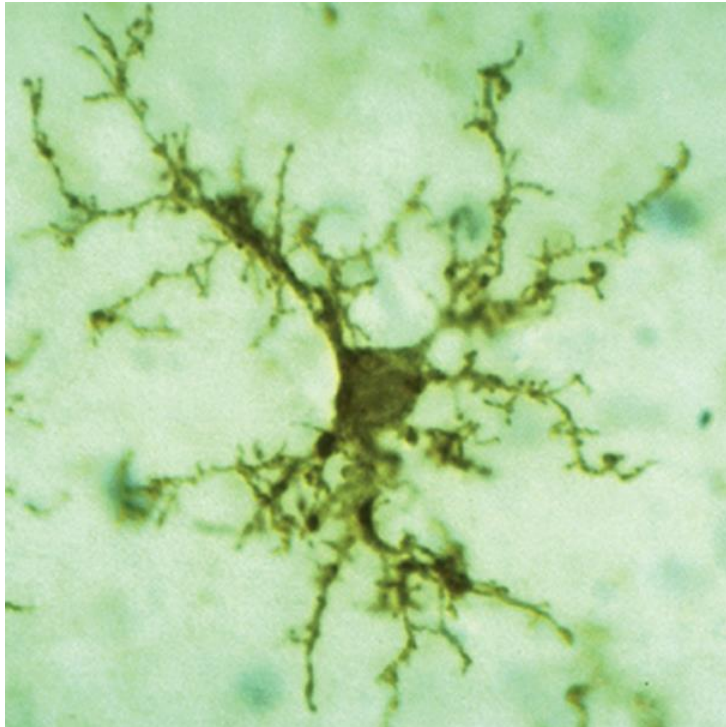


oligodendrocyte



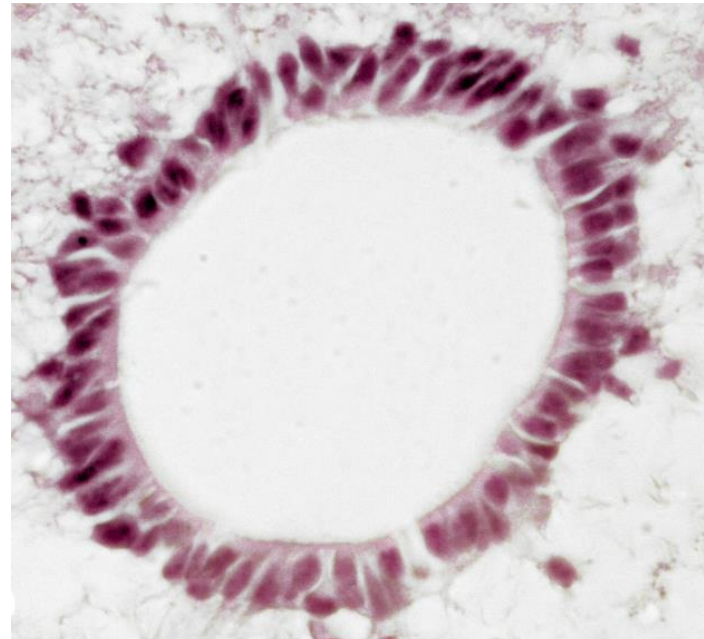
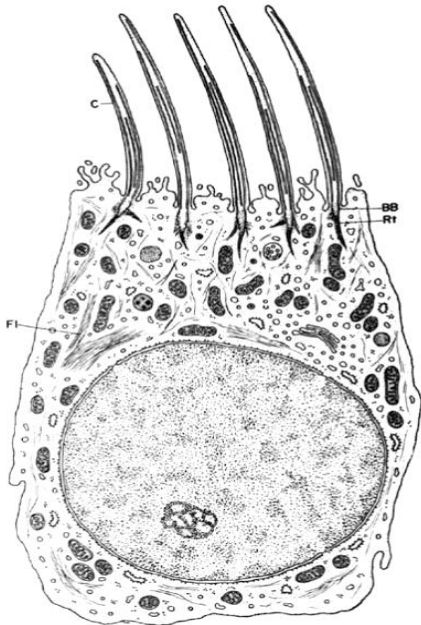
# Neuroglia - Microglia

- ✓ **smallest** neuroglial cell
- ✓ small, dark, **elongated nuclei**
- ✓ possess **phagocytotic** properties
- ✓ when activated – **antigen presenting** cell
- ✓ originate in bone marrow (**mesodermal** origin)

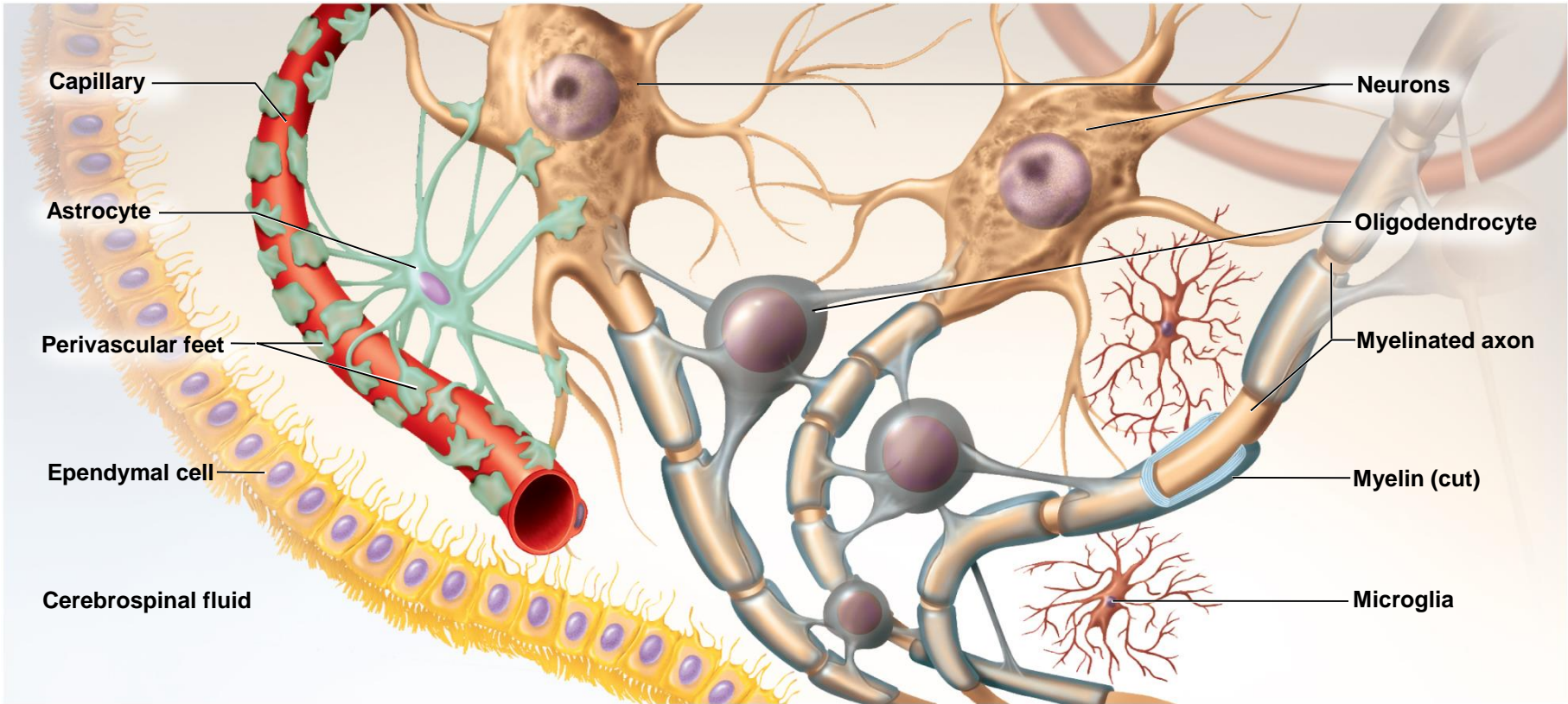


# Neuroglia – Ependymal cells

- ✓ line ventricles of CNS and central canal of spinal cord
- ✓ cuboidal or low columnar shape
- ✓ no basal lamina
- ✓ **secrete** cerebrospinal fluid (CSF)
- ✓ some are **ciliated**, facilitate movement of CSF
- ✓ participate in formation of **Choroid plexus**



# Neuroglia – Central - Summary



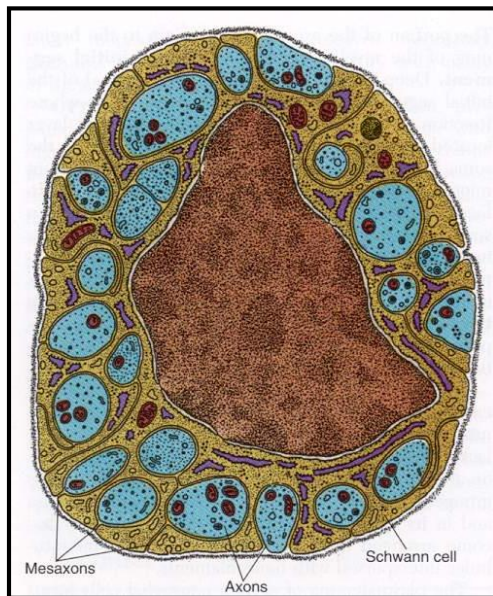
Copyright © The McGraw-Hill Companies, Inc. Permission required for reproduction or display.



# Neuroglia in PNS – Schwann cells

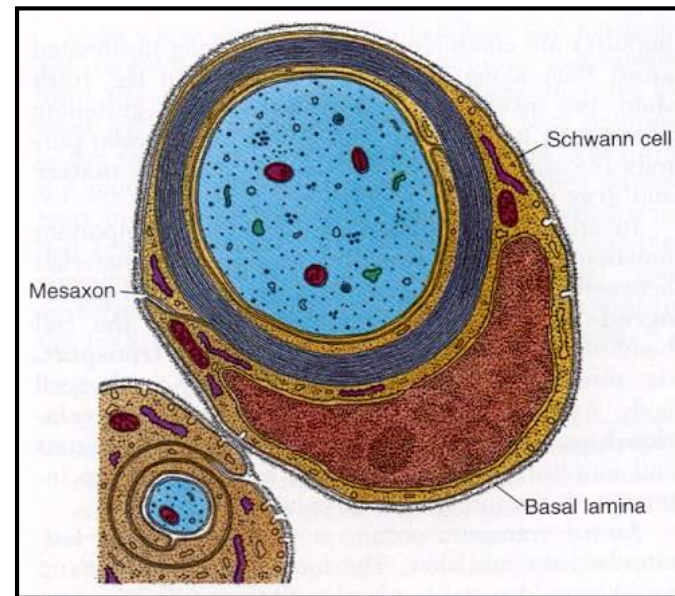
- cells that encircle all axons in PNS
- provide structural and metabolic support to axons
- provide guidance for axonal growth

## Small diameter axons Enveloping by only cytoplasm



only Schwann sheath – **gray** nerve fiber

## Large diameter axons Wrapping by myelin sheaths



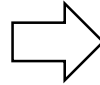
**X**

Schwann + myelin sheath – **double contoured** nerve fiber



# Neuroglia in PNS – Schwann cells

Double contoured nerve fiber

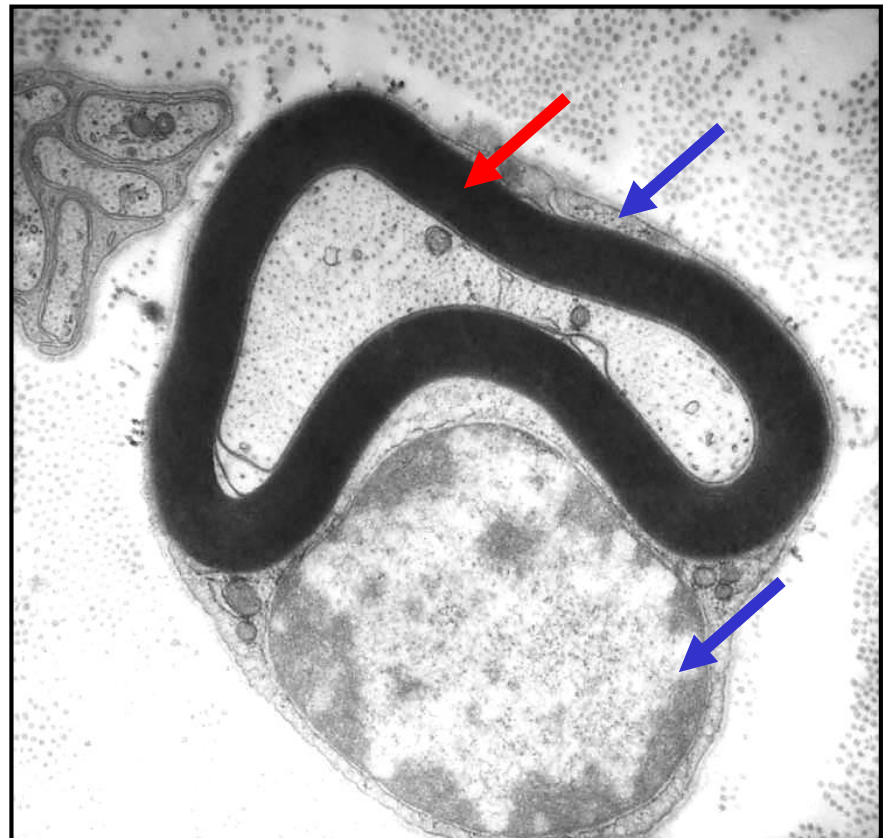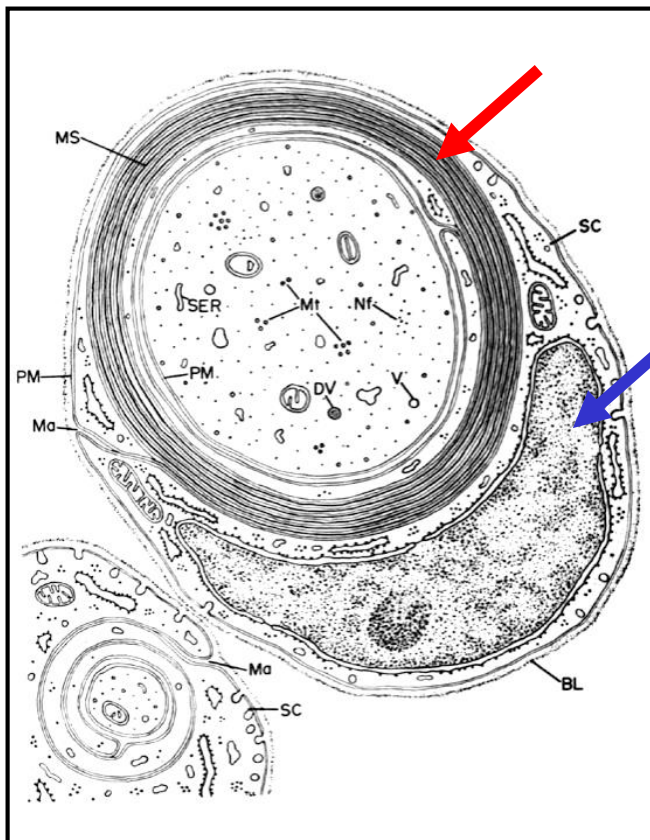


Schwann sheath

+

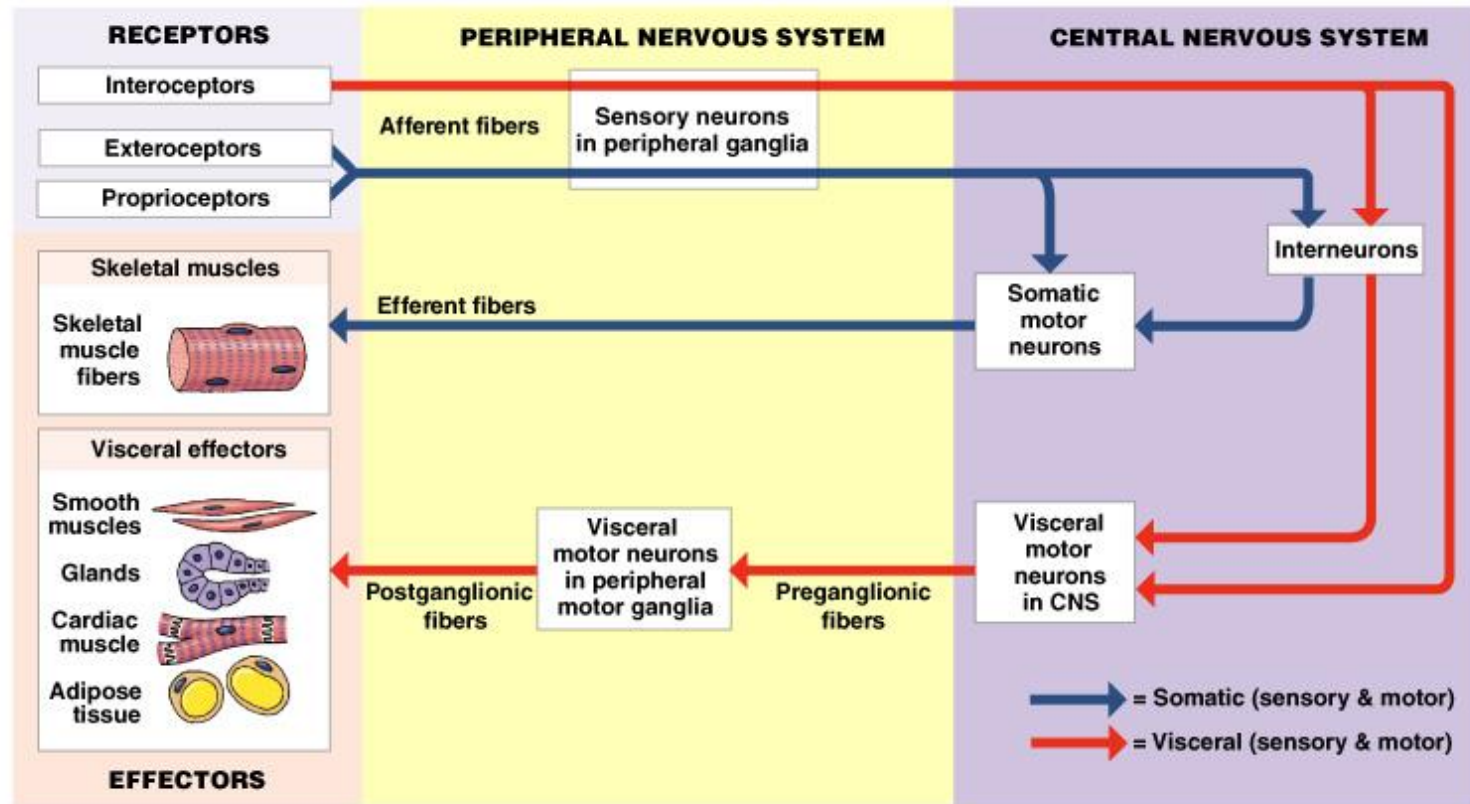
= Neurilemma

Myelin sheath

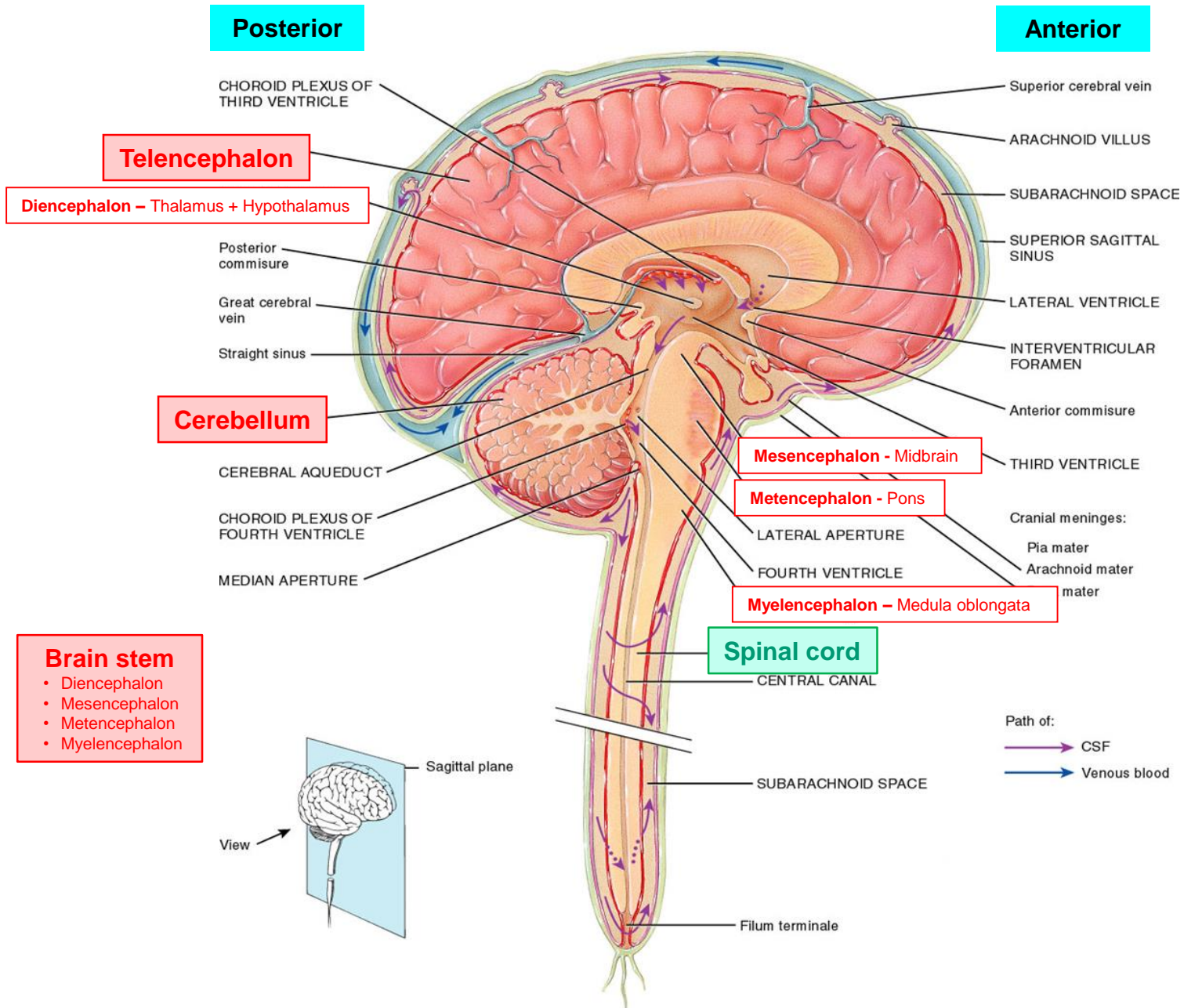


# Nervous system – Peripheral x Central

CNS is Brain and Spinal cord + PNS is everything else



# Central nervous system – Brain + Spinal cord





# Central nervous system – Neuronal organization

## Gray matter

- **Cell bodies**
  - **Nonmyelinated neurons** (dendrites, proximal + distal ends of axons)
  - **Neuroglia** (plasmatic astrocytes, microglia)
  - **Capillaries** (Blood-Brain barrier)
- forms the outer layer of the cerebrum **cerebral cortex**
- also forms **nuclei** deep in the brain = clusters of neuronal cell bodies in CNS
- collections of nuclei can form a **centers** (higher brain function)

## White matter

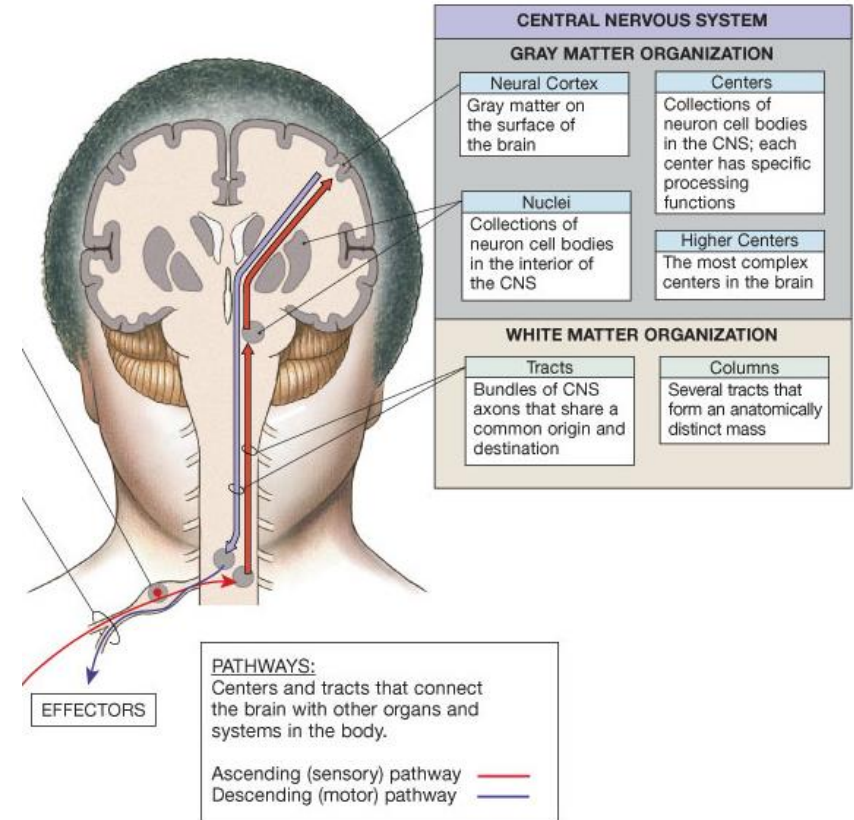
- **Myelinated axons of nerve cells**
- **Neuroglia** (oligodendrocytes, fibrillar astrocytes)
- **Blood capillaries** (lesser density than in the gray matter)

### Brain


- axons are bundled together to form **white matter tracts** conduct nerve impulses from gray region to gray region
- three types of tracts (**commisural, association, projection**)

### Spinal cord

- **sensory and motor tracts** (ascending and descending)



# Central nervous system – Distribution of grey/white matter



## Telencephalon + Cerebellum

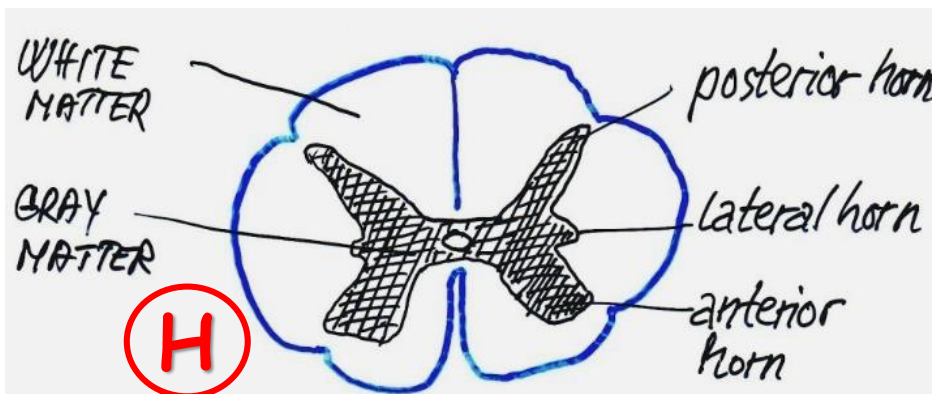
### Gray matter:

- covers surface of both hemispheres forming the folded plate - **cortex**
- forms islands nearby ventricular system – **telencephalic and/or cerebellar nuclei**
- centrally located **also in brain stem**

### White matter:

- occupies the interior of hemispheres

X

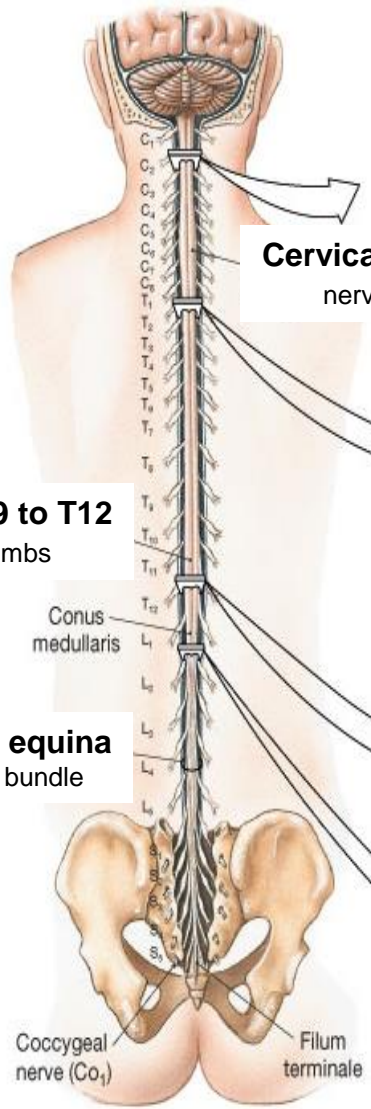


## Spinal cord

### Gray matter:

- **centrally** forms the **core of the organ** - resembles letter **H**
- **at the periphery** it is surrounded by funiculi of the white matter

# Central nervous system – Spinal cord - Anatomy



**Cervical enlargement - C4 to T1**  
nerves to and from upper limbs

**Lumbar enlargement – T9 to T12**  
nerves to and from lower limbs

**Cauda equina**  
nerve bundle

Coccygeal nerve (Co<sub>1</sub>)      Filum terminale

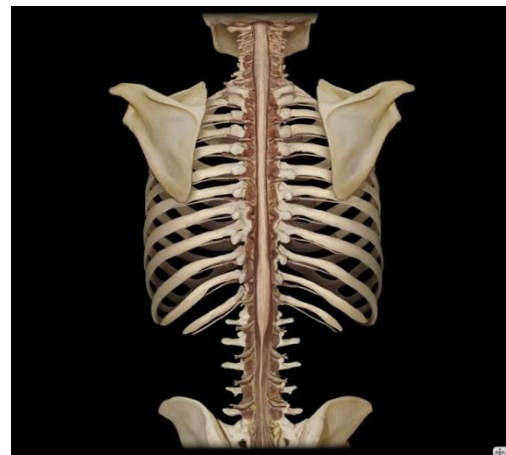(a) Spinal cord, posterior view



Approx. 40-50 cm

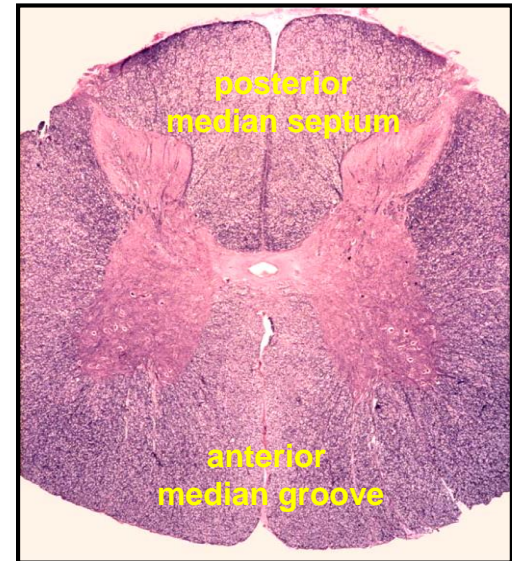
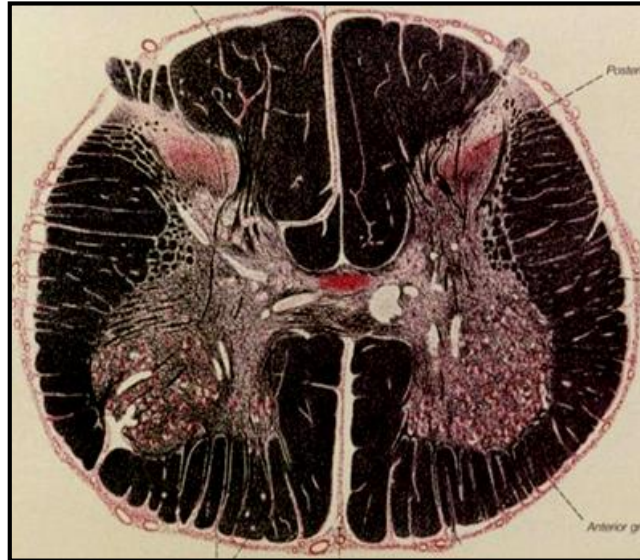
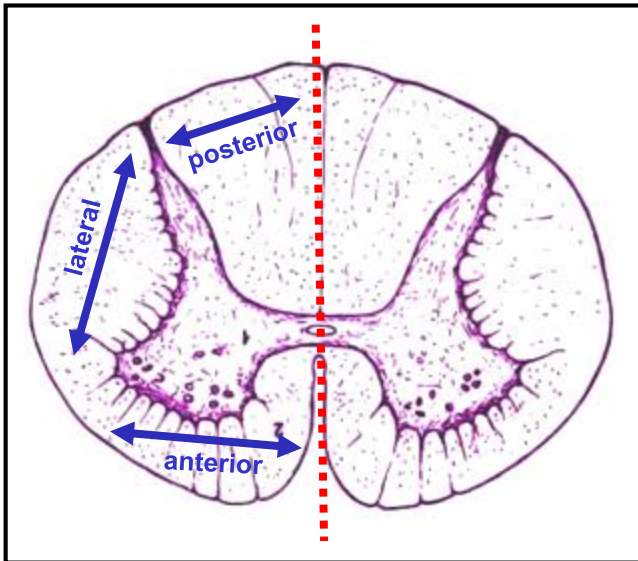
- Cylindrical strand
- Narrowed conically
- Bilaterally symmetrical
- Central canal

31 segments  
+  
31 pairs of *spinal nerves*



# Central nervous system – Spinal cord – White matter

POSTERIOR



## Fasciculi = Funiculi (= Columns)

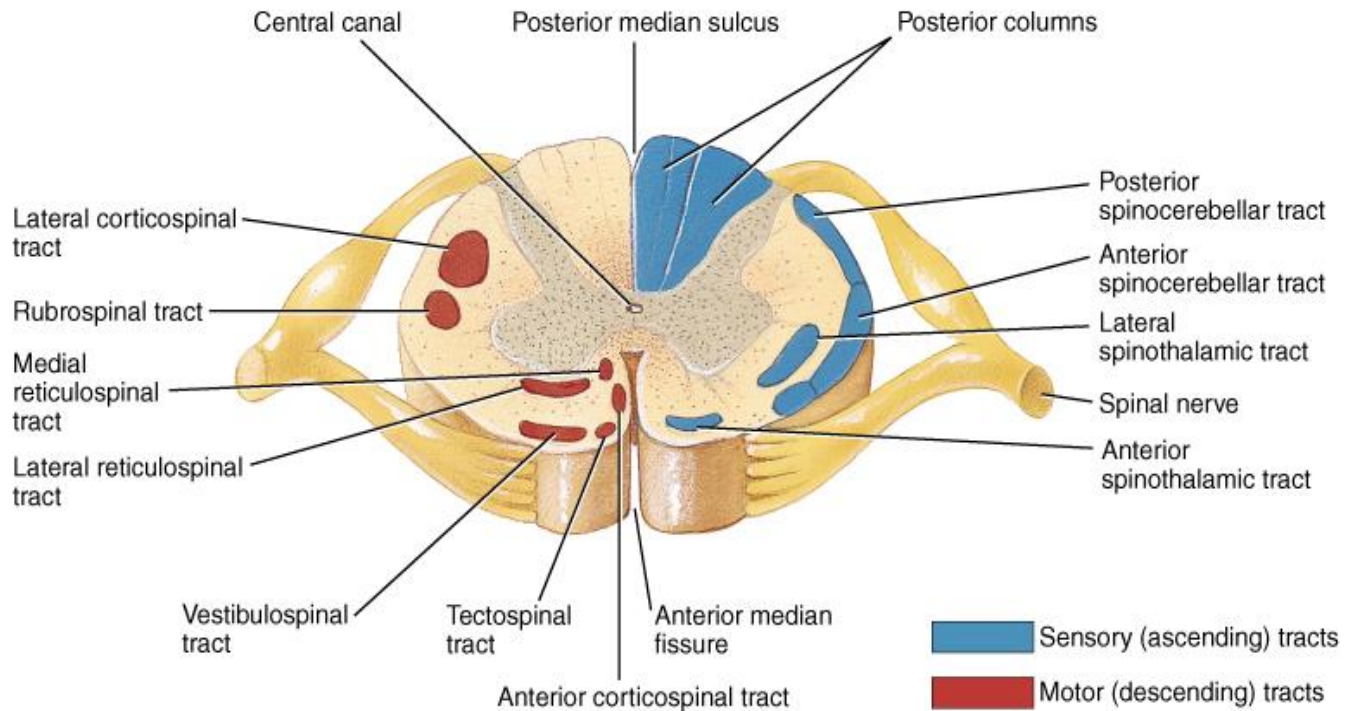
- Anterior – sensitive tracts + motoric tracts
- Lateral – sensitive tracts + motoric tracts
- Posterior – sensitive tracts

Sensitive = Ascending  
Motoric = Descending


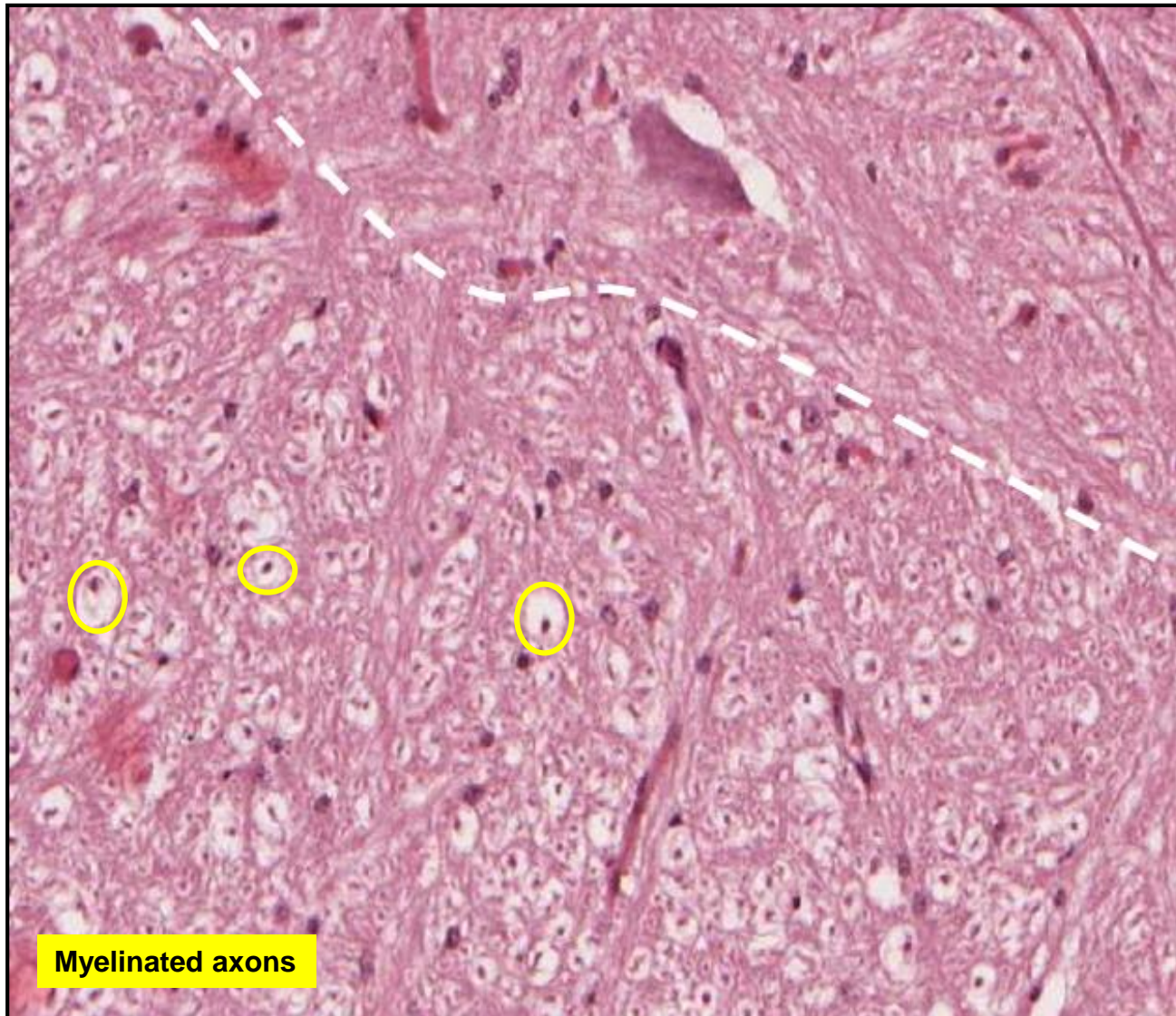


# Spinal cord – White matter - Tracts

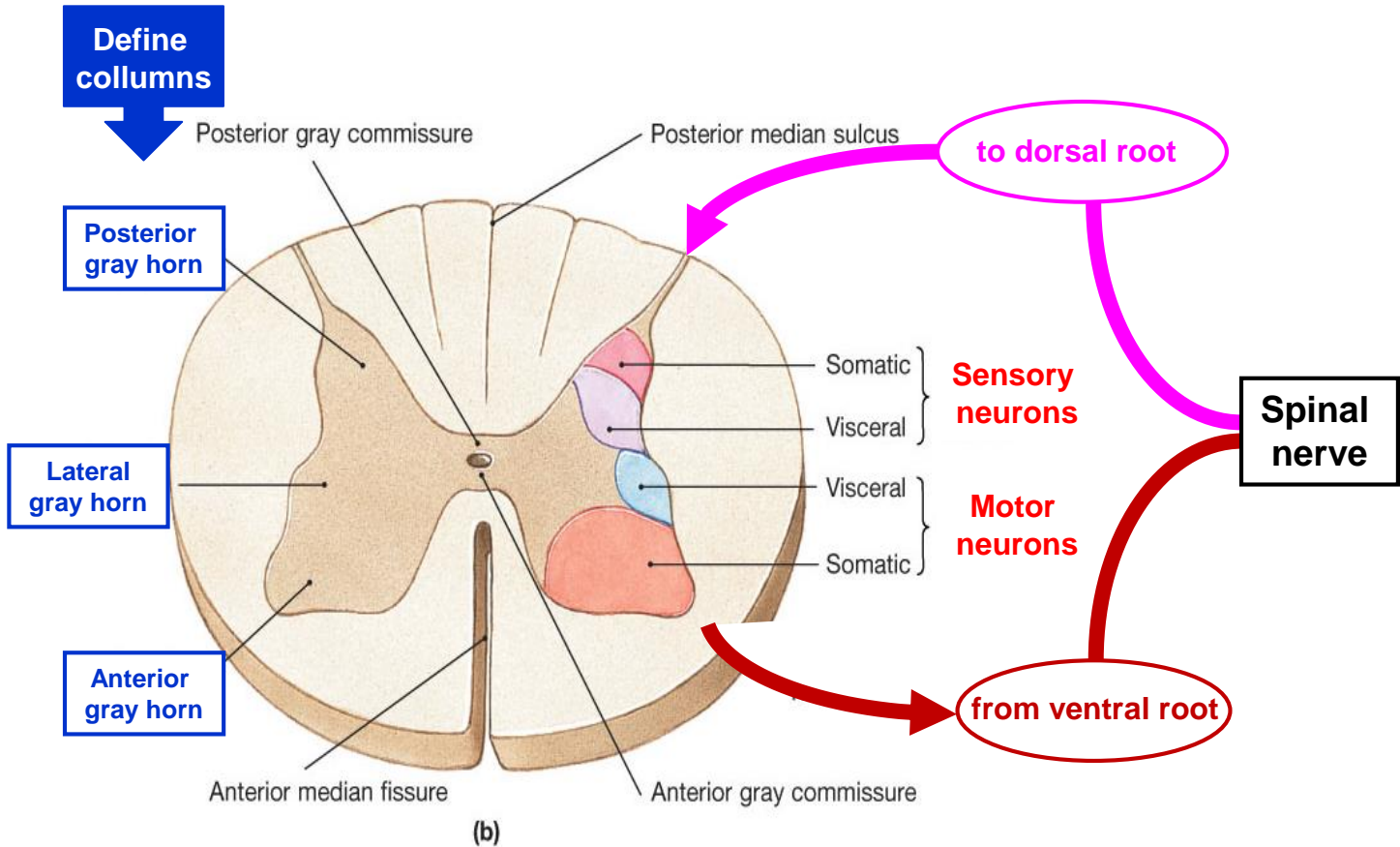
Only for demonstration purpose – no need of memorizing !!!



# Spinal cord – White matter



# Spinal cord – Gray matter – Organization



## Neurons in gray matter – all are multipolar

**Motor neurons (radicular)**

- in the anterior (ventral) horns
- stellate shape, 150 µm in diameter
- send off long myelinated axons ending on muscle fibres

**Funicular cells**

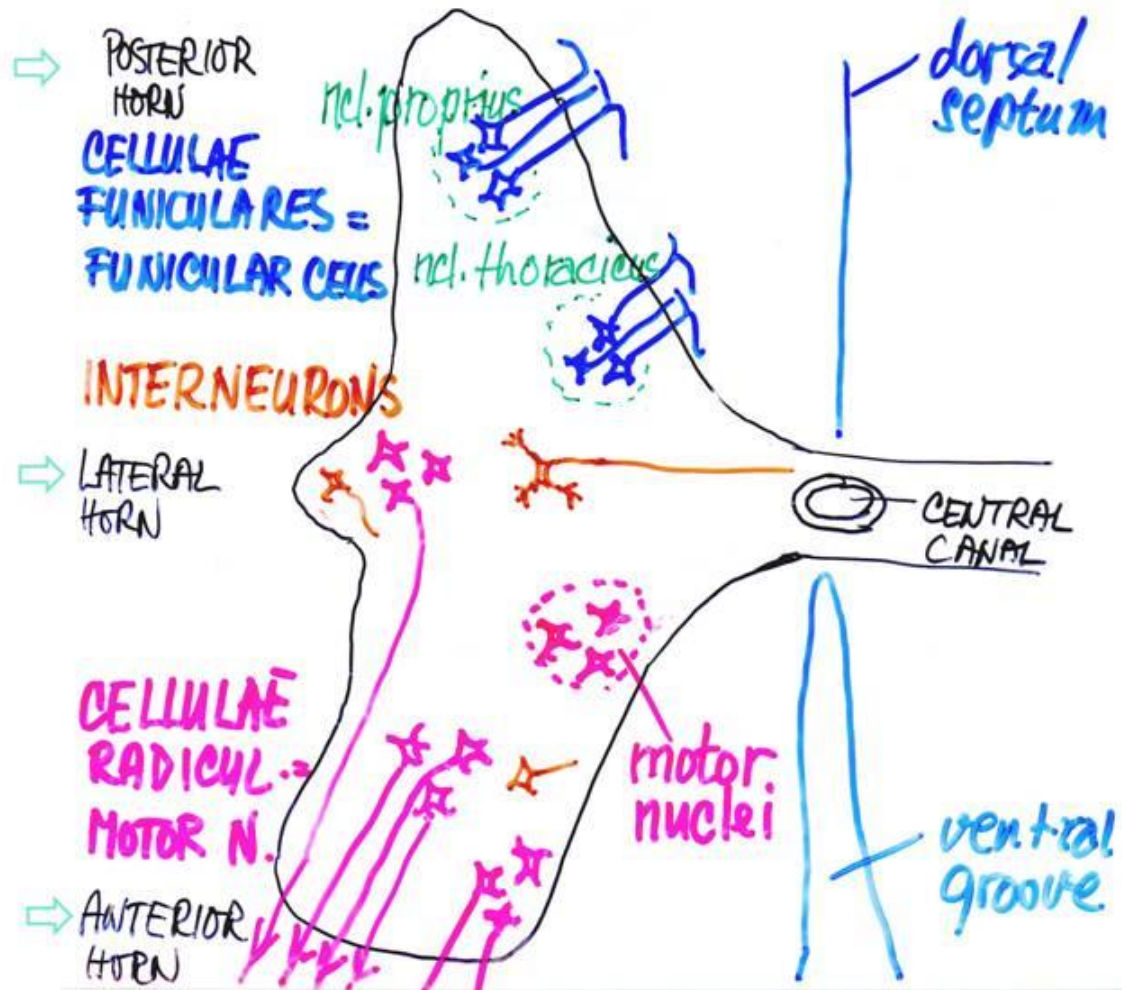
- mainly in the posterior horns
- their axons enter the white matter and connect to other segments of SC and to brain stem

**Interneurons**

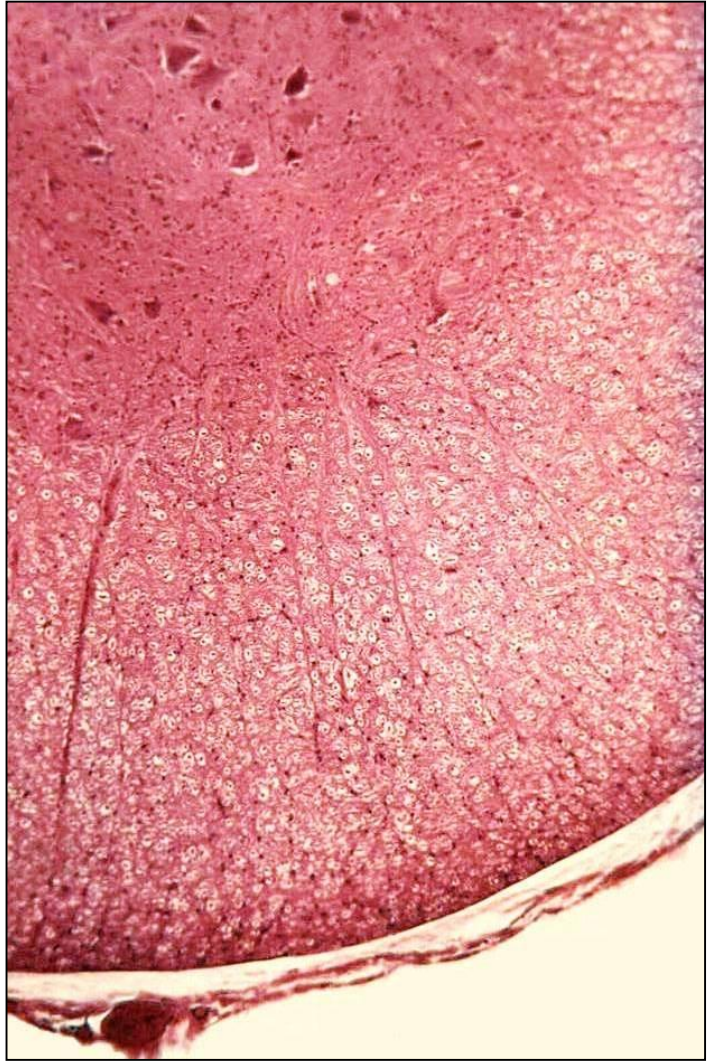
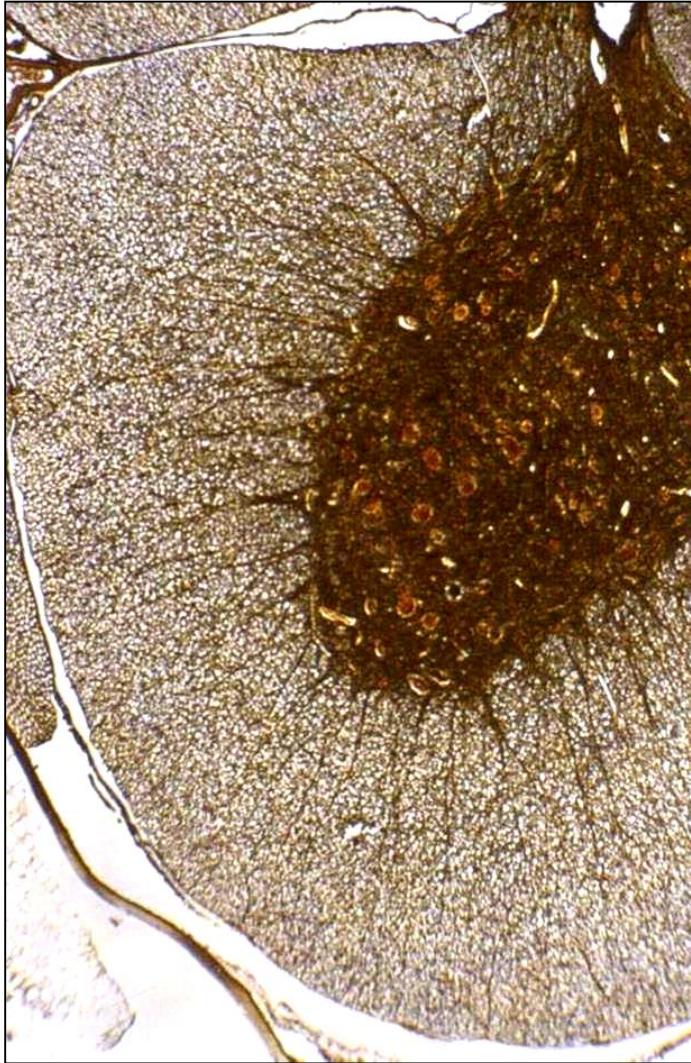
- small neurons
- diffusely distributed among motor and funicular cells



# Spinal cord – Gray matter – Organization

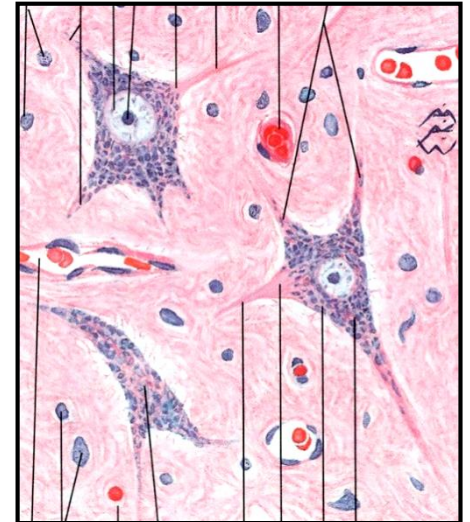
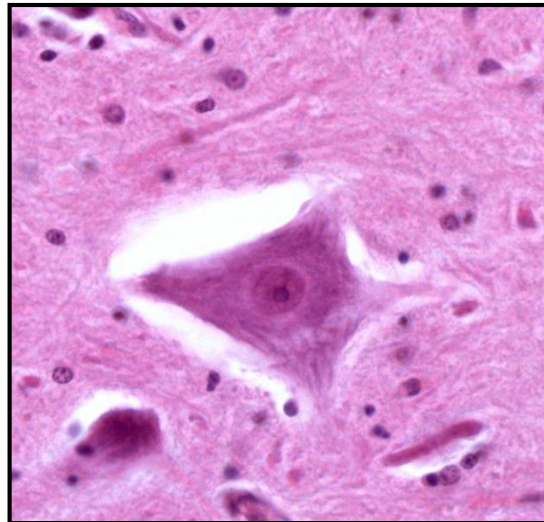
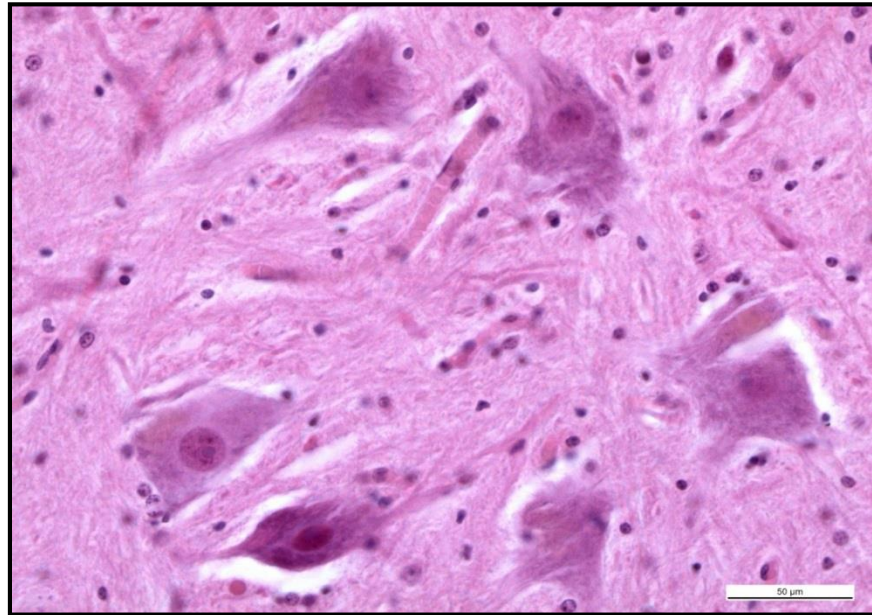
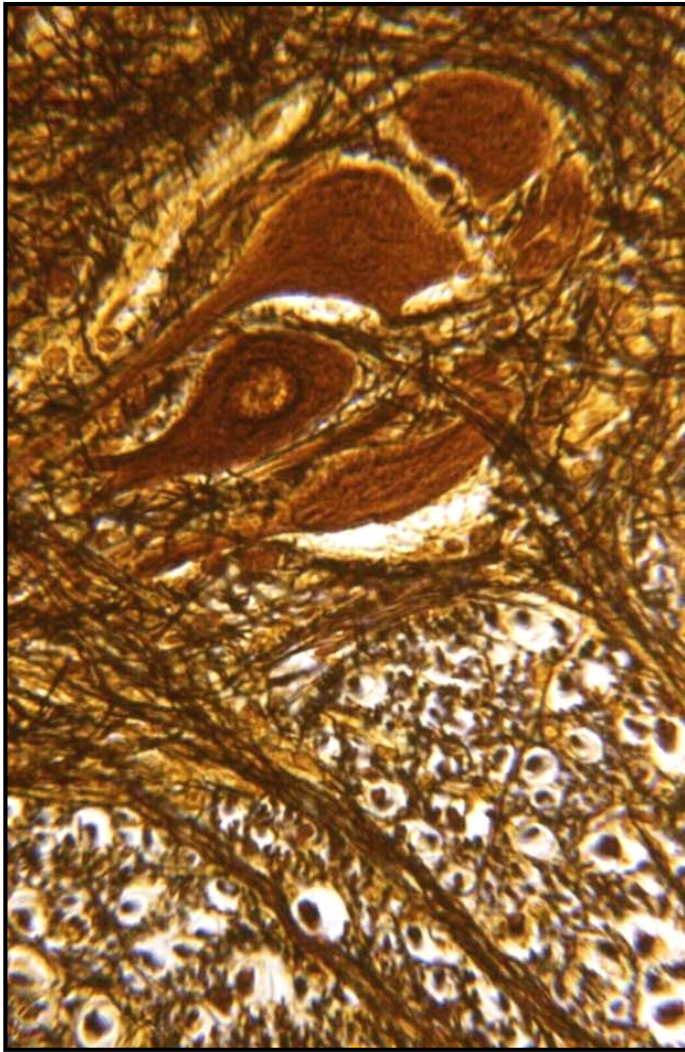


# Spinal cord – Gray matter



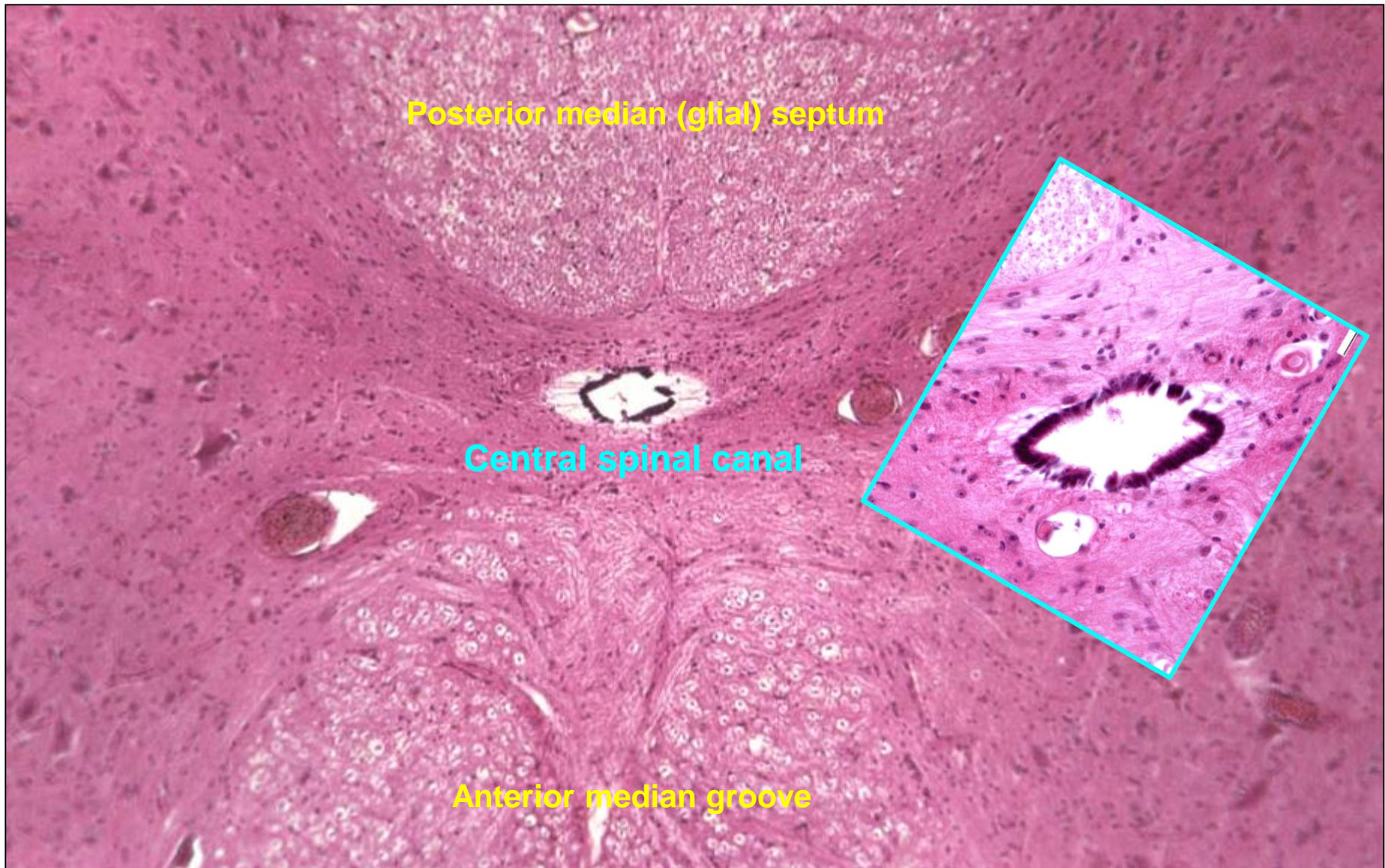


# Spinal cord – Gray matter – Motor neurons



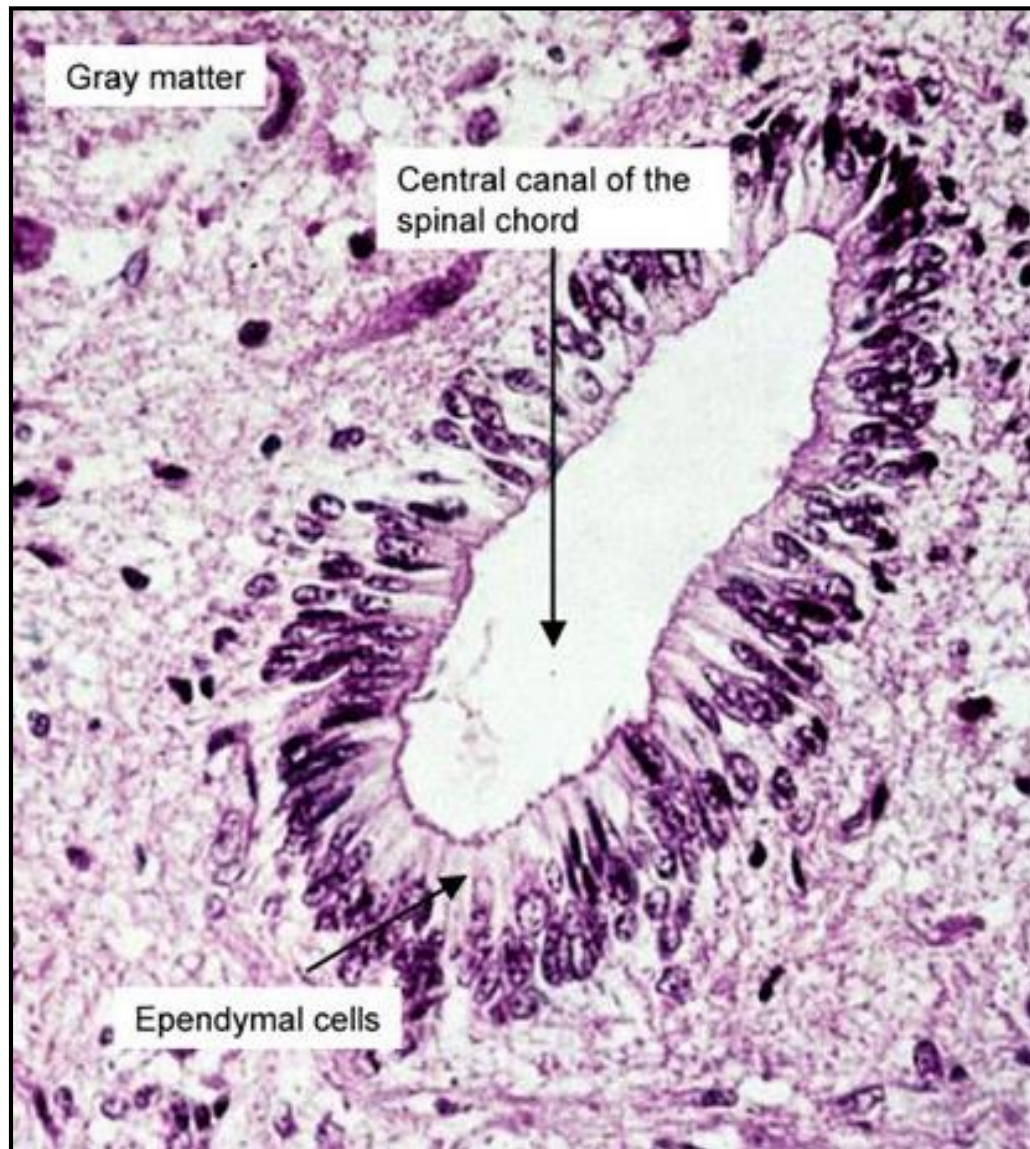


# Spinal cord – Central spinal canal





# Spinal cord – Central spinal canal

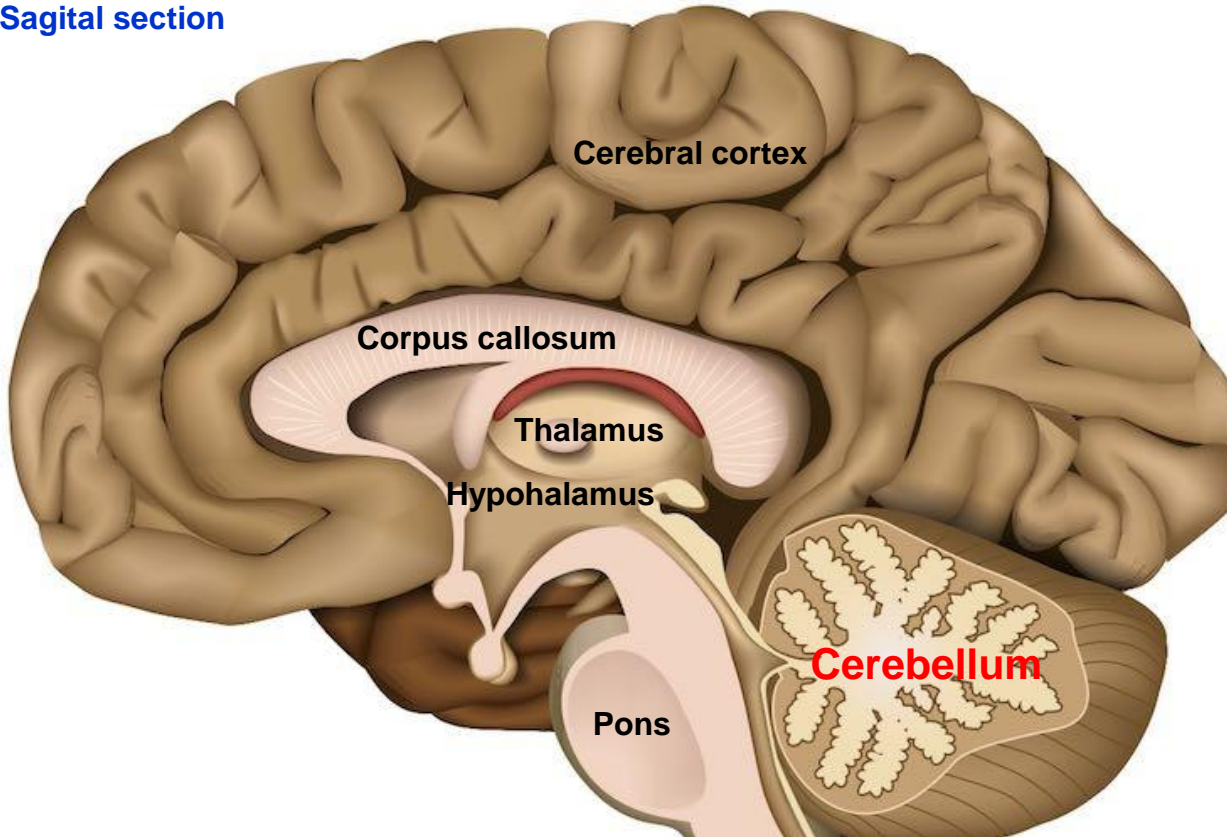


# Cerebellum

## Function

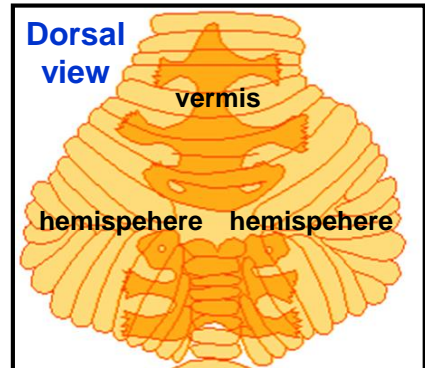
- co-ordination of voluntary movements and helping to maintain balance
- allows for smooth, co-ordinated movements by constantly adjusting muscle tone and posture

Sagittal section

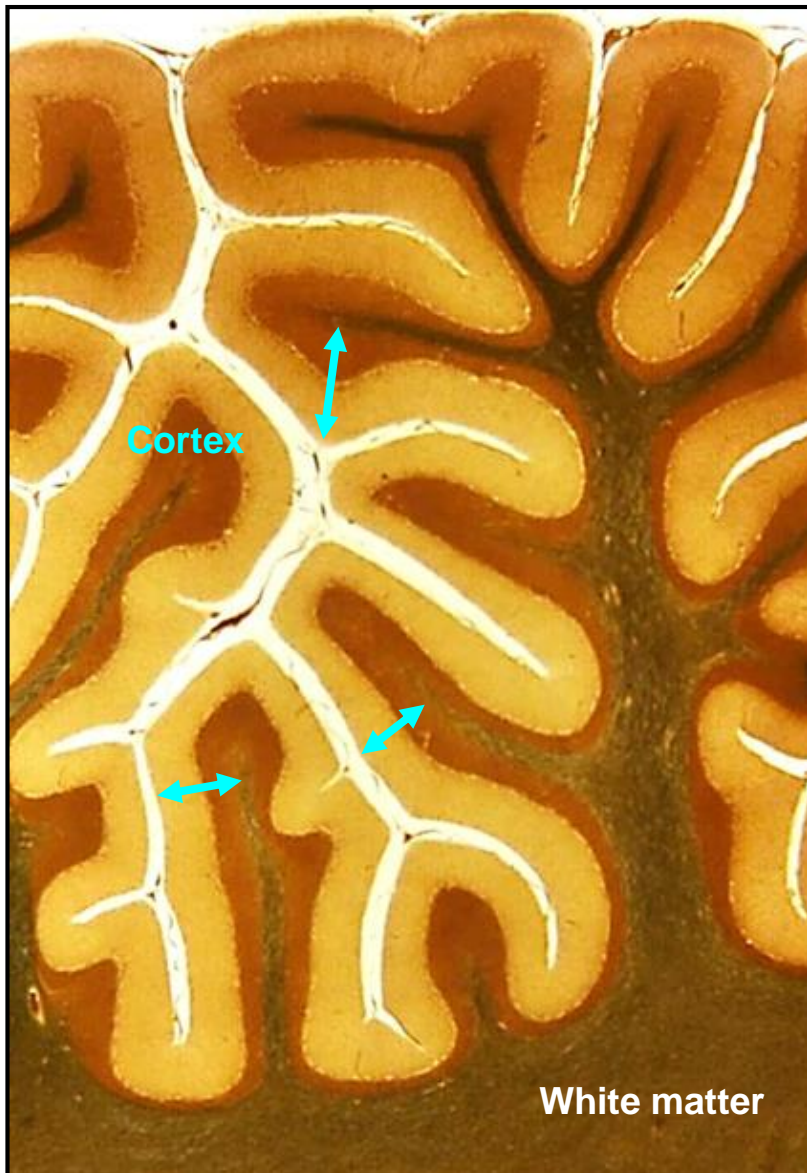


**Weight:** 130 grams  
**Surface area:** 0,10 - 0,15 m<sup>2</sup>

Dorsal view



## Cerebellum – Gray matter

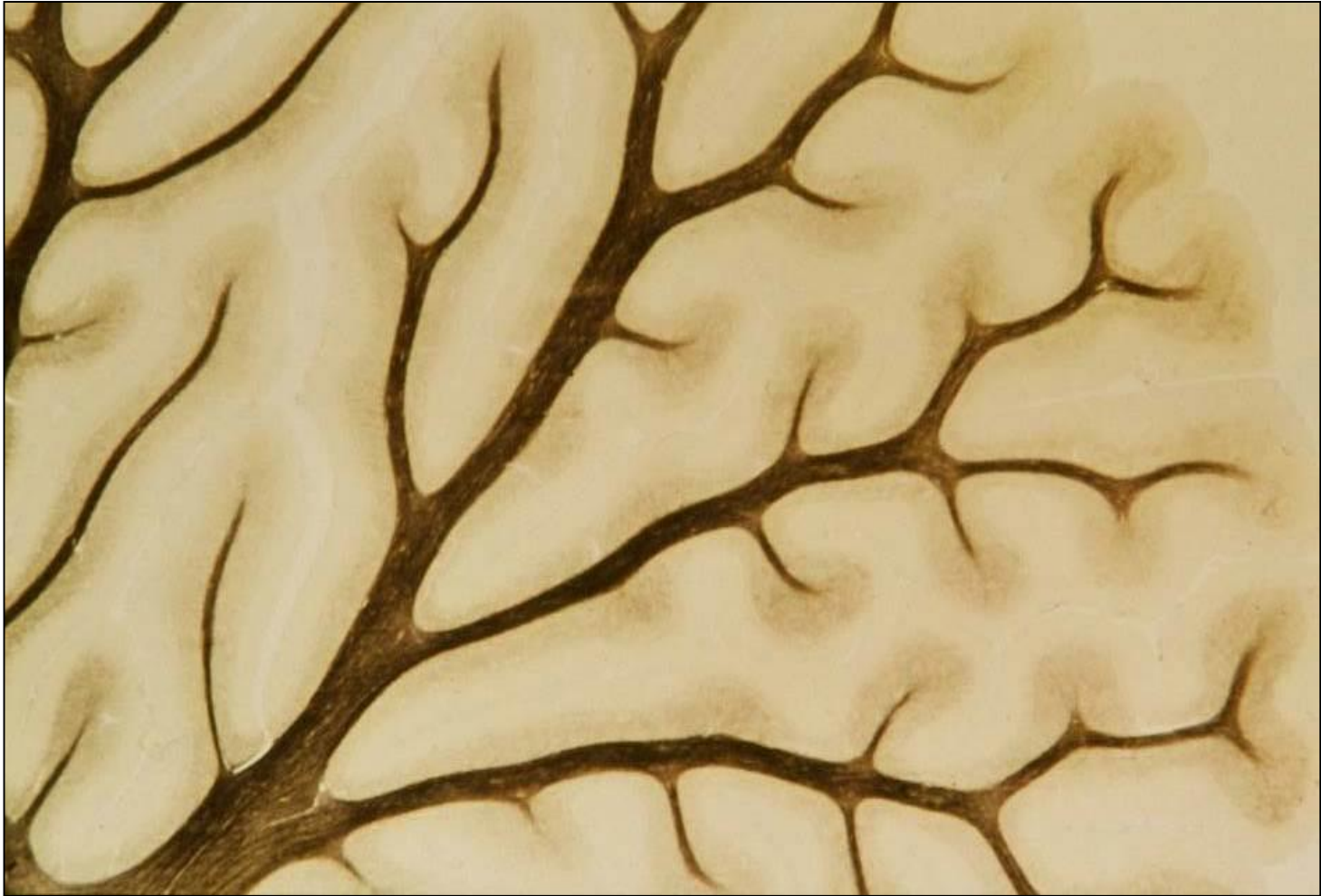

### Gray matter

- **Cortex at the surface** (1 mm thick)
- **Nuclei in white matter** (nucleus dentatus, emboliformis, globus, and fastigii)



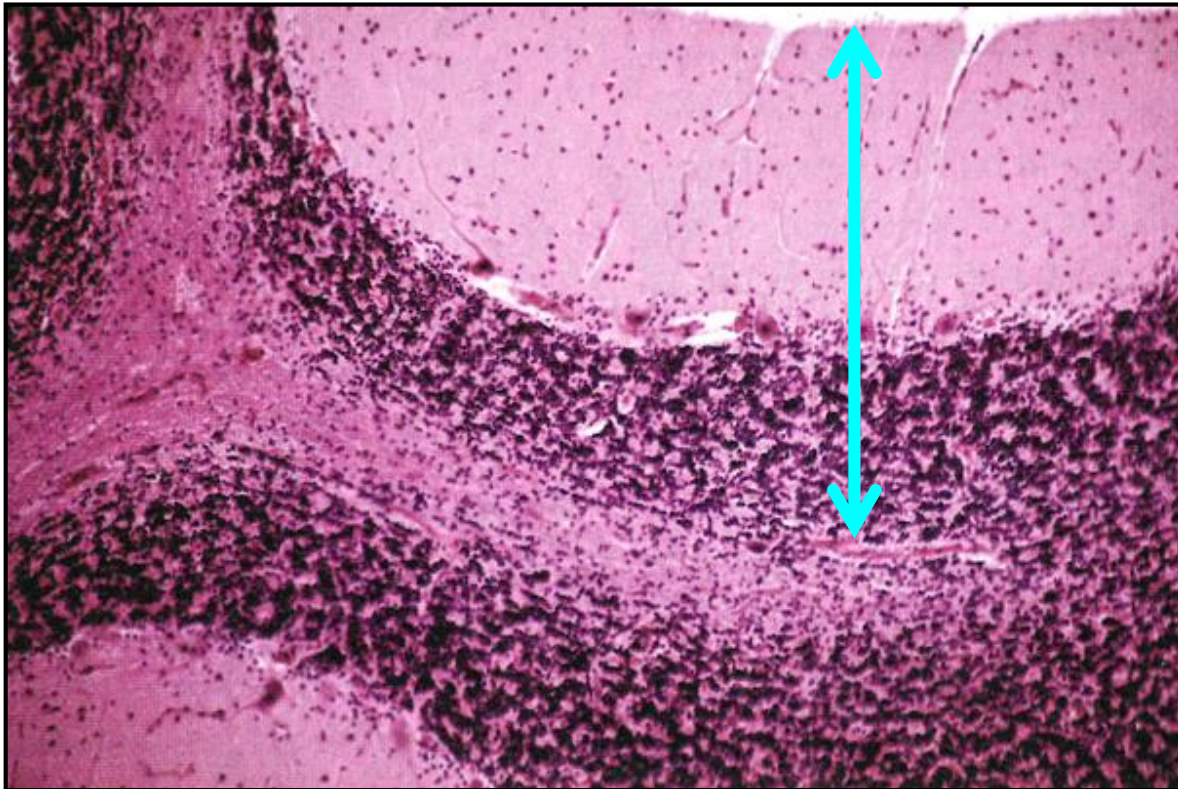
## Cerebellum – White matter



„Arbor vitae“ – white matter



## Cerebellum – Cortex

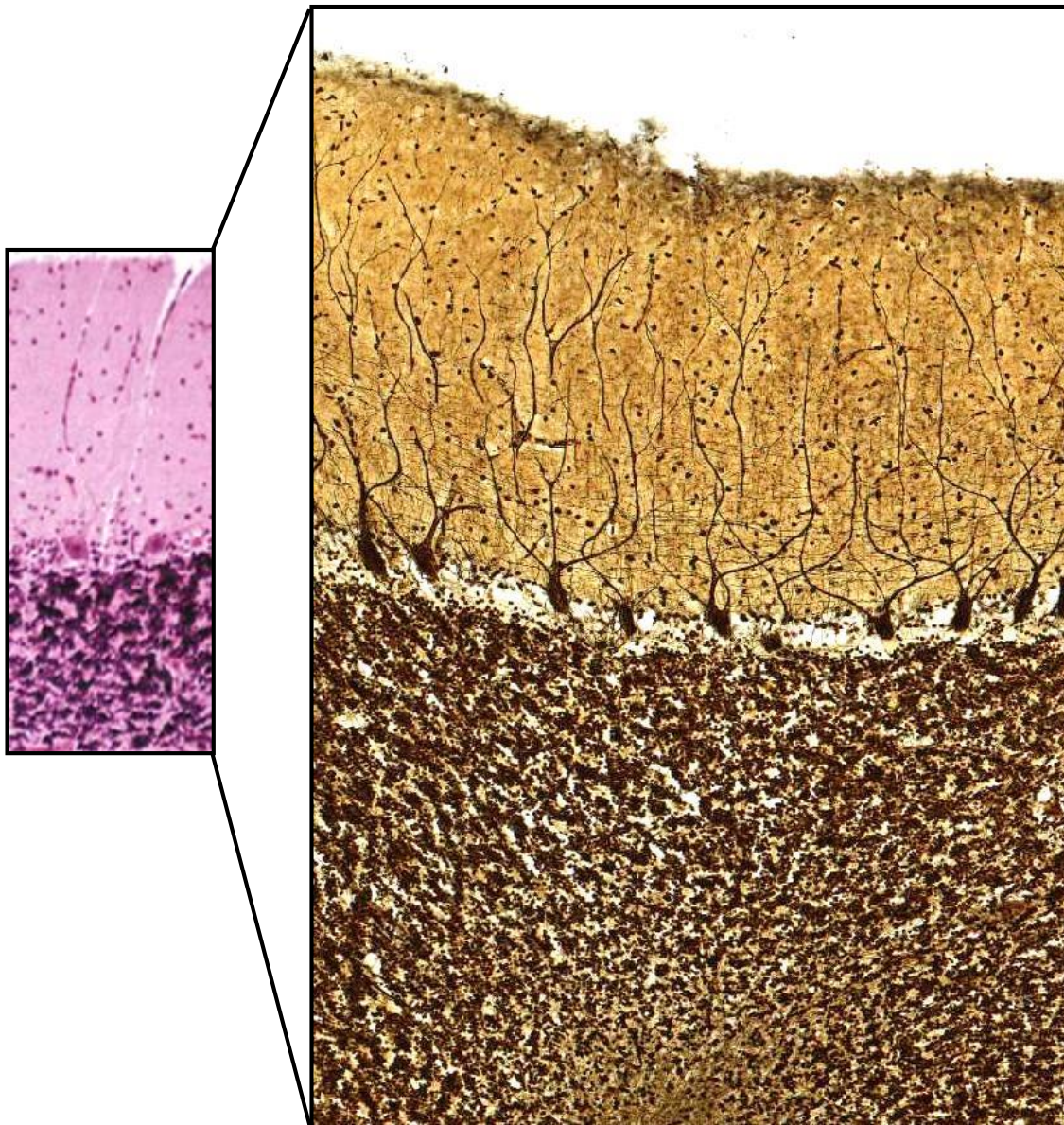


**Molecular layer**  
(*stratum moleculare*)

**Purkinje cell layer**  
(*stratum gangiosum*)

**Granule cell layer**  
(*stratum granulosum*)

# Cerebellum – Cortex - Cells



## Molecular layer (*stratum moleculare*)

- Basket cells
- Stellate cells

## Purkinje cell layer (*stratum gangliosum*)

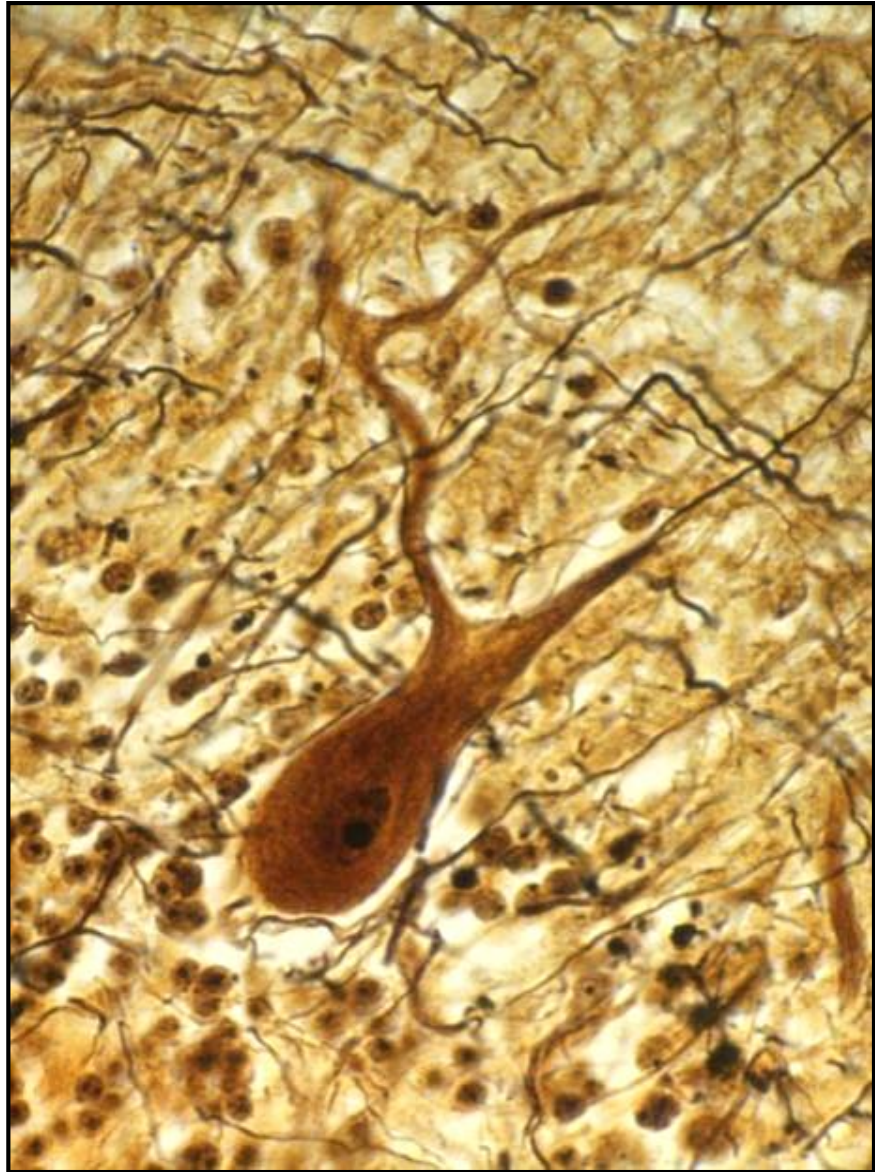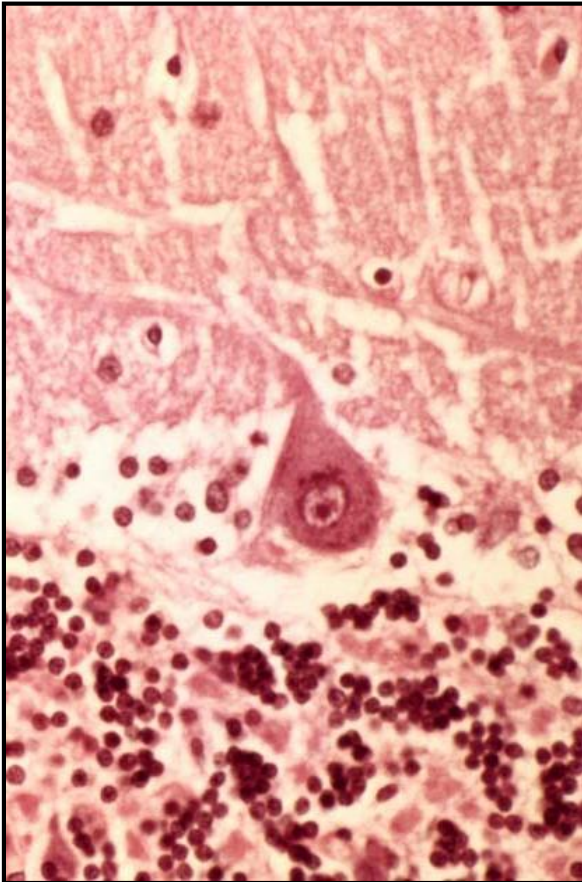
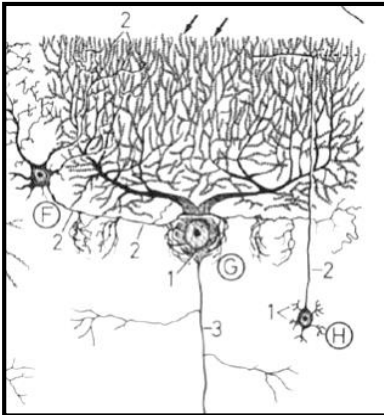
- Perikaryons of Purkinje cells
- Golgi (Bergman) glial cells

## Granule cell layer (*stratum granulosum*)

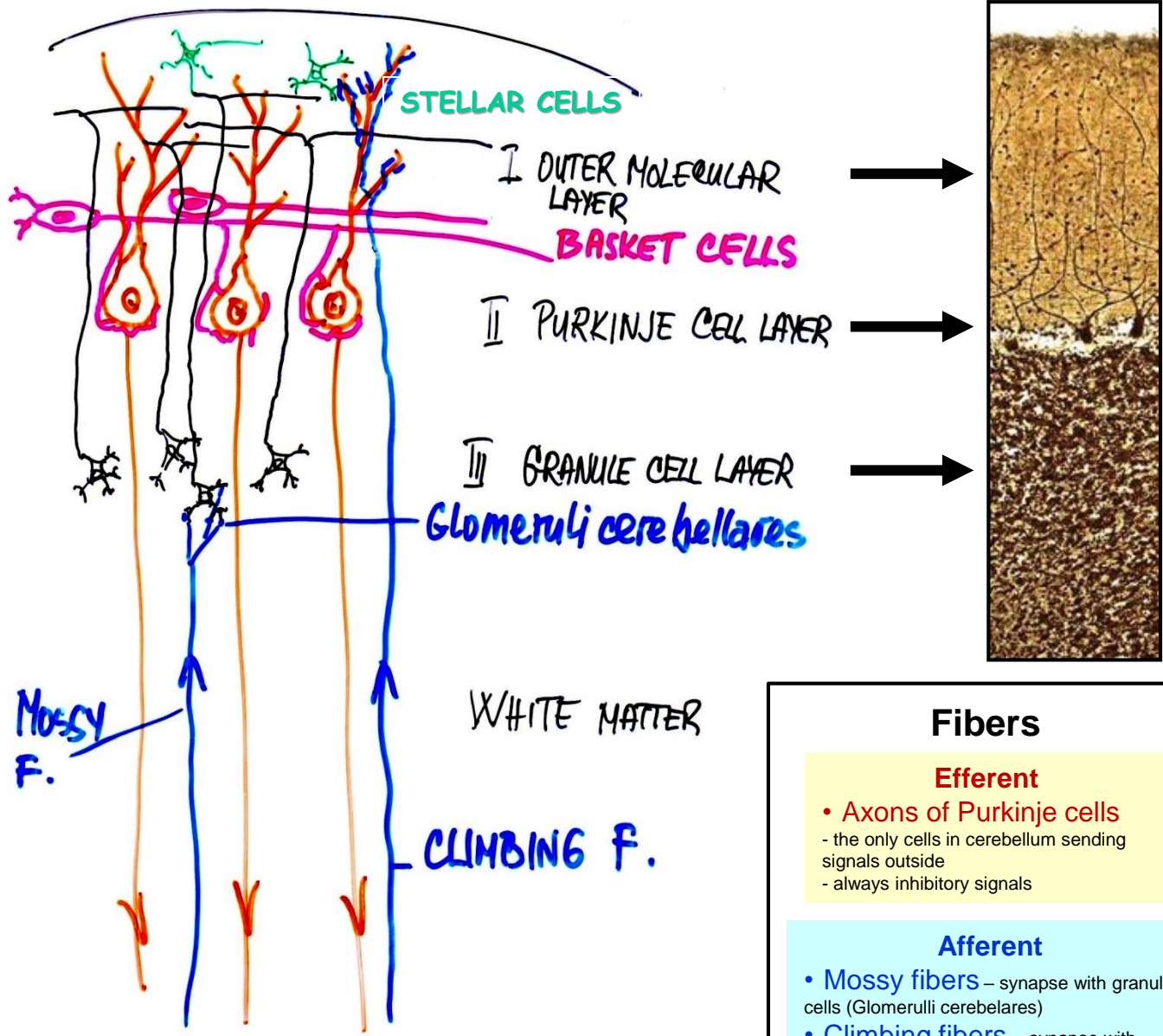
- Granule cells
- Golgi (Bergman) glial cells



# Cerebellum – Purkinje cells



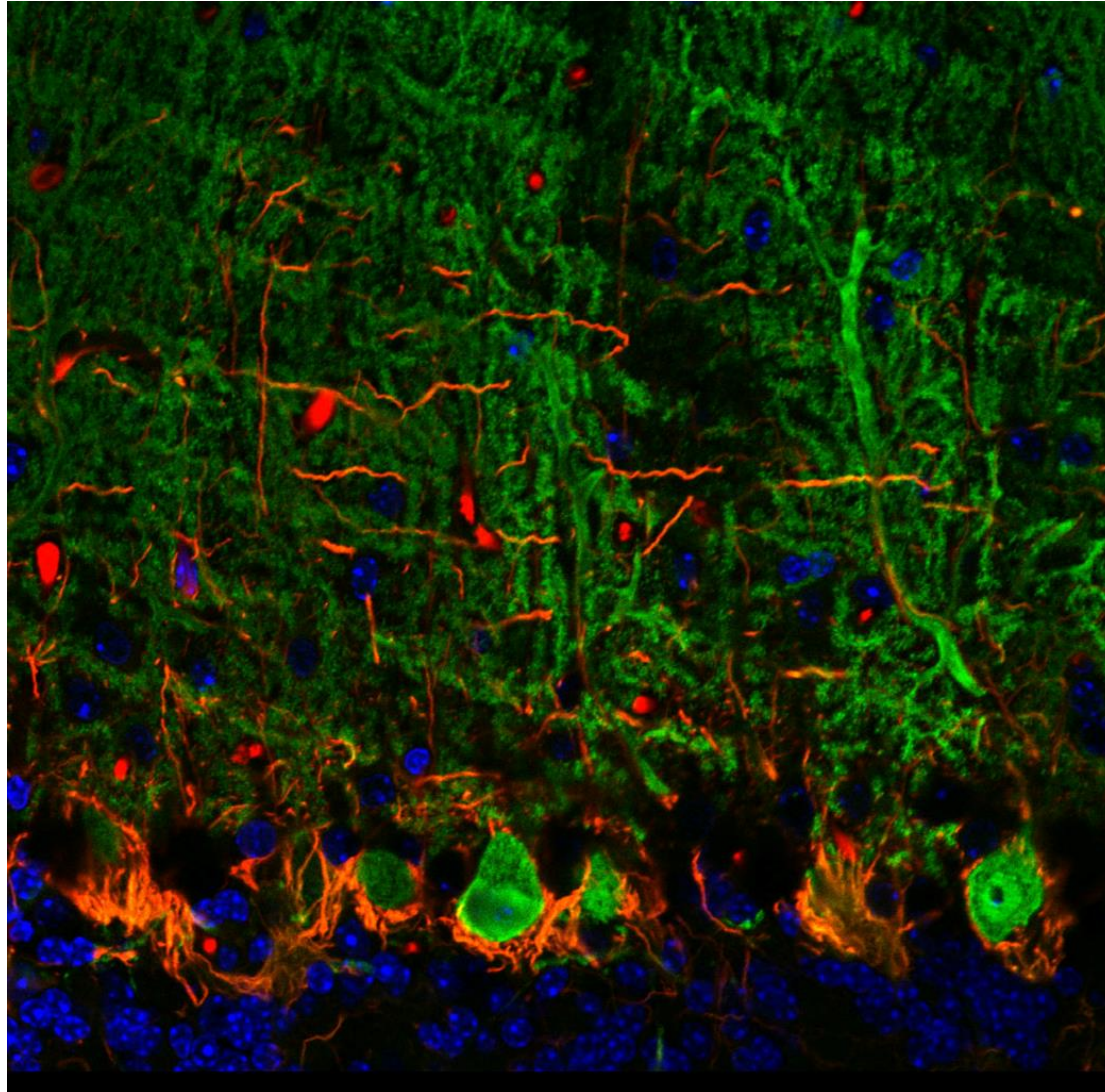
# Cerebellum – Cortex – Cells and Fibers



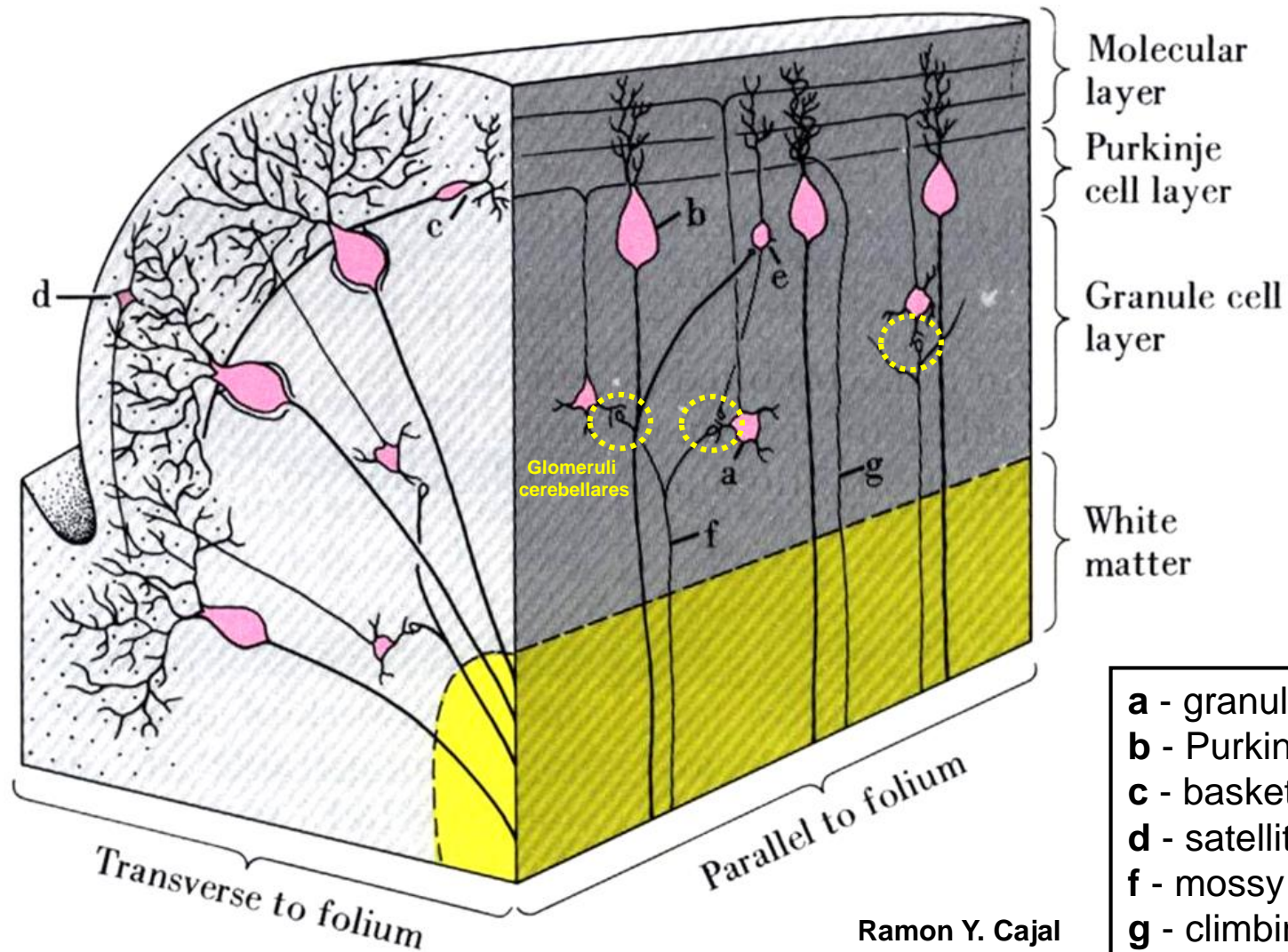
Fibers	
<b>Efferent</b>	
<ul style="list-style-type: none"> <li>• <b>Axons of Purkinje cells</b></li> <li>- the only cells in cerebellum sending signals outside</li> <li>- always inhibitory signals</li> </ul>	
<b>Afferent</b>	
<ul style="list-style-type: none"> <li>• <b>Mossy fibers</b> – synapse with granule cells (Glomerulli cerebellares)</li> <li>• <b>Climbing fibers</b> – synapse with dendrites of Purkinje cells</li> </ul>	



# Cerebellum – Cortex – Cells and Fibers



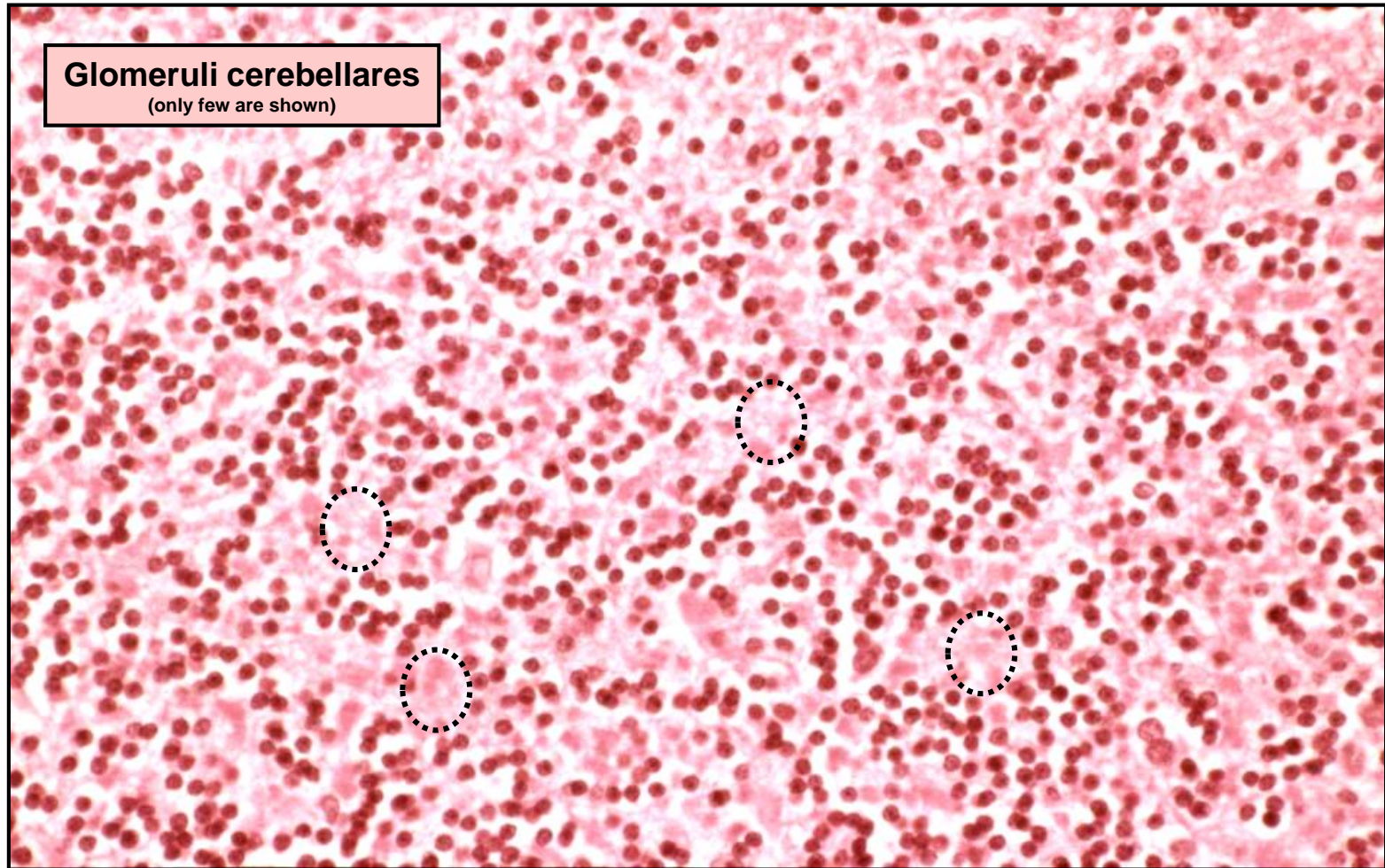
# Cerebellum – Cortex – Cells and Fibers



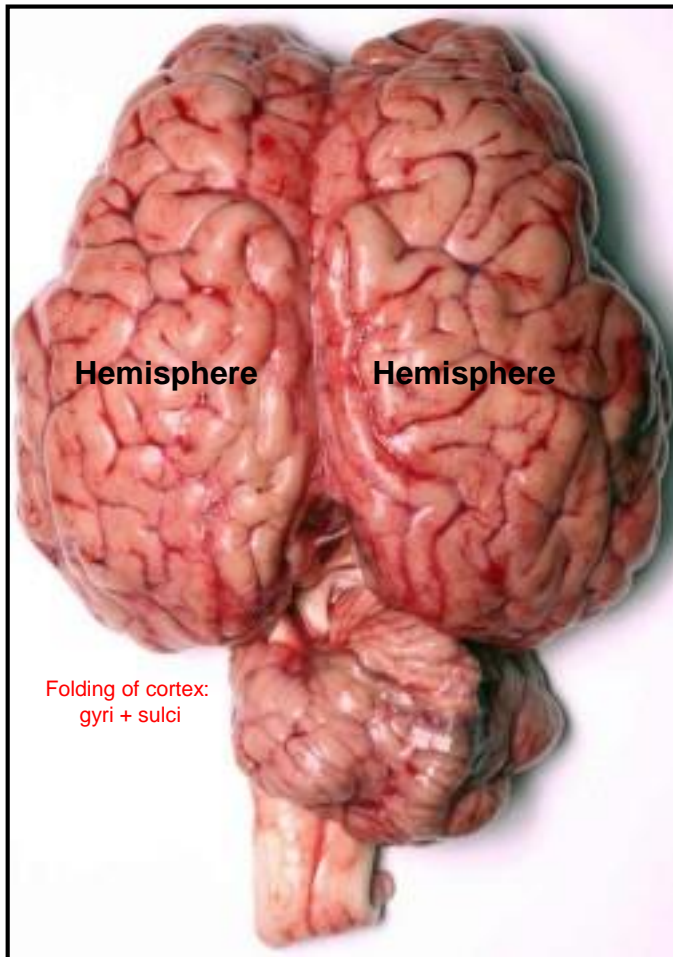
Ramon Y. Cajal



# Cerebellum – Cortex – Cells and Fibers



# Telencephalon



## Gray matter

- Cortex at the surface
- Nuclei in white matter

## White matter

- Among the cortex and nuclei



# Telencephalon – Cerebral cortex

## Functions:

- perception and conscious understanding of all sensations
- integration of different sensory modalities
- higher cognitive and advanced intellectual functions
- responsible for features such as emotion, personality and intellect
- involved in planning and executing complex motor activities

## Overall characteristics:

- about 80% of the mass of the brain
- surface area about 0.20 – 0.25 m<sup>2</sup>
- thickness about 2 - 5 mm
- contains about 10 billion neurons

## Isocortex:

- = **neocortex** (phylogenetically youngest)
- only in mammals
- 90% of the cortex in humans
- **6 distinguishable layers of cells**

## Allocortex:

- = **archicortex** + **paleocortex**
- less layers of cells  
(e.g. olfactory cortex – 3 layers, hippocampus – 1 layer)

# Telencephalon – Cerebral cortex – Neuron types + layers

## Pyramidal

- efferent – projecting neurons
- triangular perikaryon (different size)
- axons with myelin sheets
- axons travel to different cortical layers and to subcortical areas

## Non-pyramidal

- variety of different cells
- act as interneurons
- axons stay in the layer with their perikayons  
(e.g. fusiform cells, granule (stellate) cells, horizontal cells (Cajal), vertical cells (Martinotti))

### 1. Molecular layer

- horizontal cells (of Cajal)

### 2. Outer granular layer

- small granular (stellate) cells

### 3. Outer pyramidal layer

- pyramidal cells (various sizes)

### 4. Inner granular layer

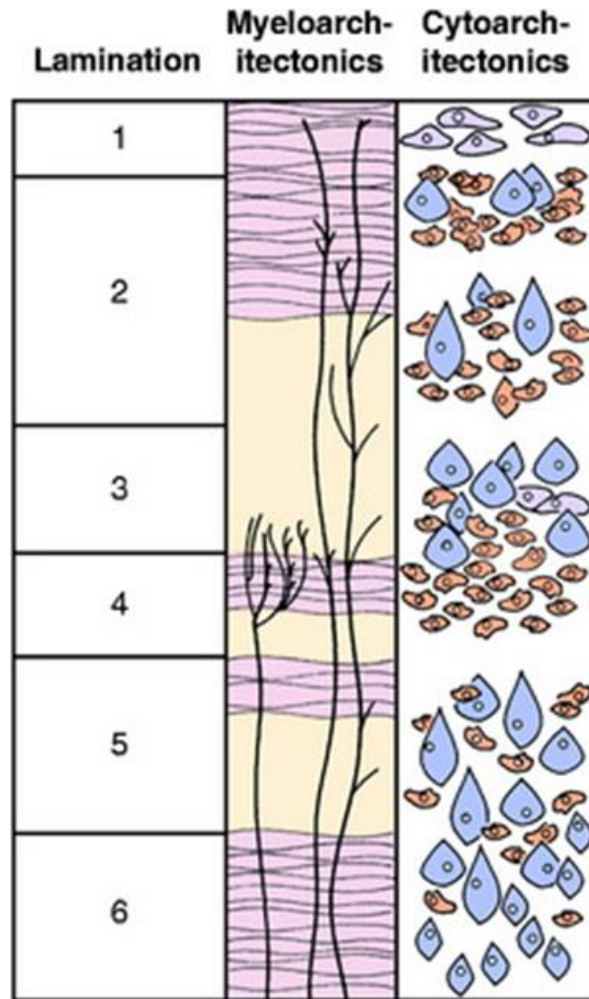
- small granular (stellate) cells

### 5. Inner pyramidal layer (ganglionic)

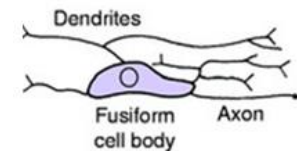
- large pyramidal cells (various sizes)

### 6. Multiform layer

- fusiform cells
- small granular (stellate) cells
- vertical cells (of Martinotti)

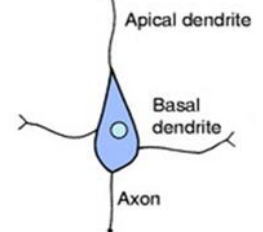


Horizontal neuron of Cajal

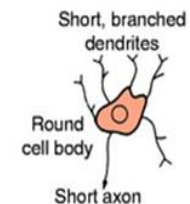


Processes parallel to the surface of the cortex

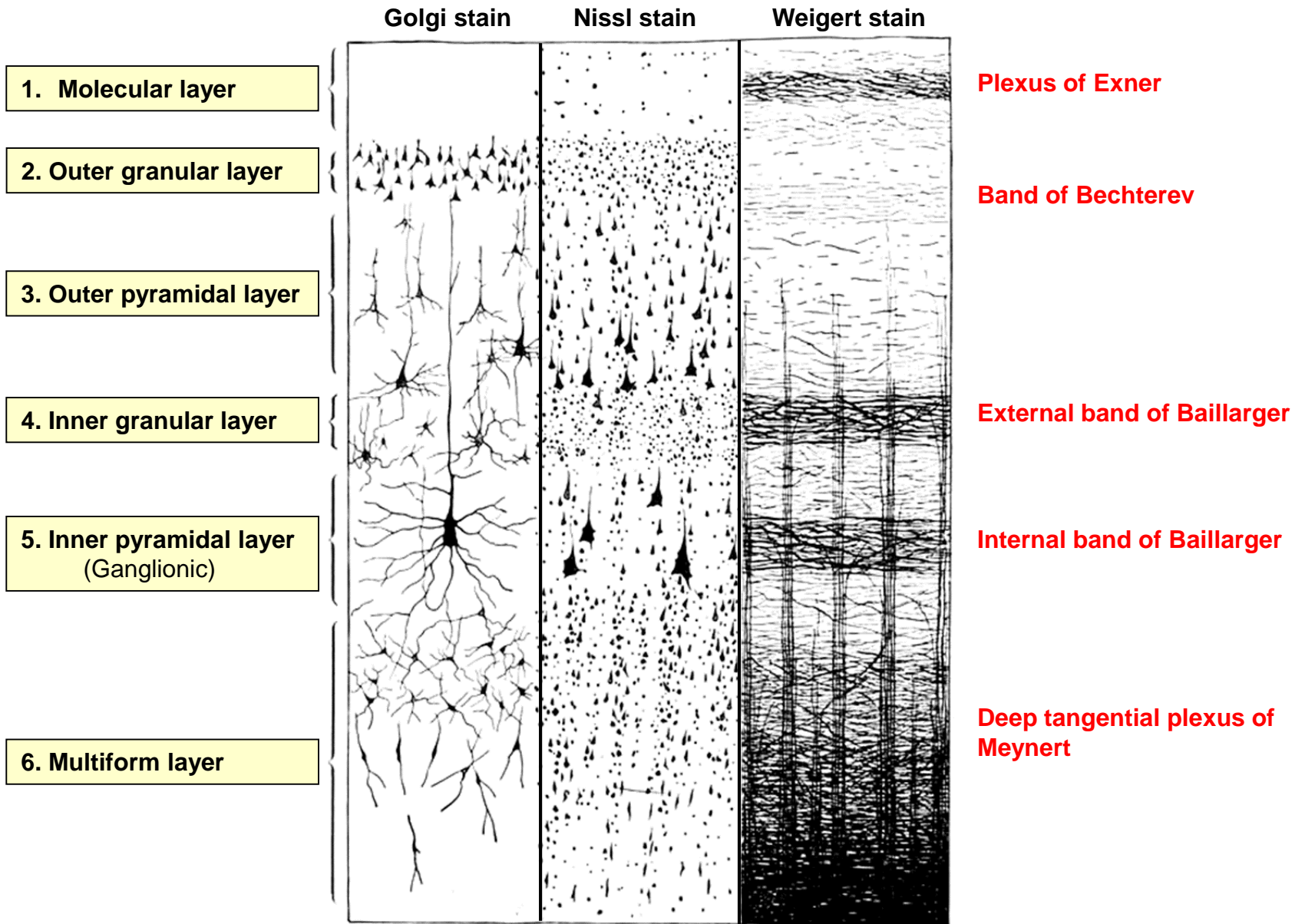
Pyramidal neuron  
10-50  $\mu\text{m}$



Stellate (granular) neuron

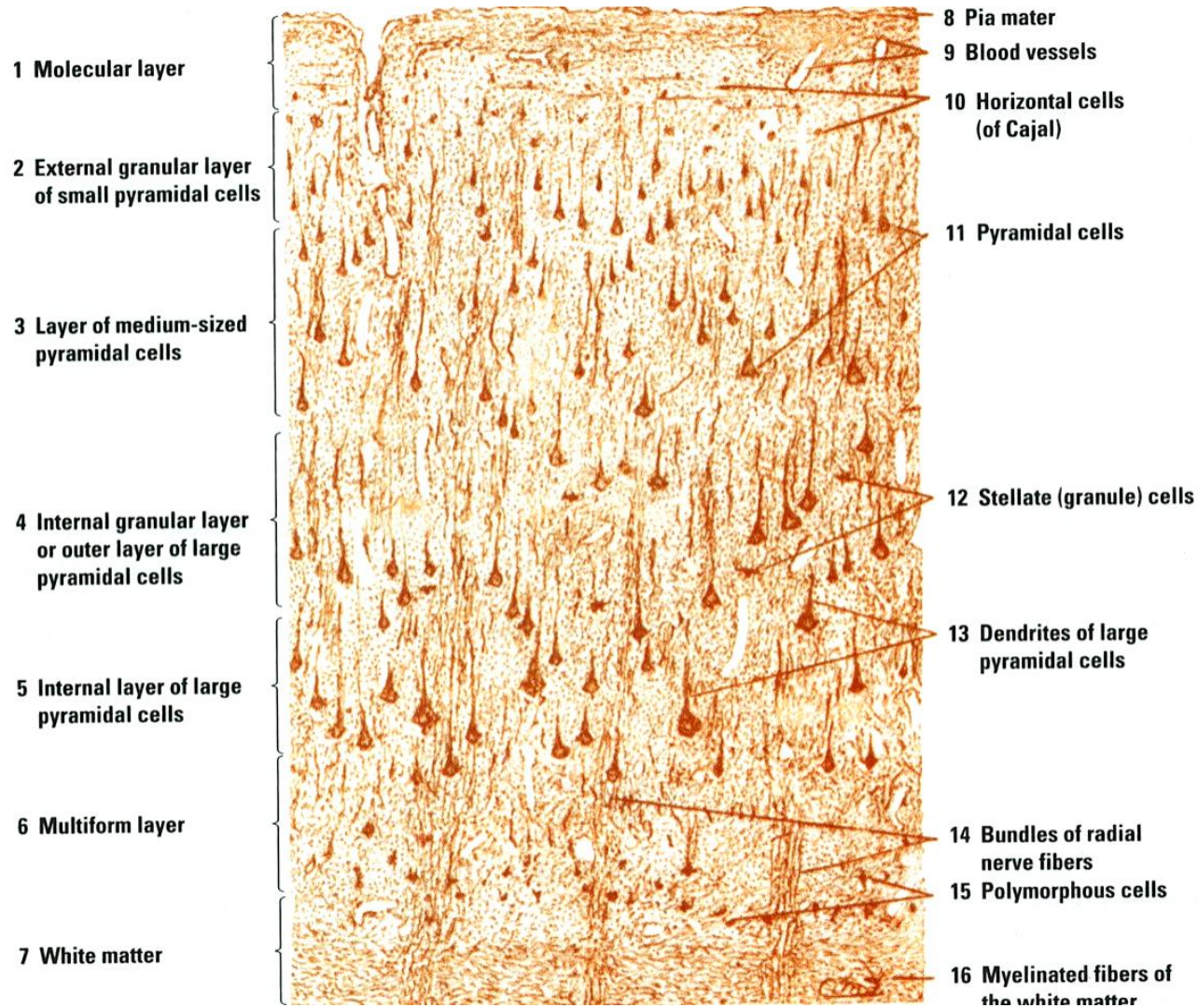


# Telencephalon – Cerebral cortex – Cell types + Plexuses



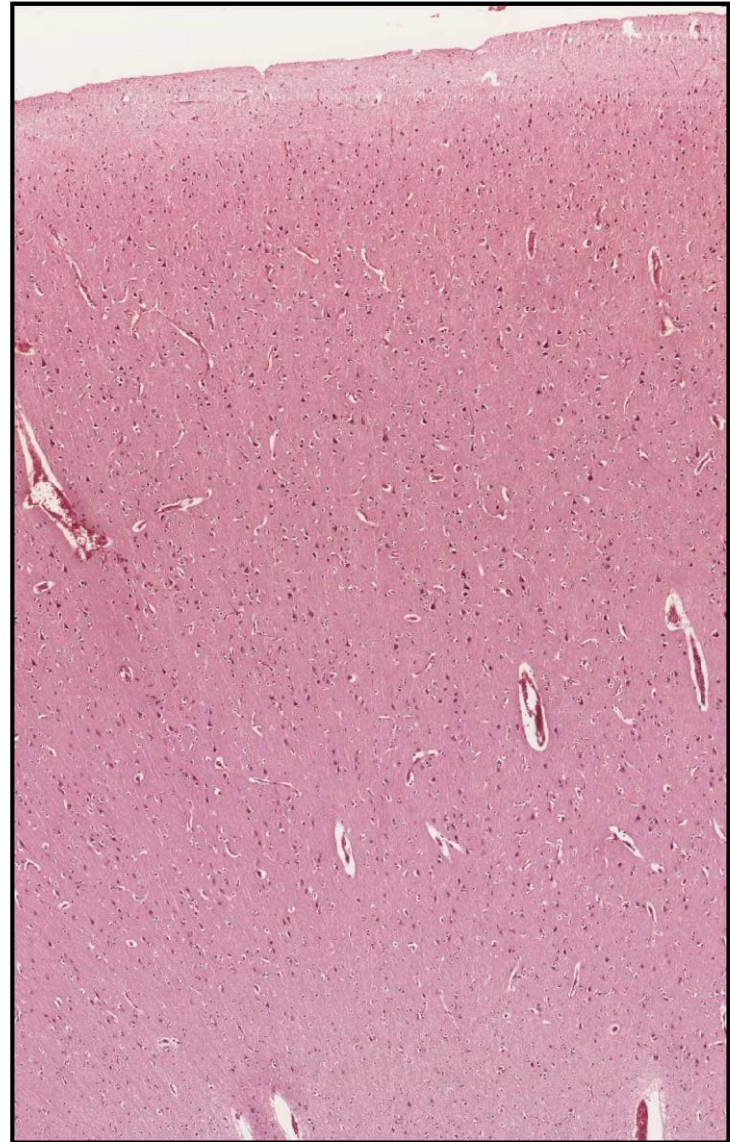
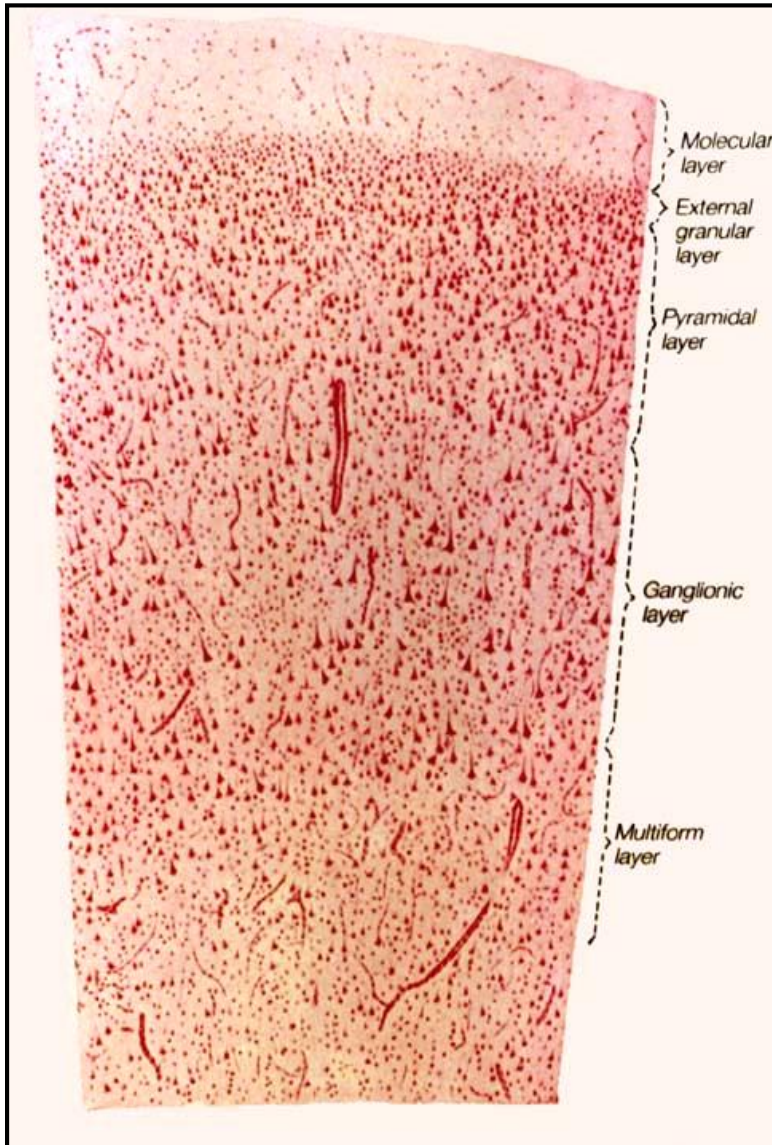


# Telencephalon - Isocortex



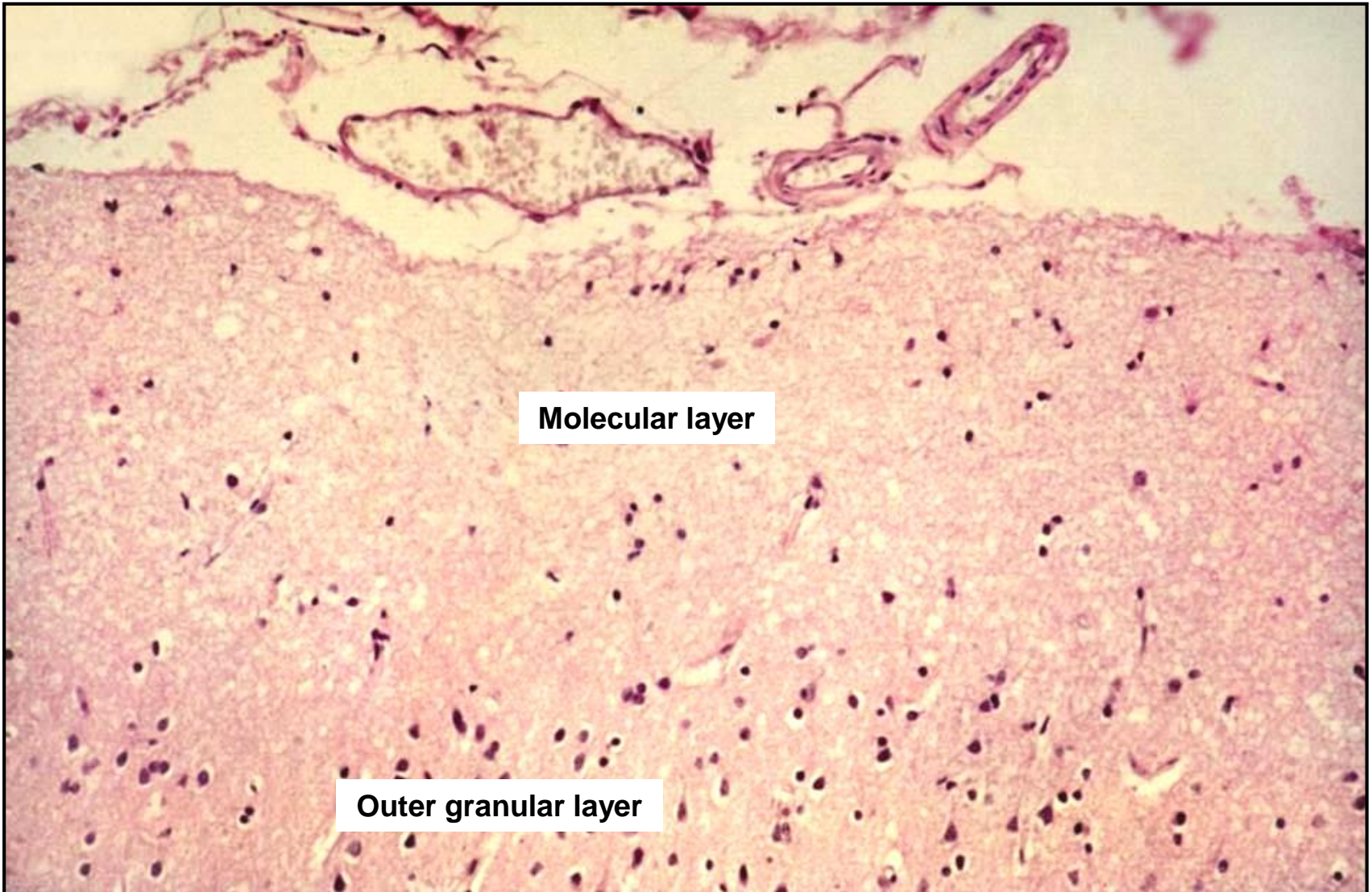


# Telencephalon - Isocortex



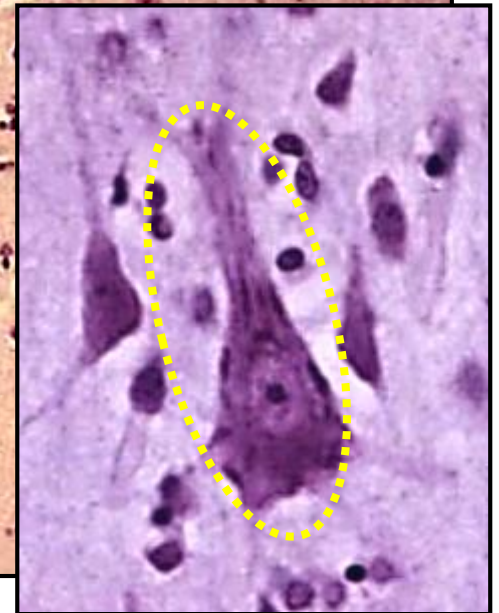
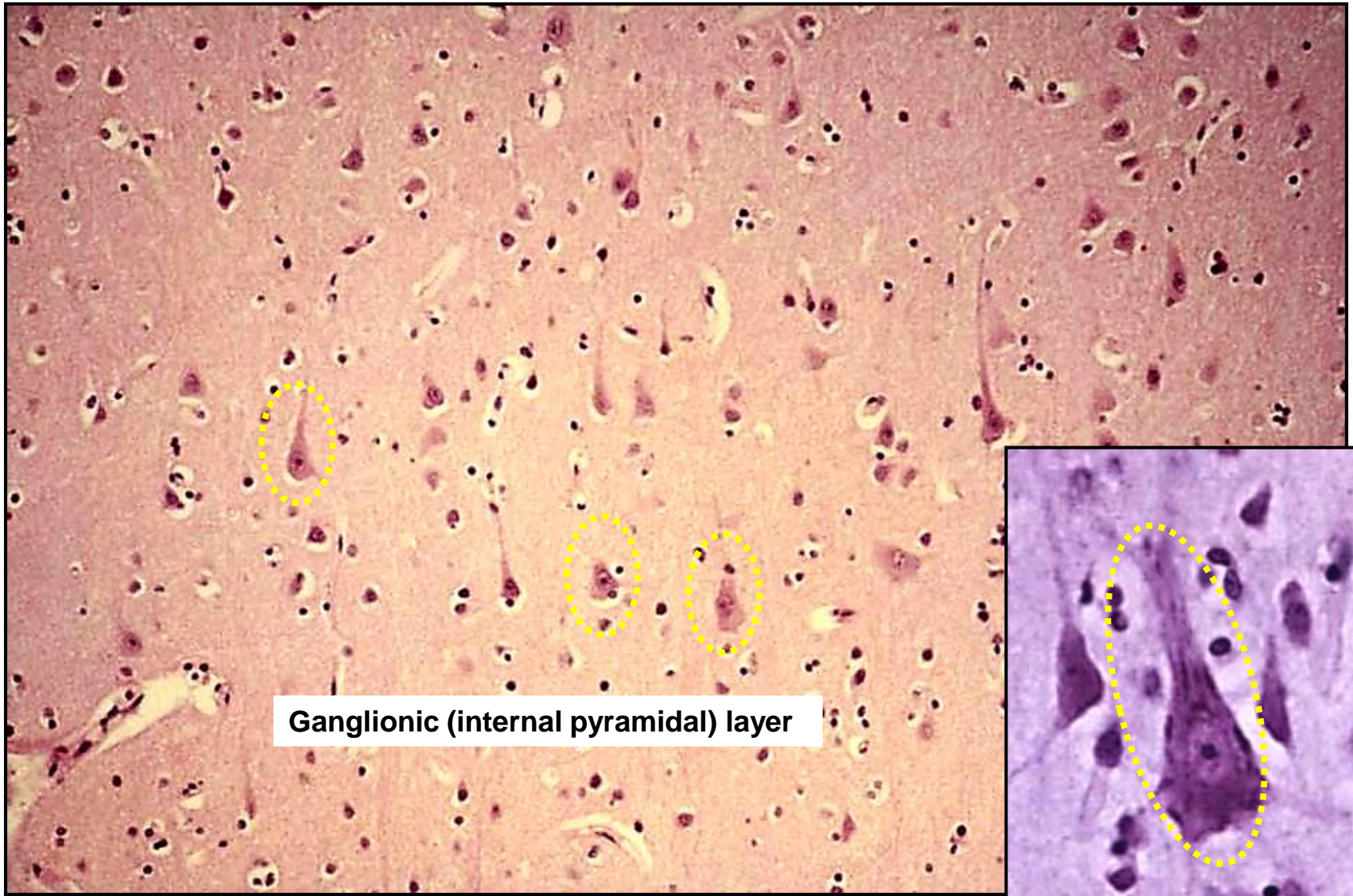


# Telencephalon - Isocortex

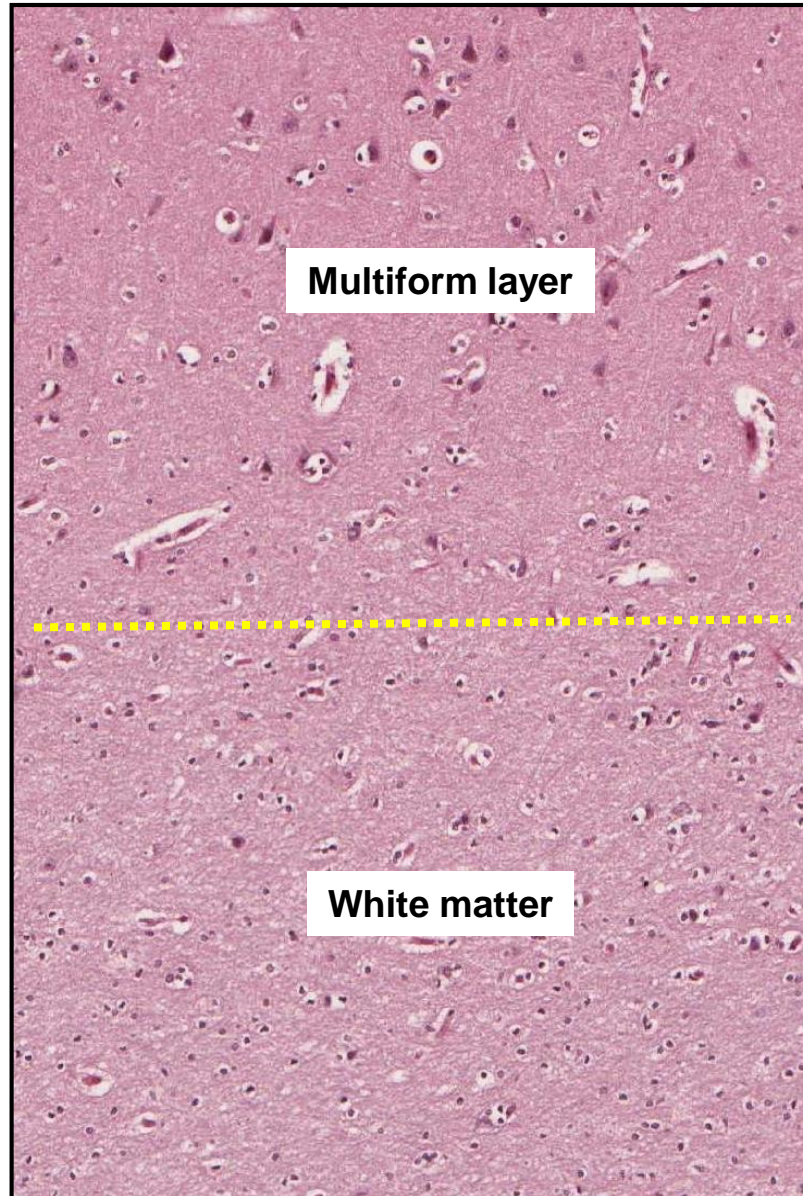




# Telencephalon - Isocortex



# Telencephalon - Isocortex





# Telencephalon - Isocortex

## Homotypic

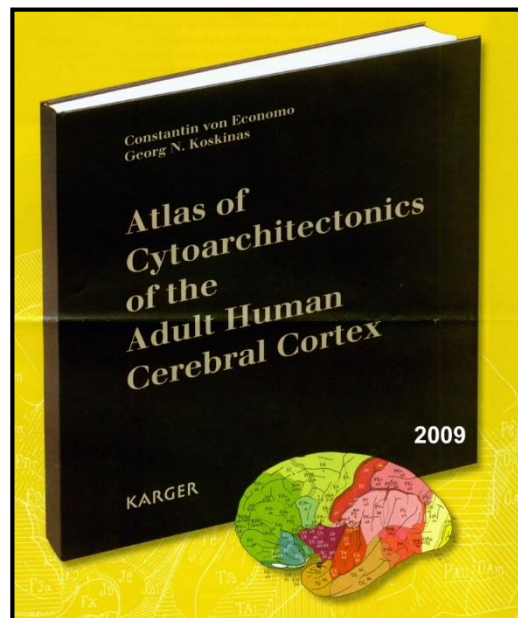
typical 6-layered architecture

## Heterotypic

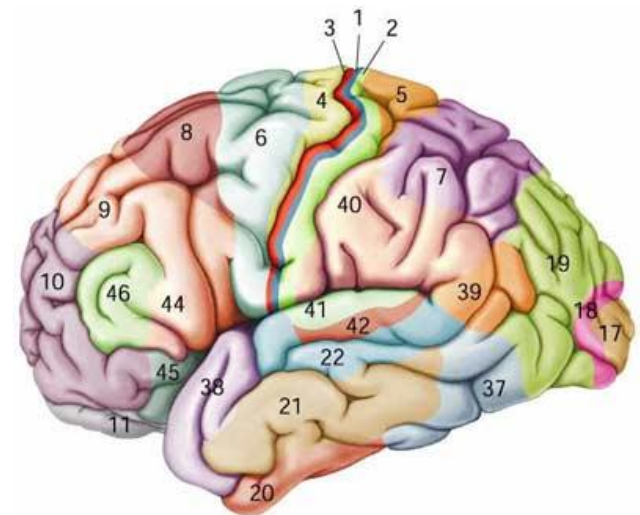
various divergences from the typical architecture  
(cell numbers/density, relative proportions, thickness, fibers, vessels, ...)

### Maps

- **cytoarchitectonic** - the density of perikarya
- **myeloarchitectonic** - the density of myelinated fibers
- **glioarchitectonic** - the type and density of glial cells
- **angioarchitectonic** - the density of blood capillaries or vascularization
- **synptoarchitectonic** - the density synapses in the isocortex



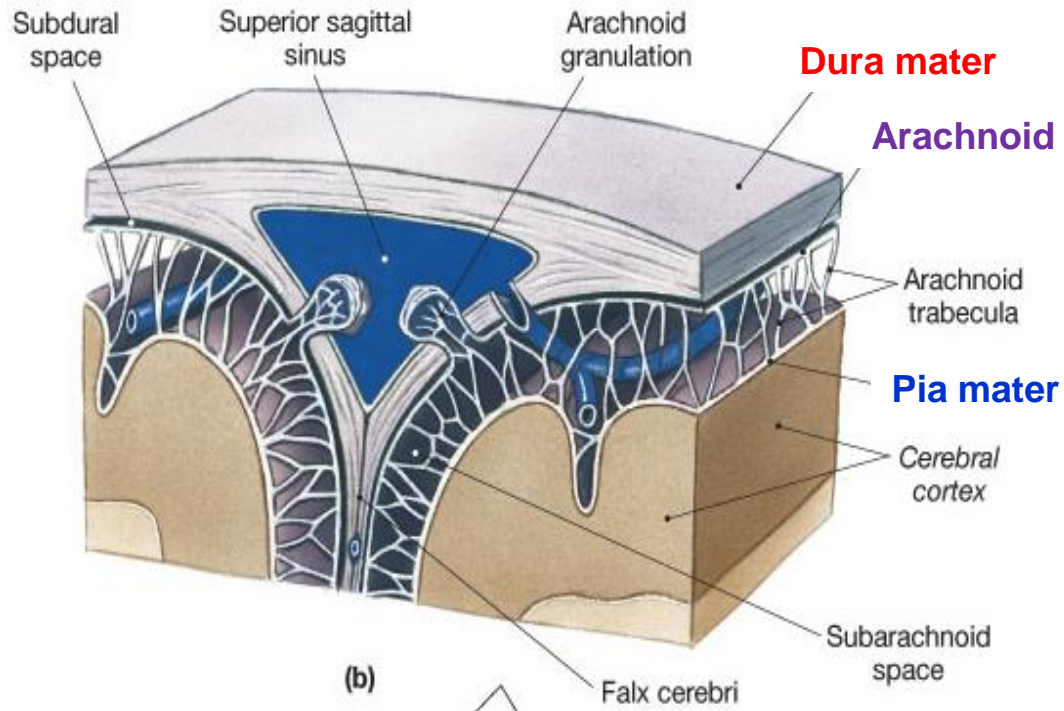
1909 - K. Brodman  
11 regions and 52 areas





# Meninges

- membranes
- protect CNS + contribute to distribution of liquor
- cover both brain and spinal cord (are continuous)



**Pachymeninx (hard)**

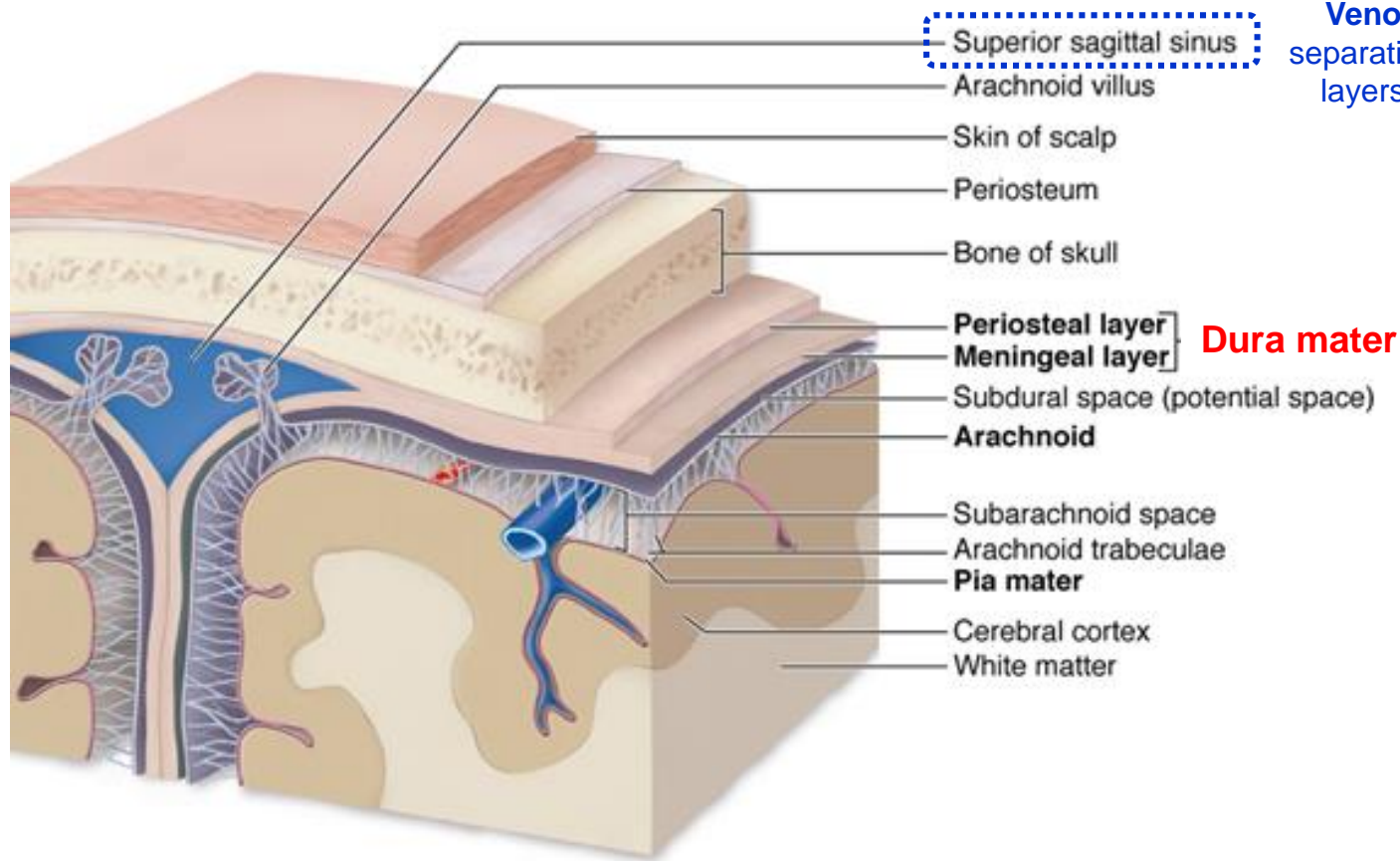
**Dura mater**

**Leptomeninges (soft)**

**Arachnoid + Pia mater**

# Meninges – Dura mater

the outermost + robust (fibrous)



## Cranial dura

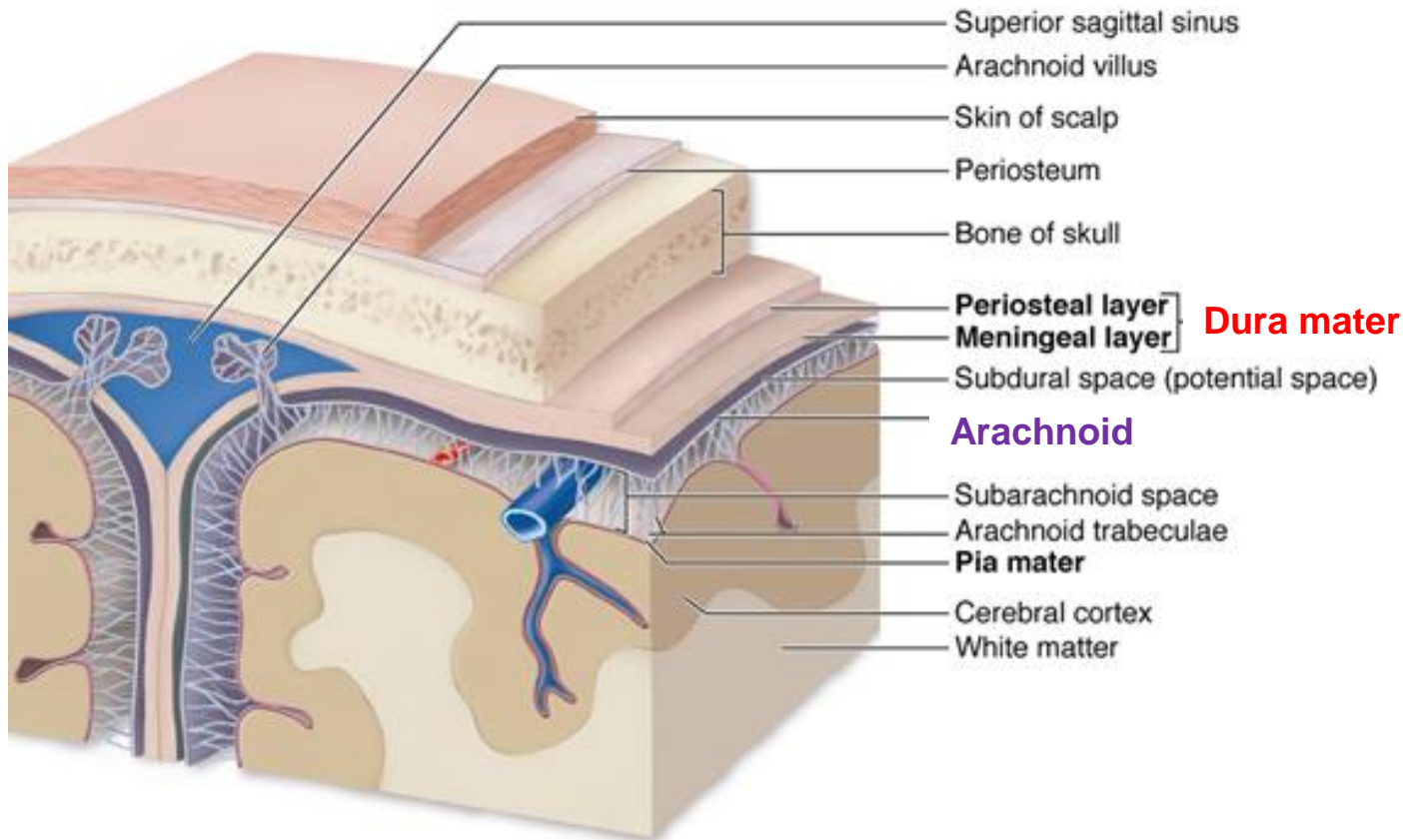
- **Endosteal layer (periosteal; outer)** - adhering to the inner surface of the bones of the skull
- **Meningeal layer (inner)** - thinner fibrous tissue membrane, inner surface covered by mesothelial cells

## Spinal dura

- continuation of the inner layer of cranial dura

# Meninges – Arachnoid

middle + spider web-like + avascular



## Arachnoid

- **Neurothel (*lamina neurothelialis*)** - adhering to the inner layer of dura mater, tight junctions – barrier between CSF and blood in dura mater
- **Trabeculae** – delicate fibers covered by flat (meningeal) cells

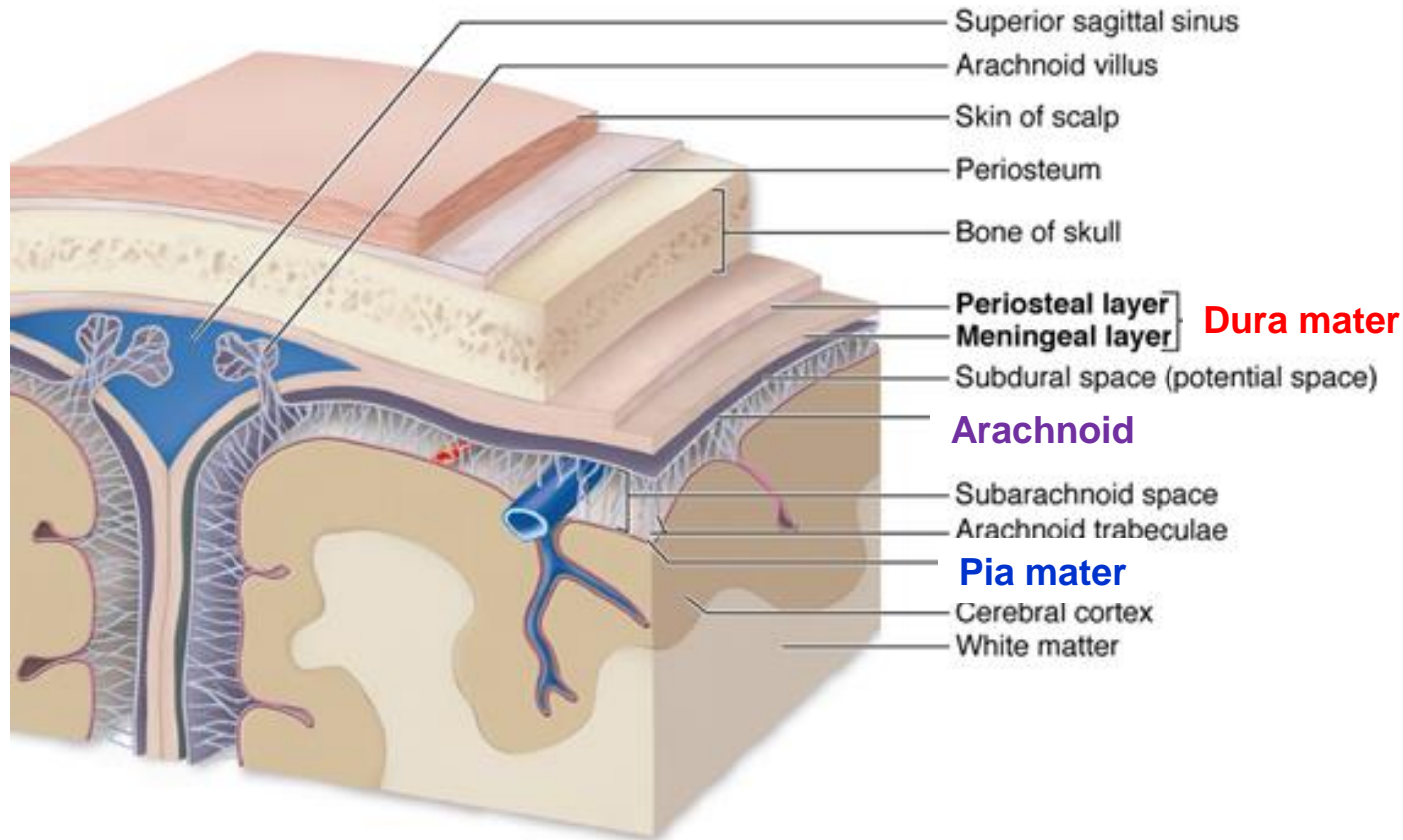
## Subarachnoid space

- enclosed between the arachnoid and pia mater
- filled by **cerebrospinal fluid (CSF)**



# Meninges – Pia mater

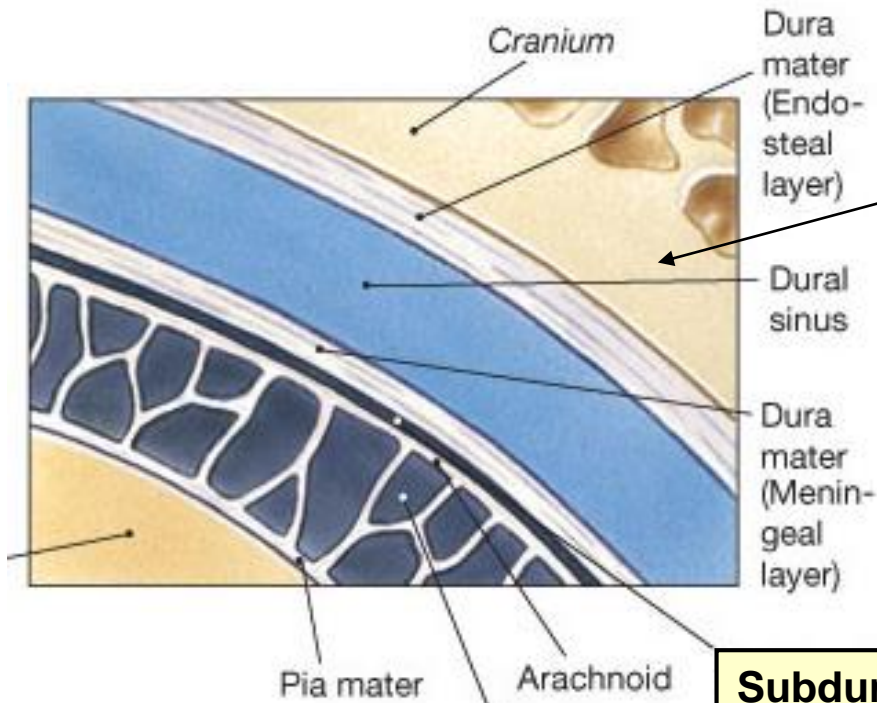
the innermost + delicate + vascular + adheres to and follows the surface of brain



## Pia mater

- **Superficial layer**- receives trabeculae of the arachnoid
- **Inner layer** – elastic and reticular fibers, firmly attached to the under-lying nervous tissue, covered from outside with simple squamous cells of mesodermal origin

# Meninges – Spaces between the membranes



**Epidural space**

**Epidural space**  
• between the **dura mater** and the **vertebral canal** in the spinal column  
(potential space in the cranial region)

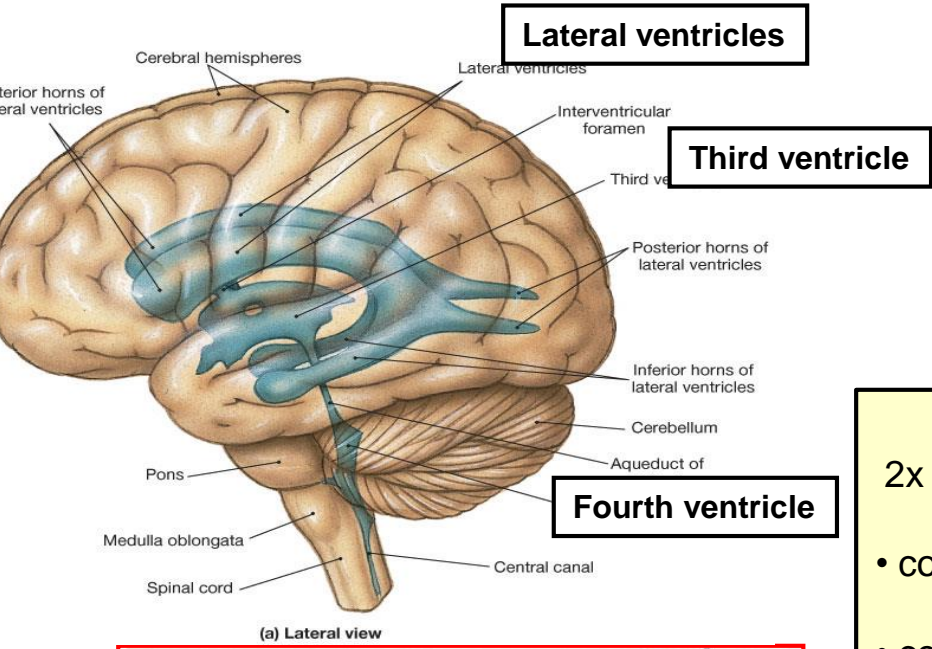
**Subdural space**

**Subdural space**  
• between the **arachnoid** and the **dura mater**  
(potential space in the cranial region)

**Subarachnoid space**


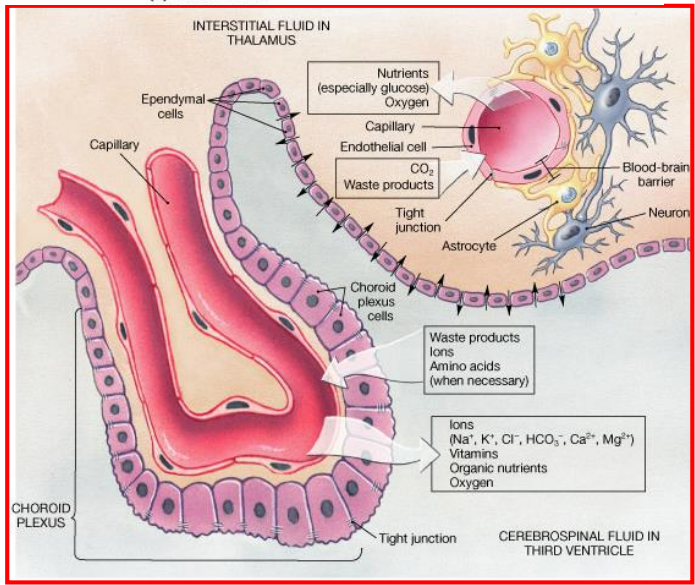
**Subarachnoid space**  
• between the **arachnoid** and **pia mater**  
(large veins run through the subarachnoid space - e.g. cerebral veins)

# Cerebrospinal fluid



**Brain ventricles (chambers)**  
2x lateral ventricles + 1x third ventricle + 1x fourth ventricle

- connect to central canal which runs to spinal cord
- contain cerebrospinal fluid (CSF)
- CSF is produced by **ependymal cells of choroid plexuses**

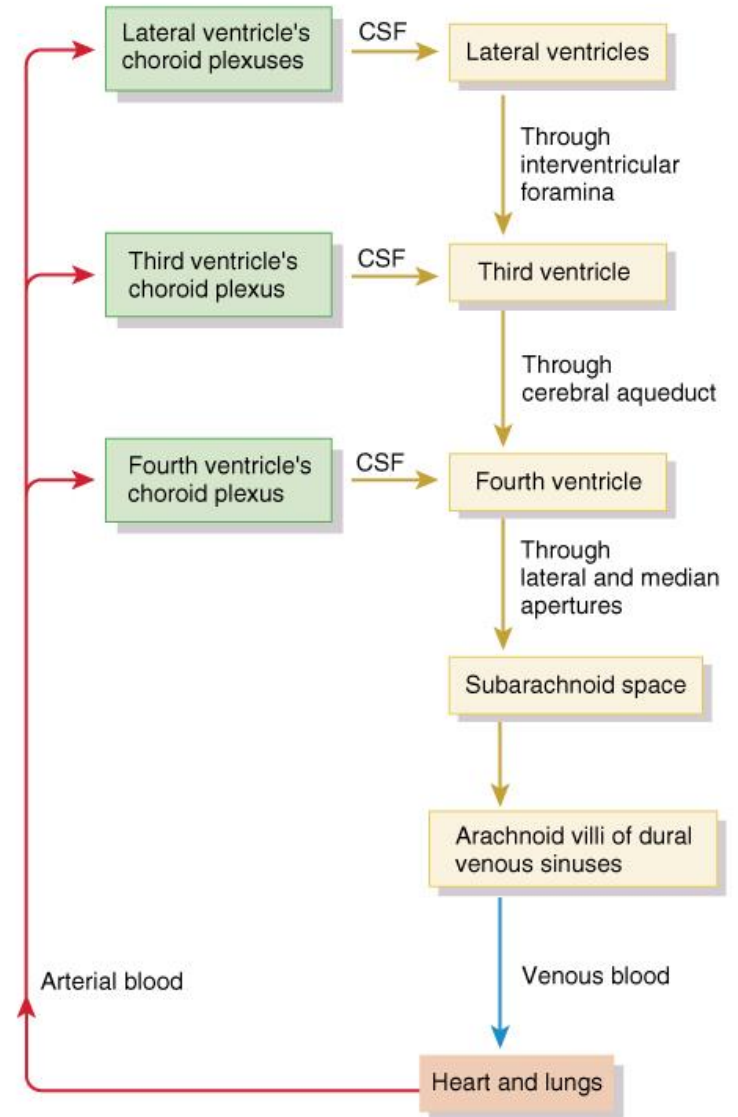
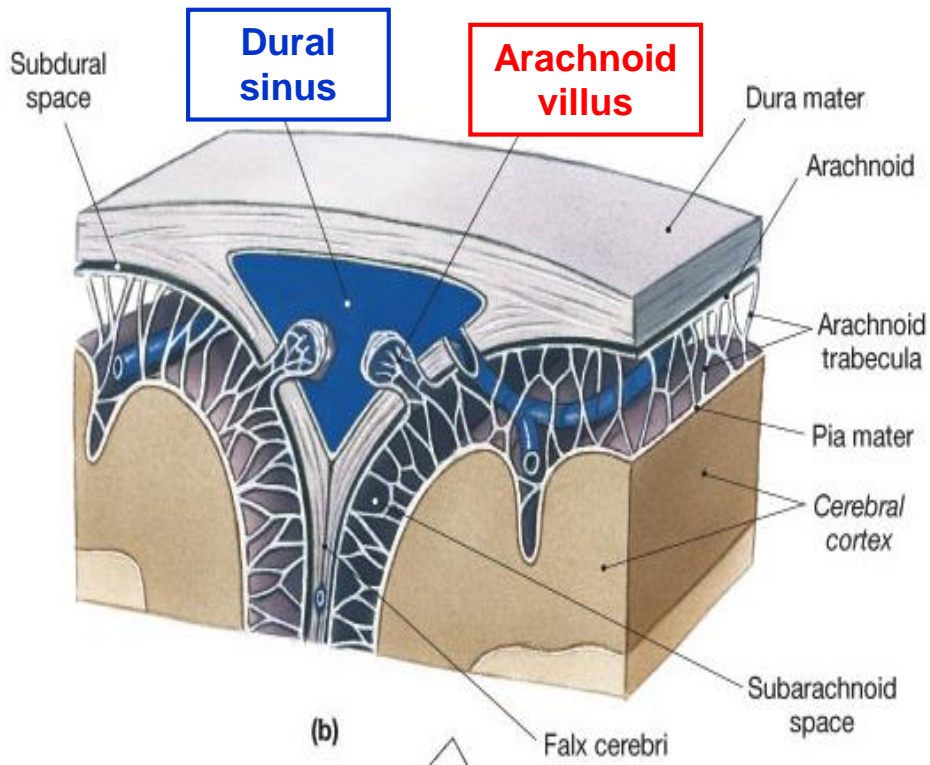




# Cerebrospinal fluid - Circulation

## Arachnoid villi

- fingerlike projections into the dural venous sinuses
- mediate gradual reabsorption of CSF into the blood



# Peripheral nervous system - Components

## Definition:

Made up of transmission pathways carrying information between the CNS and external/internal environments.

## Afferent (sensory) pathways:

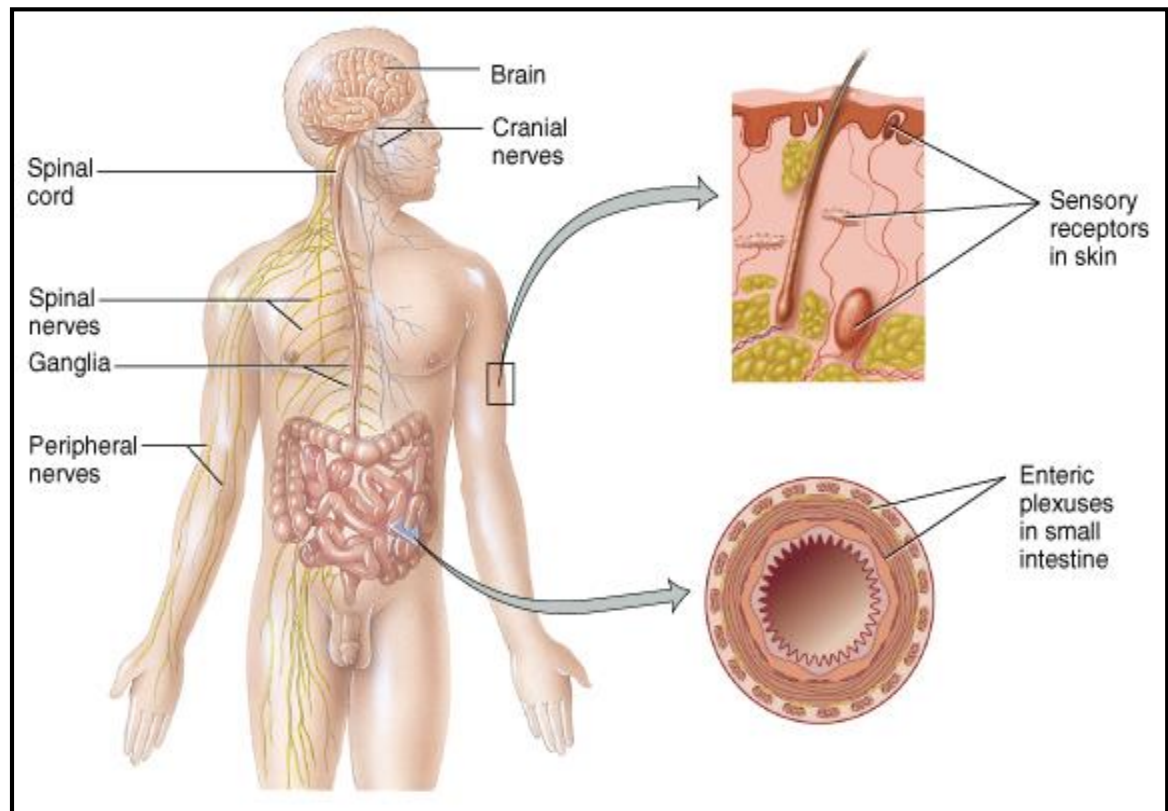
Carry information to the CNS.

## Efferent (motor) pathways:

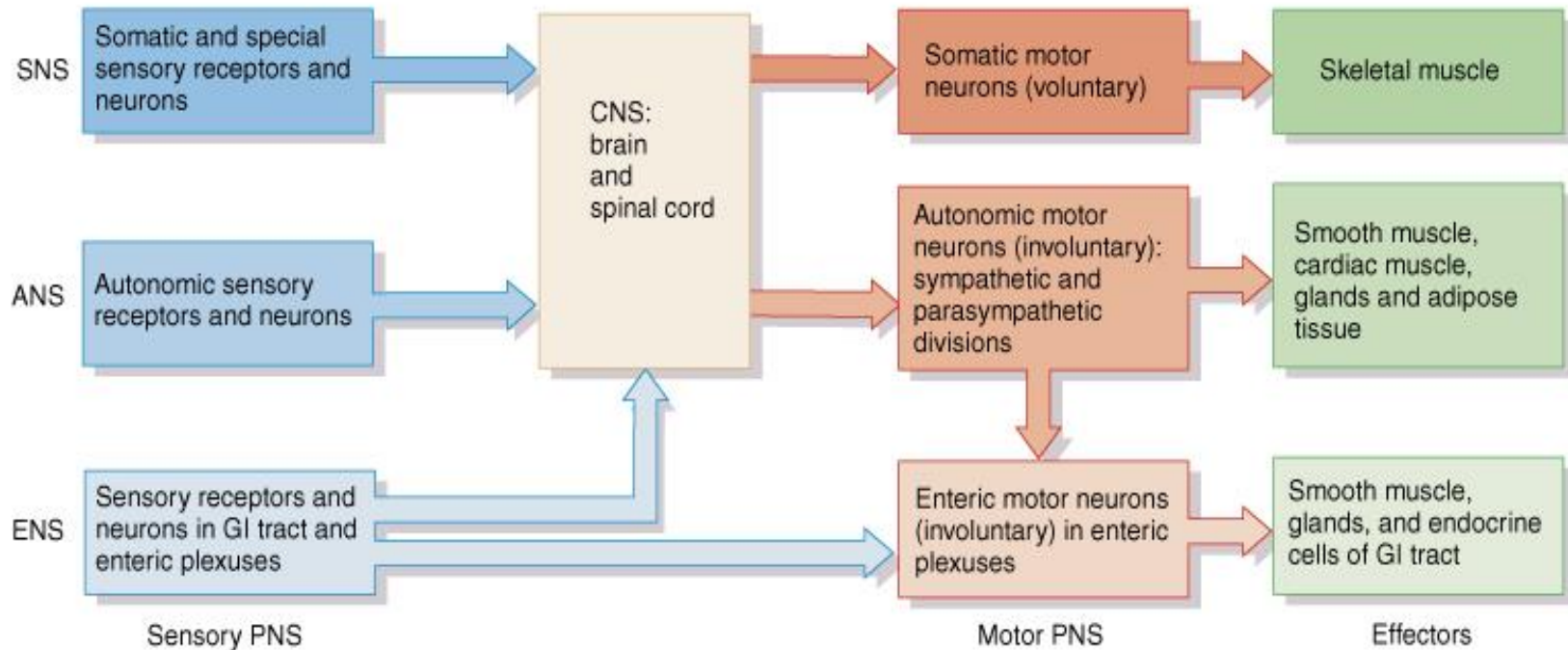
Carry information from the CNS.

## Includes:

- Cranial nerves (12 pairs)
- Spinal nerves (31 pairs)
- Peripheral nerves
- Ganglia
- Sensory receptors



# Peripheral nervous system – Overall organization



## **Somatic (voluntary) nervous system (SNS)**

- neurons from cutaneous and special sensory receptors to the CNS
- motor neurons to skeletal muscle tissue

## **Autonomic (involuntary) nervous systems (ANS)**

- sensory neurons from visceral organs to CNS
- motor neurons to smooth & cardiac muscle and glands
  - 1. sympathetic division** (*speeds up heart rate*)
  - 2. parasympathetic division** (*slow down heart rate*)

## **Enteric nervous system (ENS)**

- involuntary sensory & motor neurons control GI tract
- neurons function independently of ANS & CNS

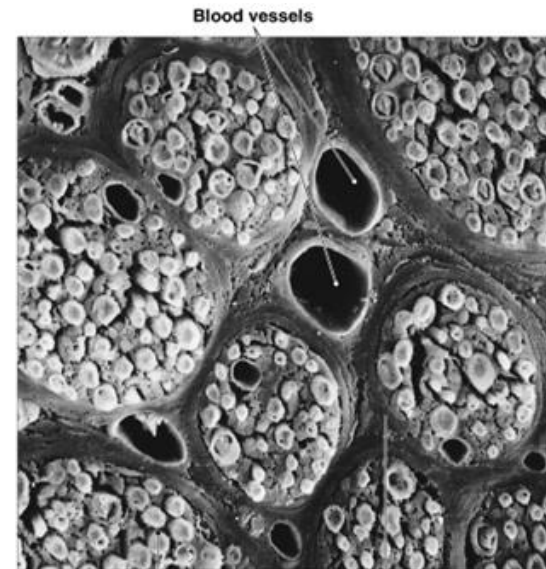
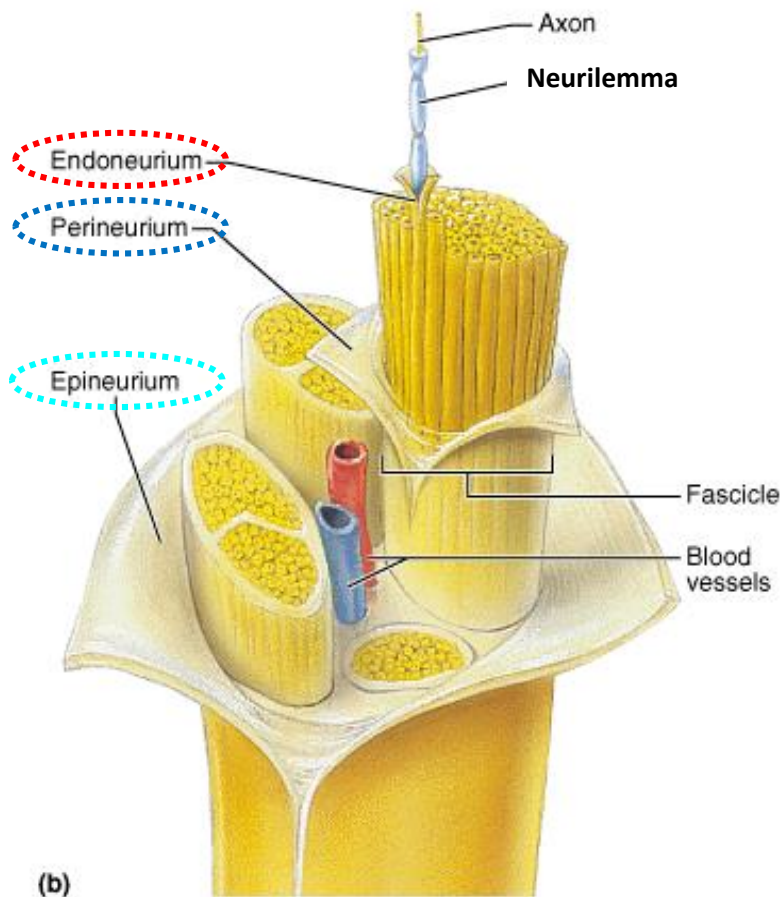


# Peripheral nervous system - Nerves

Consists of 100's to 100,000's of myelinated and unmyelinated axons (nerve fibers).

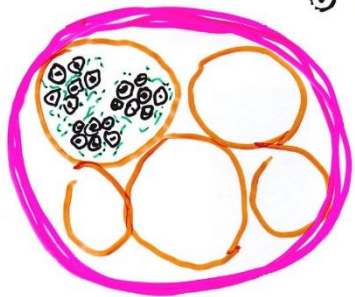
**Connective tissue layers composing nerves:**

- **Endoneurium** - surrounds axons - **primary nerve bundles**
- **Perineurium** - surrounds fascicles – **secondary n. bundles**
- **Epineurium** - surrounds the entire nerve



(b) **Endoneurium** (circled in red) and **Perineurium (around one fascicle)** (circled in blue)

# Peripheral nervous system - Nerves



⊙ MYELINATED FIBER

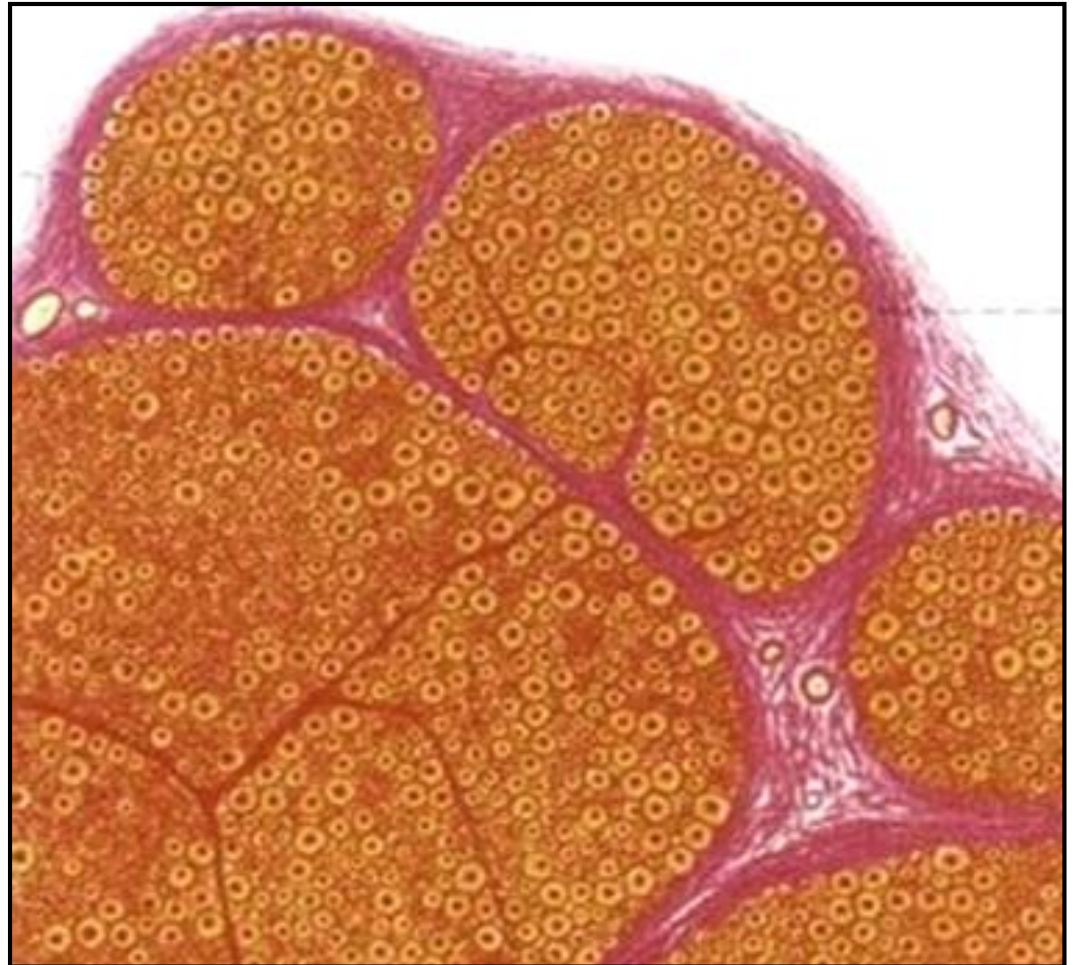⊙ PRIMARY N.B.

ENDONEURIUM

SECONDARY N.B.

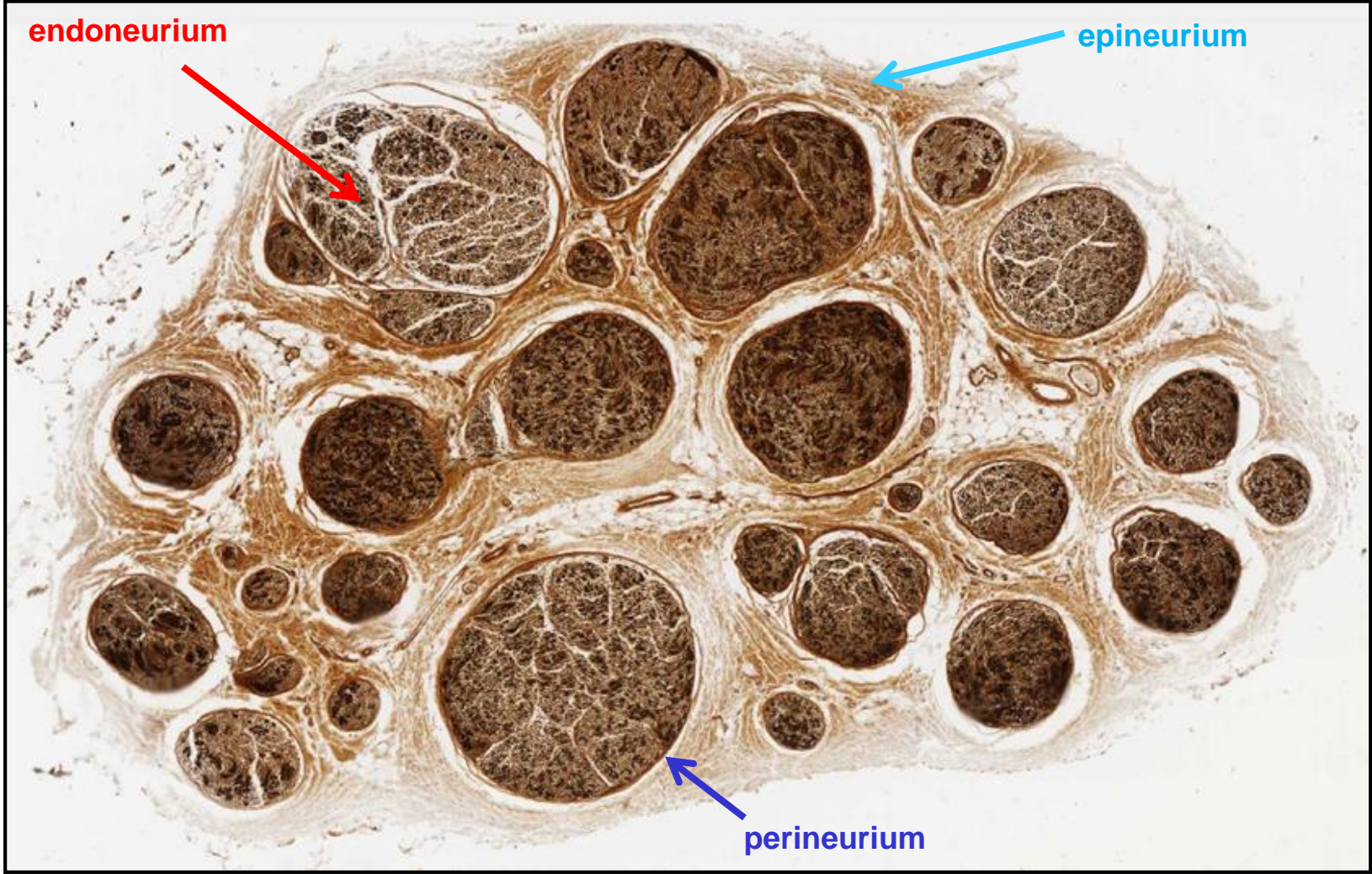
PERINEURIUM

EPINEURIUM



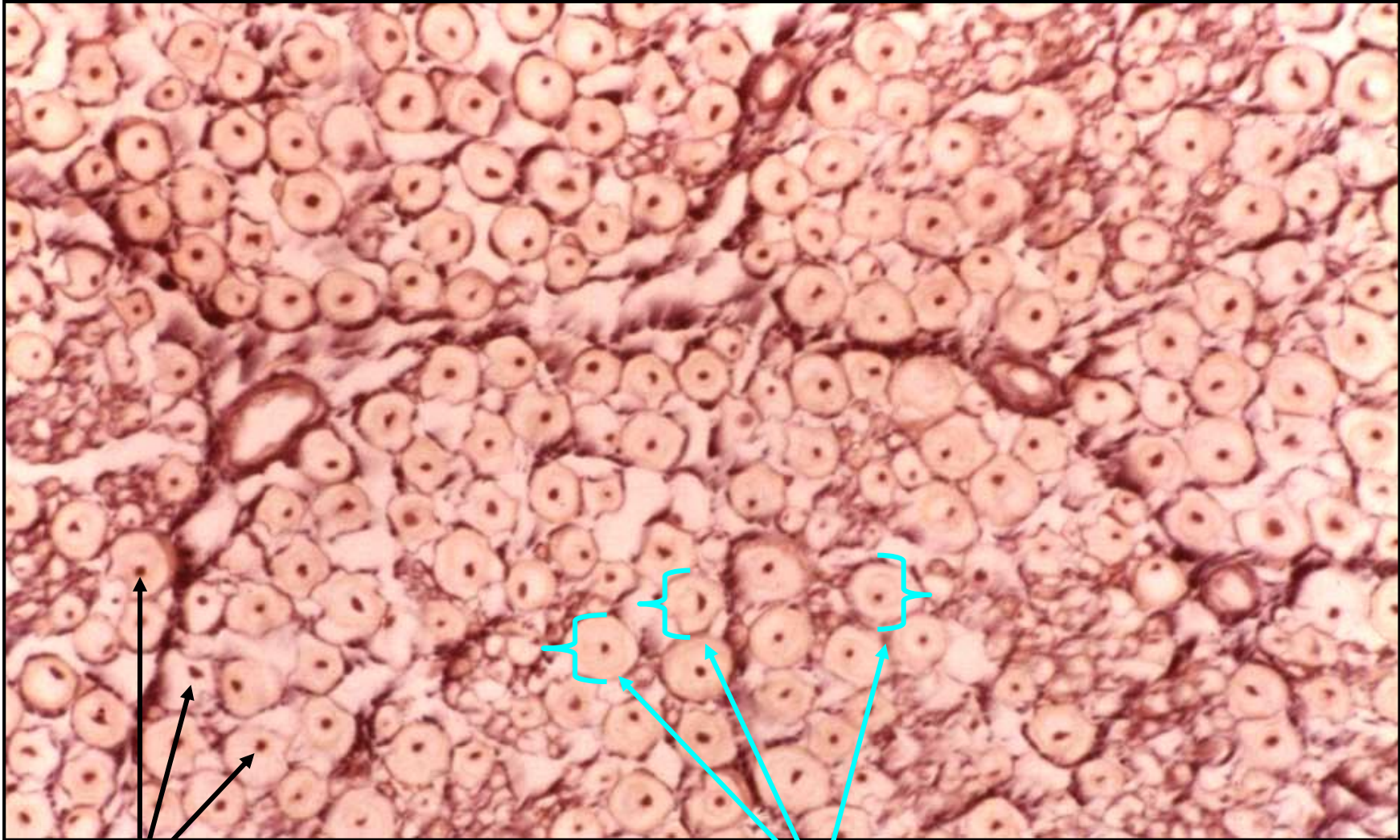

# Peripheral nervous system – Nerves





# Peripheral nervous system – Nerves

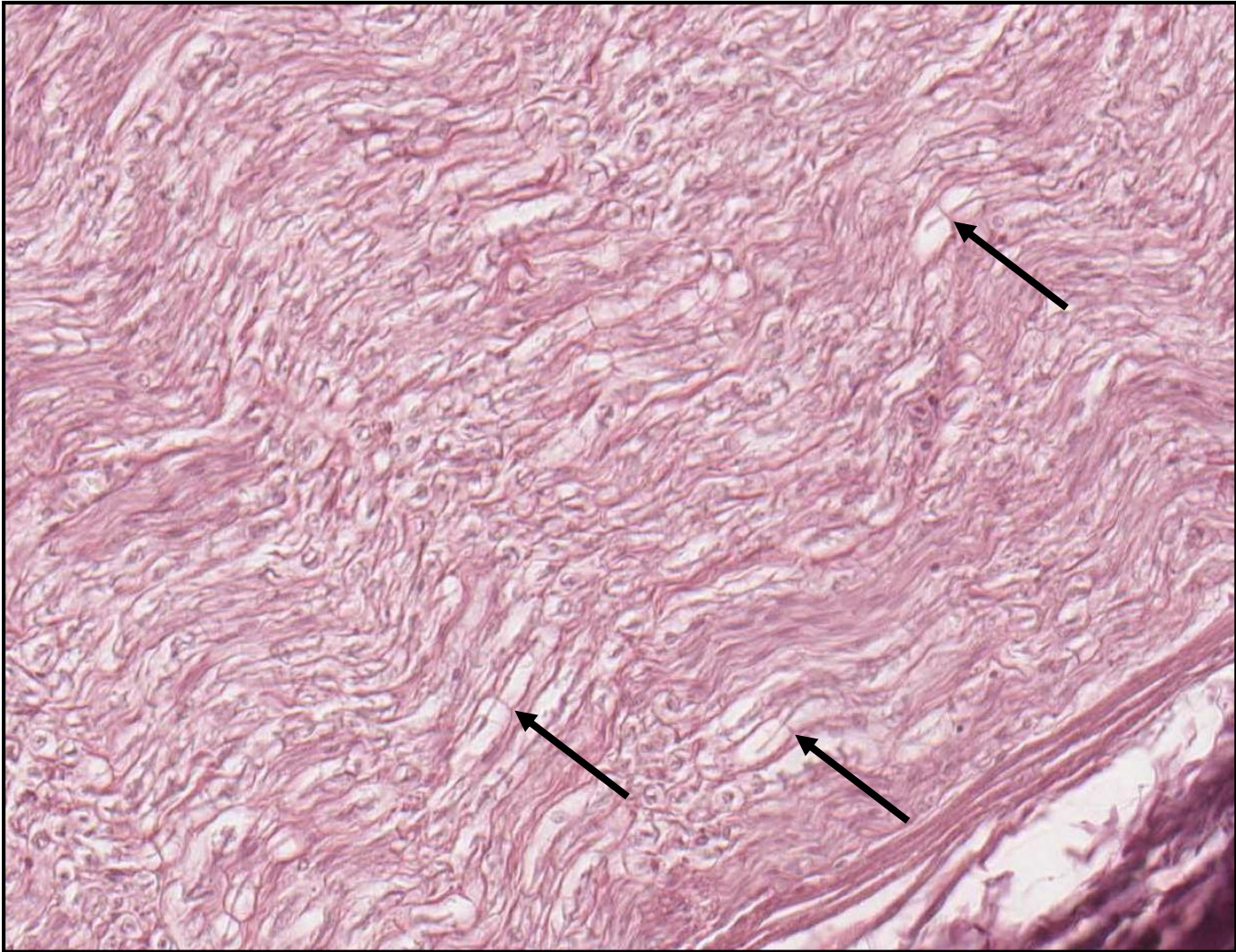


axons

myelin sheets



# Peripheral nervous system – Nerves



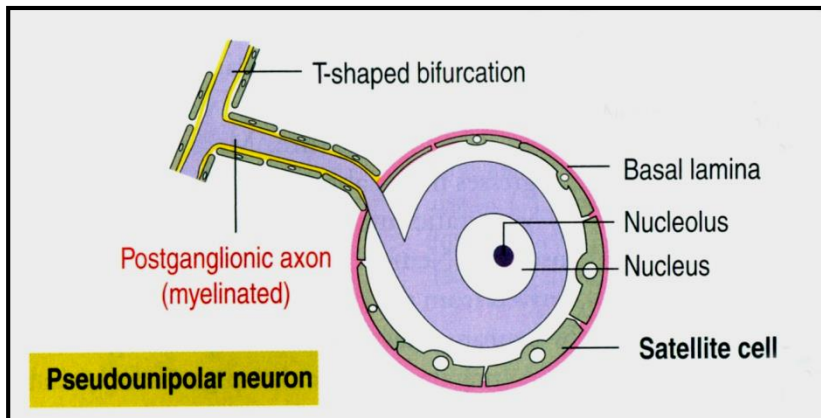
**Nodes of Ranvier**

# Peripheral nervous system – Ganglia

= aggregations of cell bodies of neurons located outside of CNS

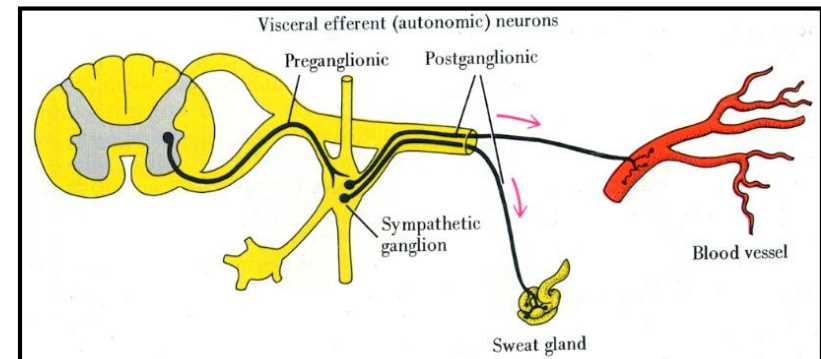
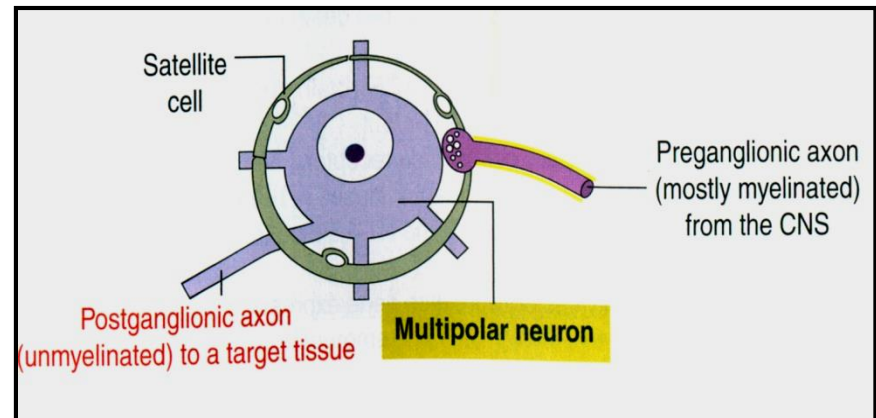
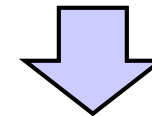
## Sensory ganglia

- associated with cranial nerves (V, VII, IX, X; **cranial ganglia**) and with all spinal nerves (**dorsal root ganglia**)
- contain **pseudounipolar neurons**
- neurons are enveloped by **satellite cells**



## Autonomic ganglia

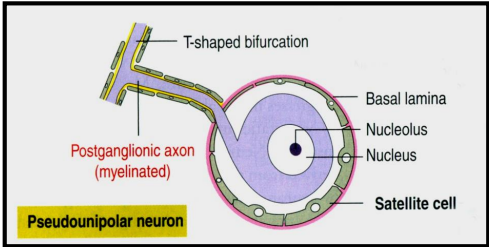
- associated with nerves of the autonomic nervous system
- contain medium-sized **multipolar neurons**
- neurons are **motor** by function (smooth and cardiac muscle, glands)
- neurons are enveloped by **satellite cells**



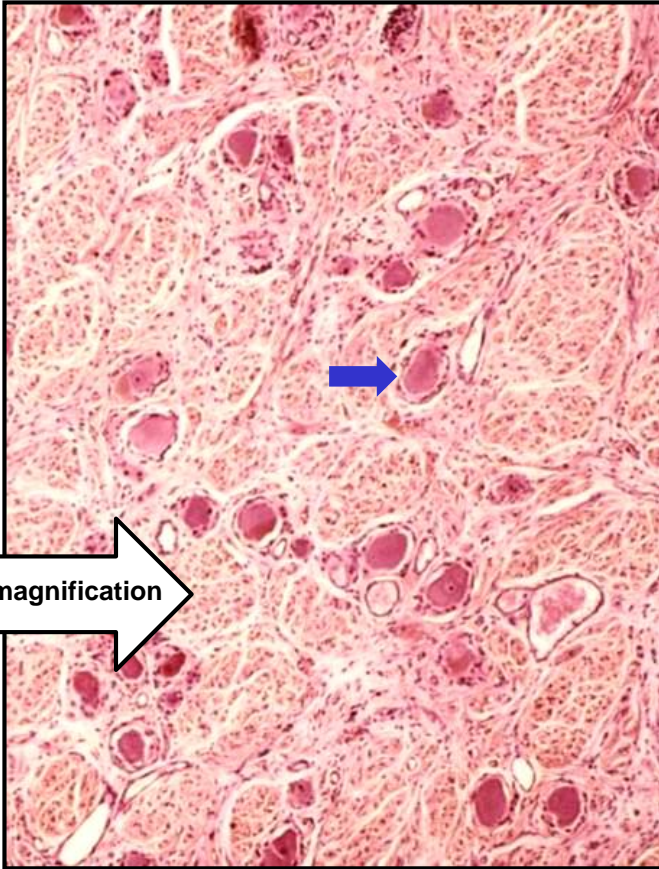
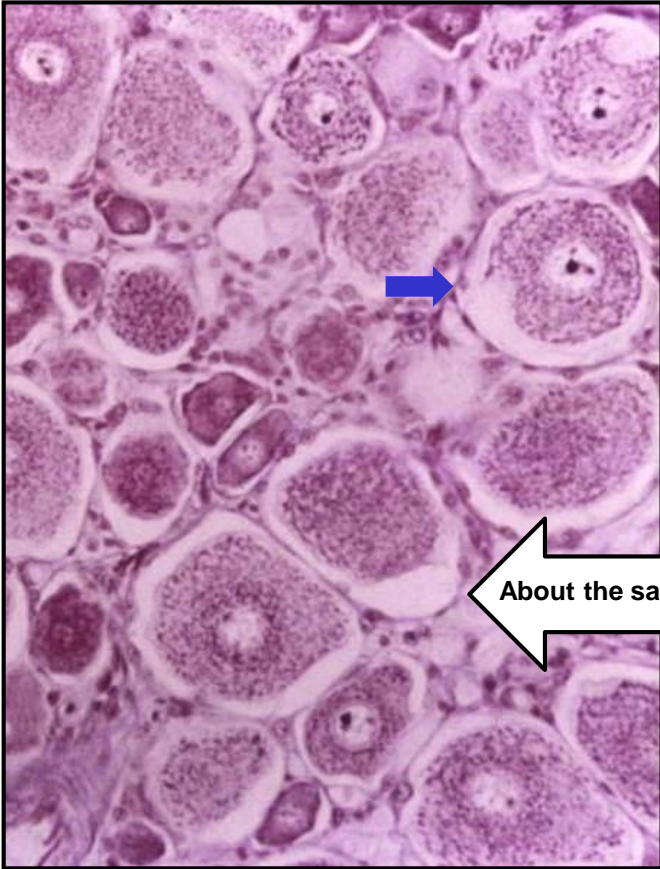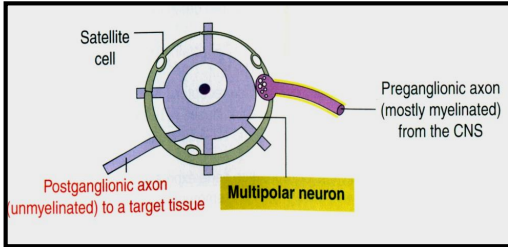


# Peripheral nervous system – Ganglia

## Sensory ganglion

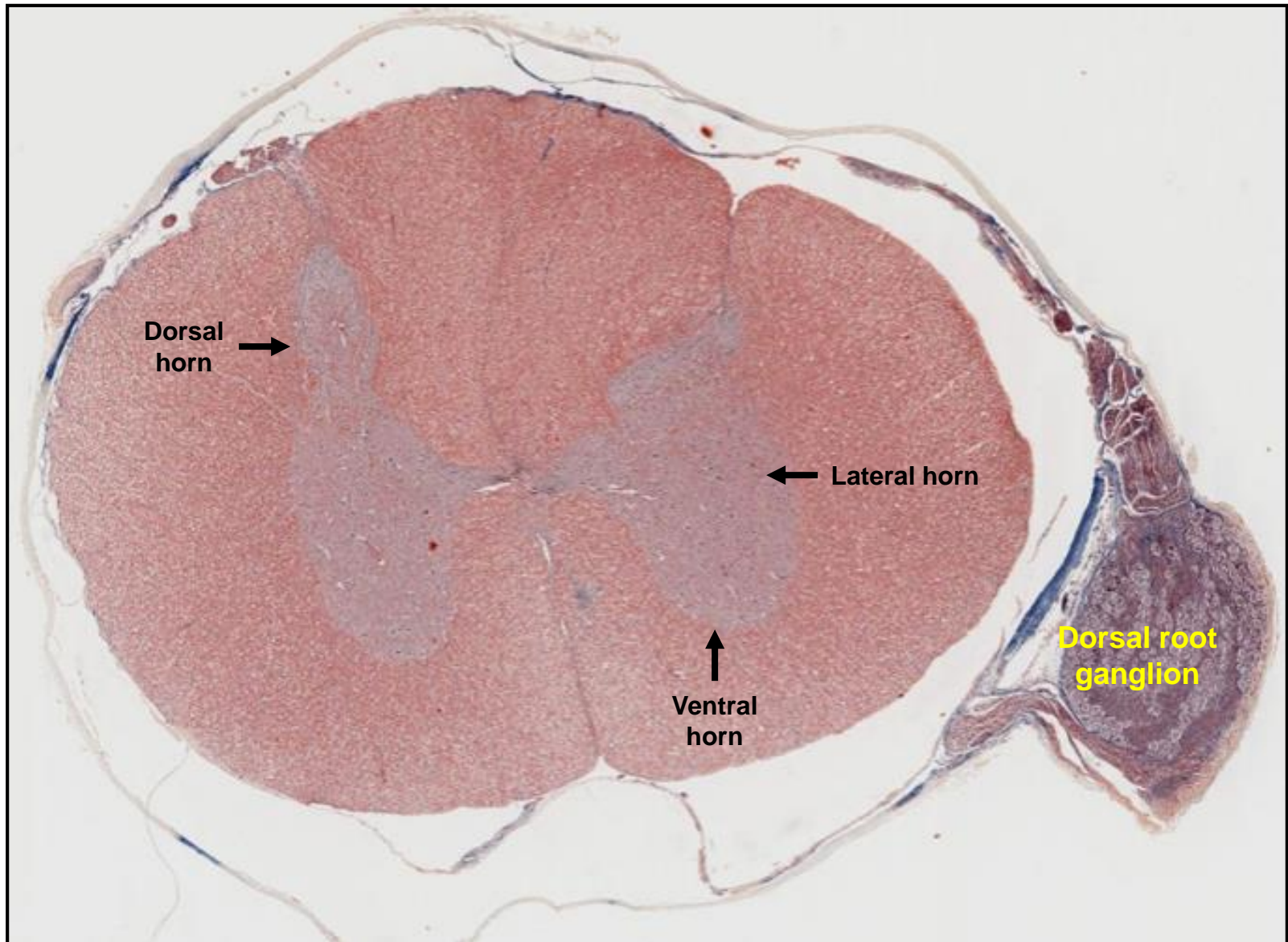


## Autonomic ganglion



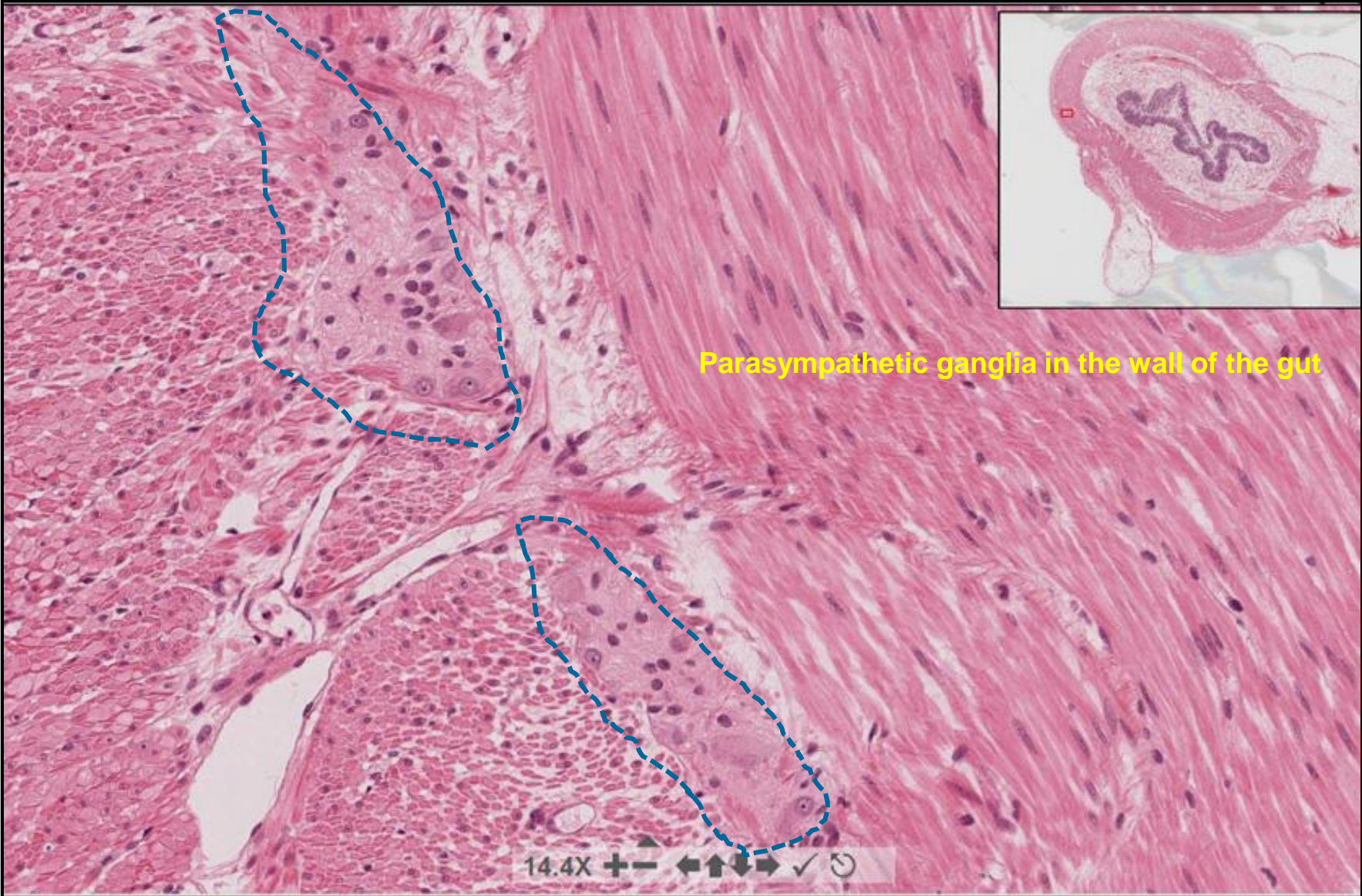
← About the same magnification →

# Spinal cord + Dorsal root ganglion





# Autonomic ganglion



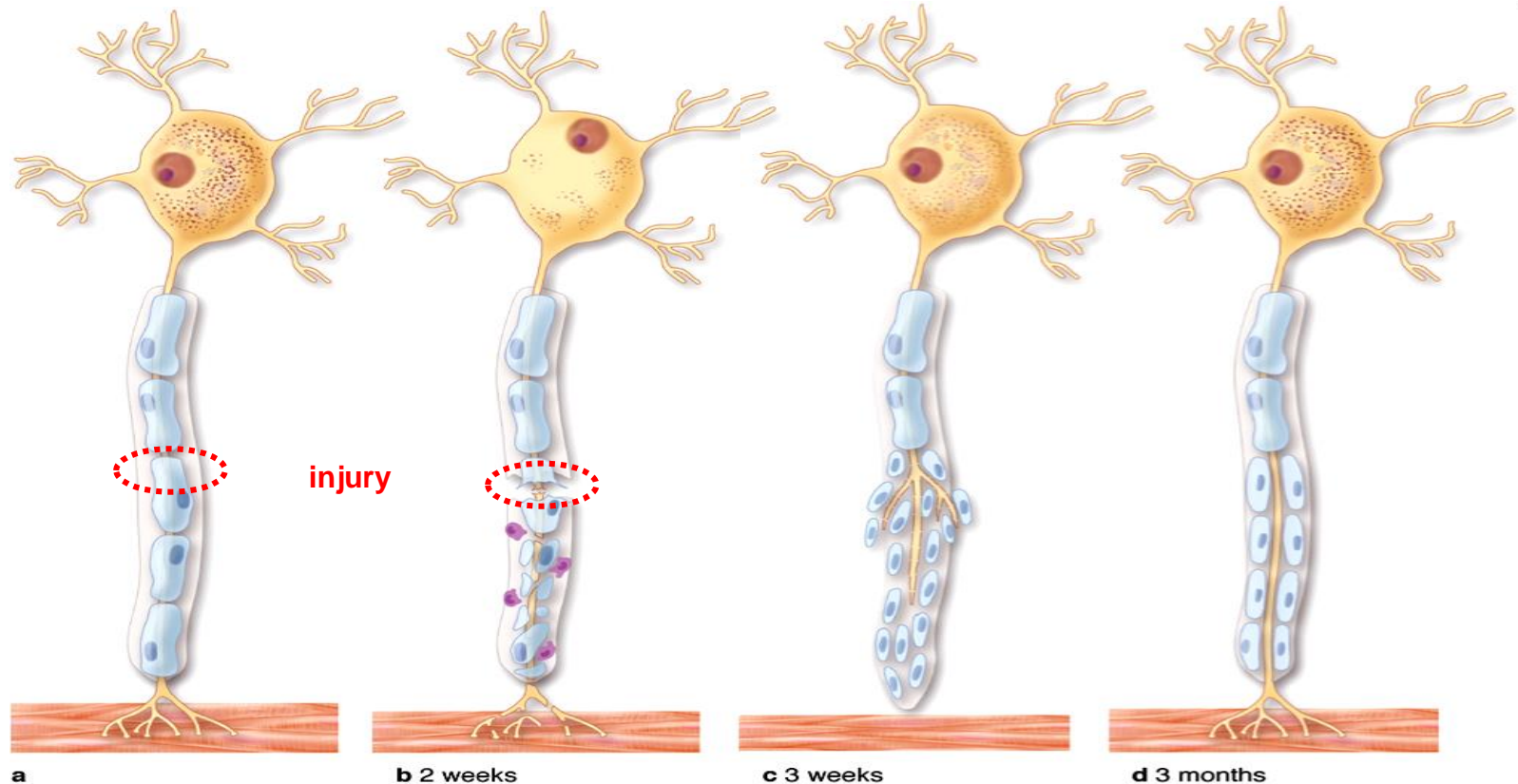
Parasympathetic ganglia in the wall of the gut



# Nerve tissue regeneration - PNS

## Axons and dendrites may be repaired if:

- Neuron cell body remains intact
- Schwann cells remains active and form tube
- Scar tissue does not form too rapidly



Breakdown of axon  
Breakdown of myelin sheath

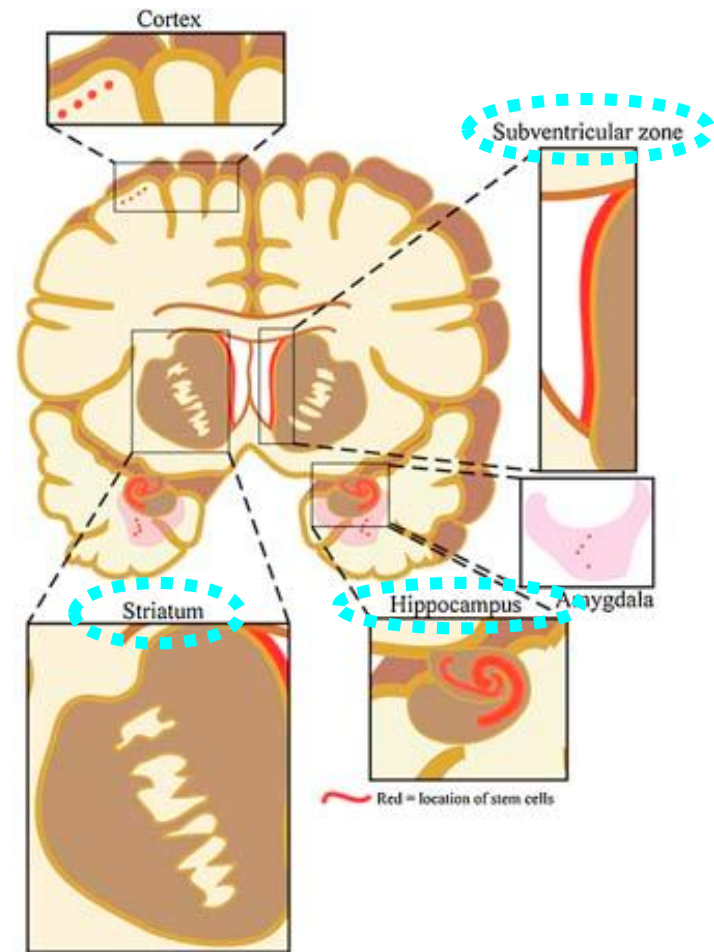
Schwann cells divide  
Axon begins to grow  
(1.5 mm/day)  
Navigation by Schwann cells  
Collaterals will die

# Nerve tissue regeneration - CNS

Stem / progenitor cells residing in some areas of adult brain

## Life-long plasticity of CNS

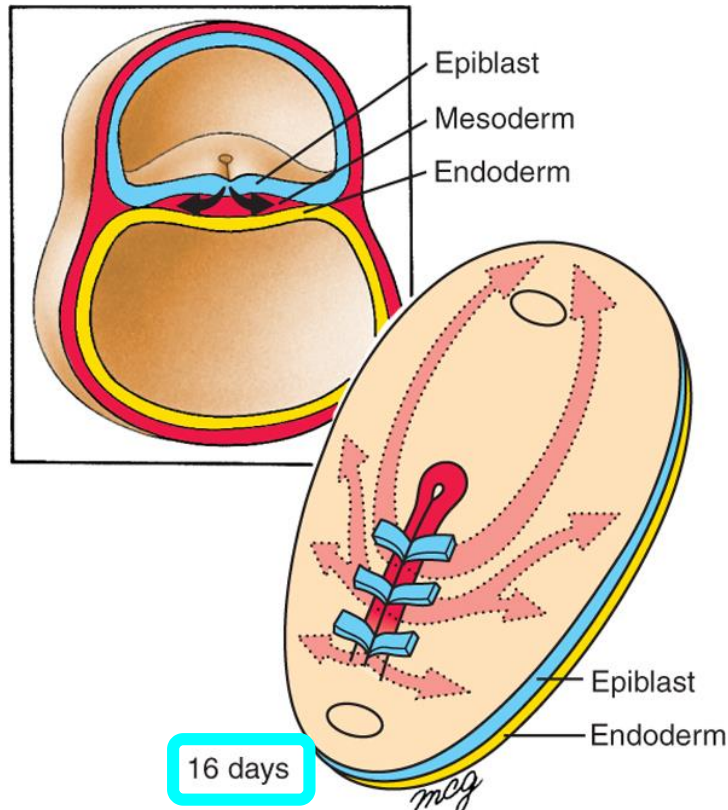
- Sprouting new dendrites
- Synthesis of new proteins
- Changes of synaptic contacts



# Nerve tissue – Ectoderm

## Gastrulation

Formation of the three germ layers



**Ectoderm:** outside, surrounds other layers later in development, generates **skin** and **nervous tissue**.

**Mesoderm:** middle layer, generates most of the **muscle, blood** and **connective tissues** of the body and placenta.

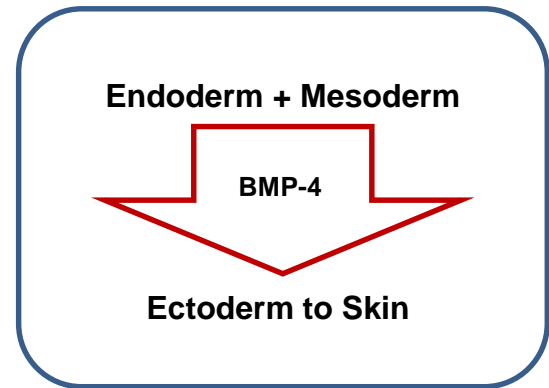
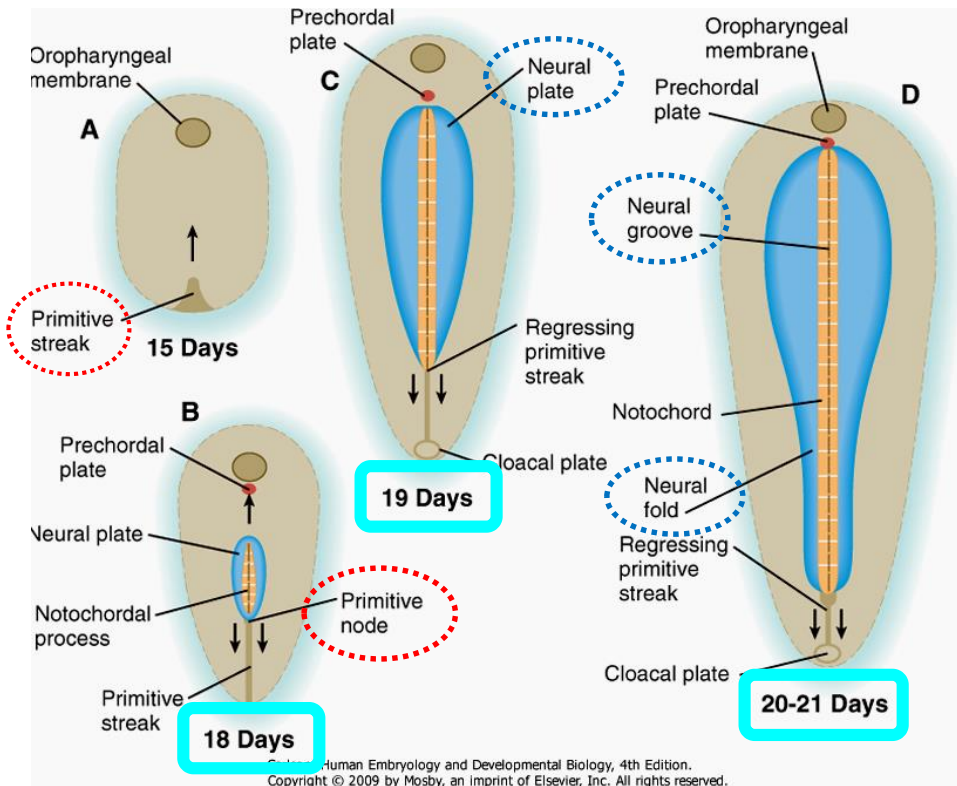
**Endoderm:** eventually most interior of embryo, generates the **epithelial lining** and associated **glands** of the **gut, lung,** and **urogenital tracts**.



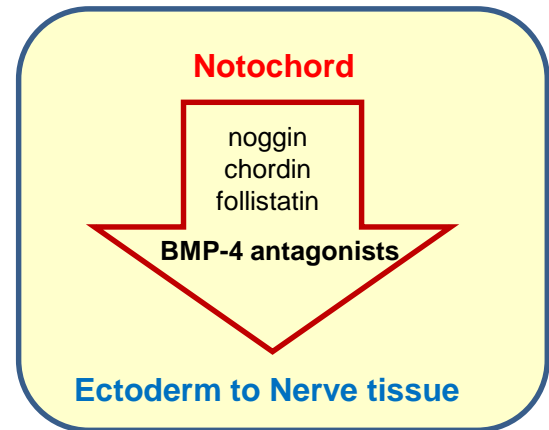
# Nerve tissue – Neural plate

## Neural Induction

In addition to patterning the forming mesoderm, the **primitive node** also sets up the **neural plate**



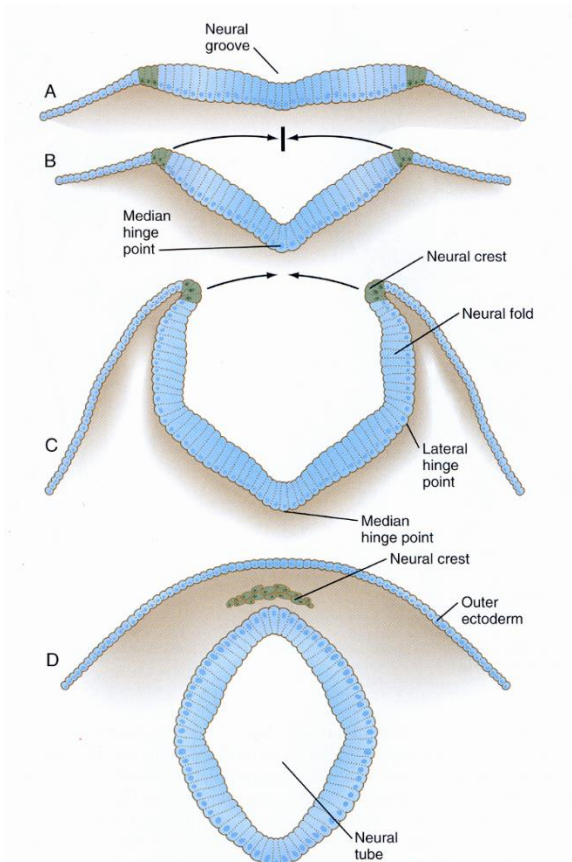
X



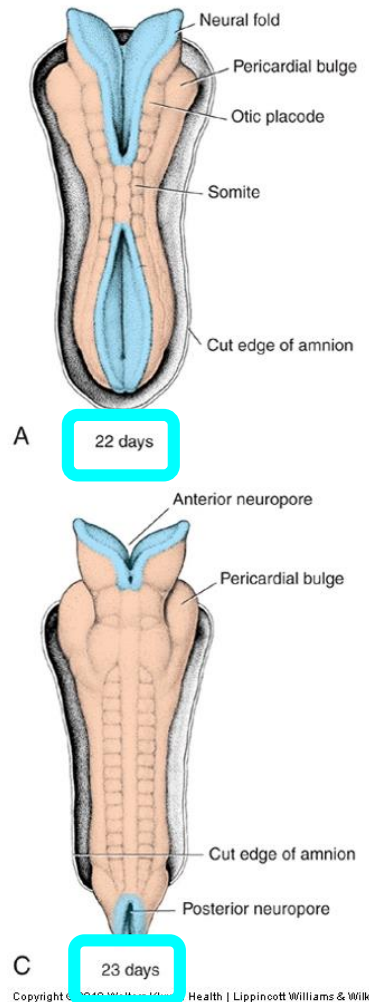
# Nerve tissue – Neural tube

## Neurulation

Folding and closure of the neural plate

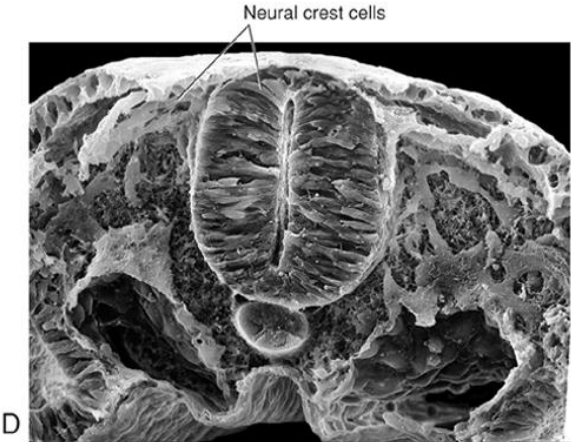
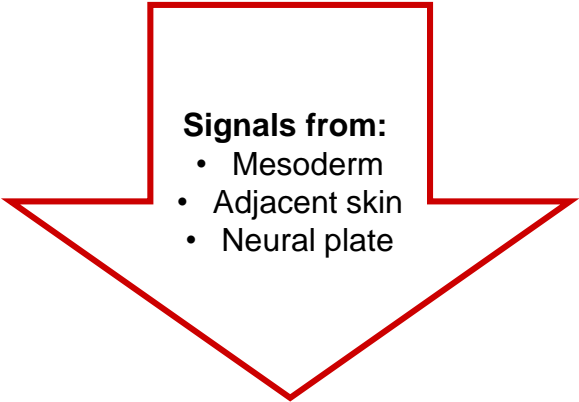
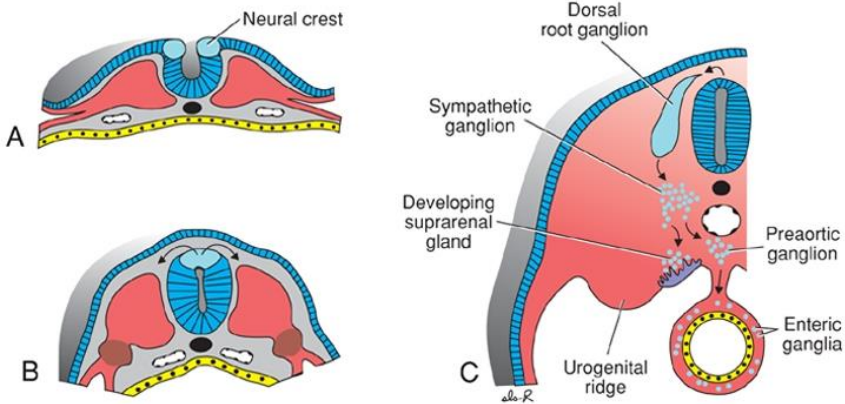


- **neural folds close**
- **neural crest delaminates** and migrates away
- **closure happens first in middle** of the tube and then **zips rostrally and caudally**
- **anterior neuropore closes around day 25**
- **posterior neuropore closes around day 28**



# Nerve tissue – Neural crest

**Neural crest**  
the “4<sup>th</sup> germ layer”



**Neural crest cells**

- Down-regulate cadherin
- Delaminate from neuroepithelium
- Transform into migratory mesenchymal cells
- Give rise to many cell types



# Nerve tissue – Neural crest derivatives

## Neuroblasts

- **pseudounipolar** neurons of spinal ganglia
- **multipolar** neurons of autonomic ganglia
- **chromaffin cells** of the adrenal medulla

## Spongioblasts

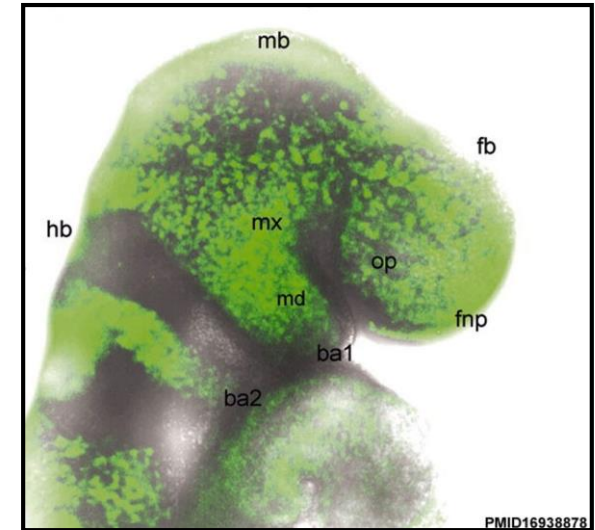
- **Schwann cells**
- **satellite cells**

## Melanocytes

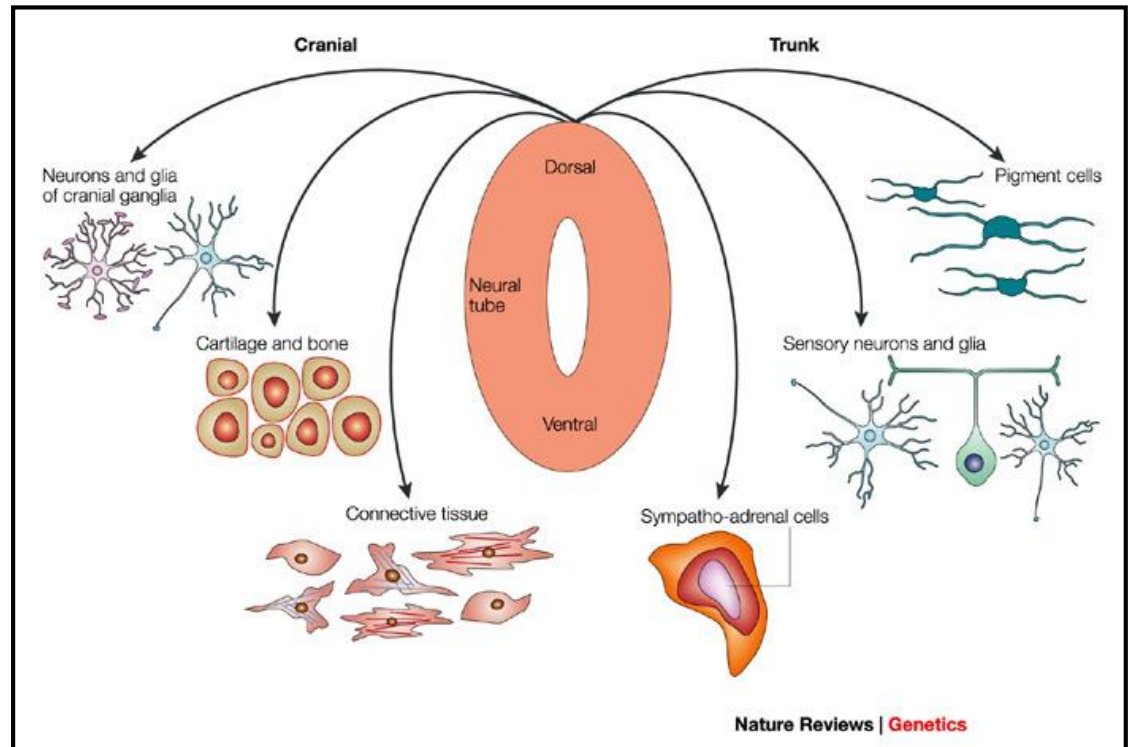
- migrate to the epidermis

## Ectomesenchymocytes

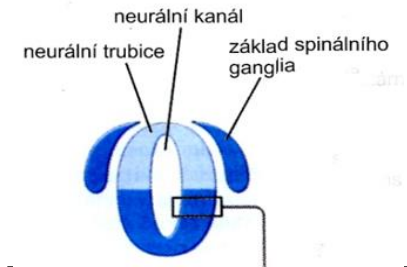
- migrate into the branchial arches
- replace the mesenchyme of mesodermal origin



PMID16938878



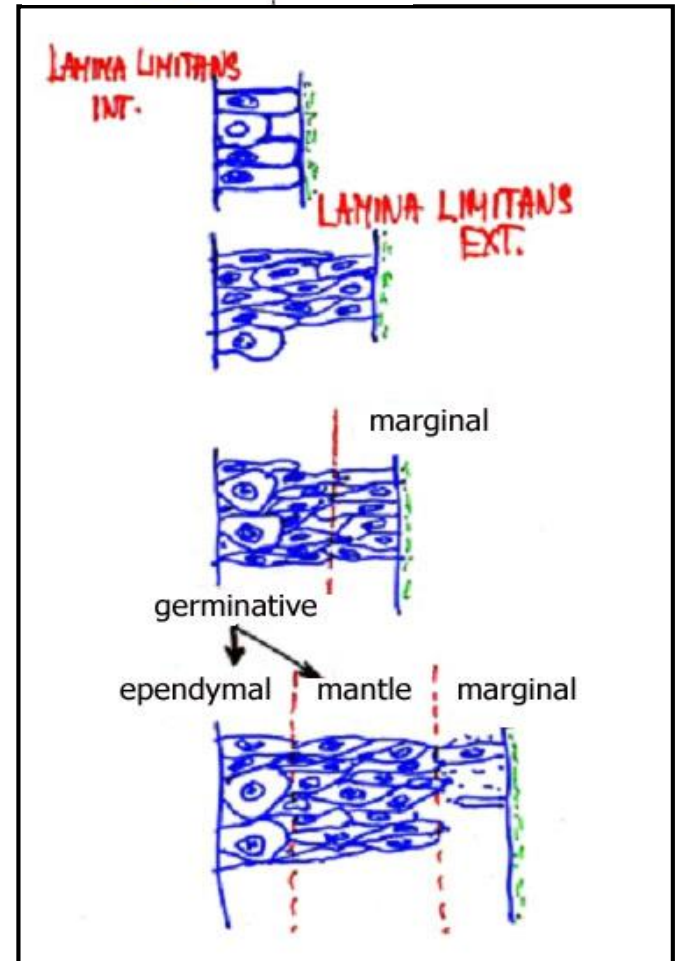
# Nerve tissue – Histogenesis of neural tube



- initial state - **pseudostratified columnar** epithelium
- initially cells divide in whole thickness of the wall
- later mitotic activity is reduced only to cells situated near the luminal aspect of the neural tube

- neural tube develops 2 zones: **germinative** (inner) + **marginal** (outer)
- cells of the germinative zone continue dividing and migrate peripherally to form **mantle layer**

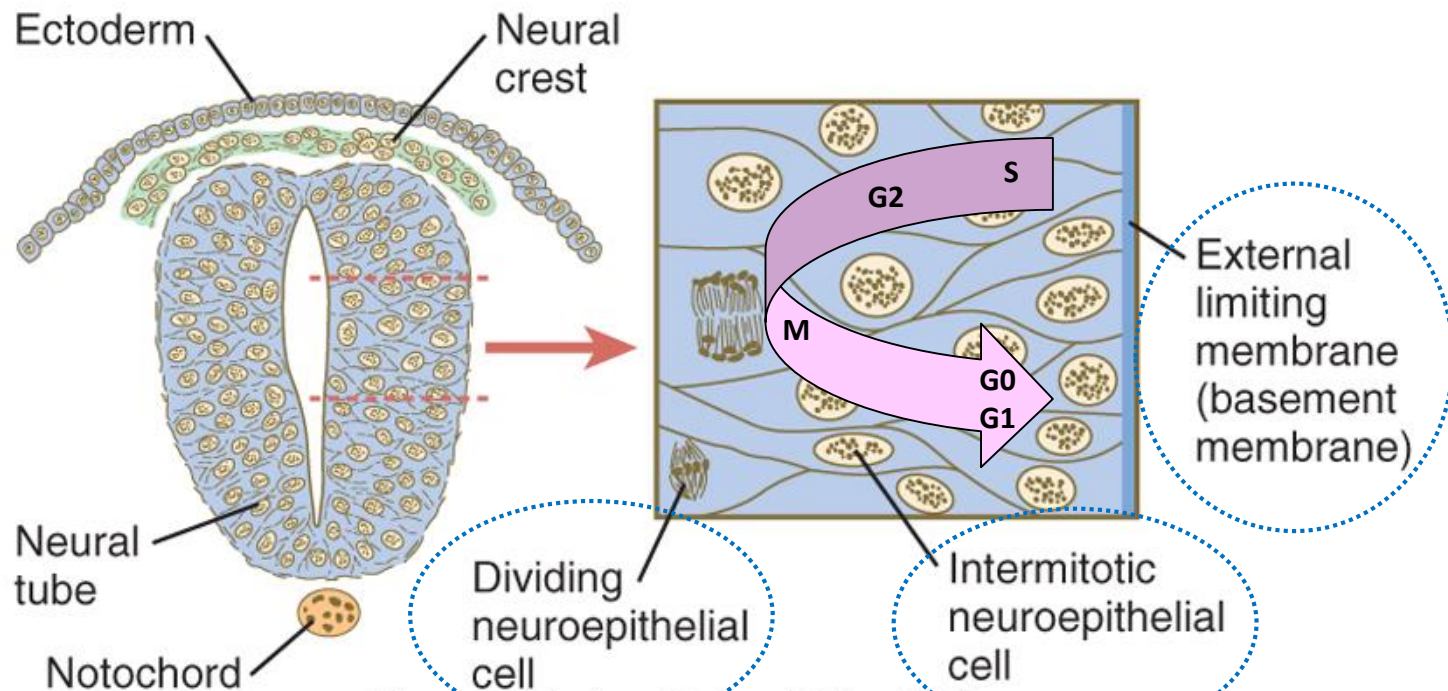
- **ependymal** layer = **ependyma**
- **mantle** layer = **gray matter** - differentiate into primitive neurons - neuroblasts and spongioblasts (glioblasts)
- **marginal** layer = **white matter** (contains no cells)



# Nerve tissue – Neural tube

The **early neural tube** is a pseudostratified epithelium

- The “**apical**” portion abuts the **central canal**
- The “**basal**” portion abuts the **surrounding tissue** (e.g. somites, notochord, etc.).
- Cell division occurs in the apical portion.





# Nerve tissue – Neural tube – Cell differentiation

## Ependymal layer:

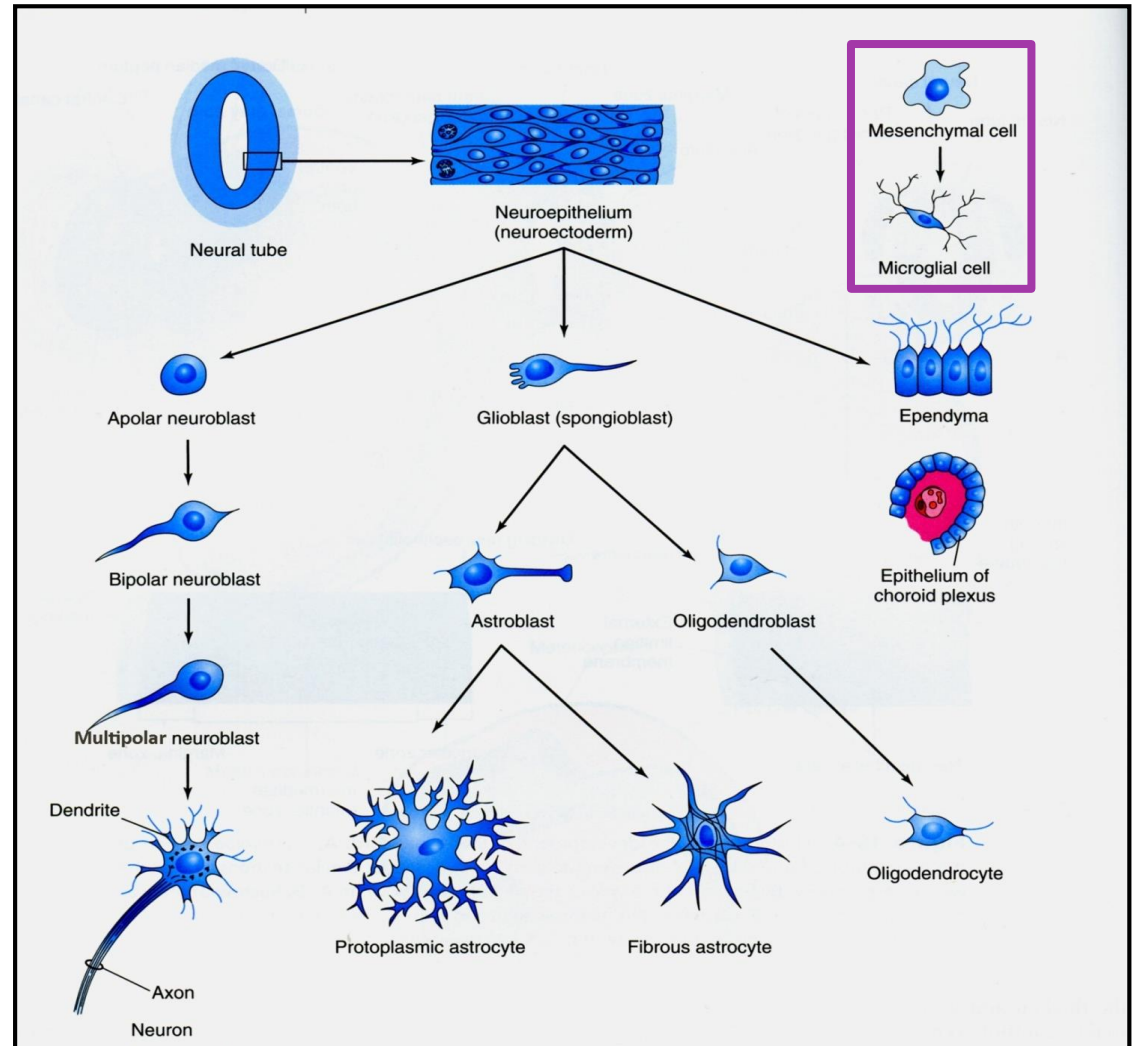
- **ependymal cells** (ependymocytes)

## Mantle layer:

- **neuroblasts** - to neurons
- **spongioblasts (glioblasts)** – to:
  - astrocytoblasts
  - oligodendrocytoblasts

## Marginal layer:

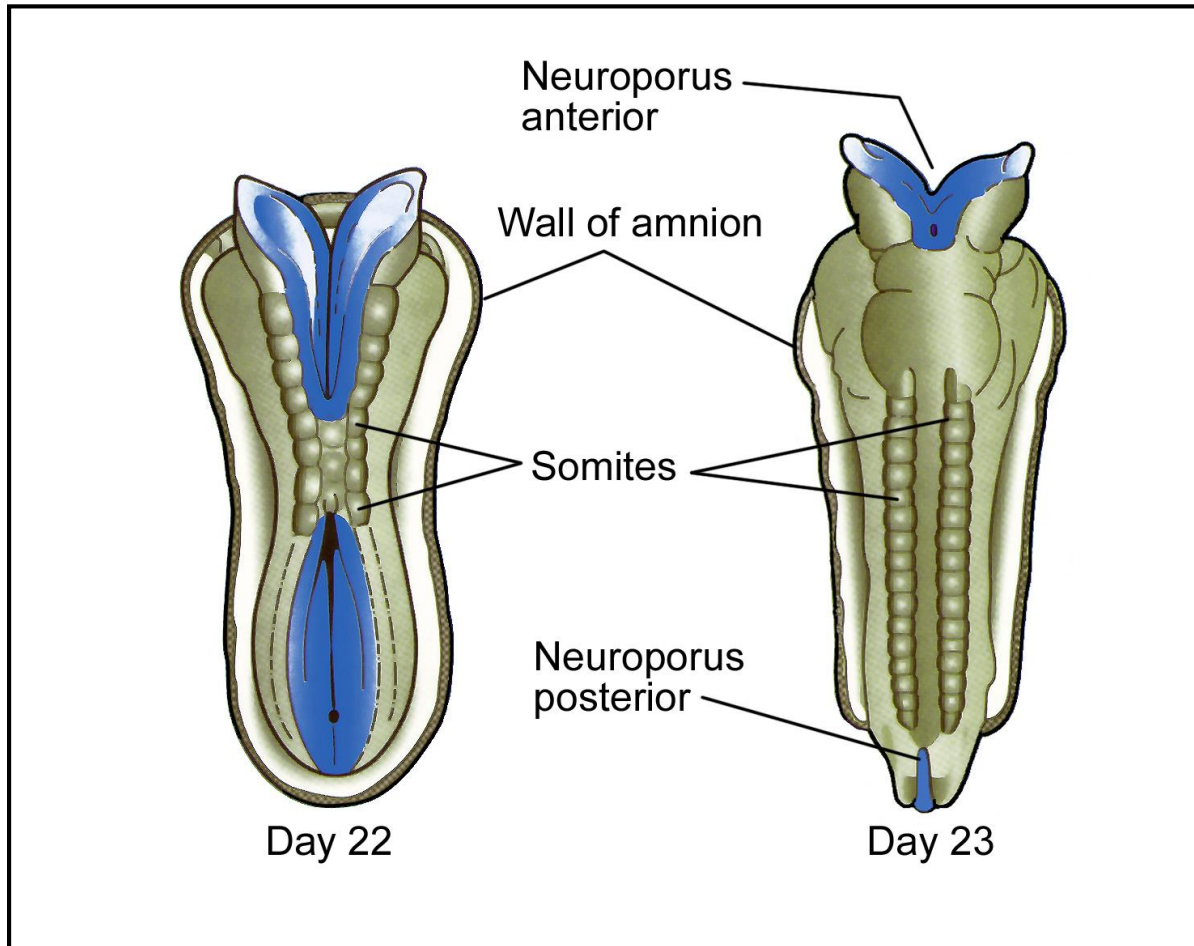
- no cells



# Nerve tissue – Morphogenesis

**Brain** – develops from the proximal segment of the neural tube that is broadened from the very beginning

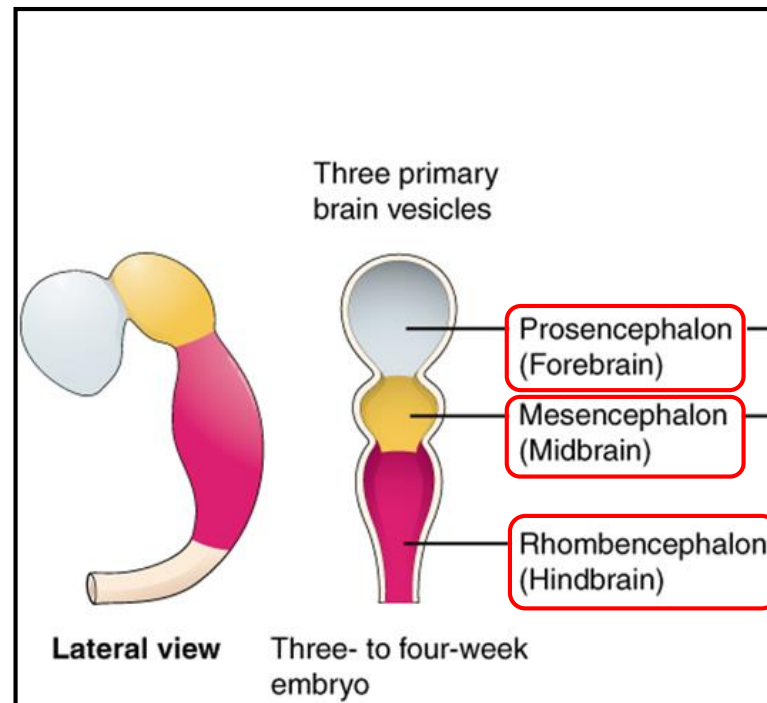
**Spinal cord** – develops from the narrower caudal segment of the neural tube



# Nerve tissue – Brain development

Brain develops from the cranial part of the neural tube at **4th week** - **3 primary brain vesicles**

- Forebrain - prosencephalon
- Midbrain - mesencephalon
- Hindbrain - rhombencephalon



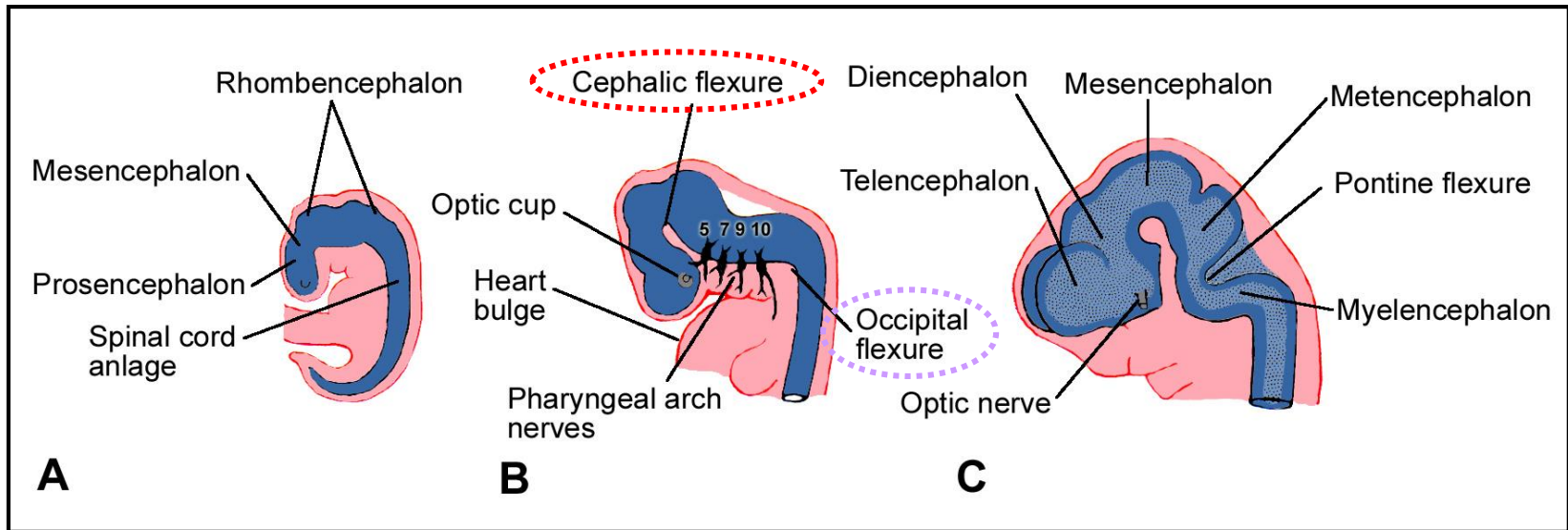


# Nerve tissue – Brain development

vesicles are not followed each to other linearly, but are bent in the sagittal plane

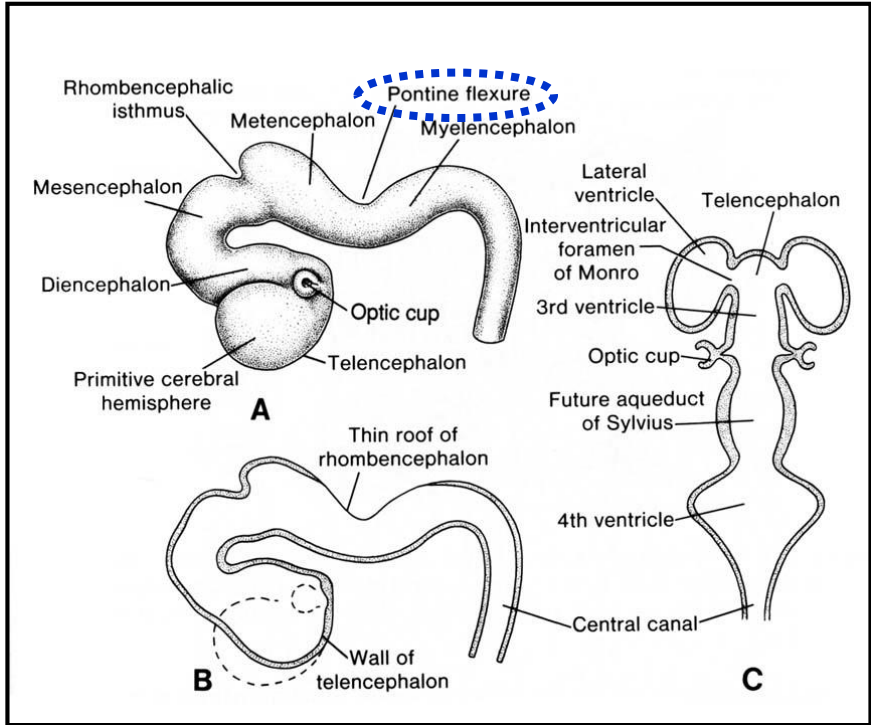
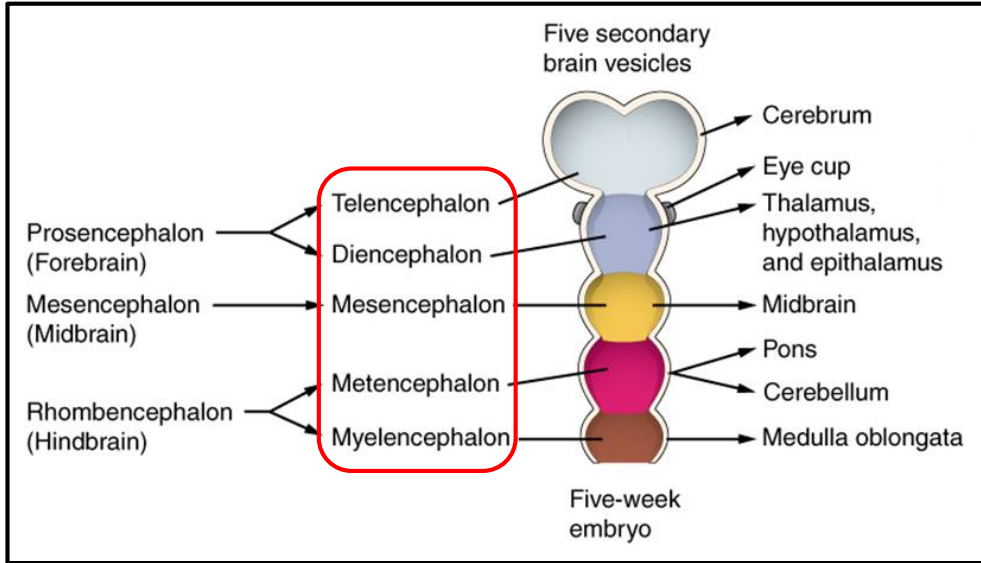
**Cephalic flexure** - permanent

**Occipital (cervical) flexure** - after 2 months it is on straightening, so is not evident in the adulthood

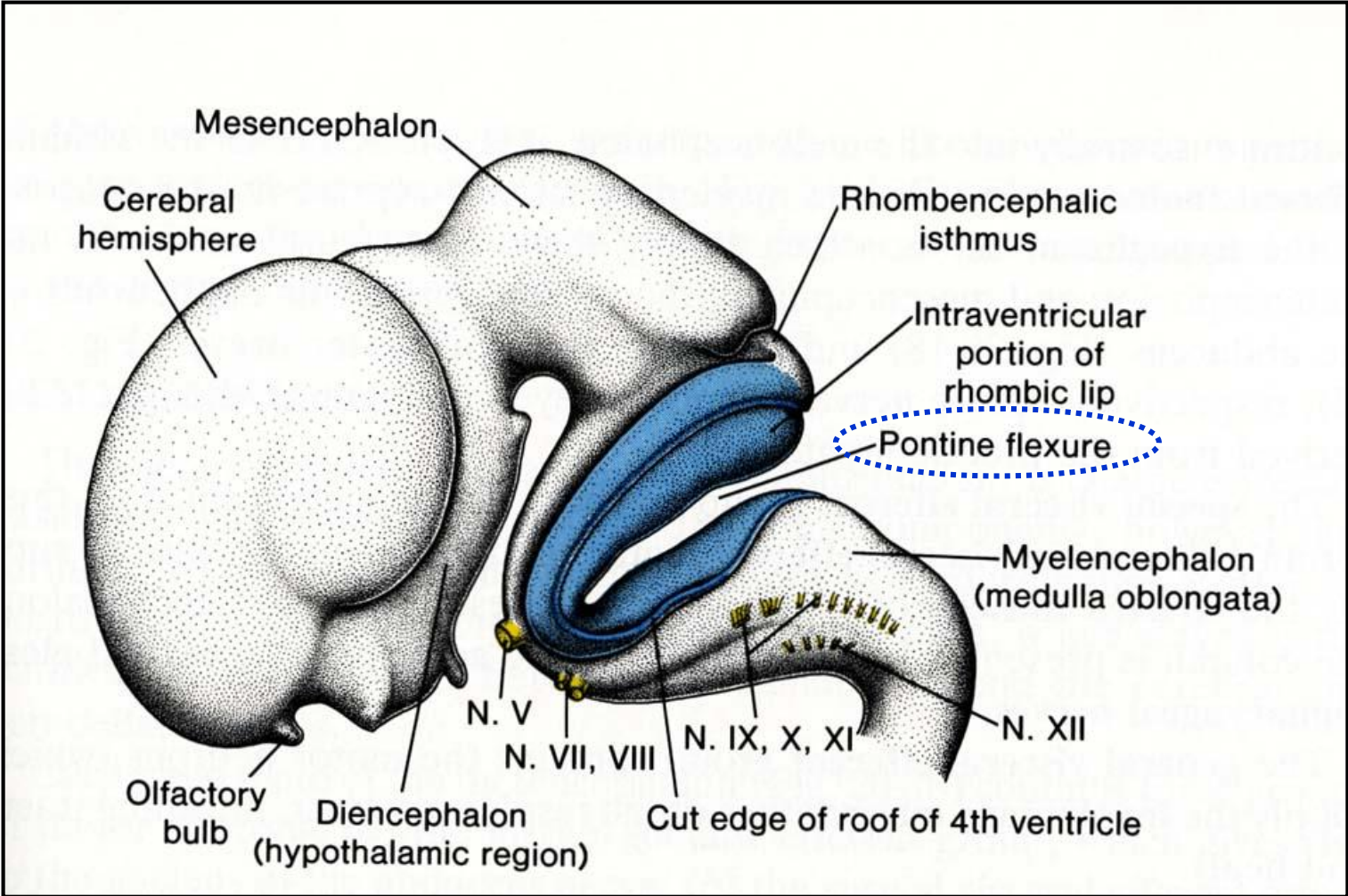


# Nerve tissue – Brain development

- 5th week
- **5 secondary vesicles**
- **Pontine flexure** – remains to adulthood



# Nerve tissue – Brain development



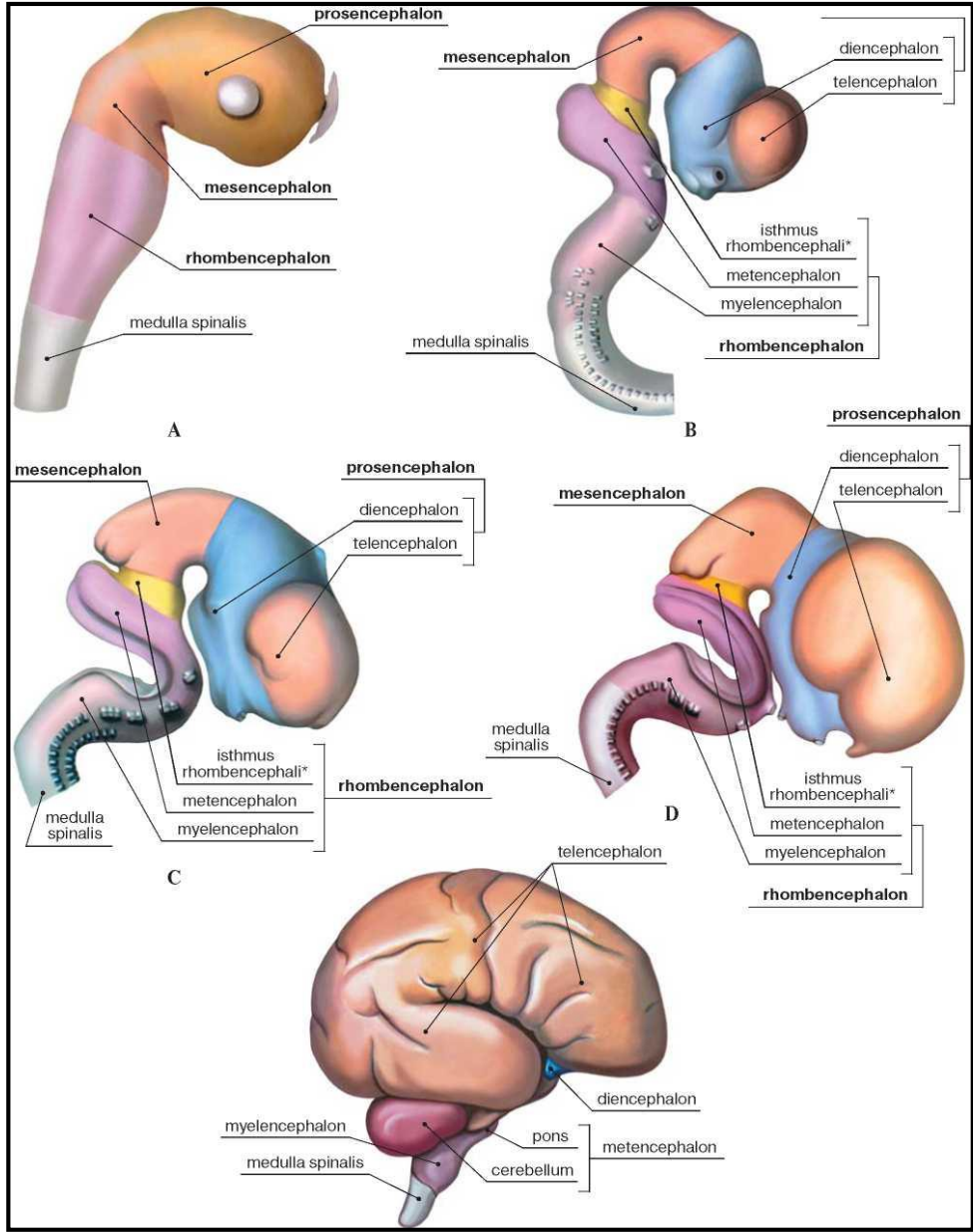


# Nerve tissue – Brain development

**Early brain development results in:**

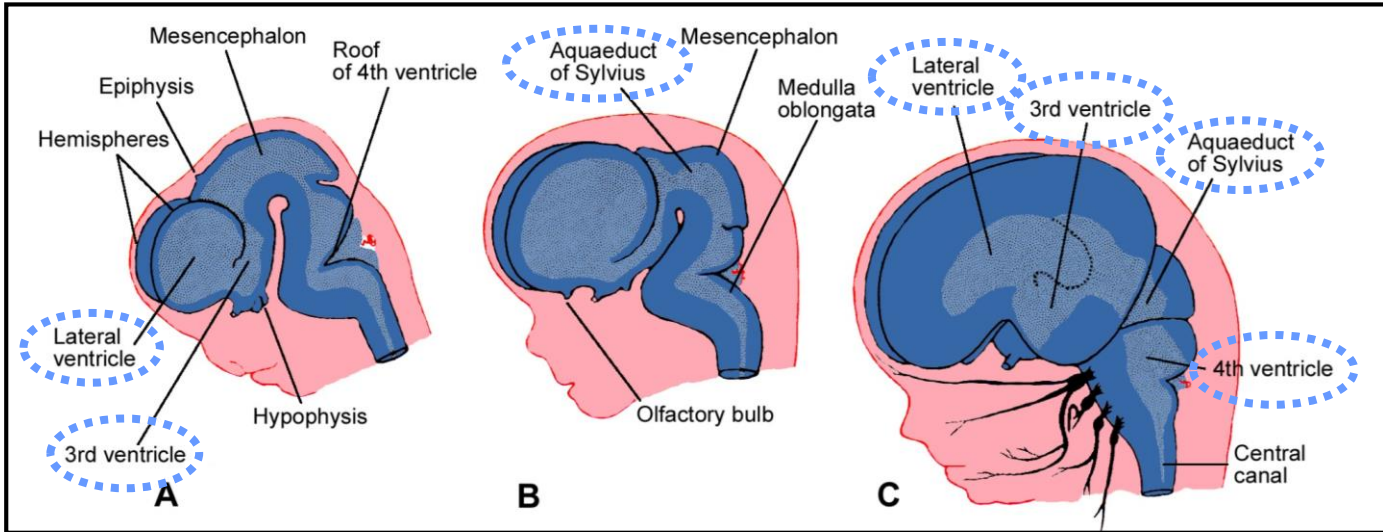
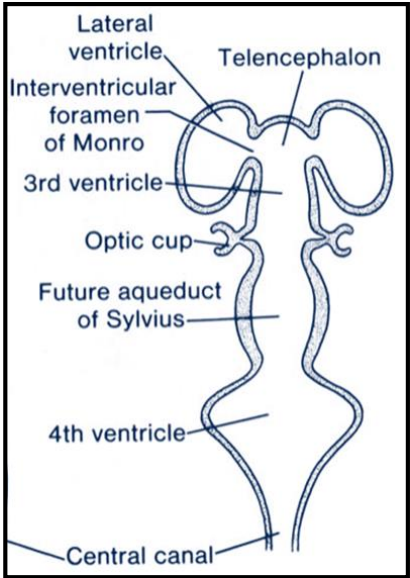
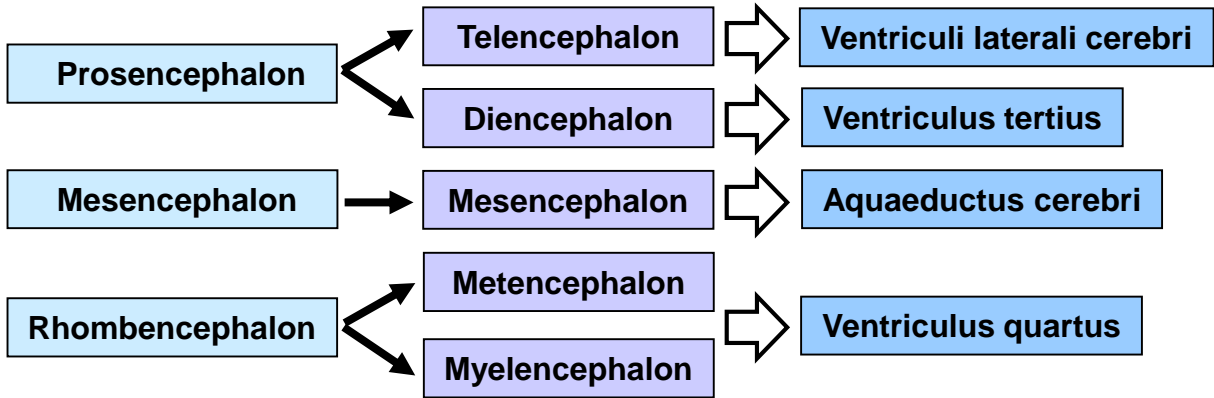
- deflection of the brain base
- constitution of five final brain sections

Definitive position compared to the baseline situation is highly complicated due to different growth rates of individual sections.



# Nerve tissue – Brain development - Ventricles

**You must memorize !**

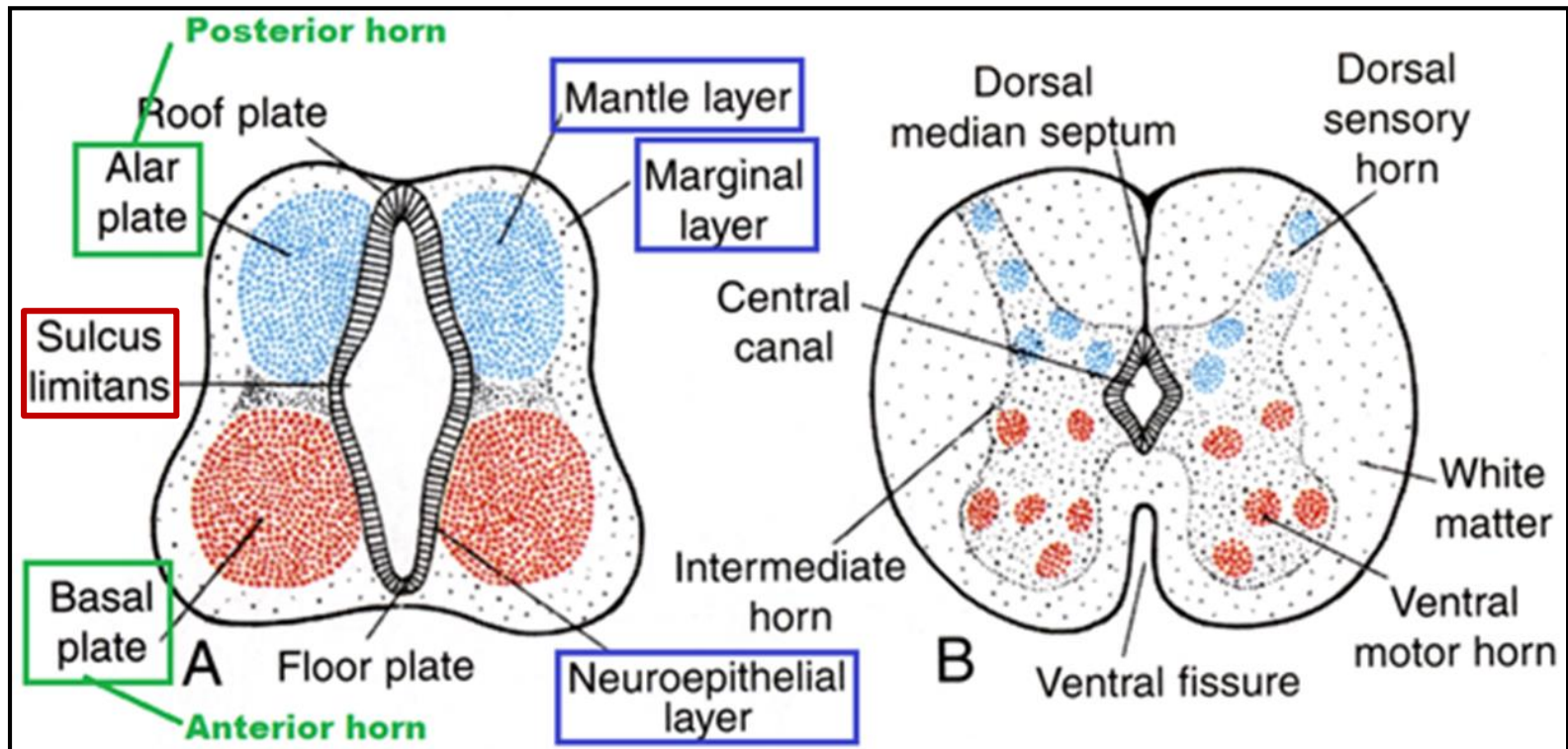


# Nerve tissue – Spinal cord development

- it develops from the caudal part of neural tube
- cells of mantle layer proliferate and produce 2 sheets - the dorsal **alar plate** and ventral **basal plate**, which are separated by longitudinal groove called the **sulcus limitans**

## To remember:

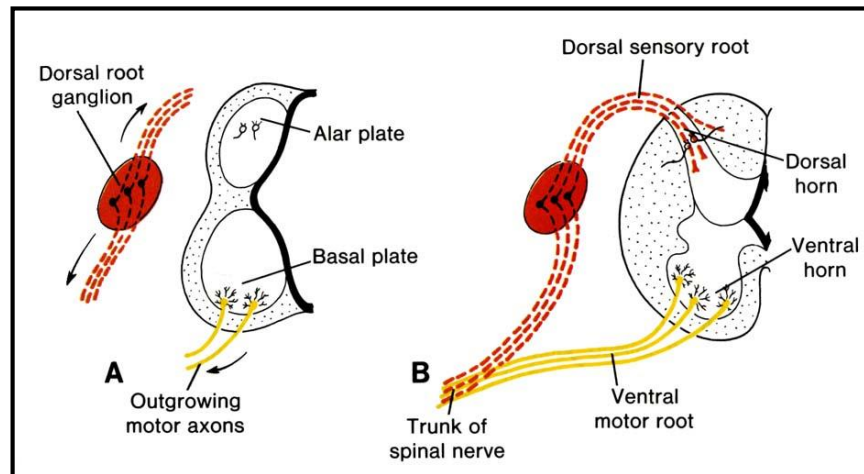
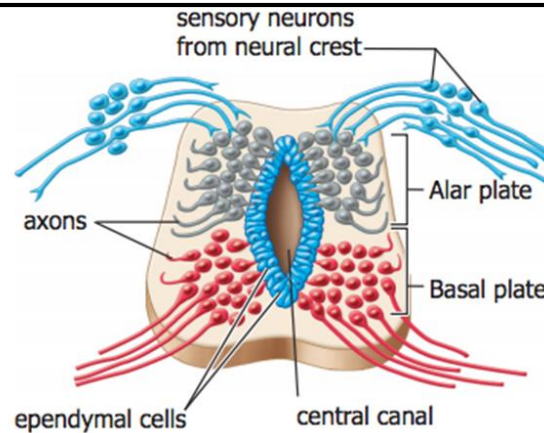
- **alar plate** - gives rise to **dorsal horn**
- **basal plate** - gives rise to **ventral horn**





# Nerve tissue – Spinal cord development

- Alar plate
  - Dorsal neuroblasts form sensory interneurons
- Basal plate
  - Ventral neuroblasts form **motor** neurons
- Axons form white matter.

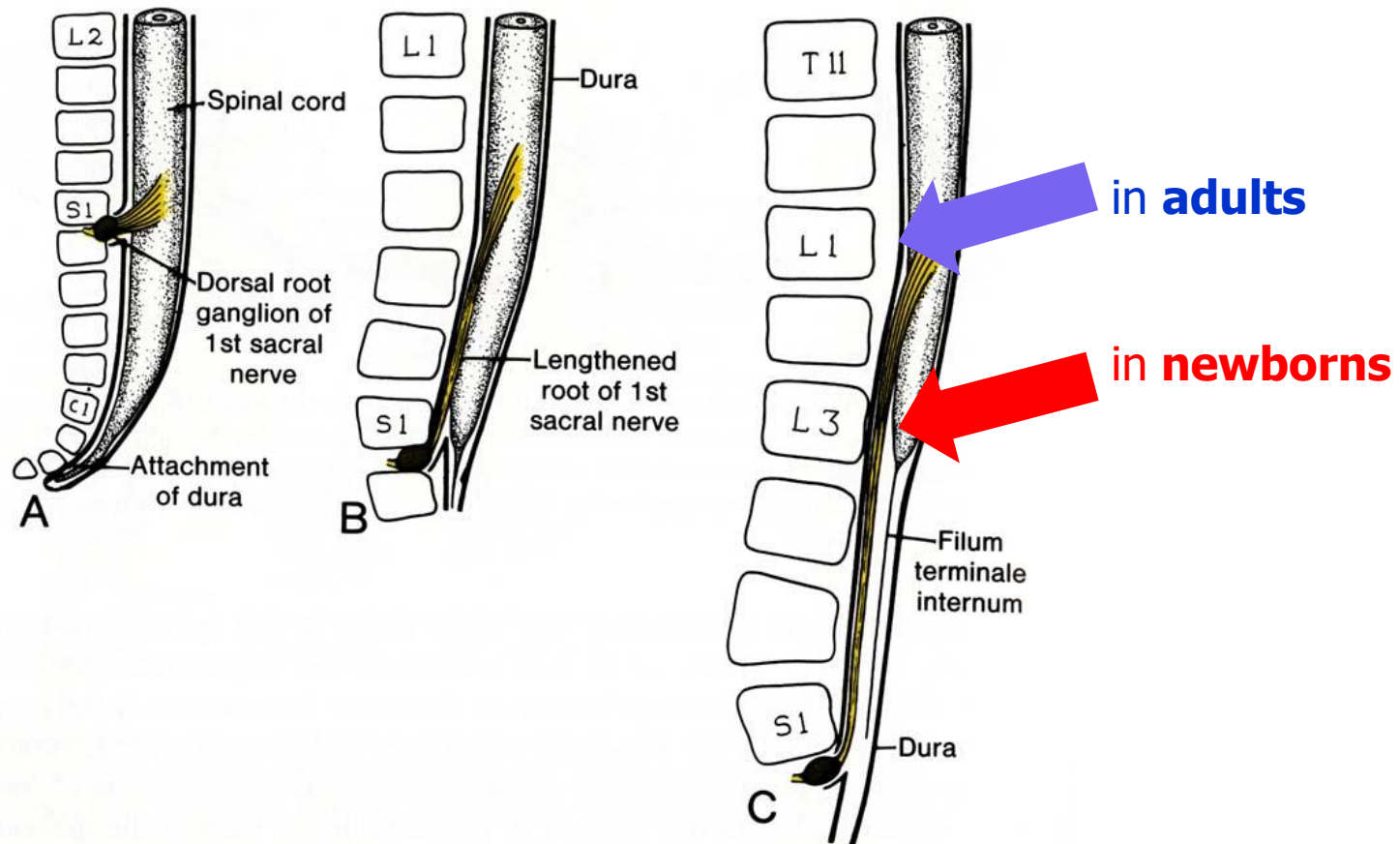


Axons of neuroblasts of anterior horns unite with peripheral processes of corresponding spinal ganglia neuroblasts and together leave the spinal canal as a trunk of **spinal nerve**.

# Nerve tissue – Spinal cord development

## Positional changes of the spinal cord

- initially, length of spinal cord correlates with length of the vertebral canal
- during further development, the vertebral canal grows more rapidly than spinal cord so that its caudal end gradually comes to lie at relatively higher levels of the canal
- in adults, it usually terminates at the inferior border of the first lumbar vertebra



**Thank you for your attention !**

**Questions and comments at:  
ahampl@med.muni.cz**