

# Musculoskeletal tumors

Janíček, P, Pazourek L.,  
Ondrůšek Š., Rozkydal, Z.

# *Classification*

- Malignant
- Benign
- Tumor like lesions
- Metastases

They are produced in mesenchym

Most of them are benign

Malignant tumors 1-2 % of all malignancies

Bone sarcomas

Soft tissue sarcomas

# *Symptoms*

- Pain
- Swelling
- Impaired function
- Pathological fracture
- General symptoms (fever, weakness, cachexia ...)

# *Diagnostics*

- History
- X-ray
- CT / MRI
- Scintigraphy of the skeleton
- Chest X-ray, CT of the lungs
- Ultrasonography of the abdomen
- Biopsy (histology)
  
- Other imaging methods (PET, angiography, laboratory tests. Genetic examination ...

# Biopsy

- True cut biopsy
- Needle biopsy under CT
- Excisional biopsy
- Histology- experienced pathologist
- Biopsy – in special centres

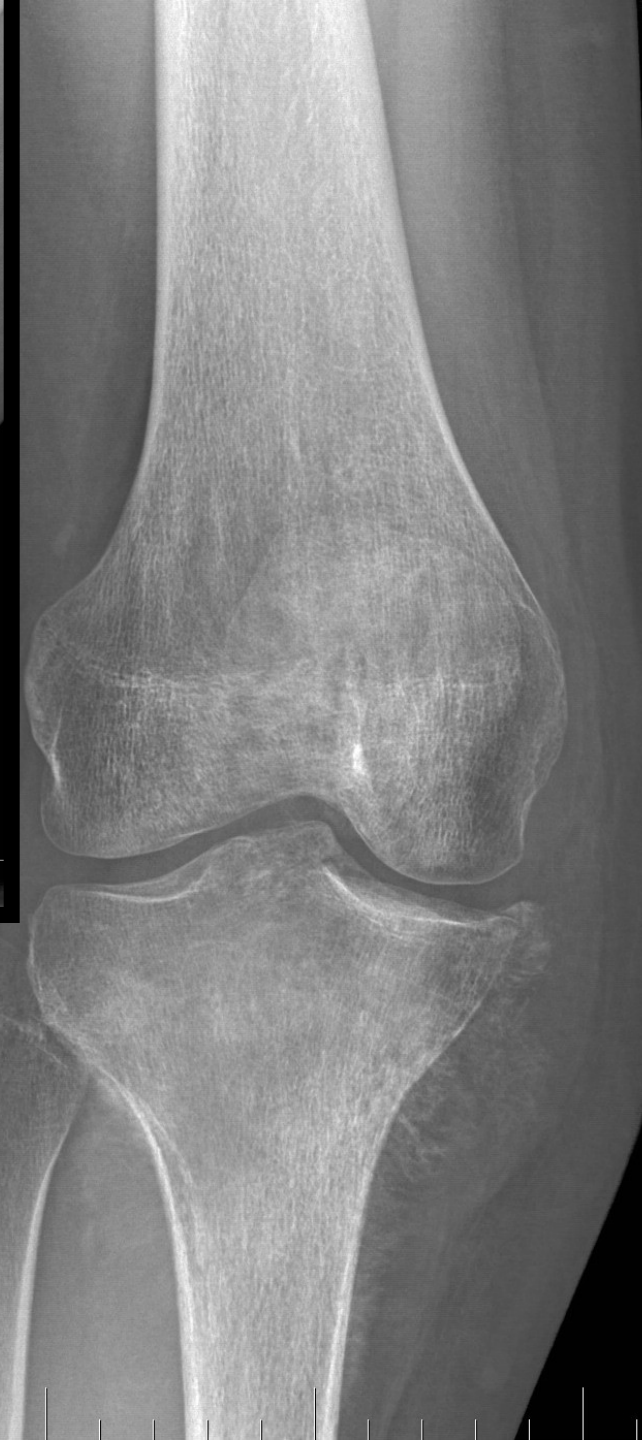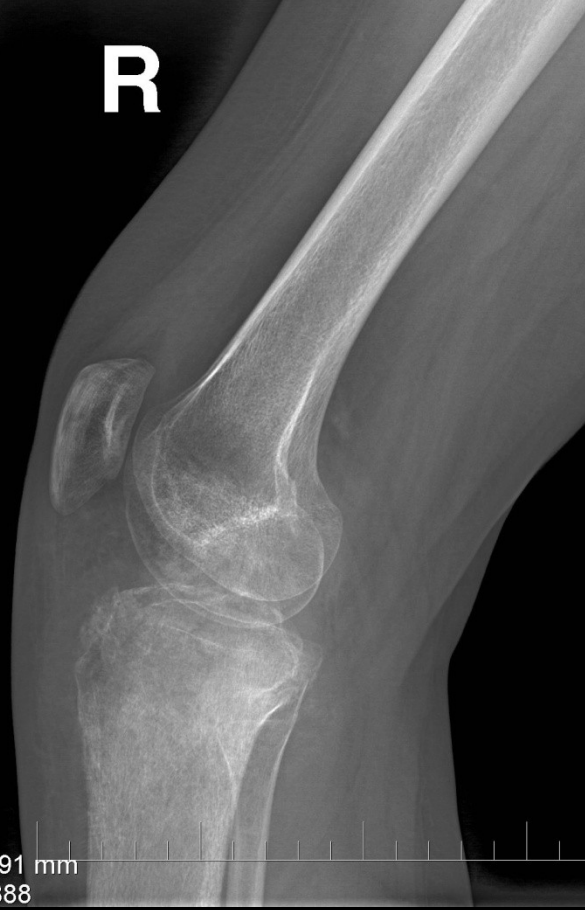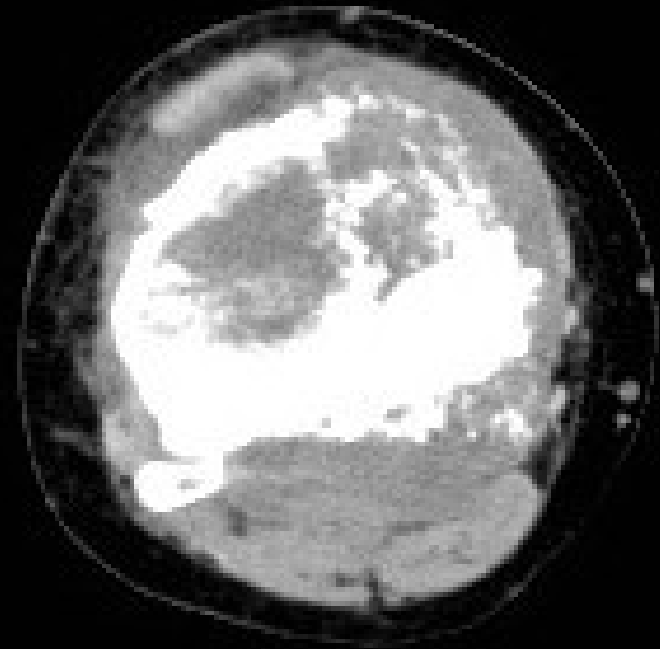
# ***X-ray finding in malignant bone tumors***

- Aggressive lesions
- Periosteal reaction
- Erosions of cortex
- Endostal irregularities

# Irregularities

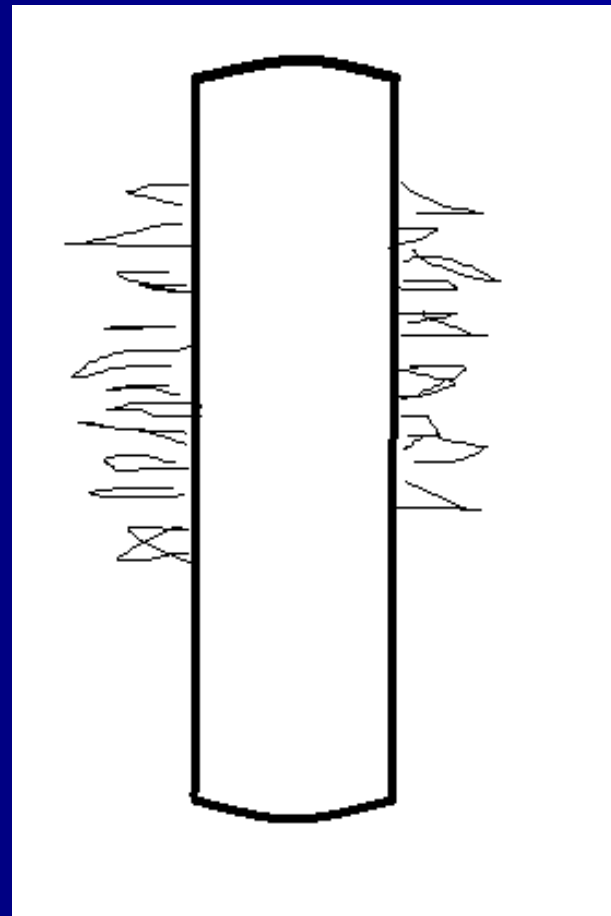
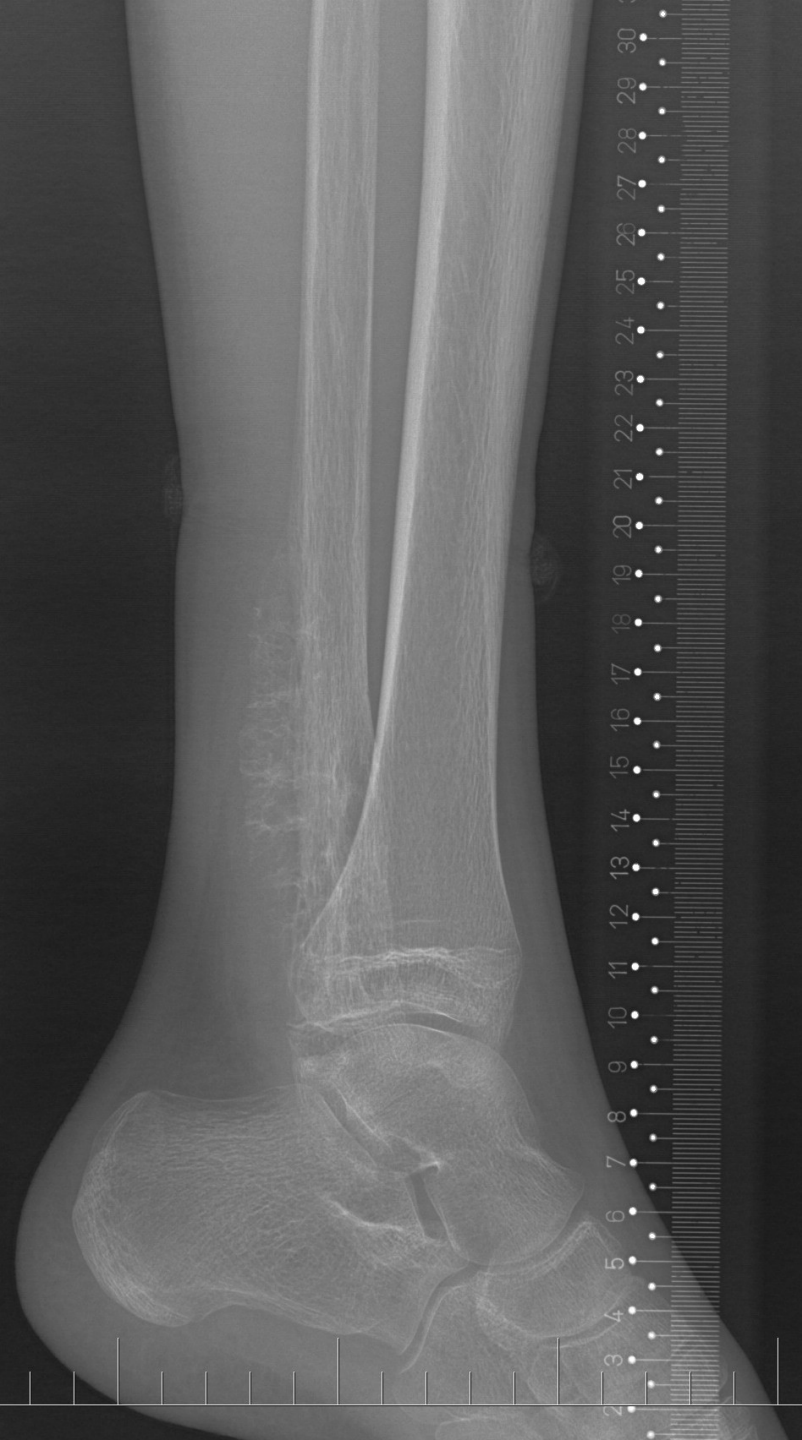R

91 mm  
388

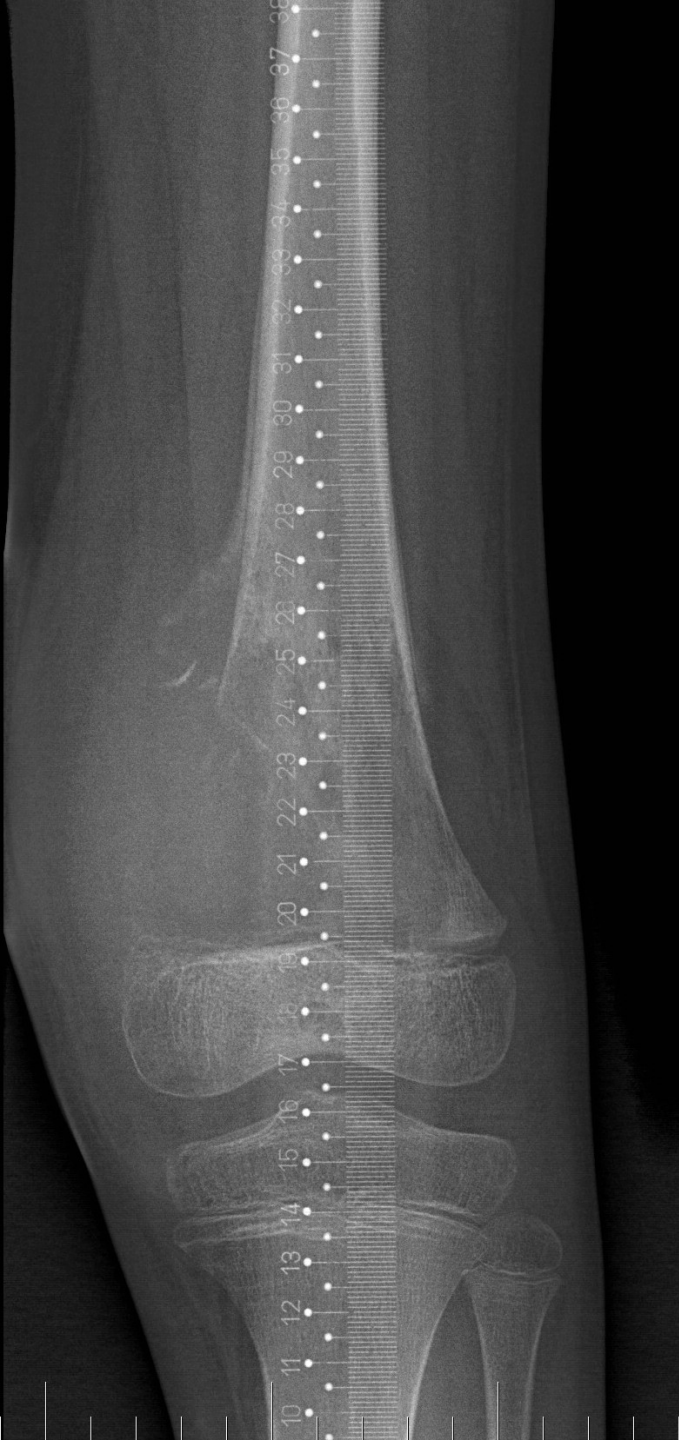




# Periosteal reaction (spikes)

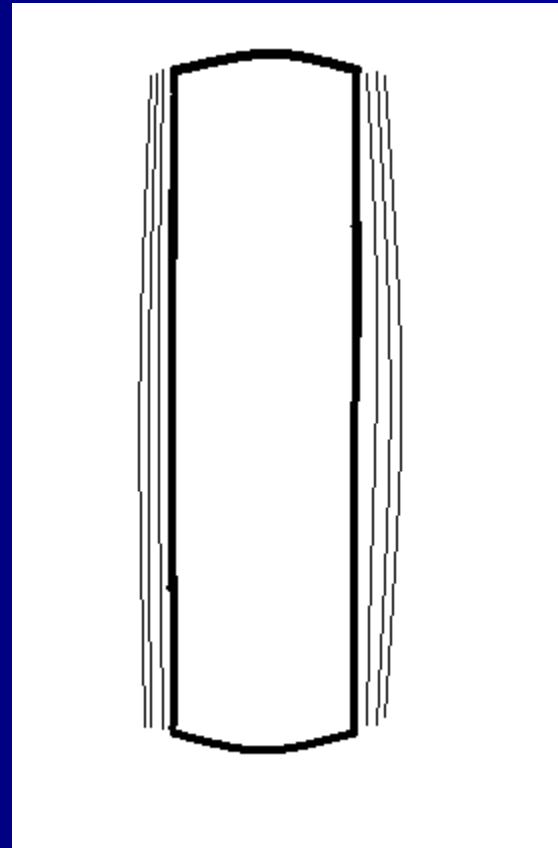


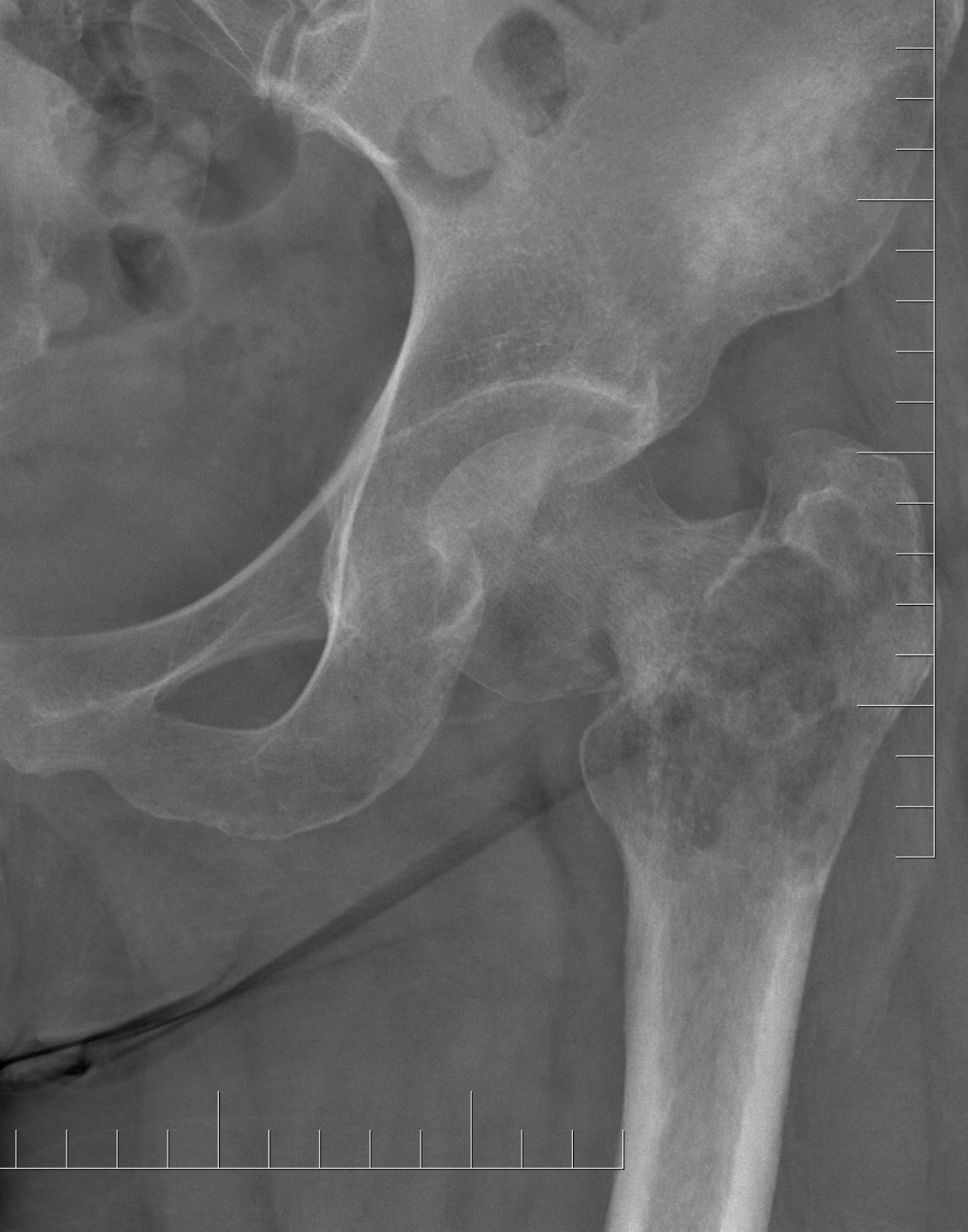# Codman's triangle



R

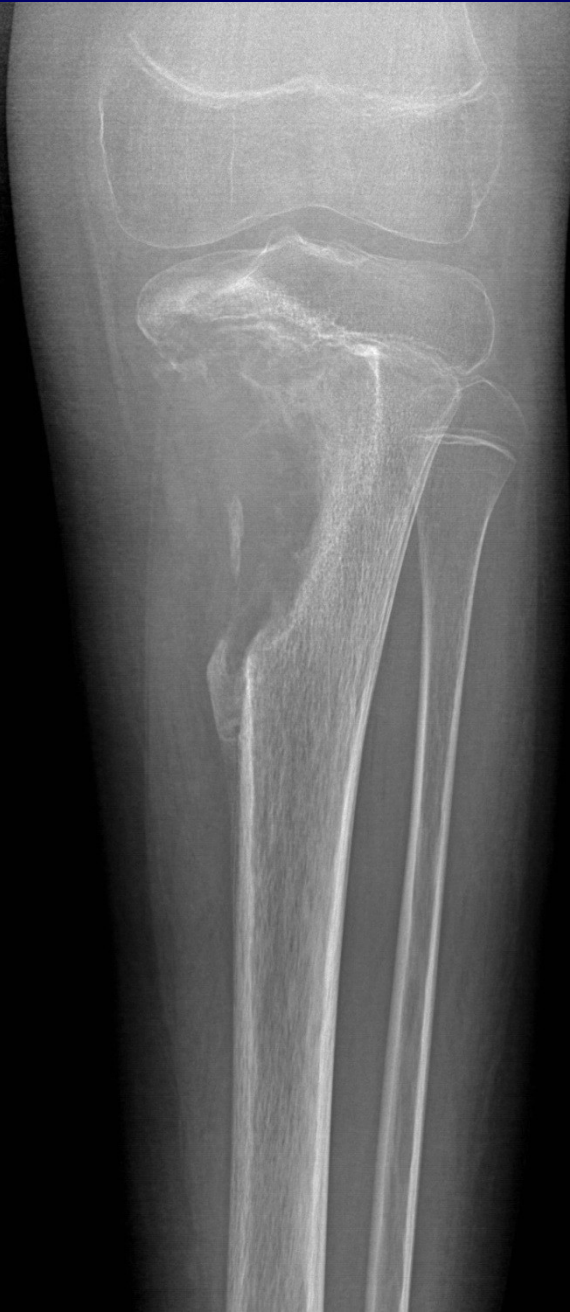# Onion-like periostosis



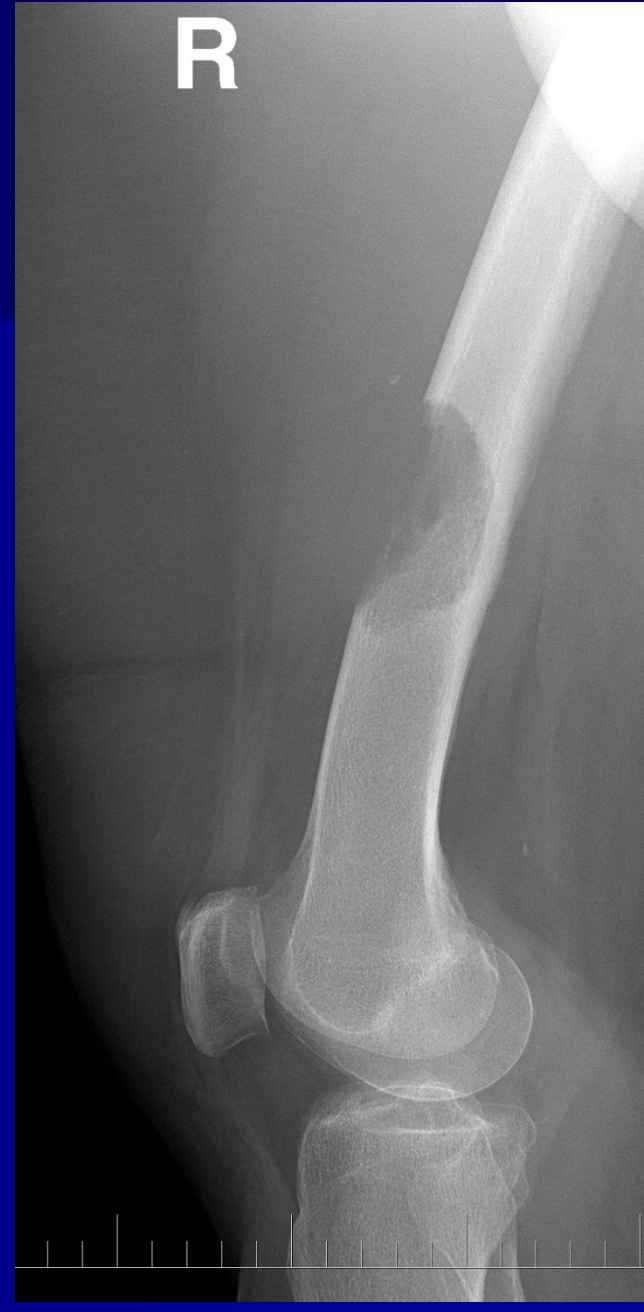

**Osteolytic  
patches**

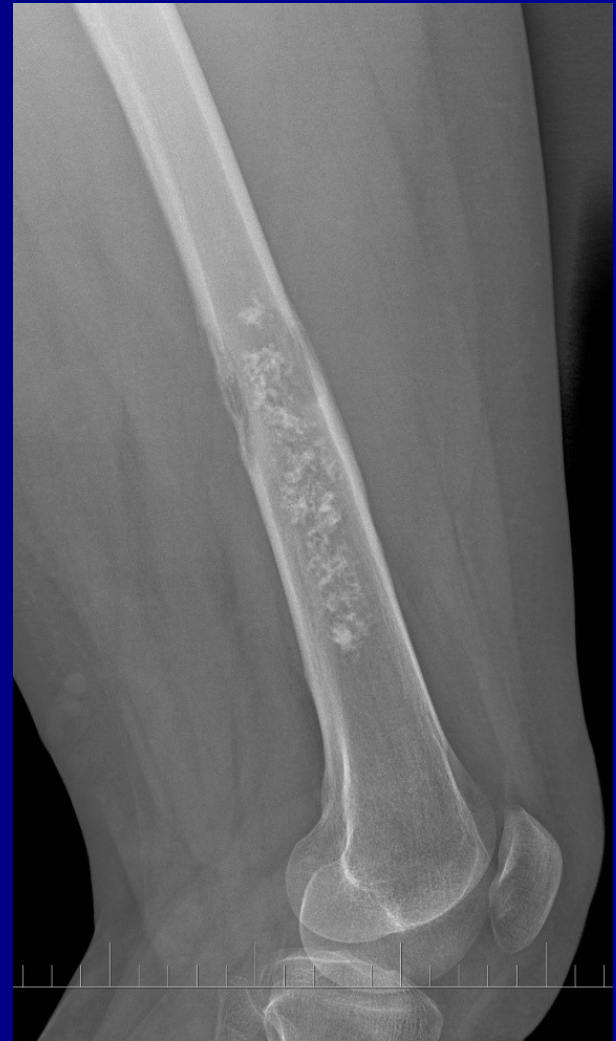
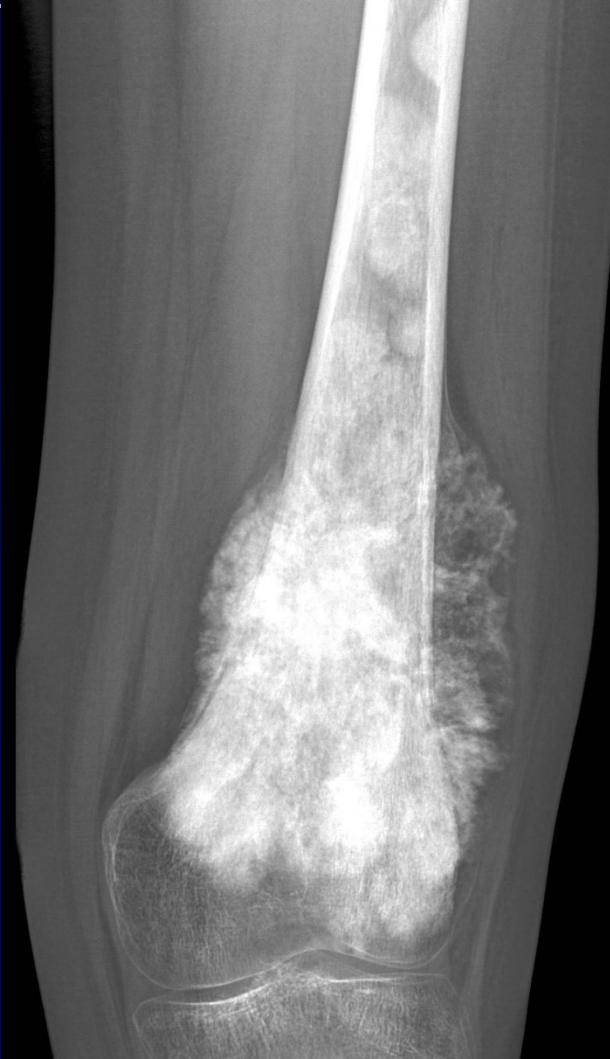


# Erosions of the cortex



# Expansion of the tumor



# Age

- 1. decade: EwingSA
- 2.-3. decade: OSA
- 3.-4. decade: osteoclastoma, parosteal OSA, chondrosarcoma ...
- 5. decade ....: Myeloma, secondary bone tumors, chondrosarcoma

# Staging

TNM classification

T1- T4 (size and localisation)

N0-2 (lymphonodes)

M0, M1- lung, skeleton, liver, CNS



# Staging of musculoskeletal tumors (Enneking)

- Grade – biological aggressivity
- Local finding (T)
- N0-2 ( lymphonodes)
- M0-1 (metastases)

# Biological agresivity, Grade

Summary of  
clinical, radiological and histological findings

G0 benign cytology

G1 invasive growth, mitoses, anaplastic cells

G2 infiltrative growth, no anatomical margins, high vascularity

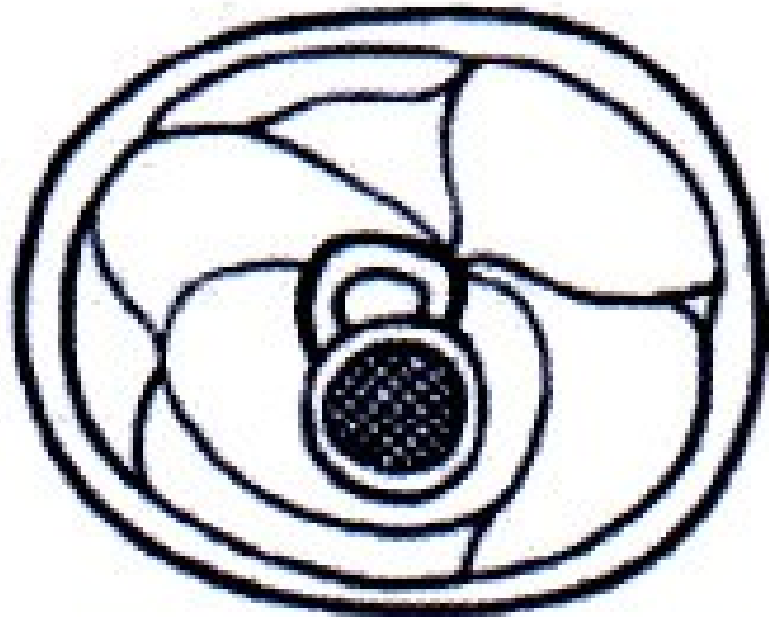
G3 fast growth, dediferencial tumor cells, distant metastases

# Site of tumors

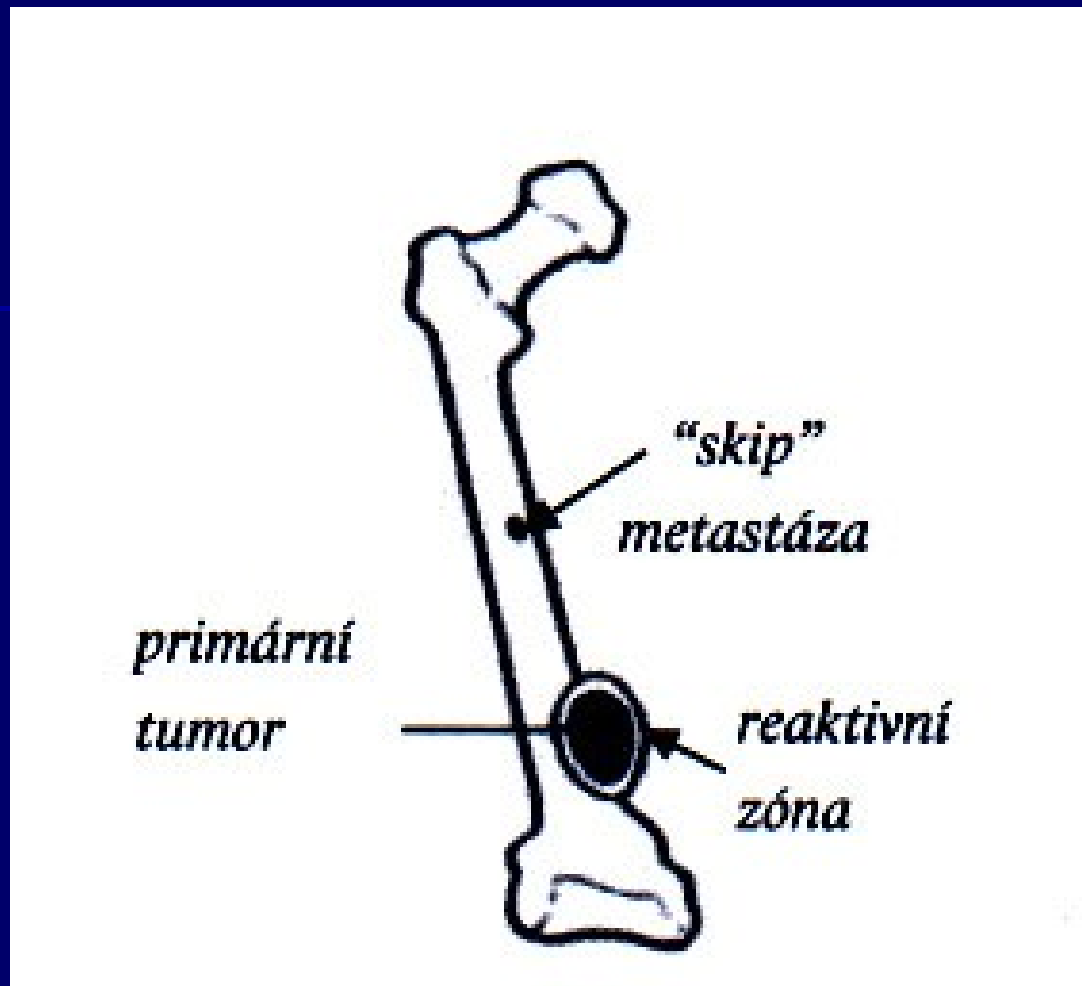
T0 tumor in capsule

T1 extracapsular growth, in compartment  
Satelites in reactive zone

T2 extracompartamental growth



Extracompartmental growth



Reactive zone- satellite metastases  
Skip metastases

# Metastases

M0 no metastases

M1 metastases are present

regional lymphonodes

distant metastases- lung, skeleton, liver, CNS

# Classification

- **I Low grade**

<b>A</b> Intracompartmental	G1-2	T1	M0
-----------------------------	------	----	----

<b>B</b> Extracompartmental	G1-2	T2	M0
-----------------------------	------	----	----

- **II High grade**

<b>A</b> Intracompartmental	G3	T1	M0
-----------------------------	----	----	----

<b>B</b> Extracompartmental	G3	T2	M0
-----------------------------	----	----	----

- **III Metastatic**

<b>A</b> Intracompartmental	G1-3	T1	M1
-----------------------------	------	----	----

<b>B</b> Extracompartmental	G1-3	T2	M1
-----------------------------	------	----	----

# Clinical stage

I. Surgery

II. surgery + radiation + chemotherapy

III. Chemoinduction + radiation (or surgery + chemotherapy)

IV. Palliative management

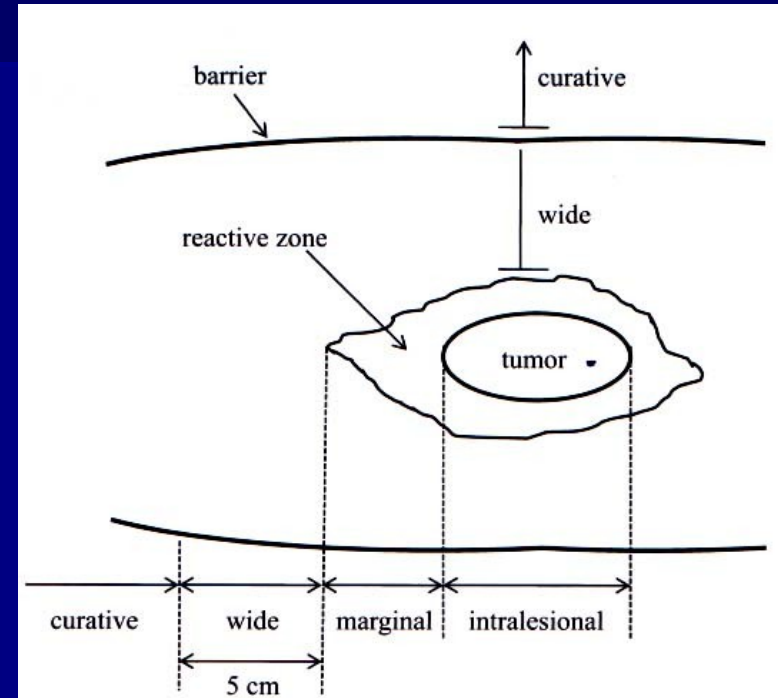


# *Therapy*

- **Local therapy**
  - surgery
  - radiotherapy
  - others (embolisation, RFA ...)
  
- **Systemic therapy**
  - chemotherapy
  - hormonal therapy
  - bisphosphonates
  - biological treatment ...

# *Surgical radicality*

- Radical
- Wide resection
- Marginal
- Intralesional



R0 margins of removed tumor - without tumor cells  
R1 microscopic infiltration  
R2 macroscopic infiltration

# Oncological radicality

R0 surgery is curative

R1 surgery is not curative  
adjuvant radiotherapy

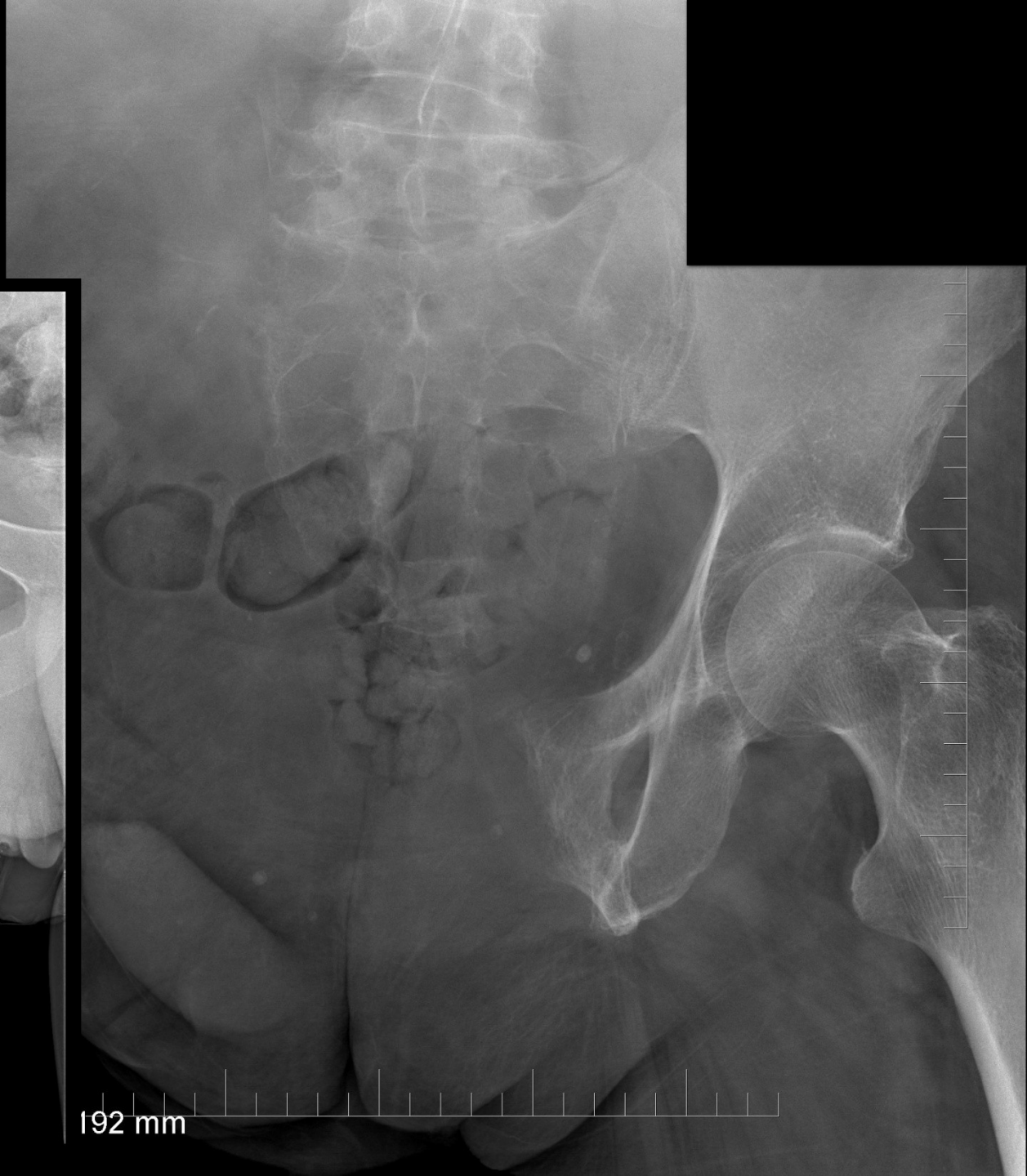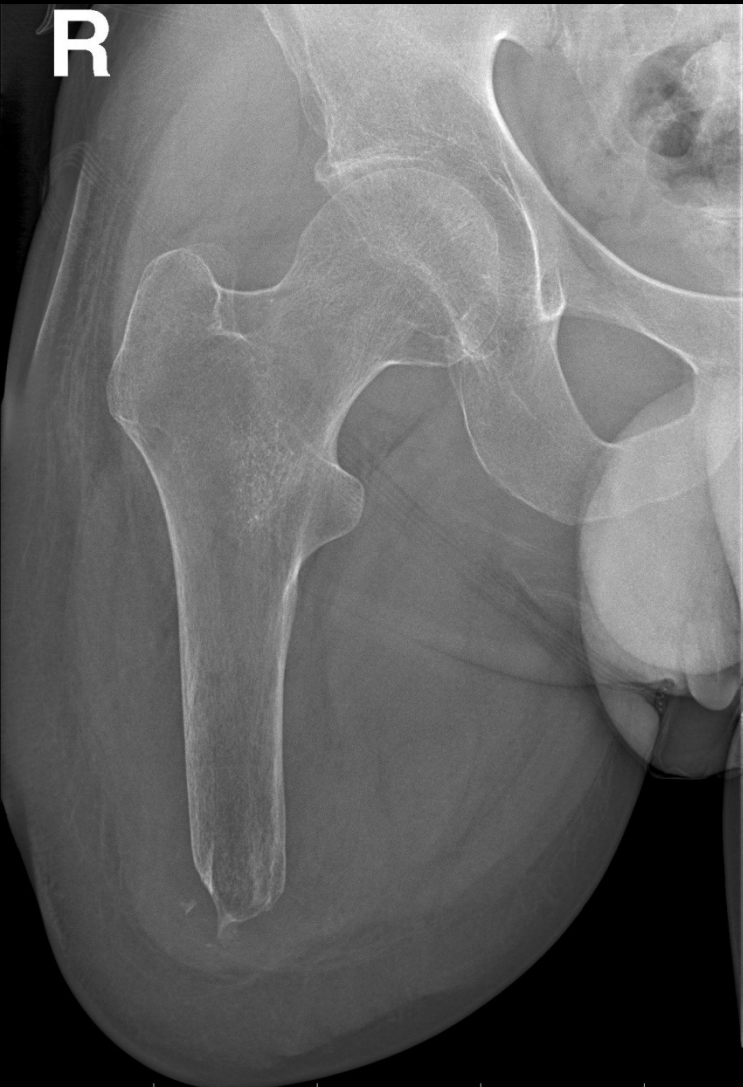R2 debulking  
Surgery is not curative, only paliative  
Adjuvant radiotherapy and chemotherapy

# *Surgery*

- Ablative (amputation, disarticulation)
- Limb-salvage surgery

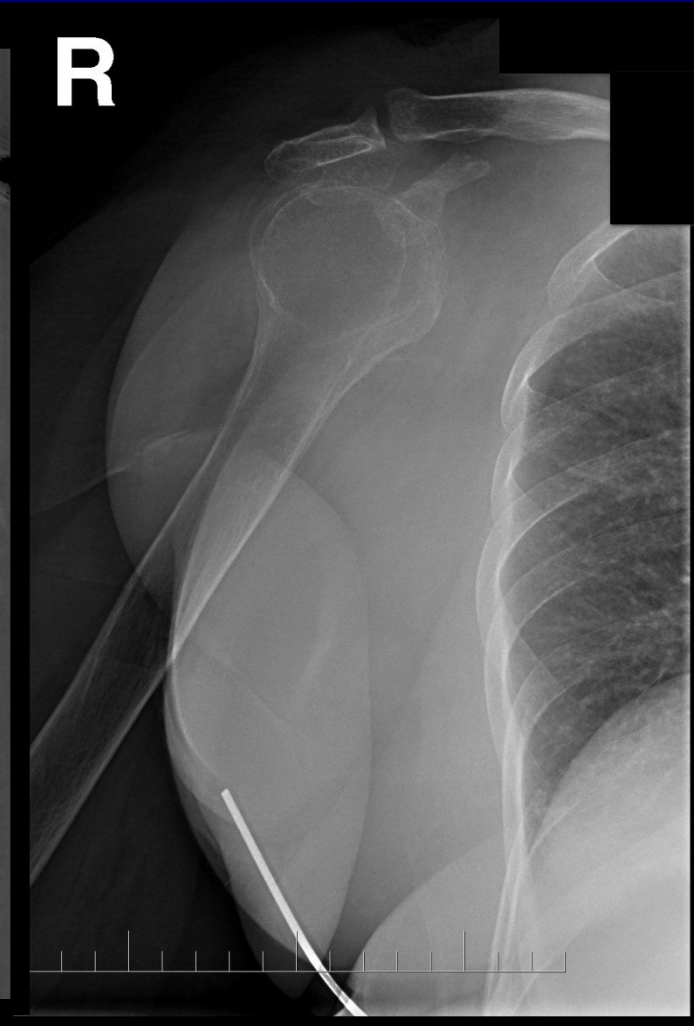
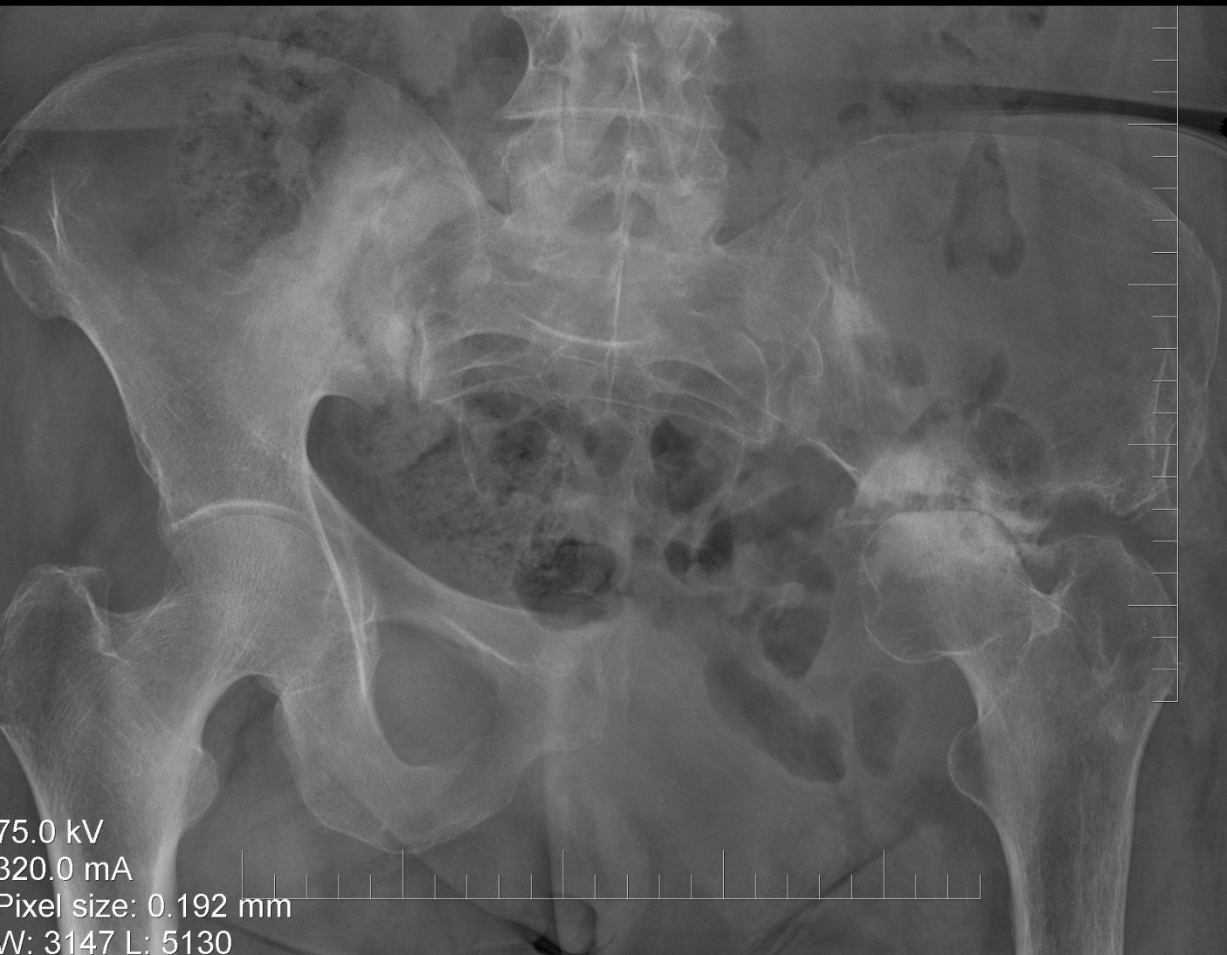# Ablative

R



192 mm

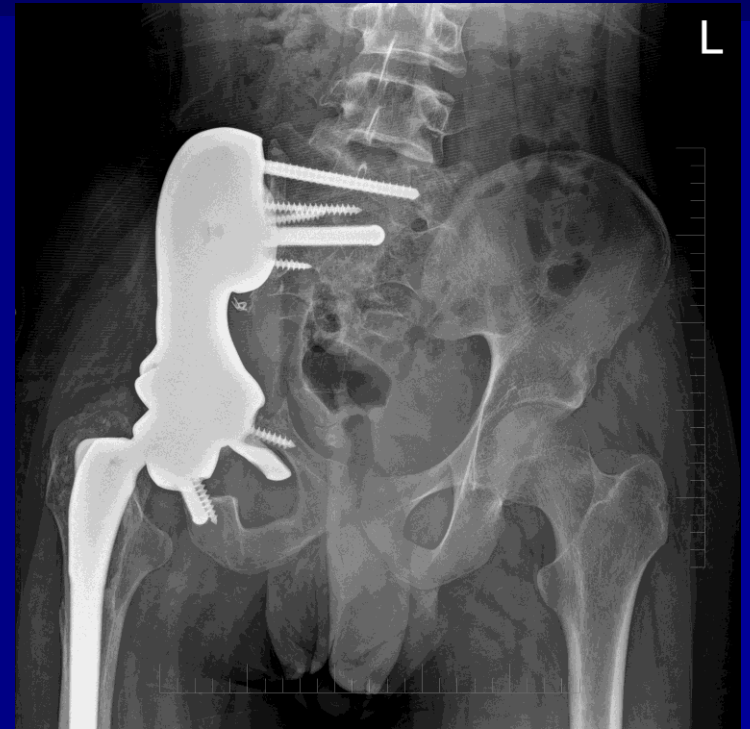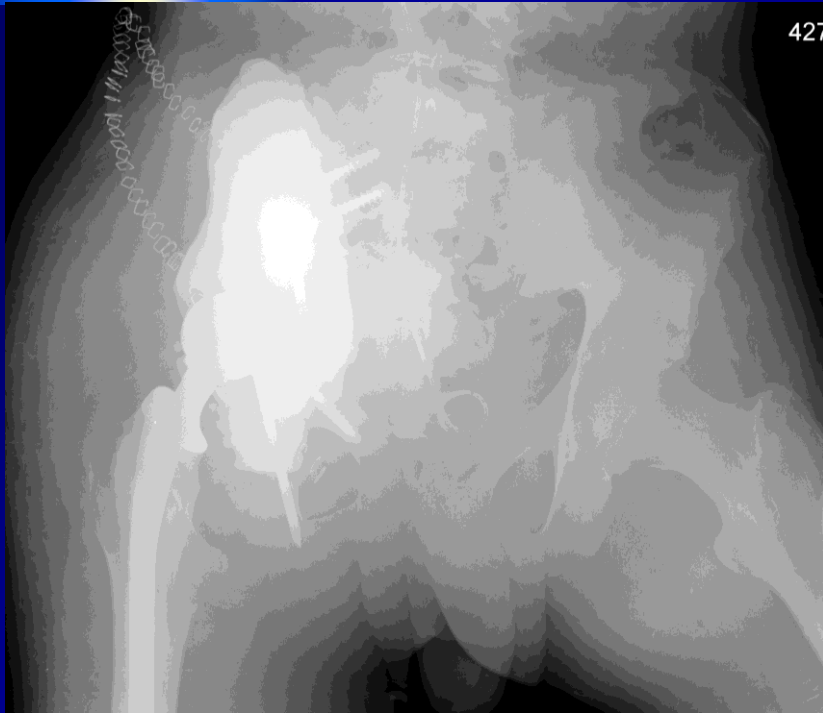
# Conservative hemipelvectomy Scapulectomy





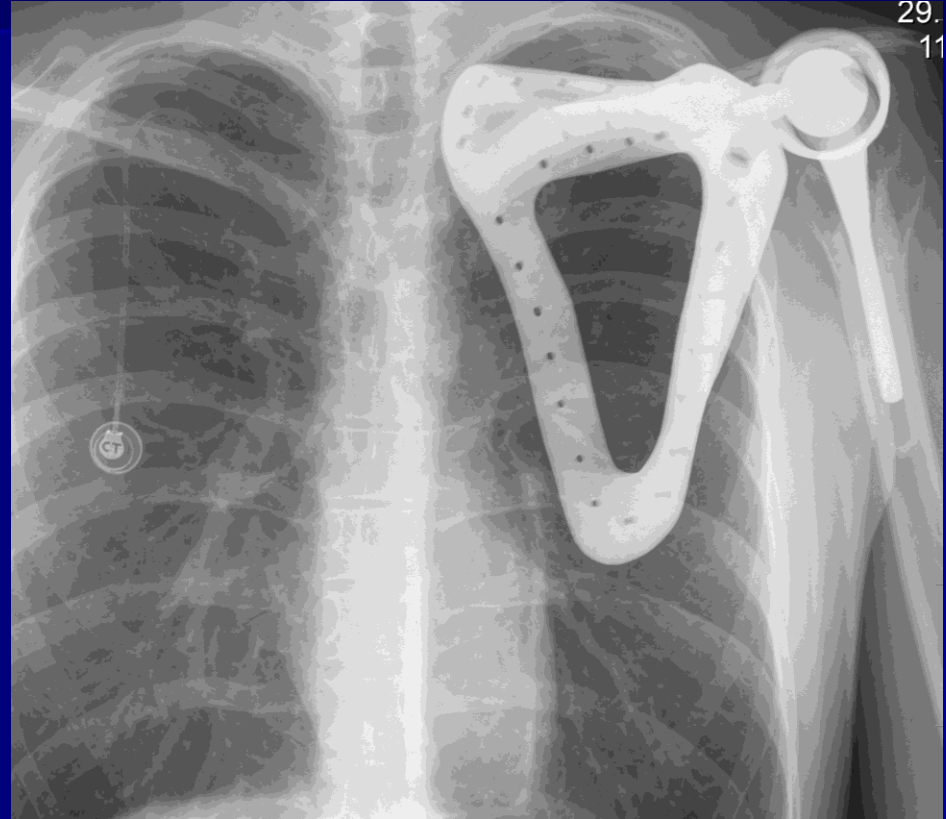
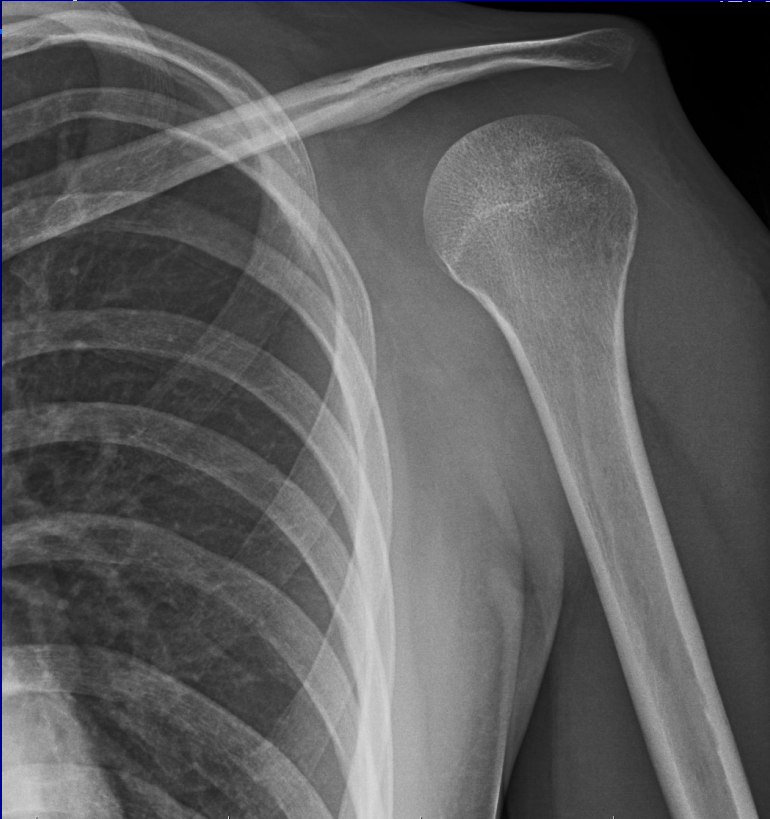# Tumor of the pelvis

1. Stage- removal, bone cement + THA
2. Stage- replacement + THA



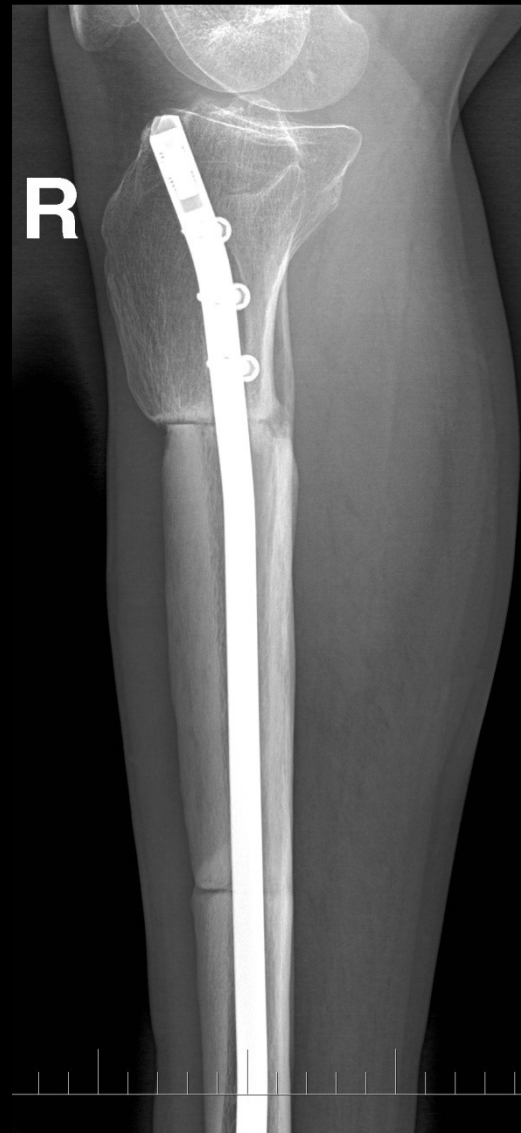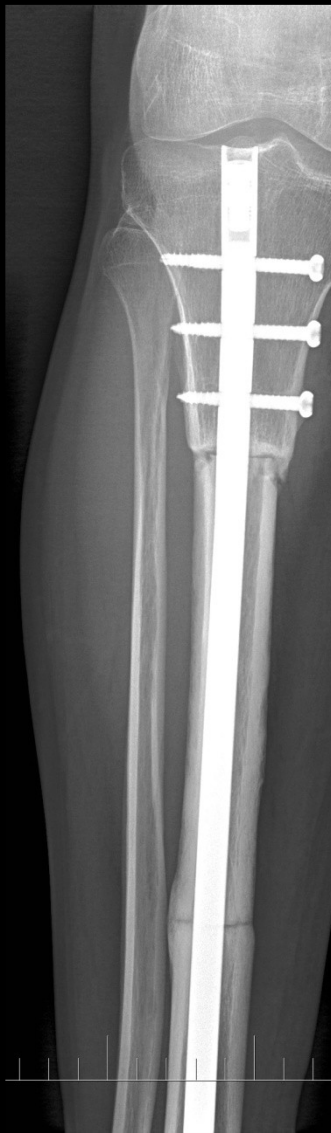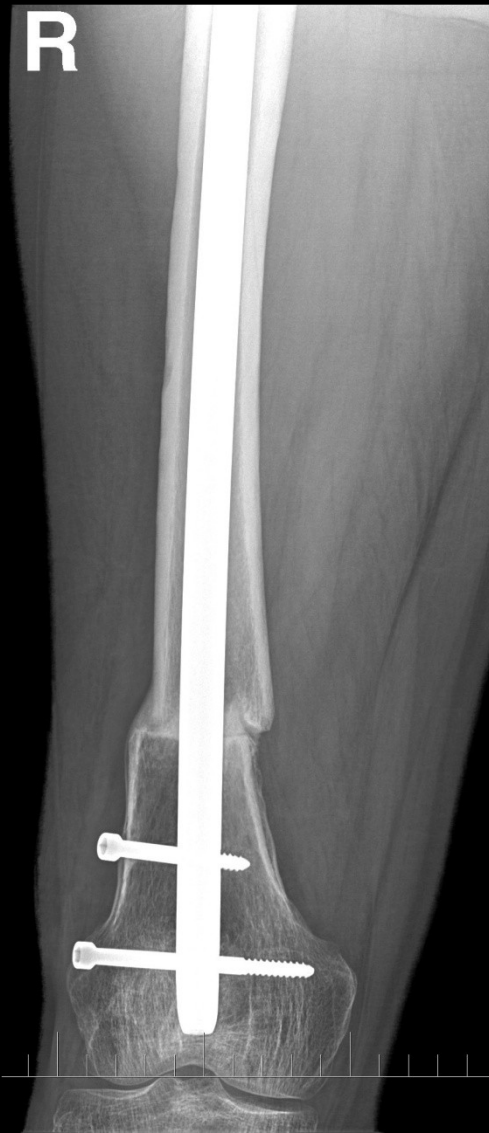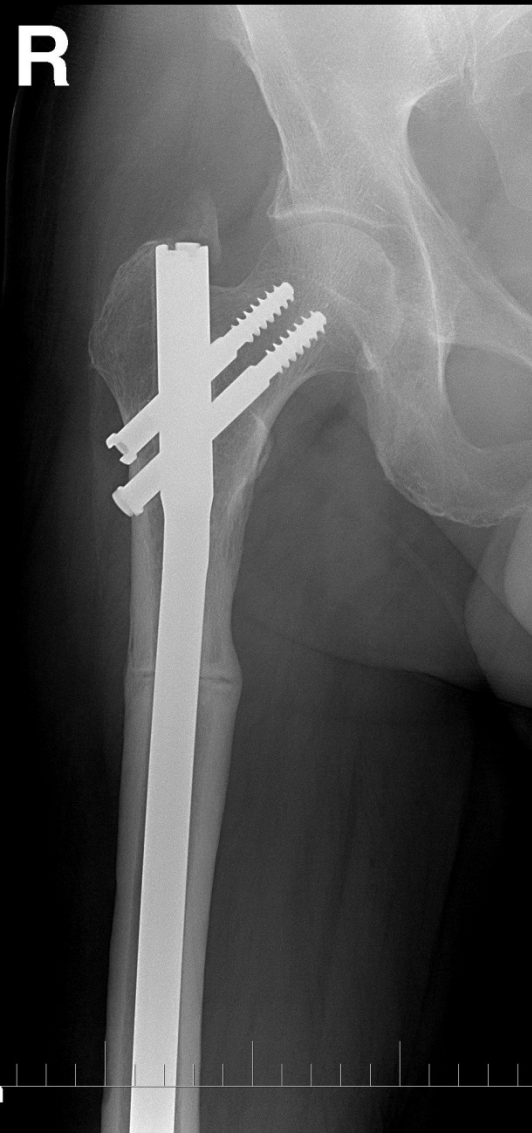
# Tumor of the scapula

Removal, replacement of the scapula + total shoulder arthroplasty

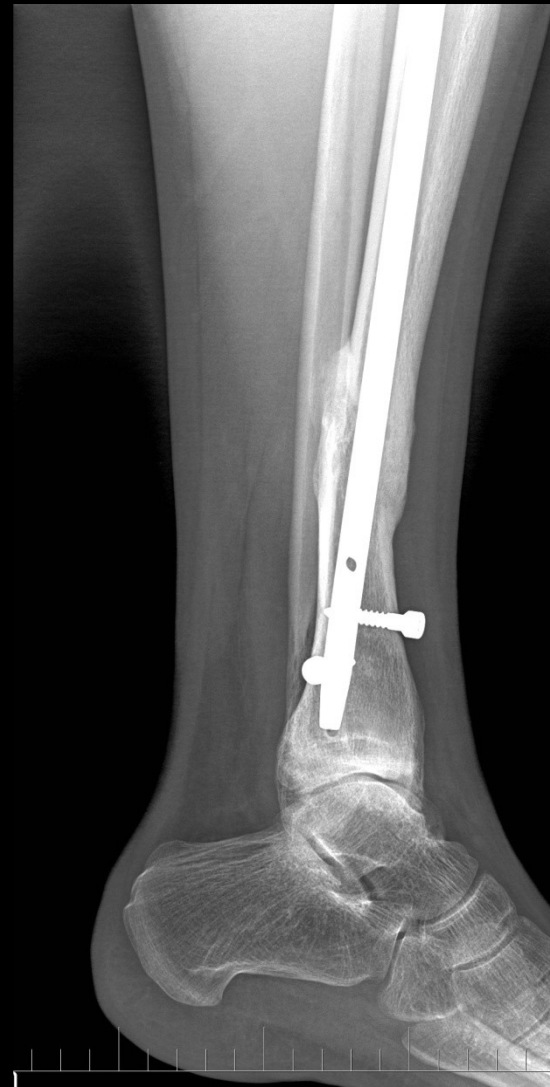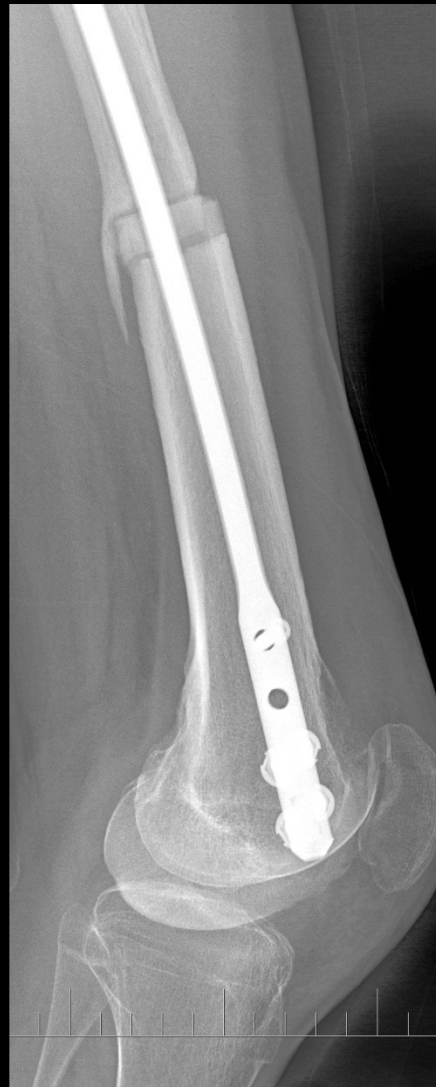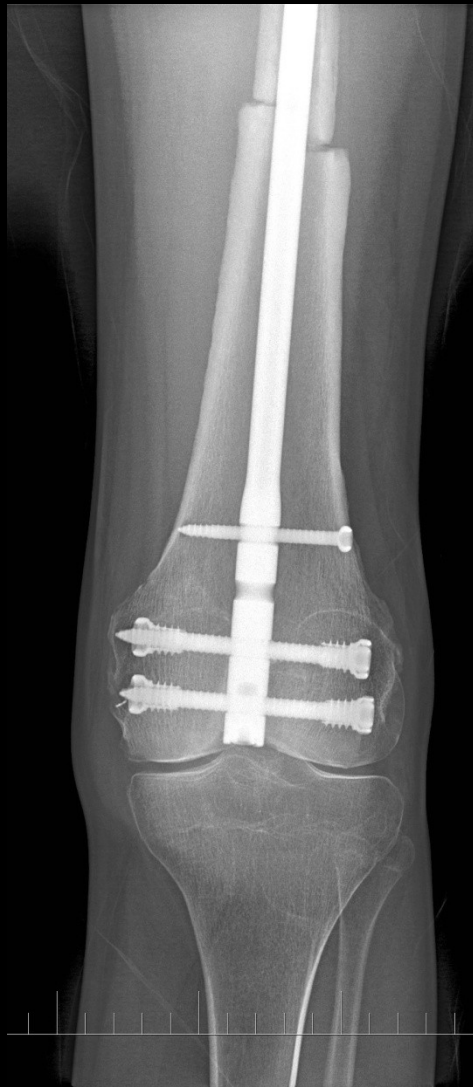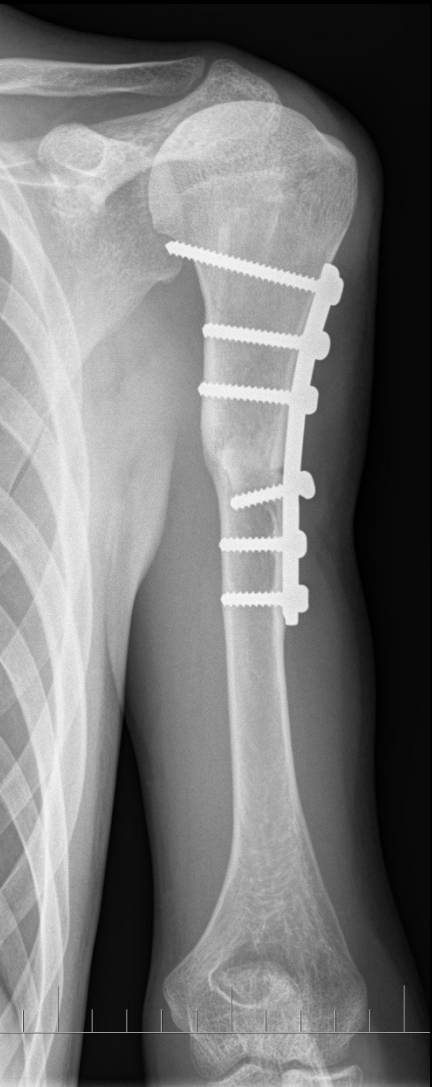




# Intercalary bone graft

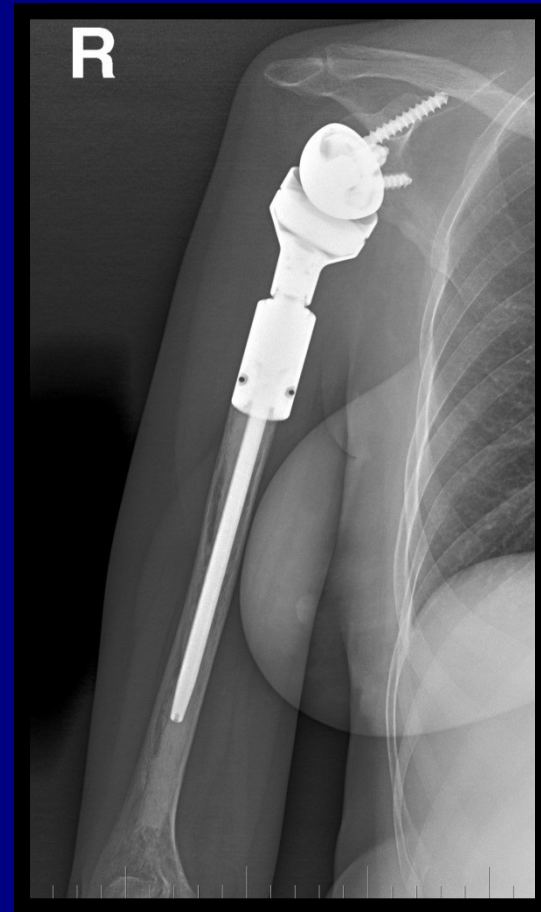
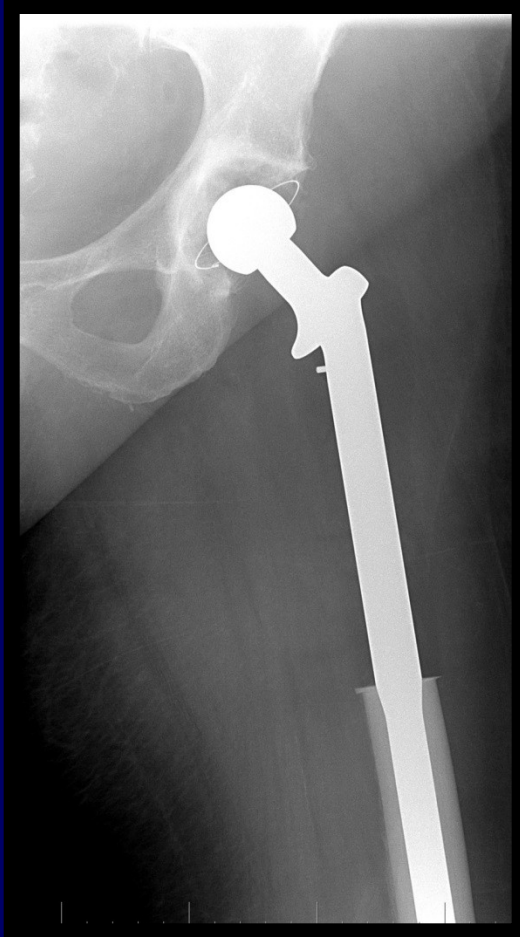
# Osteochondral grafts

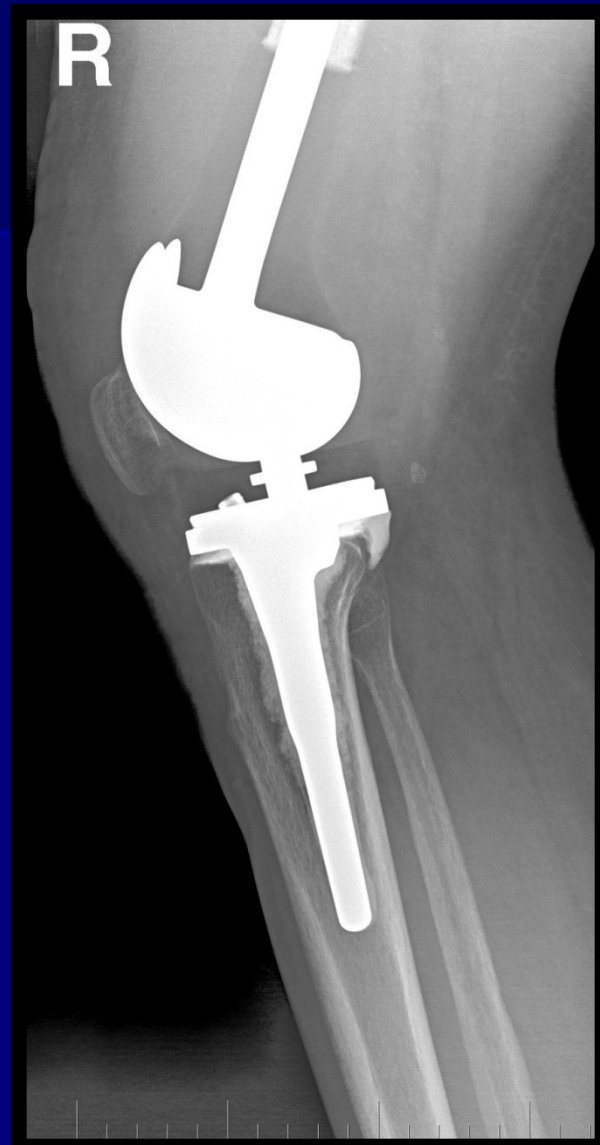
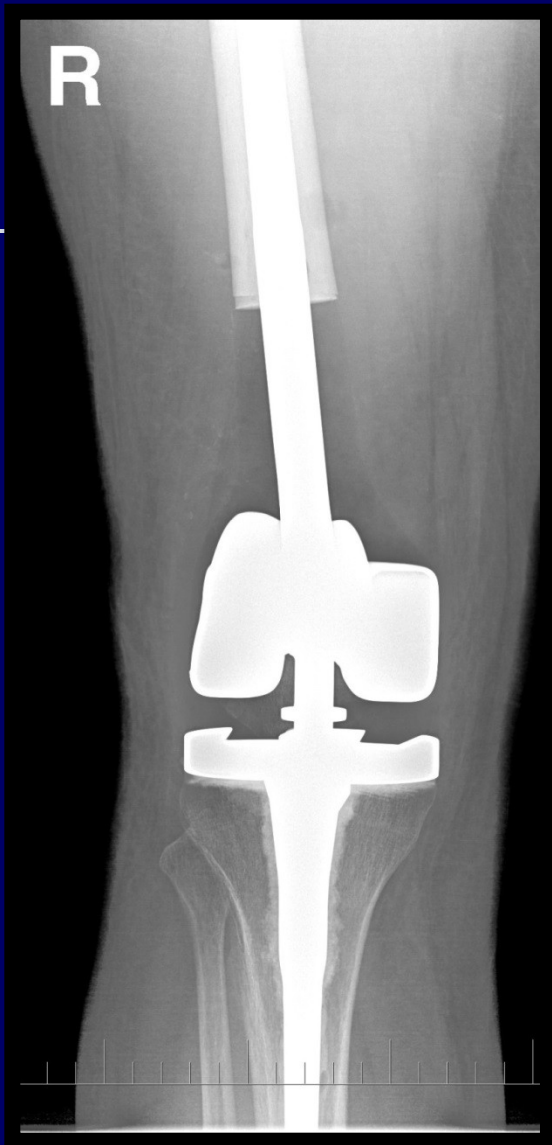
# Tumor endoprosthesis

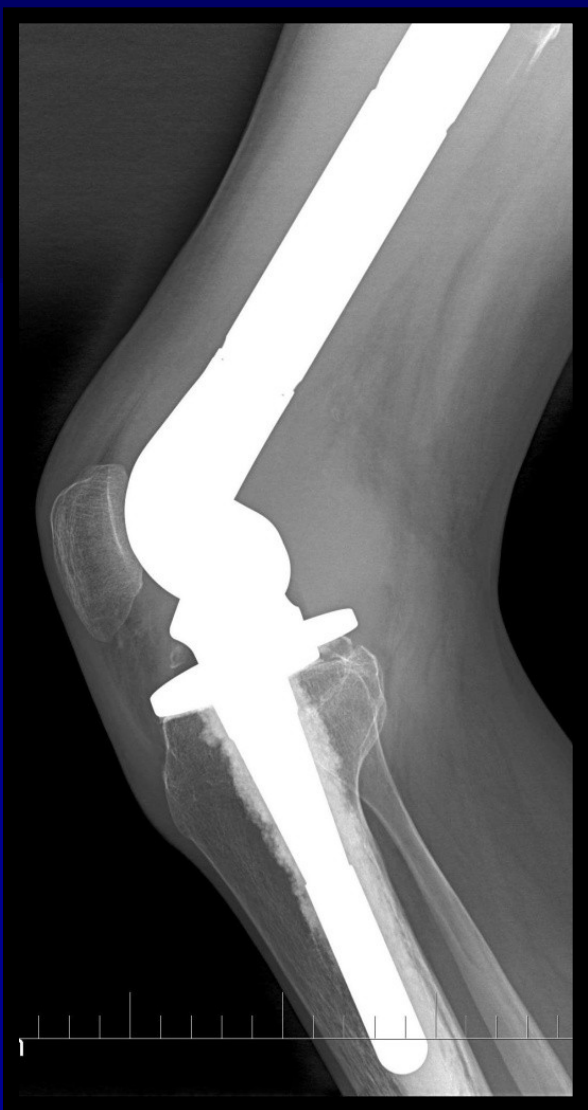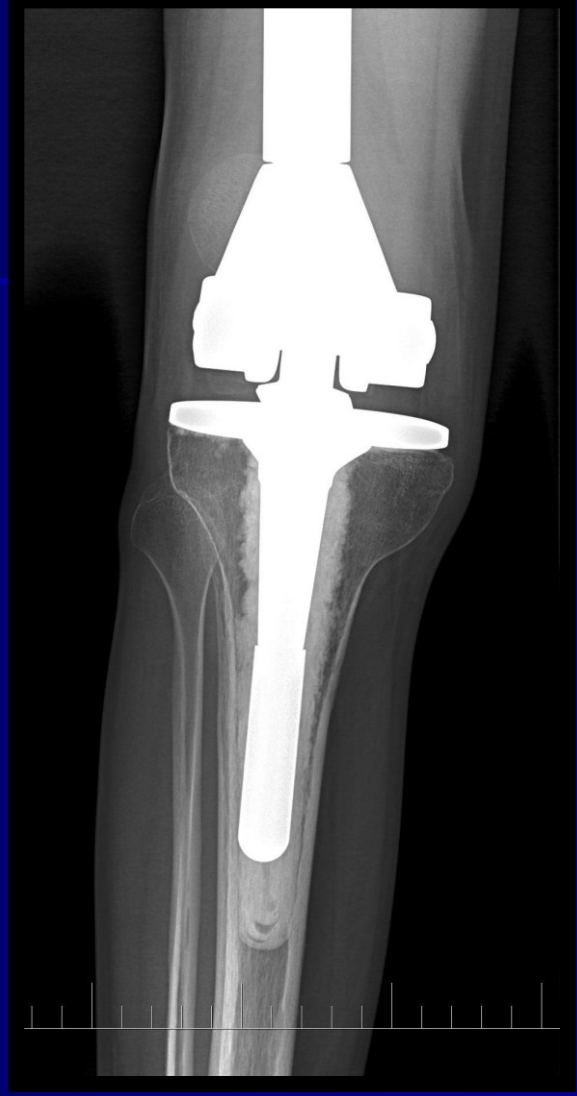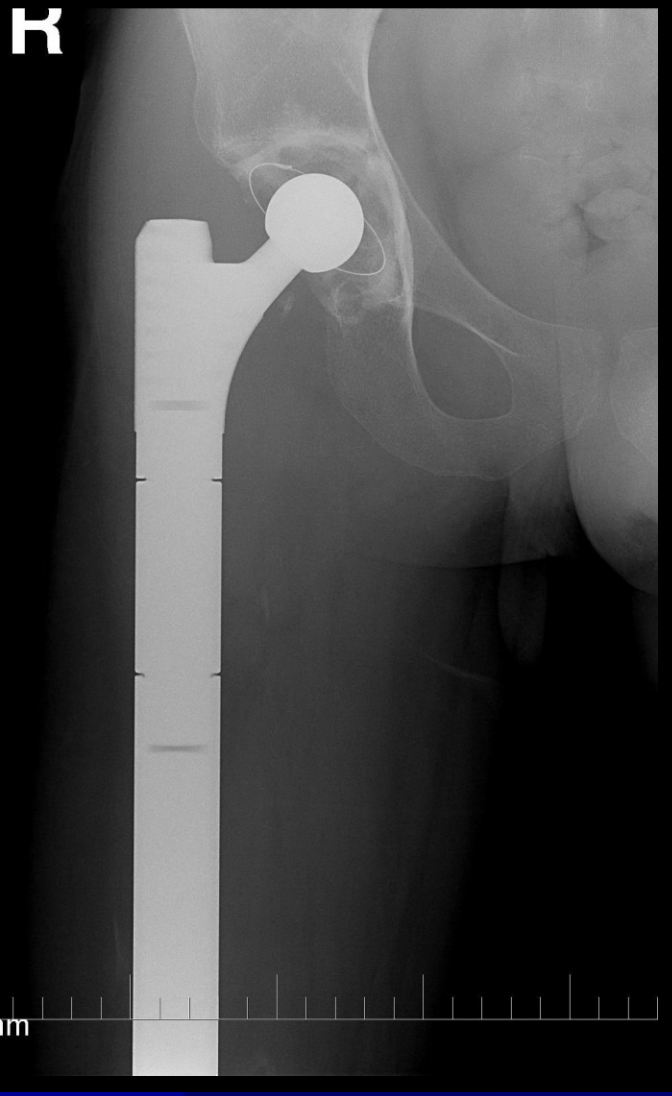- Resection and joint replacement







R



# Composite endoprosthesis

