

# Restorative dentistry I. 3rd lecture

## Dental caries in posterior teeth

M U N I  
M E D

# Pit and fissure caries

Occlusal surfaces of premolars and molars  
Foramina coeca

# All pit and fissure restorations (fillings)

They are assigned in to three groups.

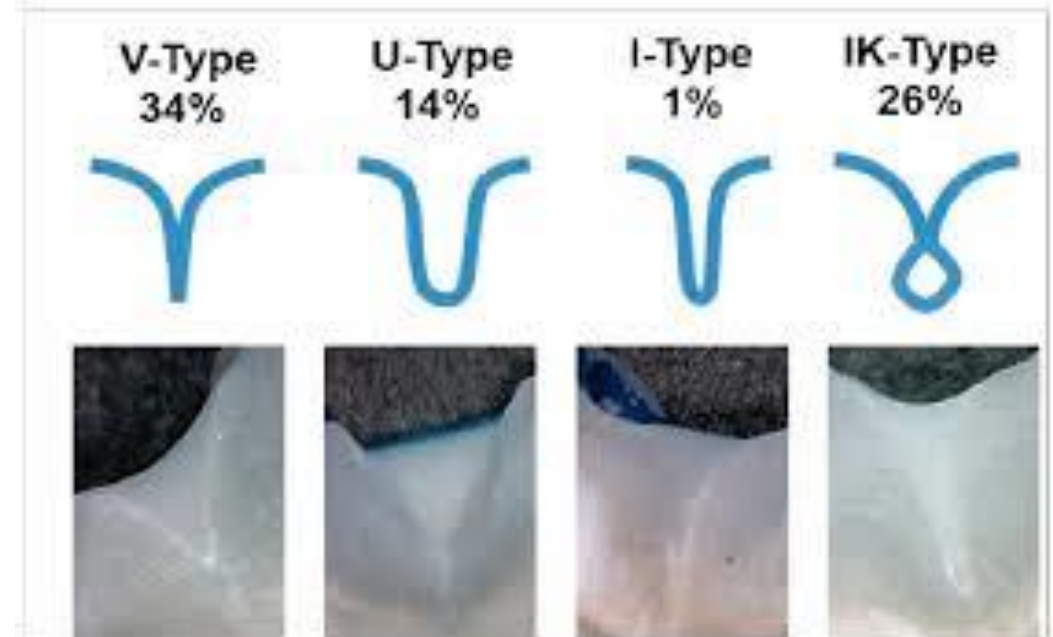
R. on occlusal surface of premolars and molars

R. in foramina coeca – usually on occlusal two thirds of the facial and lingual surfaces of molars.

R.on lingual surface of maxillary incisors.

# Classification of fissures

- 1. Shallow and wide
  - V or U
- 2. Deep and narrow
  - I or K



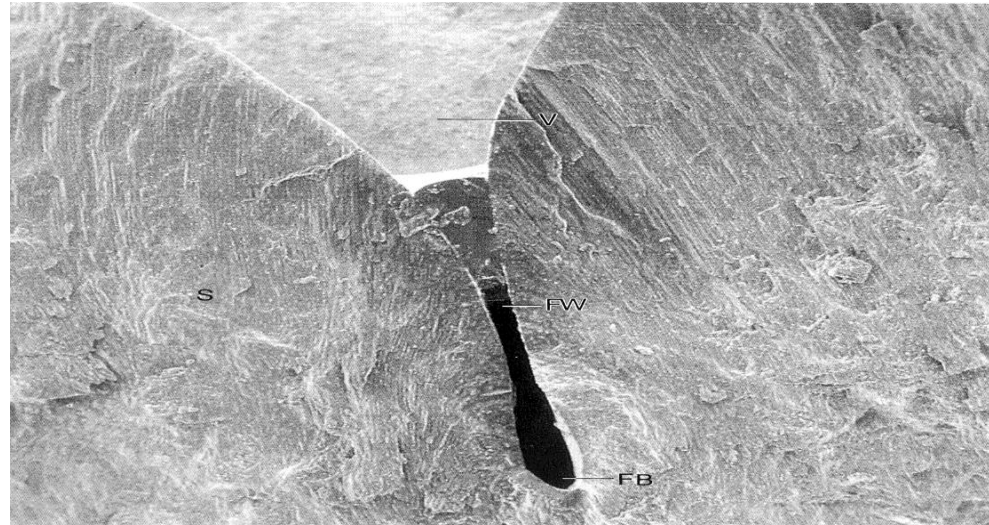

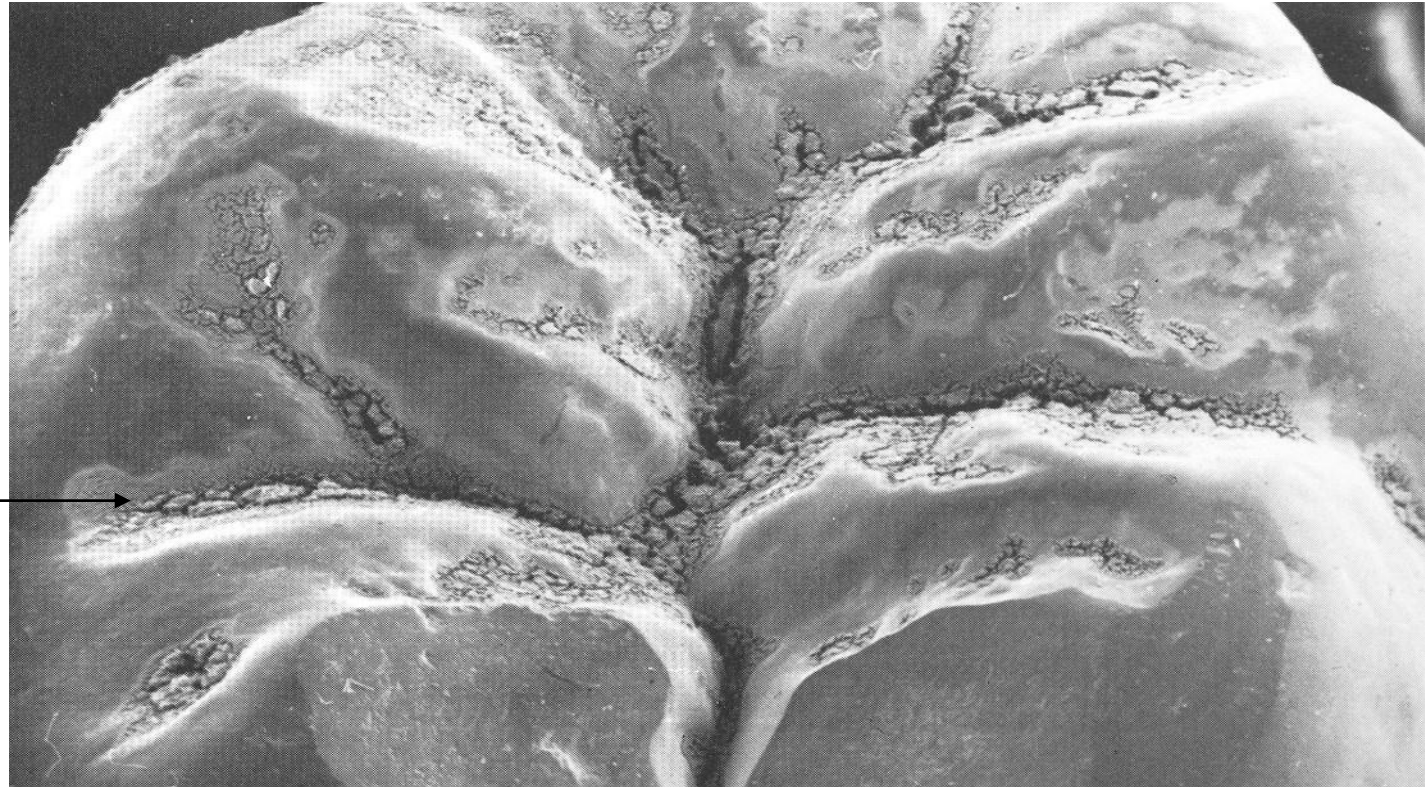


# Pits and fissures

- Caries danger areas – plaque accumulation due to morphology of fissures
- Structure of hydroxyapatite (carbonated HA) – enamel does not mature completely

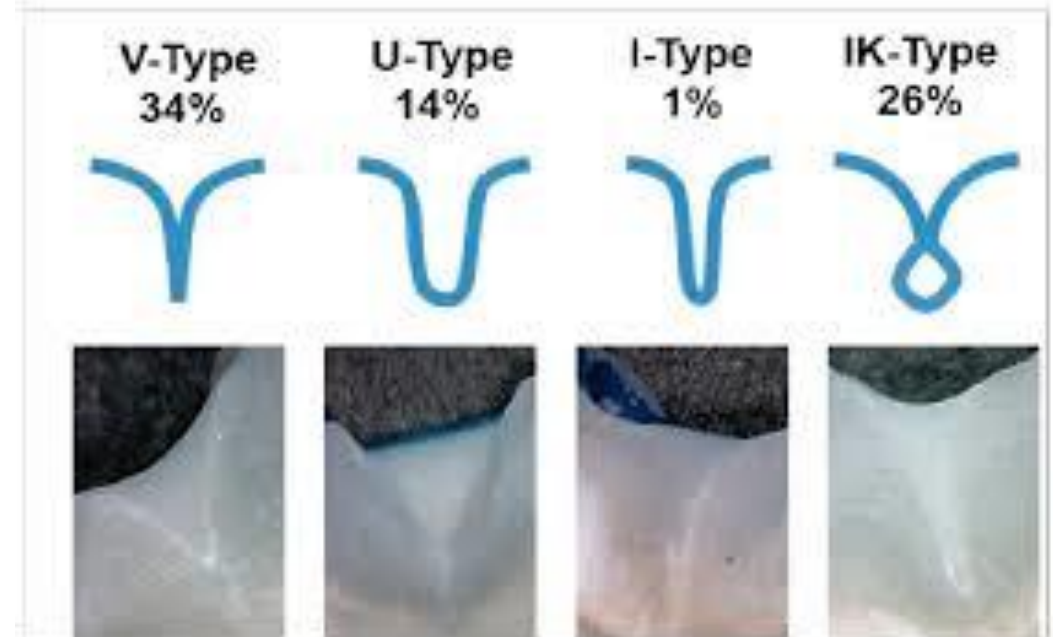
Morphology  
of fissures

Biofilm



# Classification of fissures

- 1. Shallow and wide
  - V or U
- 2. Deep and narrow
  - I or K



# Diagnosis

- Visual diagnosis – ICDAS, UNIWISS
- Infrared laser fluorescence (uncertain)
- Radiogram – if it spreads to dentin
- Diagnocam (uncertain)

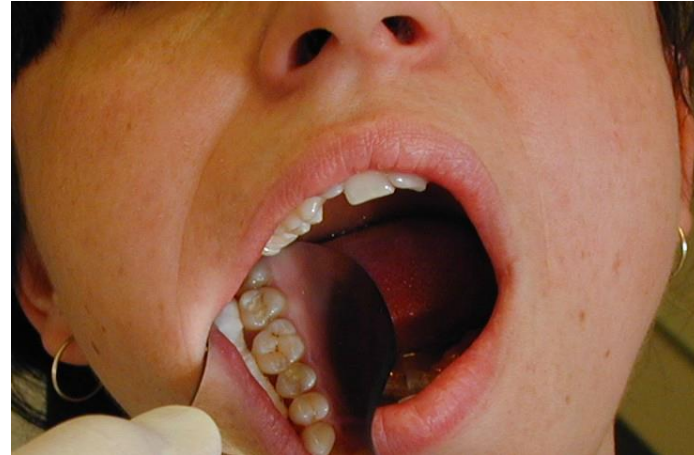# Pit and fissure caries

– Class I. acc. to Black

Caries danger area

Special morphology

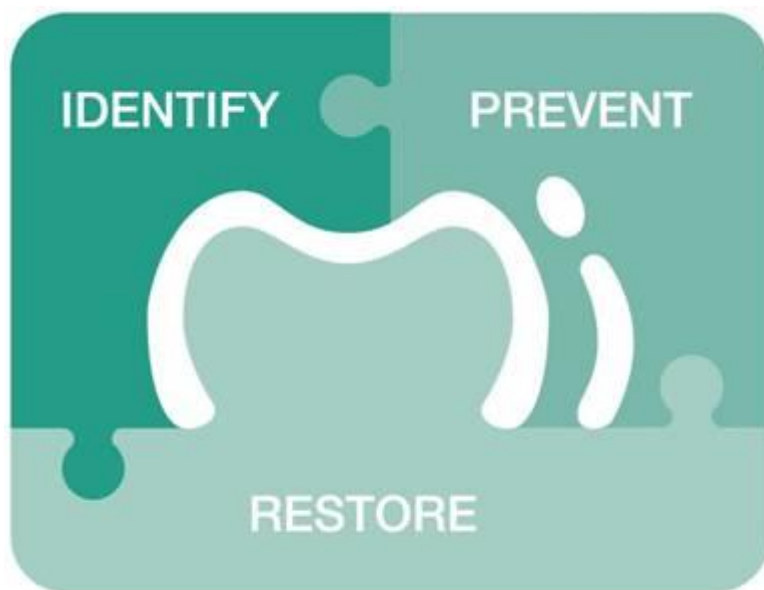Special structure of enamel



# Diagnosis

- Visual criteria

# ICDAS-INTERNATIONAL CARRIES DETECTION AND ASSESSMENT SYSTEM

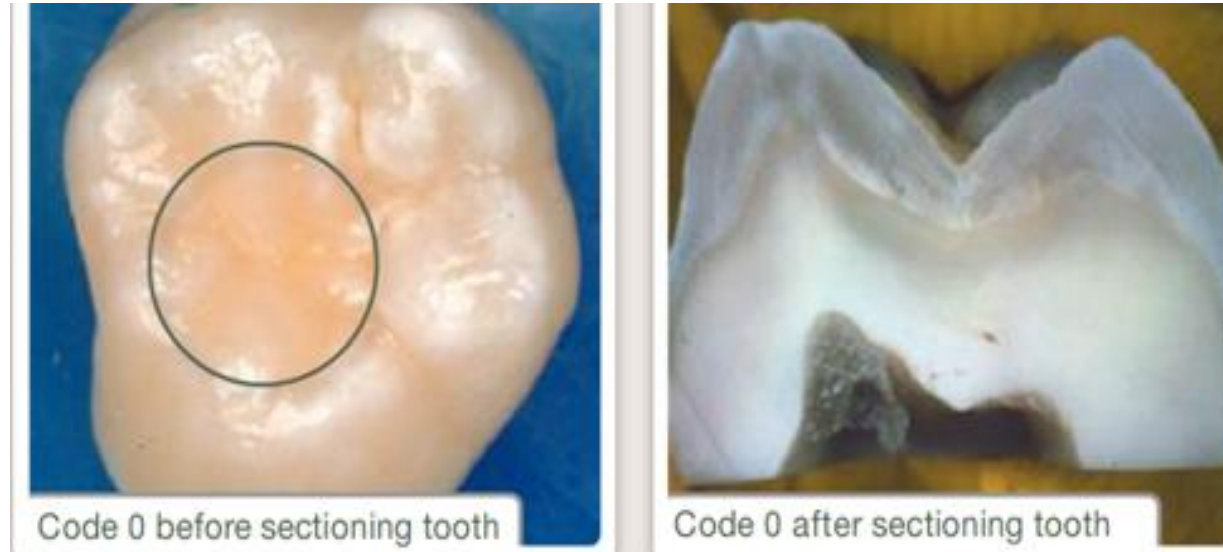

- **ICDAS**(2002)–6 code, later **ICDAS –II** –4code
- □ Caries lesions in pit and fissures, smooth surfaces, roots and next to fillings –**CARS** (Caries Associated with Restoration and Sealants)
- Blunt probe
- Clean and dry surfaces, time of observation 5 s
- <http://www.icdas.org/courses/english/index.html>



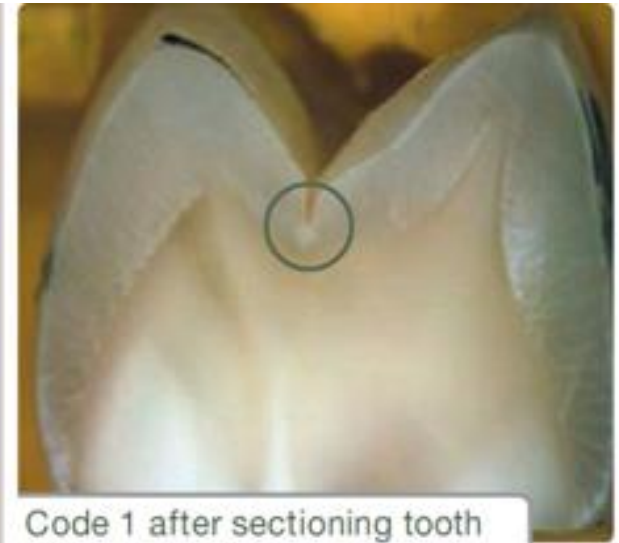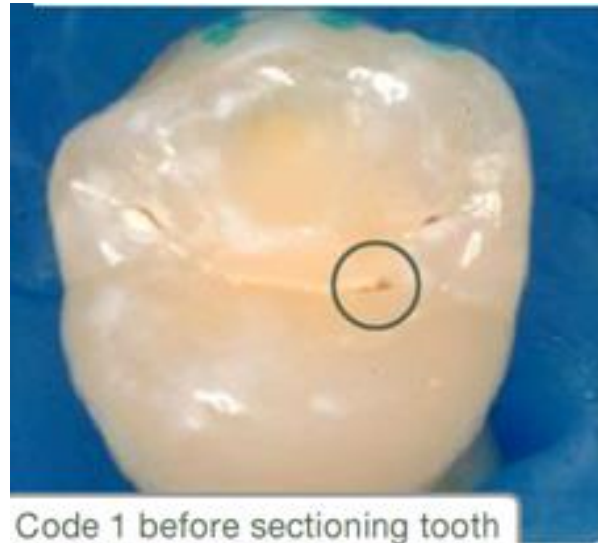# ICDAS – criteria

– 0 no changes observed



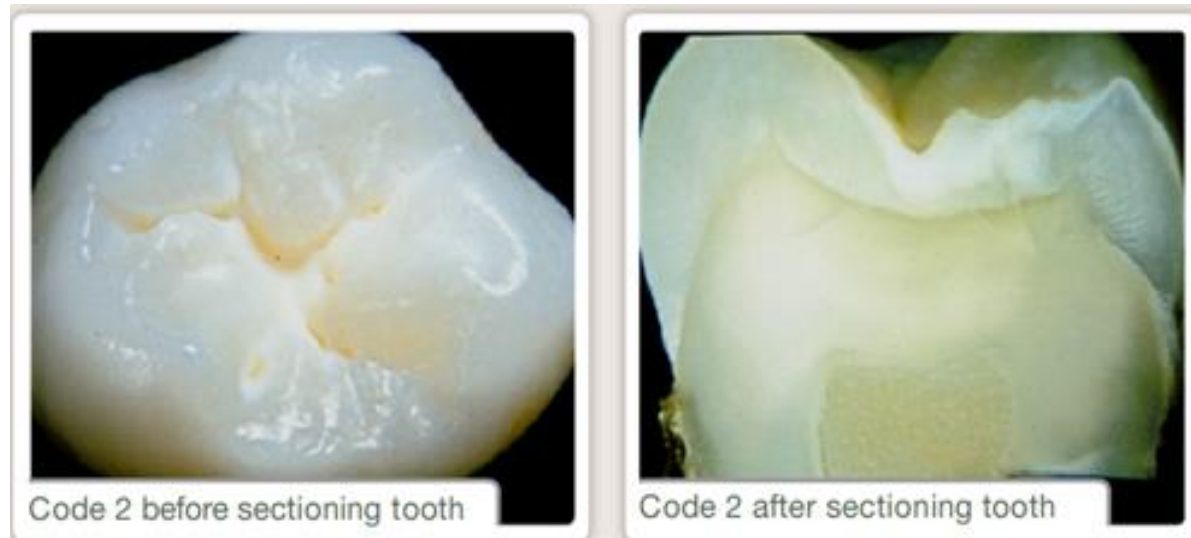
# ICDAS - criteria

- 1.- first visual changes observed on dry surface only (opaque, white, brown)



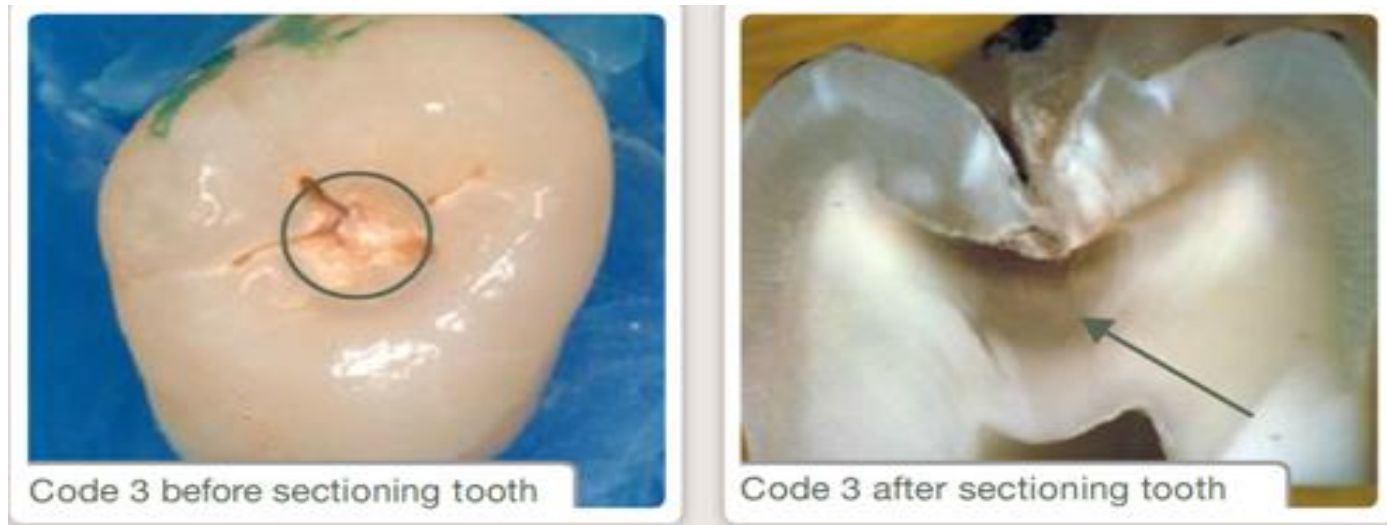# ICDAS - criteria

- **2.** – first visual changes on wet surfaces



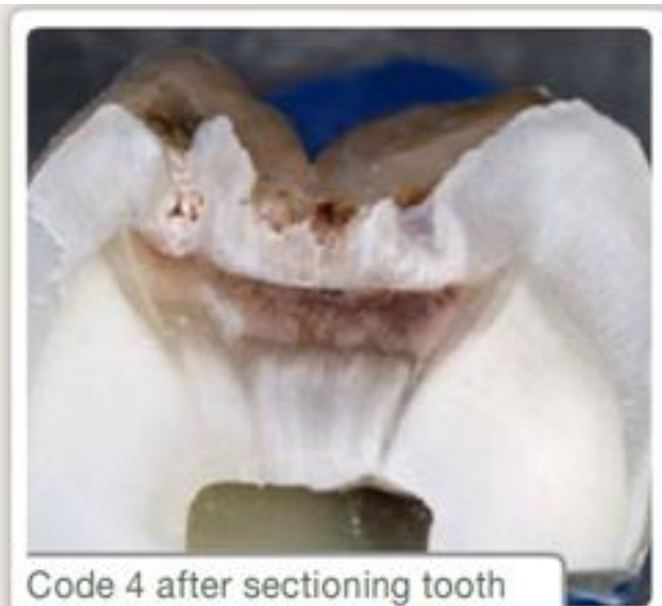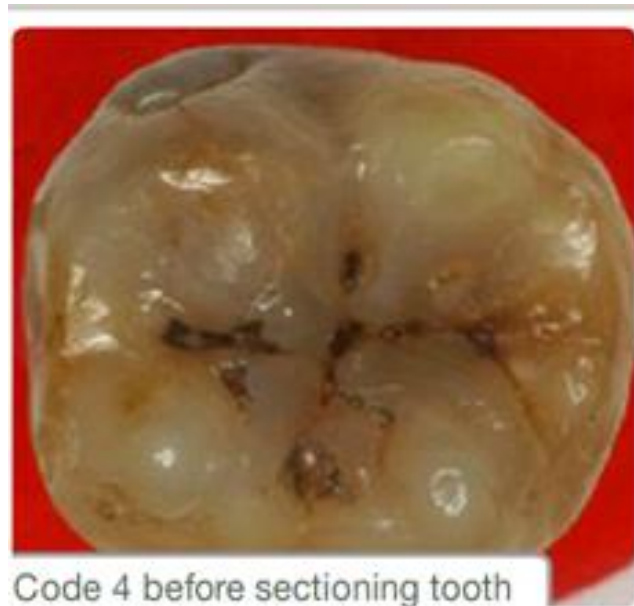# ICDAS - criteria

- 3 – enamel is still present, zone of decalcification is out of fissure, dentin is affected



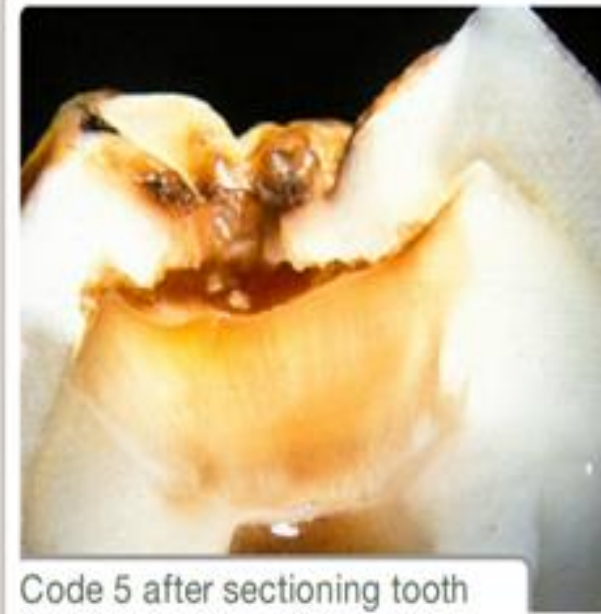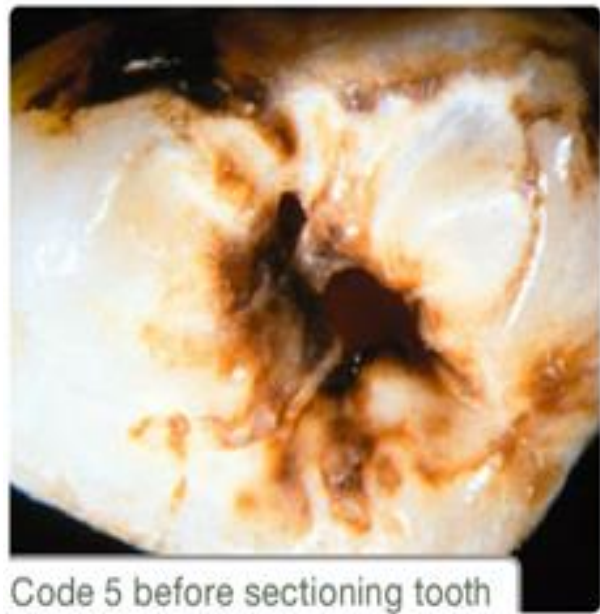
# ICDAS - criteria

- 4 – dark colour around the fissure (grey, blue, brown), enamel can be broken



# ICDAS - criteria

























## – 5 – cavitated lesion



# Clinical picture

- Dark colour
- White colour (undermined enamel) around cavitation



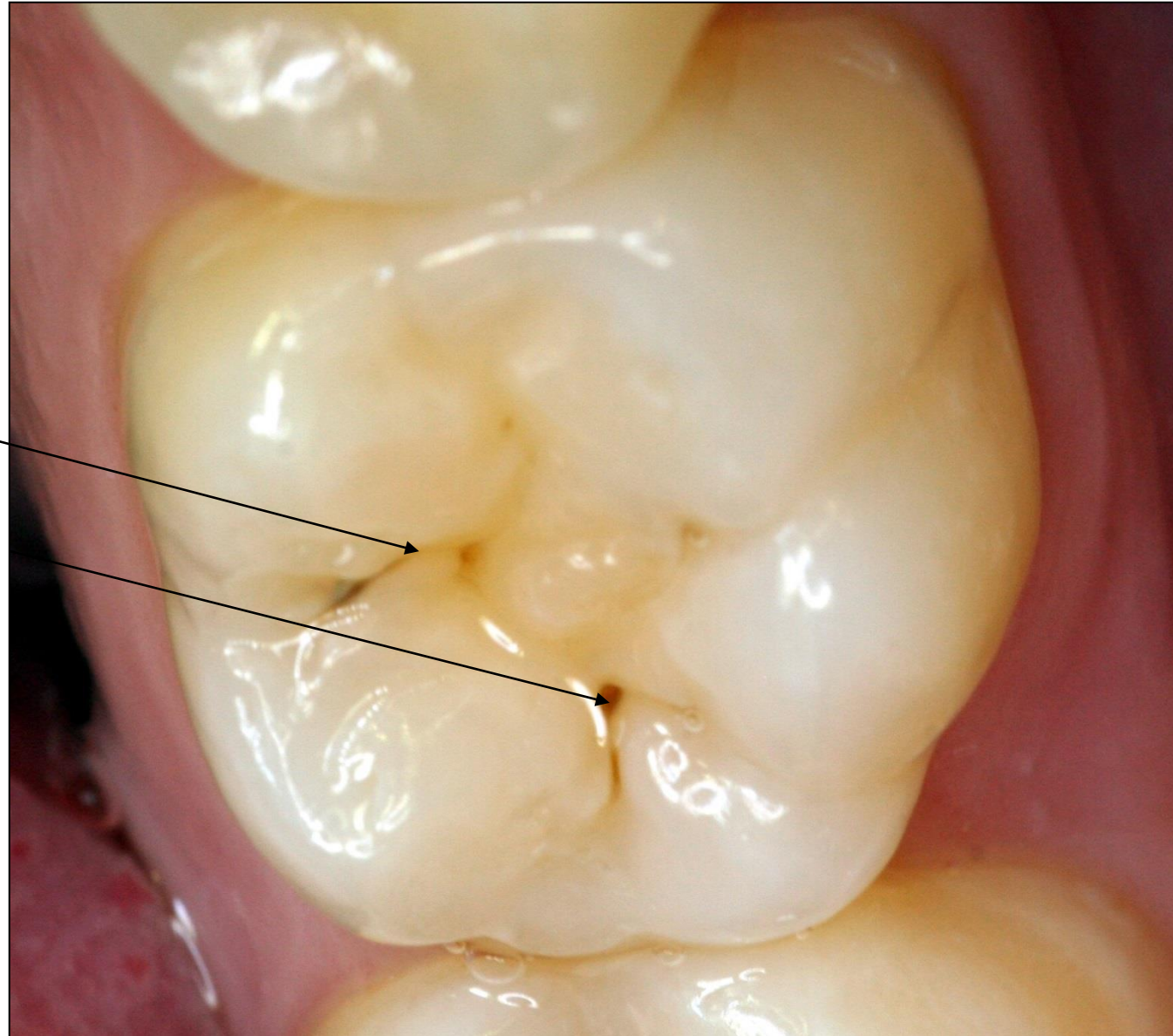
Universal Visual Scoring System for pits and fissures (UniViSS occlusal)						
Second step: Discoloration Assessment	First step: Lesion Detection & Severity Assessment					
	First visible signs of a caries lesion	Established caries lesion	Microcavity and/or localised enamel breakdown	Dentin exposure	Large cavity	Pulp exposure
	Score F	Score E	Score M	Score D	Score L	Score P
Sound surface (Score 0)	No cavitations or discolorations are detectable.					
White (Score 1)						
White-brown (Score 2)						
(Dark) Brown (Score 3)						
Greyish translucency (Score 4)						



Caries

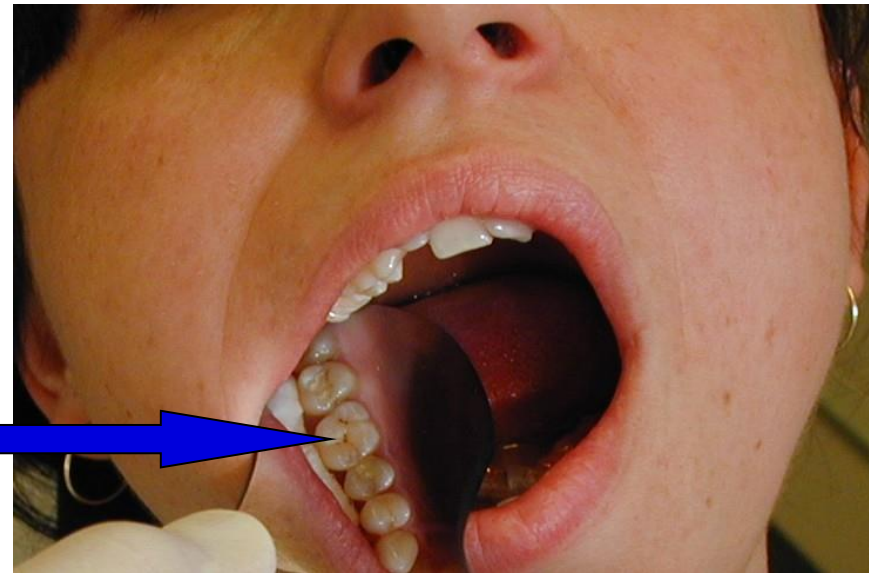ICDAS 1

ICDAS 2



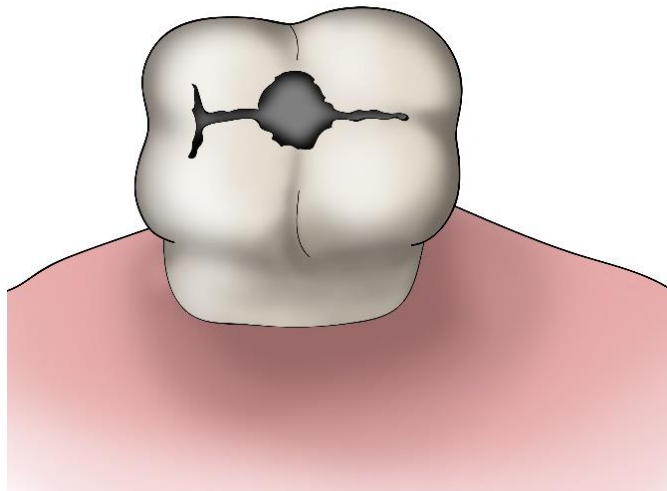
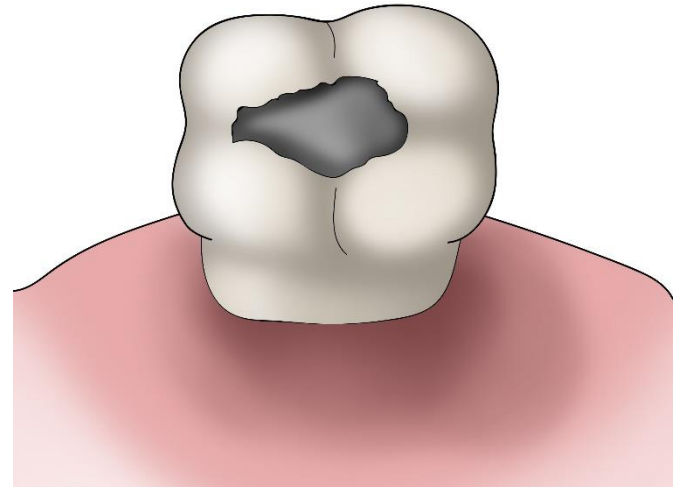
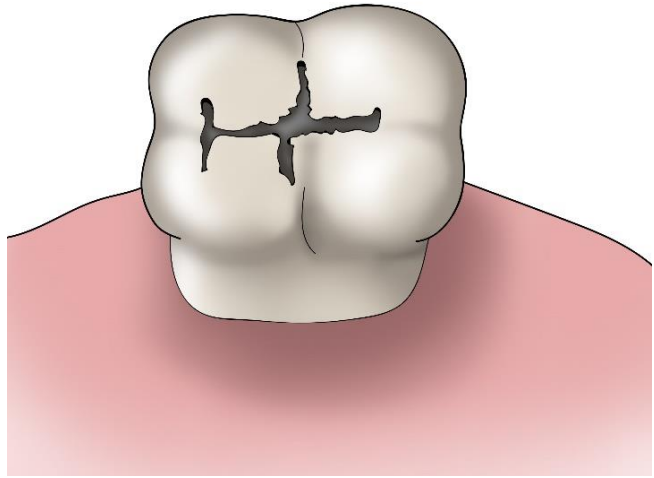


## Pit and fissure caries



# Occlusal caries

- ICDAS 0 – 1 : observation
- ICDAS 2: observation or preventive filling
- ICDAS 3 – 4: filling therapy



# Indications of dental materials – occlusal caries

- Amalgam
- Composite
- Glassionomer



# Consideration

- Caries lesion: size and location
- Occlusal stress
- Level of oral hygiene
- Isolation of operating field
- Patient's compliance

# Amalgam ?

**Pertinent material qualities and properties**

**Strength**

**Longevity**

**Ease of use**

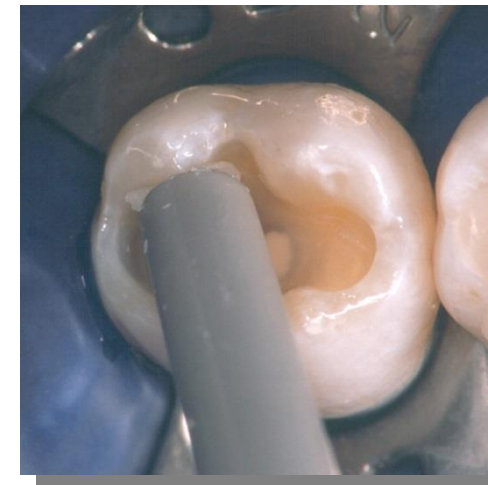
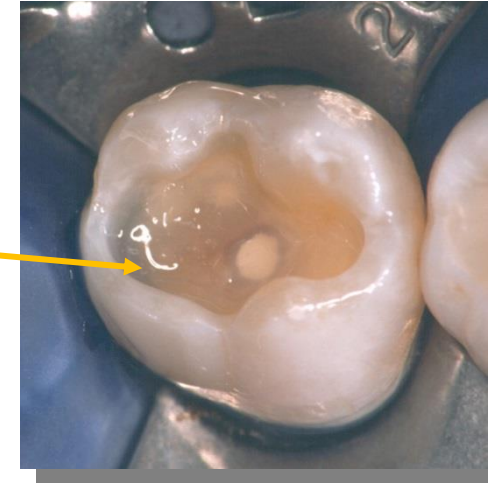
**Clinically proven success**

**BUT!**



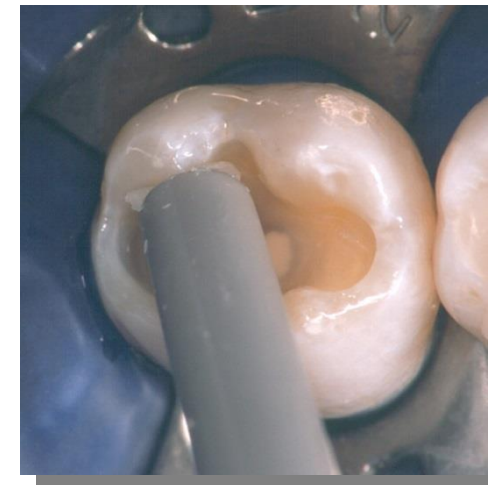
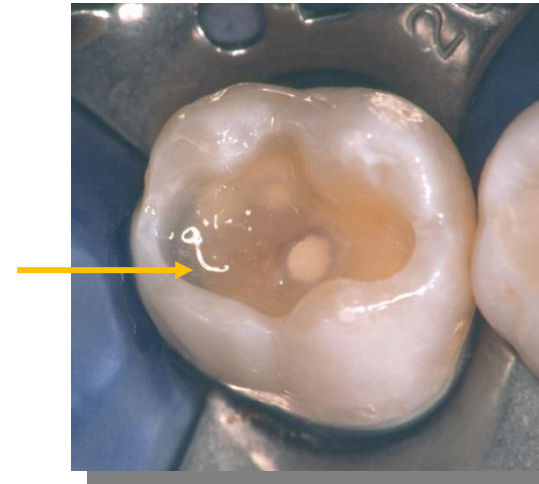
# Amalgam - disadvantages

- Infractures of marginal ridge
- Corrosion
- Bad aesthetics



# Amalgam - advantages

- Easy to place
- Good mechanical properties esp.
- Price



# Indications

- Moderate to large restorations
- If there is heavy occlusal loading (alternative onlay)
- Oral hygiene is not optimal (alternative dense glassionomer as middle term temporary)
- When the proper isolation is not possible
- Price

# Contraindications

- Aesthetically prominent areas of posterior teeth
- Small - moderate classes I. that can be well isolated

# GIC only?

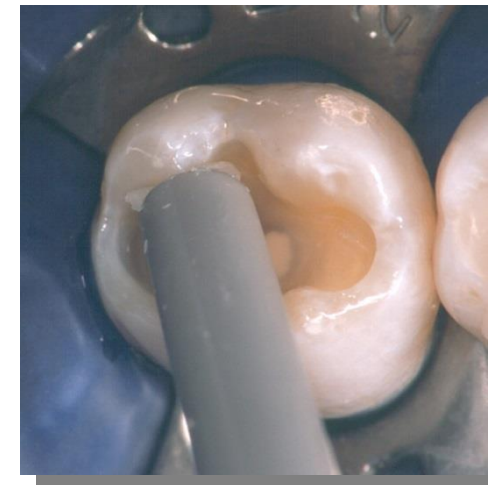
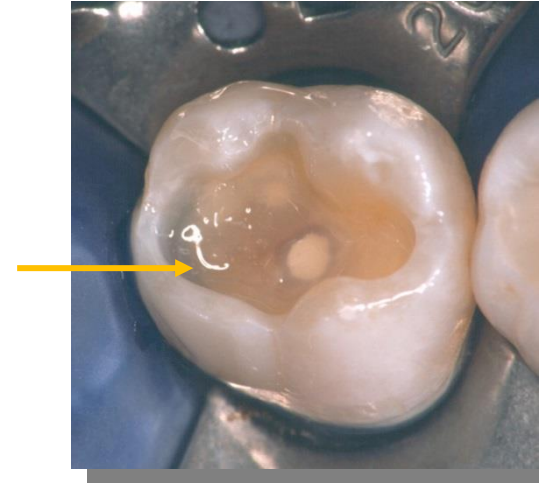
- Primary dentition
- Resin modifies GIC preferable

# Composite - benefits

- Non metallic material
- Adhesion – no gap
- Less amount of hard dental tissues that is necessary to remove
- Good resistency of the treated tooth
- Aesthetics

## Composite - disadvantages

- Good isolation is necessary
- Technique sensitive treatment
- Price



# Indications

- Aesthetically prominent areas of posterior teeth
- Small - moderate classes I. that can be well isolated
- Good level of oral hygiene is necessary




# Contraindications

- Moderate to large restorations
- Restorations that have heavy occlusal contacts
- Restorations that cannot be well isolated
- Restorations that extend onto the root surface
- Abutment teeth for removable partial dentures

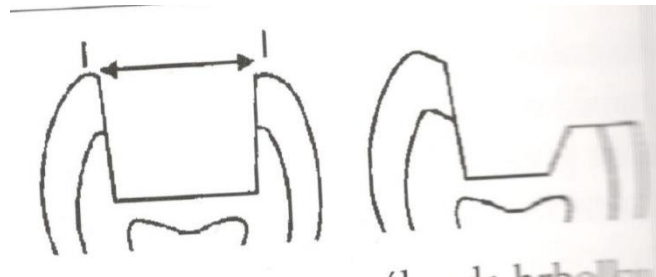
# Fillings – small to medium lesions

- Composite – small to medium lesion (if indication)
- Amalgam is a material of second choice
- Metal or adhesive inlay is not be used in medium lesions



# Fillings – medium to large defects

- Amalgam filling with replacement of cusps
- Adhesive inlay, metal inlay or onlay
- Composit is not indicated (contraindicated)



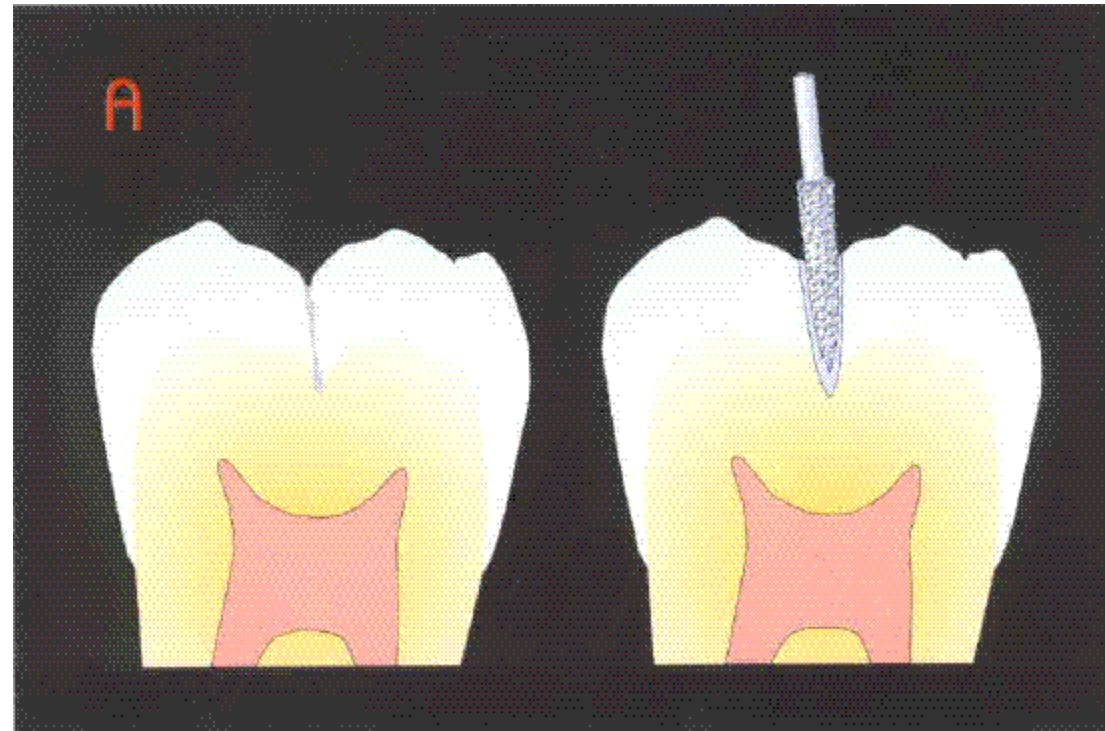
# Pit and fissure sealing indications

- Teeth soon after eruption with deep fissures
- Disabled patients
- Adults - hyposalivation

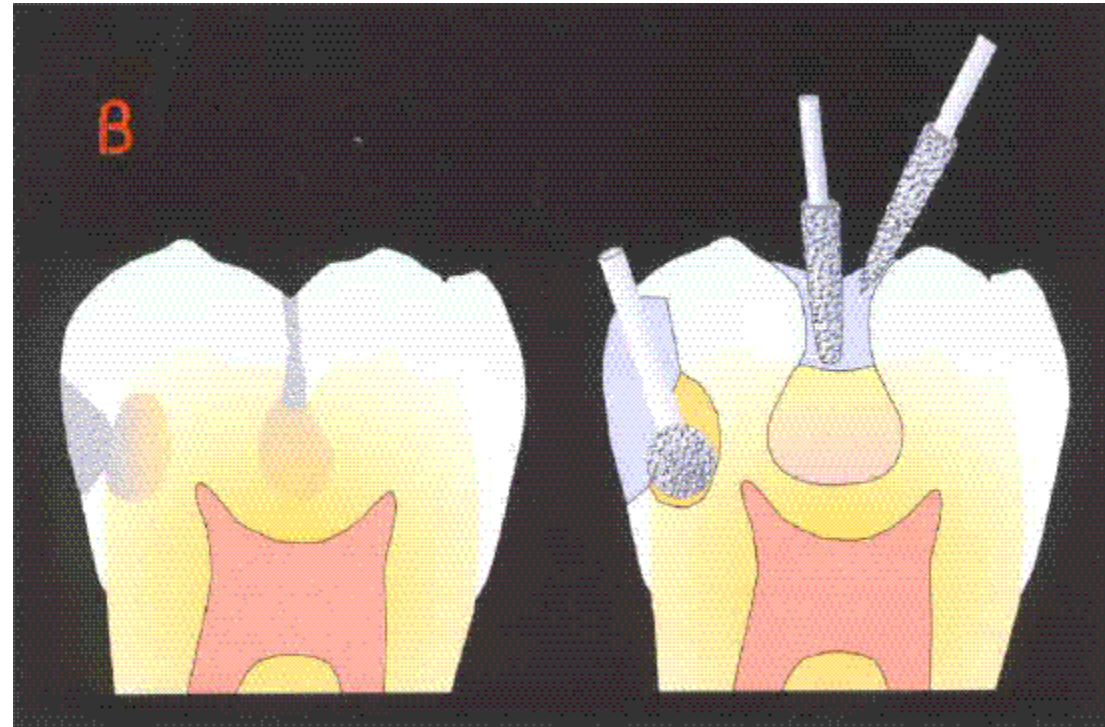
# Pit and fissure sealing - contraindications

- Shallow fissures, good oral hygiene DMF = 0
- High caries risk (DMF high) – risk of proximal caries
- Proximal caries, occlusal caries (ICDS – 3 and more)

# Adhesive preparation in a fissure – sealant filling



# Adhesive preparation – caries lesion in dentin



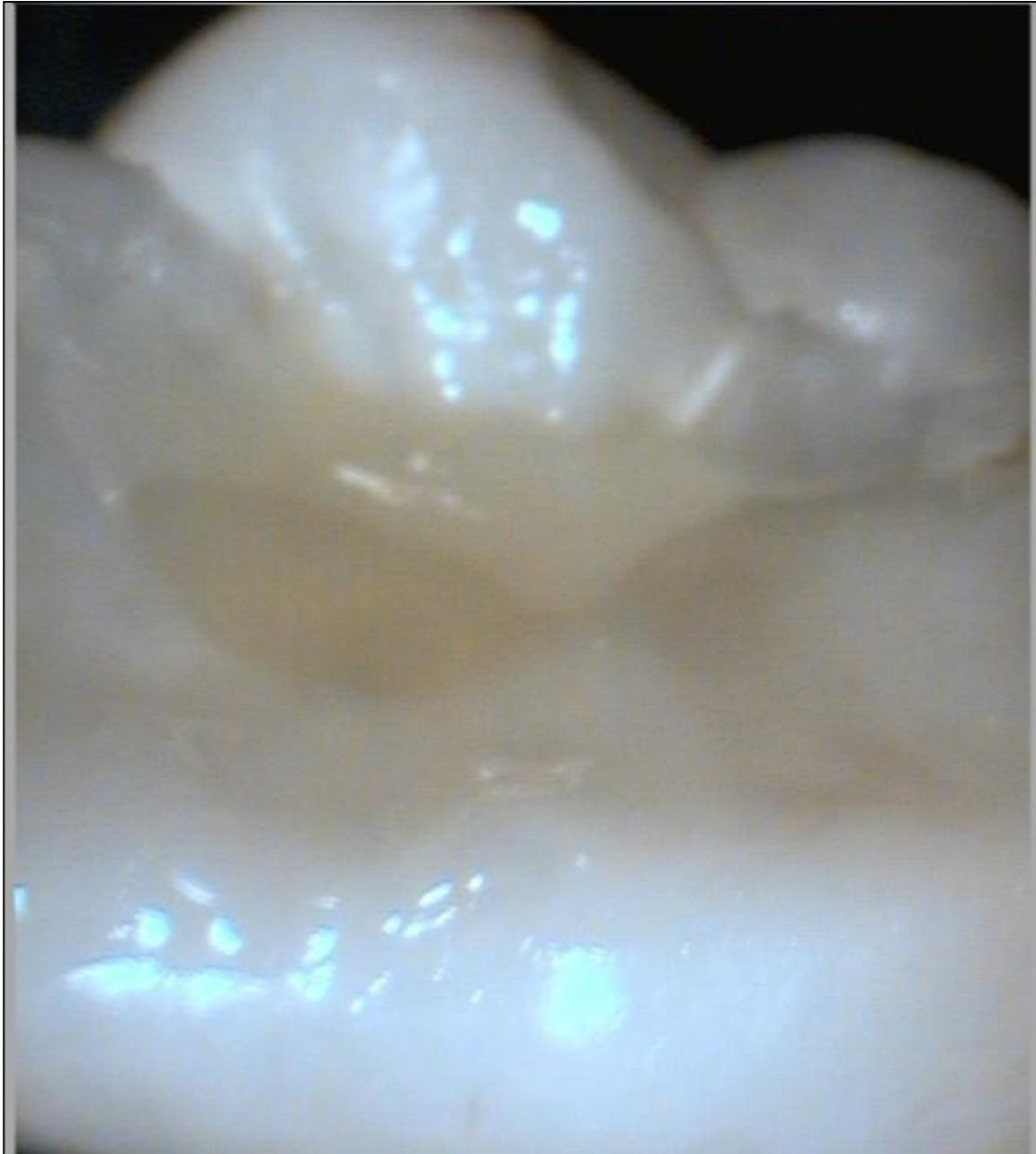
# Preventive filling - indications

- Primary molars
- Premolars
- Permanent molars (ICDAS 3 and more)



# Preventive filling - contraindications

- High caries risk, DMF > 5
- Large dental caries (more than 1/3 intercuspidal distance, underminig chronic caries
- Proximal surfaces must be intact or max D1
- Proximal cavitated lesions



Preventive composite filling

Preventive glassionomer filling

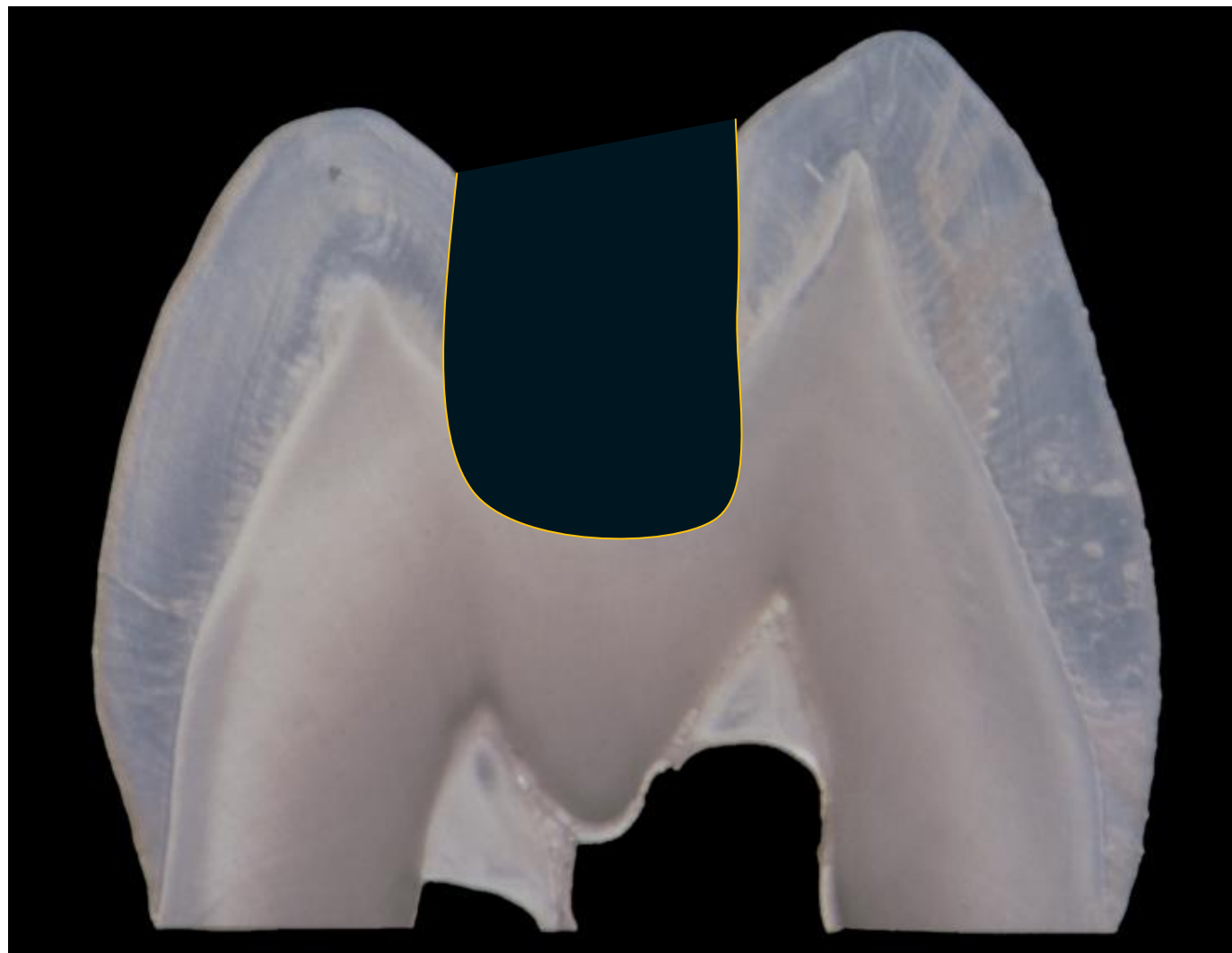
Sealant filling

Preventive filling –  
GIC + composite

# Composit material

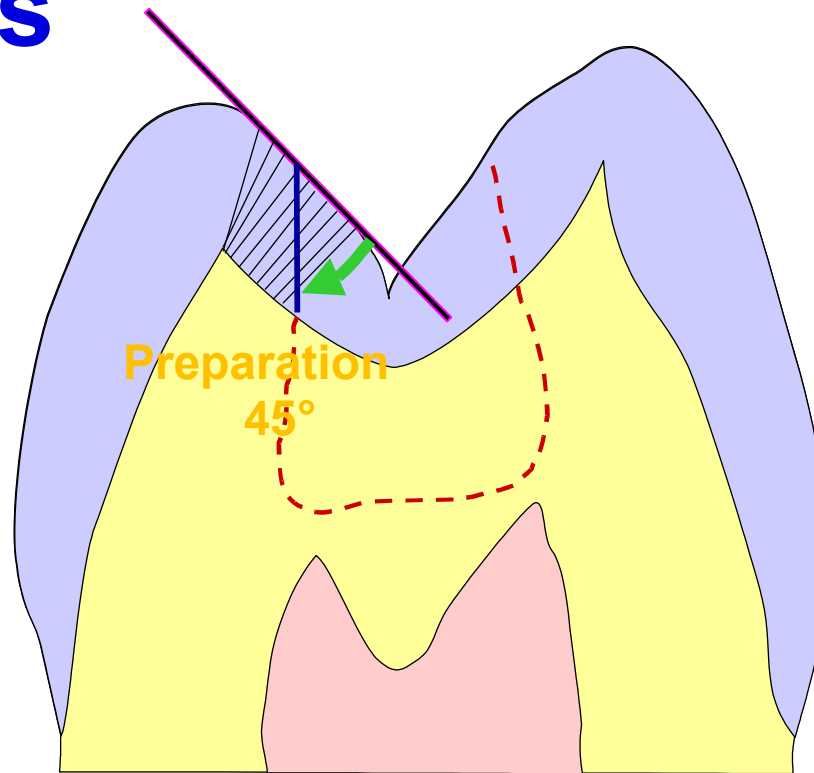
- Small cavities – preparation is limited on caries lesion only, small instruments no extention, fissure sealing around and sealant also covers the filling. This is preventive composite filling.
- Medium cavities – preparation is limited on caries lesion, GIC replaces lost entin, composite filling on the top.
- Larger cavities – preparation involved the fissures, box.

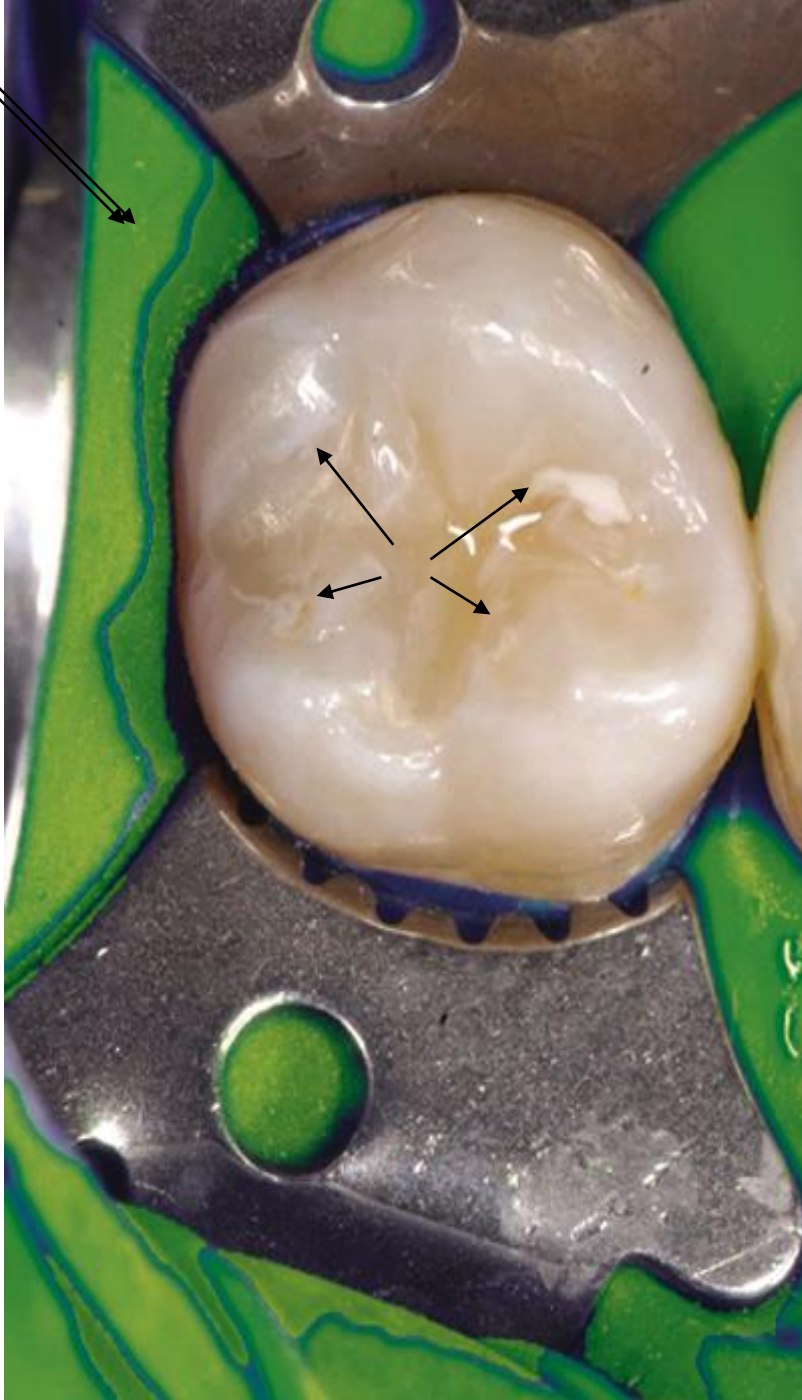
# Box (remember rounded edges)



# Preparation of enamel borders – no bevel

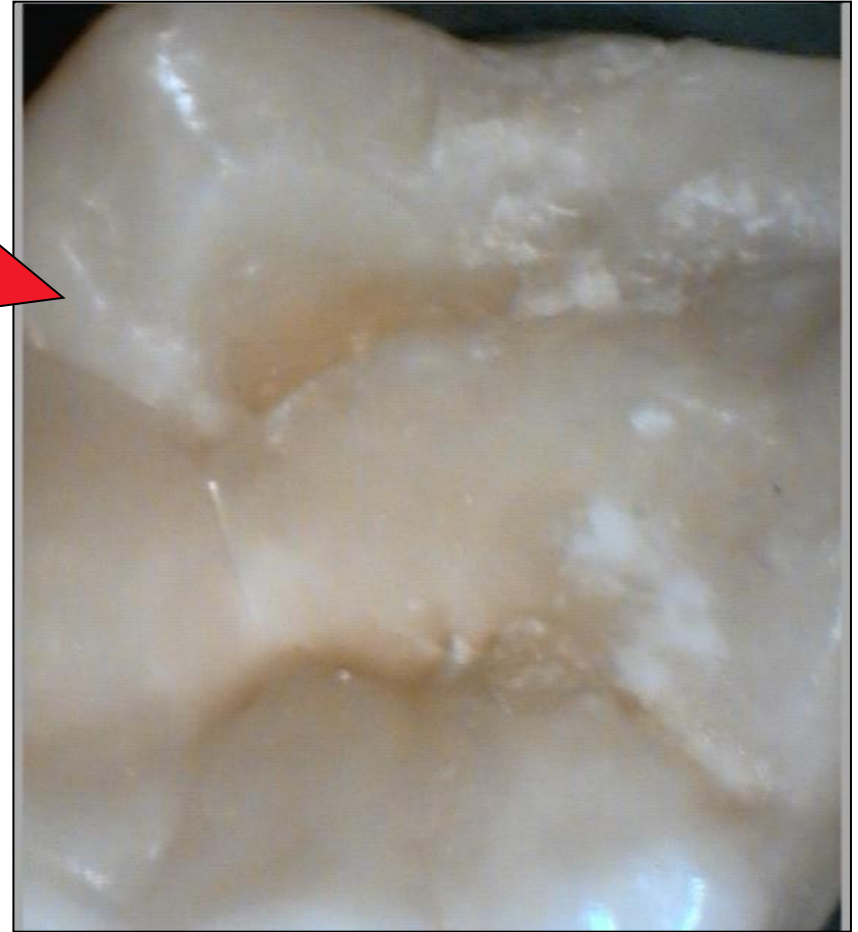
The beveling depends on the orientation of enamel rods



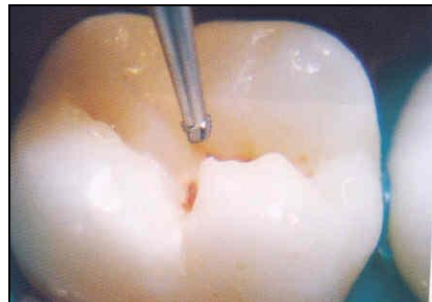
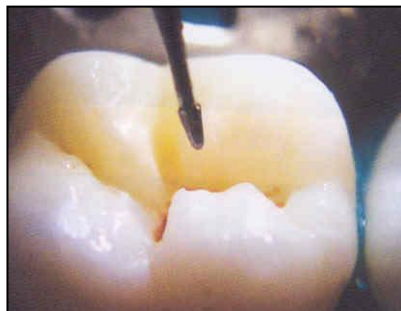
The composite material  
is built cusp by cusp

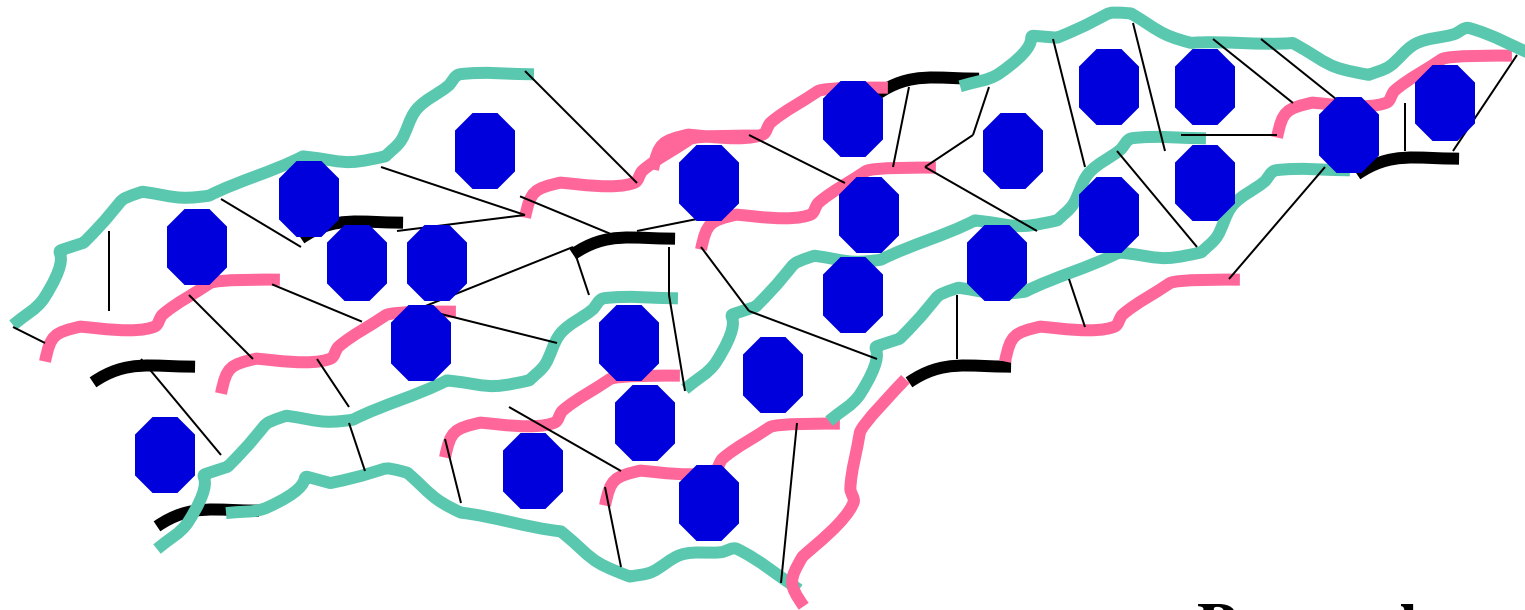
**Isolated cavities**



**Preparation of fissural complex**



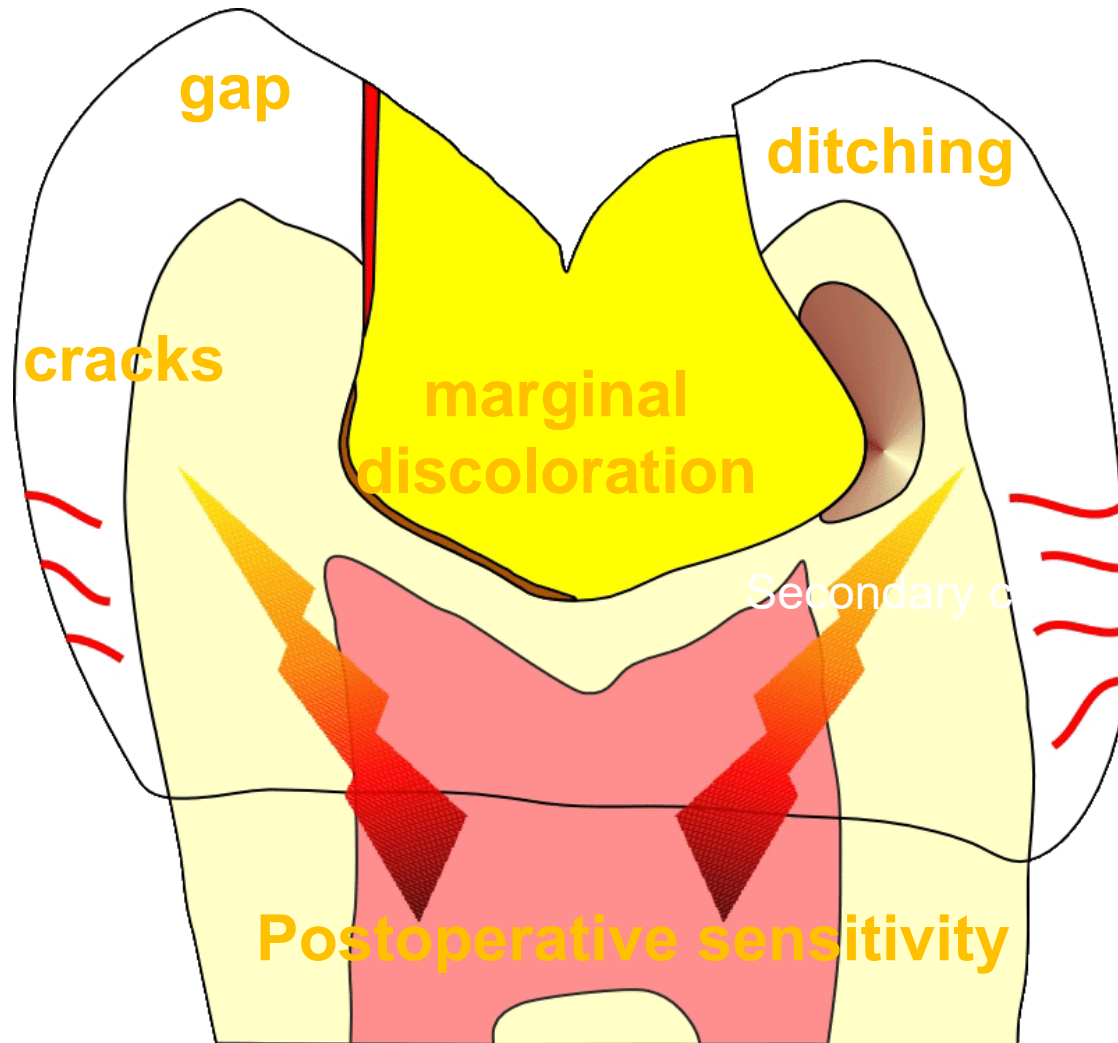
# Polymerization shrinkage and polymerization stress



Pre -gel  
Gel point  
Post -gel



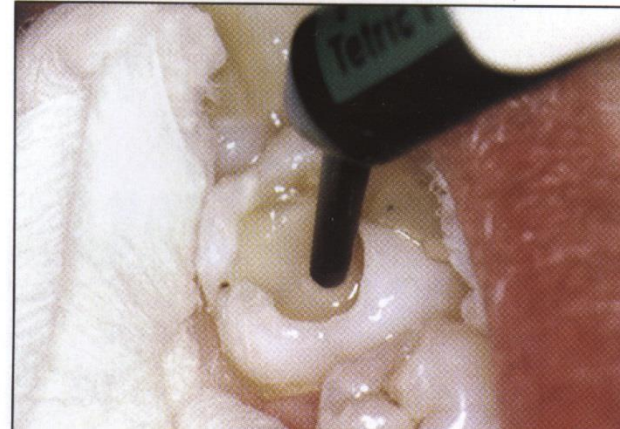
# Risks – high C-factor



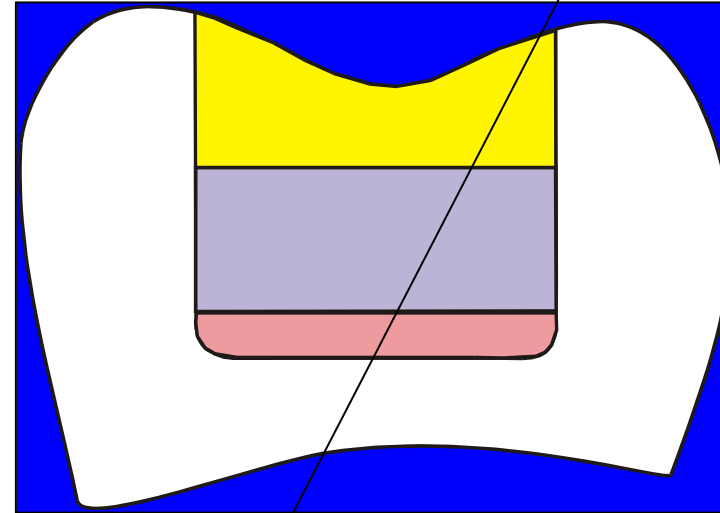
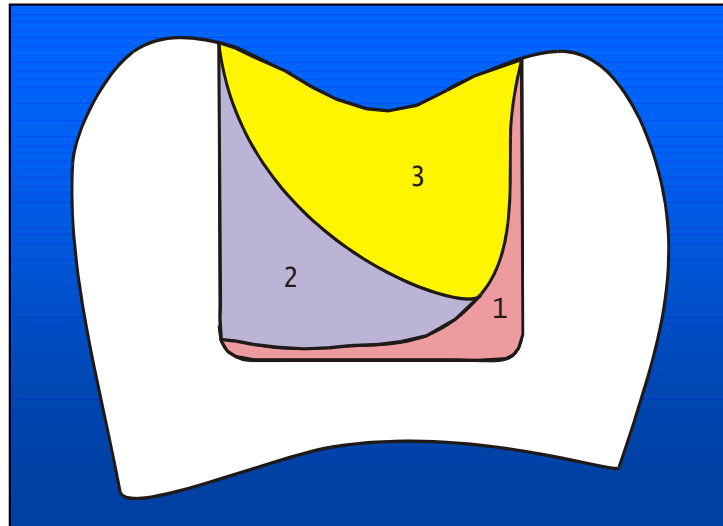
Versluis 2000

# Flowables - importance

1. **Excellent marginal adaptation**
2. **Protection of the adhesive**
3. **Elastic layer ?**



# Placement of the material Incremental technique with respect to C-factor of each layer



# Adhesives

– Acid etching technique

Etching

Washing

Priming Bonding

# Adhesives

– Selfetching adhesive systems

Priming

Bonding

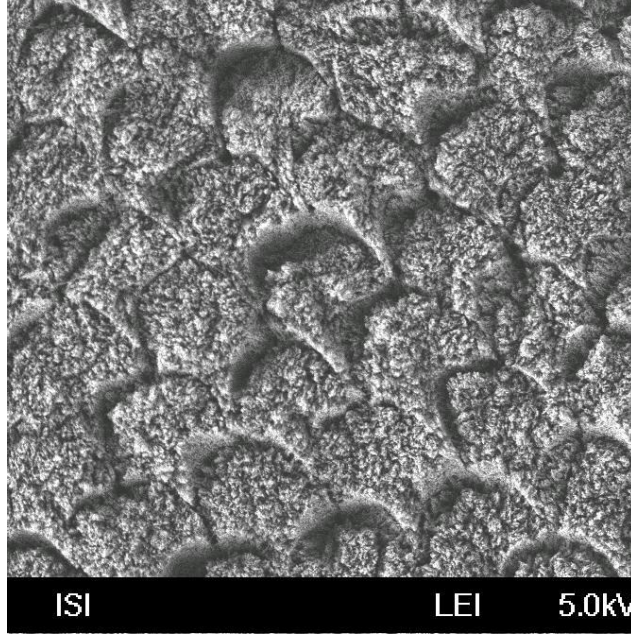
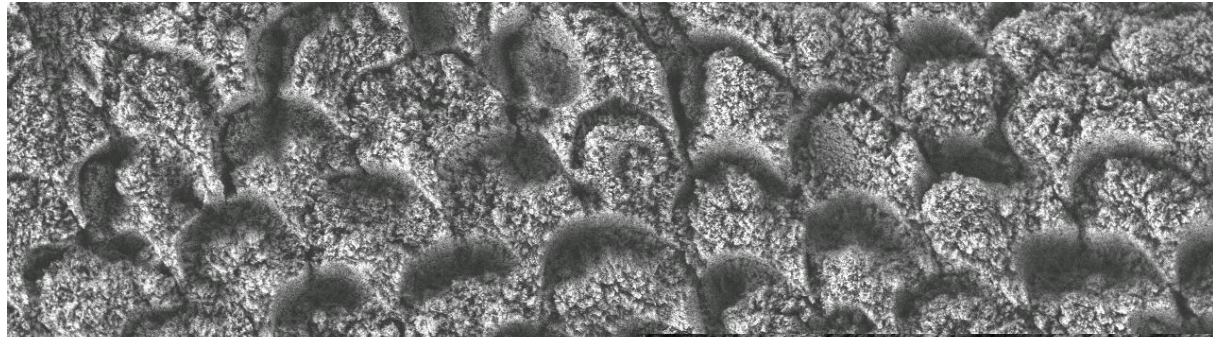
# Adhesives

- Active and passive bonding

Active – rubbing with microbrush - selfetching

Passive – without any rubbing – acid etching







ISI LEI 5.0kV



ISI LEI 5.0kV X2,000 10μm WD 7.9mm





ISI

LEI


5.0kV

X6,000

1 $\mu$ m

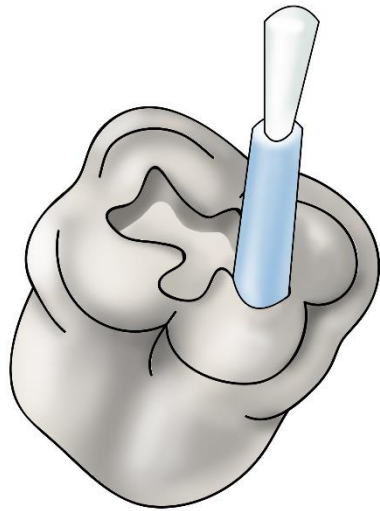
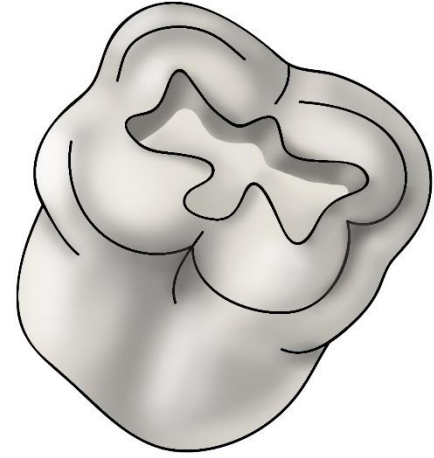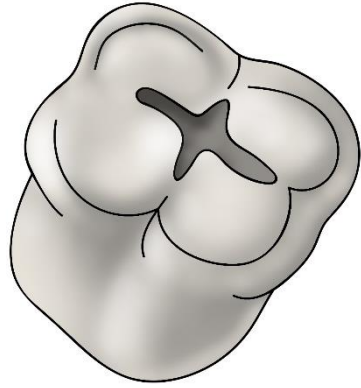
WD 9.0mm

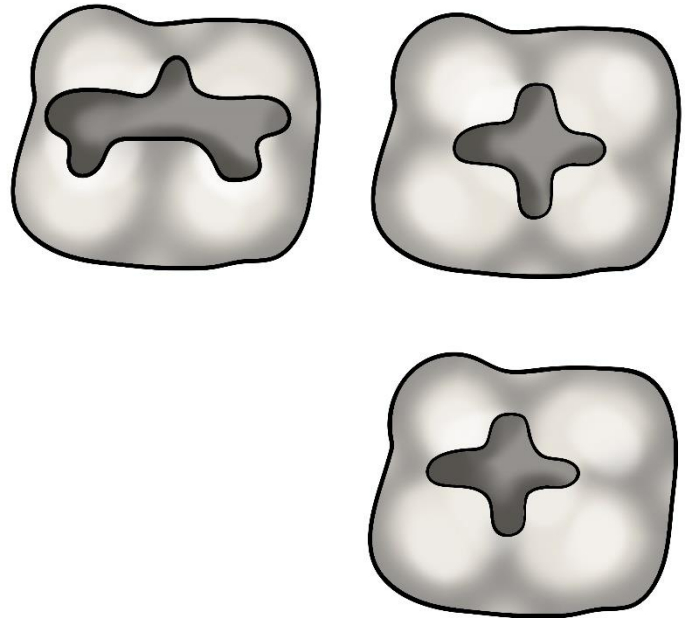
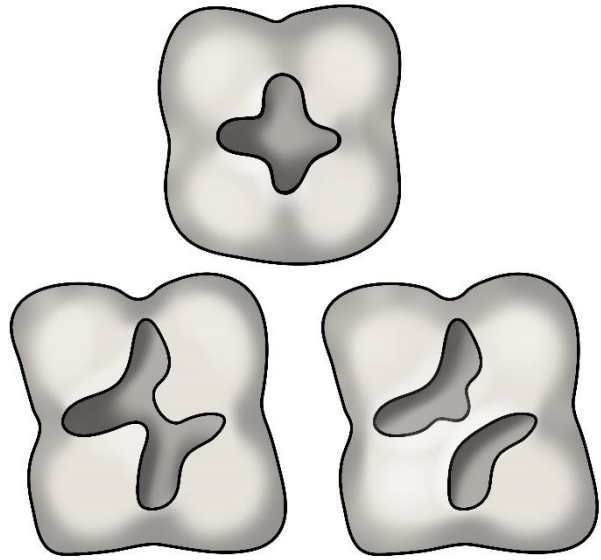



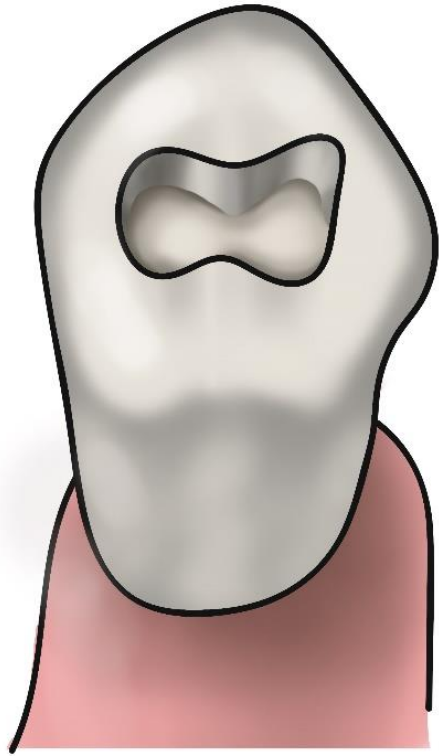


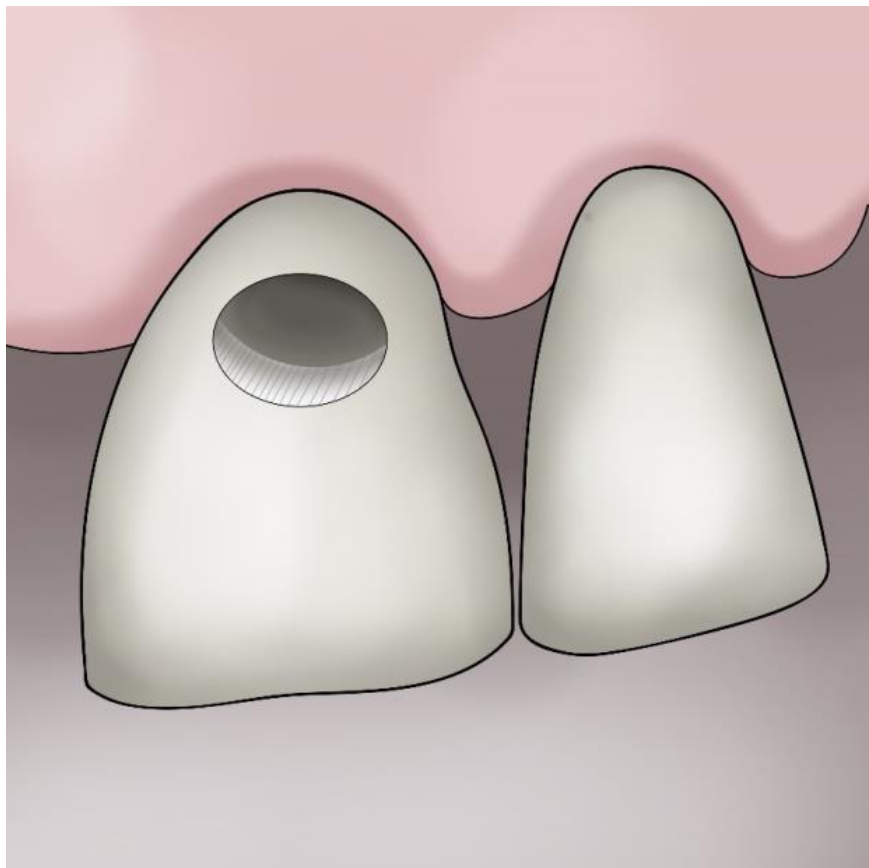
# Cavosurface margin for amalgam

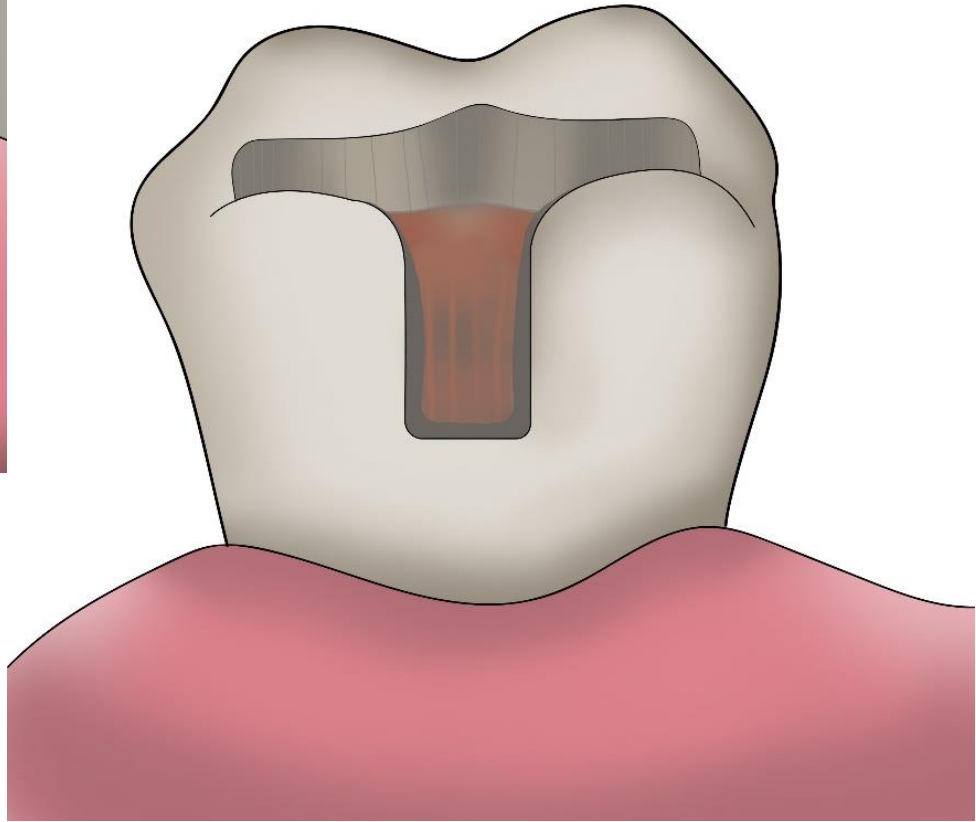
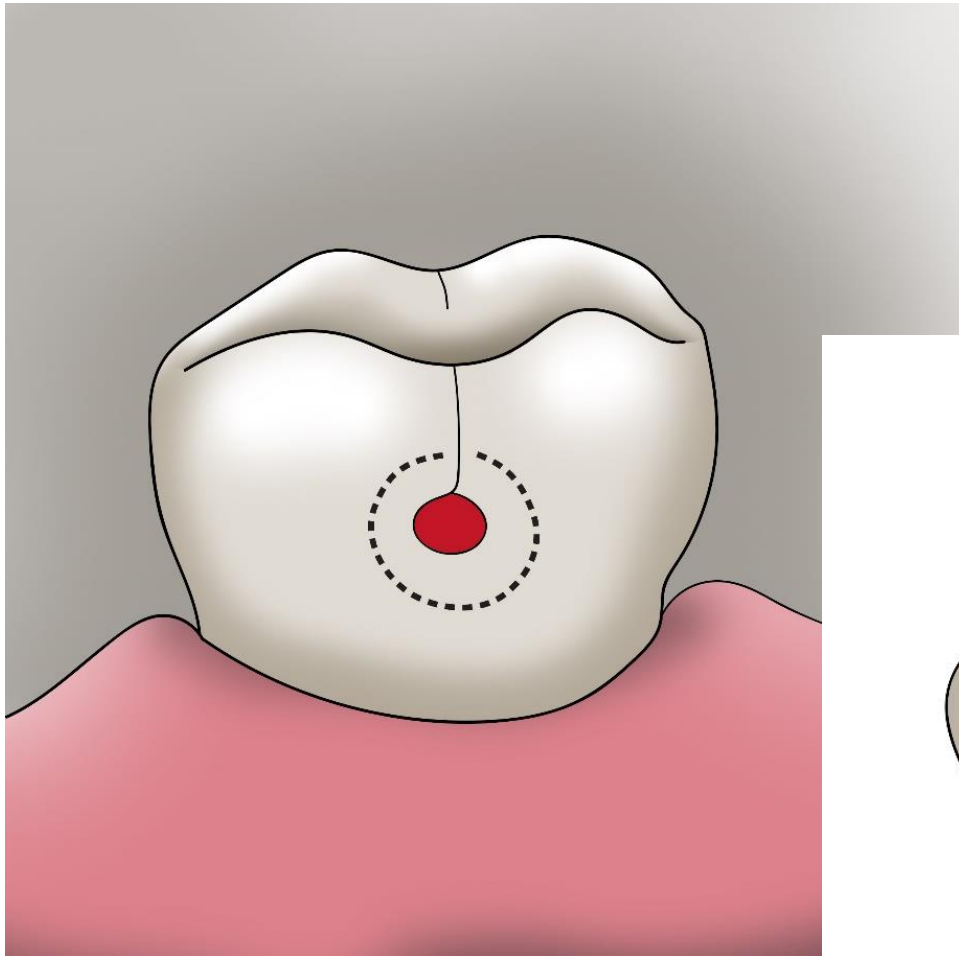
- Ideal outline includes all occlusal pits and fissures. If crista transversa (1st lower premolar) or obliqua (1st and 2nd upper molar) are not affected, it is strongly recommended not to prepare them.



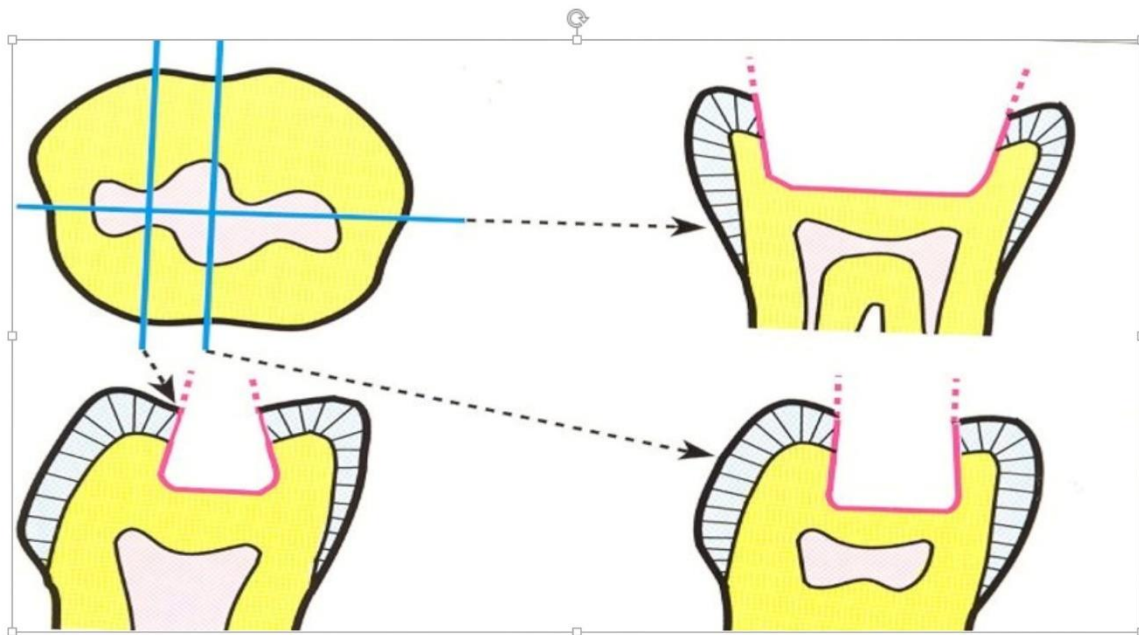






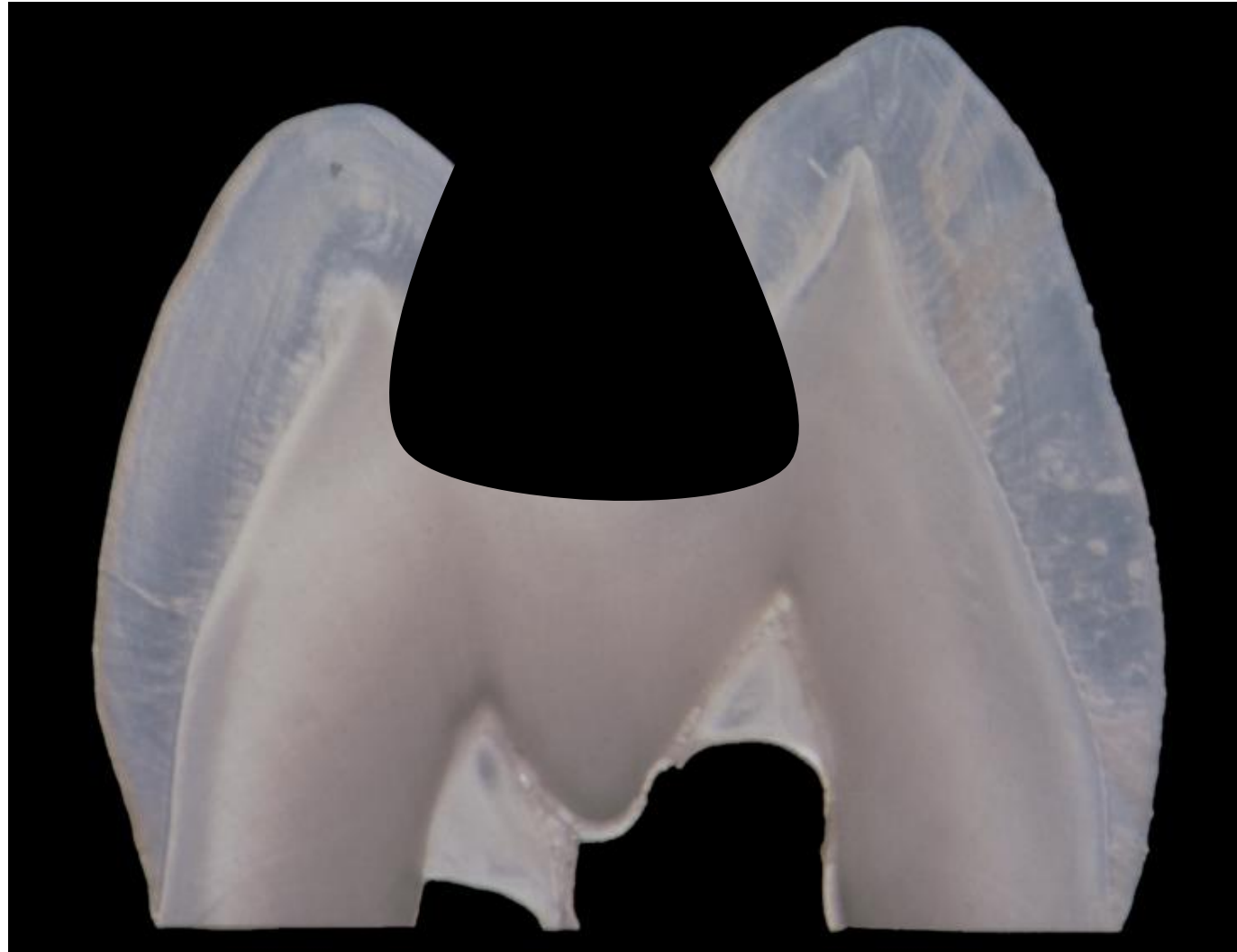








# Box with undercut



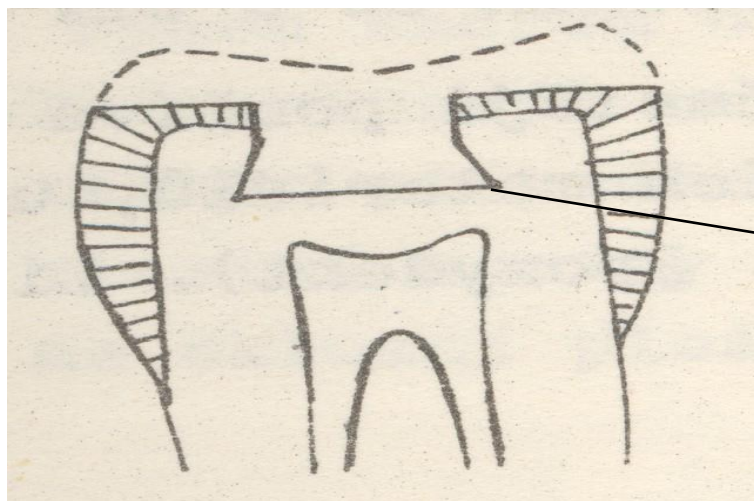
# Retention principles

- Prepare the box – the bottom is in dentin
- Undercuts can be prepared!

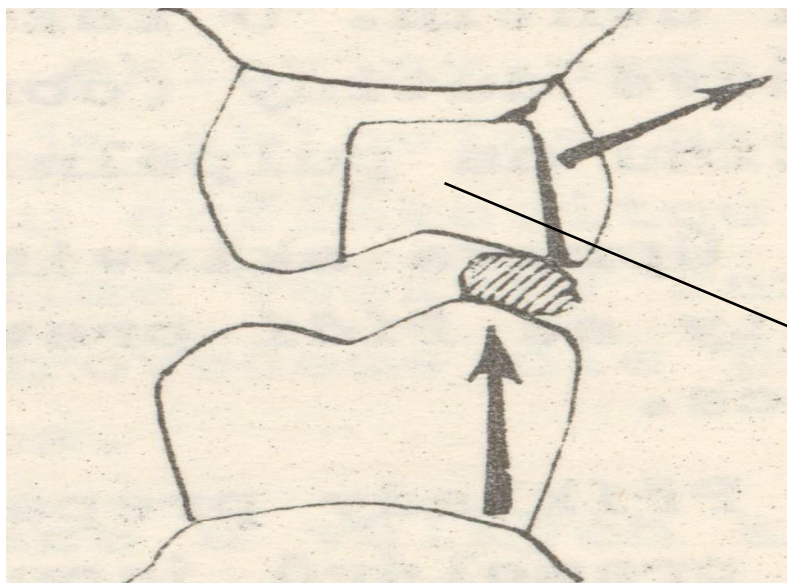
No undermine proximal ridge!§

# Principles of resistance

- No undermined enamel left (proximal ridge should not be undermined!!!)
- No sharp edges
- The thickness of amalgam 2 mm



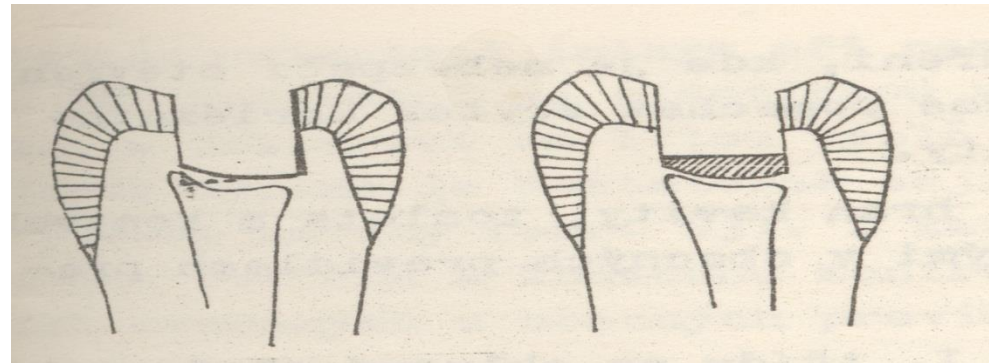
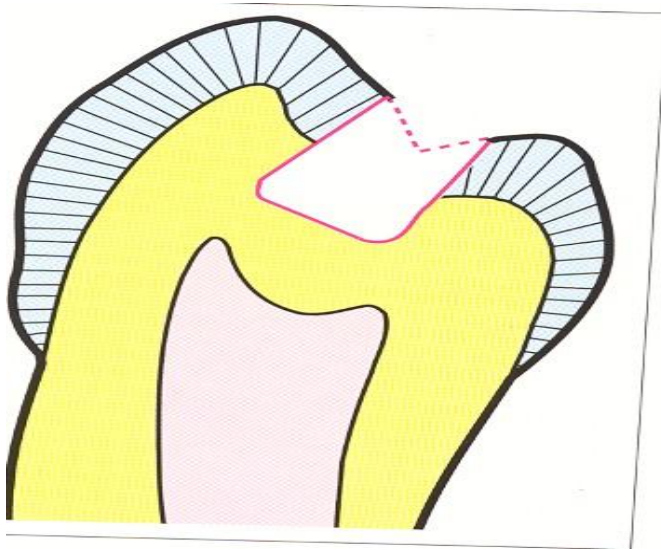
Sharp edges



Margin too next to cup

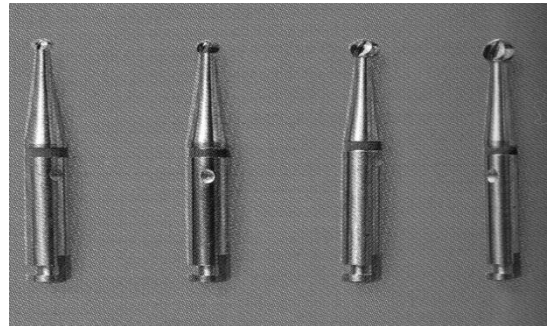
The pulpal wall and pulp chamber

Pulpal wall is parallel to the pulp chamber



# Removal of carious, infected, dentin

- Spoon excavator or a slowly revolving , round carbid bur of appropriate size.



# Protection of dentin wound

- Dentin wound should be covered – protection of dental pulp against irritation

Physical

-thermal

-osmotic

Chemical

Combination

# Protection of dentin wound

Isolation

Filling (small cavities)

Base (moderate – large cavities- depth 2mm and more approx.)

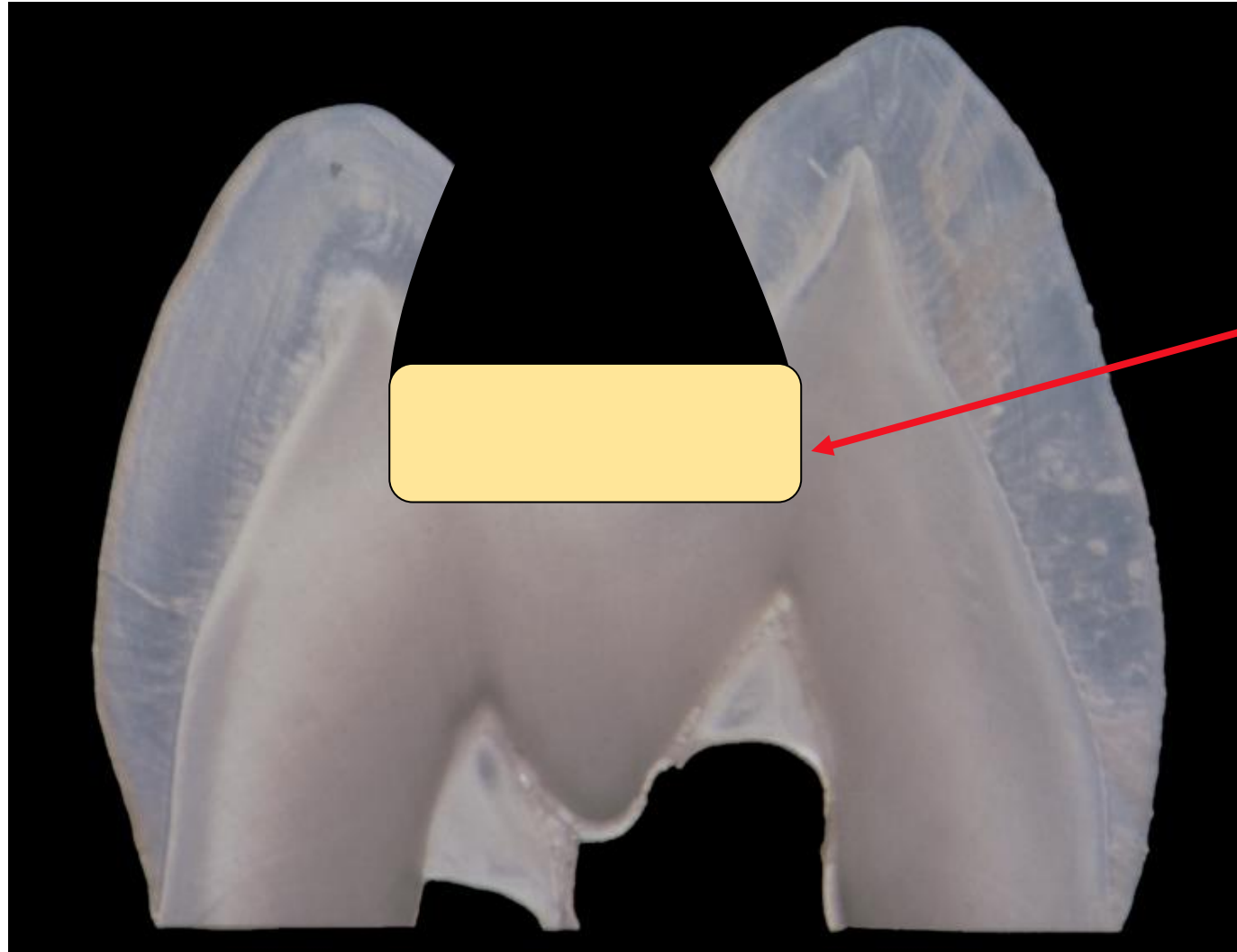
For amalgam – zinkoxidphosphate cement



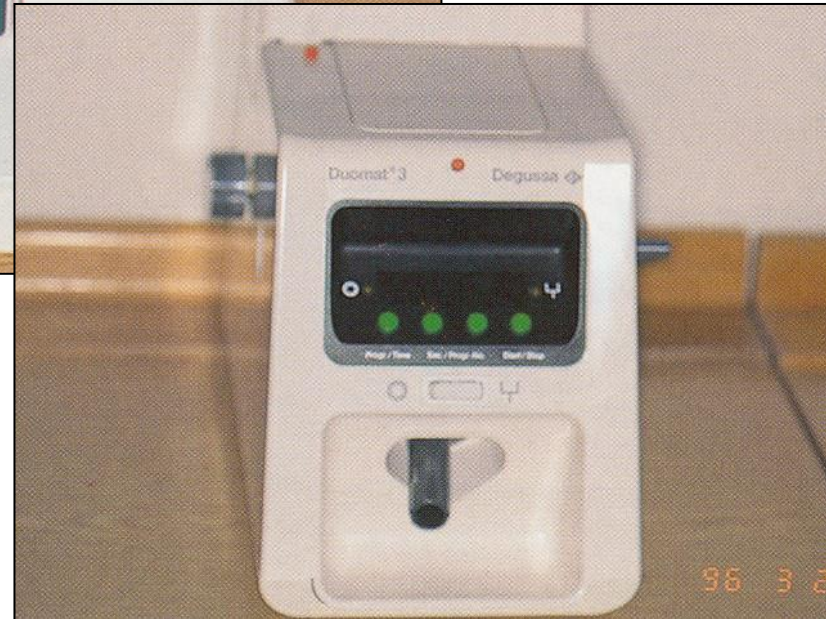
**When amalgam is used:**

**Base is made usually  
of zinkoxidphosphate cement  
It is placed only on pulpal wall**

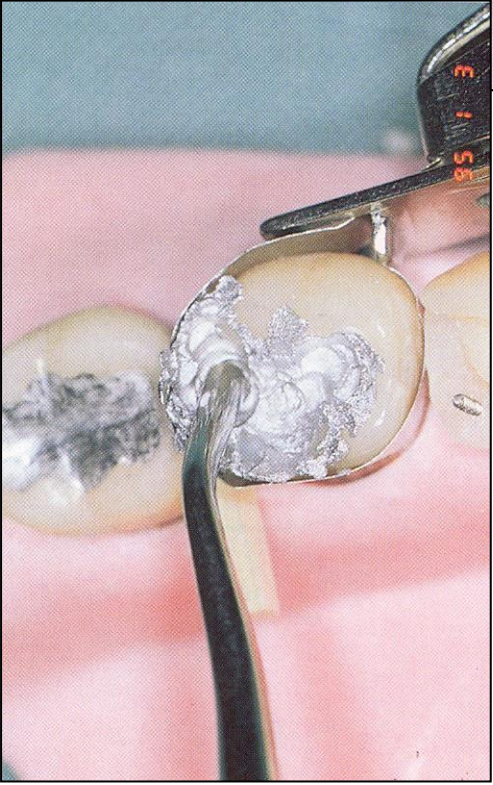
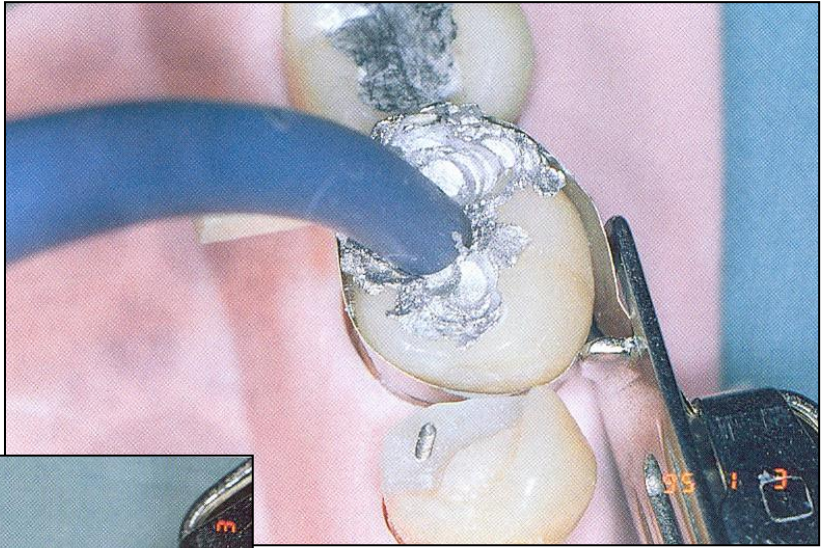

# Box with undercut

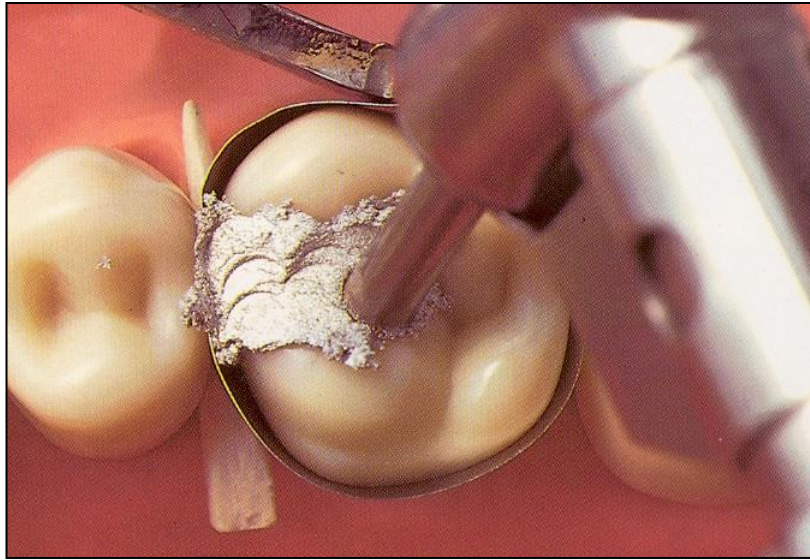
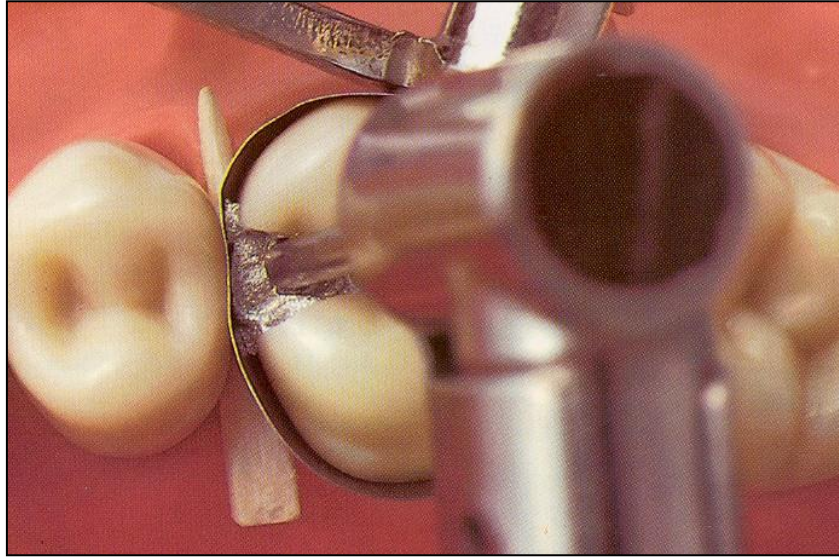


Base

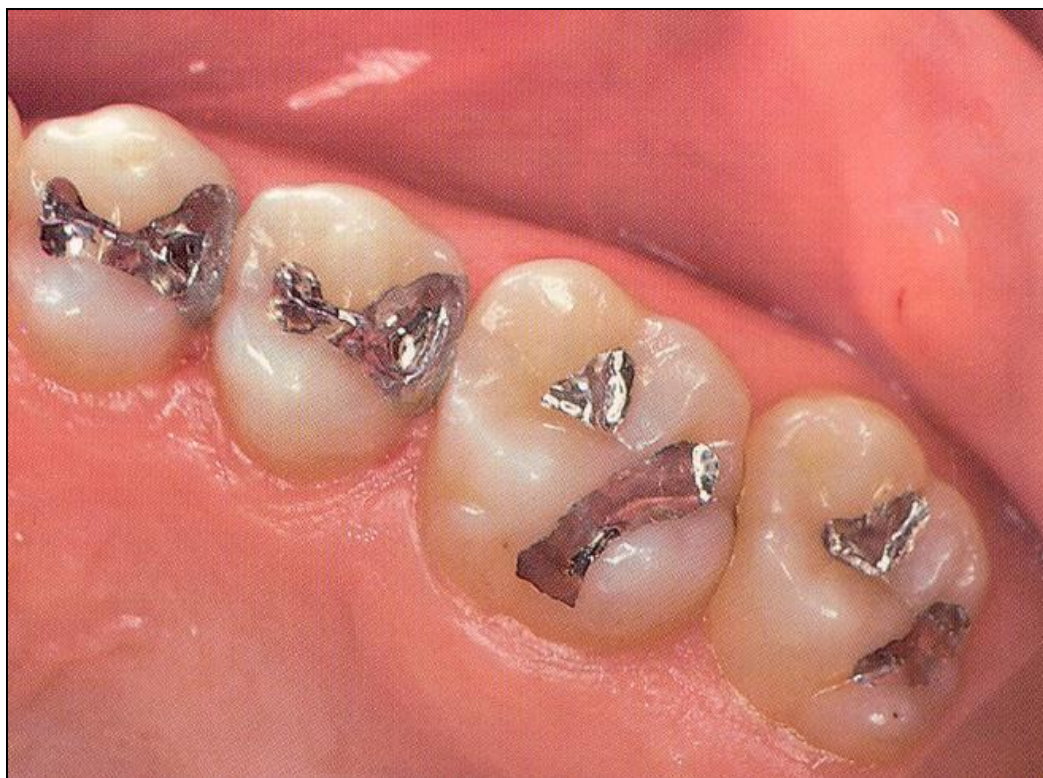











# CLASS II.

## Proximal caries in posterior teeth

Direct restorations

- Amalgam
- Composite
- Glassionomer
- Indirect restorations –inlays, onlays

Composite

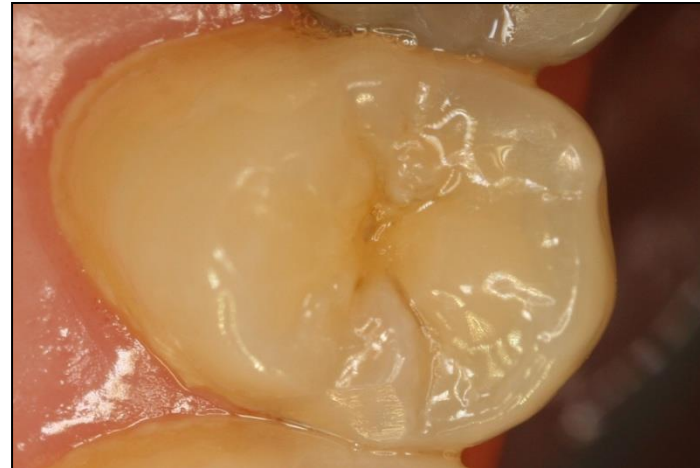
Ceramics

83 Metal alloy

# Class II.

## Location:

Defects affecting one or both proximal surfaces of posterior teeth.





# Interdental space

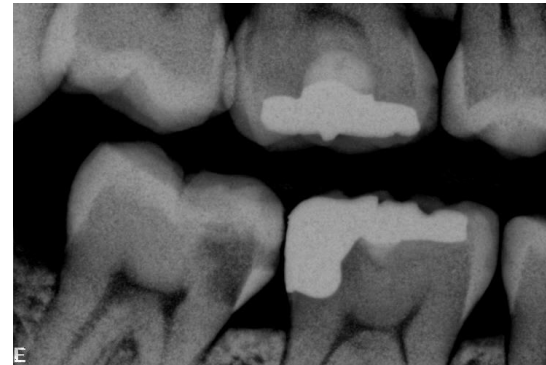- Interdental space is a caries danger area (below the contact point).
- Interdental space is infilled with interdental papilla, that moves apically during the time and the space is open.
- Dental caries begins below the contact point.

# Class II.

Origin:

Proximal surface below the contact point

Propagation of dental caries from  
the occlusal surface

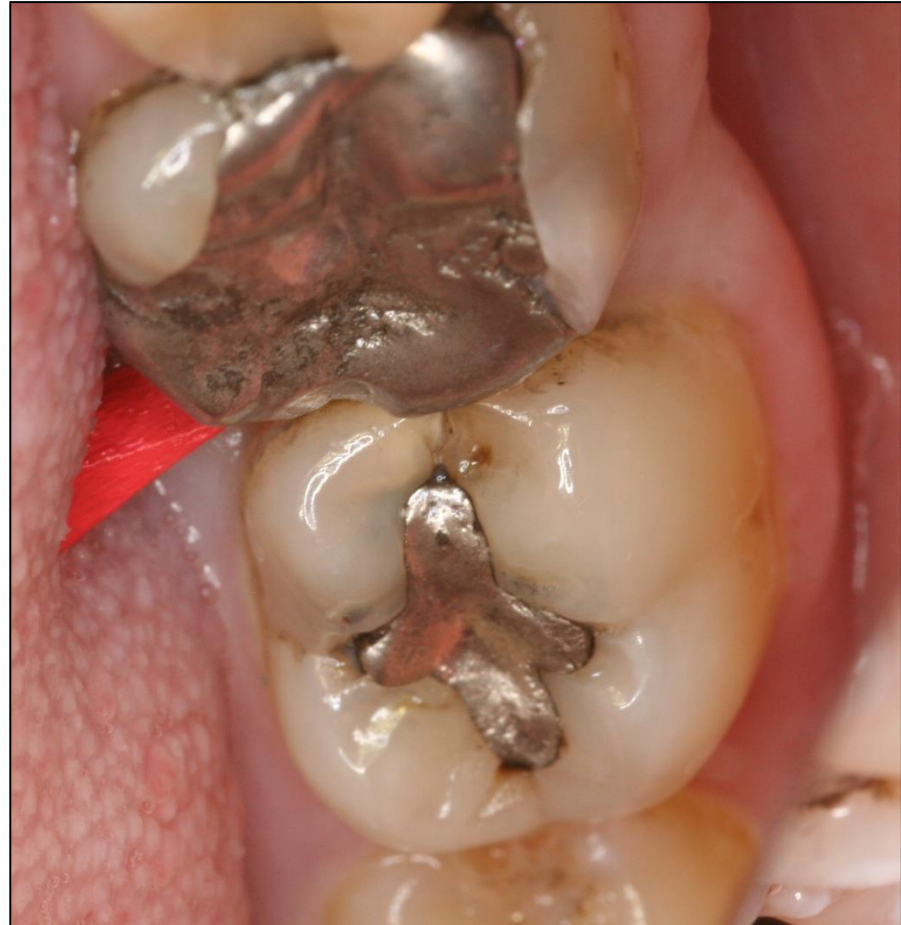
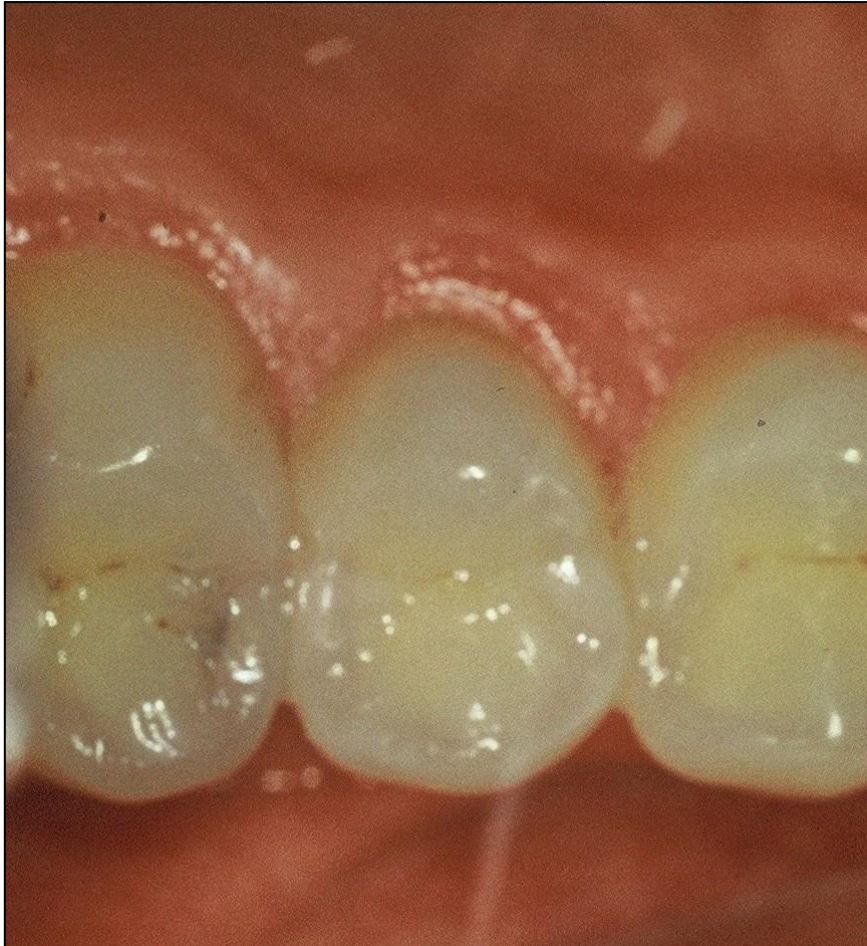
# Symptoms

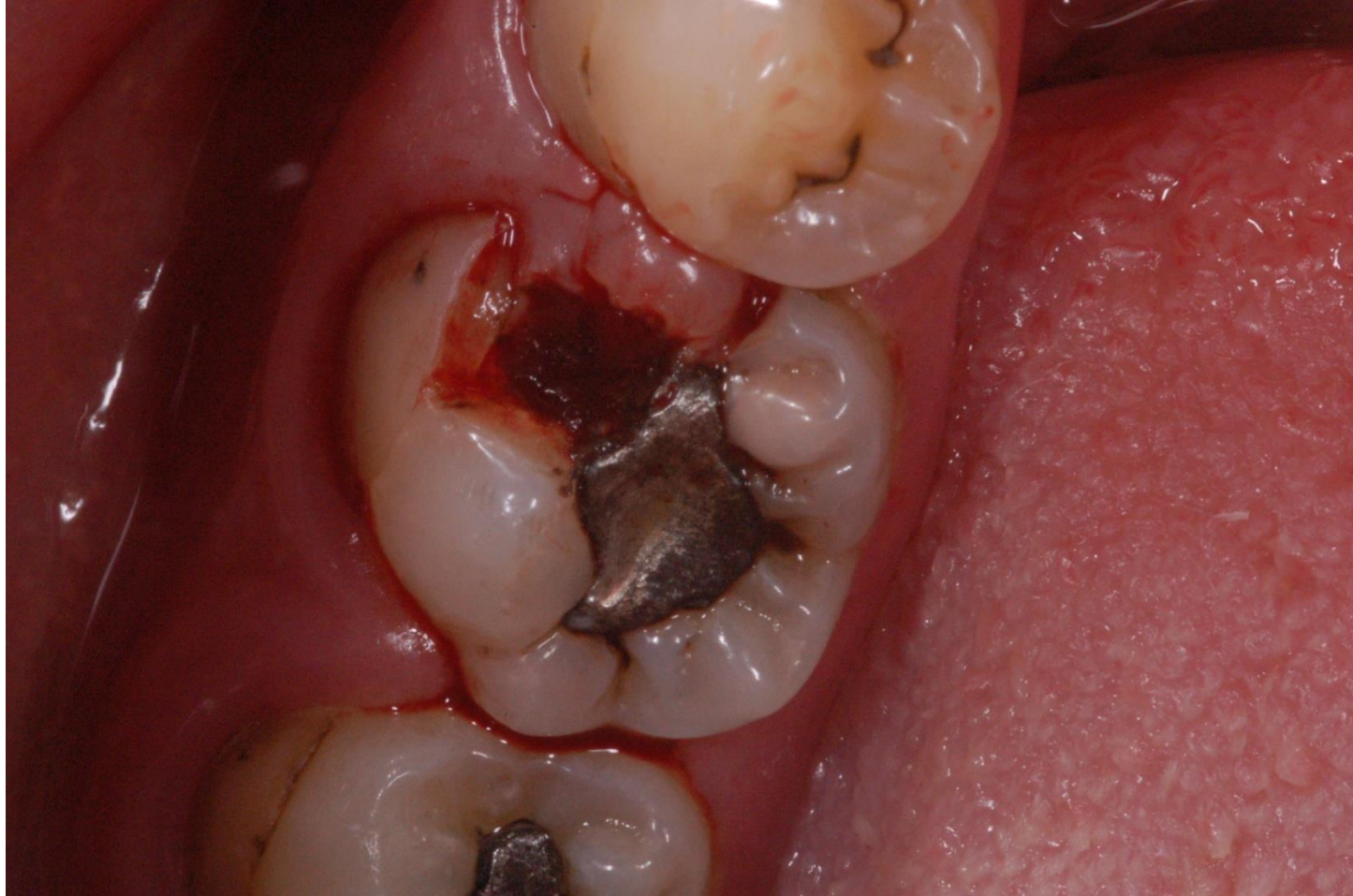- No symptoms
- Increased sensitivity (cold, sweet)
- Retention of food
- Defect (cariou lesion is open – the enamel is broken)
- Bite sensitivity (when cariou lesion is open)

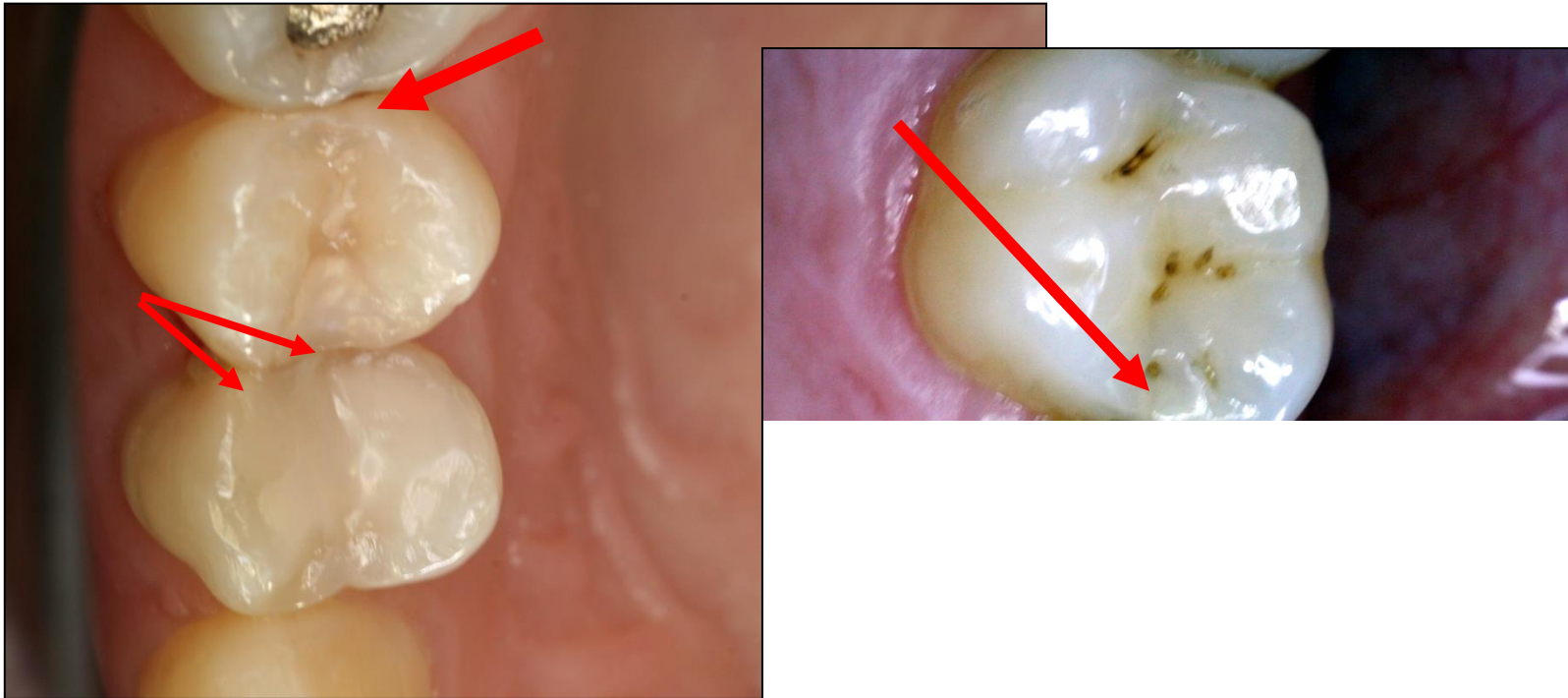
# Diagnosis

- Visual changes of tooth structure (chalk white colour).
- Transillumination (white light, or Diagno Cam).
- Radiography

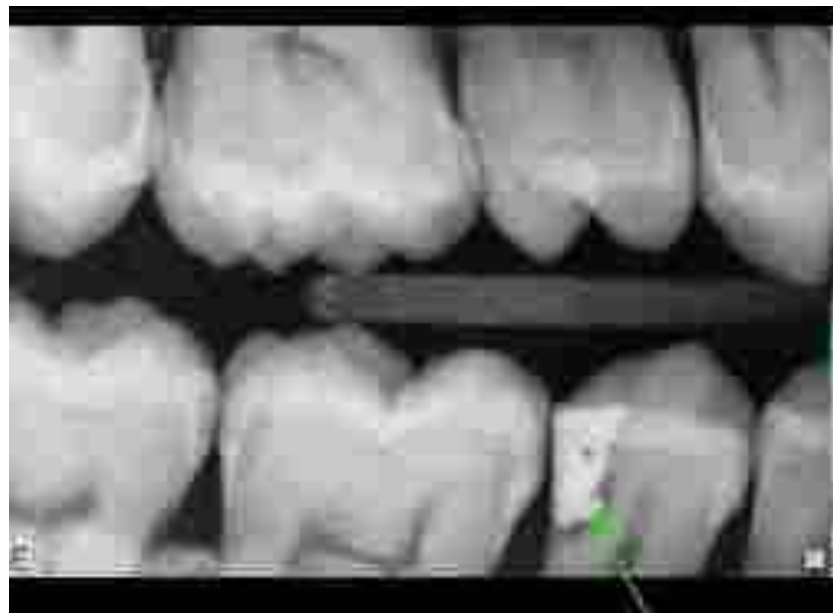







# Bite wing



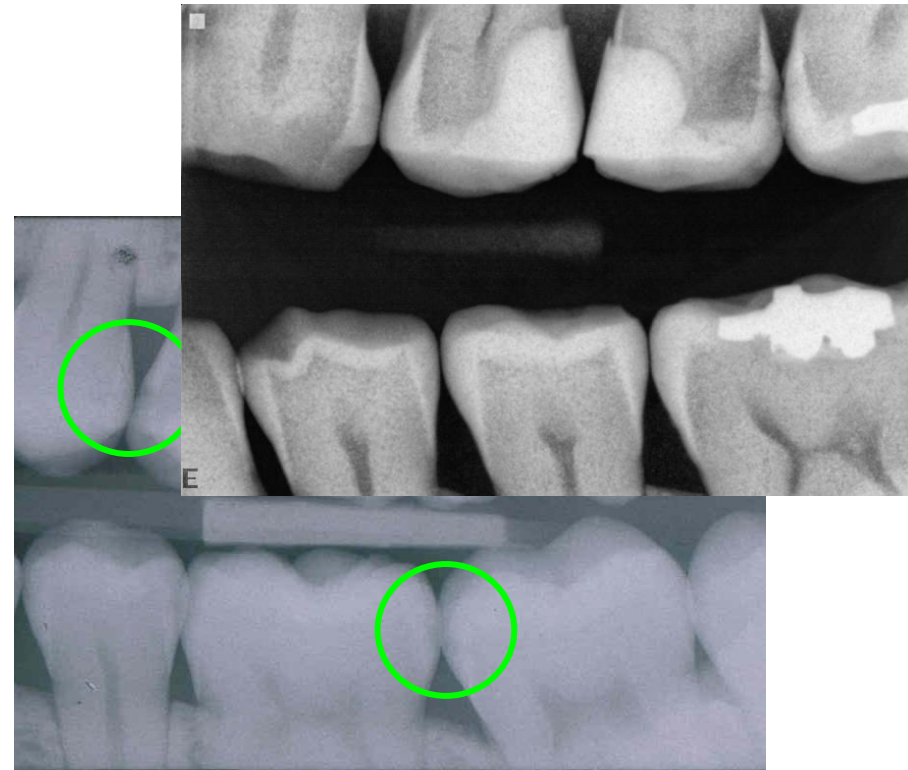
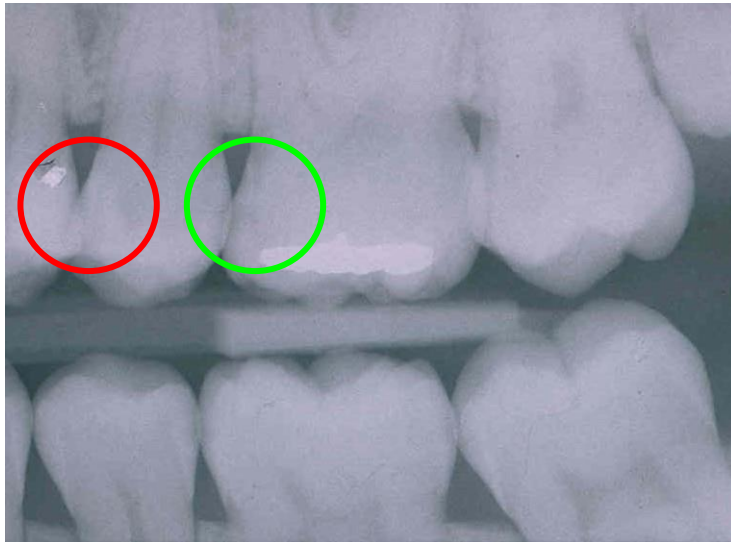


D1 – radiolucency till  $\frac{1}{2}$  the enamel

D2 – radiolucency till the border of enamel and dentin

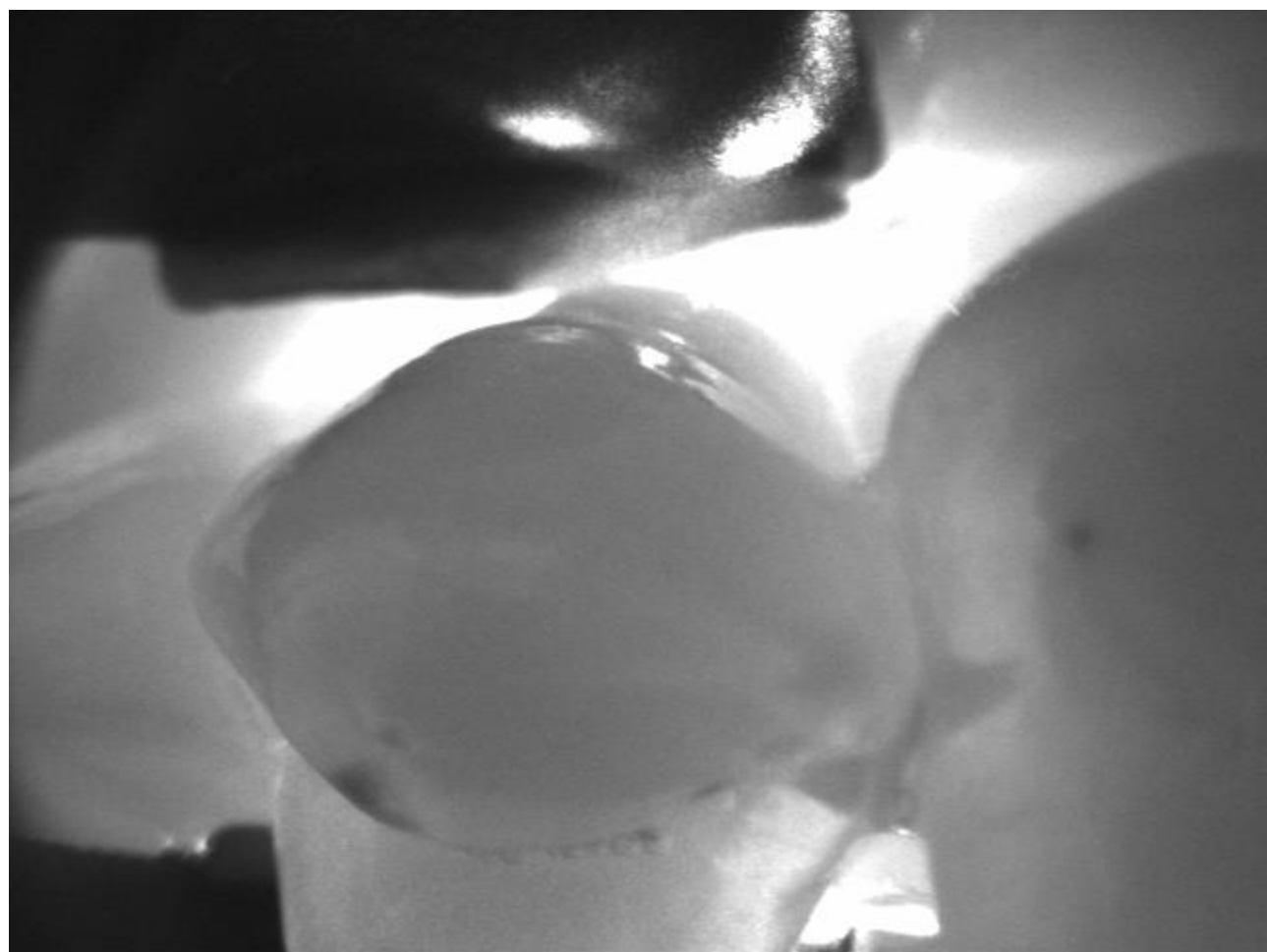
D3 – radiolucency till  $\frac{1}{2}$  dentin

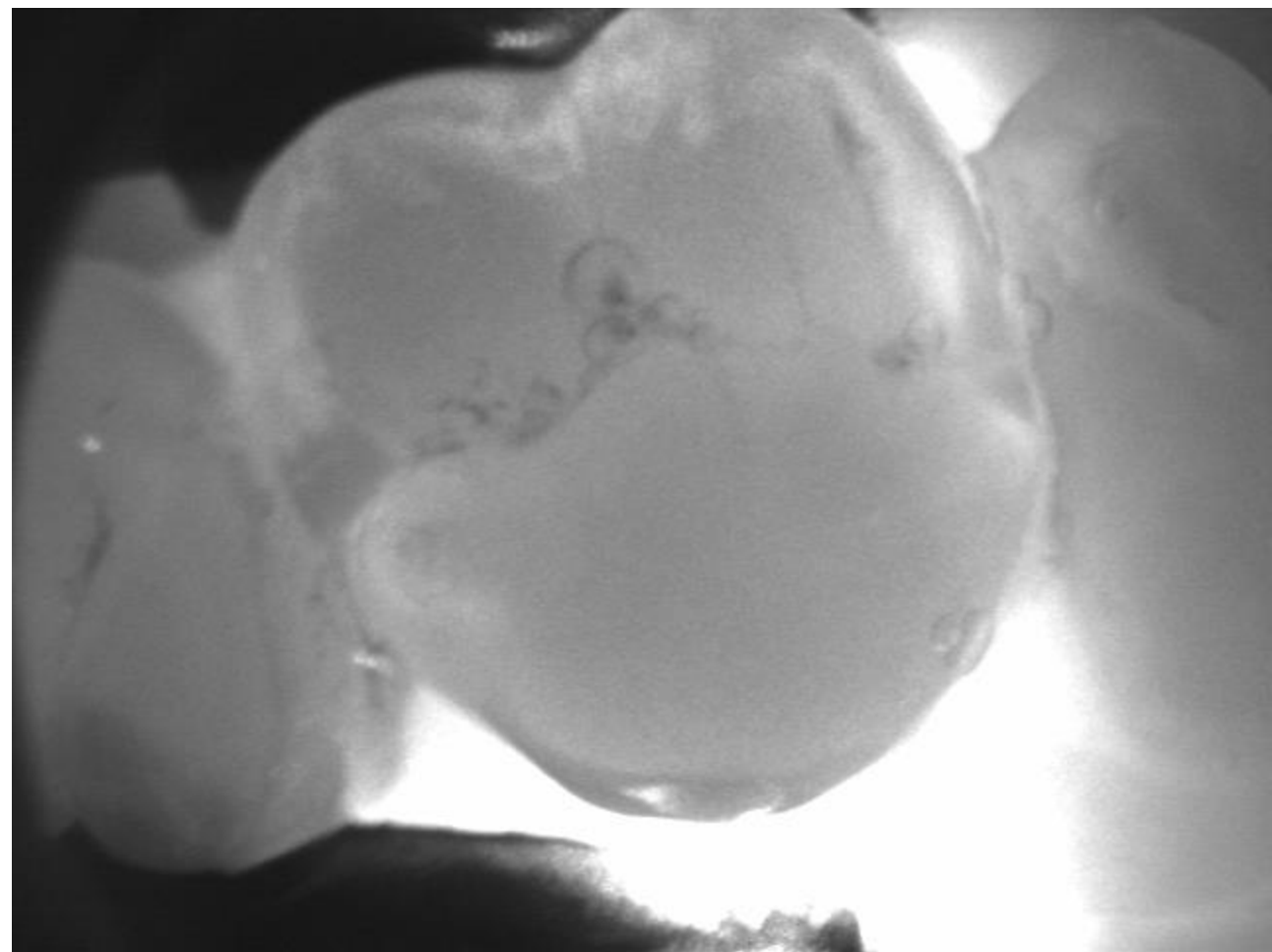
D4 - radiolucency more than  $\frac{1}{2}$  dentin



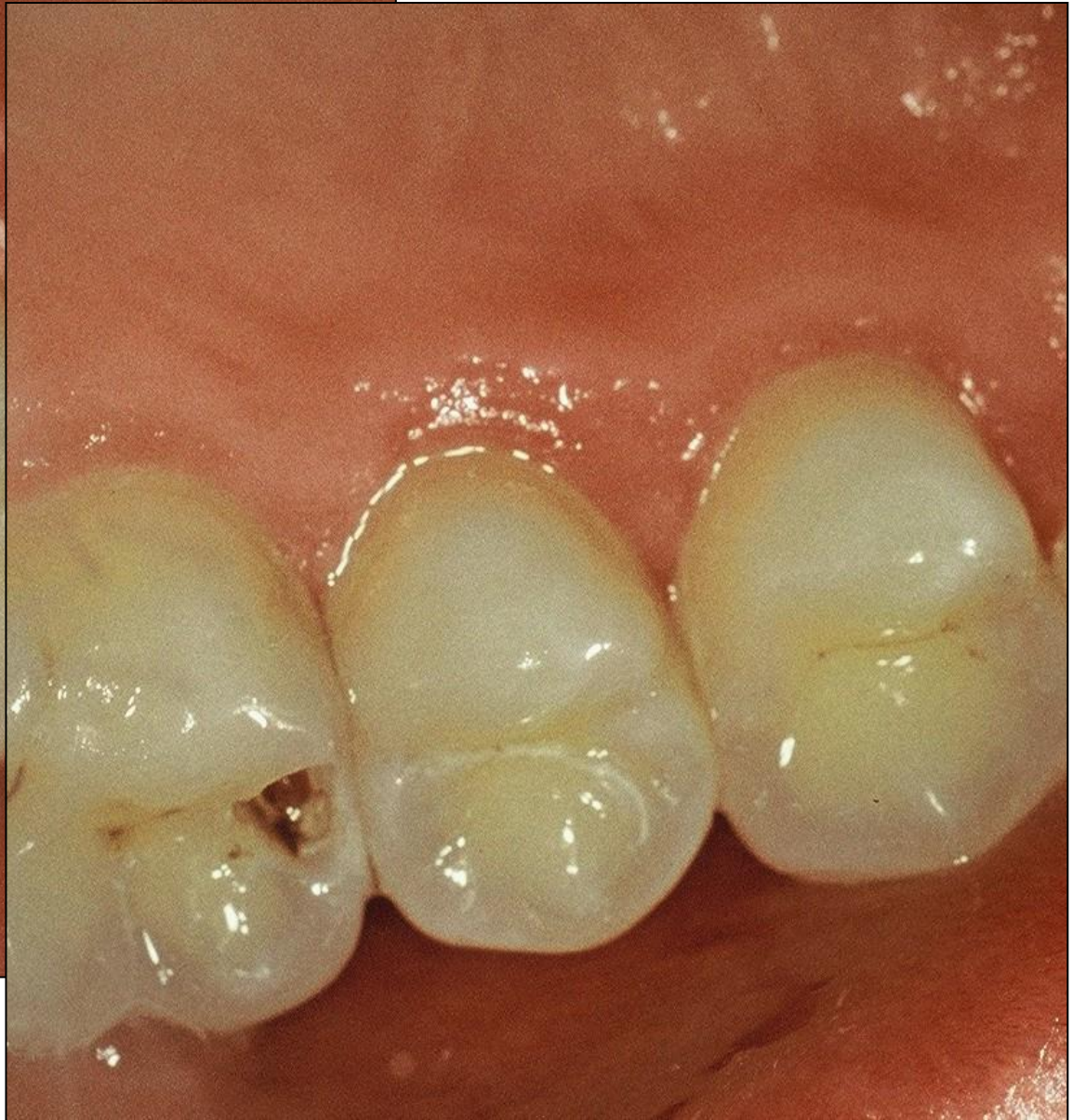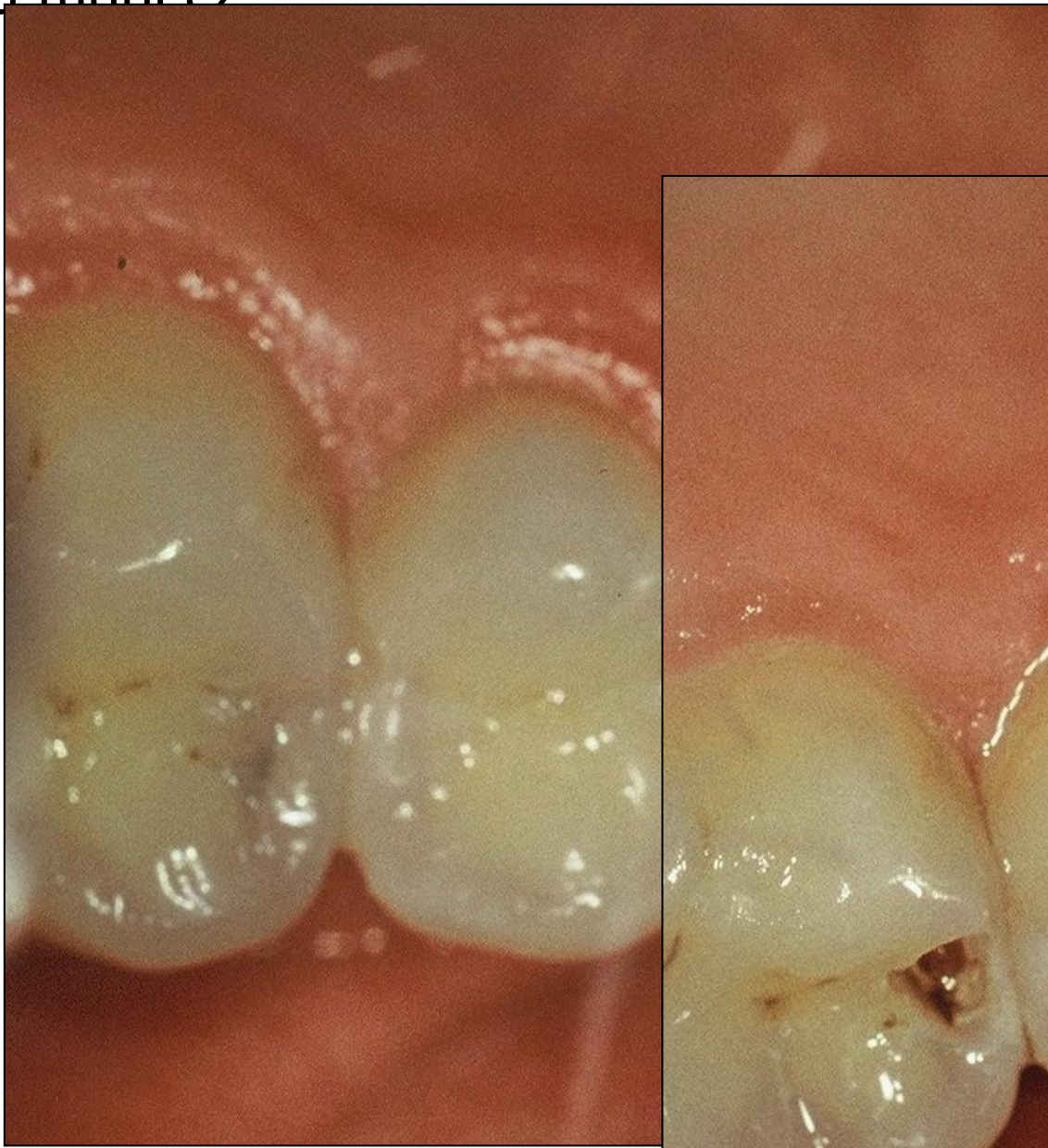# DIAGNOCam

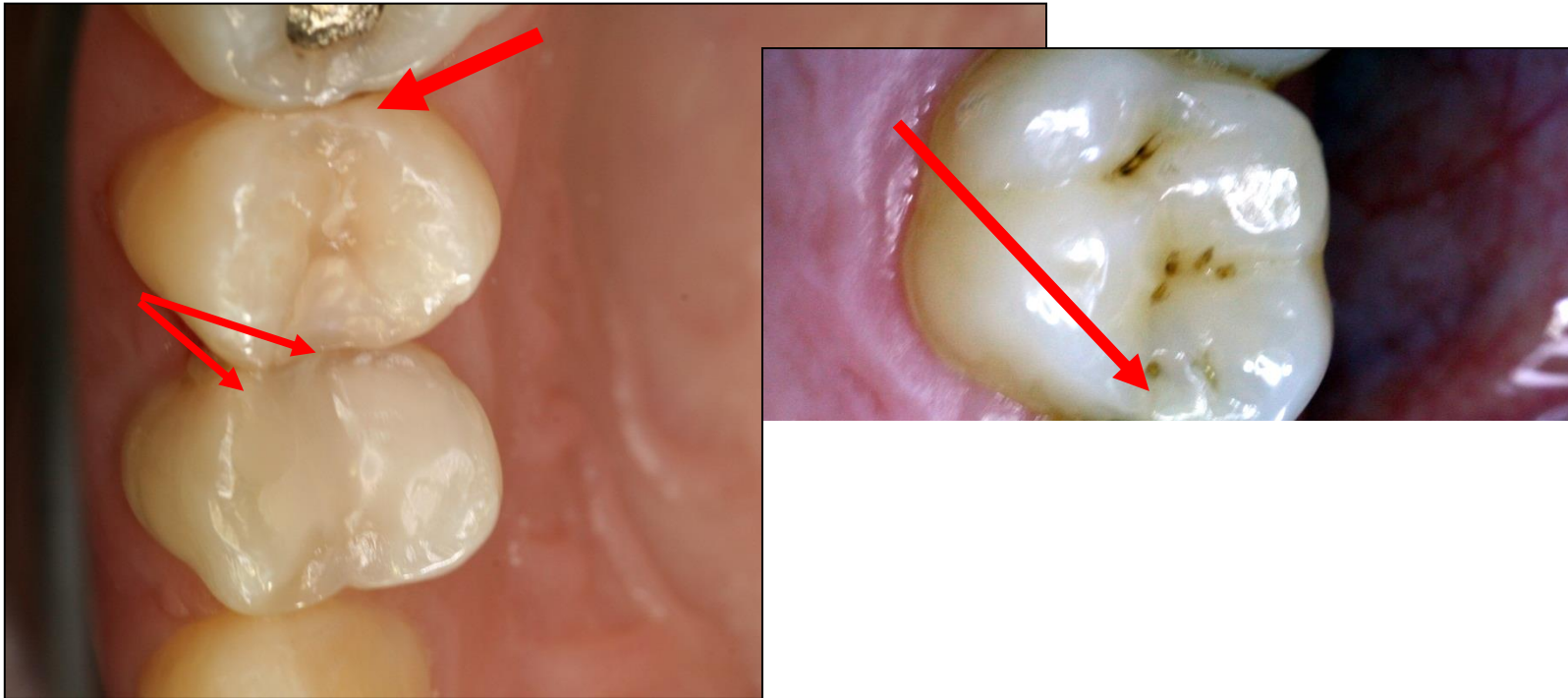










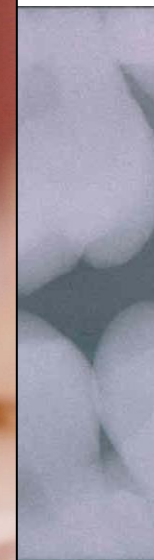
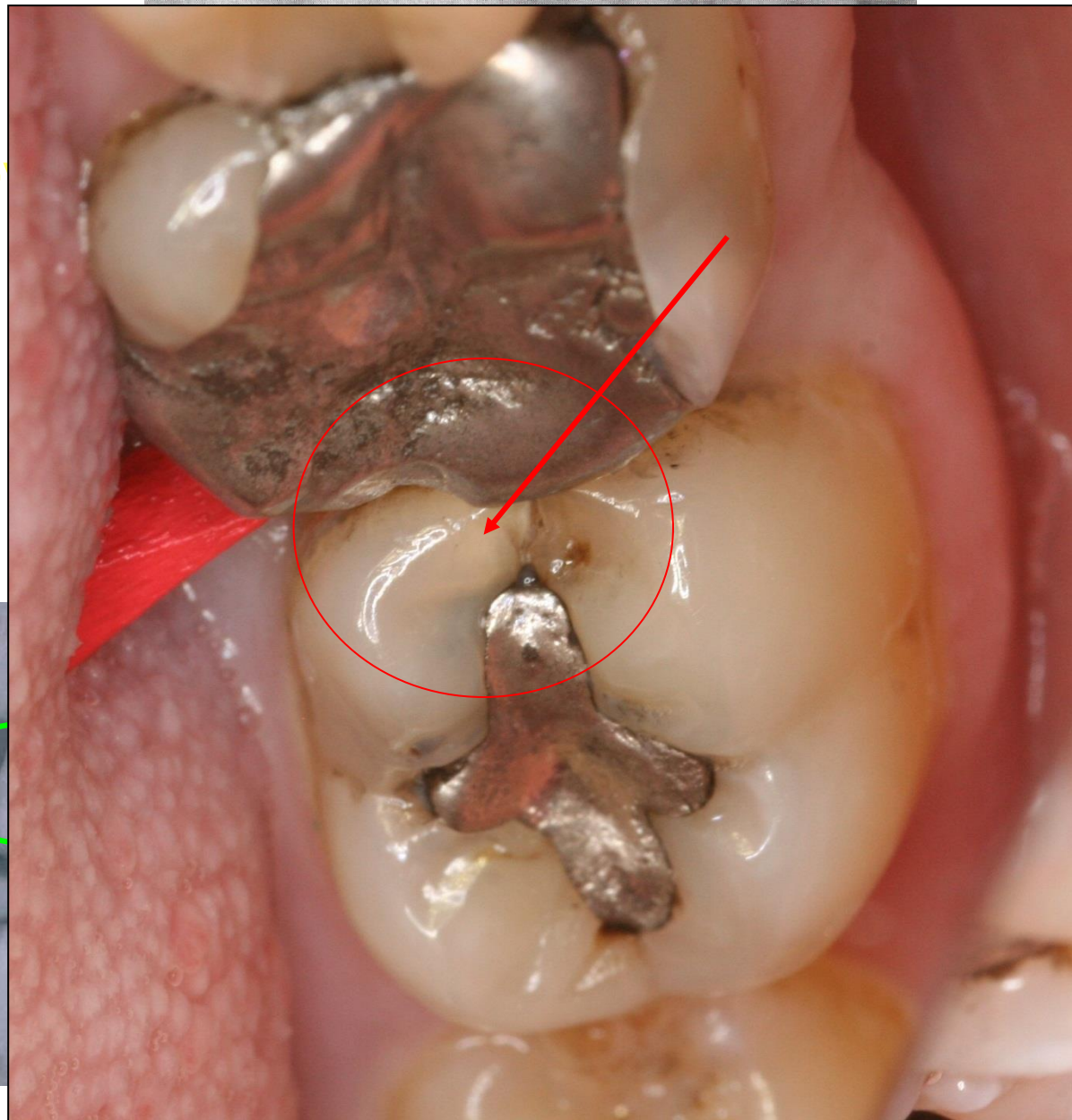
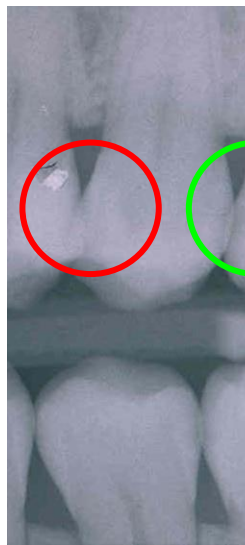








4 stupňo  
grading





# Choice of the material depends on

- Size of carious lesion
- Level of oral hygiene
- Occlusal loading
- Cooperation of the patient and other factors

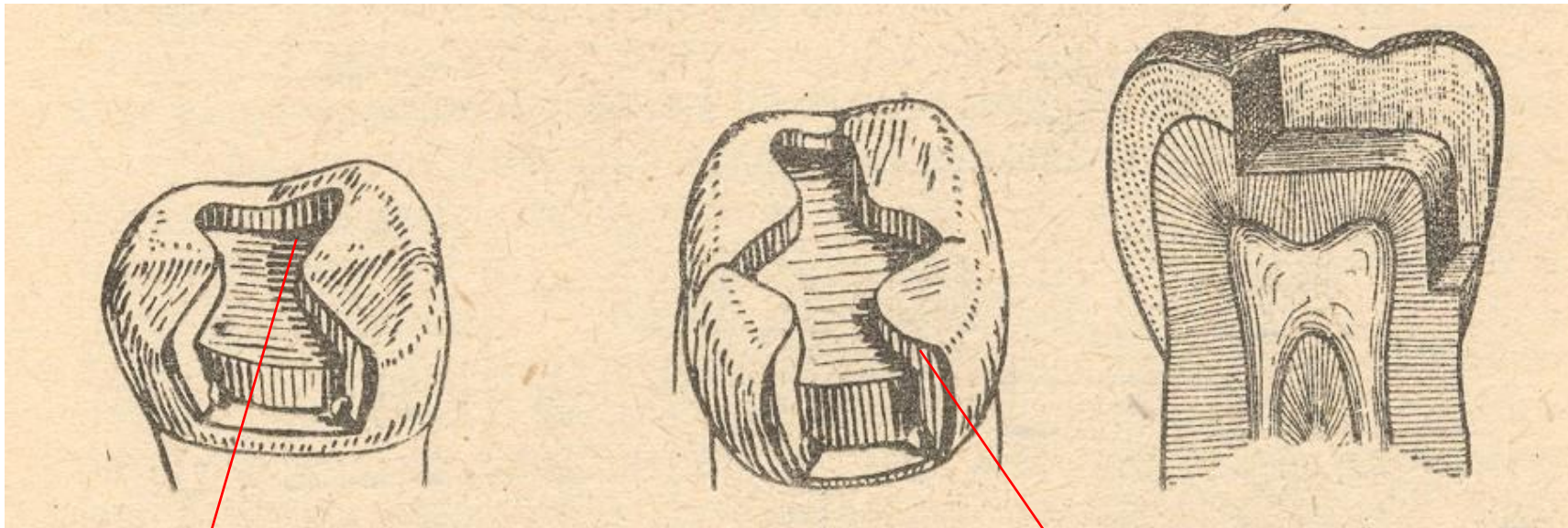
# Preparation - amalgam

- Conventional preparation acc. to the Black's rules
- Slot preparation
- Large preparation – cusp(s) involved

# Preparation - adhesive materials (composites, glass ionomers)

- Conventional preparation for composites
- Adhesive slot
- Tunnel preparation

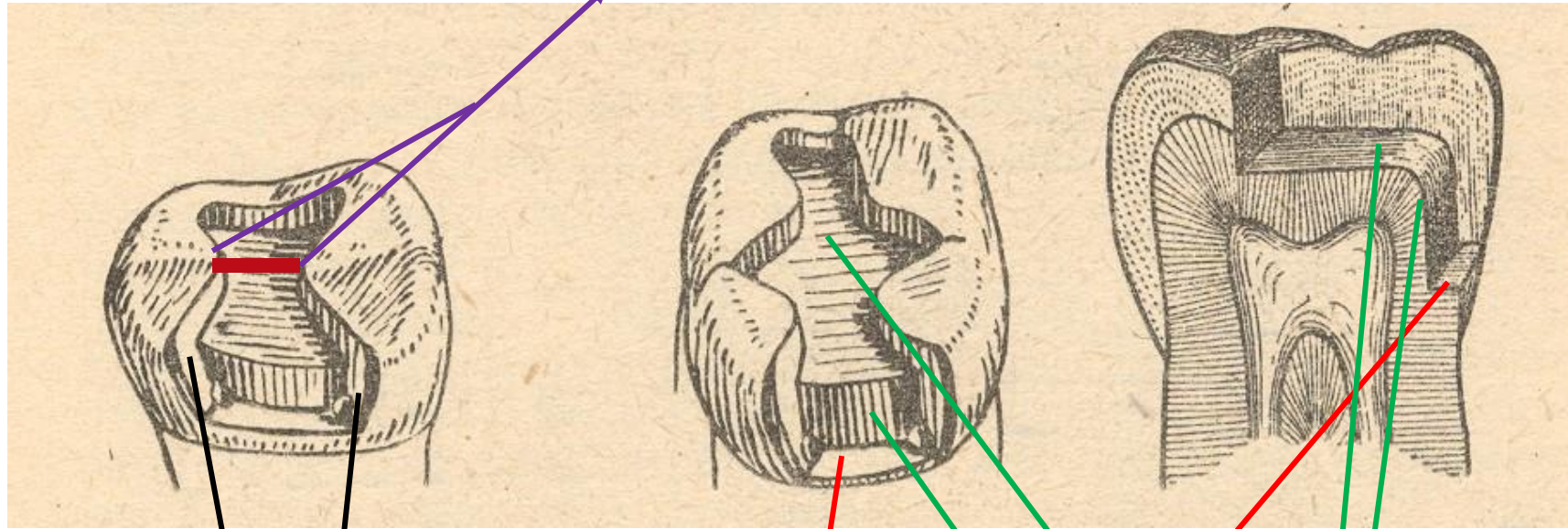
# Conventional preparation amalgam



Occlusal cavity

Proximal cavity - box

Isthmus



Axial wall

Gingival wall

Pulpal walls

# Access to the cavity

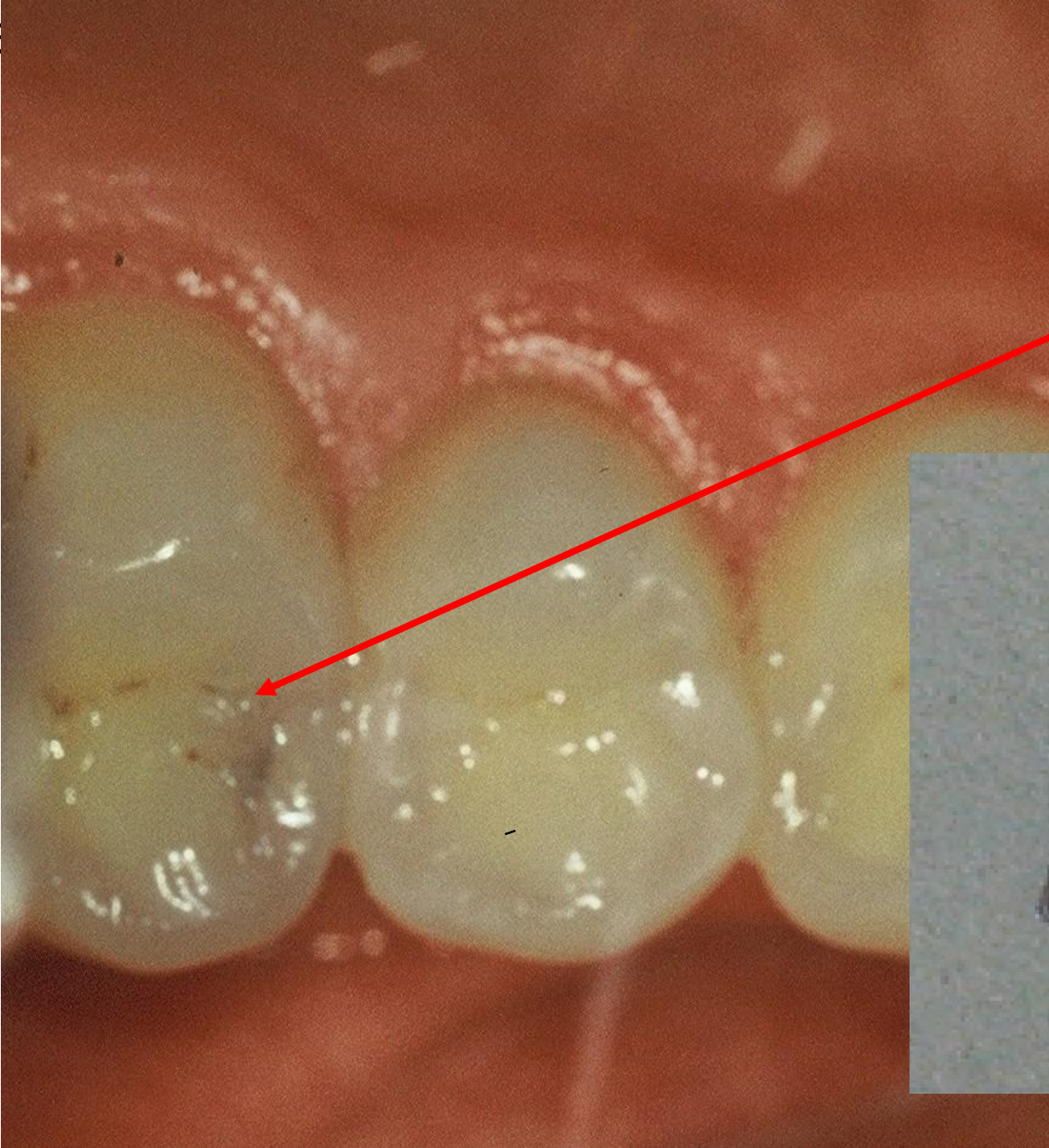
From the occlusal surface

Through the undermined enamel

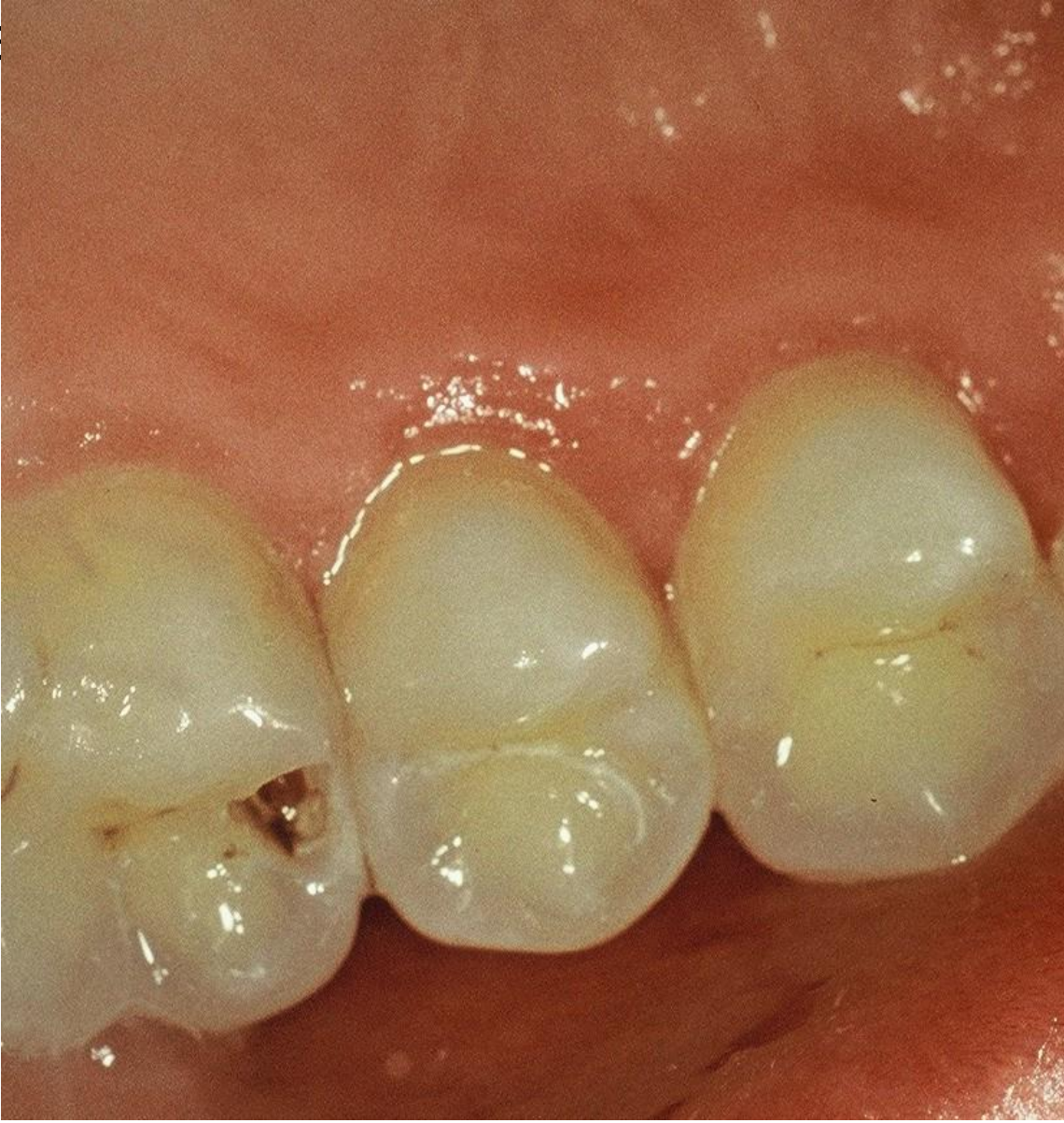
Separation using wooden wedges is useful



Pre op

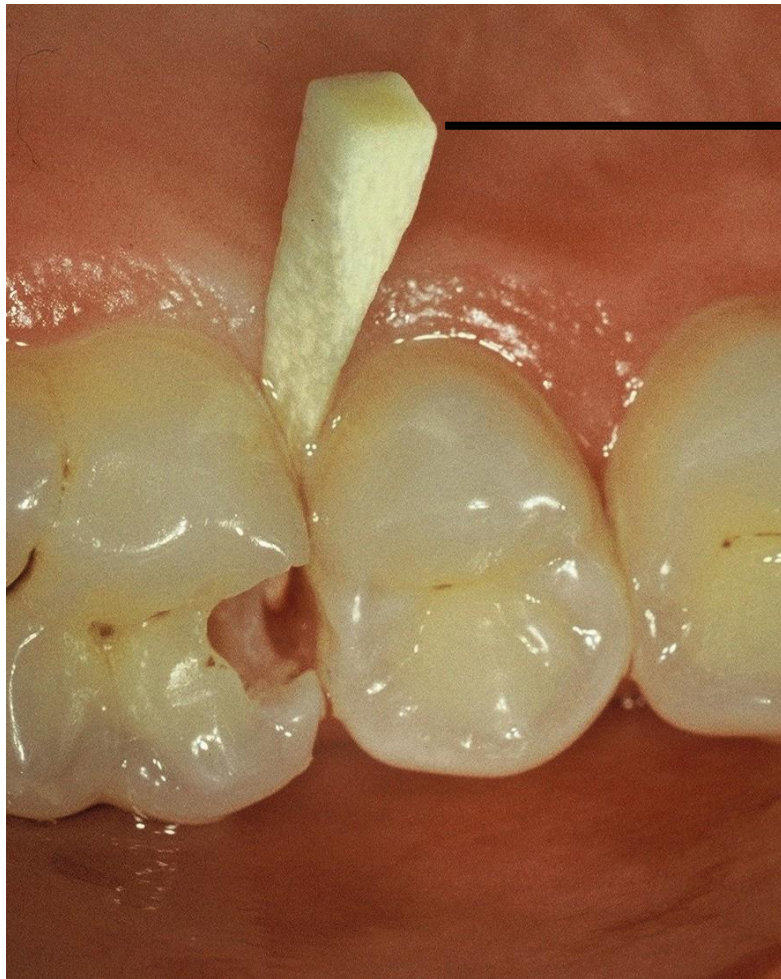



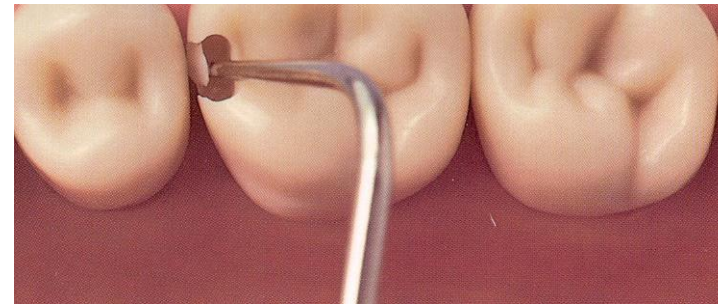


**Access to the cavity**

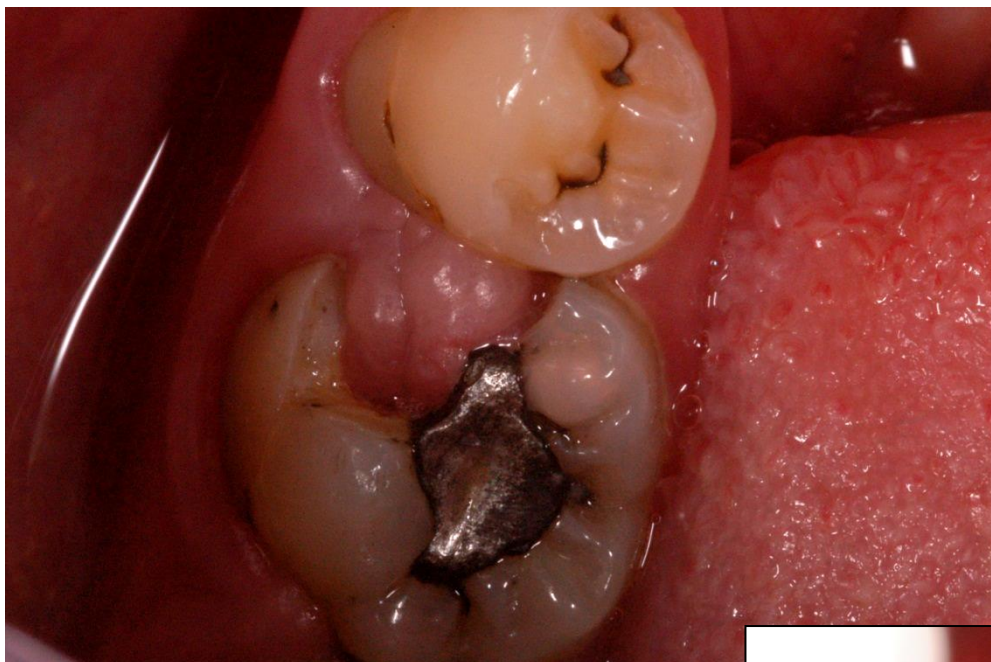




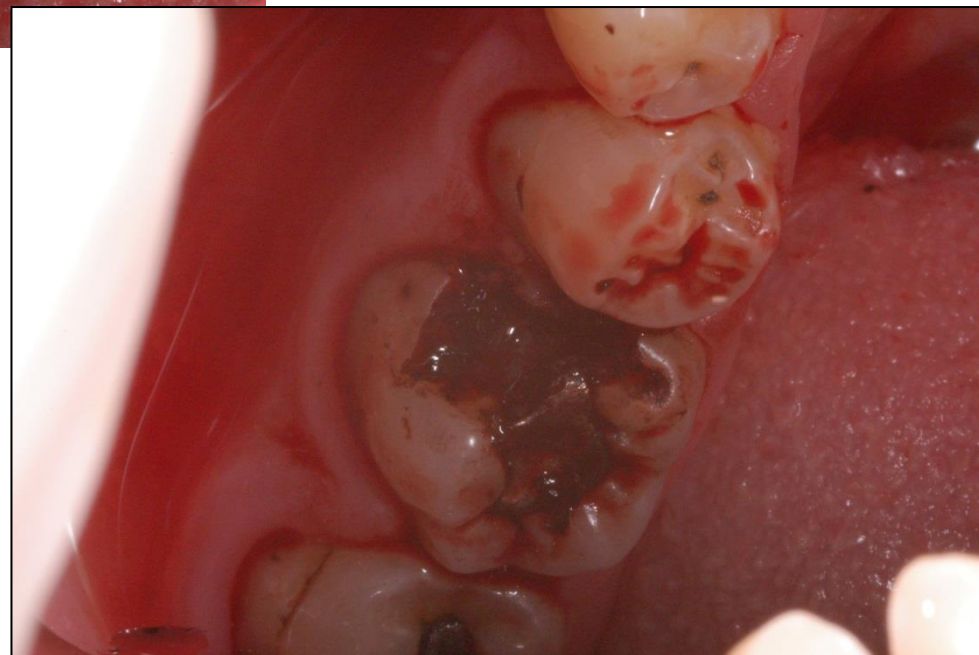Wooden wedge



Breaking the thin enamel layer out of the cavity



➤ Remove of the gingiva that grows into the cavity



# Cavosurface margin and extention for prevention

## *Proximal box:*

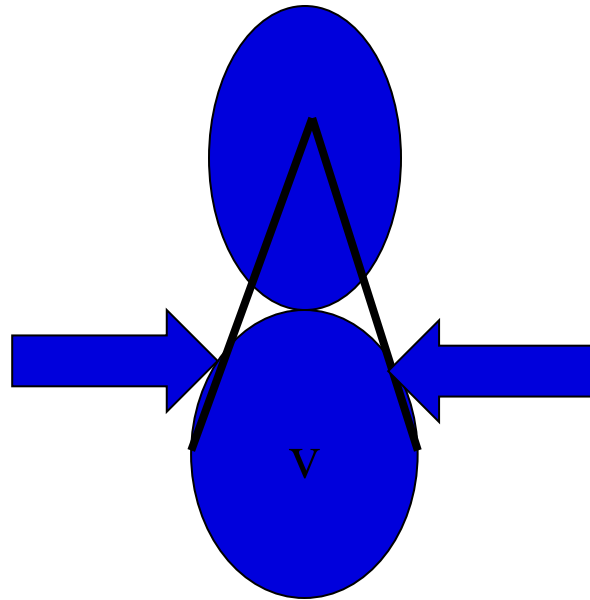
Vestibullary and orally – axial walls (the border between the oral/vestibular and proximal surface.

Below the free gingiva (0,5 mm)

## *Occlusal*

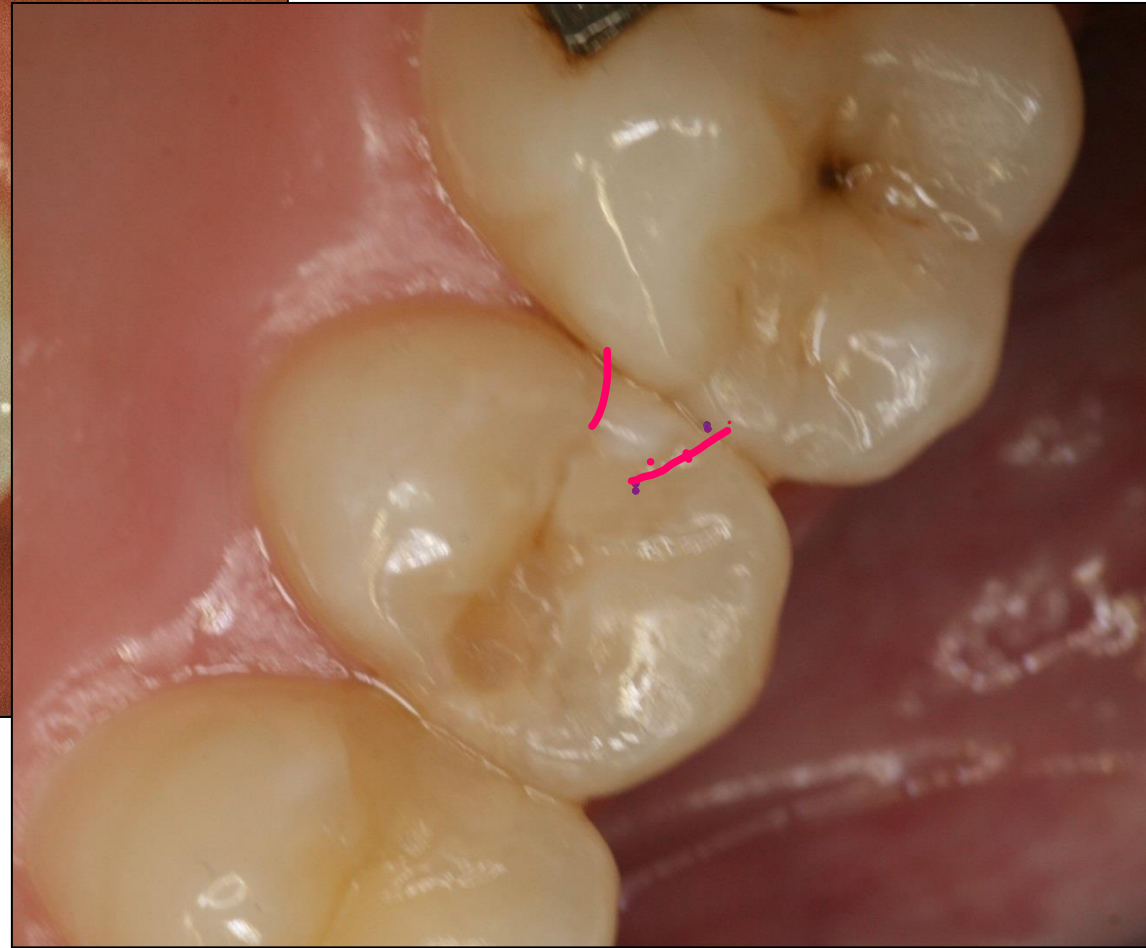
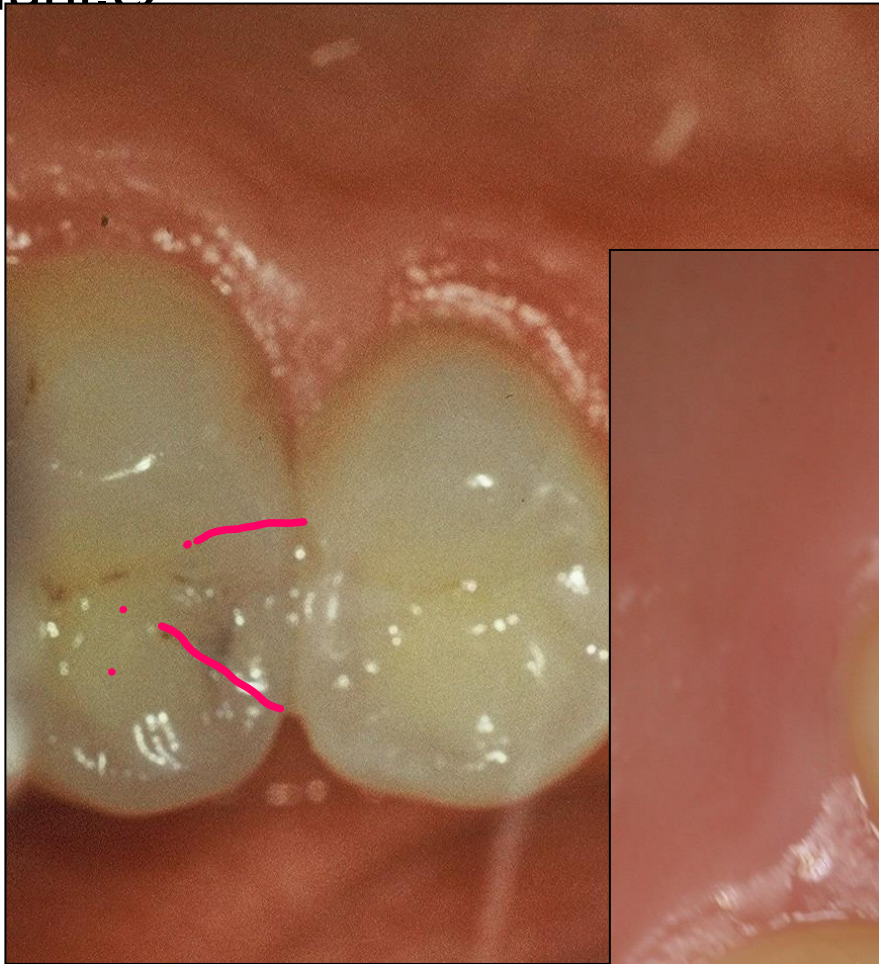Class I.

# American rule



Tangents from the middle of treated tooth to the next tooth – where these cross the treated Tooth there are borders of the preparation





Study the contact area

The contact point is made  
of the filling

The axial wall is 0,5 mm vestibular resp. orally  
from the contact point

# Retention

➤ Occlusal cavity

➤ Undercuts

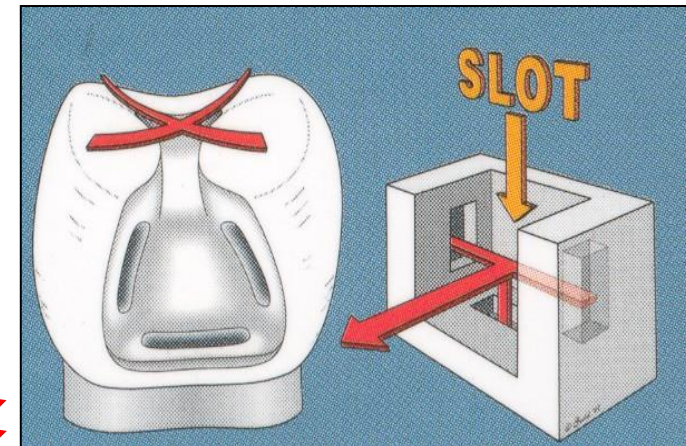
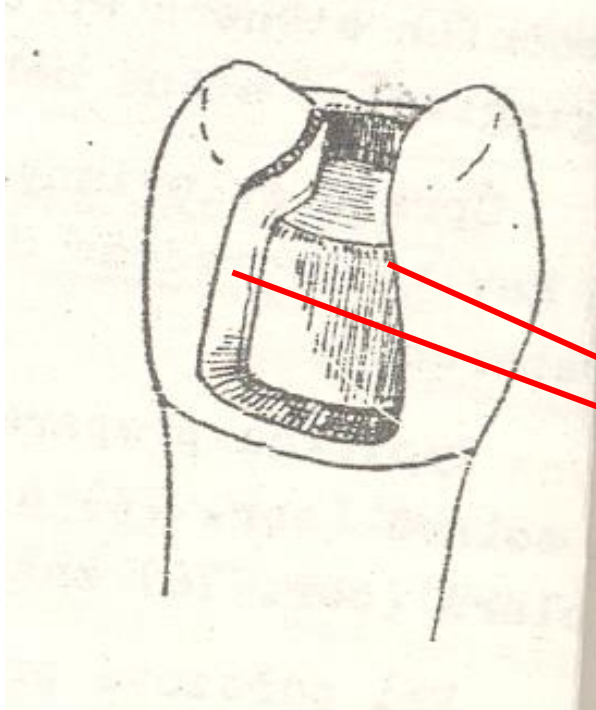
➤ Grooves

## Proximal cavity – box

Slight divergency of axial walls

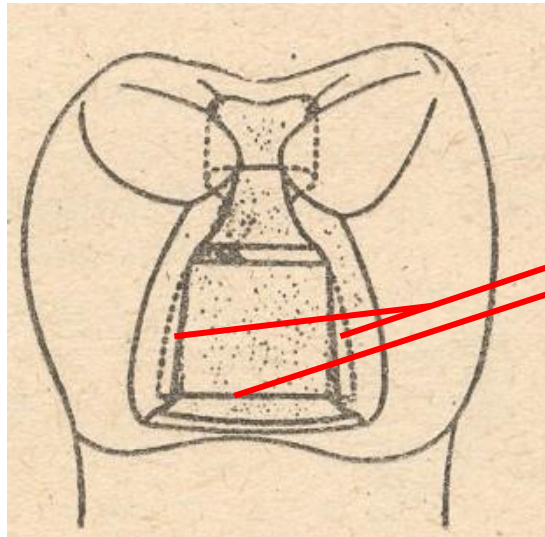
Gingival wall follows the cementsoenamel junction

Gingival wall is below free gingiva



Autoretention

Grooves



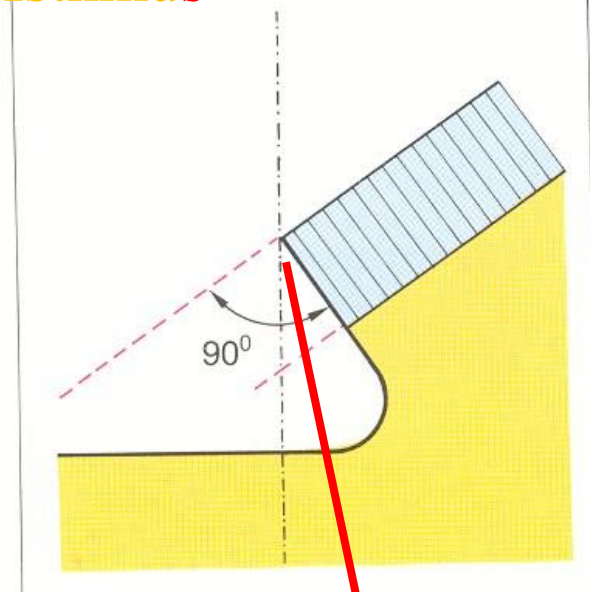
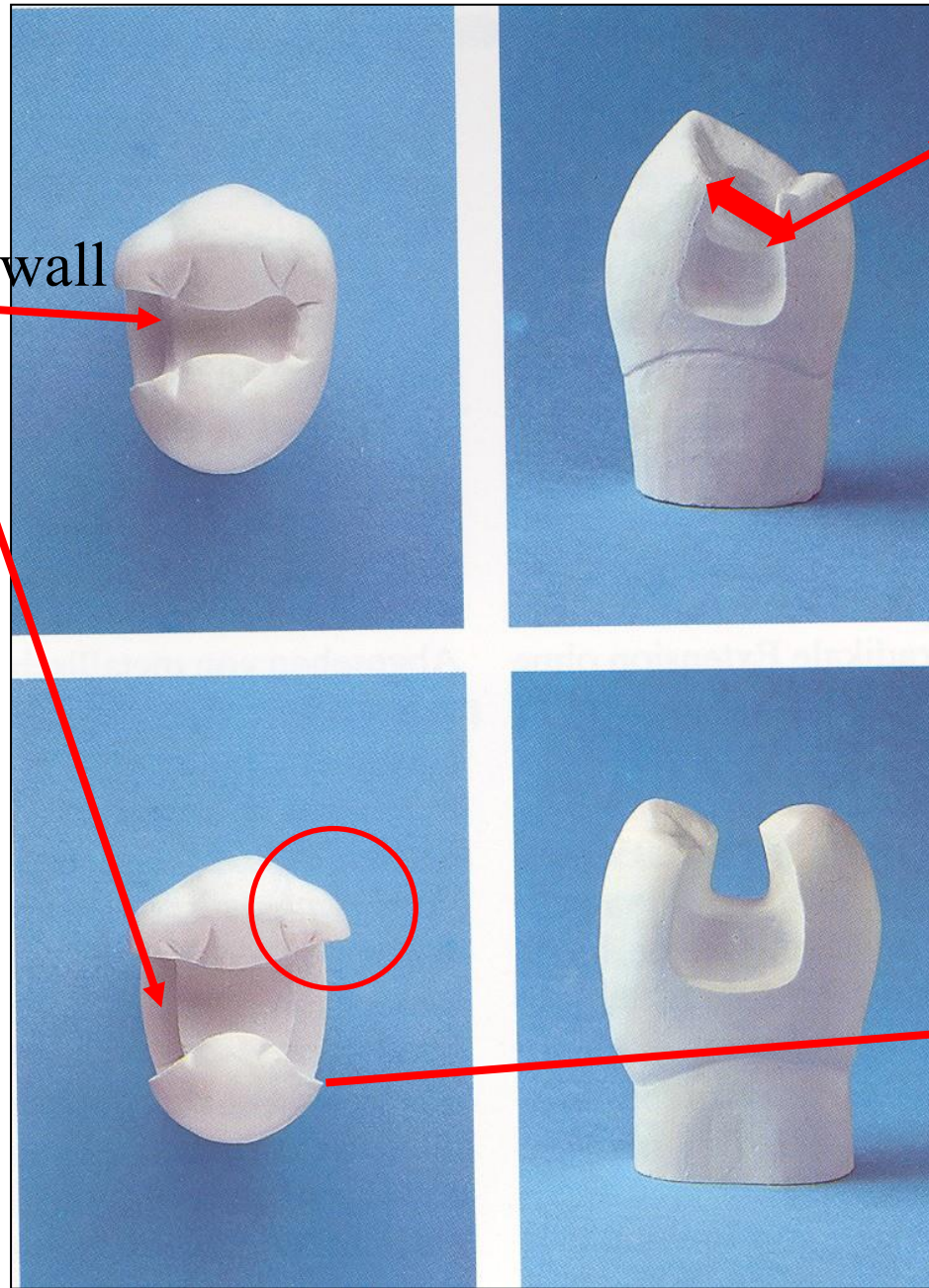


# Resistancy

- No undermined enamel
- No sharp edges
- Isthmus is  $1/3 - 1/4$  intercuspidal distance
- Angle between axial and gingival wall:  $90^\circ$ , or  $85^\circ$
- Width of gingival wall is 1 mm at least
- Thickness of the filling 2 – 4 mm (4mm if cusp replacing)

Gingival wall

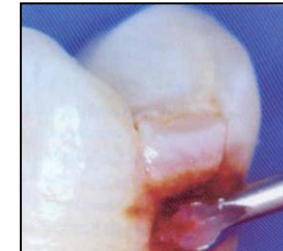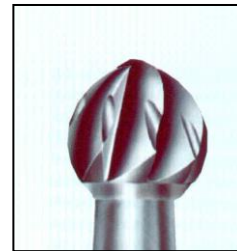
Isthmus



Cavosurface angle

# Excavation of carious dentin

Rounded bur

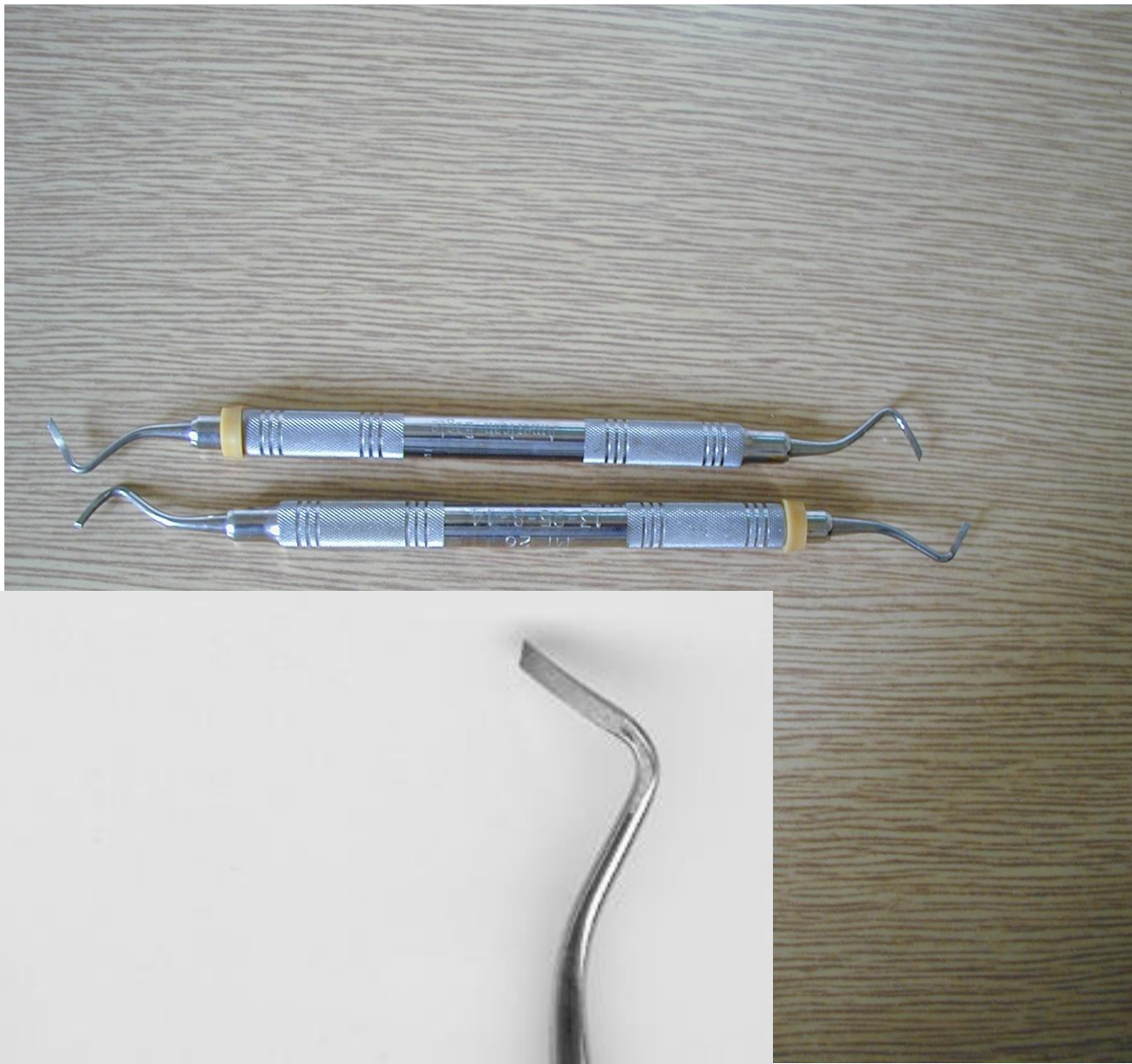


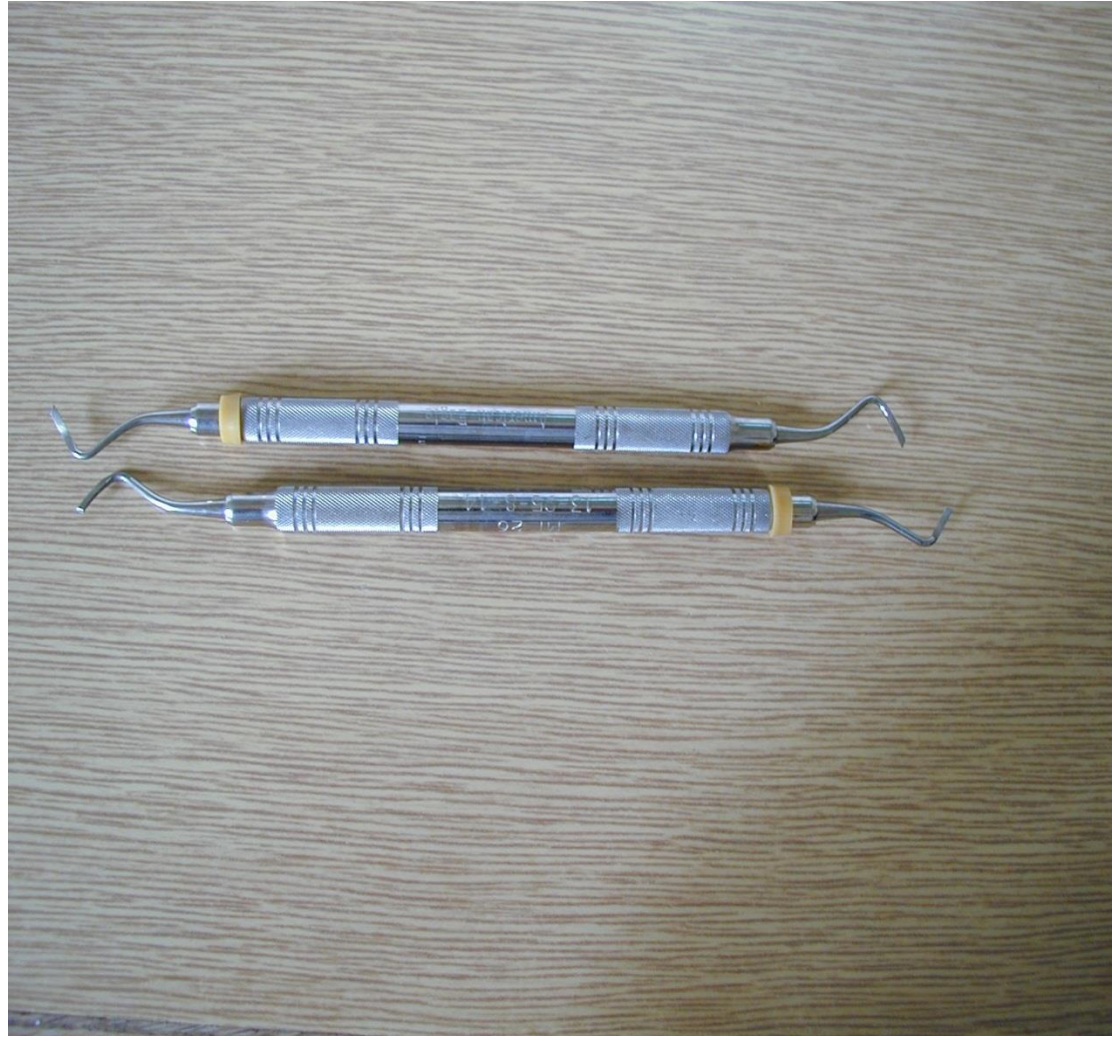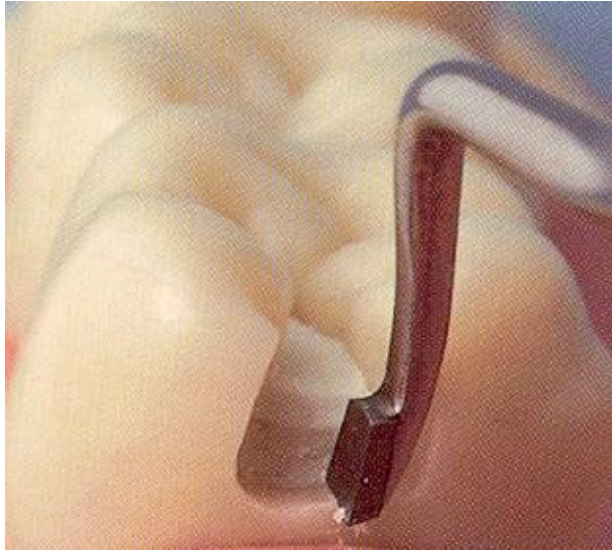
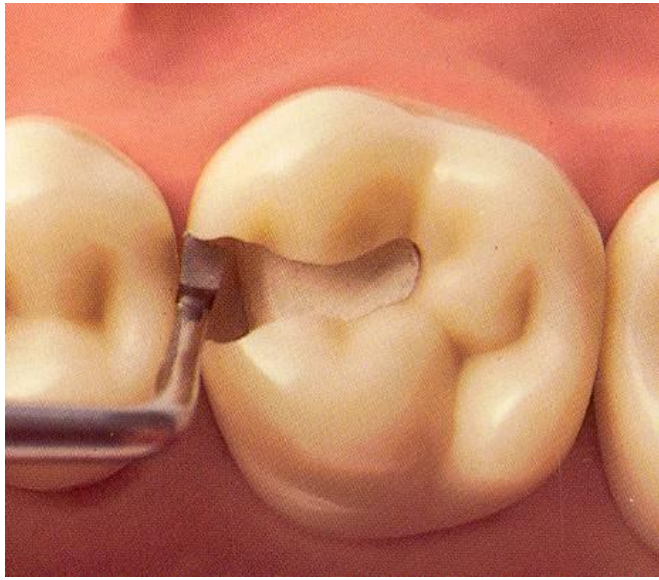
*(Caries Detector, Kuraray,  
Japonsko; Caries Marker,  
VOCO, Německo)*

# Finishing of the walls of the cavity

- Red coded diamond bur
- Chisel on the gingival wall (if in enamel)







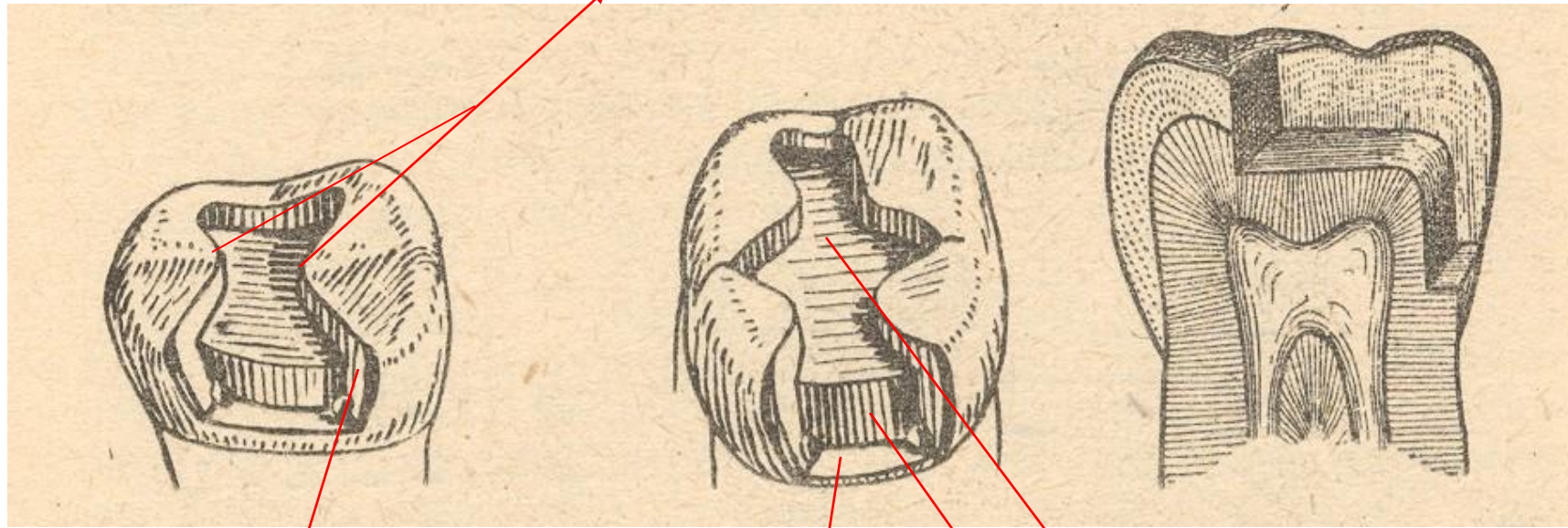




# Final check

➤ Goog light, mirror

Isthmus



Axial wall

Gingival wall

Pulpal wall

# Matrix placement

➤ Matrix primarily is used when a proximal surface is to be restored

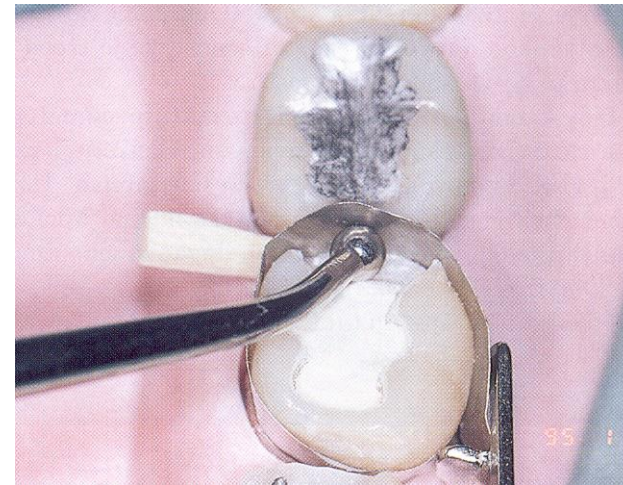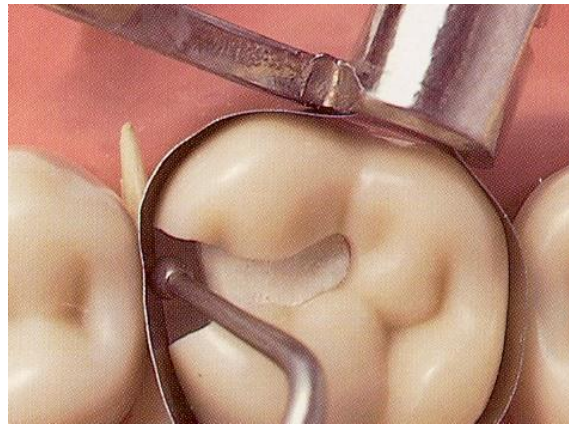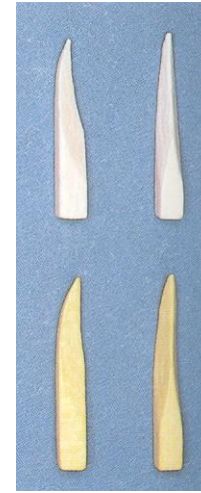


The objectives:

- Provide proper contact
- Provide proper contour
- Confine the restorative material
- Reduce the amount of excess material

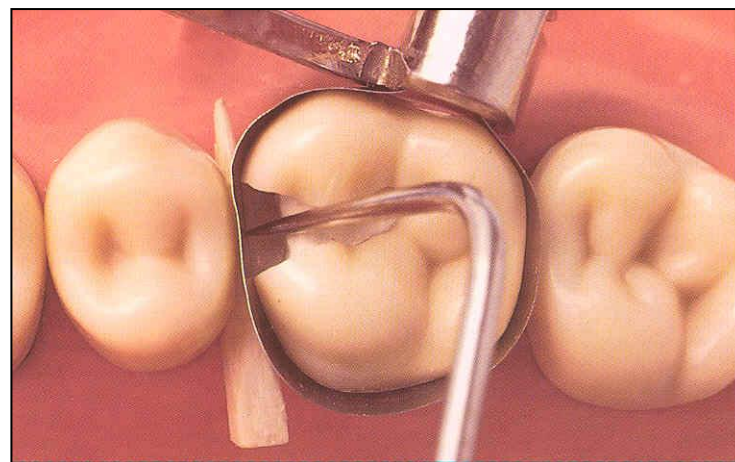
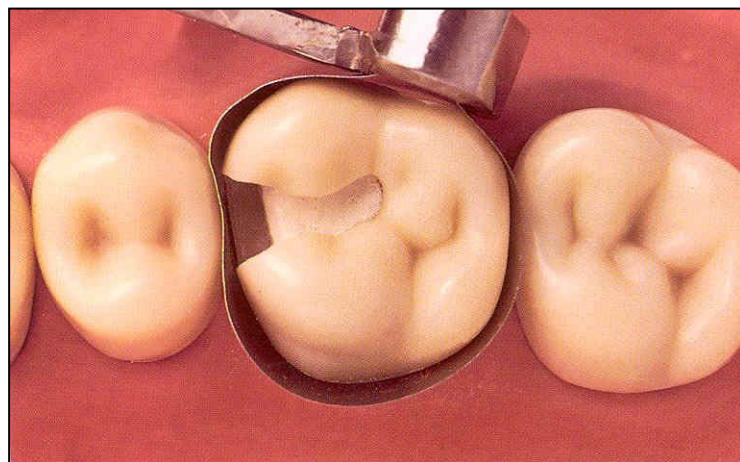

# Matrices

- Ivory I retainer Ivory 1
- Hawe Neos retainer Ivory 8
- Tofelmire matrix and retainer





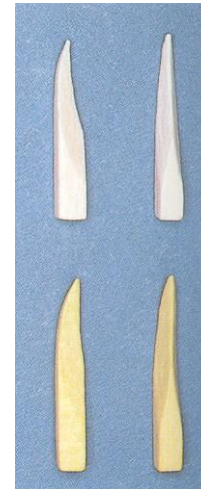




# Wedges

## ➤ Wooden wedges

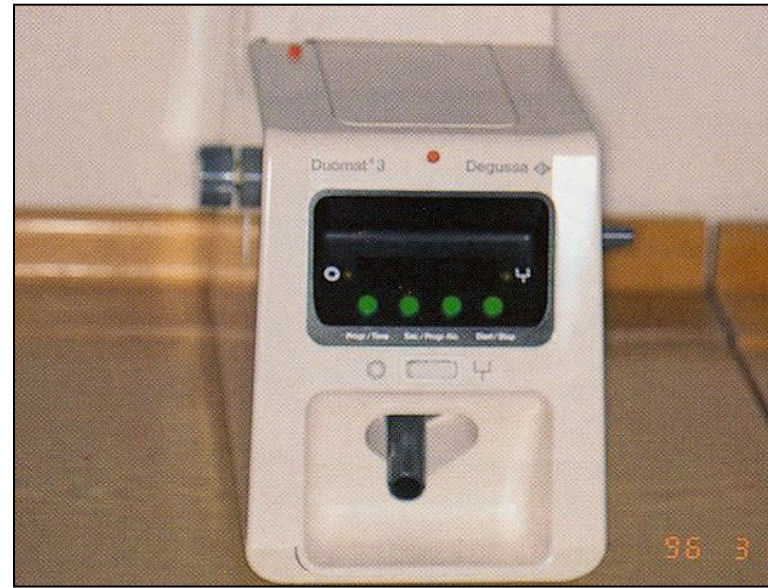

- tighten the matrix band
- compress the gingiva
- separate the teeth



# Wedging

- Slip the matrix band over the tooth (apical to the gingiva margin – 0,5, - 1 mm)
- Tighten the matrix, check it with probe
- Place a wedge
- Turn the retainer  $\frac{1}{4}$  counterclockwise
- Contour the band





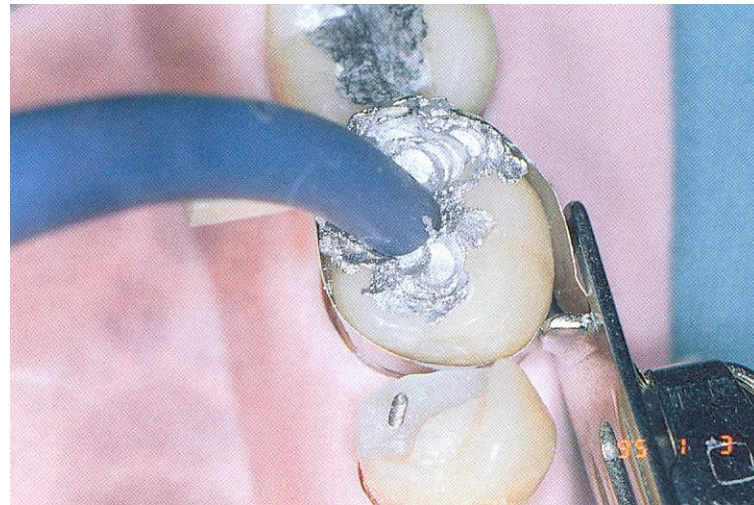
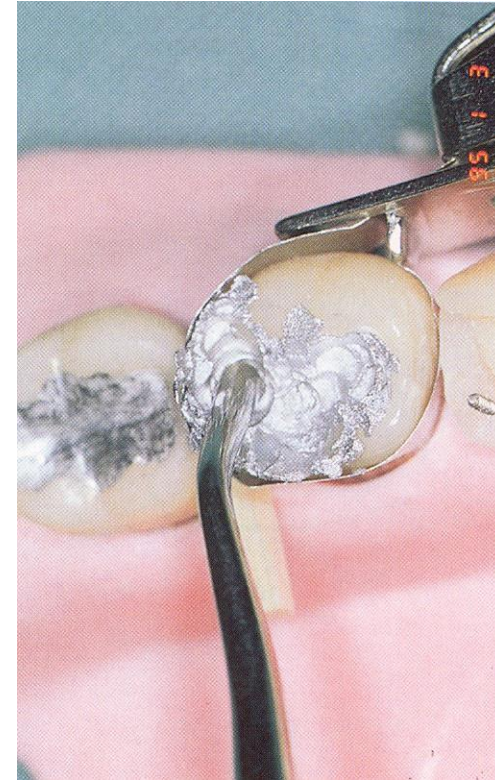
## Amalgamators

# Condensation of amalgam

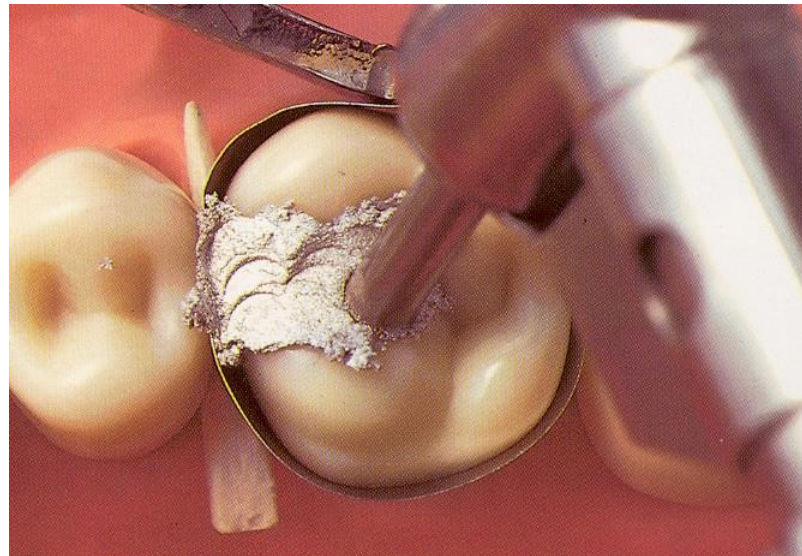
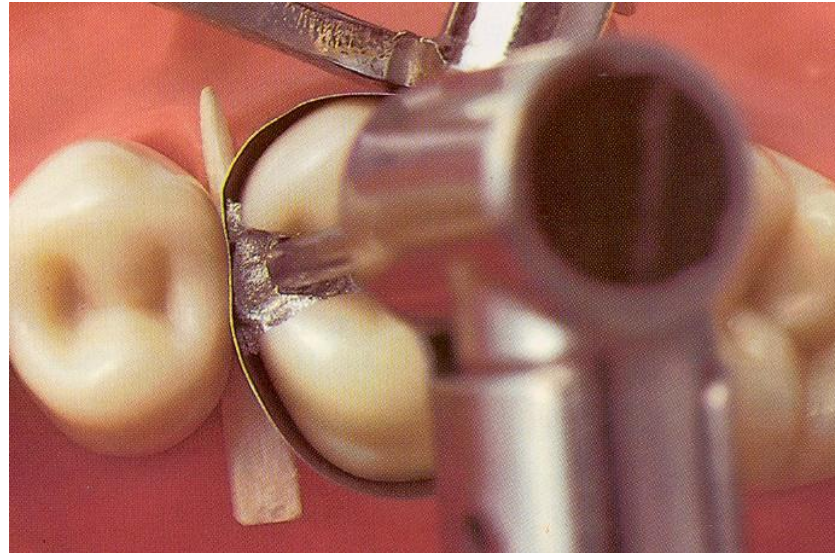
- Condensor – with the straight front
- Power driven condensation

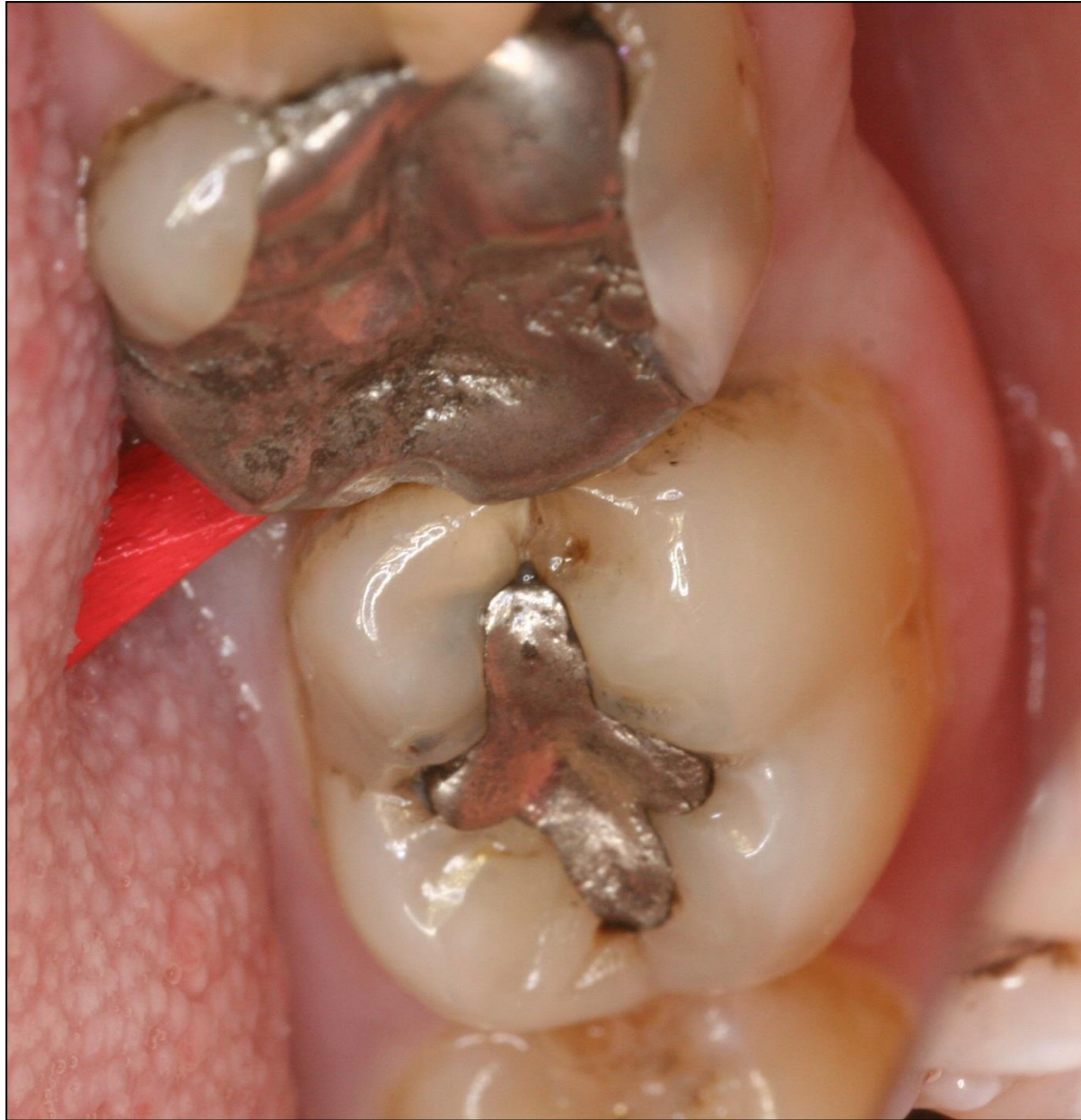How big should the front be?

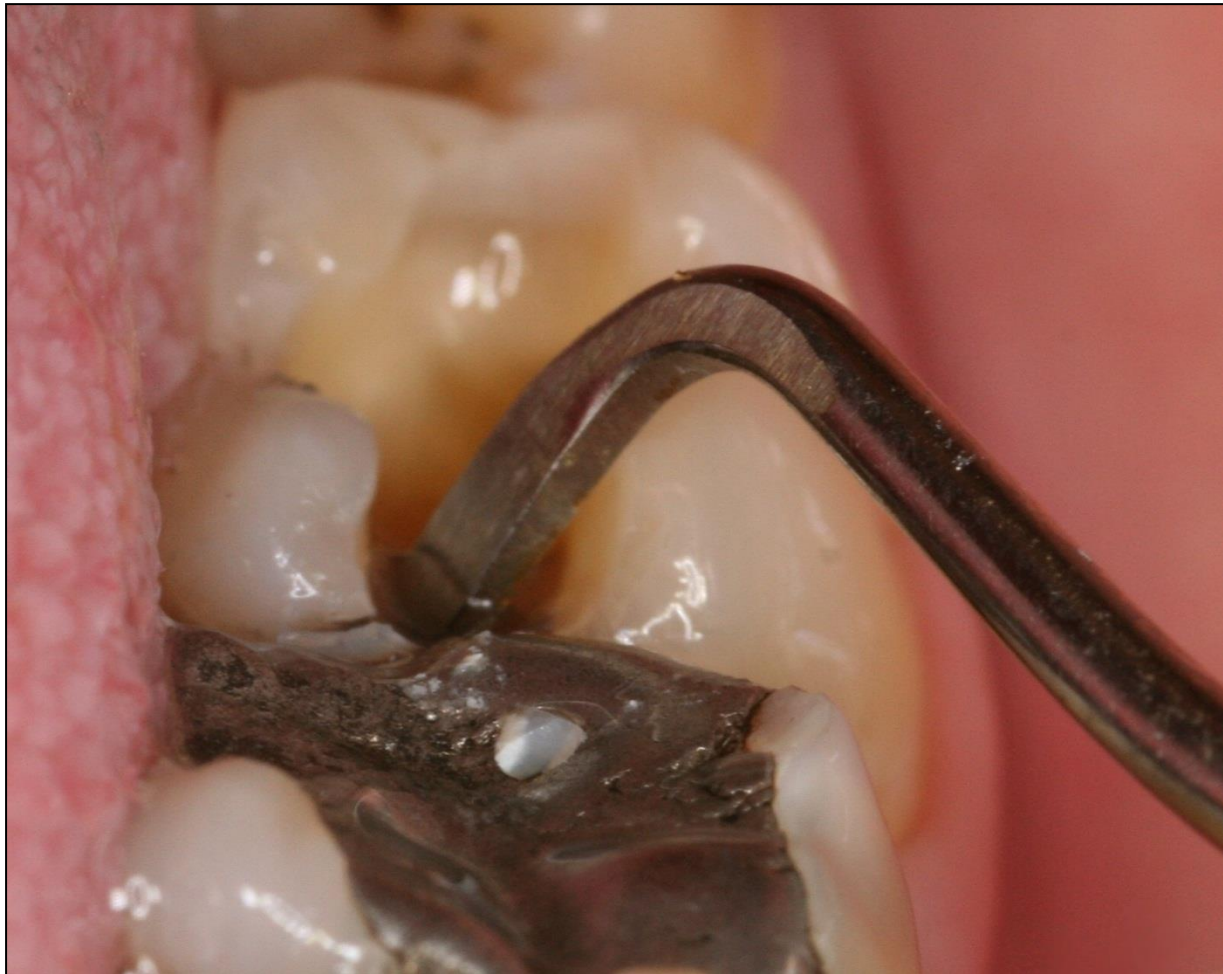




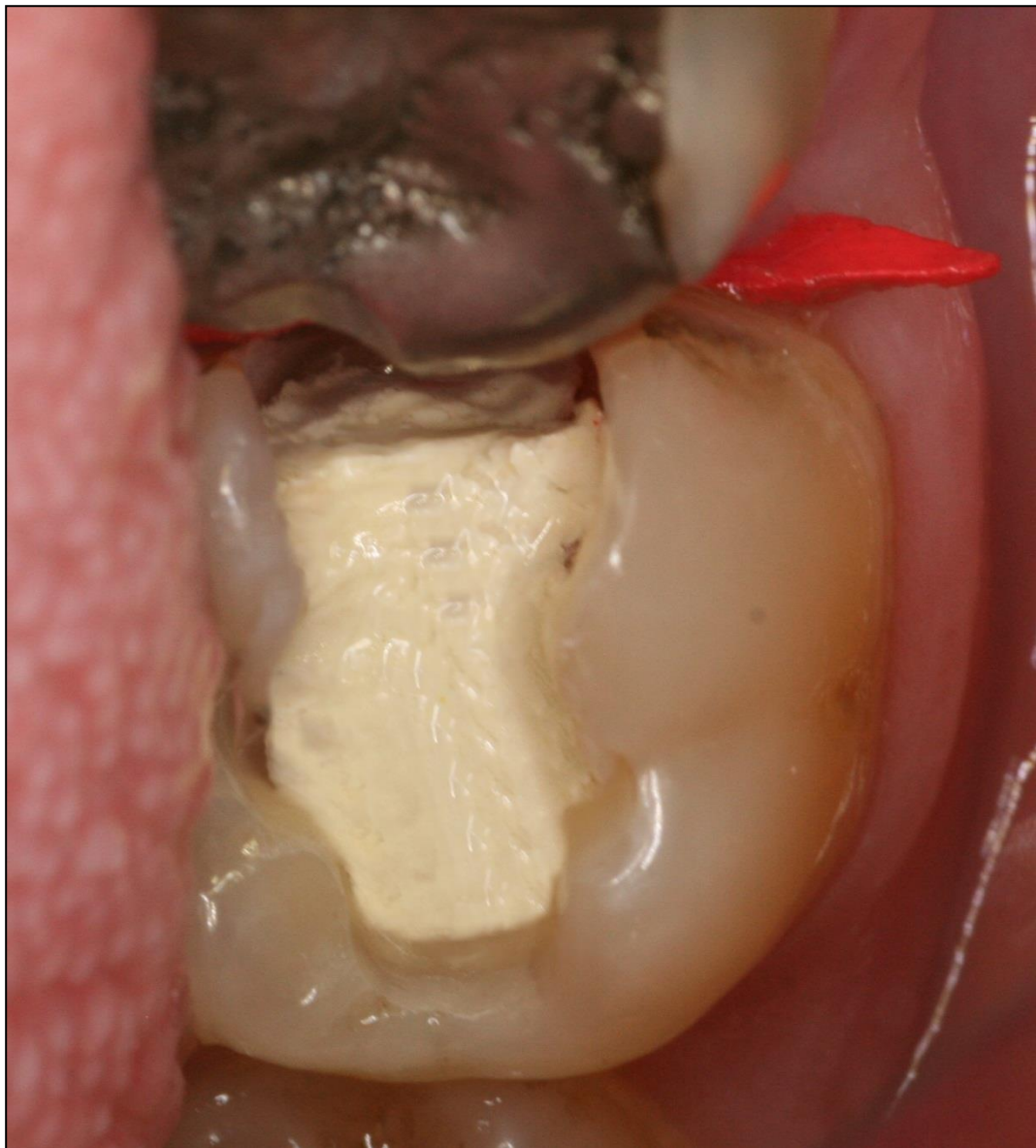


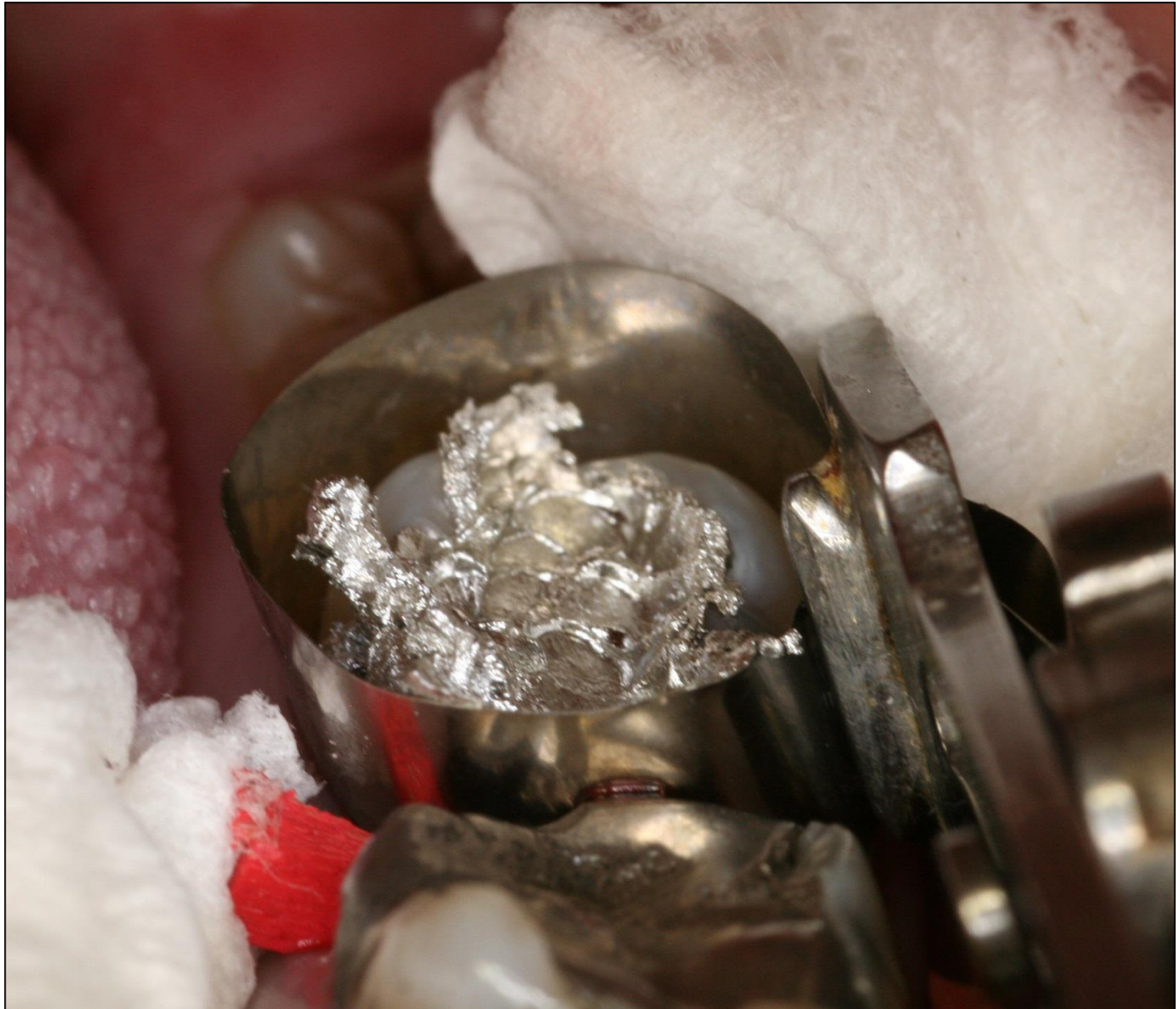




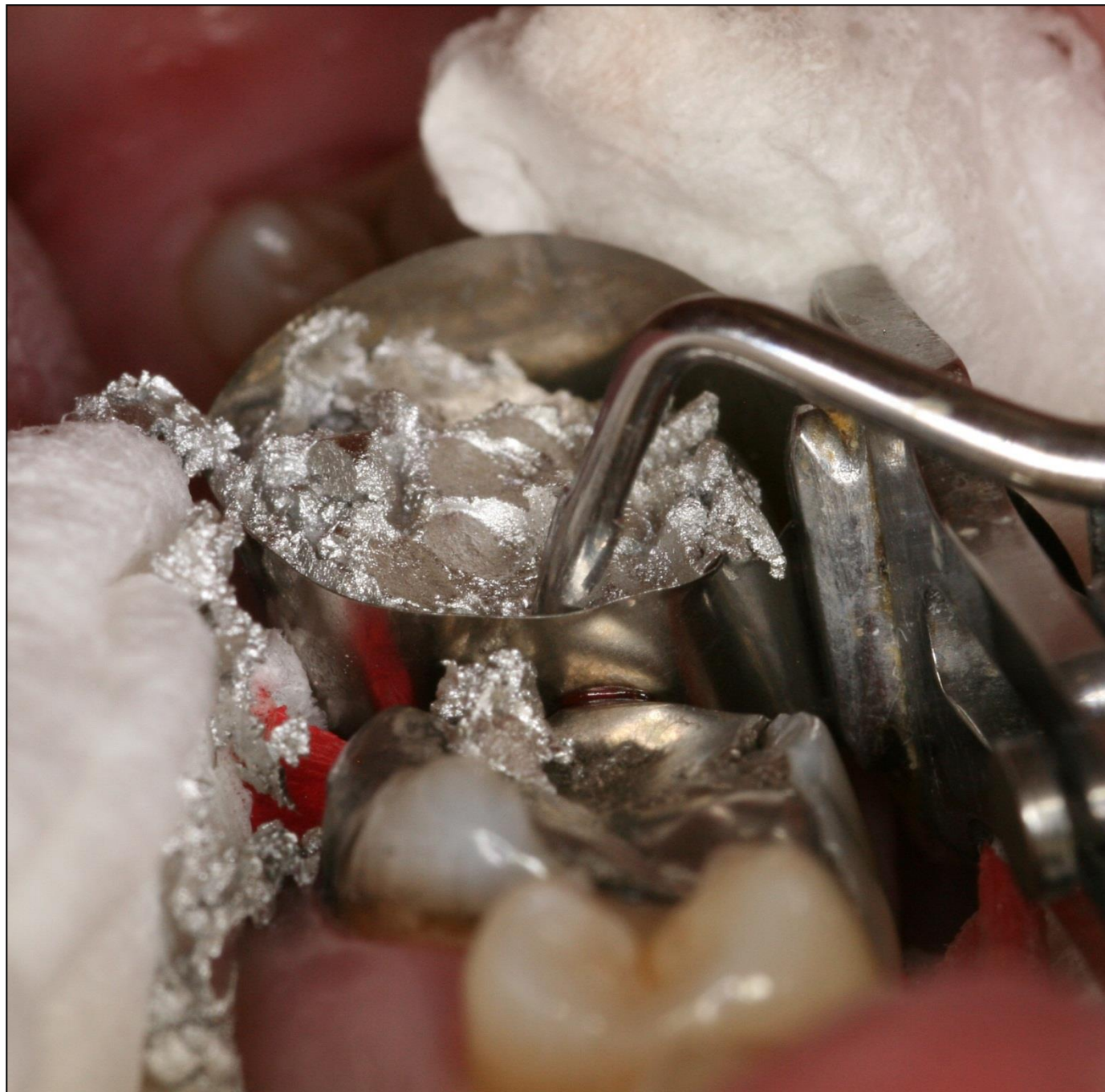




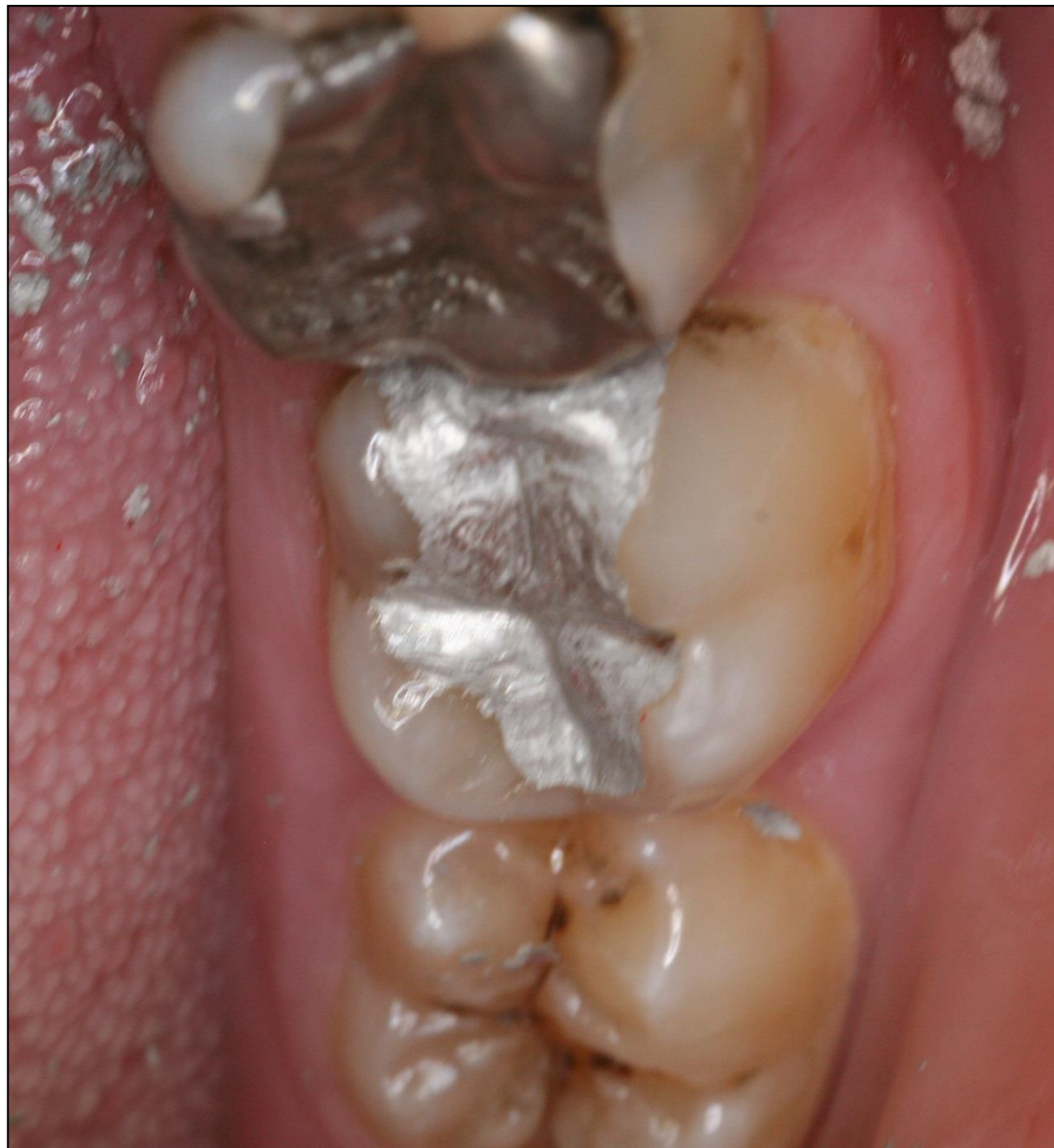



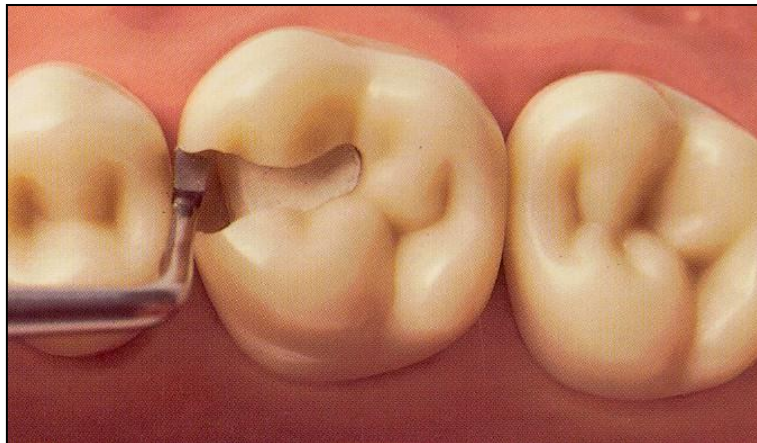
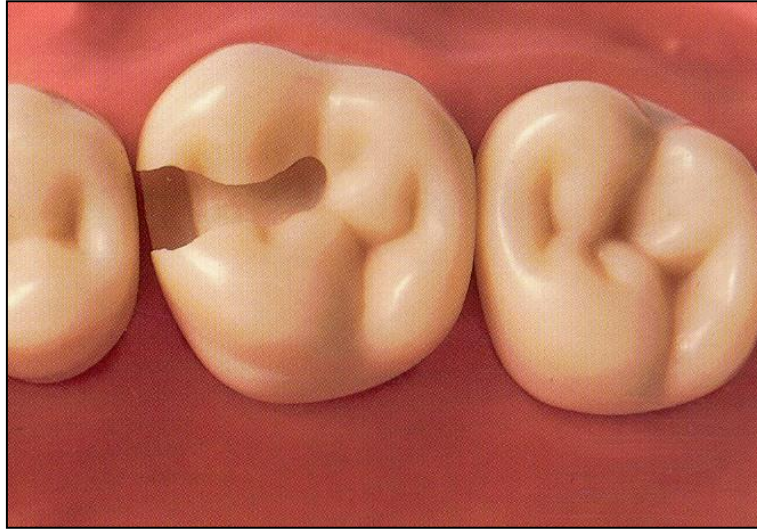




# Base

- Zinkoxidphosphate cement ○
- Zinkoxidkarboxylate cement x
- Glass ionomer cement x
- Zinkoxideugenol x

On pulpal walls only!



The base must be hardened

# Instruments

- Preparation

- Filling

- Finishing and polishing

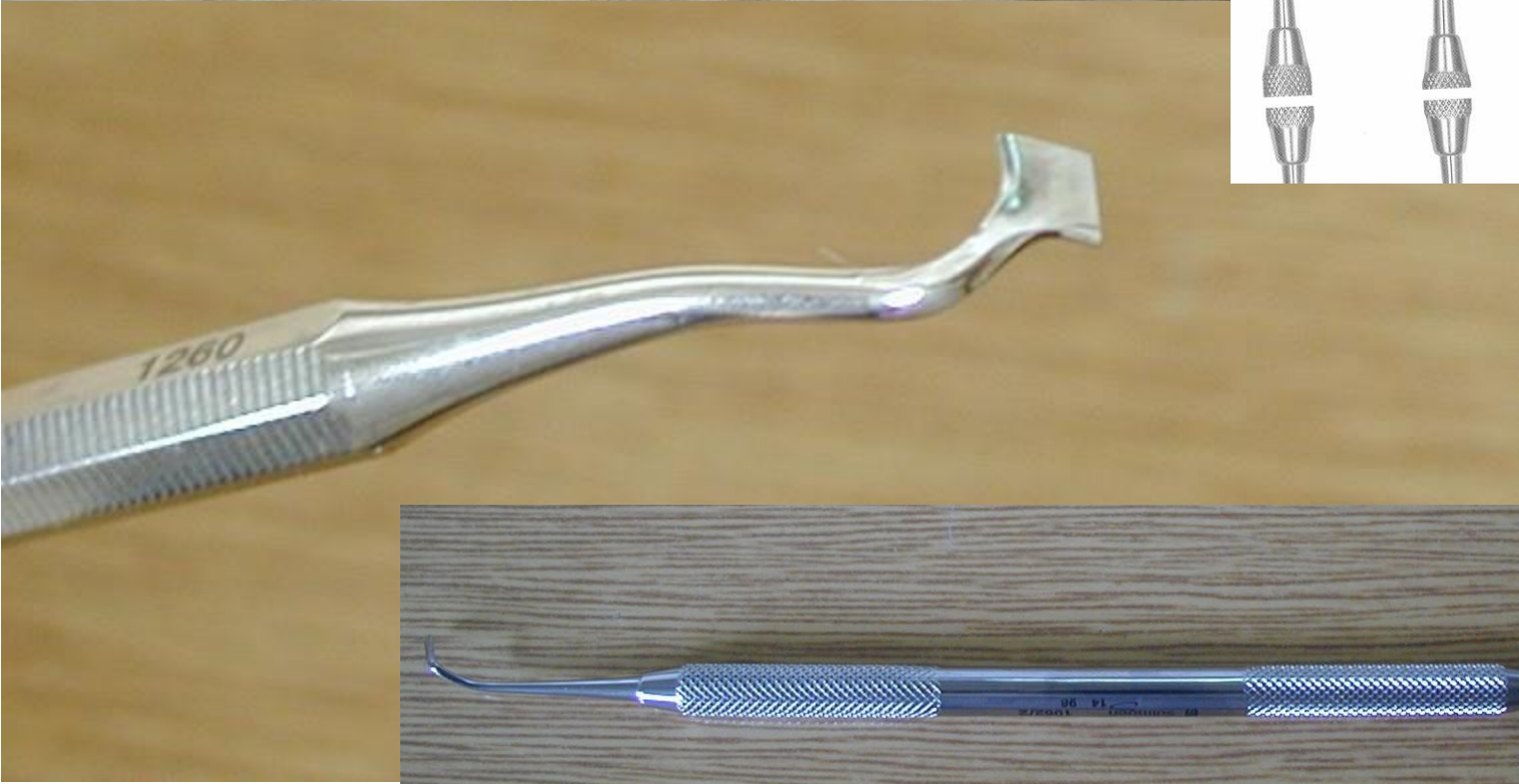
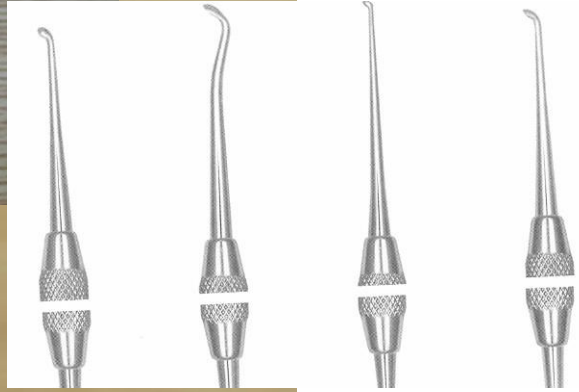Condensor with  
the straight front



# Frahm








# Sapin



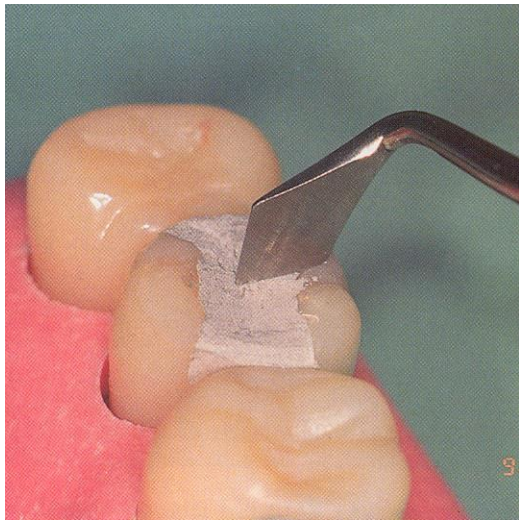
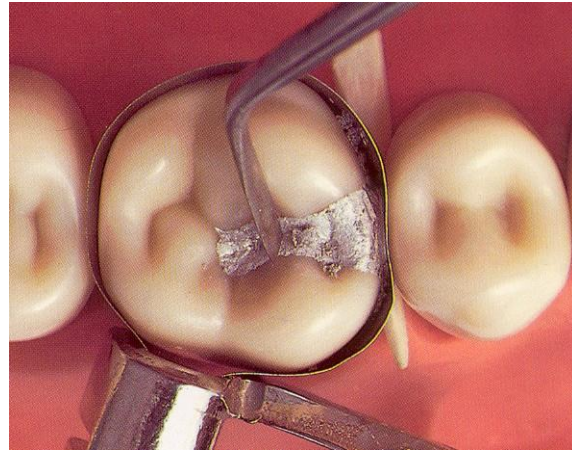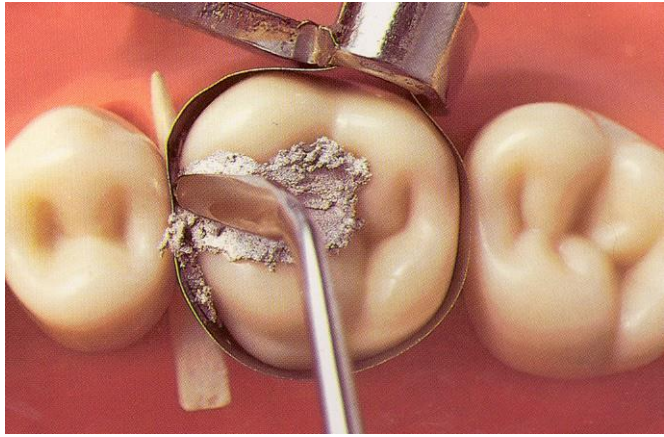
# Discoid-cleoid



# Amalgam carrier

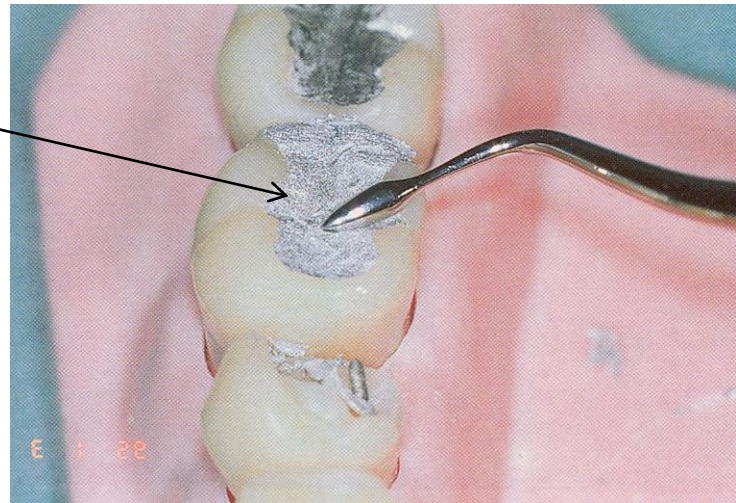






Carving

Burnishing





# Indications: Amalgam

- Moderate to large restorations
- If there is heavy occlusal loading (alternative onlay)
- Oral hygiene is not optimal (alternative dense glassionomer as middle term temporary)
- When the proper isolation is not possible
- Price

# Contraindications: Amalgam

- Aesthetically prominent areas of posterior teeth
- Small - moderate classes I. that can be well isolated

# Indications: Composite

- Aesthetically prominent areas of posterior teeth
- Small - moderate classes I. that can be well isolated
- Good level of oral hygiene is necessary

# Contraindications: Composite

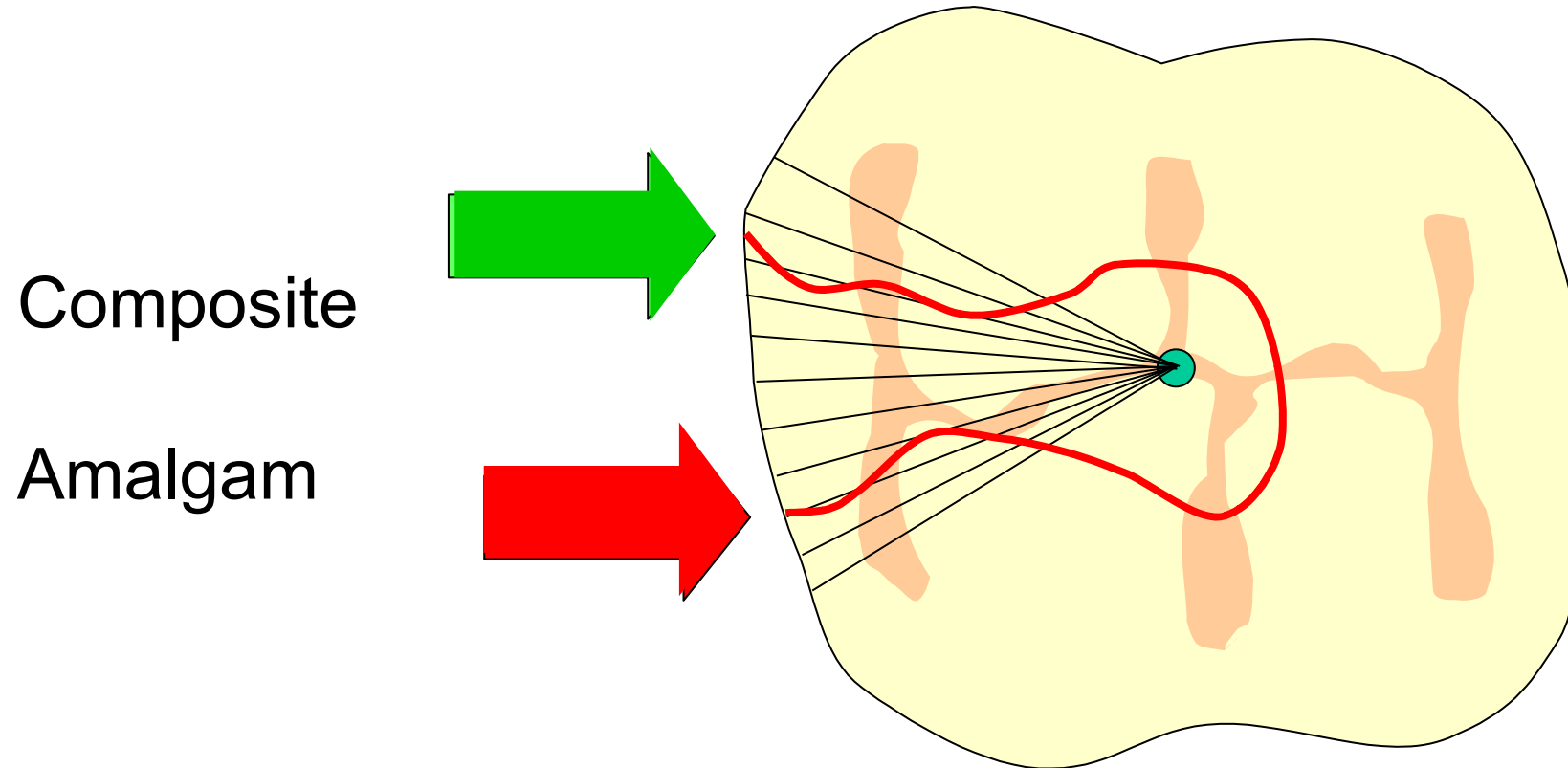
- Moderate to large restorations
- Restorations that have heavy occlusal contacts
- Restorations that cannot be well isolated
- Restorations that extend onto the root surface (subgingival – margin relocation or lengthening of the crown is necessary)
- Abutment teeth for removable partial dentures

# Composite - possibilities

- Conventional cavity (occlusal and proximal cavity)
- Adhesive slot
- Tunnel preparation
- Cusp replacement – direct, indirect.

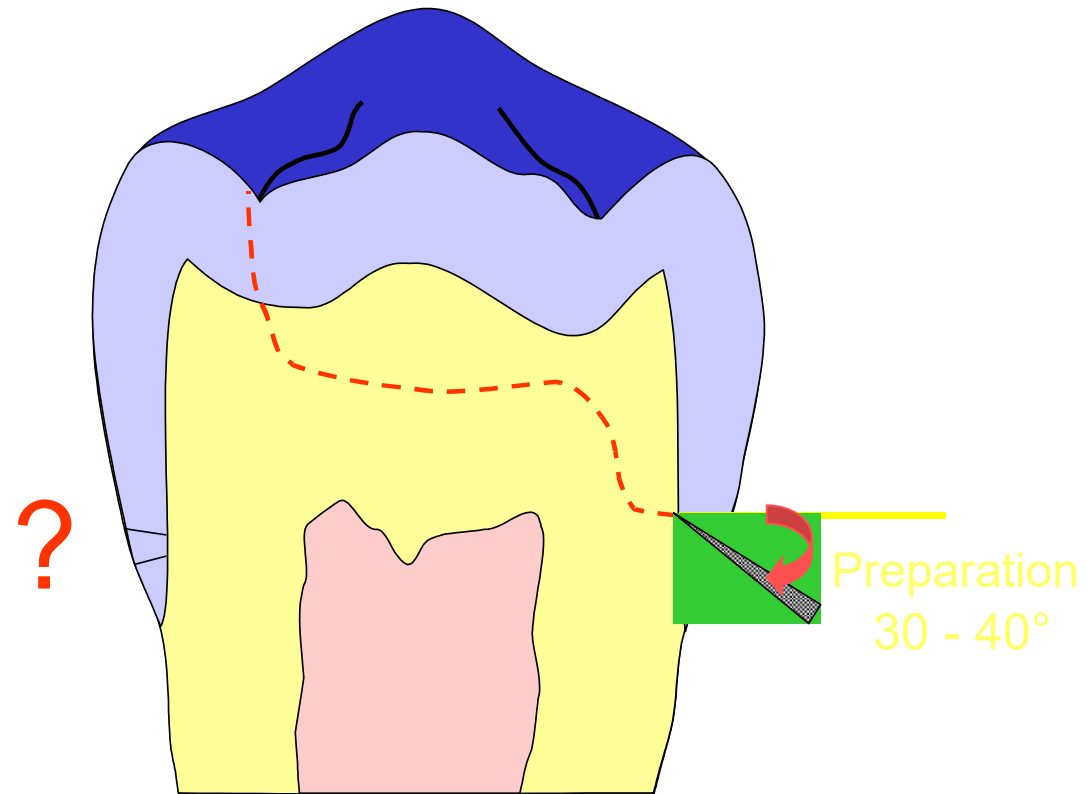


# Interproximal borders



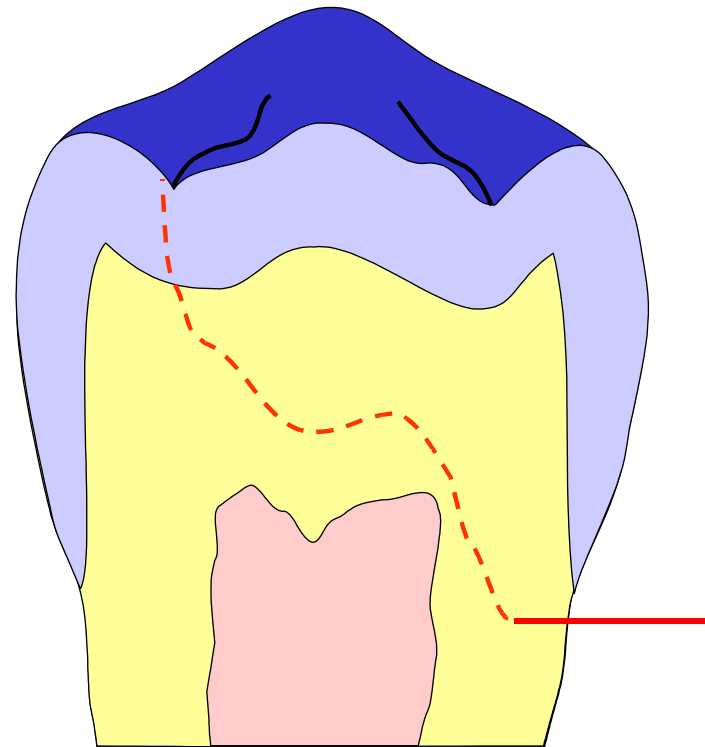
# Cervical borders

In enamel



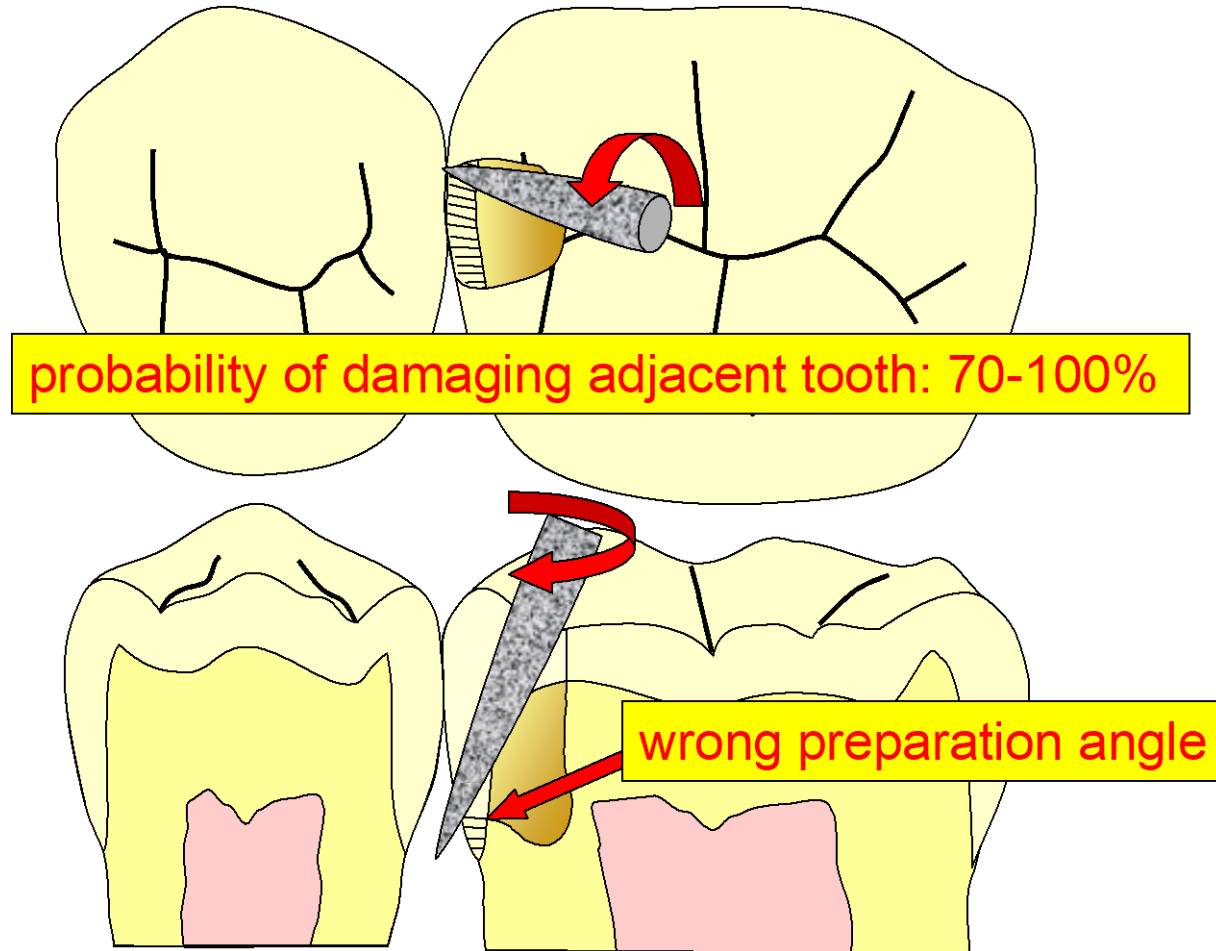
# Cervical borders

In dentin

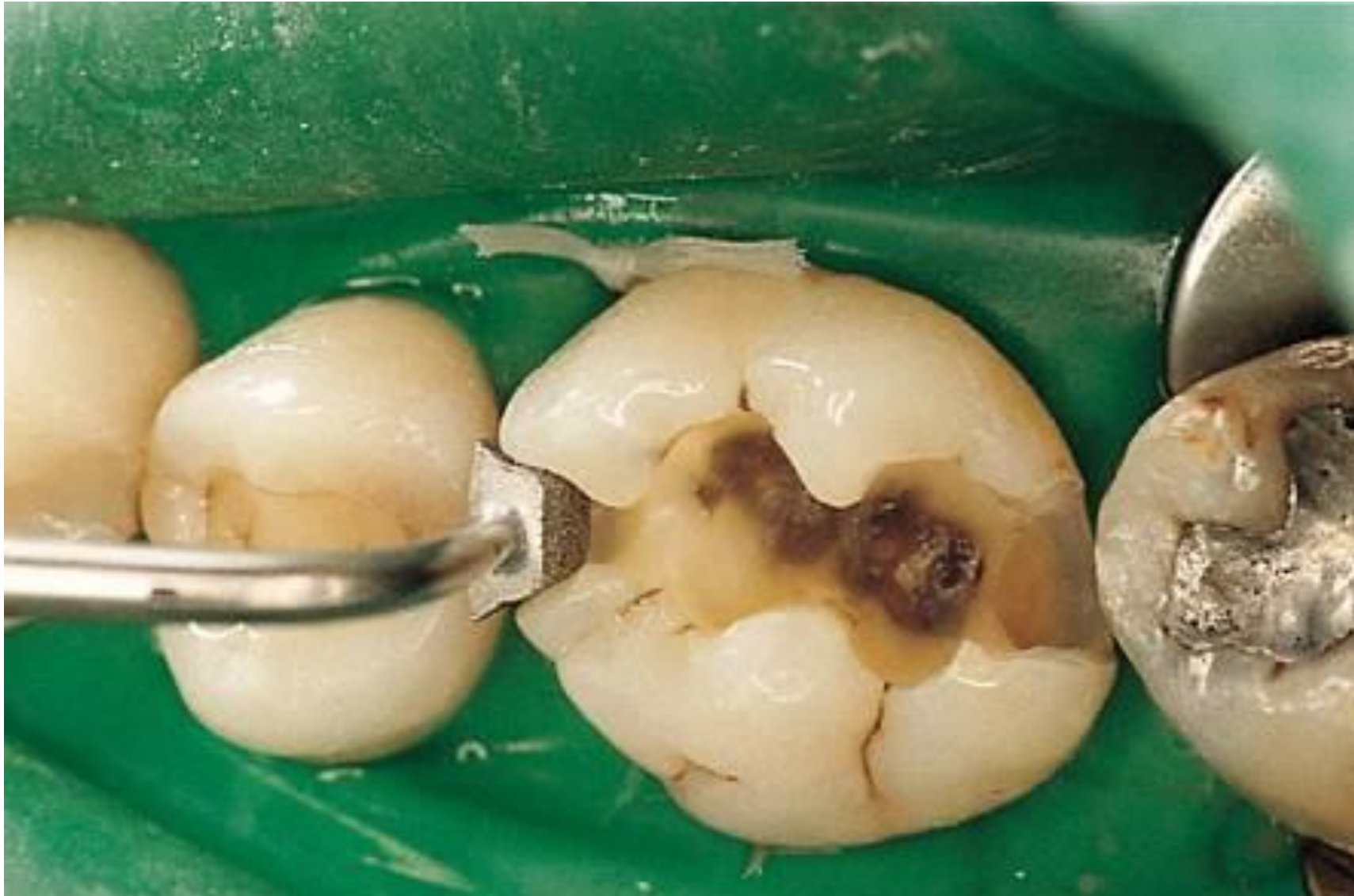

No bevel

# Preparation technique



# Oscillating instruments





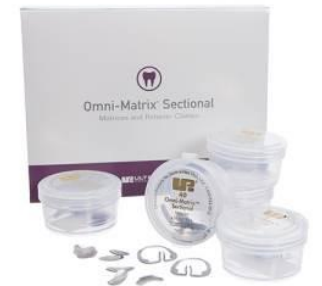# Class II. and contact point

- Matrix band + matrix retainer
  - Metal band (in primary teeth)

Without matrix retainer

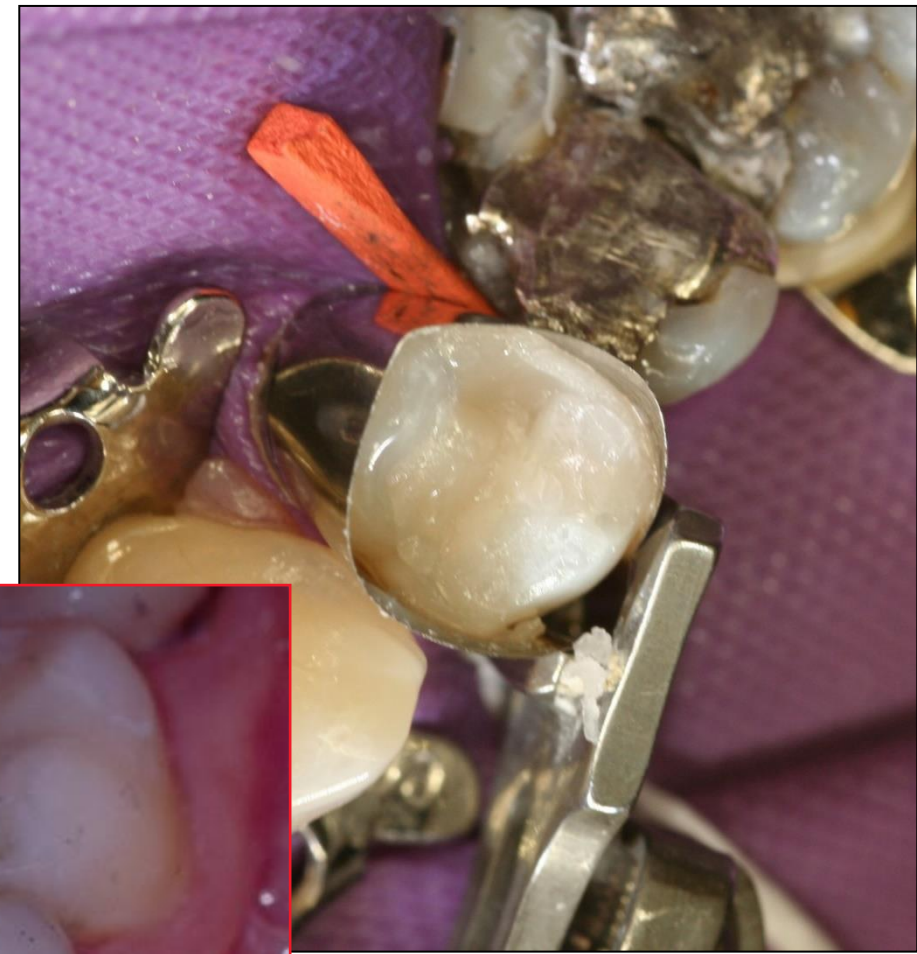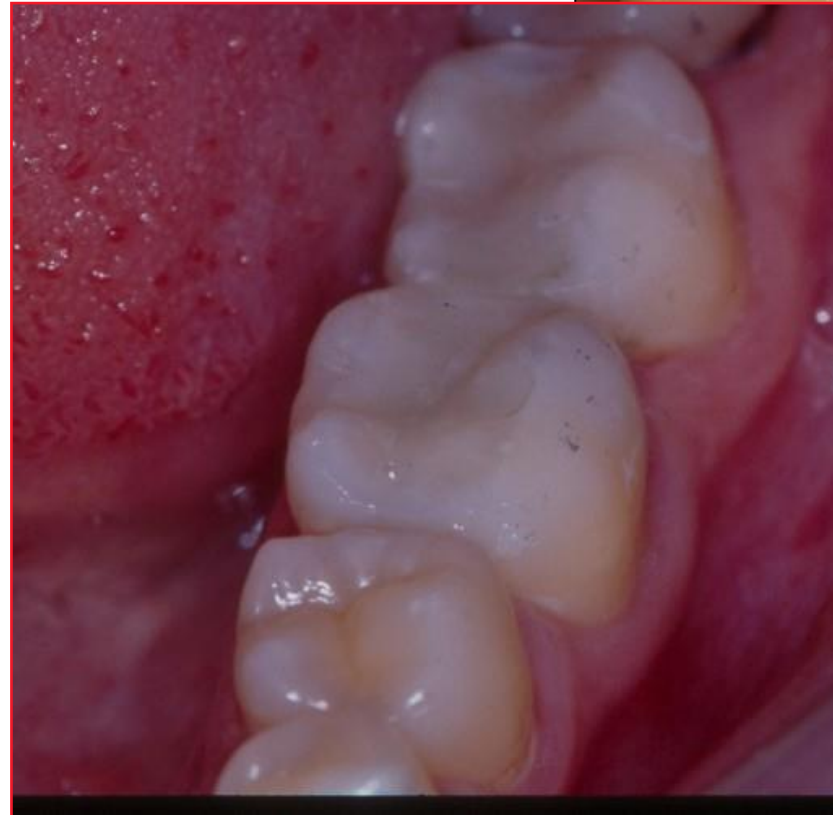Plastic band (polyester – e.g. Lucifix matrix)

Sectional matrices with separator

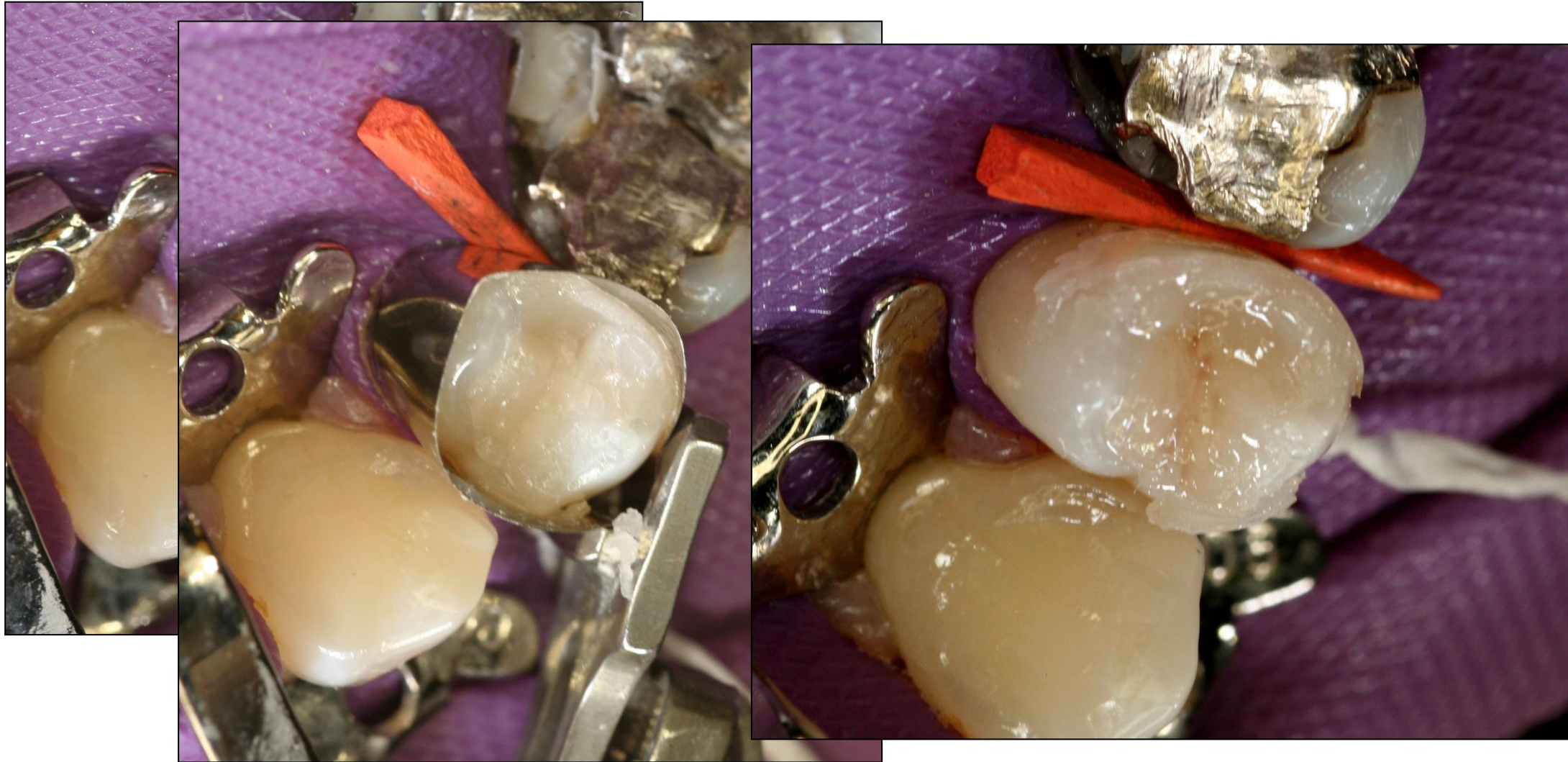

# Matrix band and matrix retainer

Contact point  
Contact area



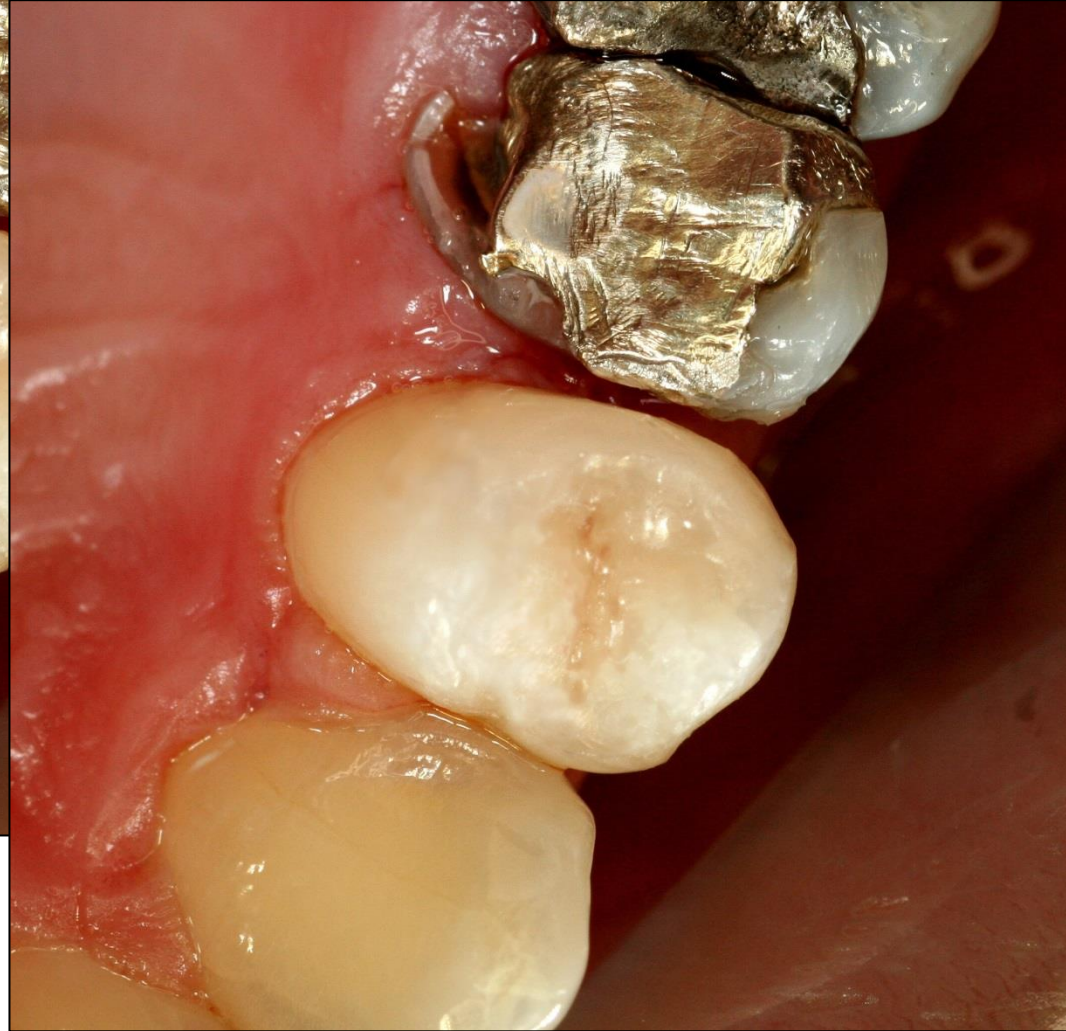
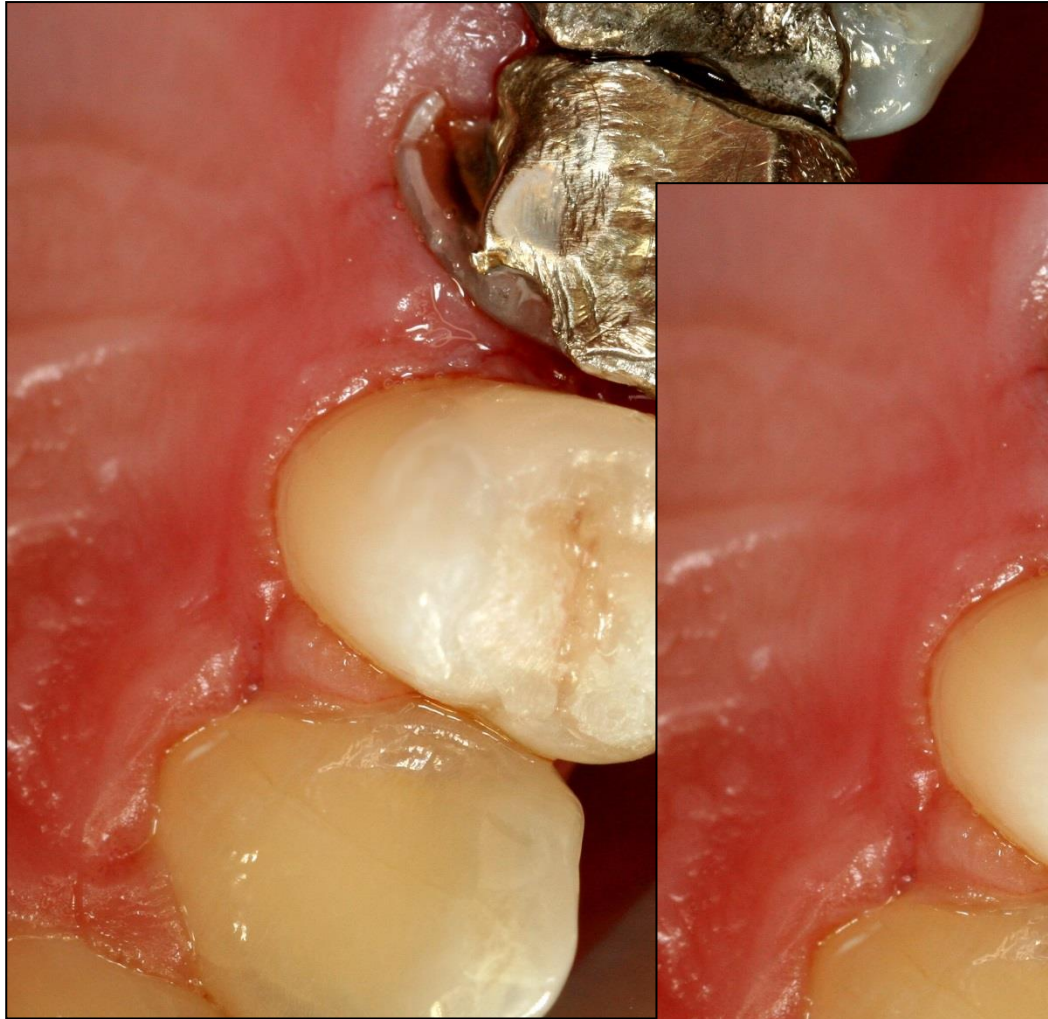


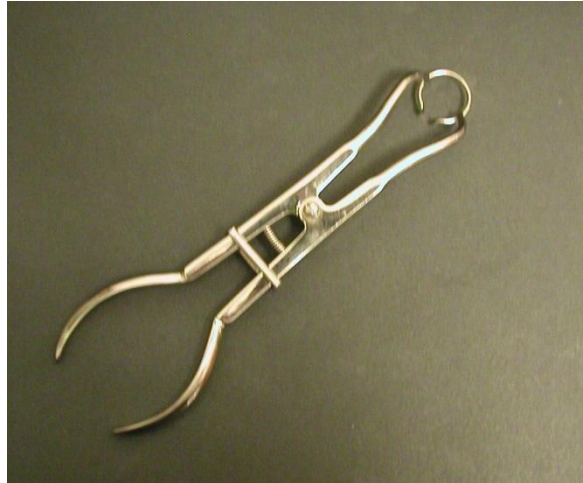
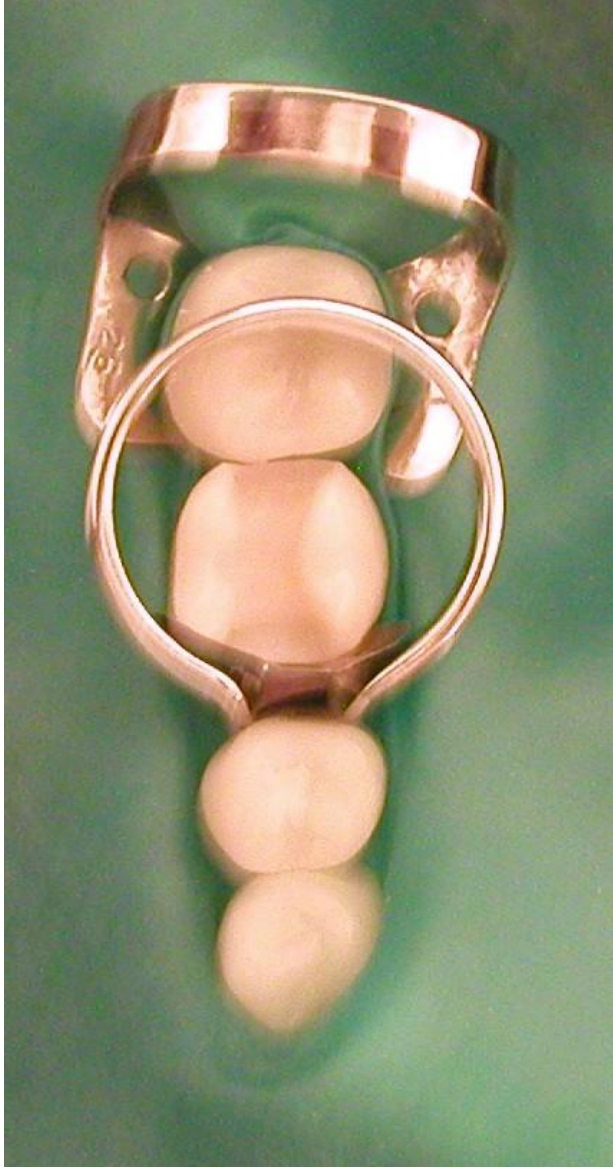






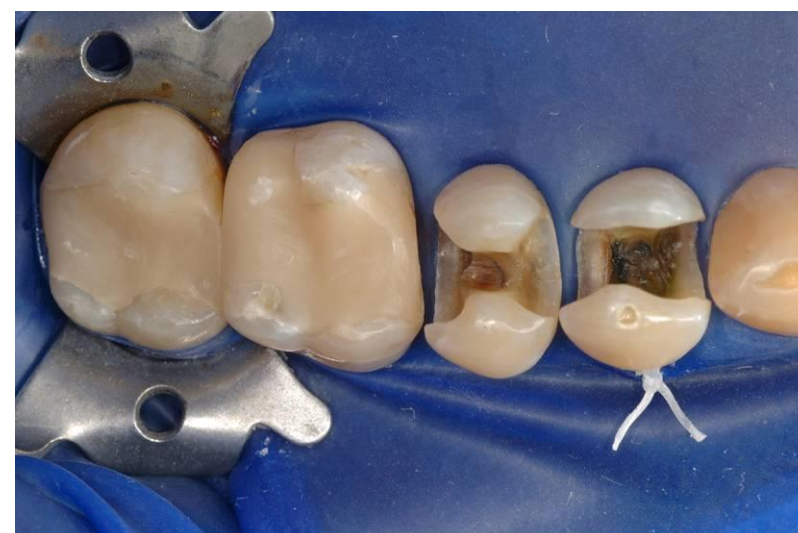
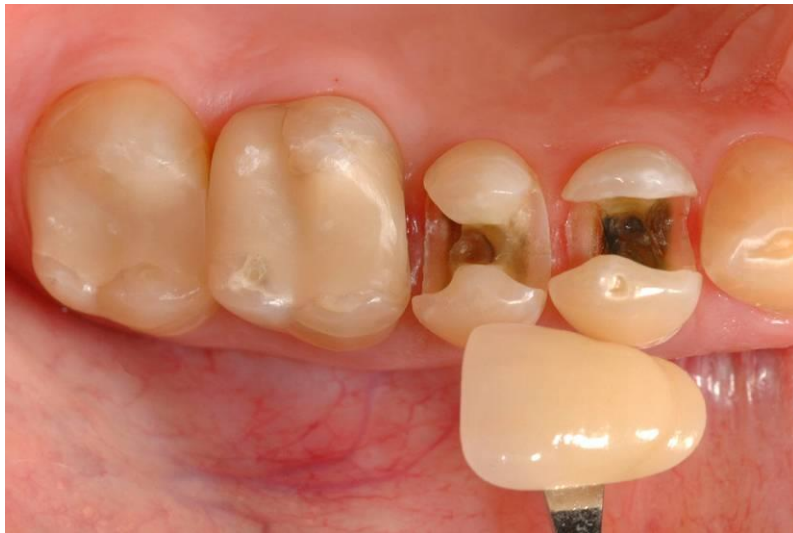
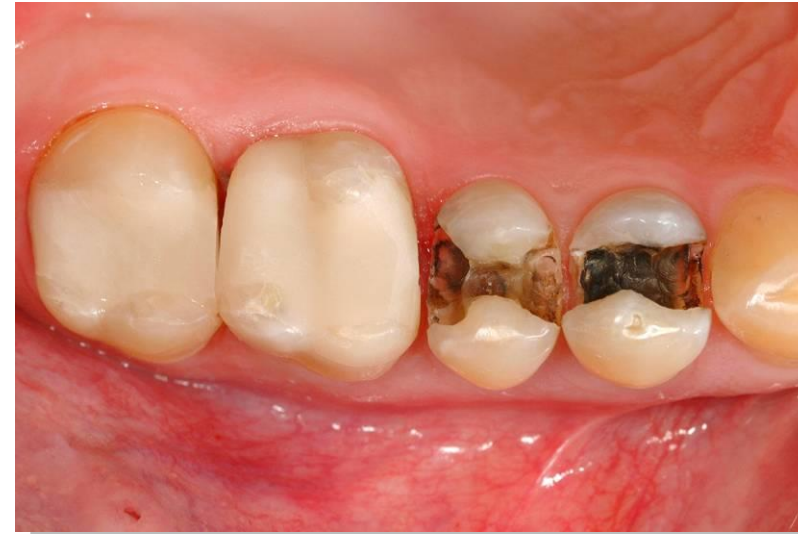
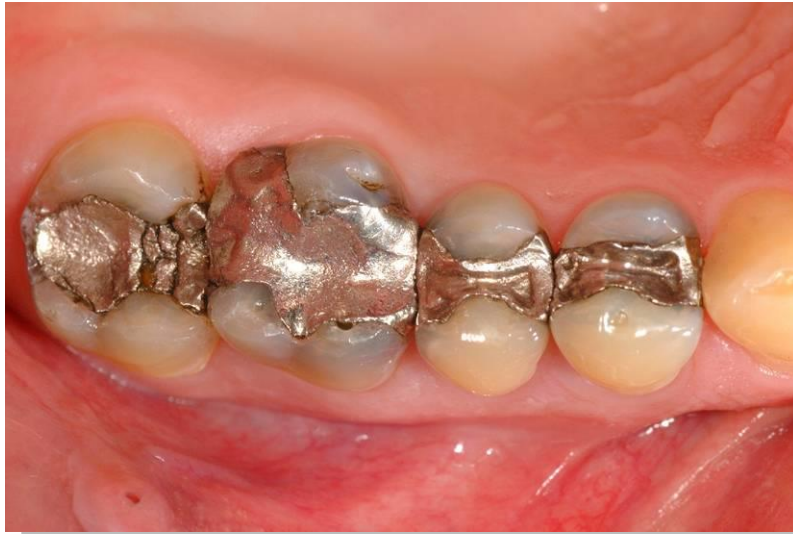
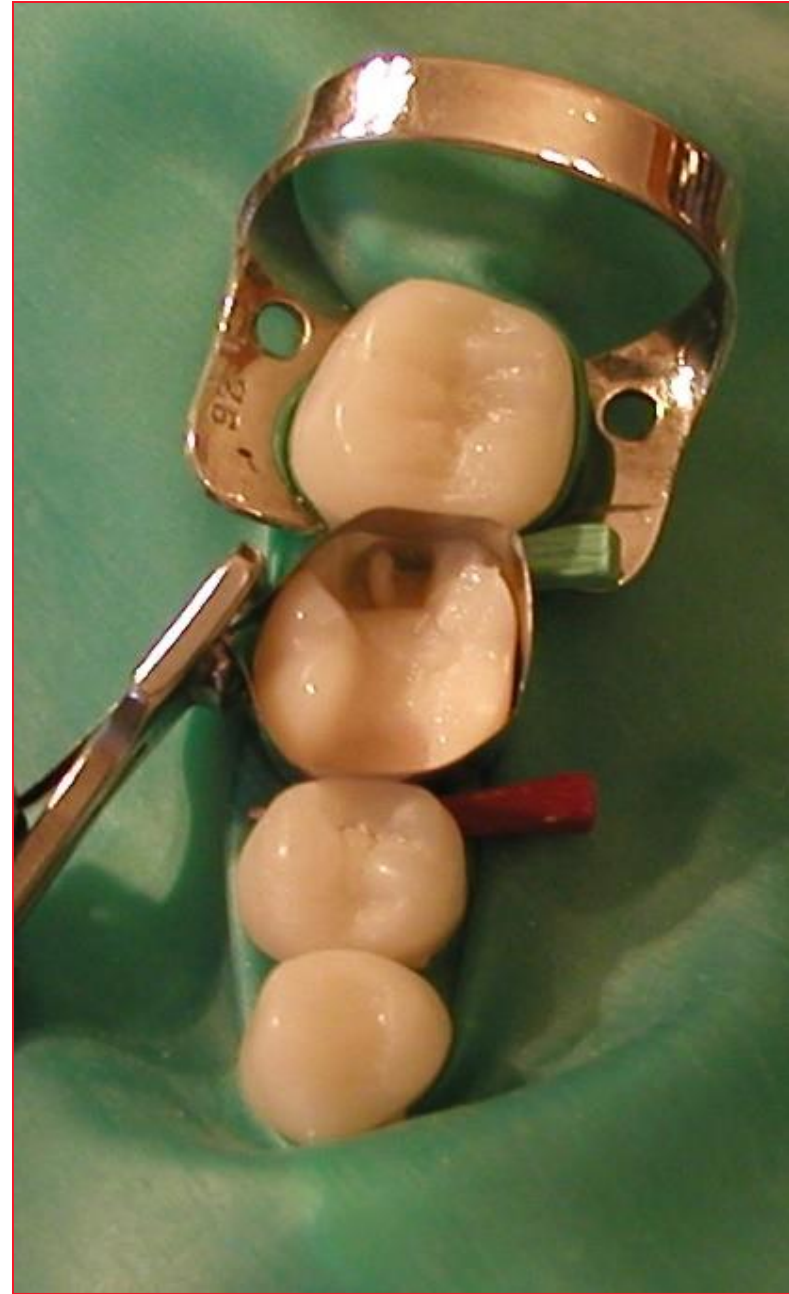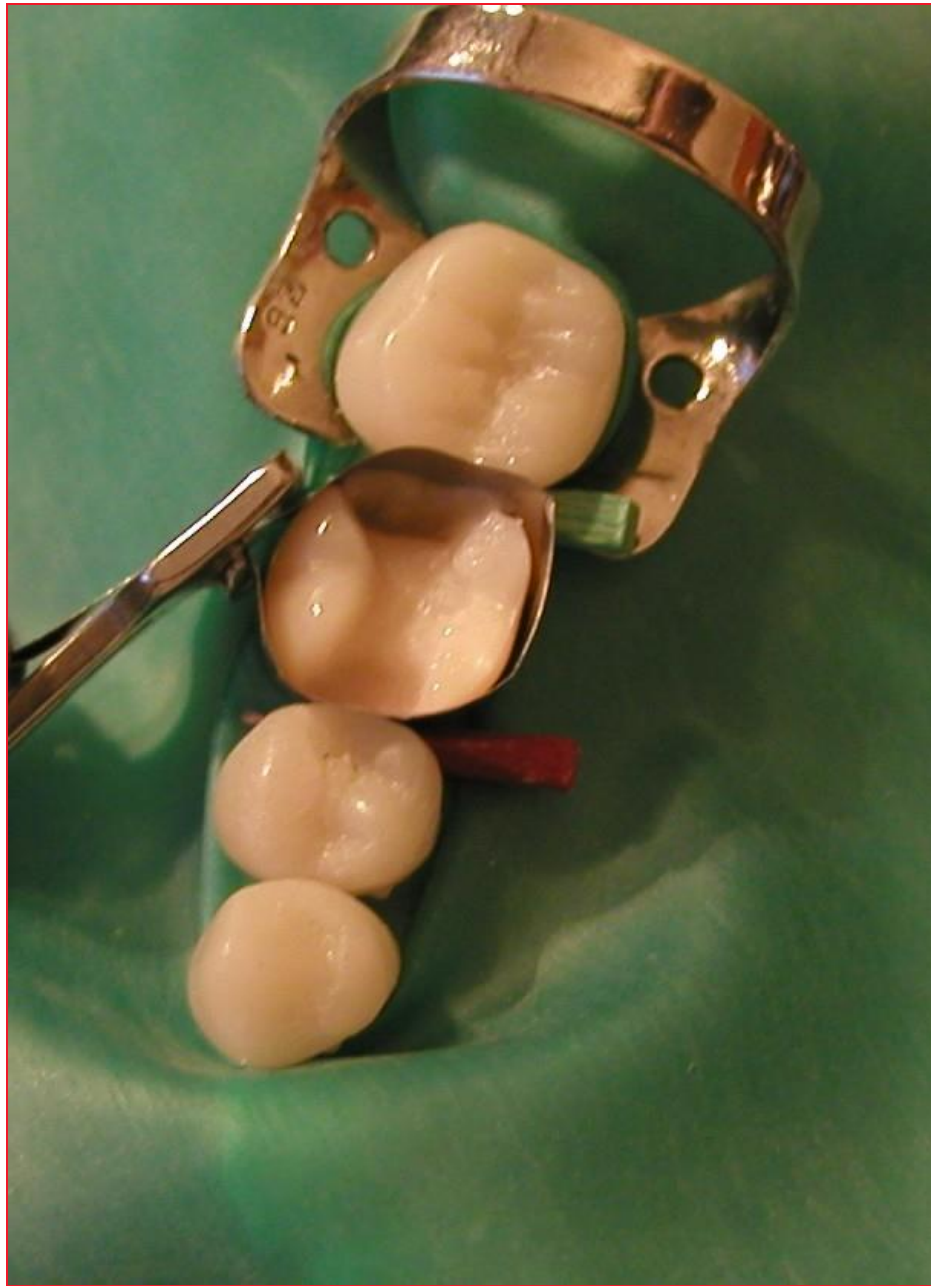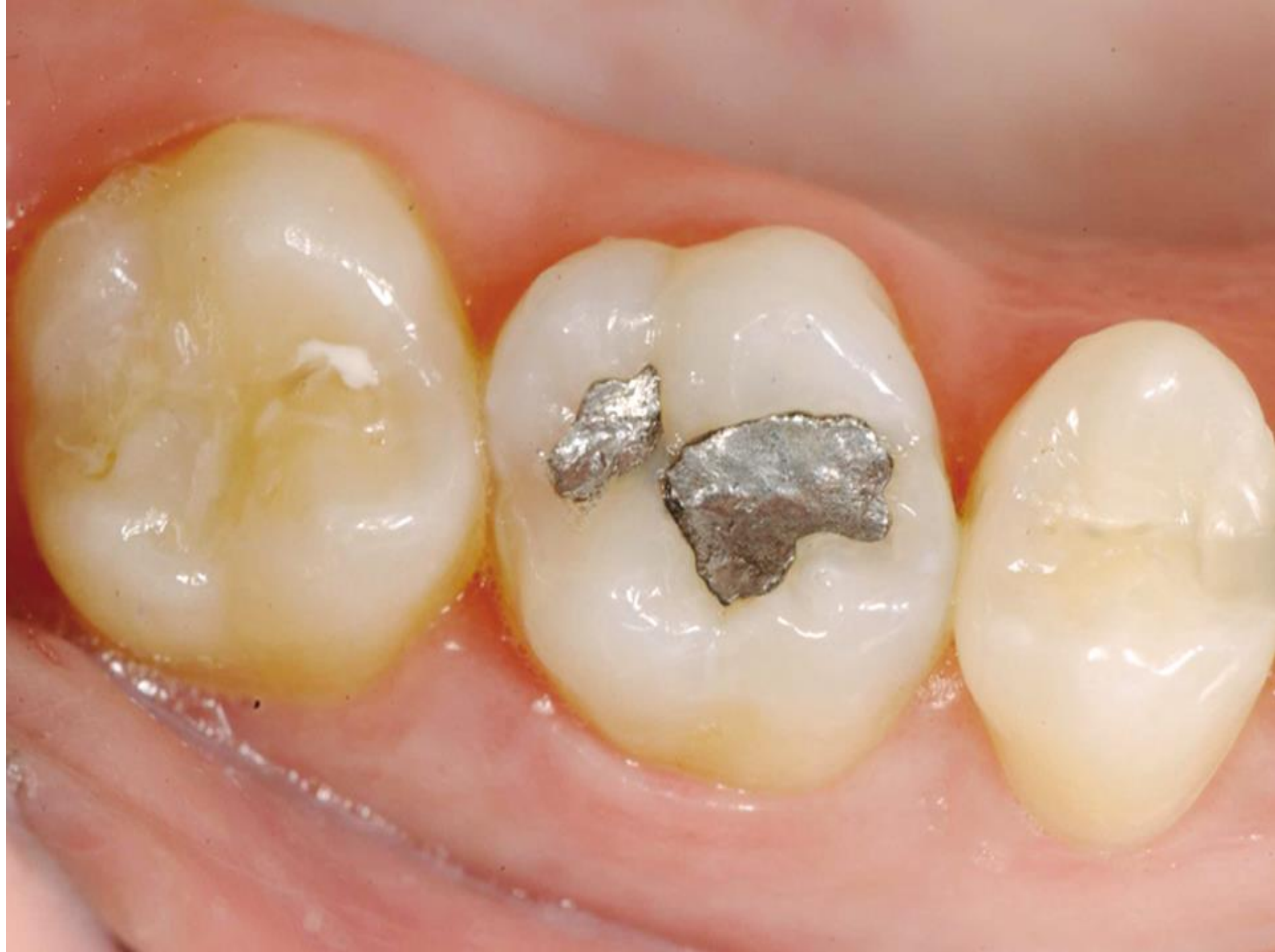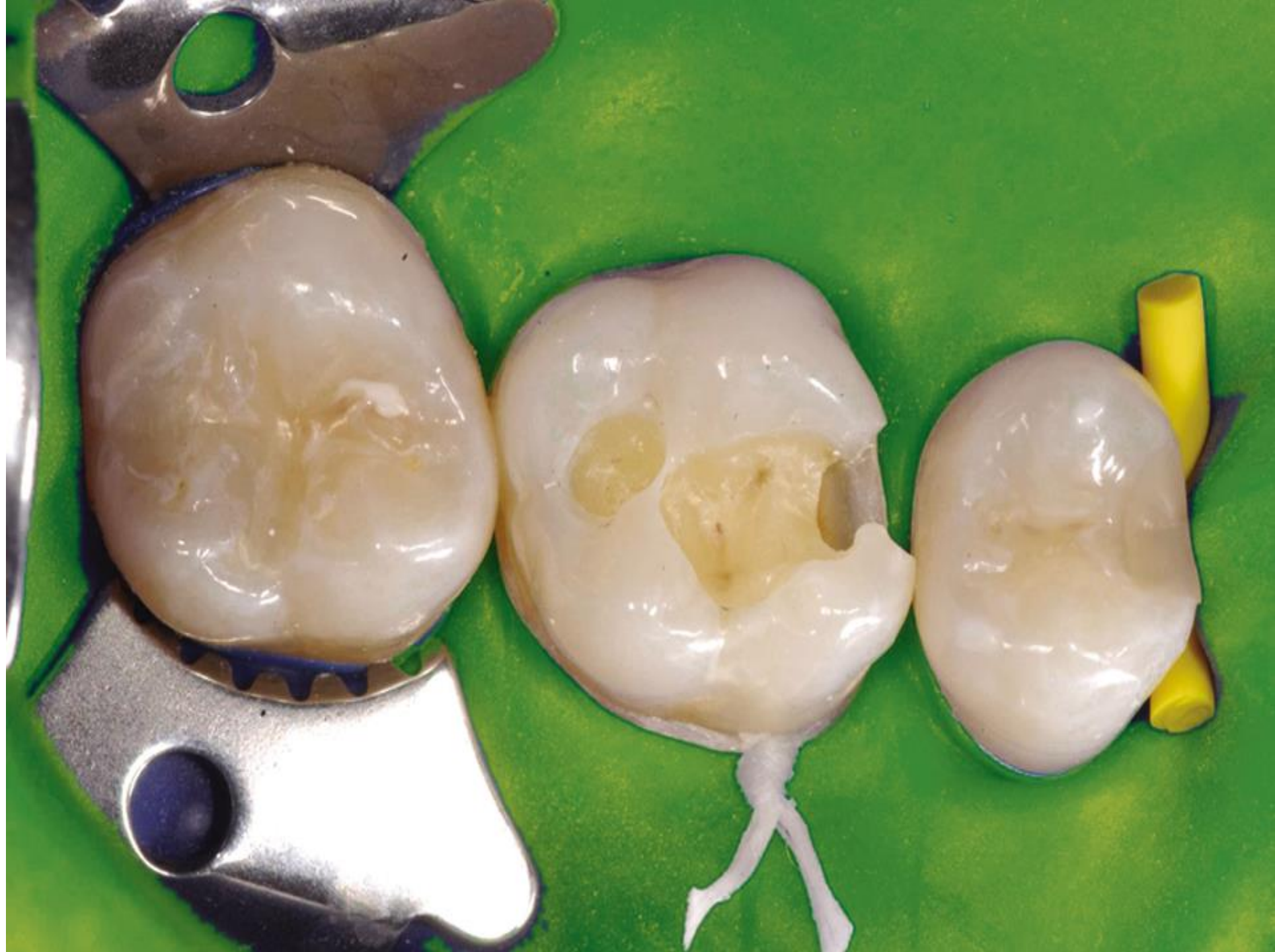# Composite filling class II. Contact point



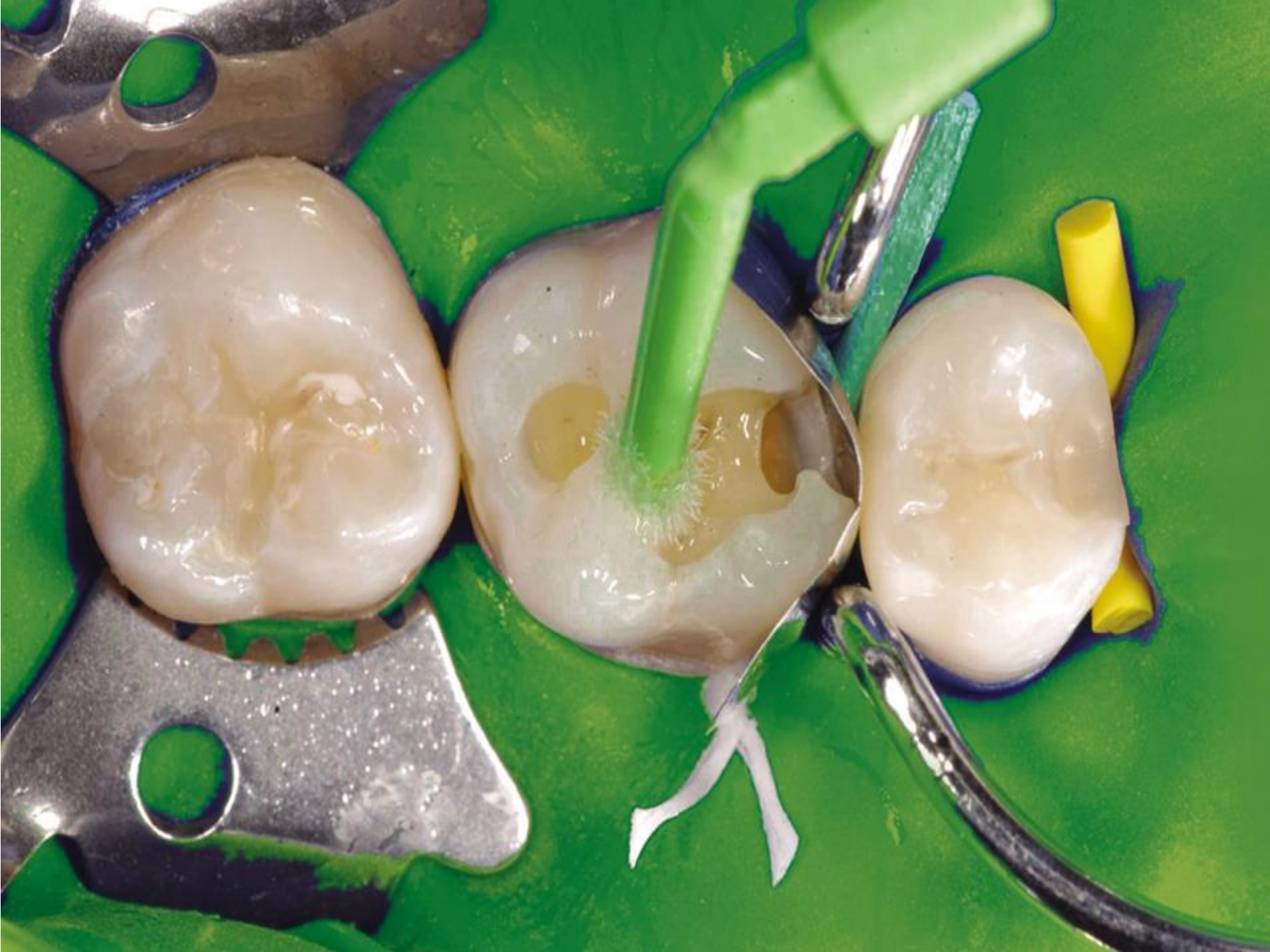




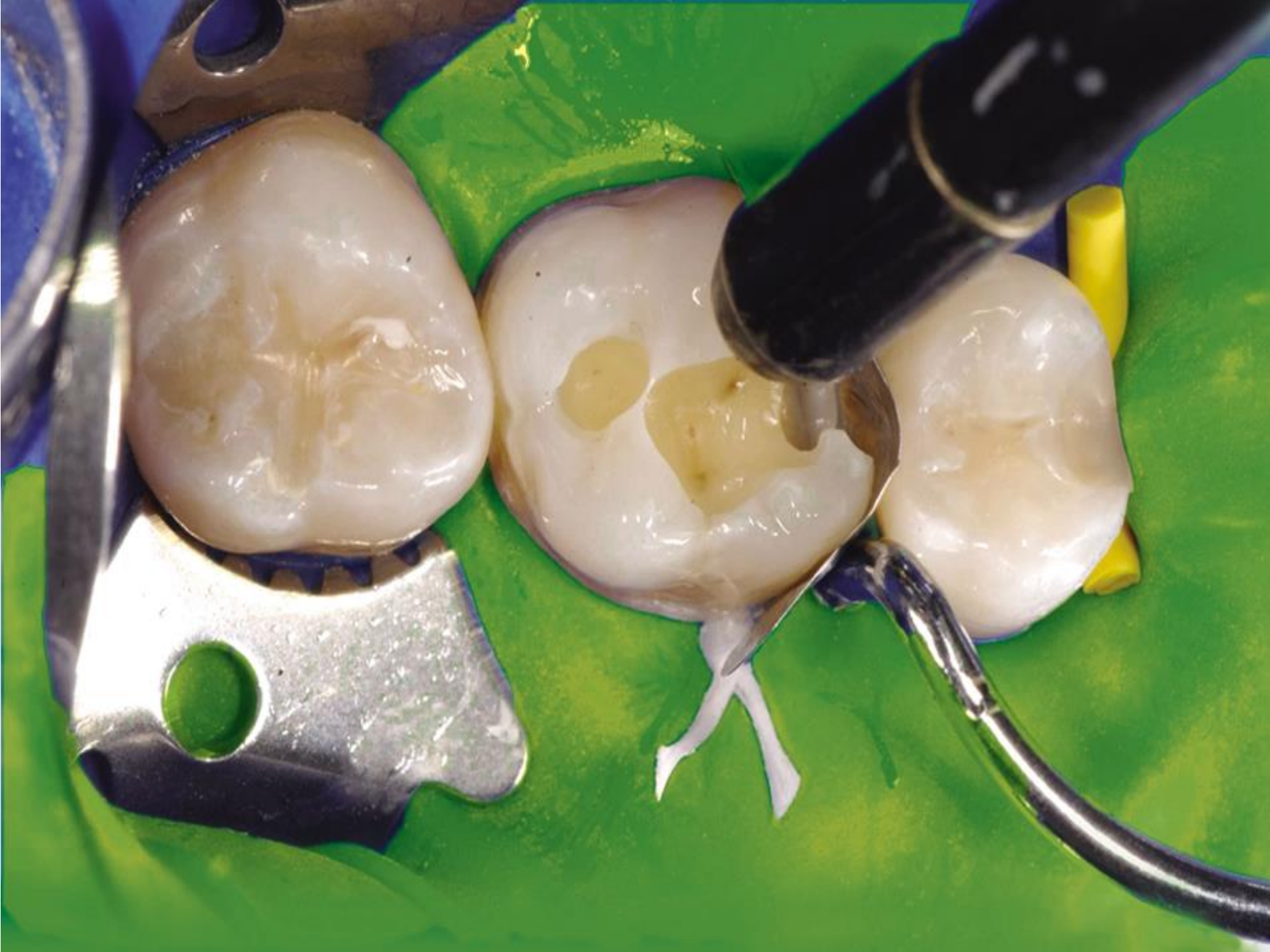


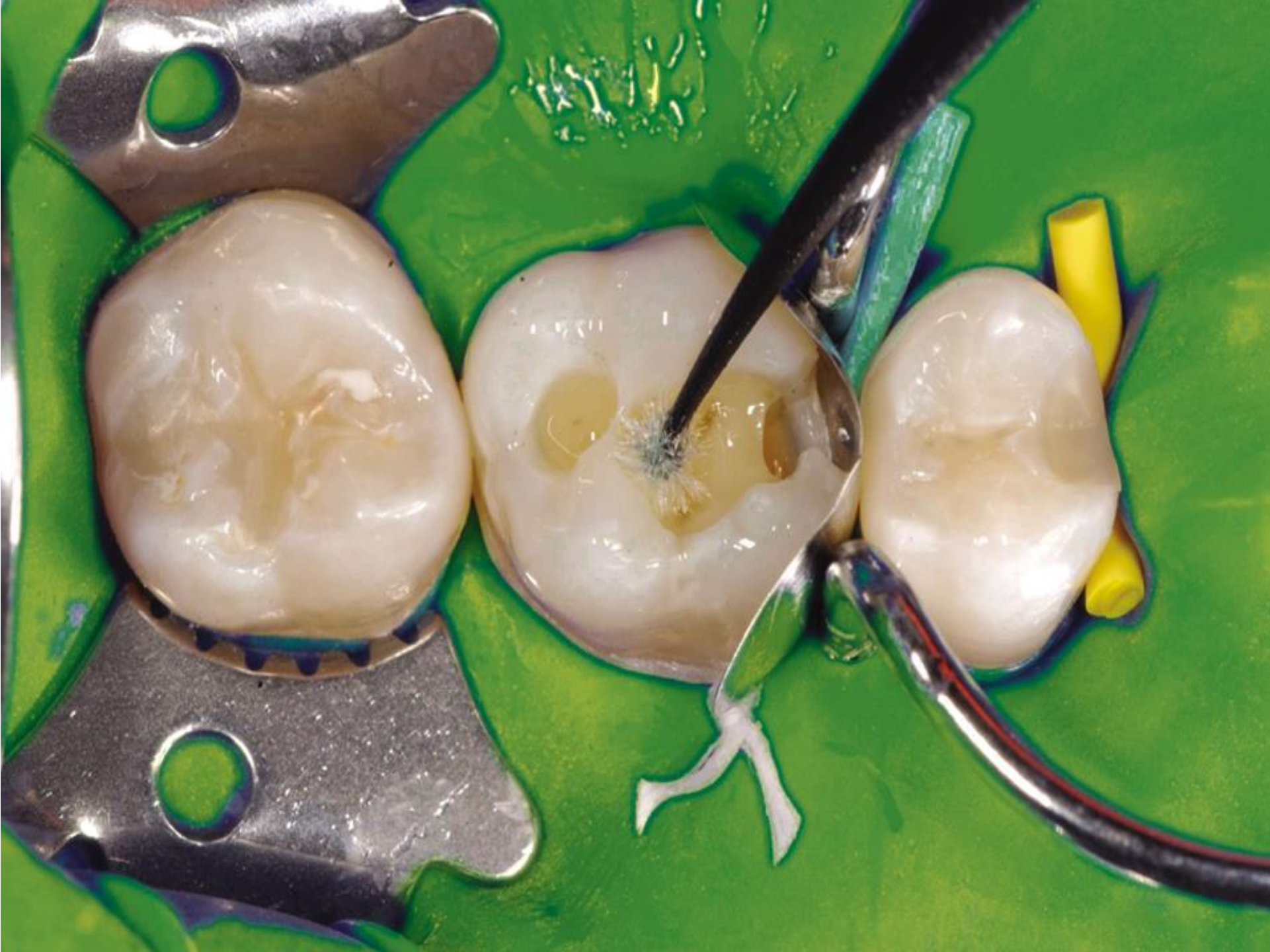




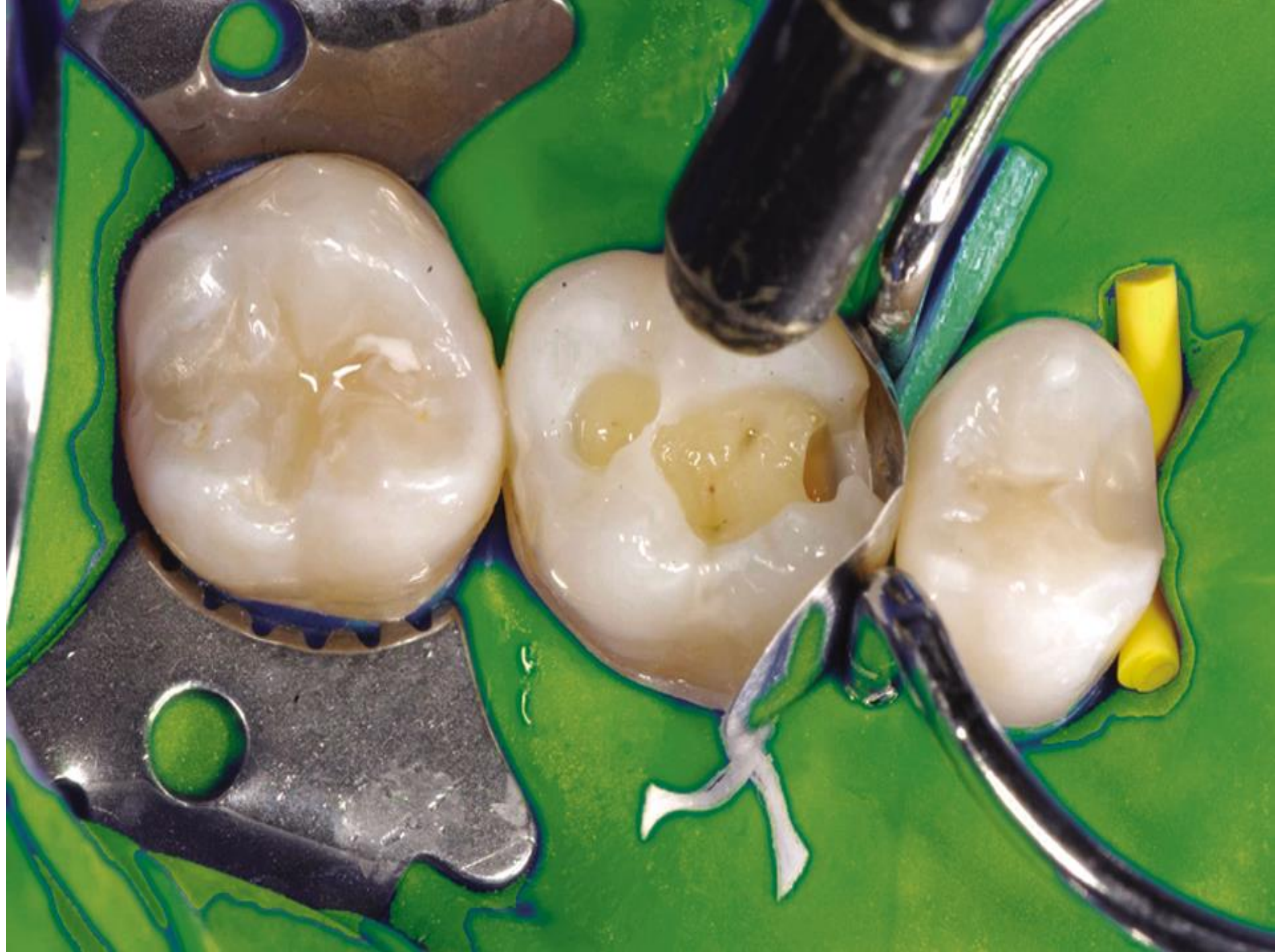


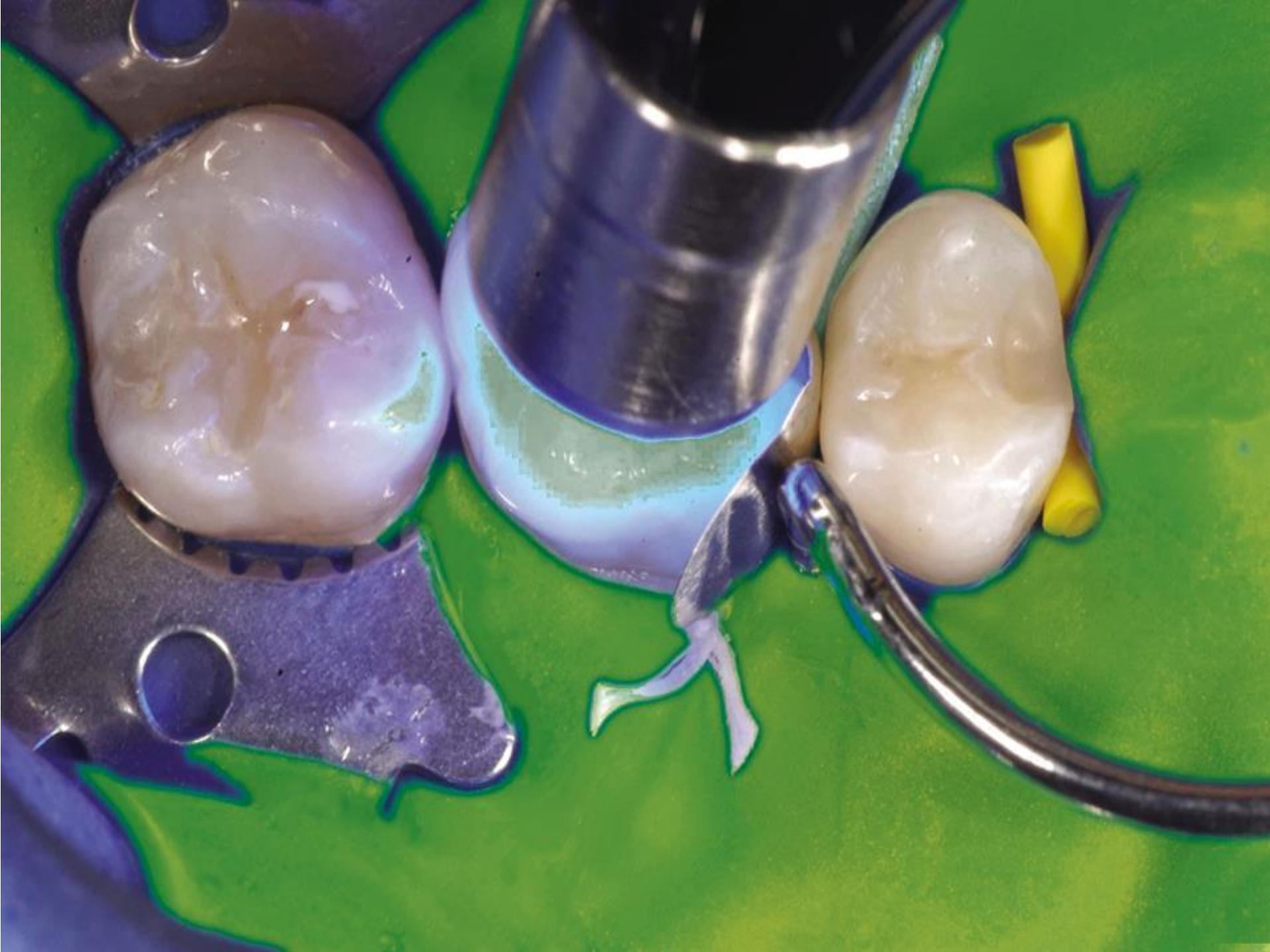




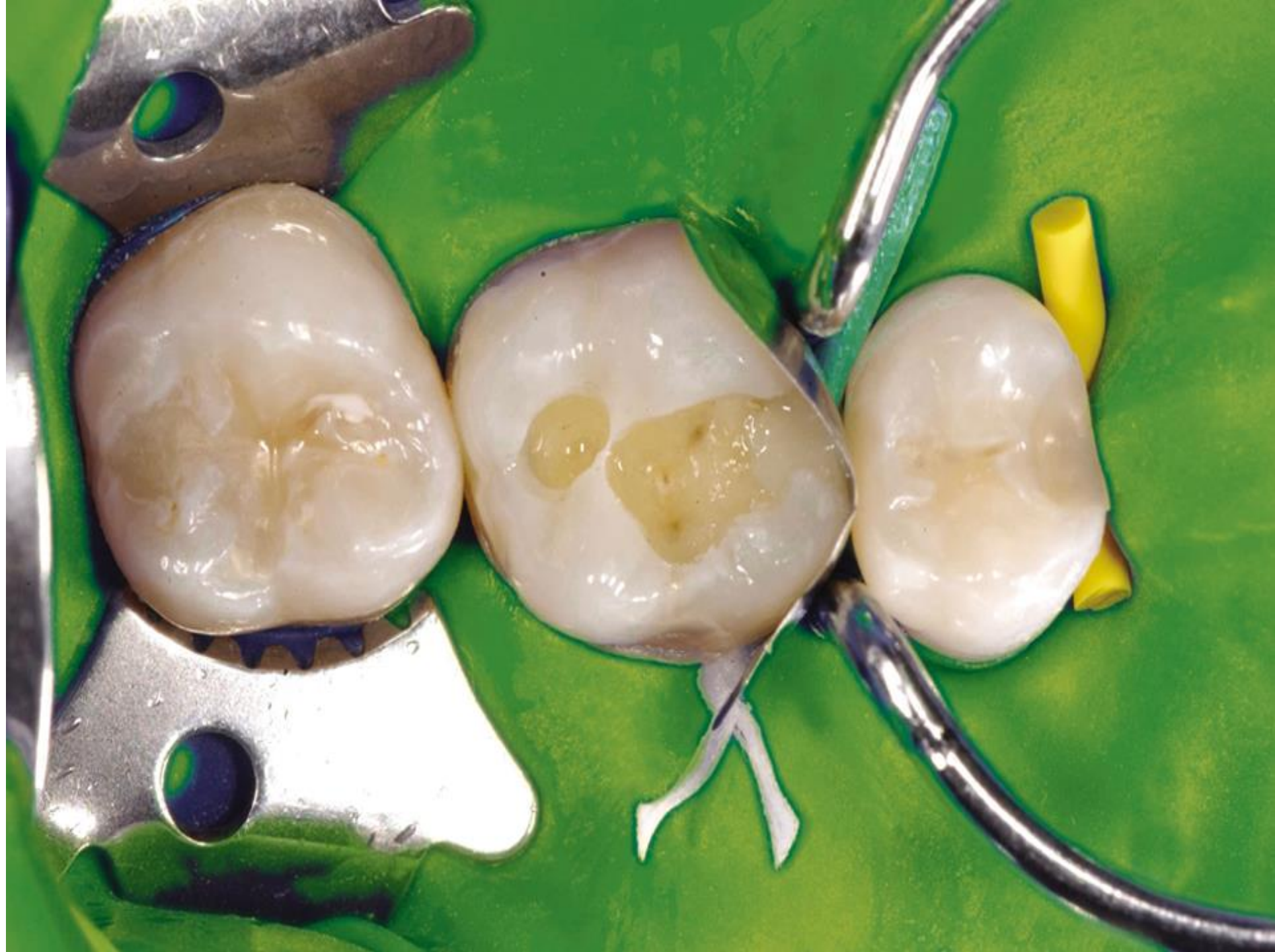




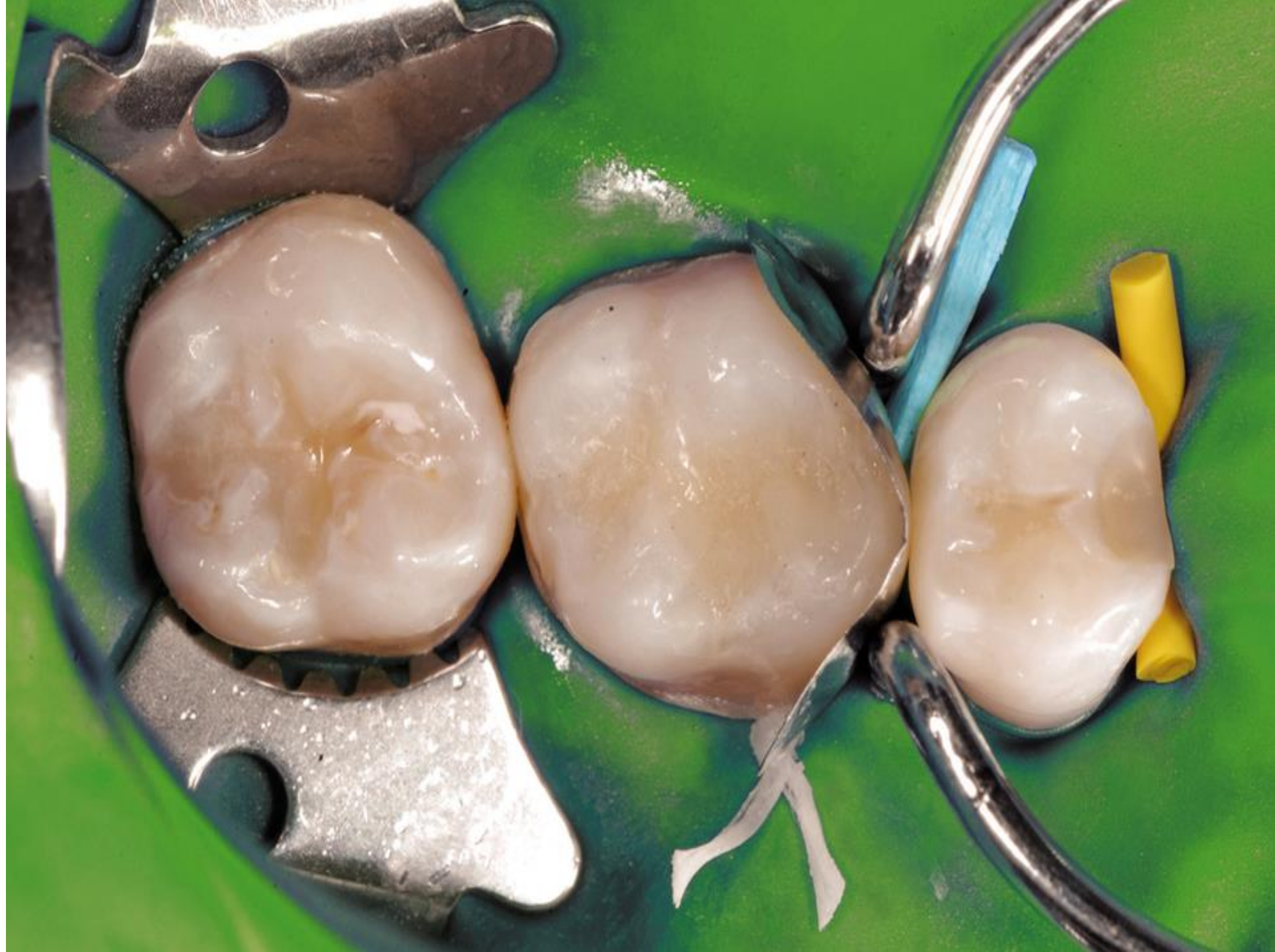


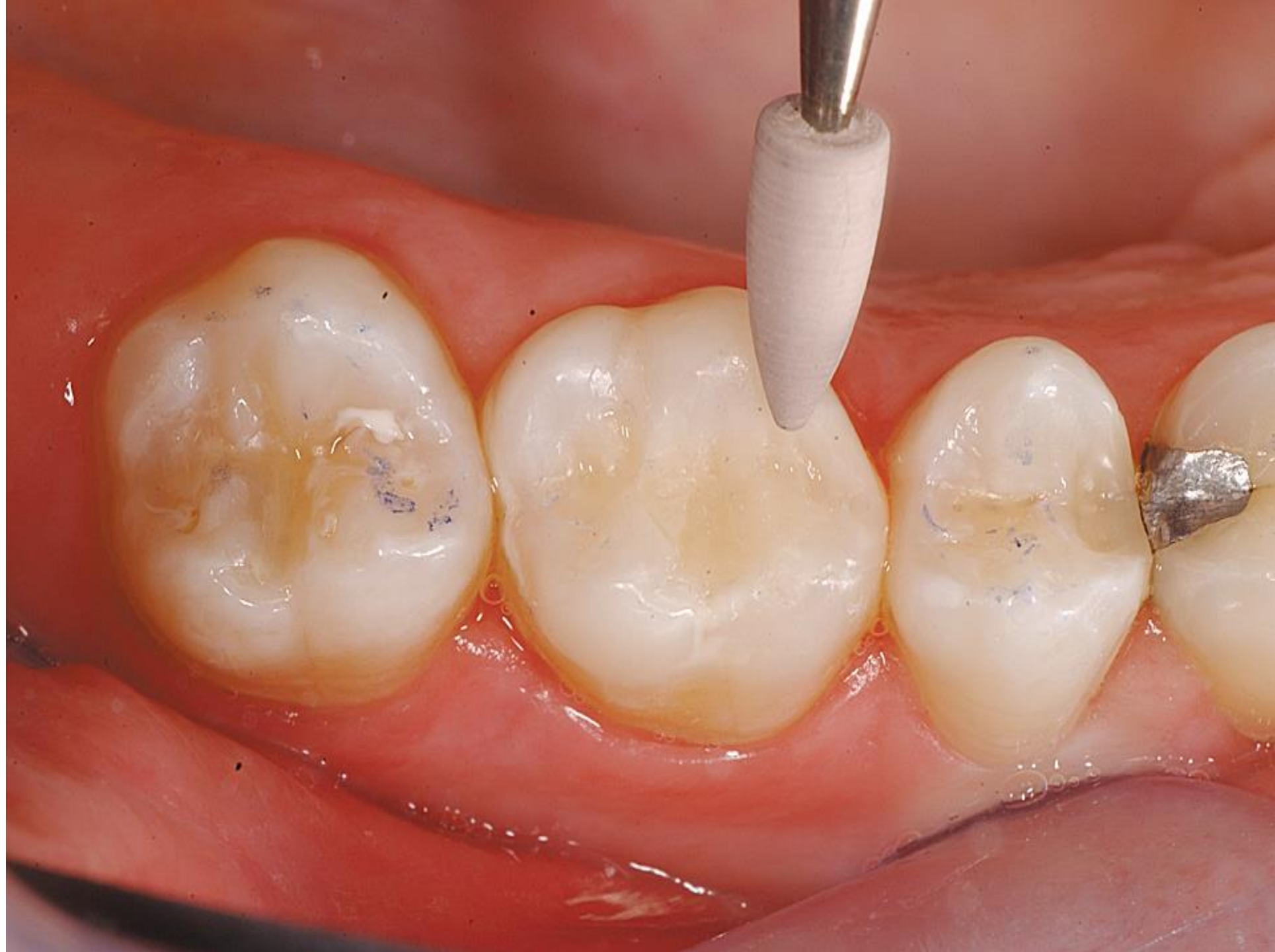




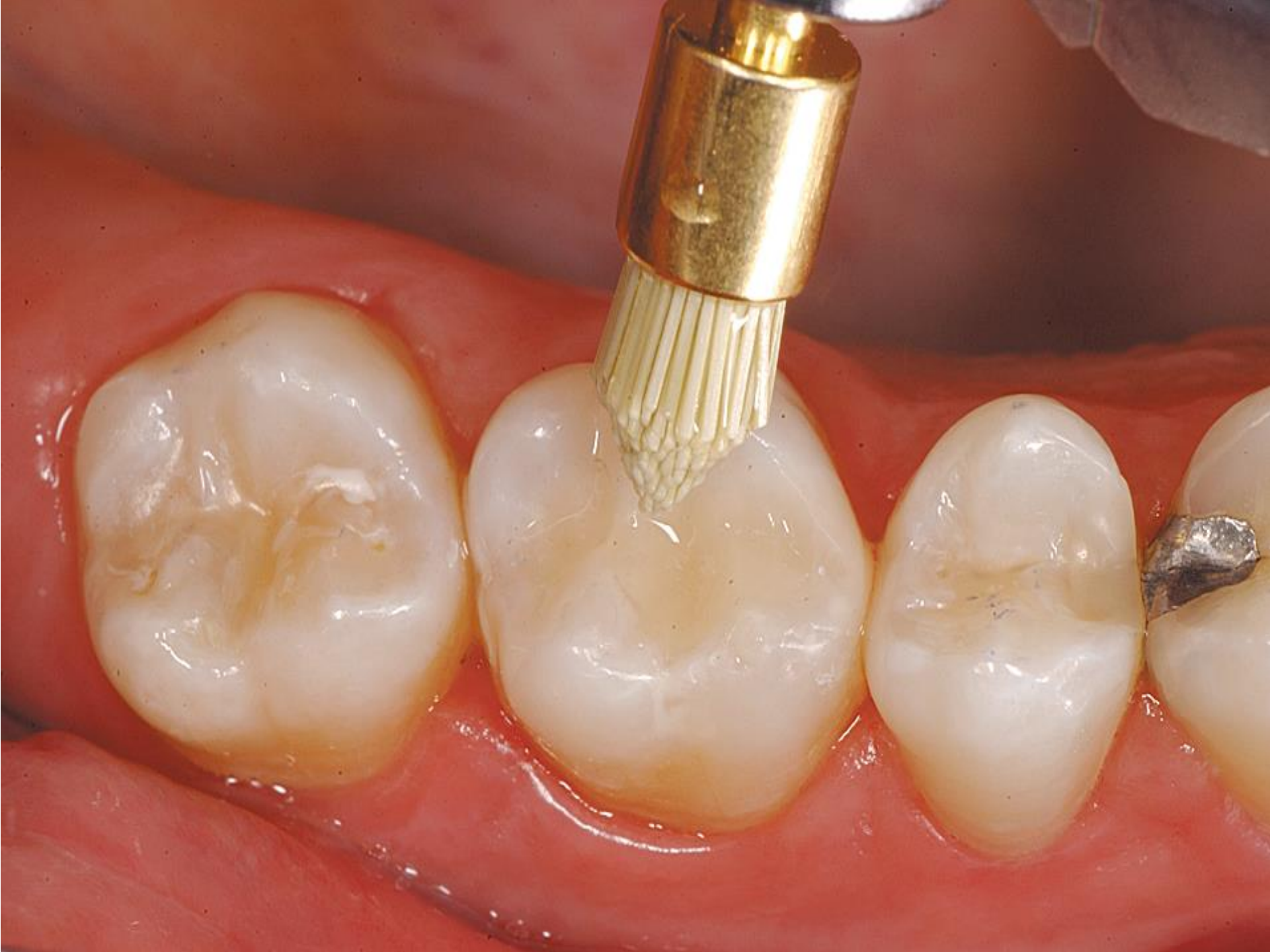


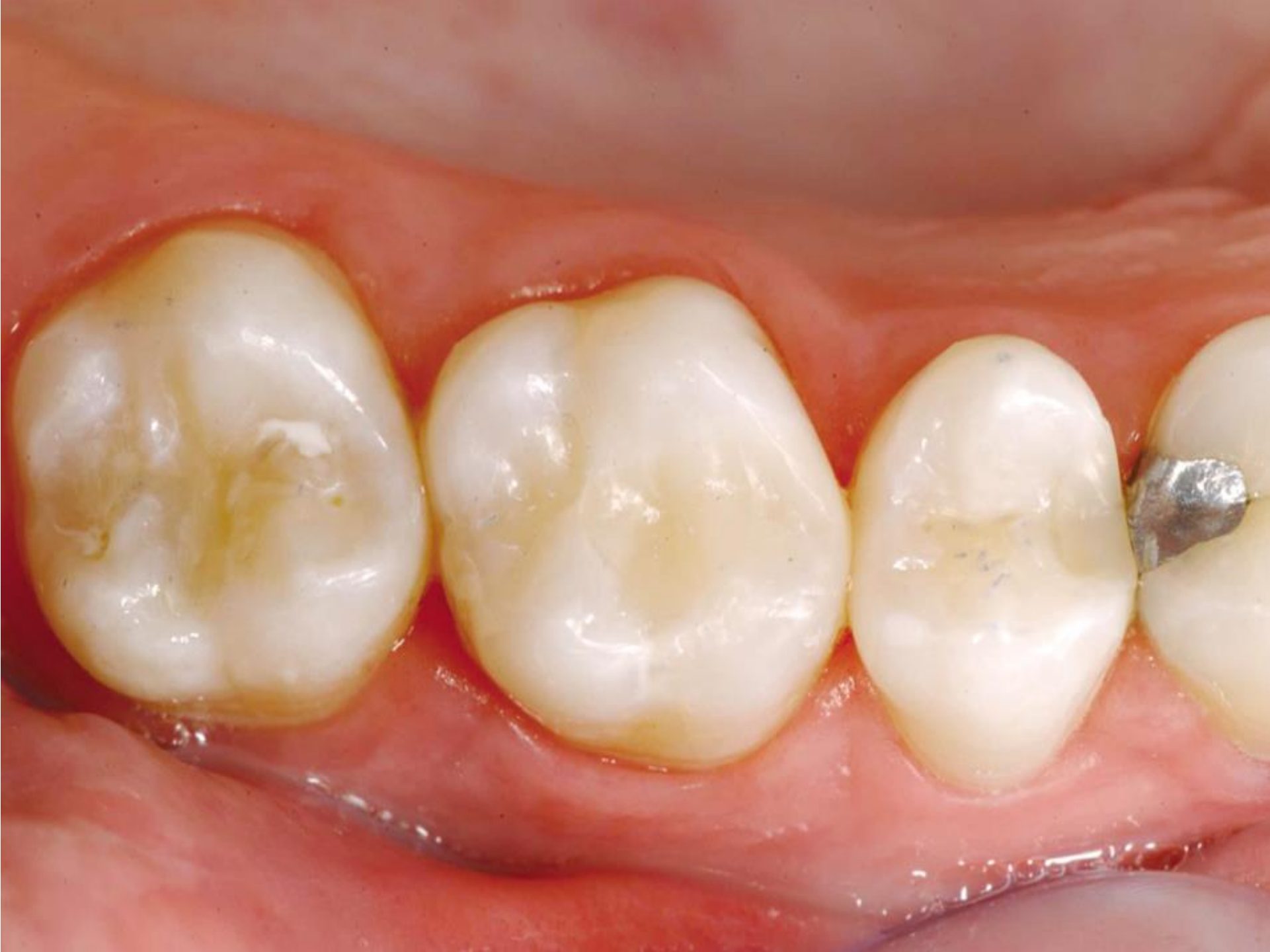




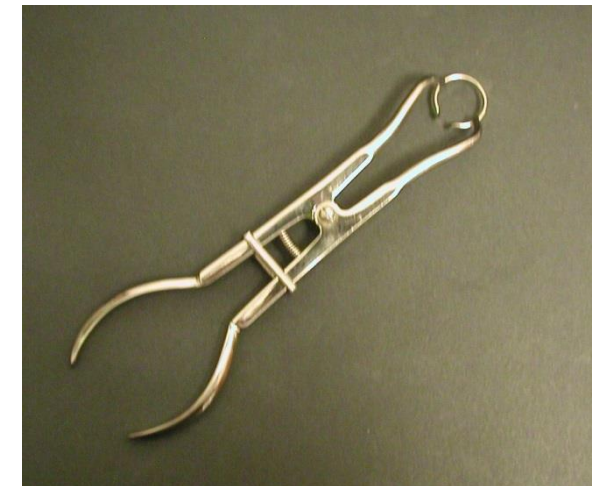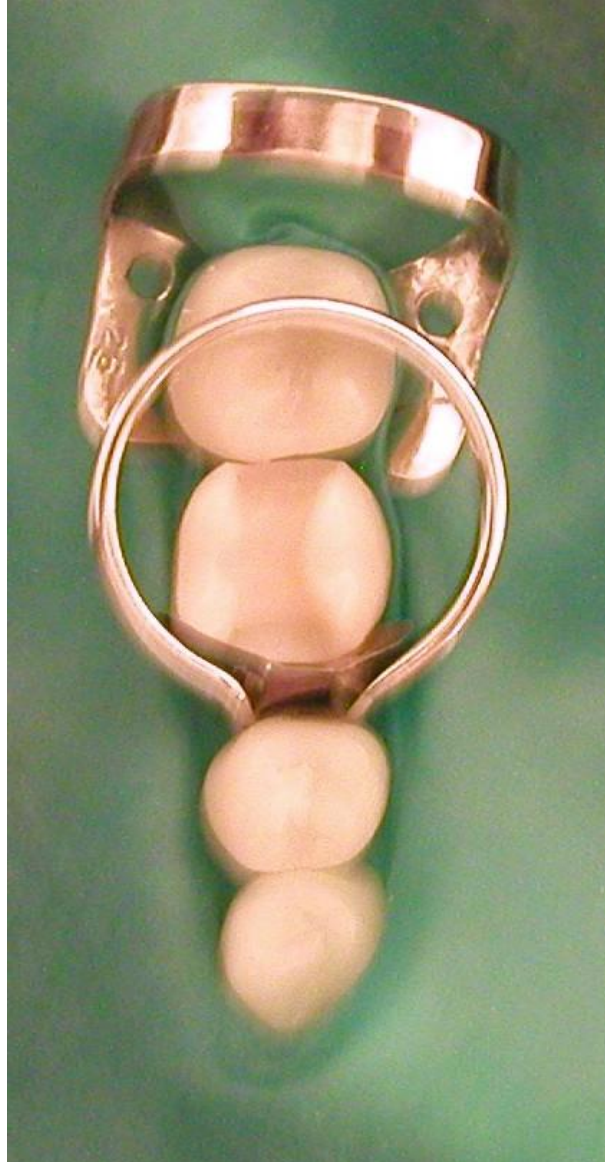# Sectional matrices

- Sectional matrices with separator
- Good adaptation
- Separation using wedge and separator





Sectional pre-contoured metal matrix system provided the highest contact tightness with the highest length of contact arc. Restorations with circumferential pre-contoured metal matrix system provided higher LCA than those with circumferential straight metal matrix with Tofflemire retainer and circumferential pre-contoured transparent matrix system“



*Kampouropoulos D, Paximada C, Loukidis M, Kakaboura A. The influence of matrix type on the proximal contact in class II resin composite restorations. Oper Dent 2010; 35; 454-462*

Use of the sectional matrix system in two-surface Class II cavities resulted in statistically significantly tighter proximal contacts than the use of the circumferential matrix system.

For the three-surface no statistically significant differences in contact tightness were found between the different matrix systems.“

*Wirsching E, Loomans B A, Klaiber B, Dörfer C E. Influence of matrix systems on proximal contact tightness of 2-and 3-surface posterior composite restorations in vivo. J Dent 2011; 39: 386–390*





# Step 1: Pre - wedging

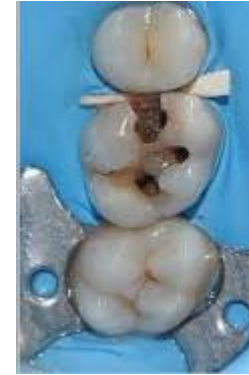The wedge is inserted before preparation:

Compression of gingiva

Separation of teeth

Together with the matrix protection of damage of neighbouring tooth

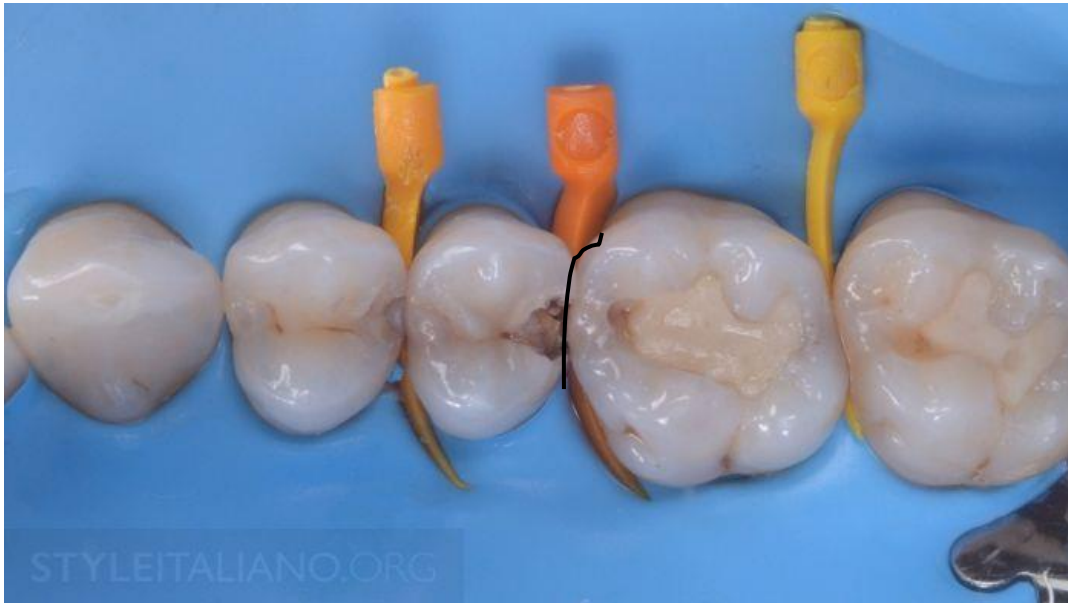
Matrix for the filling can be inserted easier.





## Step 2: preparation

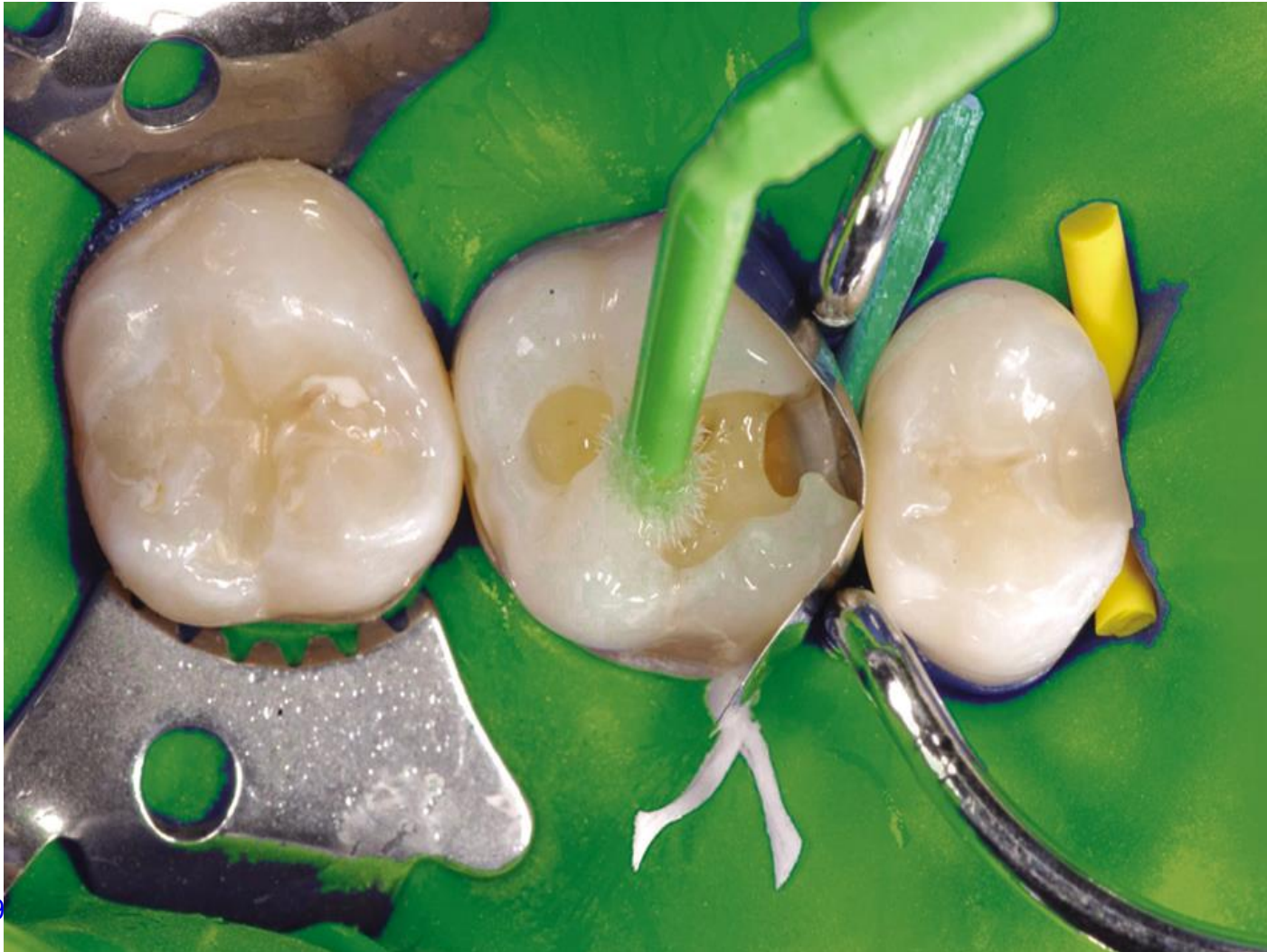- Preparation with the protection of neighbouring tooth using the metal strip or matrix.



## Step 3: adaptation of wedge, matrix and separator

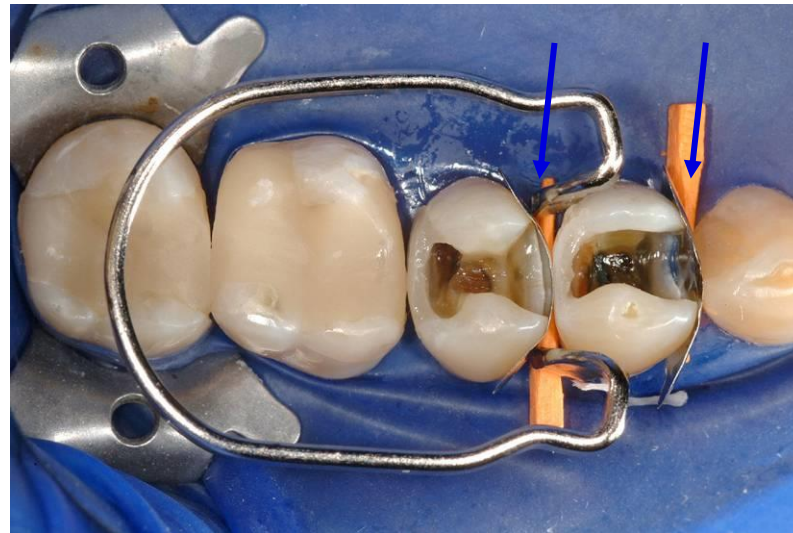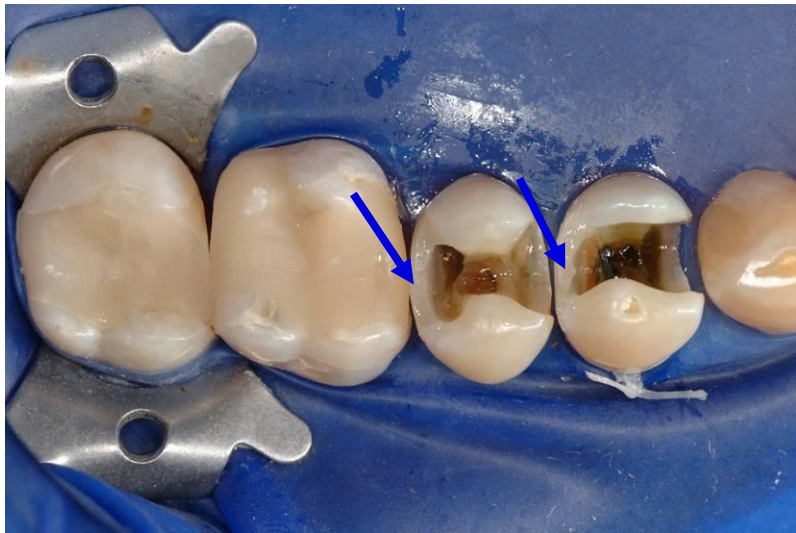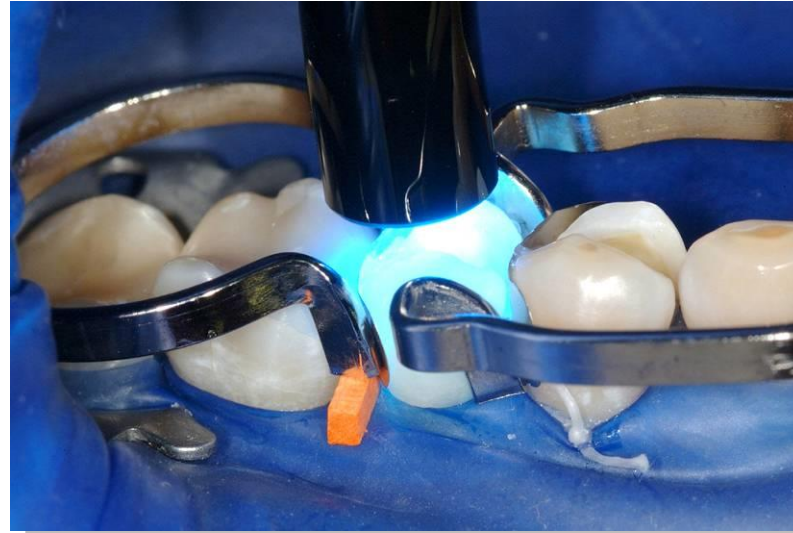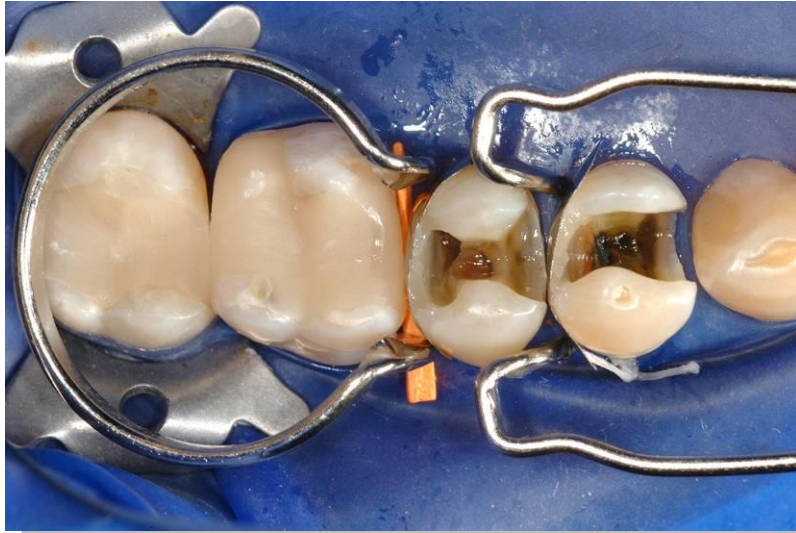- The wedge can be new or the same as previous, inserted from oral or vestibular side
- The matrix is 0,5 mm below the gingival wall
- Separator separates teeth

# Step 4 Making filling



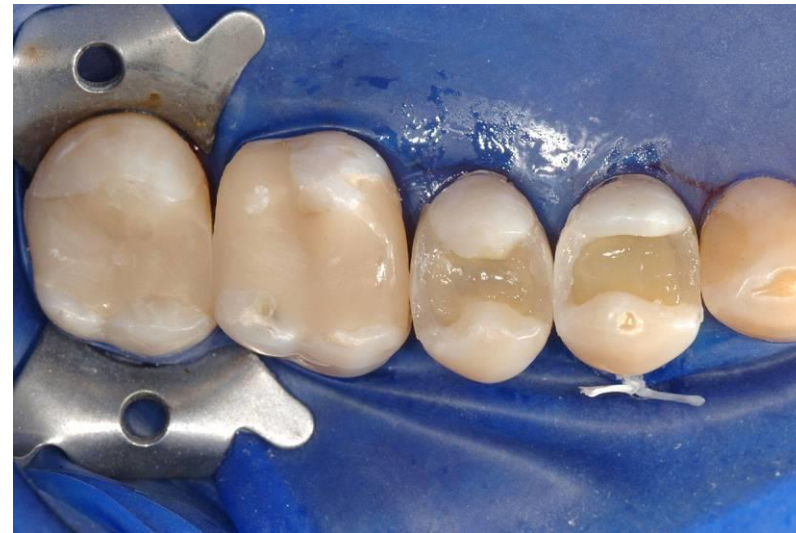
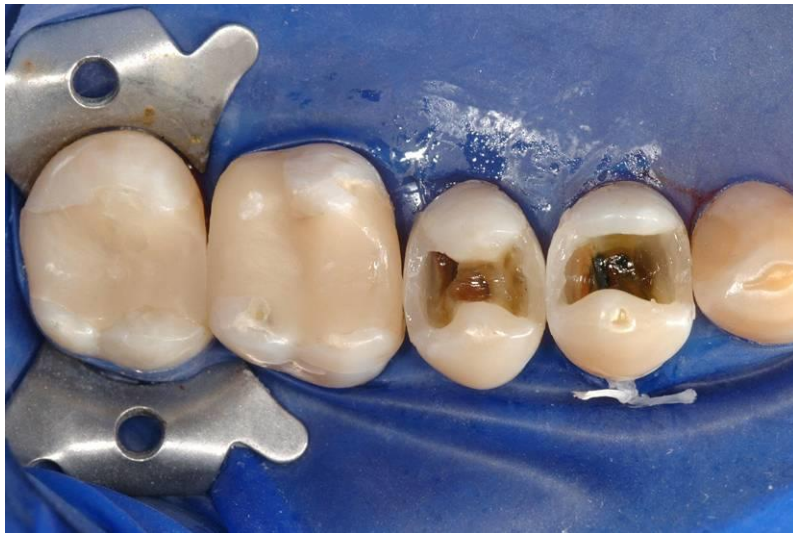
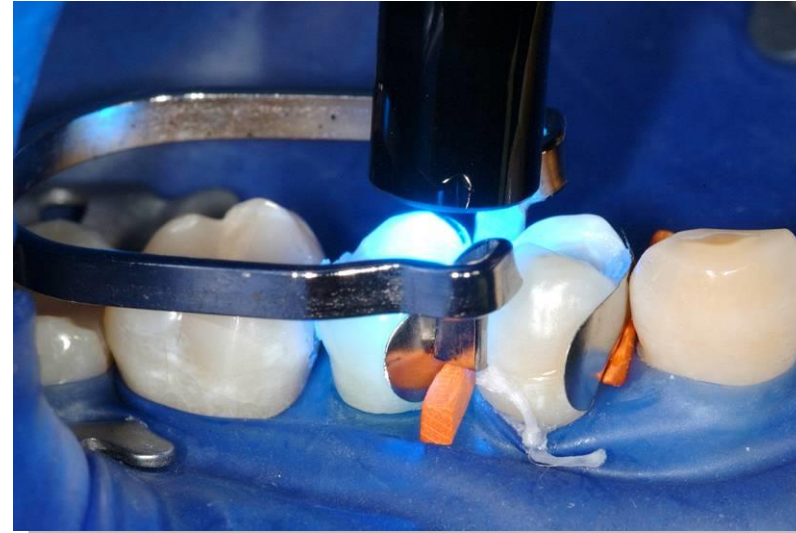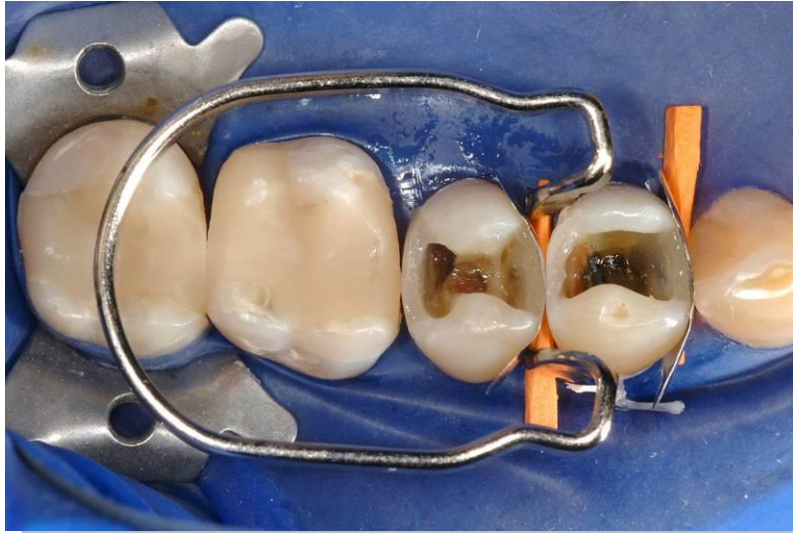# Kompozitní výplň II. třídy



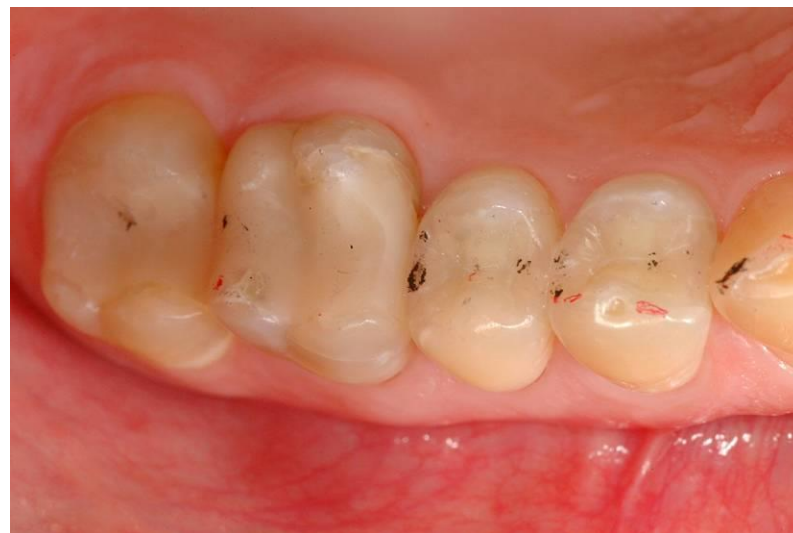
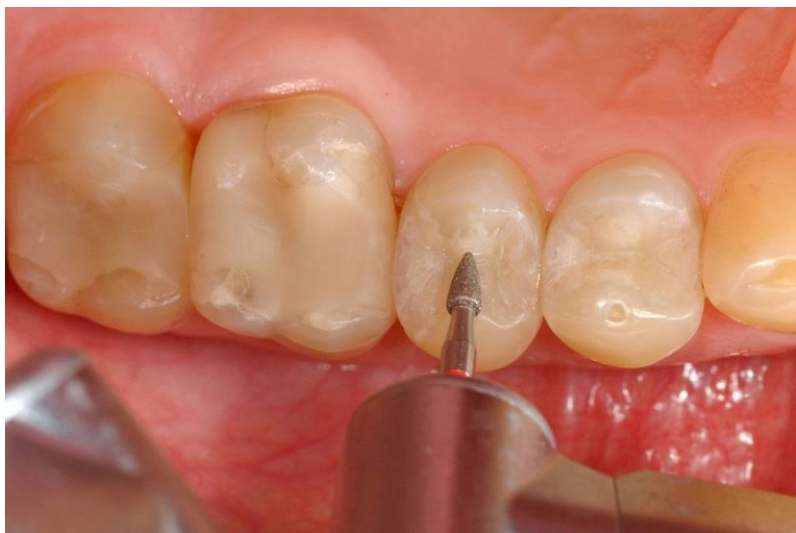
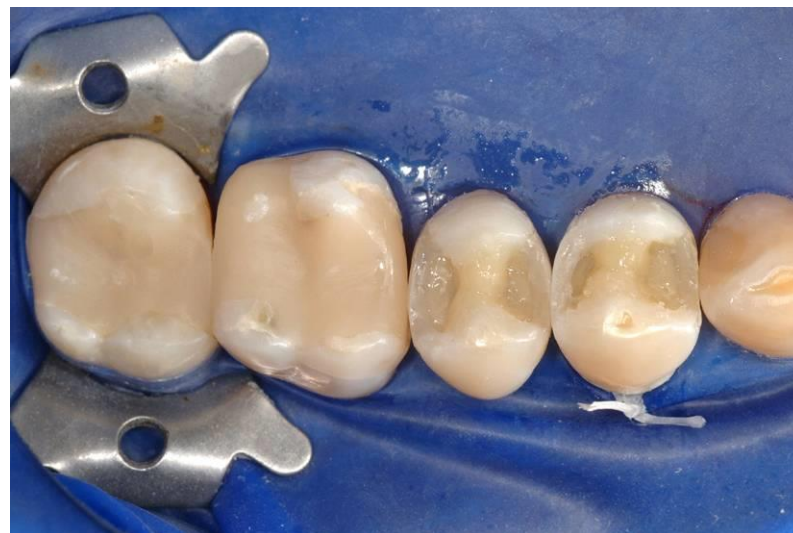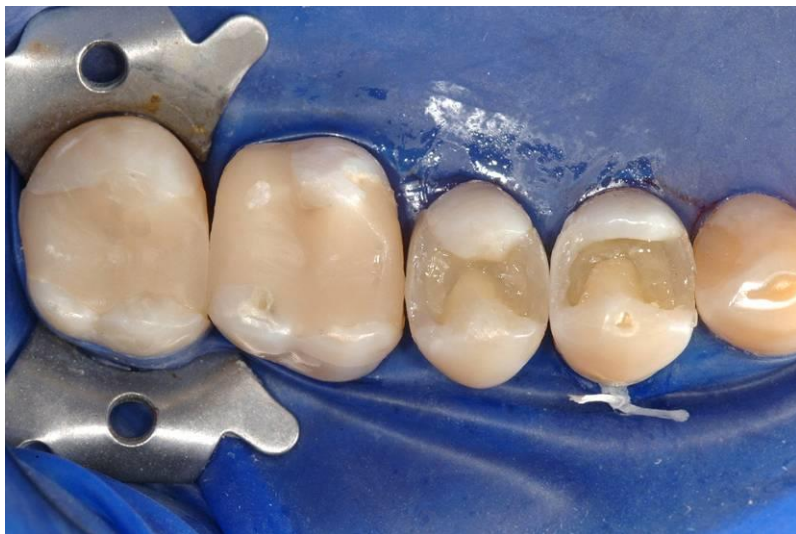# Kompozitní výplň II. třídy

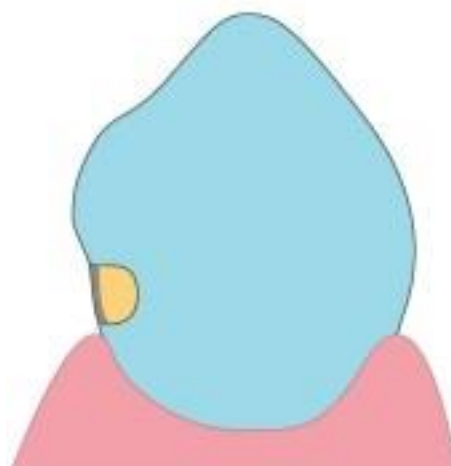
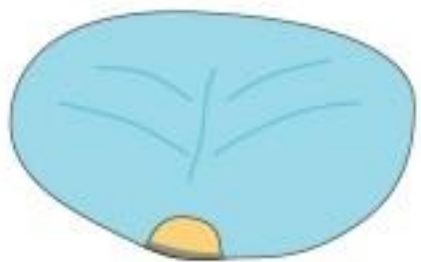
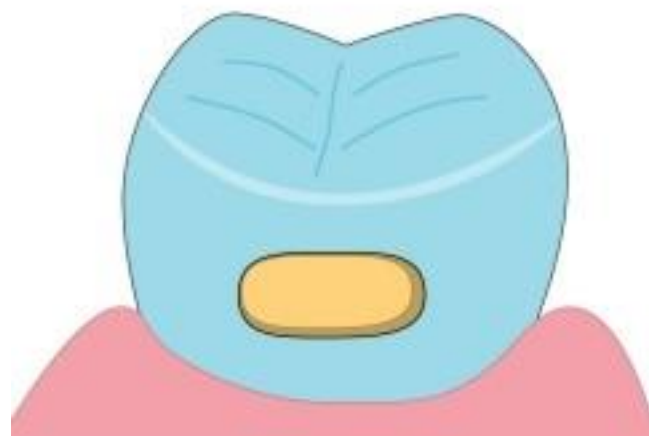
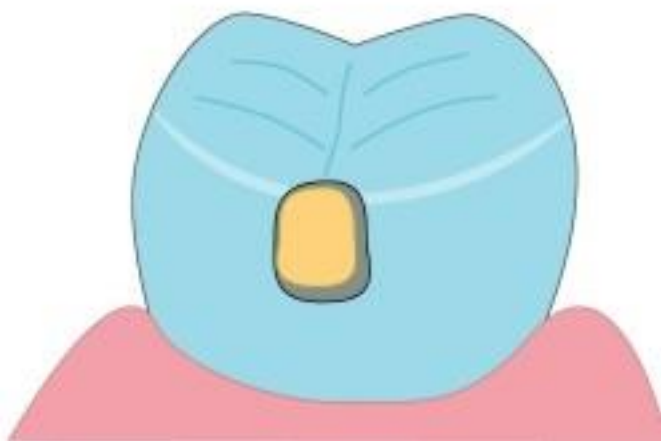

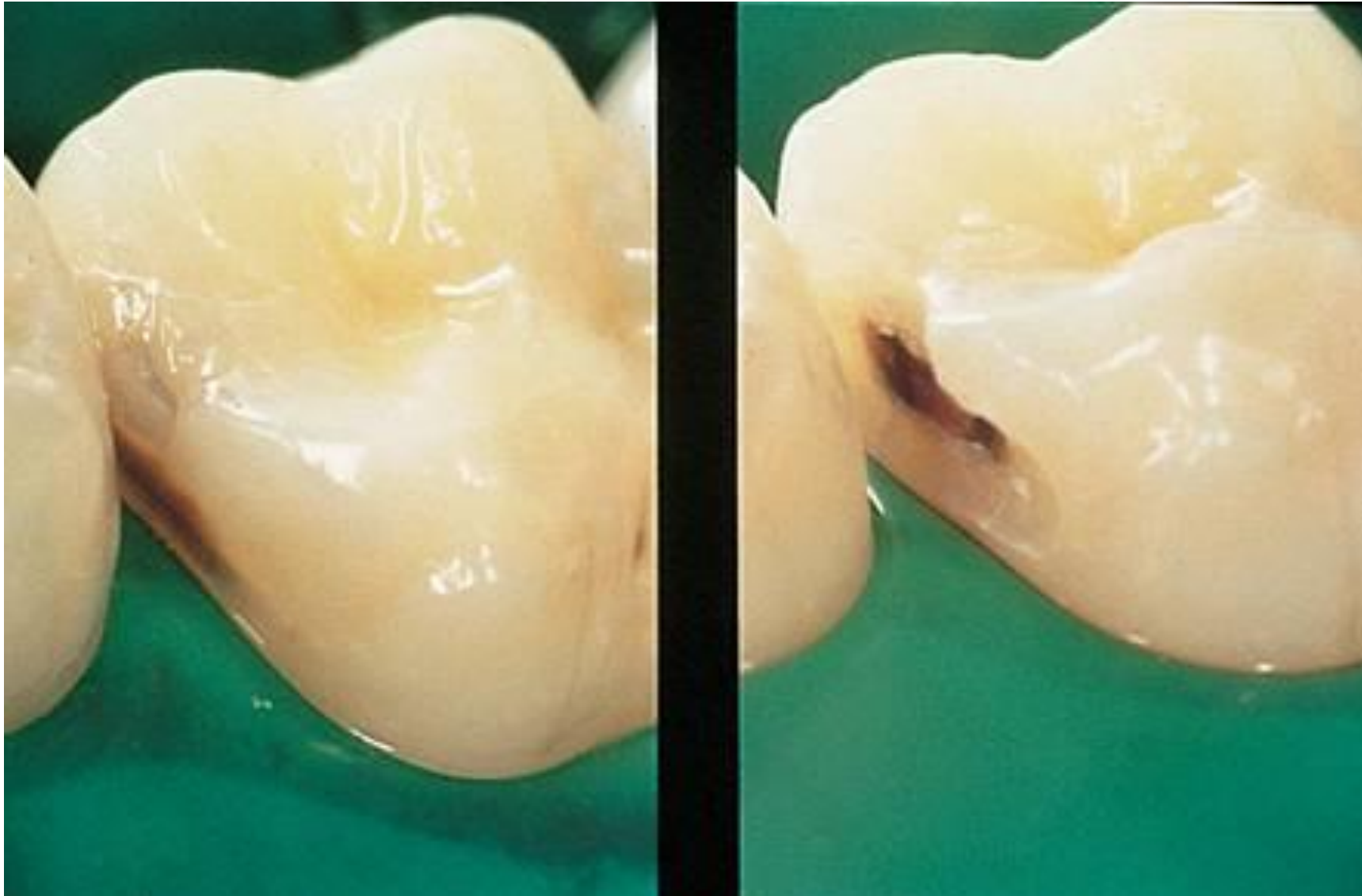
## Kompozitní výplň II. třídy



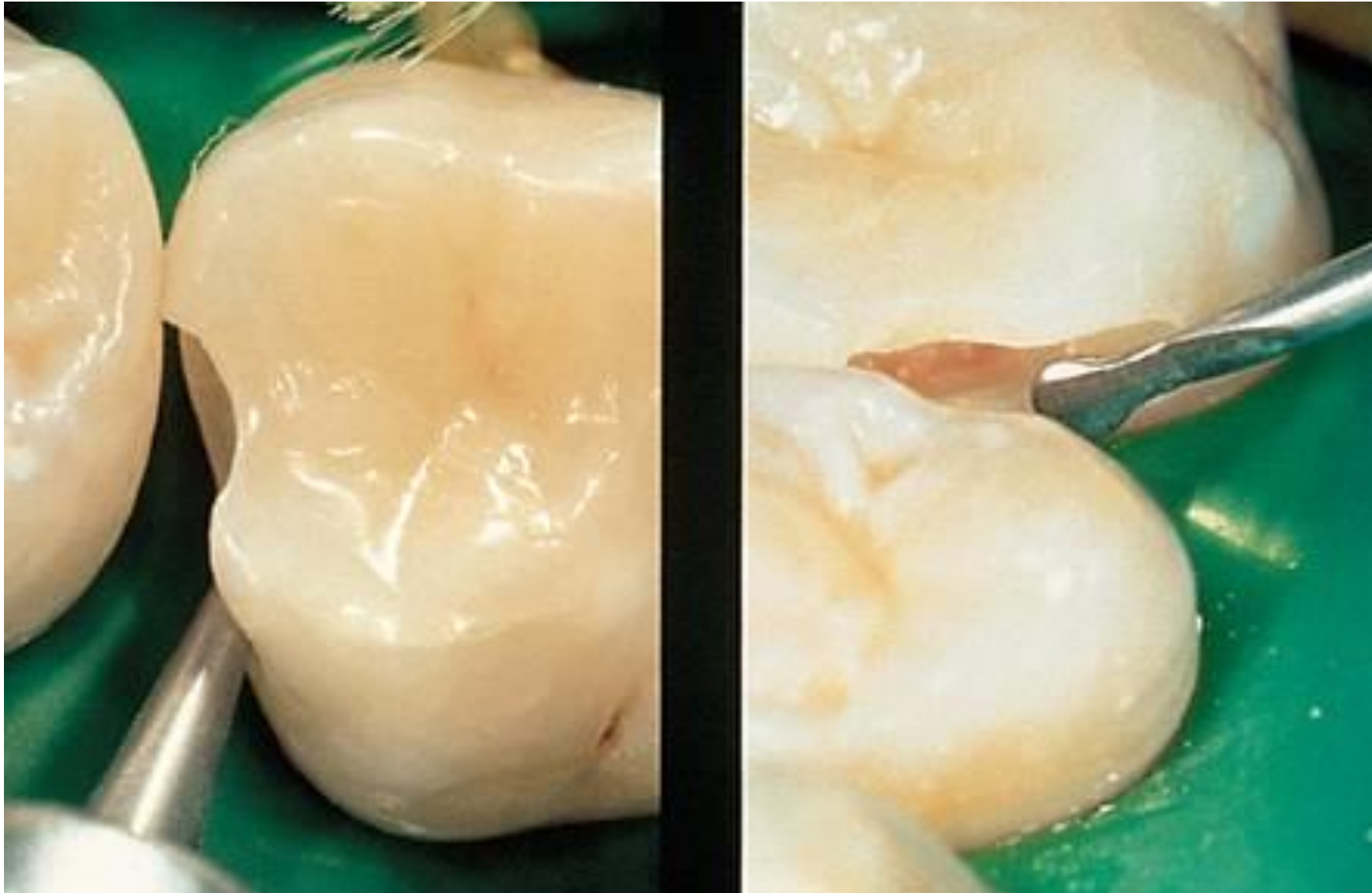
# Adhezivní slotová preparace



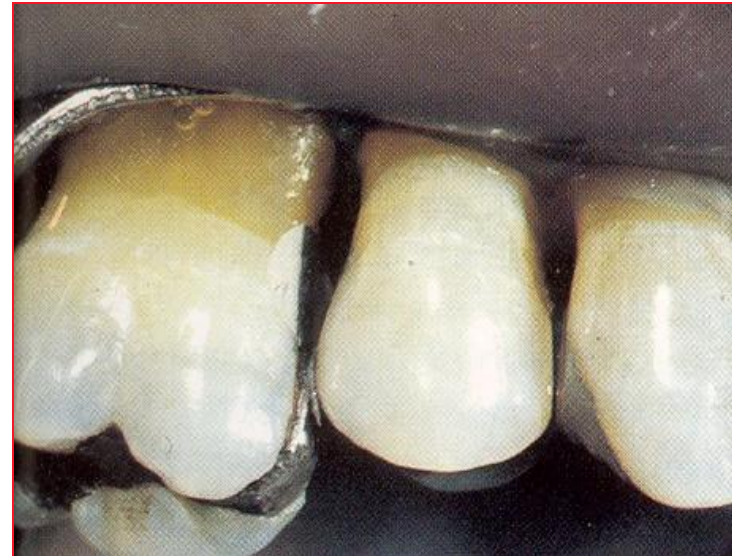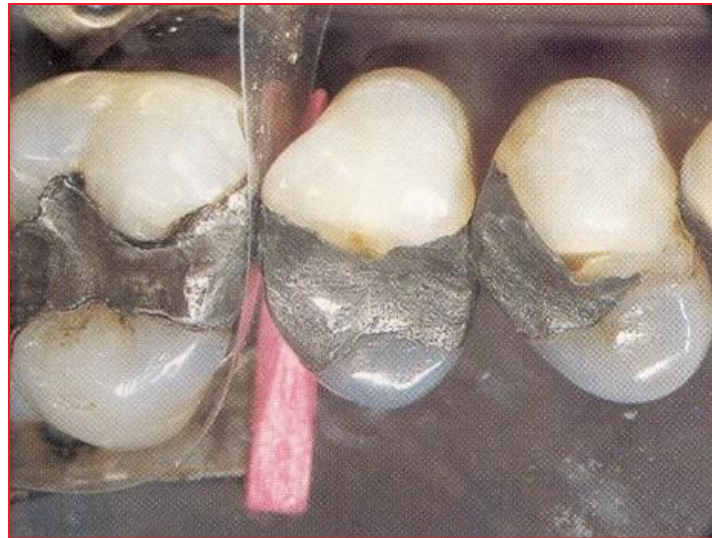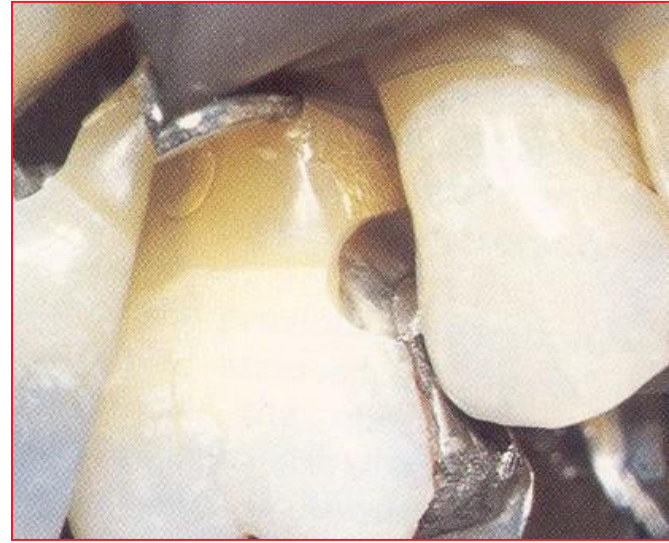
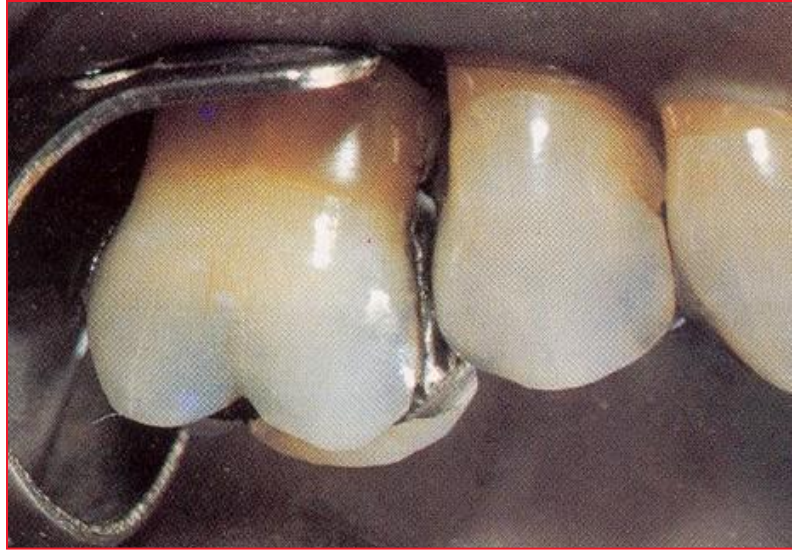# Approximal Caries



# Approximal Caries

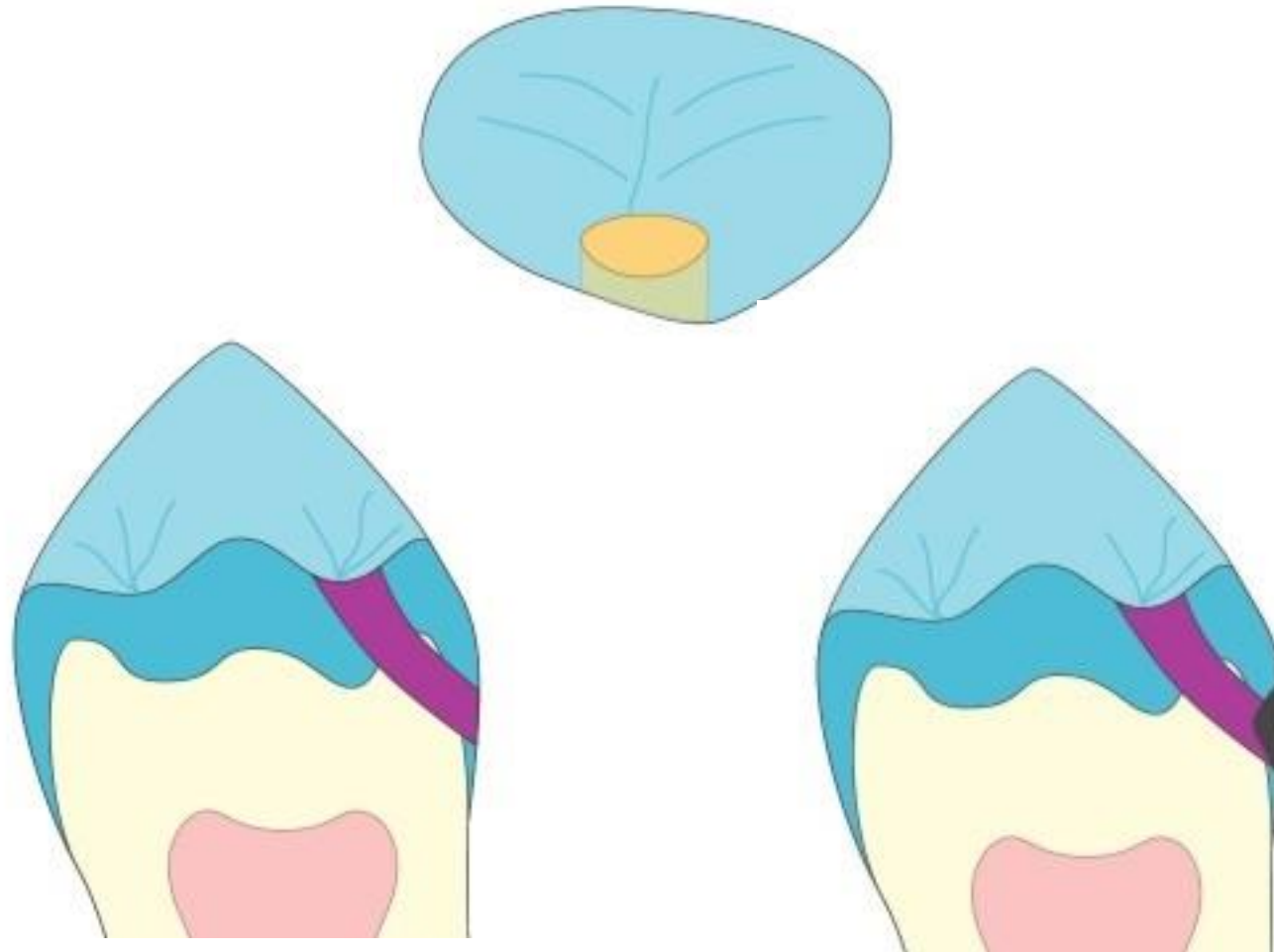


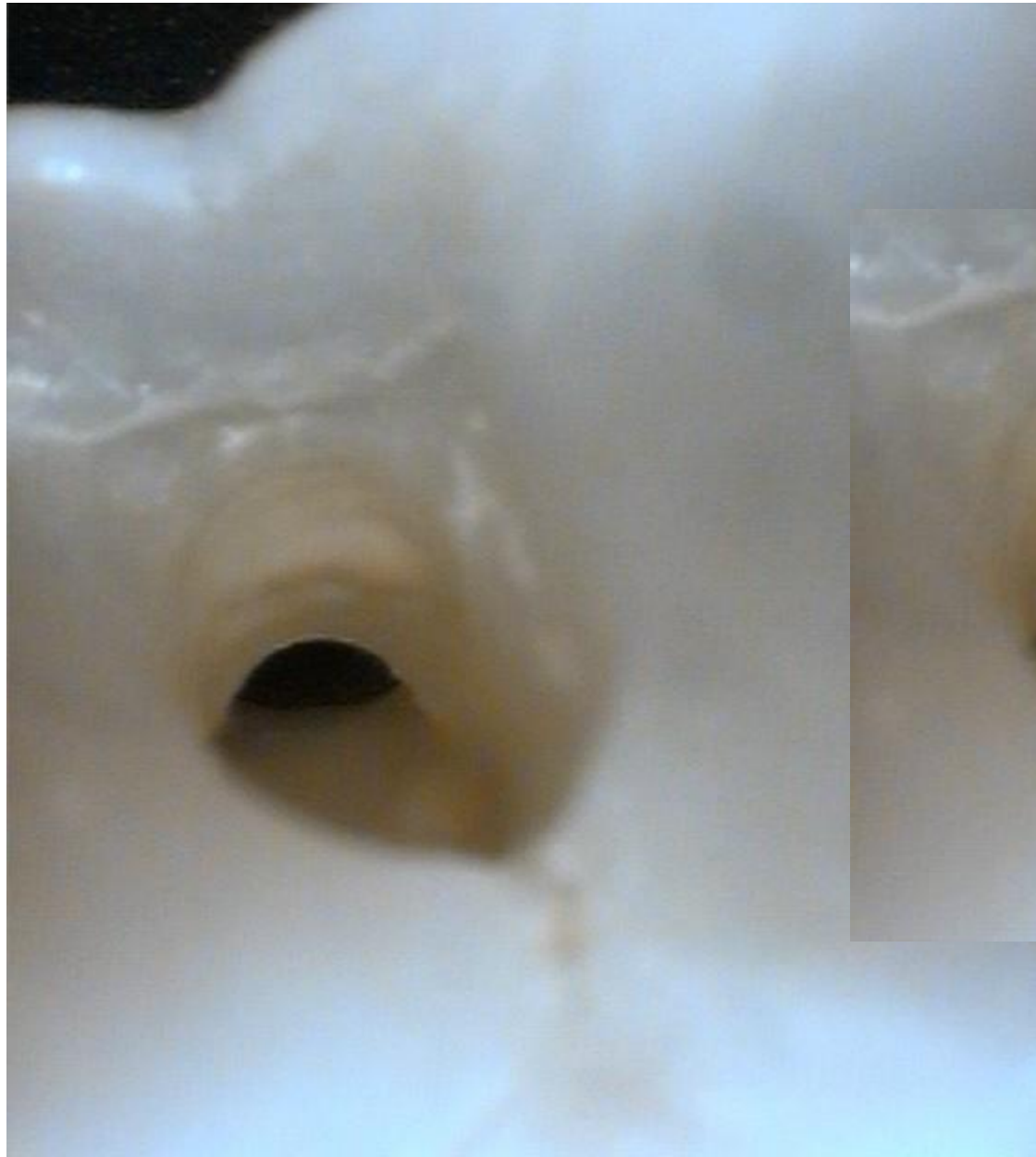


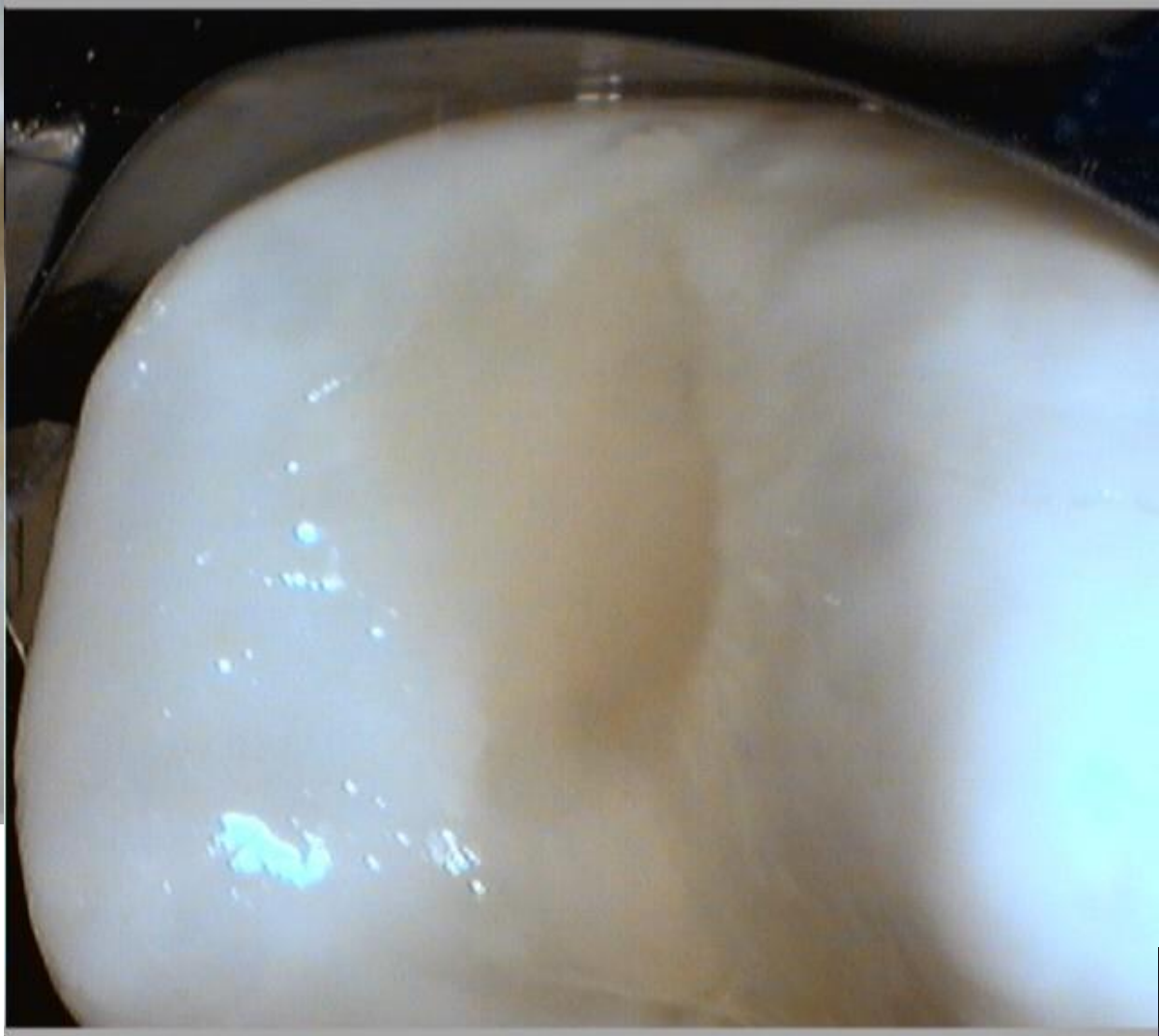
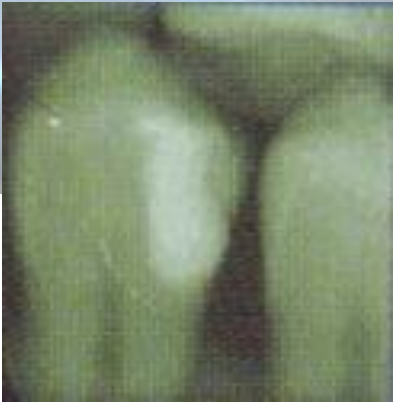
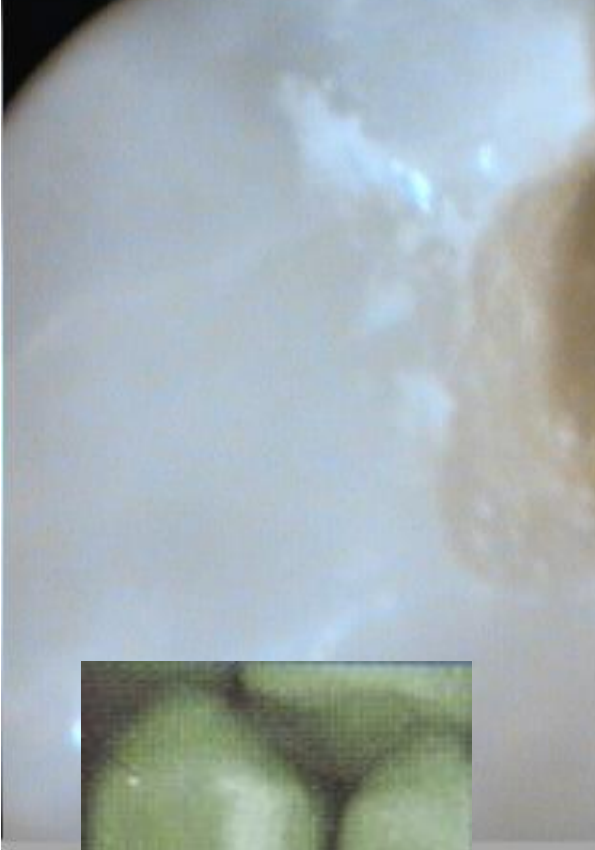


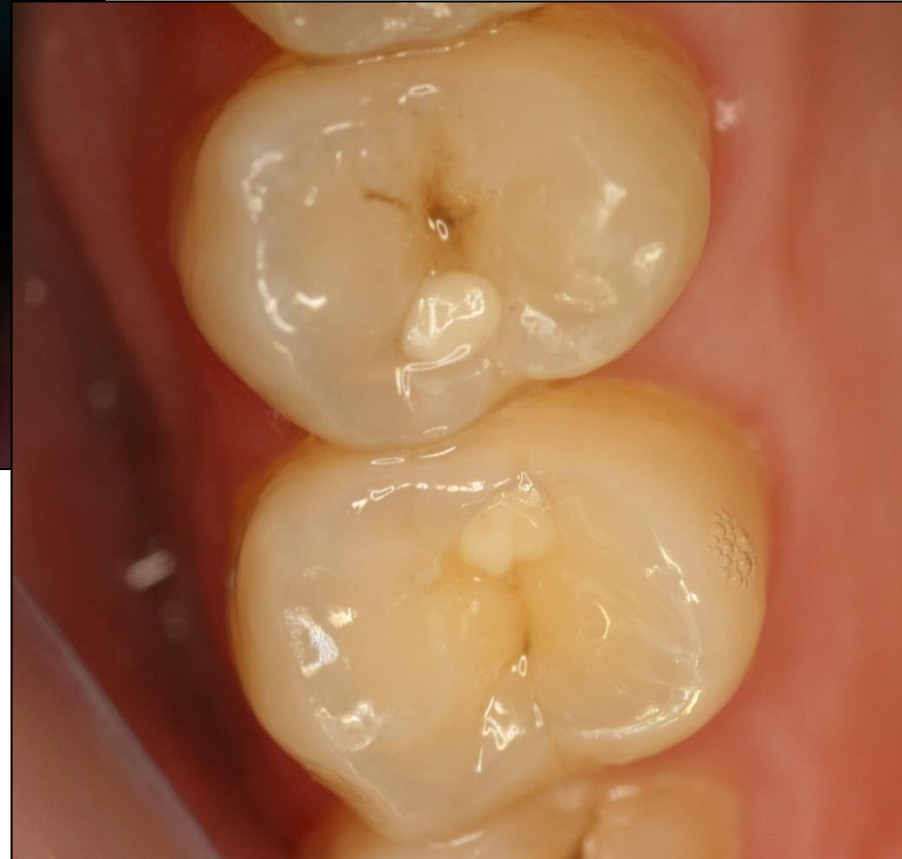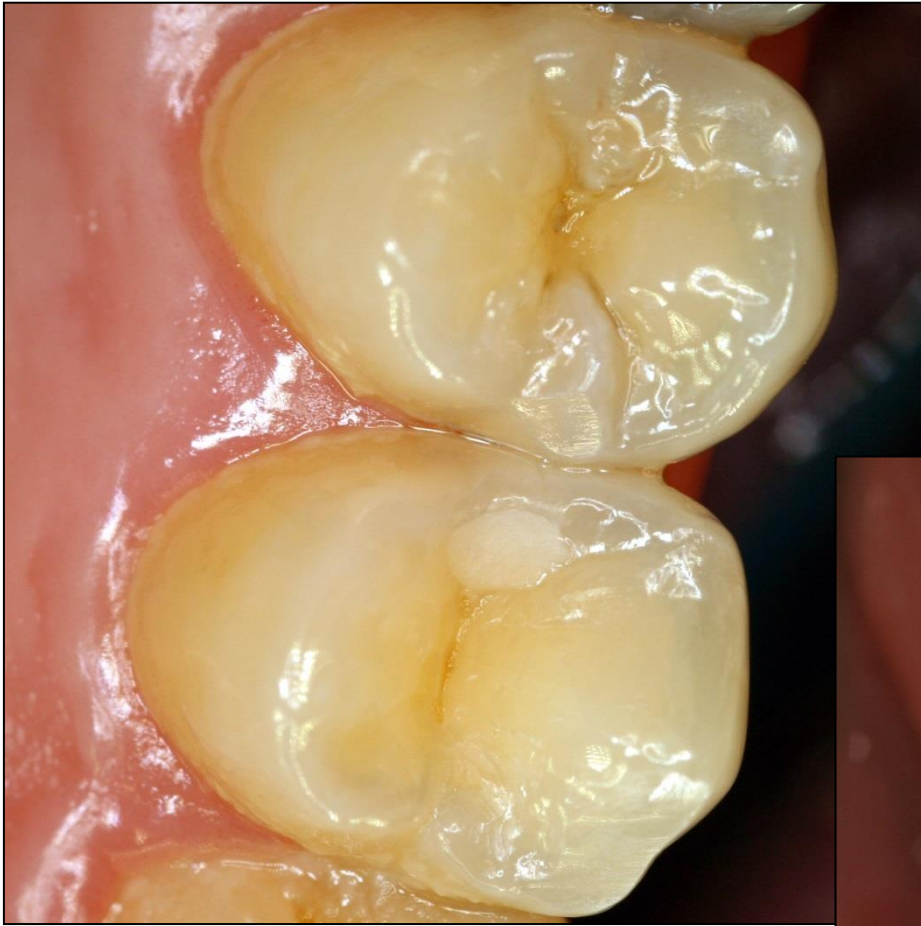# Tunnel preparation







Success?



Low caries risk  
Special small instruments  
Magnification  
BW post op