

20. Scrotal pain

Acute scrotal pain can be divided into **traumatic** and **non-traumatic**.

The diagnostic imaging **method of choice is ultrasound**. Due to surface deposit scrota use linear probe (linear probe usually has higher resolution than convex probe). **CT is not** utilised in the diagnosis of scrotal disease, it can be used only in the staging of distant metastases of testicular tumors. Exceptionally, MRI can be utilised (e.g. in non-conclusive ultrasound).

Traumatic pain scrota

In the case of **traumatic scrota pain**, we evaluate the extent of changes in the testis, epididymis or scrotum. The hematoma in the ultrasound image is a mixed echogenic formation without vascularization with different proportions of the fluid portion. Vascularization can be verified by Doppler examination or in questionable cases by application of a contrast agent. Testicular rupture is rare due to the tight fibrous envelope of the tunica albuginea.

The trauma of male genitals includes injury of the penis, e.g. penile fracture (rupture of tunica albuginea). In case of rupture of tunica albuginea, surgical intervention is indicated. In disputable cases, it is advisable to perform an acute MRI!

Non-traumatic pain scrota

The aim of ultrasound examination in **non-traumatic pain** is to **distinguish surgical from non-surgical diagnosis**.

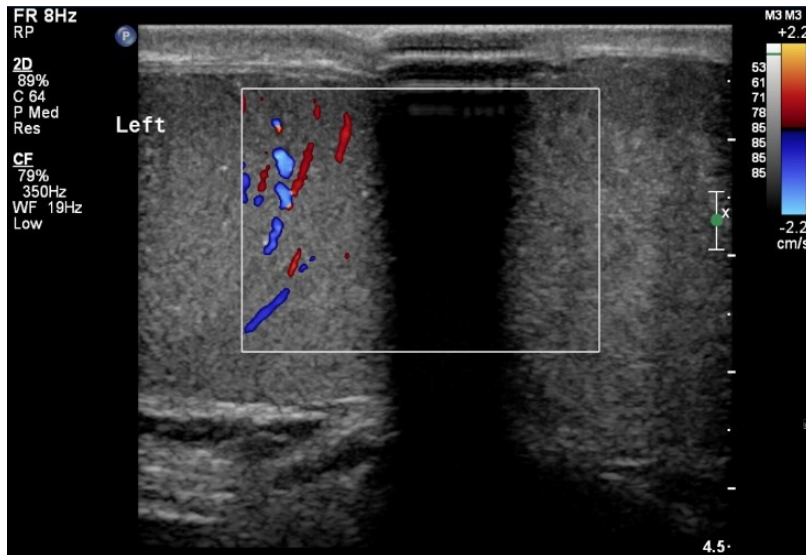
The most common causes of acute scrota pain include **seminal cord torsion**, **testicular torsion**, and **acute epididymitis**. Uncommon are strangulated scrotal hernias, acute testicular infarction, testicular tumor or idiopathic scrotal edema.

The most frequent cause of non-traumatic pain scrota in adolescents and adults, is acute **epididymitis** manifested by inflammatory swelling of scrotum (scrotum show typical signs of inflammation such as rubor, calor, dolor, and tumor). Clinically, the disease is accompanied by fever and pathological findings in the urine. The ultrasound shows edematous enlargement of the epididymis (all or part of it, most often cauda), and its hypervascularization. When inflammation spreads to the surroundings, there is also hypervascularization of the testis (compared to the bilateral testis), edema of scrotal envelopes and the presence of reactive hydrocele. The goal of ultrasound is to **rule out the presence of an abscess** that would require surgery and to rule out testicular torsion.

The most common cause of non-traumatic pain scrota children is **testicular torsion or torsion of testicular appendages** (testicular torsion is very rare in older than 35 years). Clinically, both units are manifested by sudden pain (in orchiepididymitis, the onset of pain is slower). Initially, inflammatory changes of the scrotum are not expressed, there is no fever and the finding in the urine is normal.

Torsion of the seminal cords (testicles) is an urgent diagnosis that must be resolved by manual or surgical detorsion **within 6 hours**. After 6 hours, irreversible changes develop and there is a risk of impaired fertility or orchiectomy. On ultrasound, testicular torsion is displayed as the absence of blood flow in the affected testis in Doppler mode (can be compared to a contralateral normally perfused testis), reactive hydrocele may also be present. Within 6 hours of the onset of symptoms, the testis on ultrasound usually has normal appearance.

Torsion of the appendix epididymis or appendix testis is detected on ultrasound in only about 1/3 of cases. It is shown as an enlargement of the appendix with reactive hypervascularization of the surroundings. It can thus mimic epididymitis on ultrasound, but both units can be distinguished.



Ultrasound displays absence of vascularisation in the left testis – testicular torsion.