

# Radiography

# Radiography

- Roentgen tube – x- ray tube:

Cathode – anode – tension

Catode (heated) - electrons –against anode  
– brake - x ray radiation originates



# Radiography

- Imaging method completing clinical examination of patients

# Radiography

Principle:

X- rays going through various materials  
(tissues) are absorbed – image on the film  
(a special suspension AgBr – silver bromide)  
or digital receptors



**Rigid CCD Digital Sensor**  
**Sirona Dental Systems,**  
**LLC**

**Digital Phosphor Plate**  
**Air Technique, Inc.**


**F-Speed Dental Film**  
**Kodak Dental Systems**

# Roentgen tube X ray tube

Cathode  
wolfram  
(tungsten) filament inside  
*(heated – brought to white heat)*

*Focus – made of wolfram*

Anode



# Extraoral and intraoral radiography

- Extraoral:

The film is placed outside of oral cavity

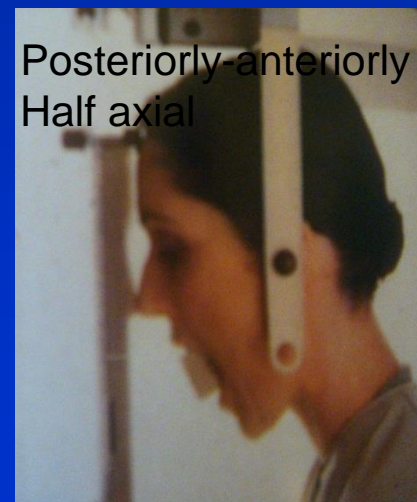
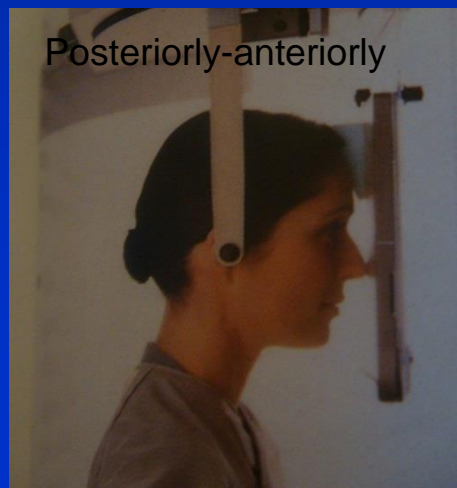
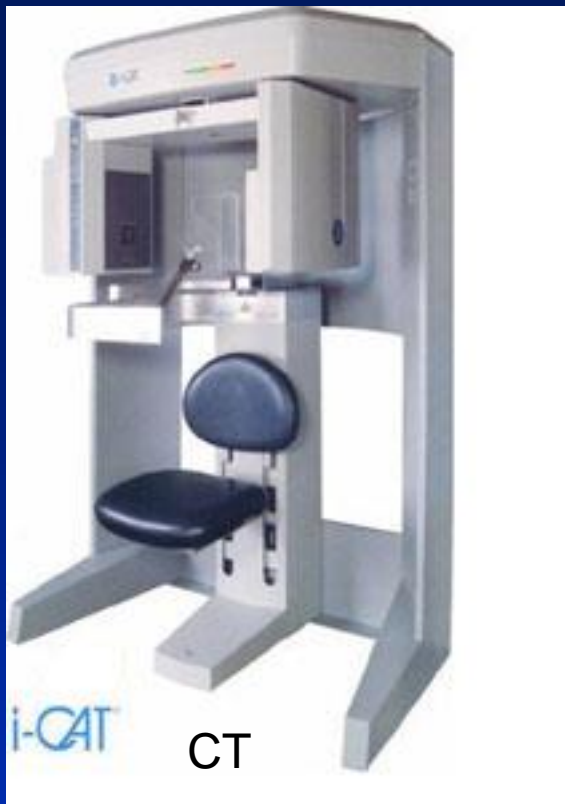
- OPG (orthopantomography)
- Teleradiography
- Special projections of a skull (posteriorly – anteriorly)
- Half axial
- Side projection (TMJ, mandible)
- CT

# Extraoral and intraoral radiography

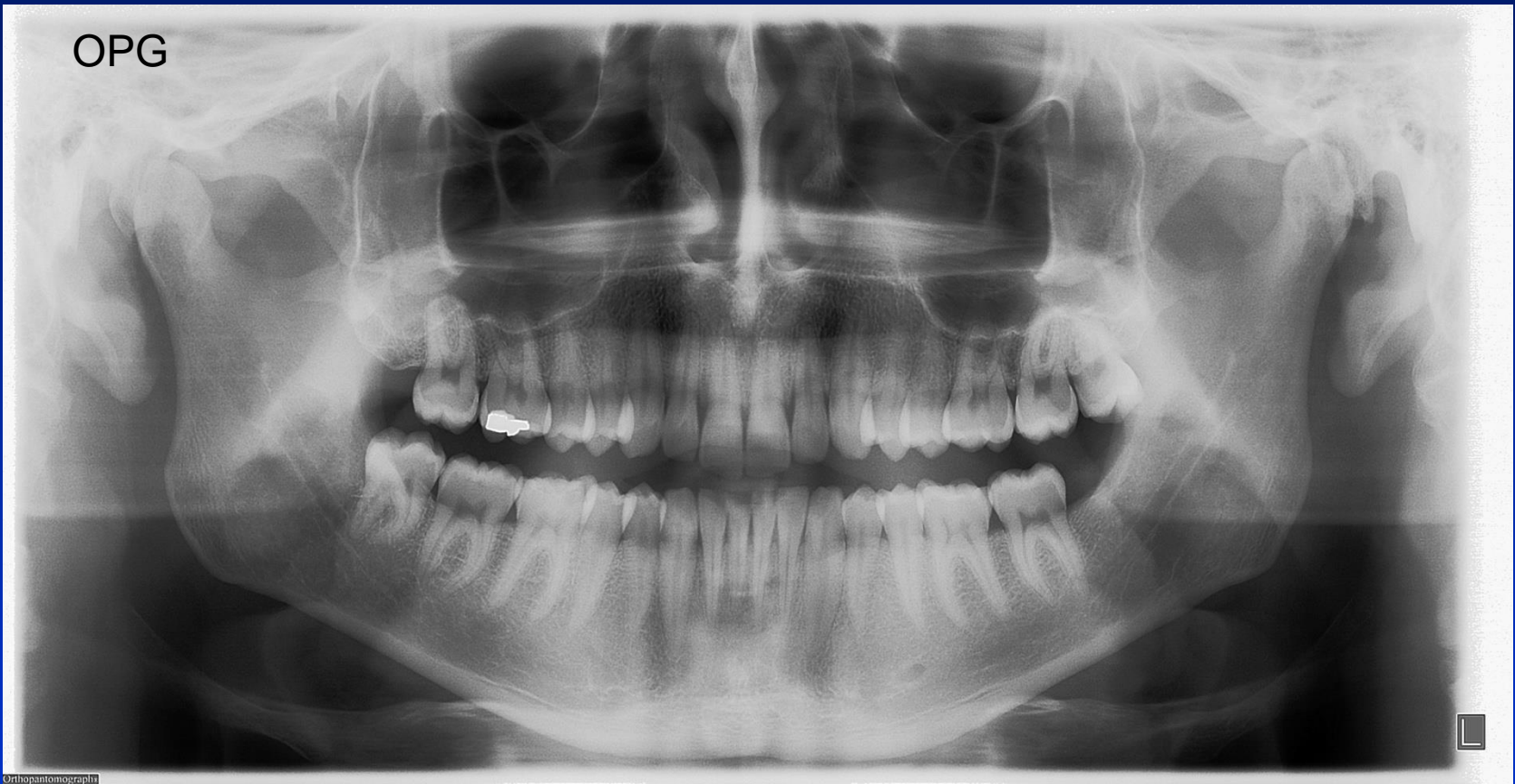Intraoral – the film is placed in the oral cavity – a special x-ray apparatus.

- Teeth
- Alveolar bone
- Periodontal space
- Fillings
- Caries
- Level of endodontic treatment





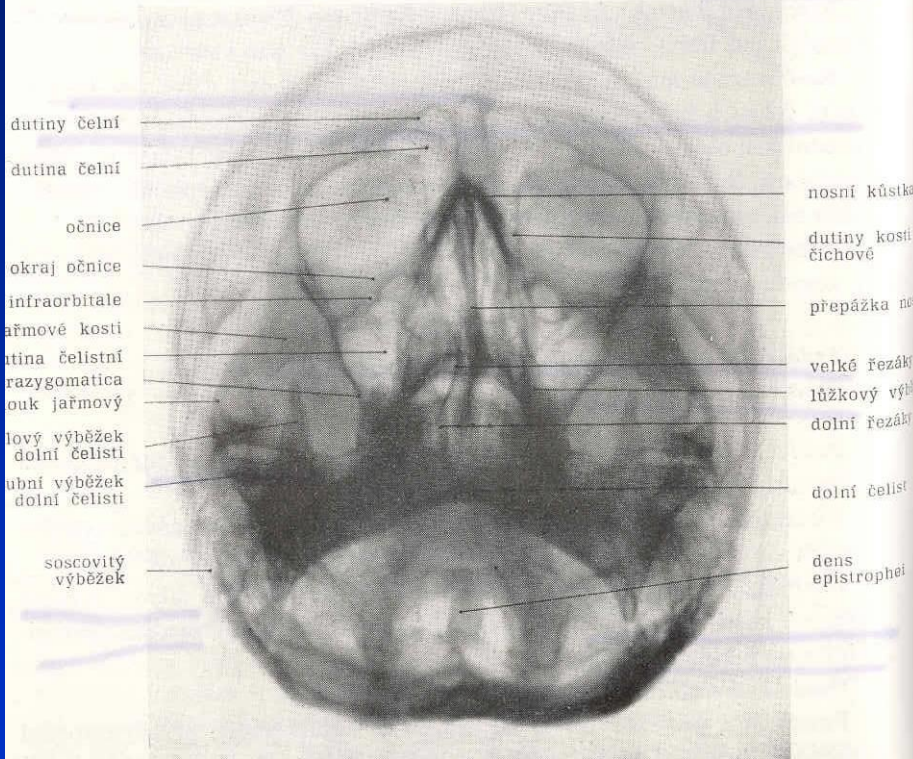
OPG



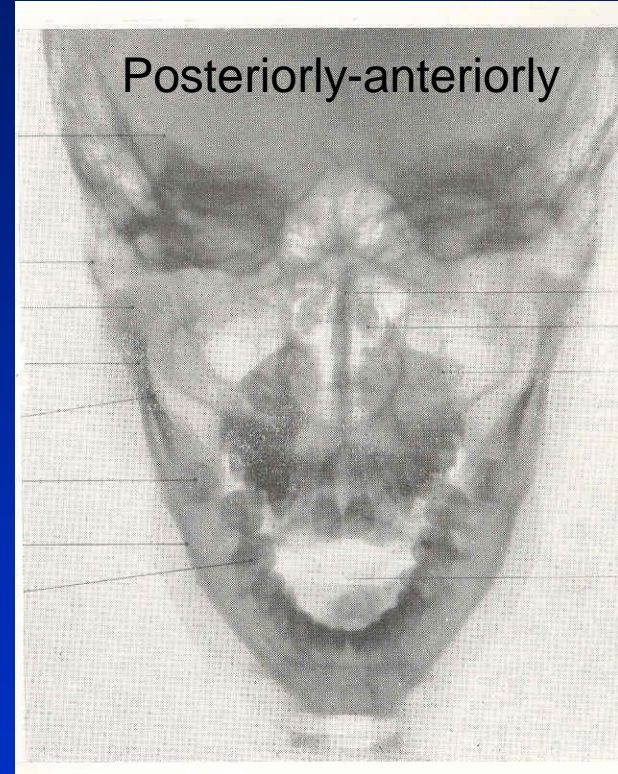
pohled zpredu

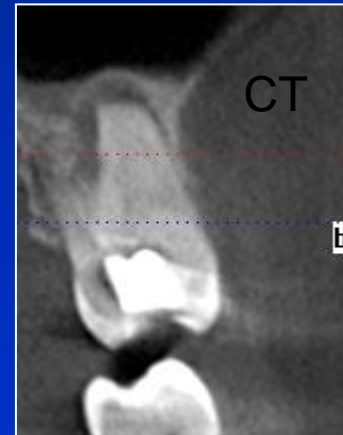
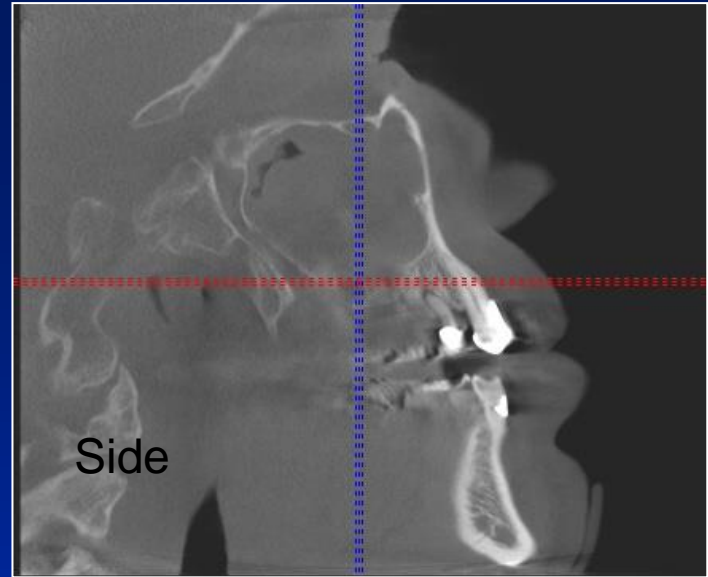
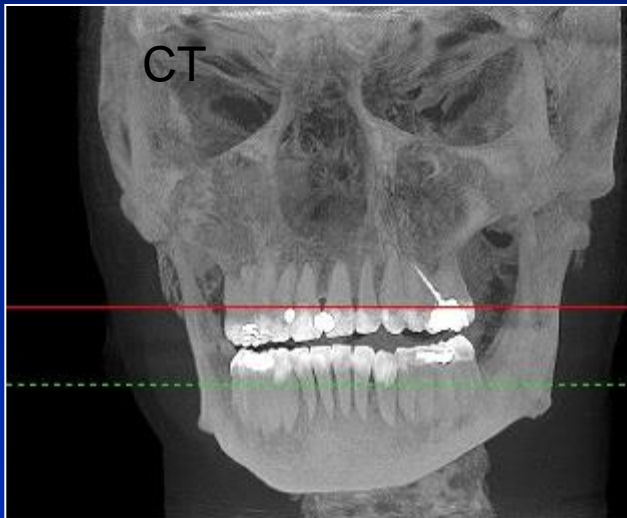
pohled z boku

## Half axial



## Posteriorly-anteriorly





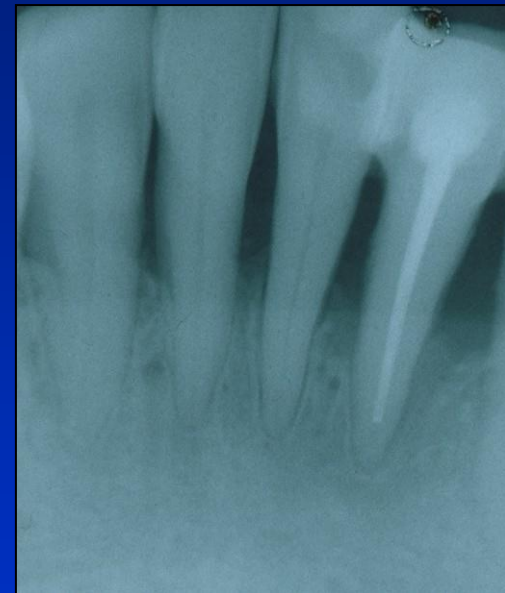
CT, 3D possibility

# Intraoral radiography

Film or receptor placed in oral cavity

Special apparatus

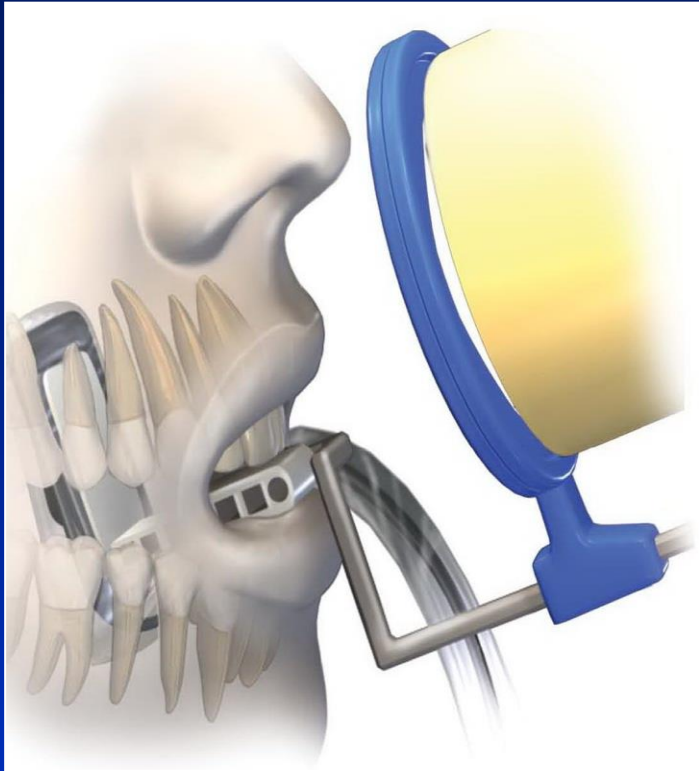
- Teeth
- Alveolar bone
- Periodontal space
- Fillings
- Caries
- Impacted teeth
- Level of endodontic treatment



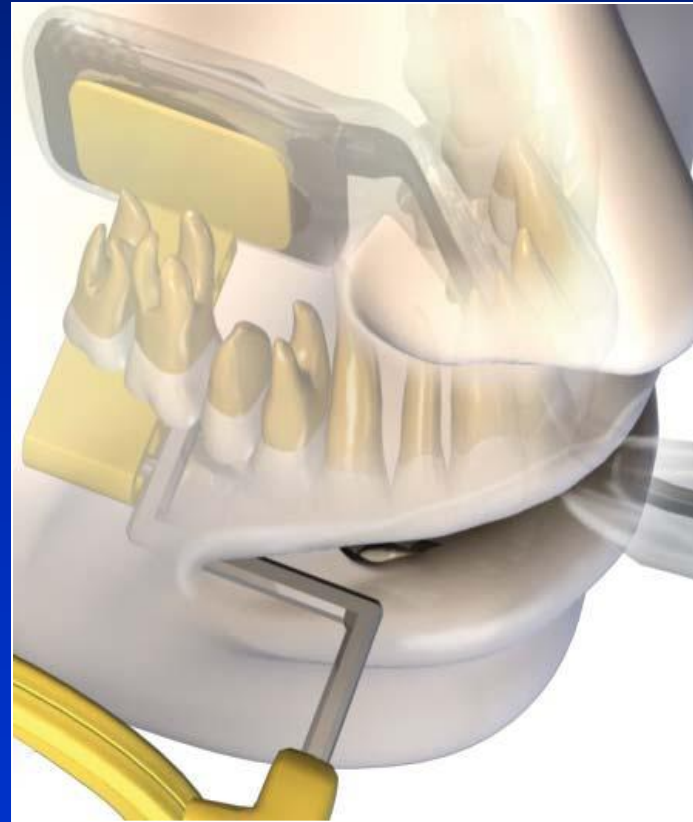# Position of the tubus

- In vertical plane
- In horizontal plane

In vertical plane

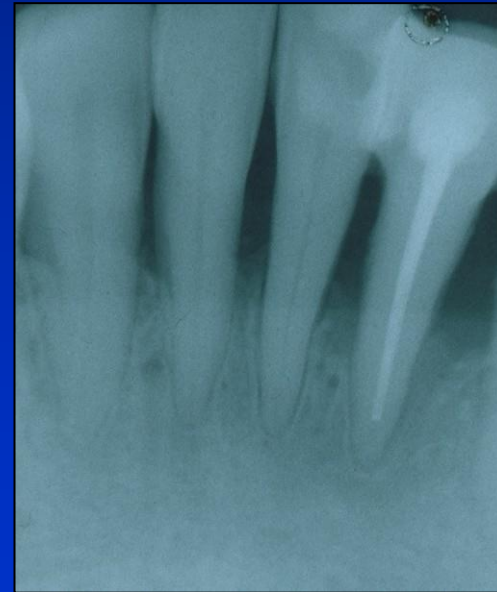
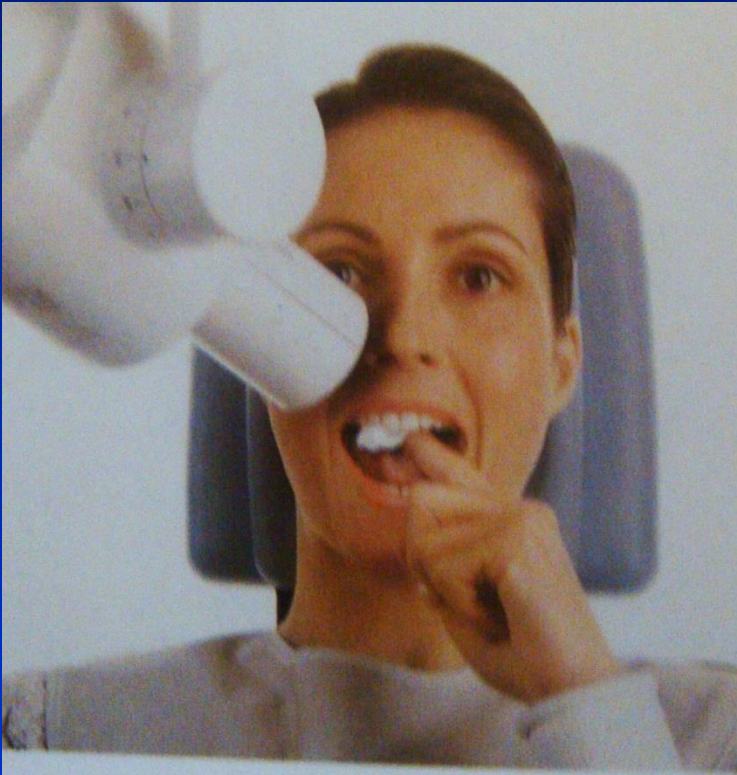


Paralleling technique  
Film or receptor in a special holder  
Parallel to long axis of teeth

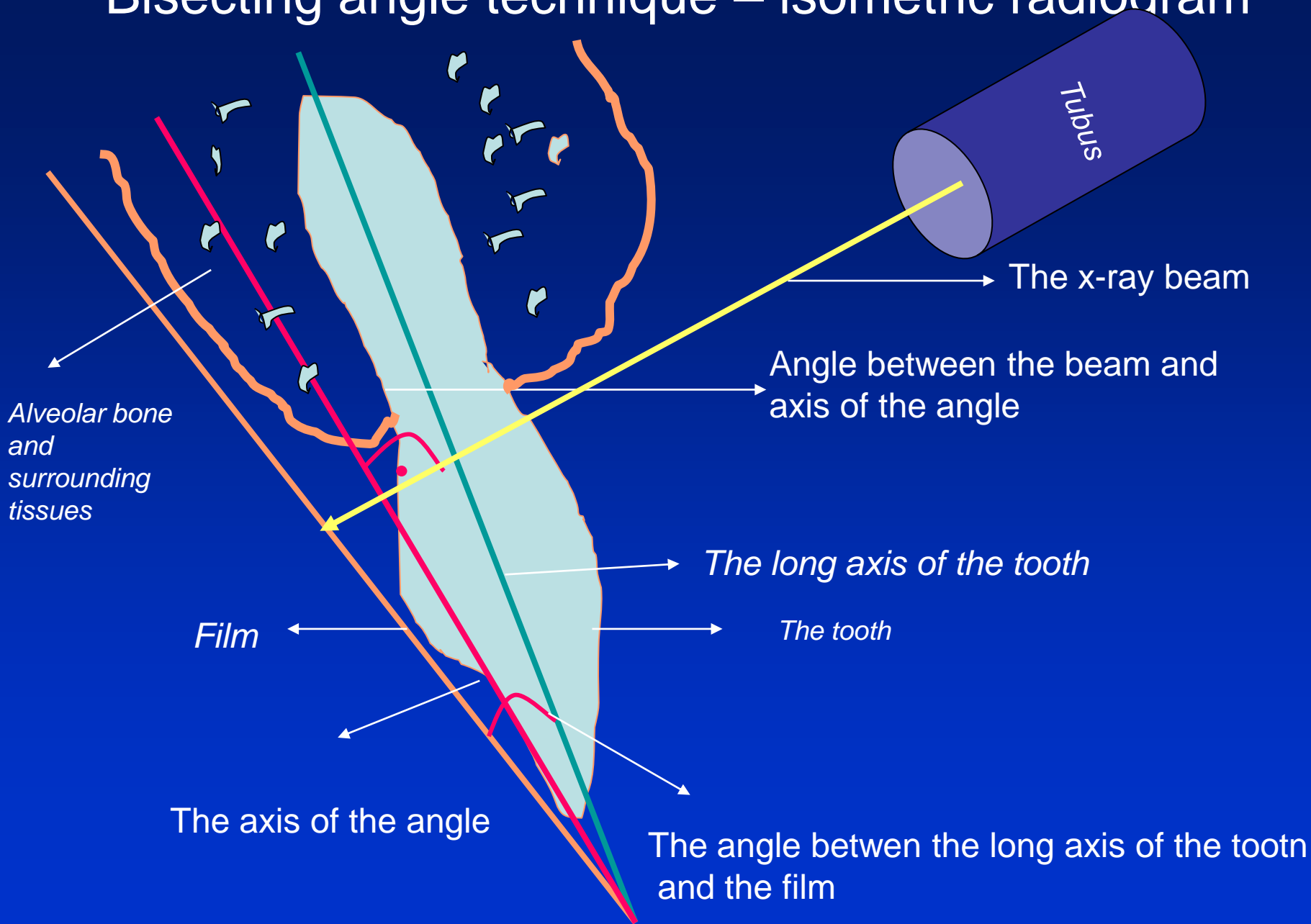




If paralleling technique is not possible use the bisecting angle technique



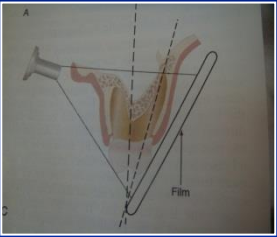
# Bisecting angle technique – isometric radiogram



# Hypometric and hypermetric picture

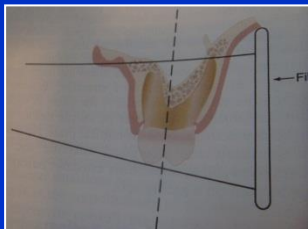
*Hypometric – the picture is smaller*

Central beam goes perpendicular on the tooth



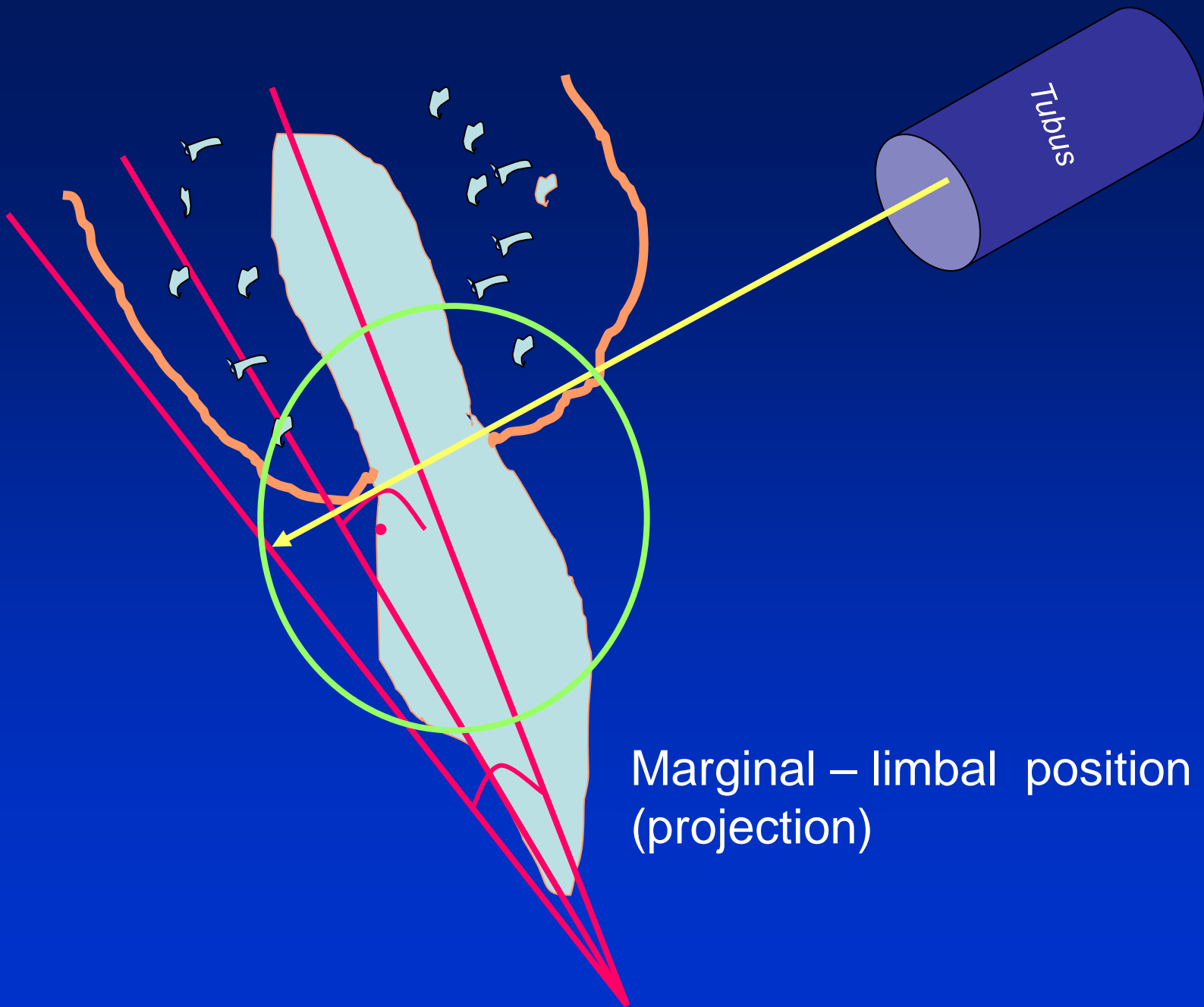
*Hypermetric picture – the picture is bigger*

*– central beam goes perpendicular to the film paprsek goes perpendicular to the film.*

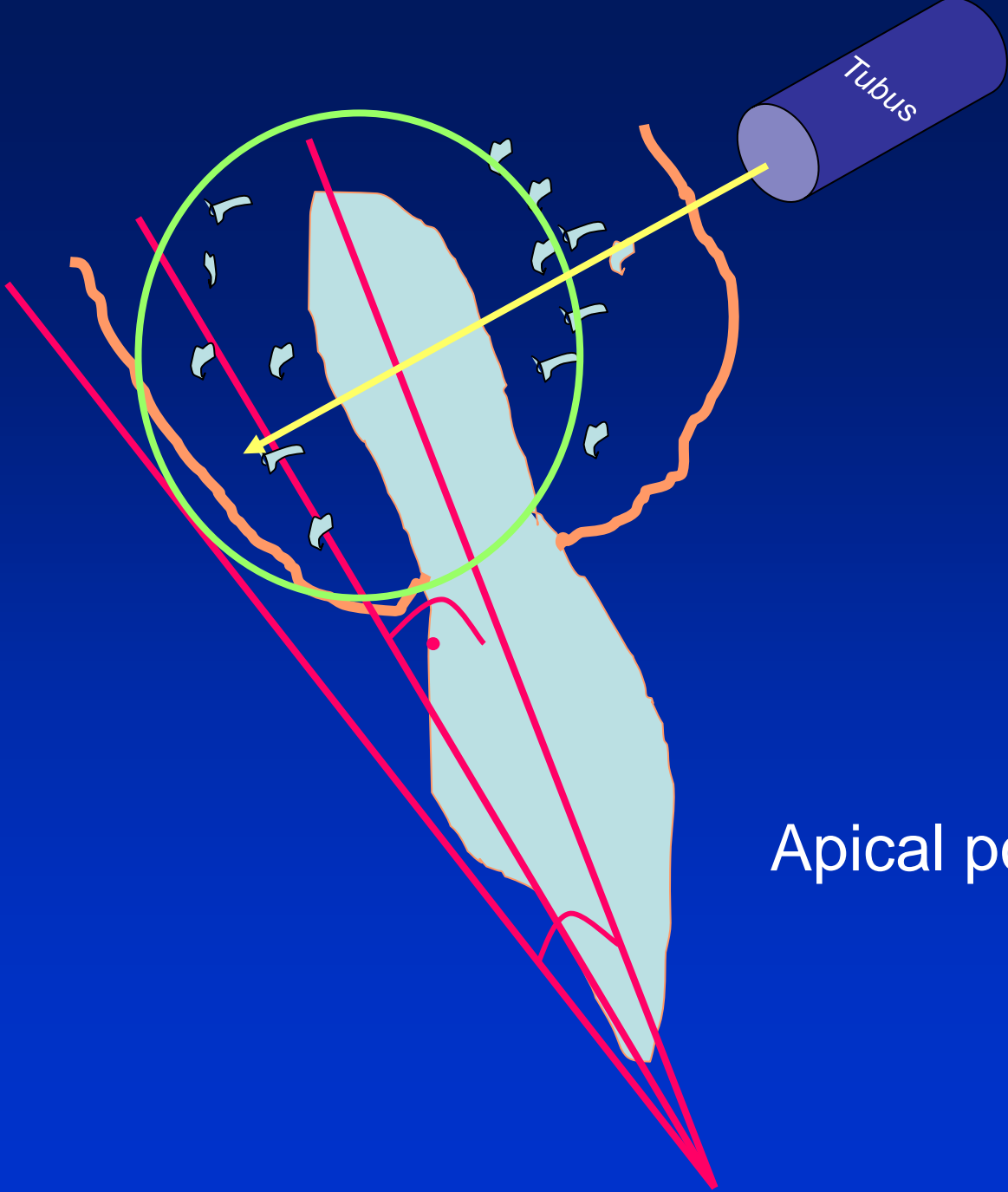


# The tubus can have various position

- Apical projection: the central beam goes through the apex area
- Periodontal projection: the central beam goes through the uper third of the root
- Coronal projection: the central beam goes through the crown.



Marginal – limbal position  
(projection)

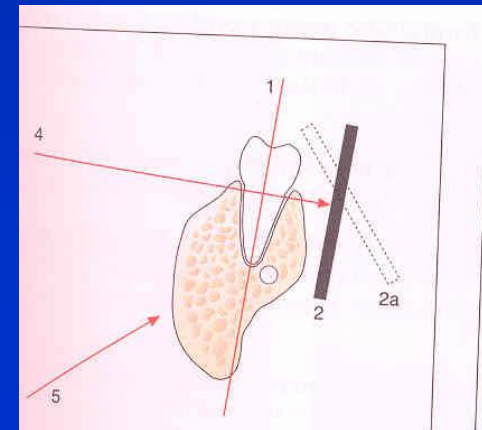
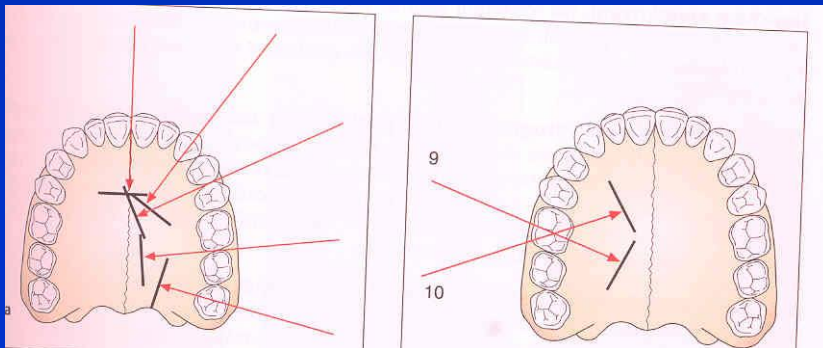


Apical position - projection

In horizontal plane

# Orthoradial and excentric projection

- Orthoradial – the central beam goes parallel to interdental septa
- Excentric– the central beam goes from distal or mesial side. (Useful for endodontics or impacted teeth esp. canine)





# Bitewing



Film or receptor is placed in a special holder, patient bites into

The central beam goes parallel to interdental septa

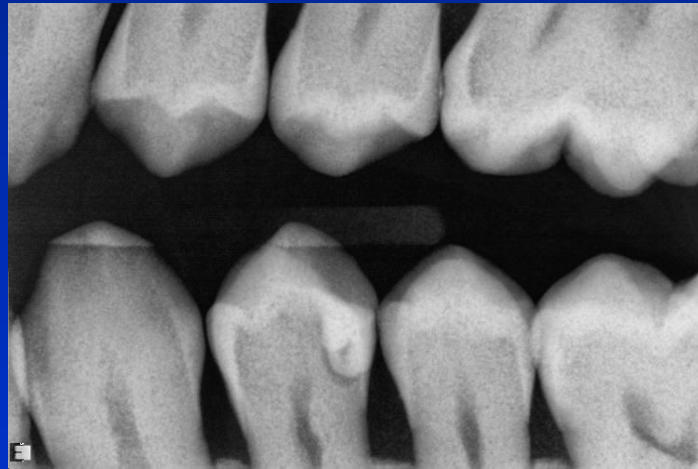
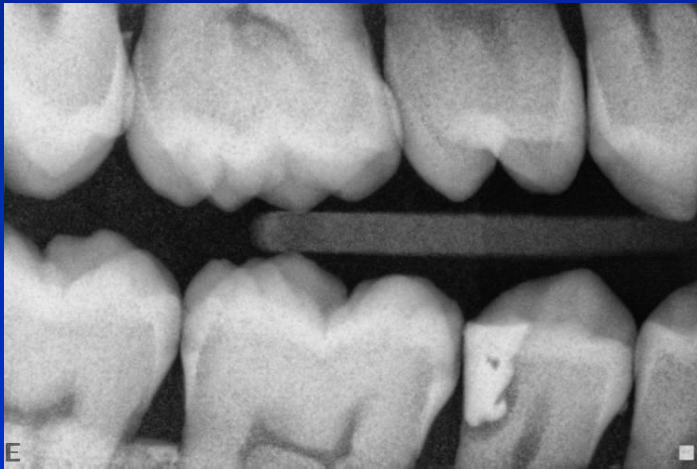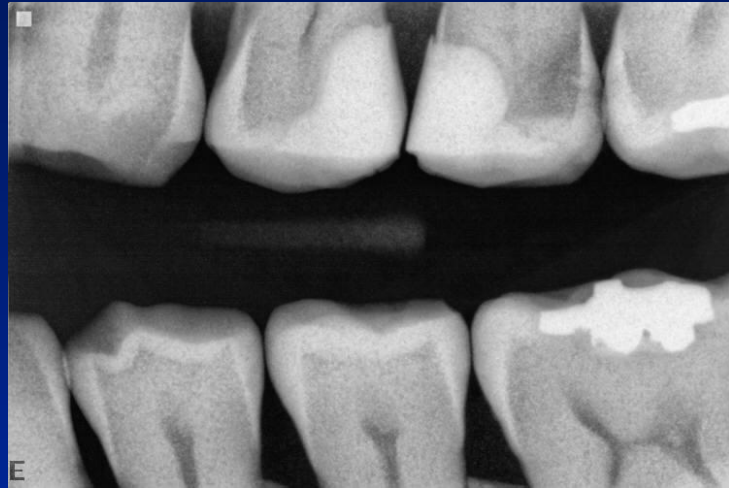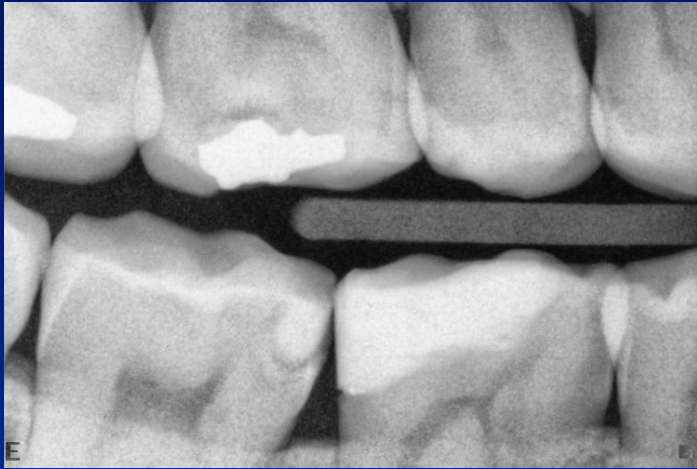Crowns of teeth are well seen  
– good for early diagnosis of dental caries in posterior area

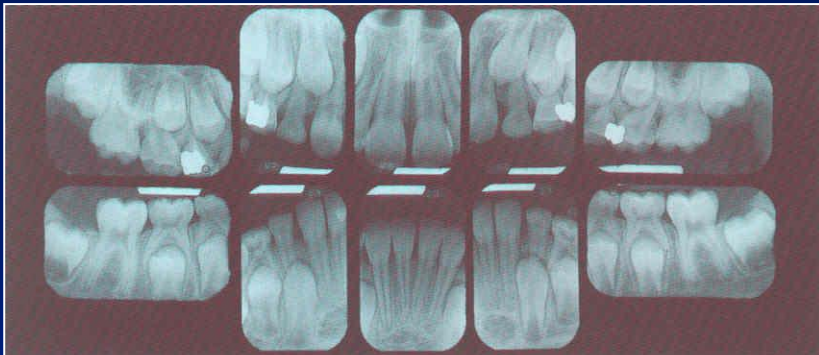
# Principle of imaging

- Irradiation is absorbed in various materials esp. in hard tissues. Accc to amount of absorbed irradiation radioopacity or radiolucency can be seen.

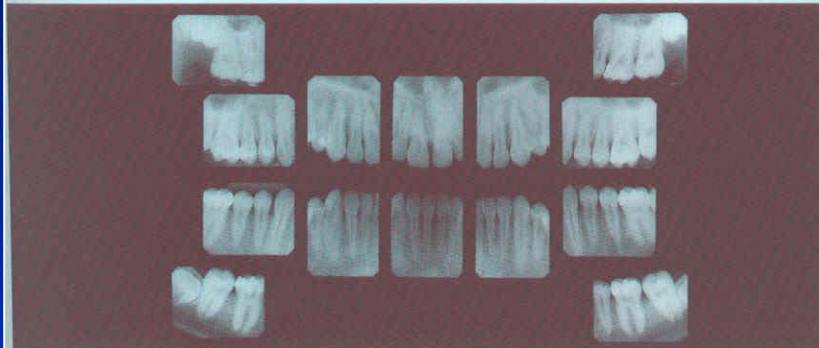
Radiolucency – dark

Radioopacity - white

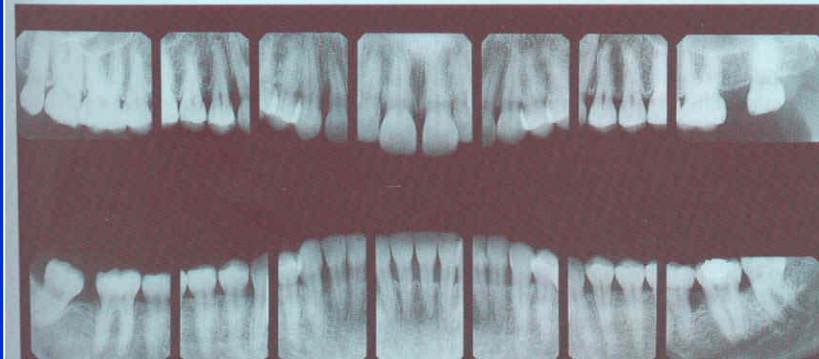




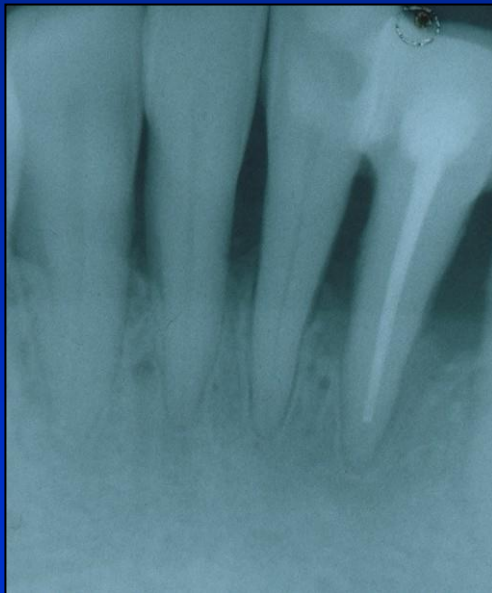
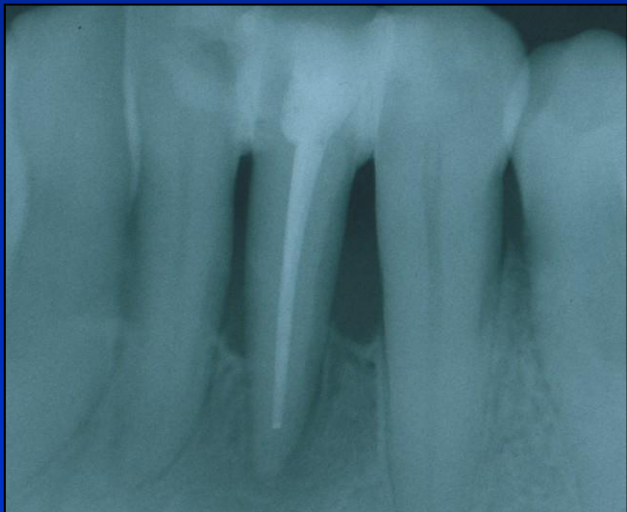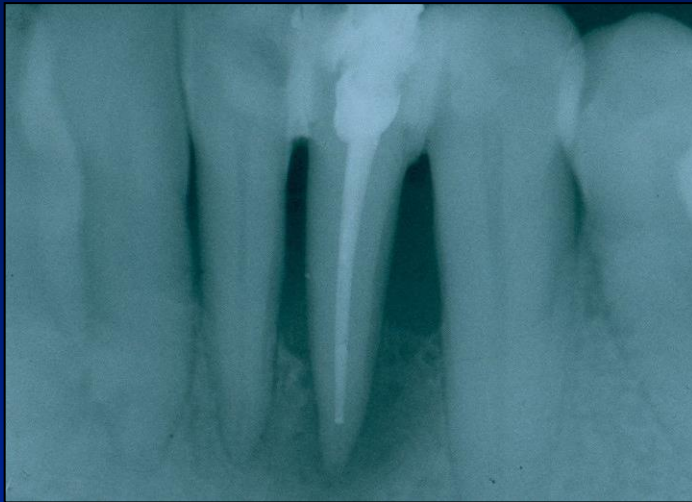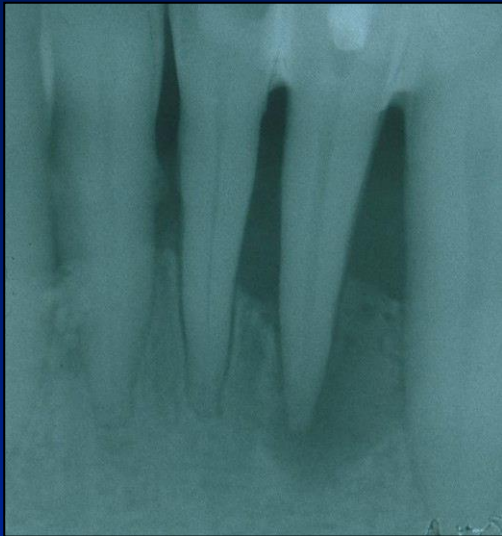58



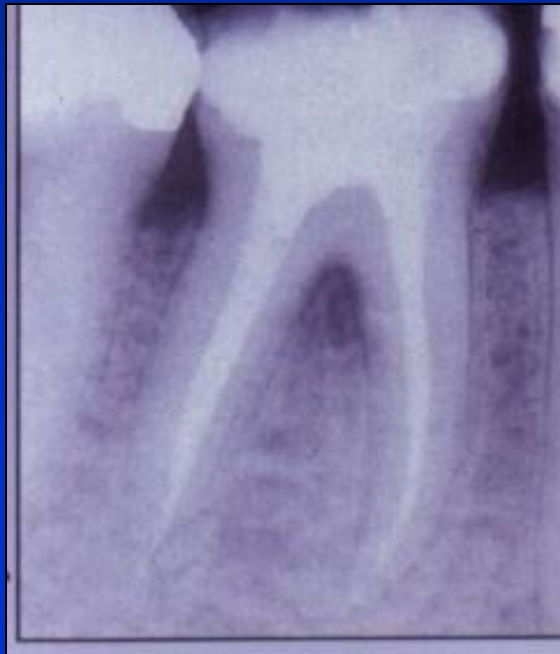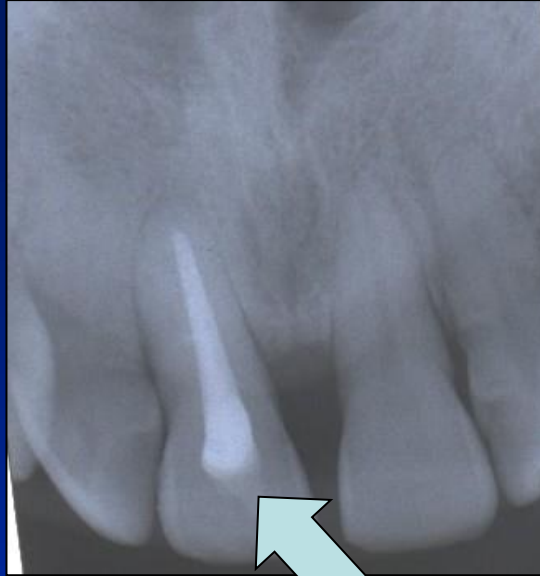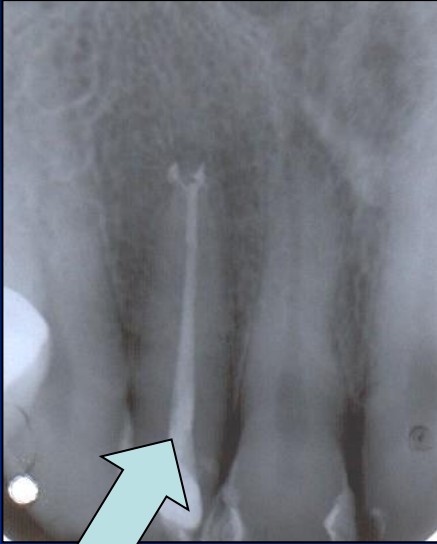59

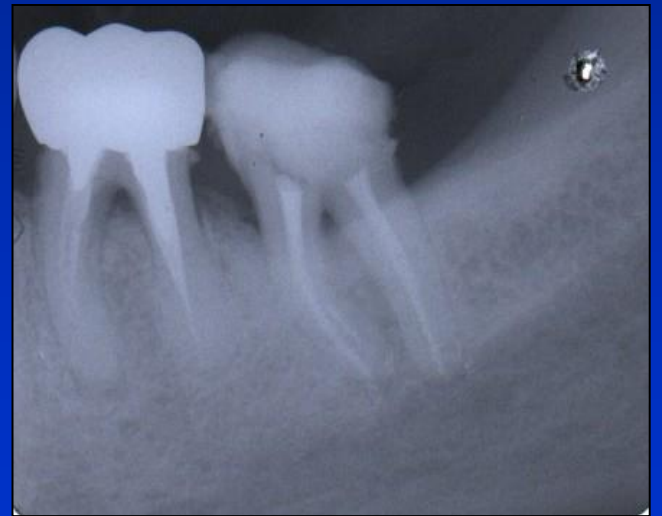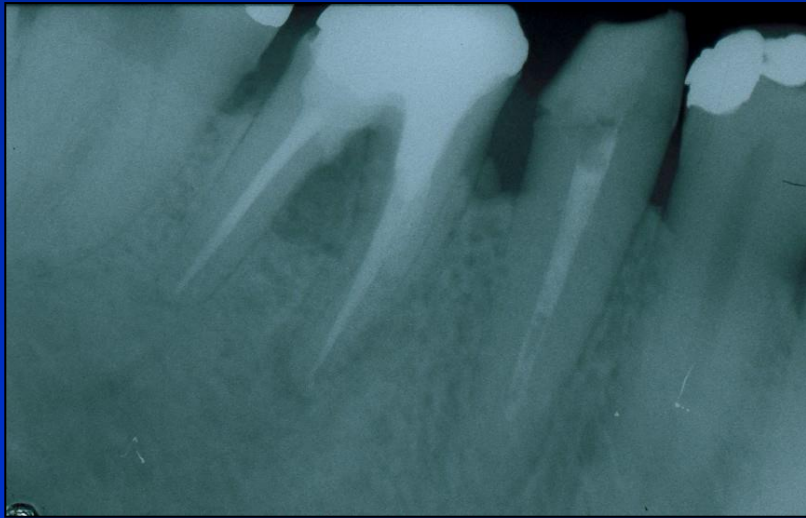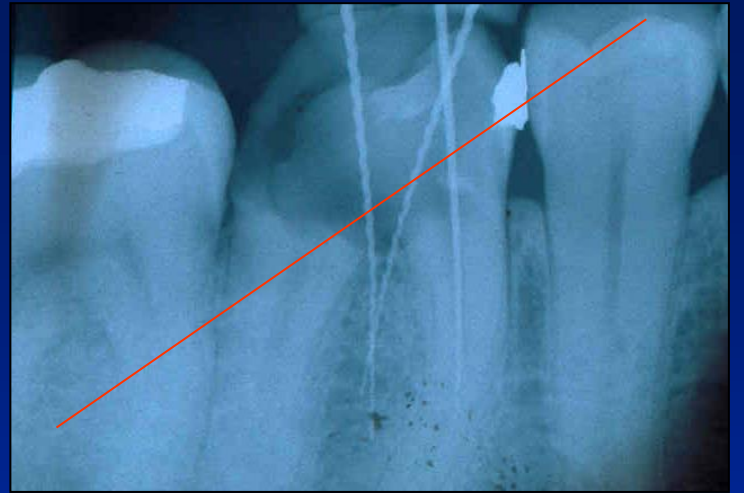


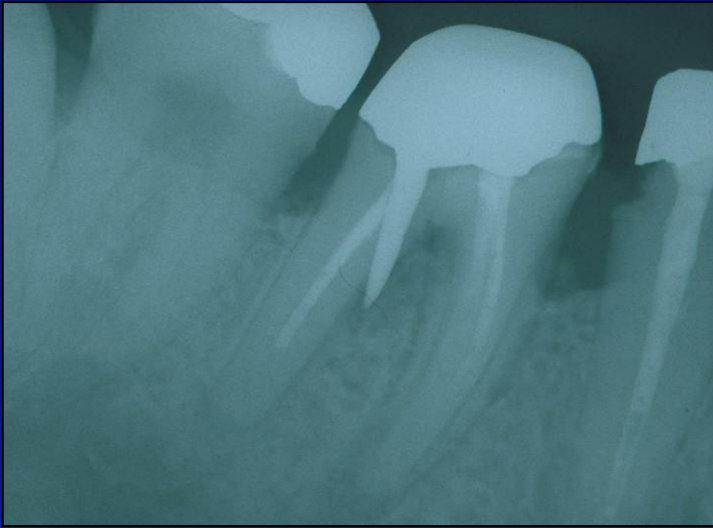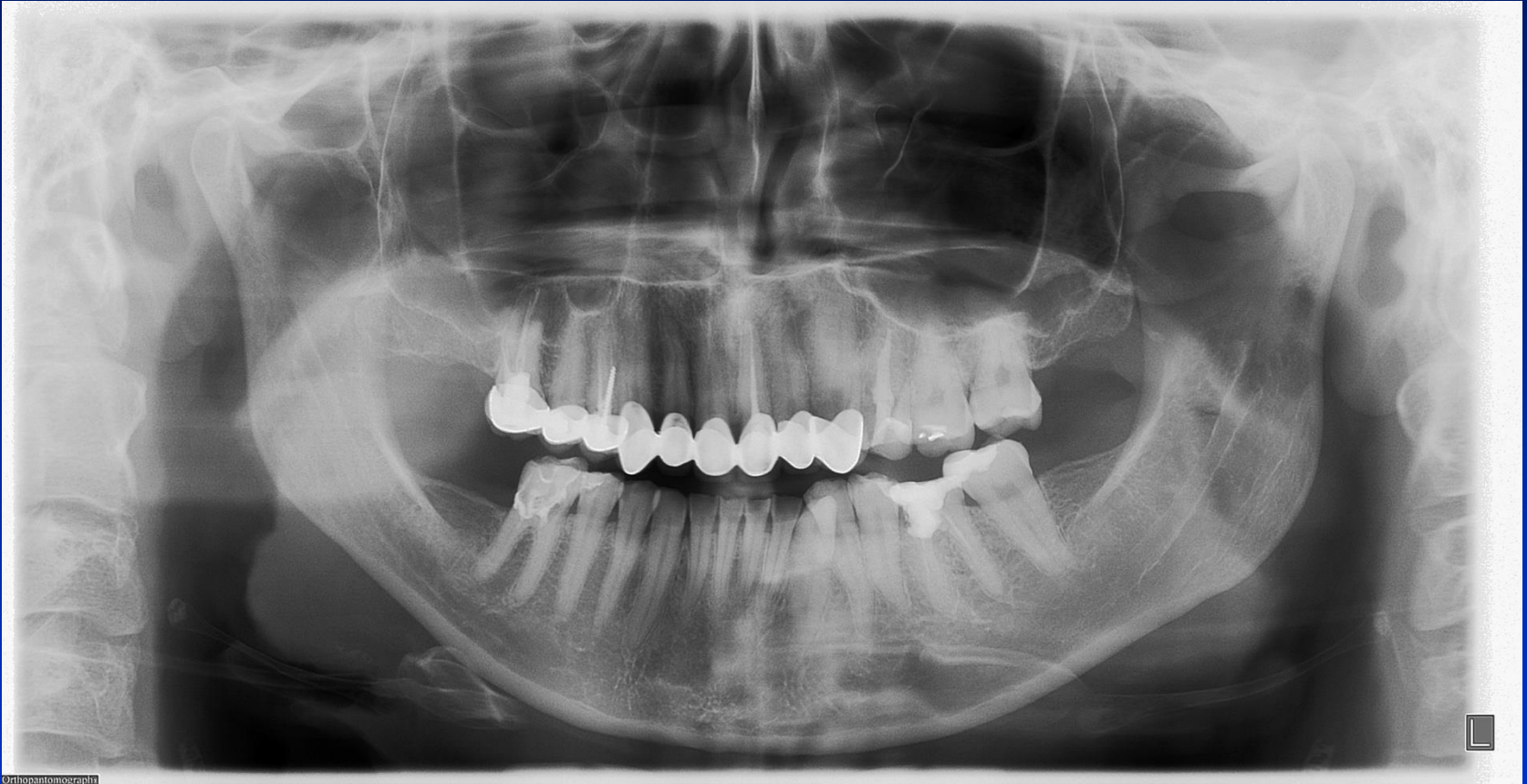- Rtg status



i.o.

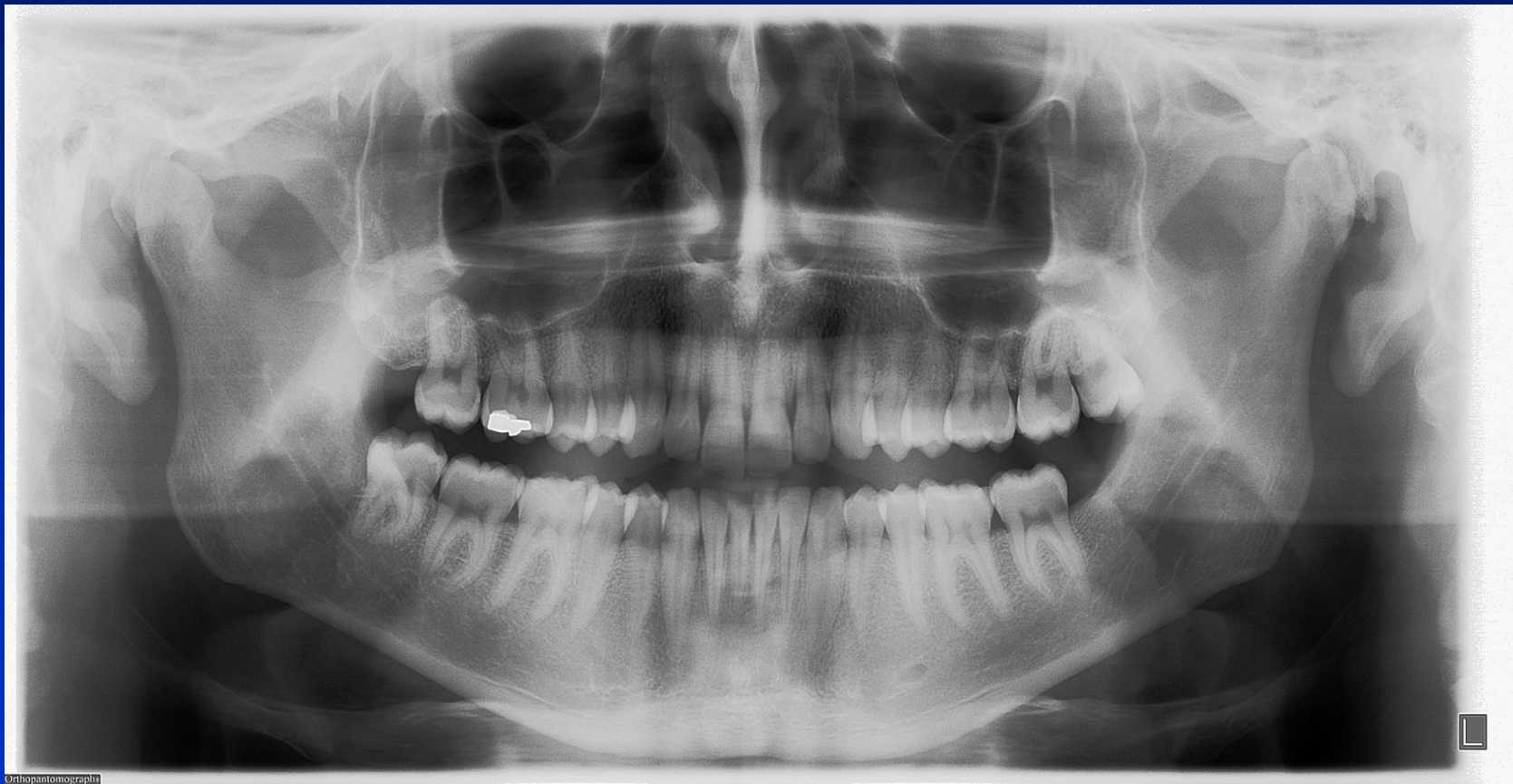



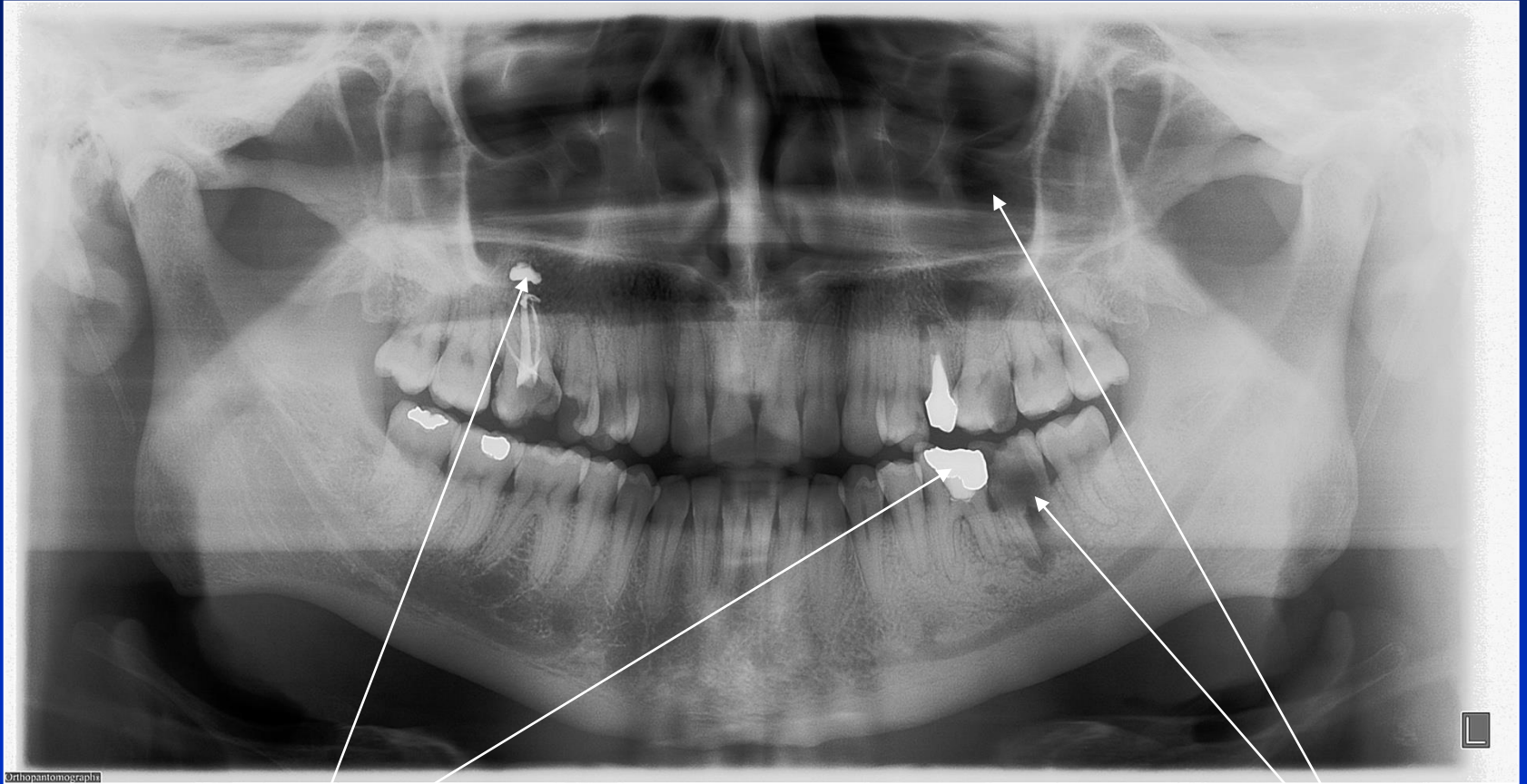


OPG





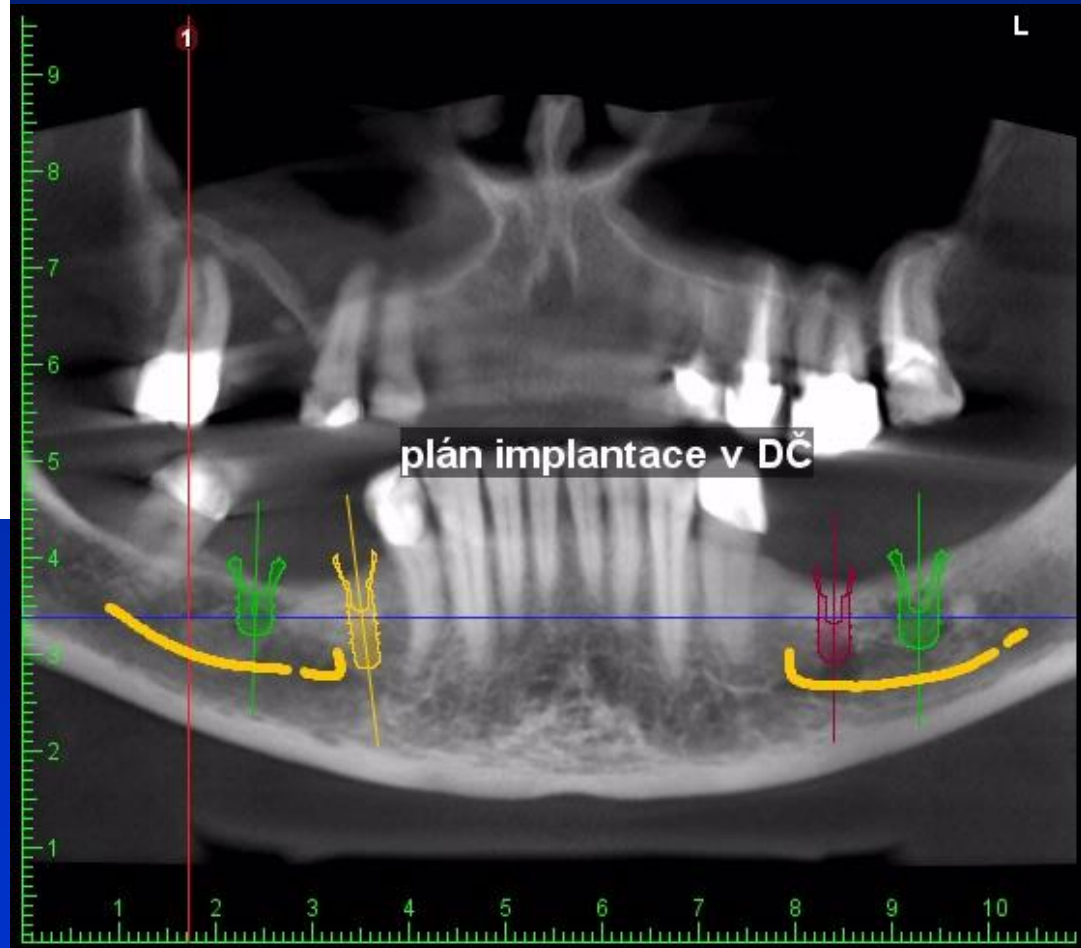
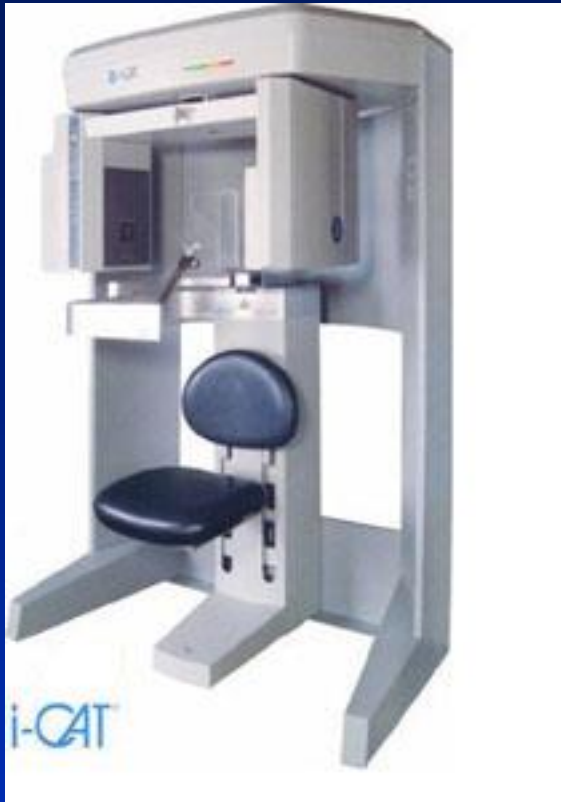Orthopantomograph

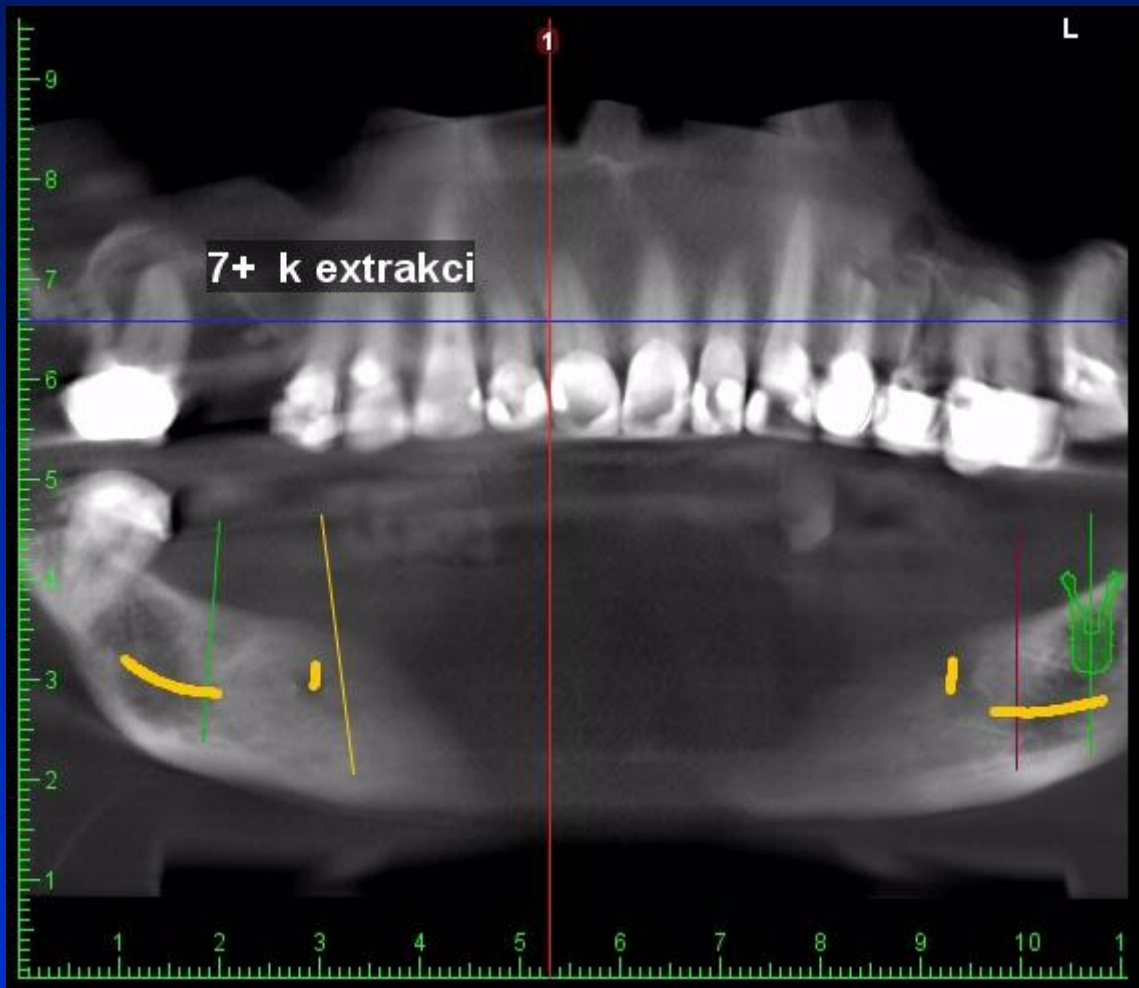


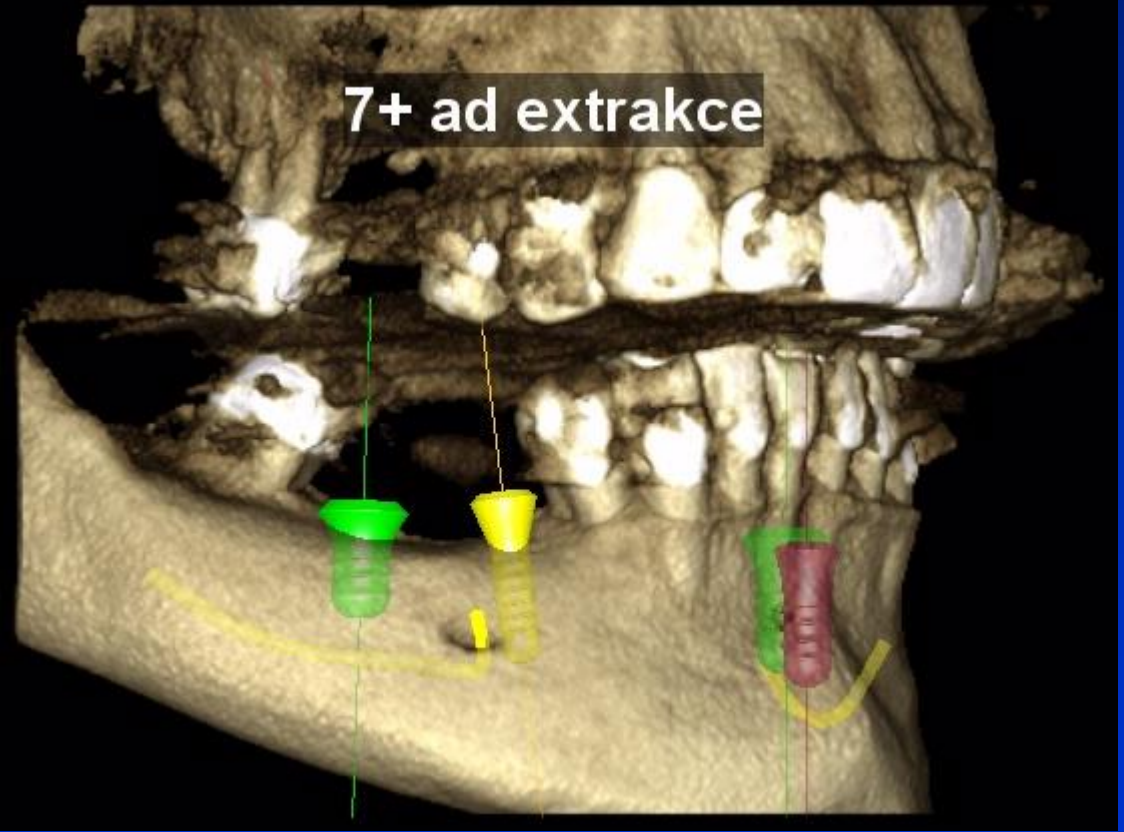
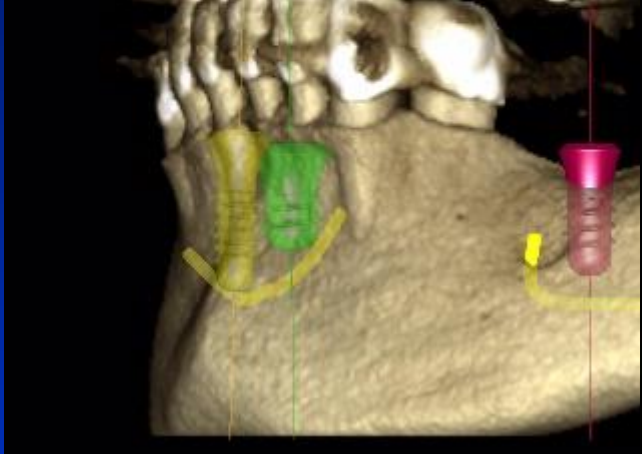
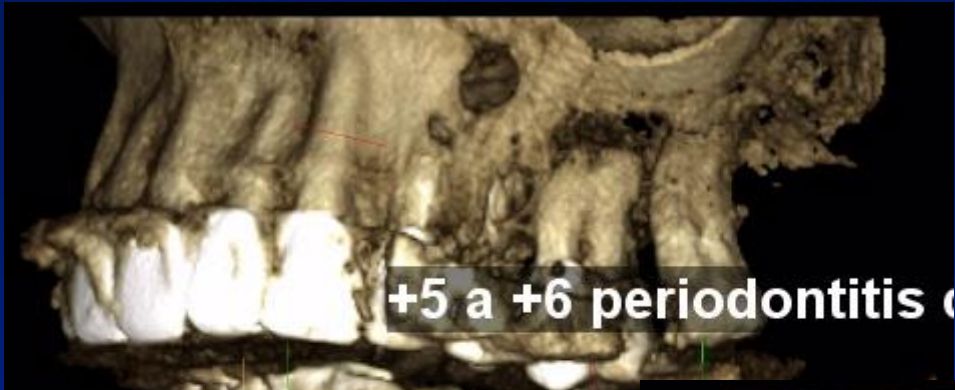radioopacity

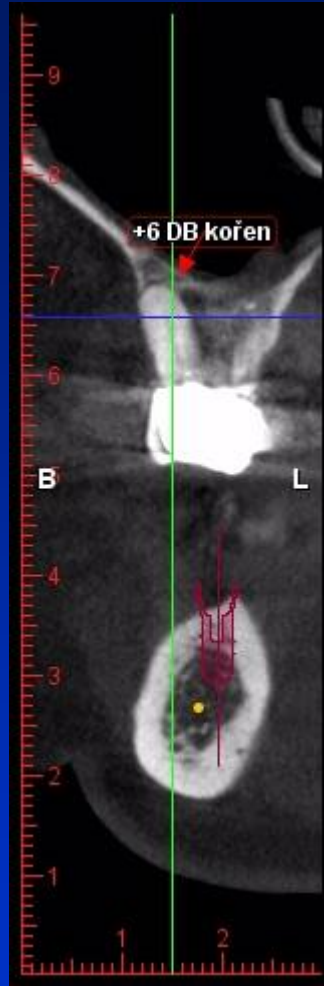
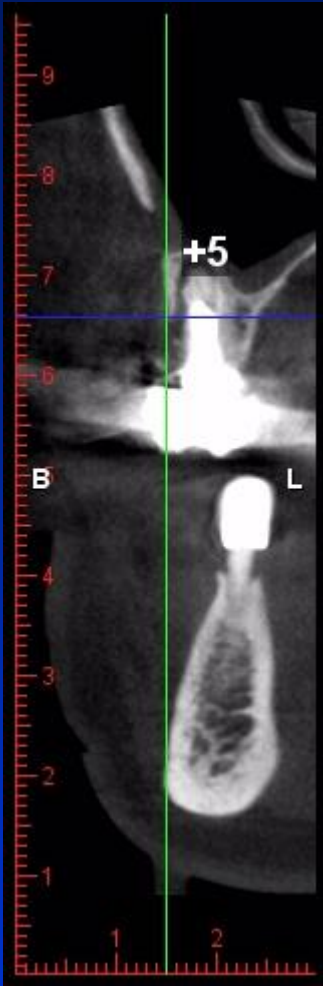radiolucency

# CBCT



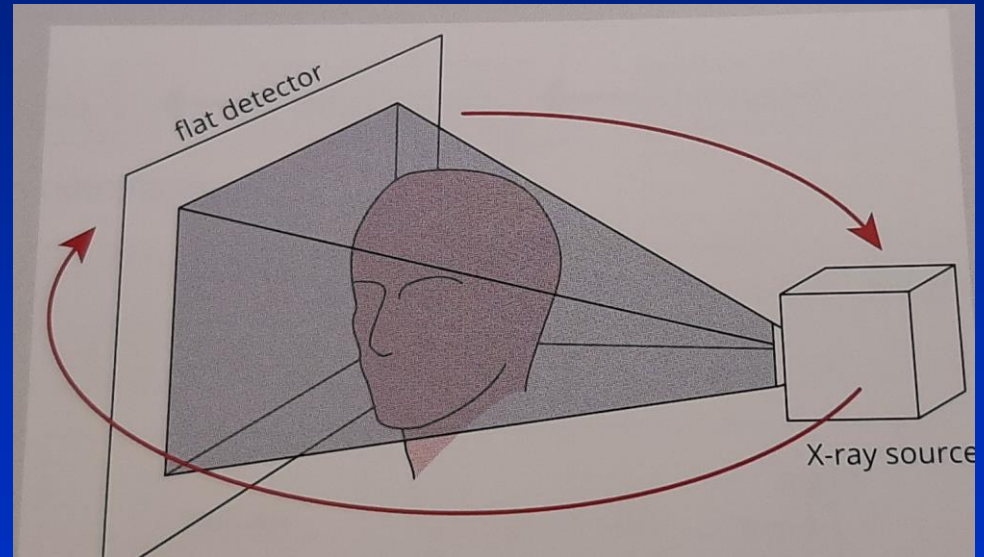






# CBCT – cone beam computer tomography

CBCT  
Source and detector rotate



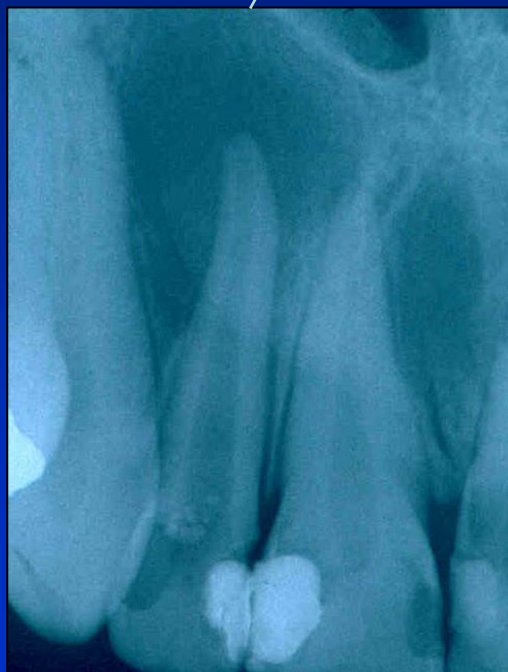# CBCT – cone beam computer tomography

- High diagnostic effect
- Endodontics
- Omplantology
- Surgery
- Traumatology

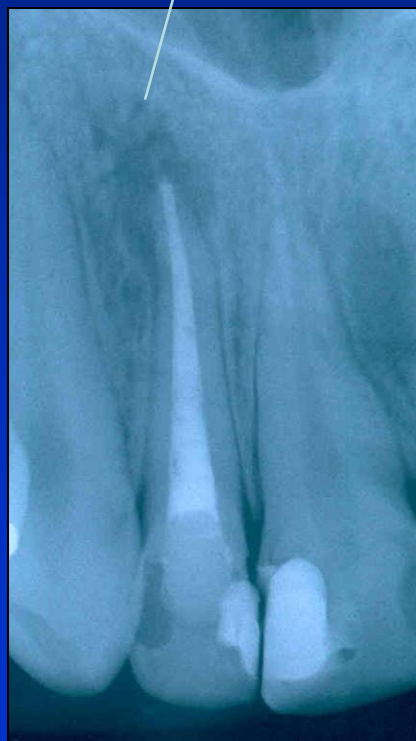



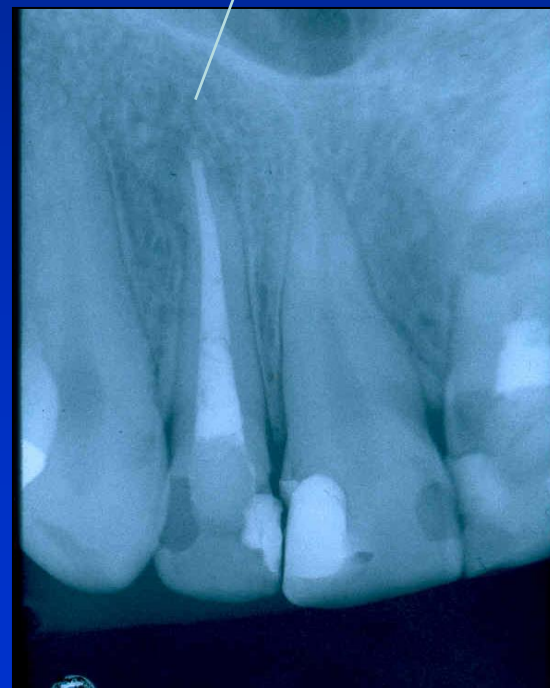Radiogram before the treatment





Radiogram after the treatment



Radiogram 6 month post.op.





Radiogram with inserted root canal instrument