

# PERIODONTOLOGY

## basics - test

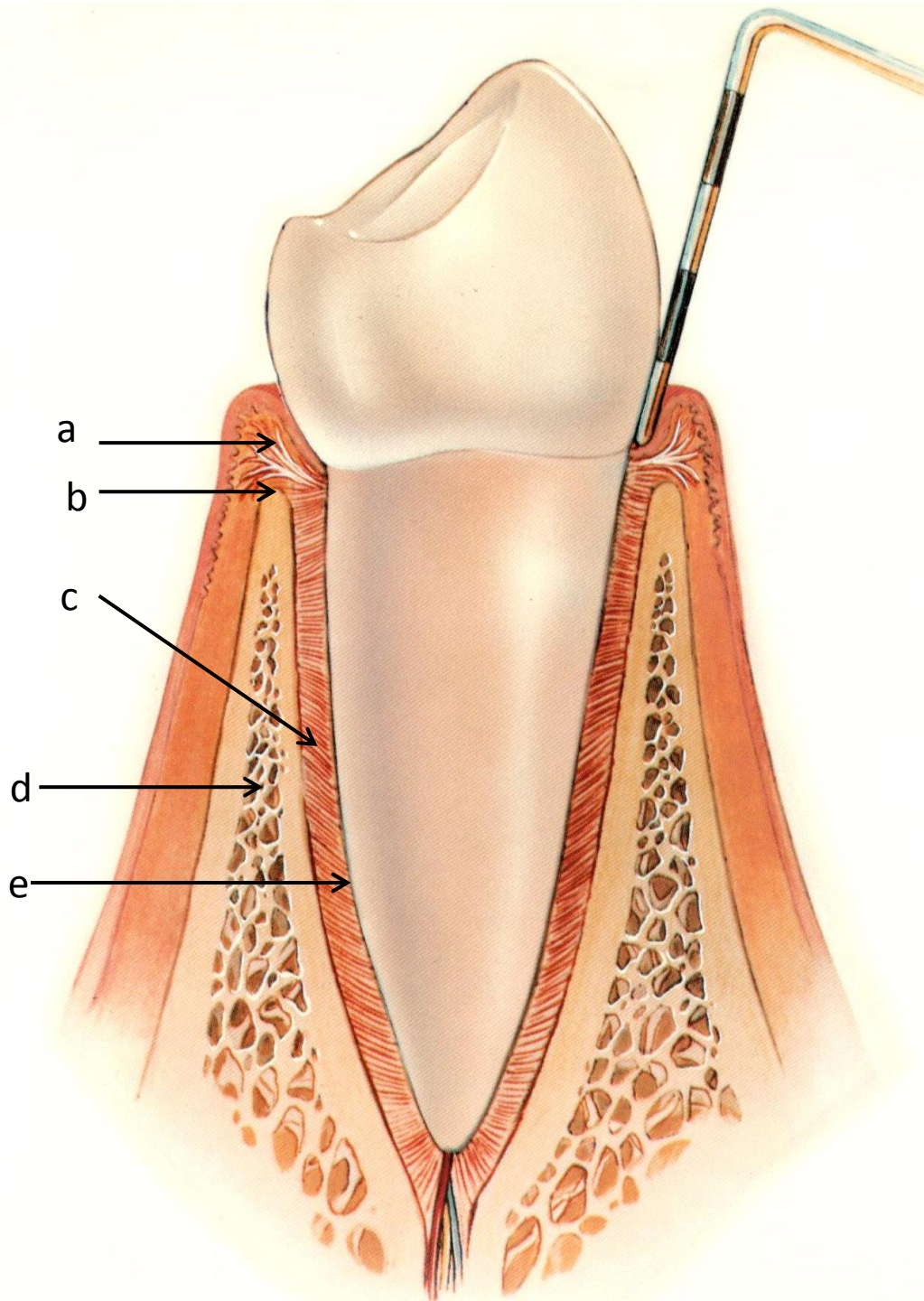
MUDr. Hana Poskerová, Ph.D.  
Stomatologická klinika  
FN u sv. Anny a LF MU v Brně



FAKULTNÍ  
NEMOCNICE  
U SV. ANNY  
V BRNĚ



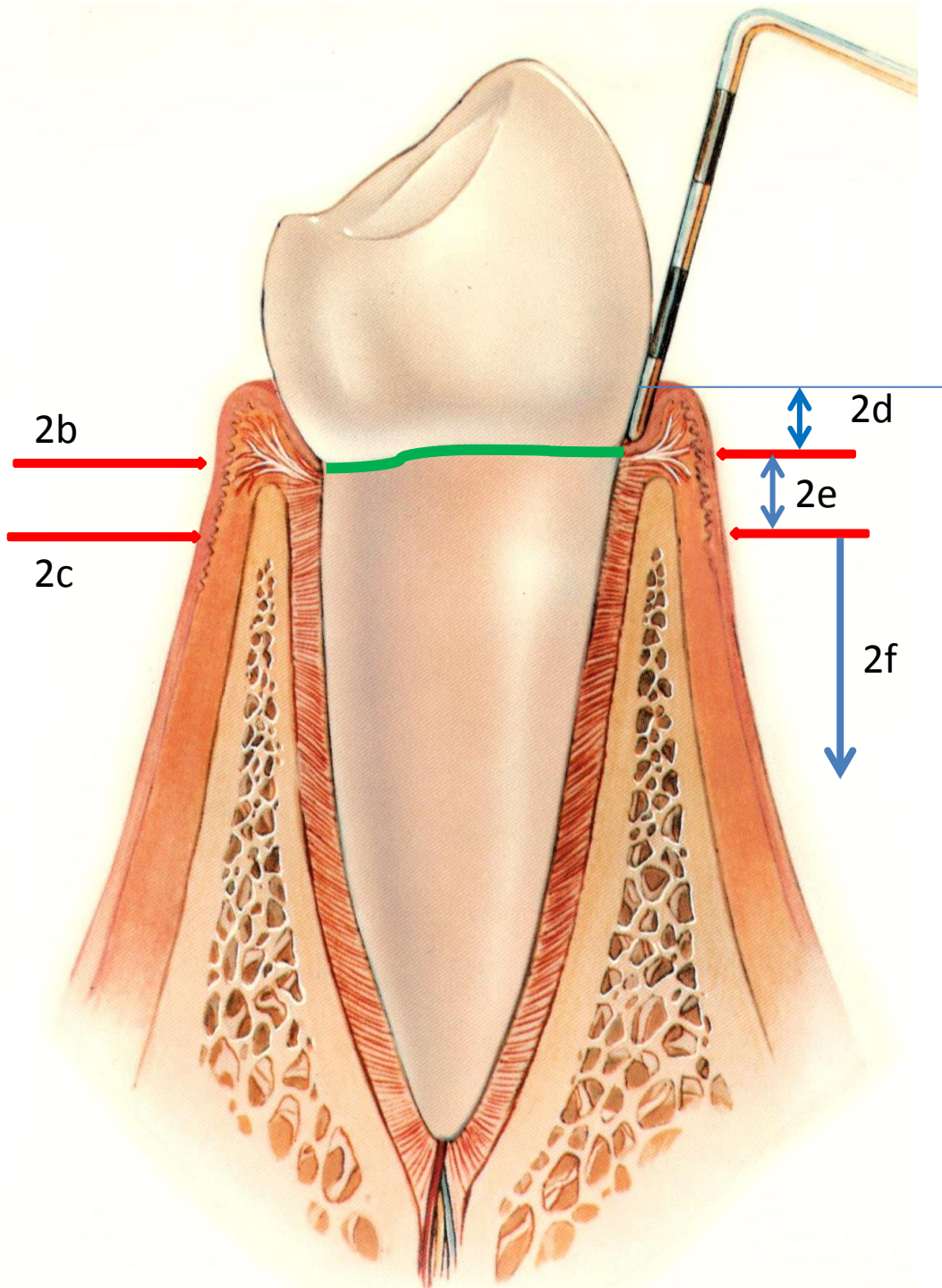
M U N I



1 - List the anatomical structures that are part of the periodontal tissue:

- 1a
- 1b
- 1c
- 1d
- 1e



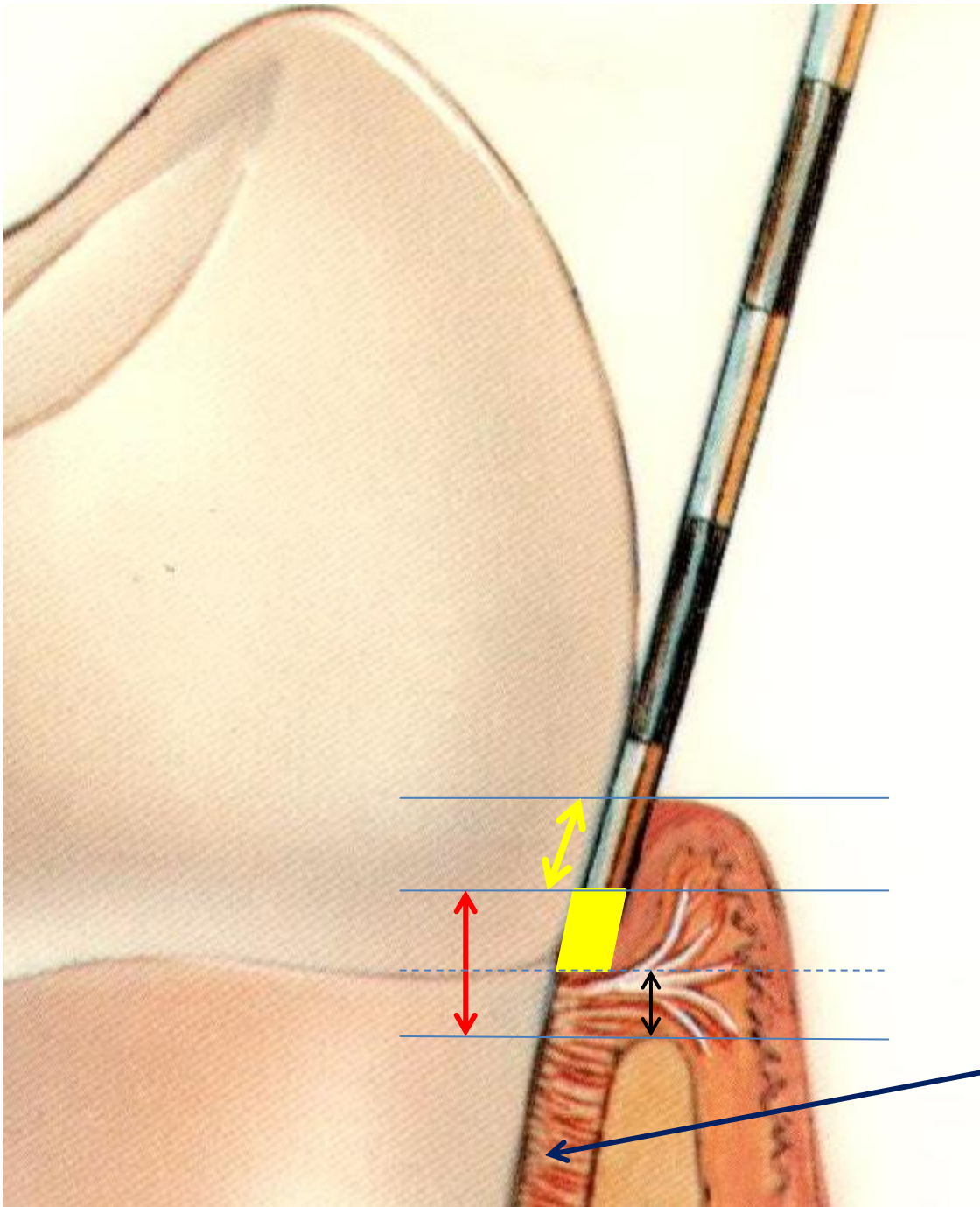


2 - List the anatomical structures within the range:

2a - green line

2b, c - red lines, there are particularly visible when viewed from the vestibulum

2d, e, f - structures within the blue arrows



3 - List the anatomical structures within the range:

3a - yellow arrow


3b - yellow field

3c - red arrow

3d - black arrow

3e - blue arrow





4 - Describe:

4a - what is the most likely diagnosis of periodontal disease

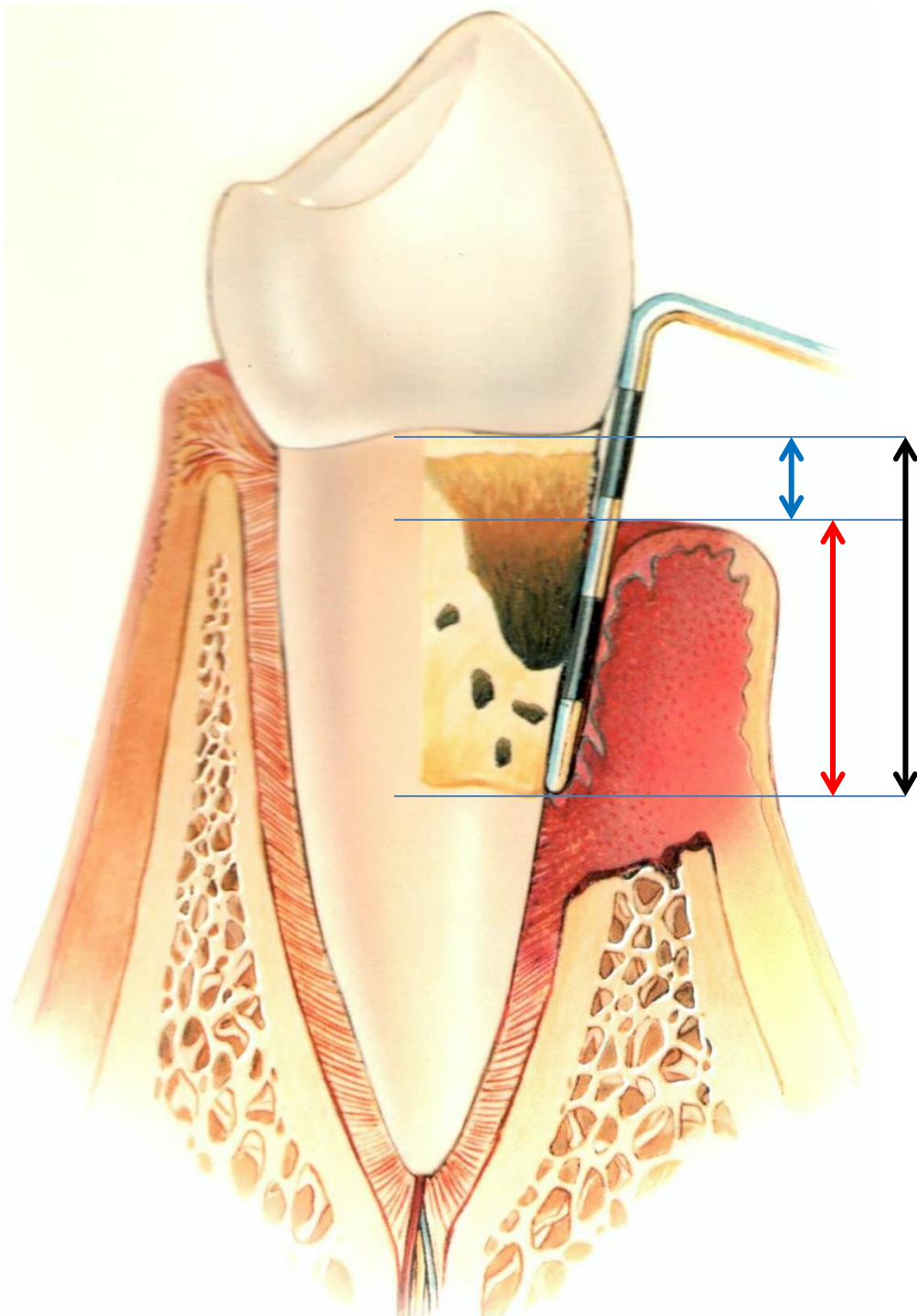
4b - typical clinical symptoms for this diagnosis

4c - is the disease reversible or irreversible?

4d - what PBI value can we expect the?

4e - what CPITN value can we expect (what values are possible and what are not)

4f - what is the basic treatment?



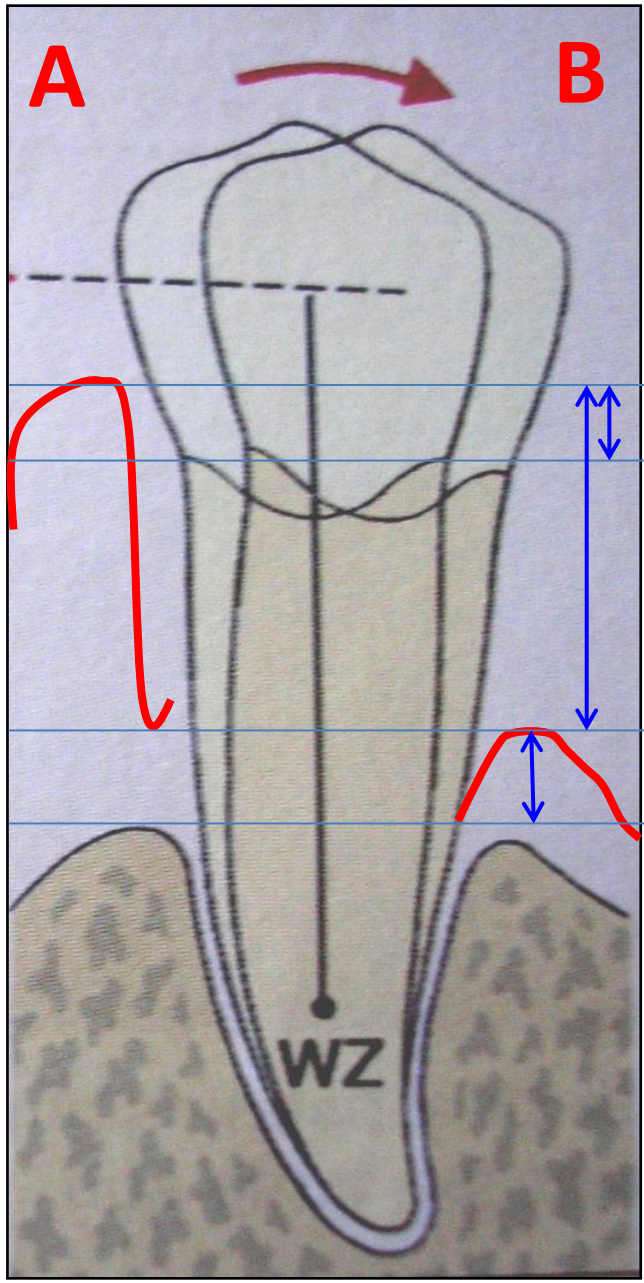
5 - Name the distances given by the arrows:

5a - blue arrow

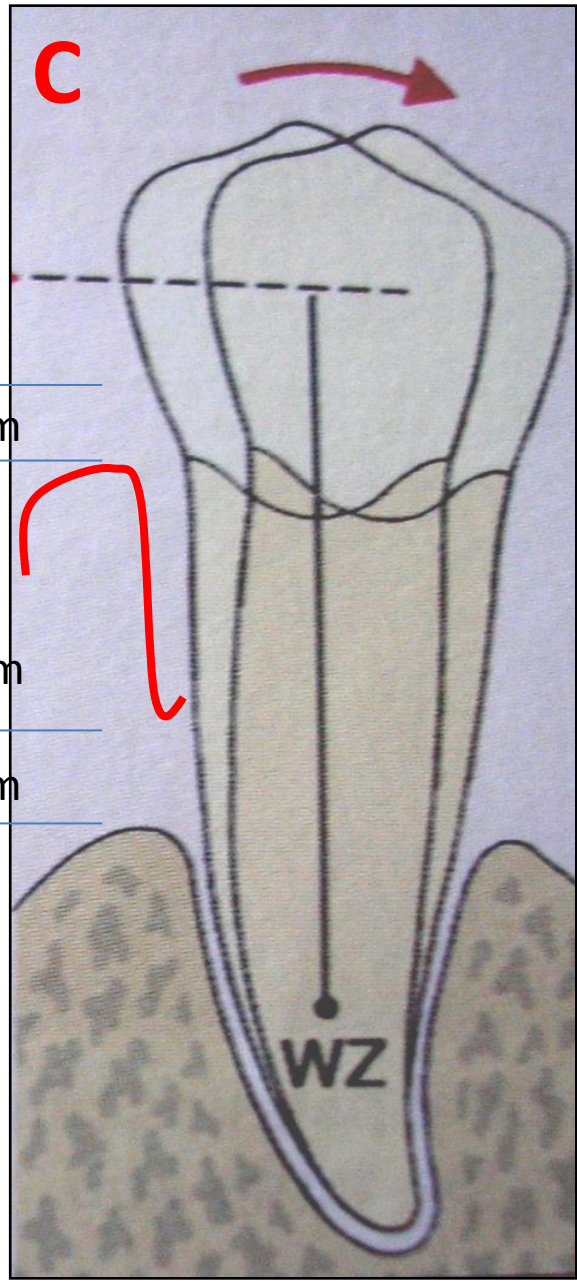
5b - red arrow

5c - black arrow





2 mm  
7 mm  
3 mm



6 - Determine for A, B, C in mm

a – pocket probing depth (PPD)

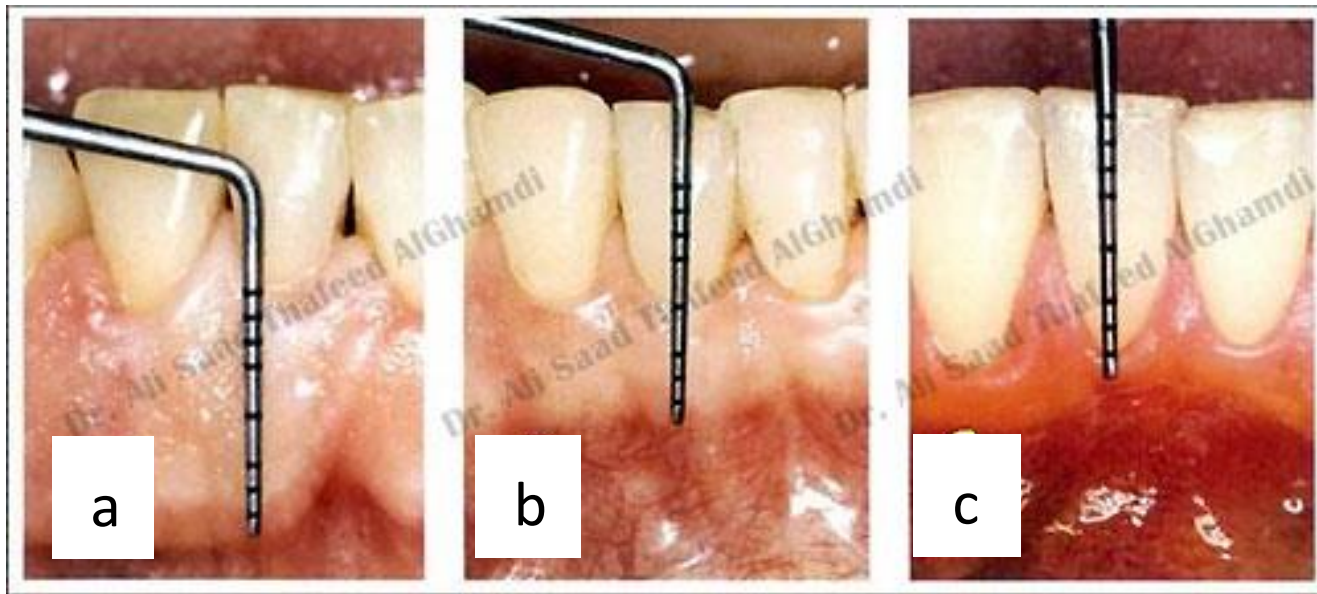
b – attachment loss (AL)

c - gingival recession (GR)

Aa  
Ab  
Ac

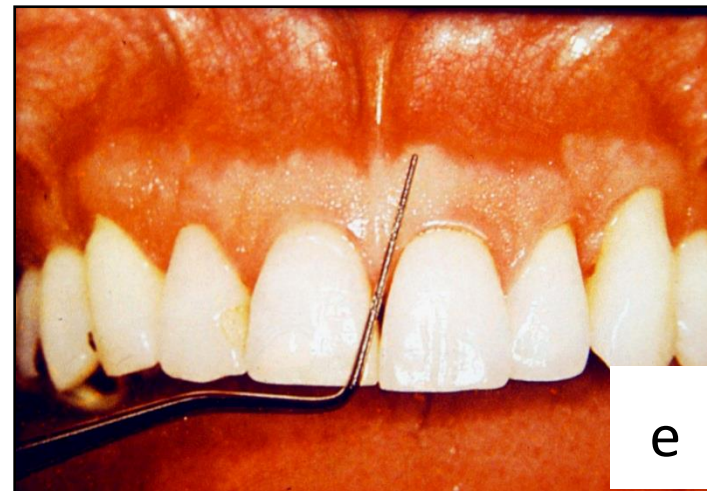
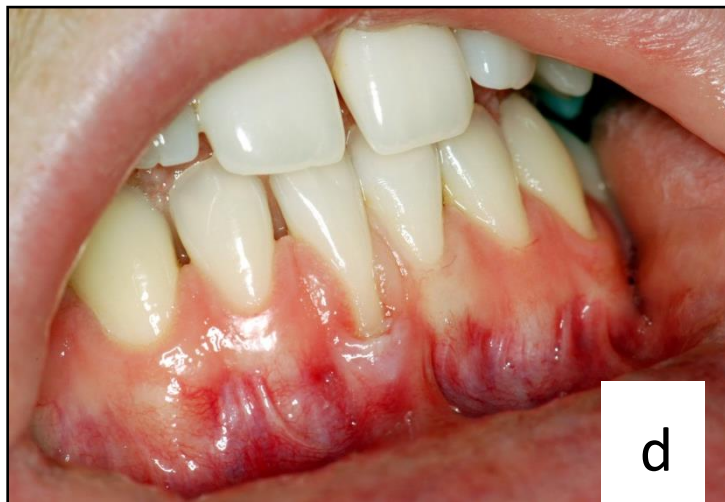Ba  
Bb  
Bc

Ca  
Cb  
Cc

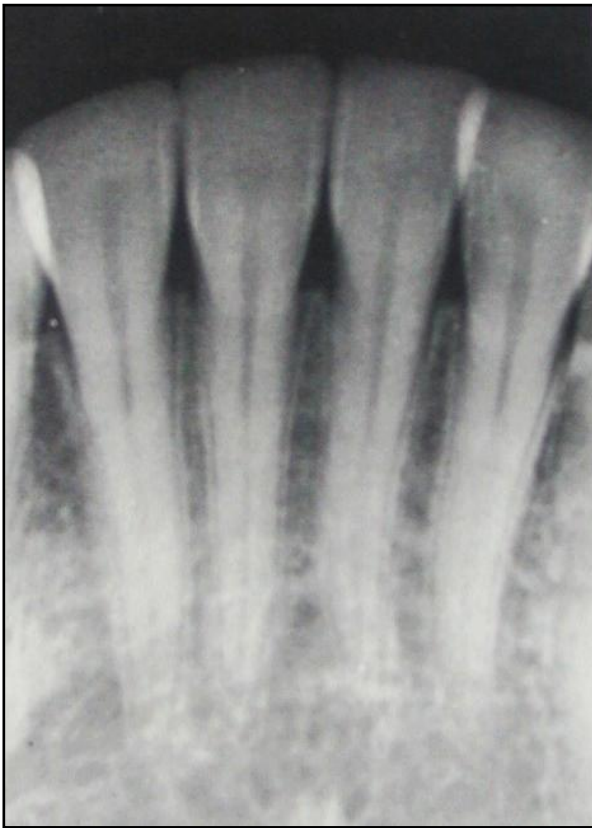

7 - Describe the gingival phenotype (a-e)

7... In which cases there is the insufficient width of the attached gingiva?



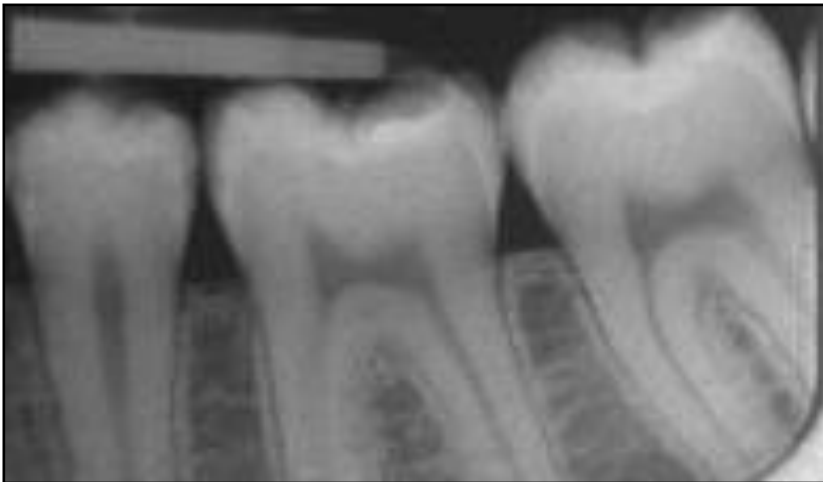


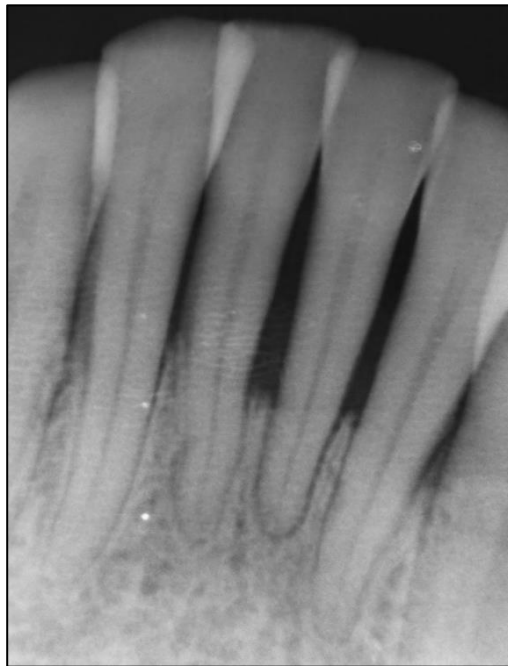
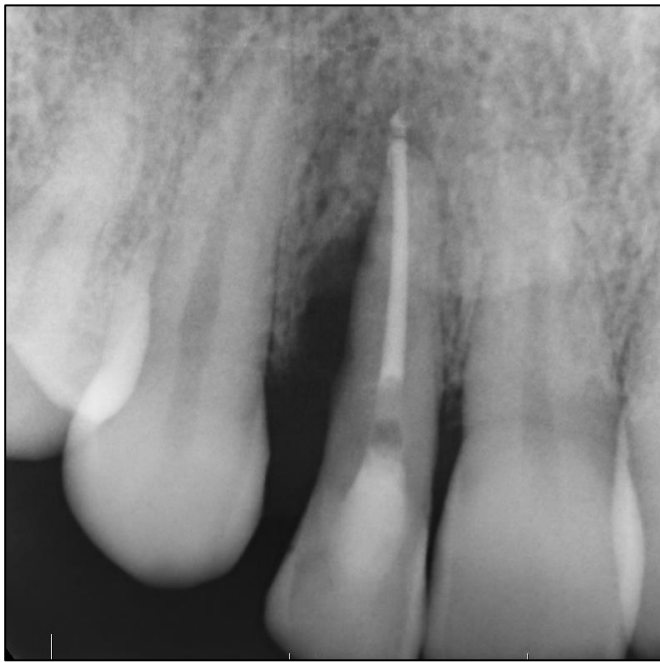
8 - Do interdental septa show bone resorption?

8a - Incipient resorption / no resorption

8b - What are the main features of alveolar bone that does not show bone resorption?





9 - What type of bone resorption is involved in the following cases:

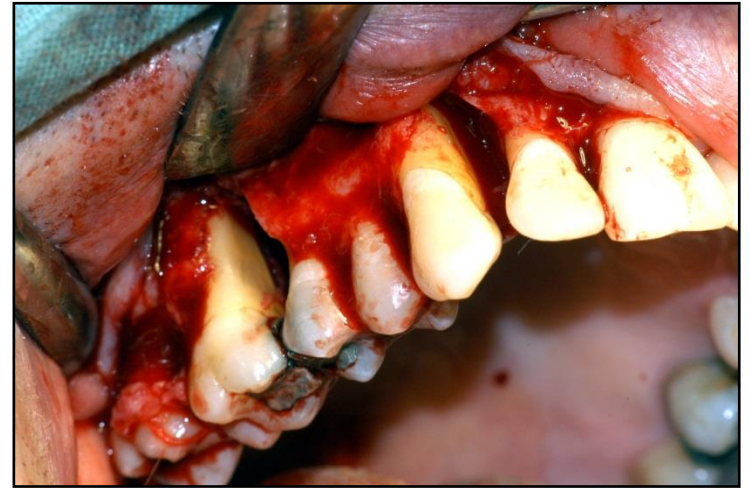
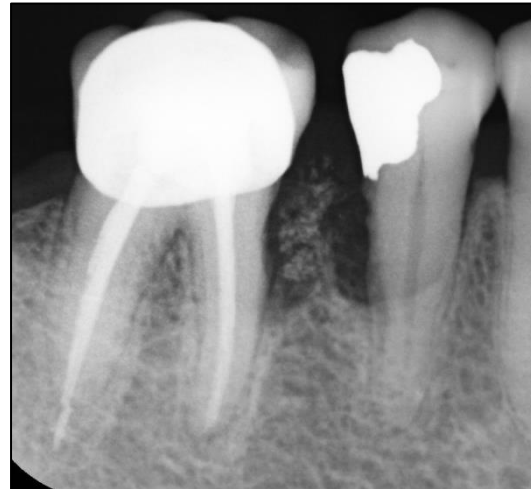
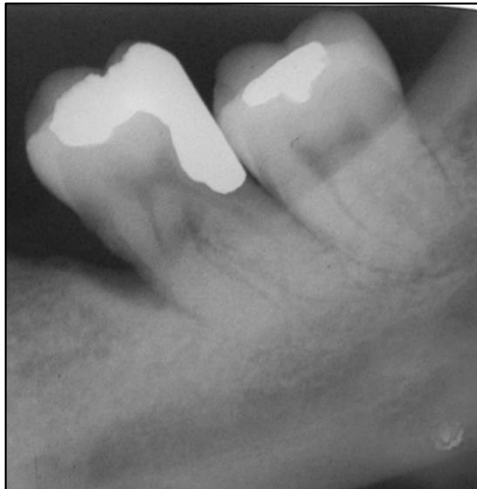9a - tooth 12

9b - lower incisors

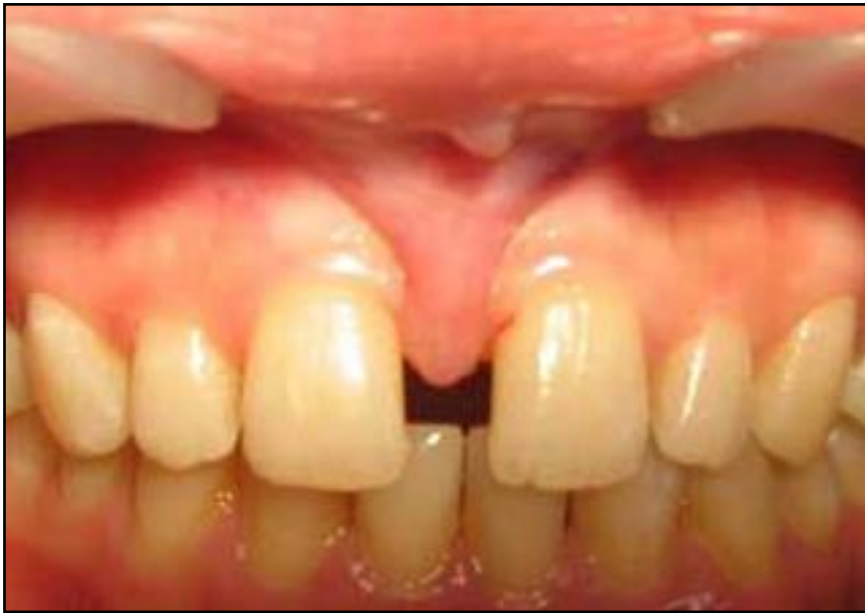9c - tooth 36

9d - tooth 45

9e - 13, 16 (FOTO)

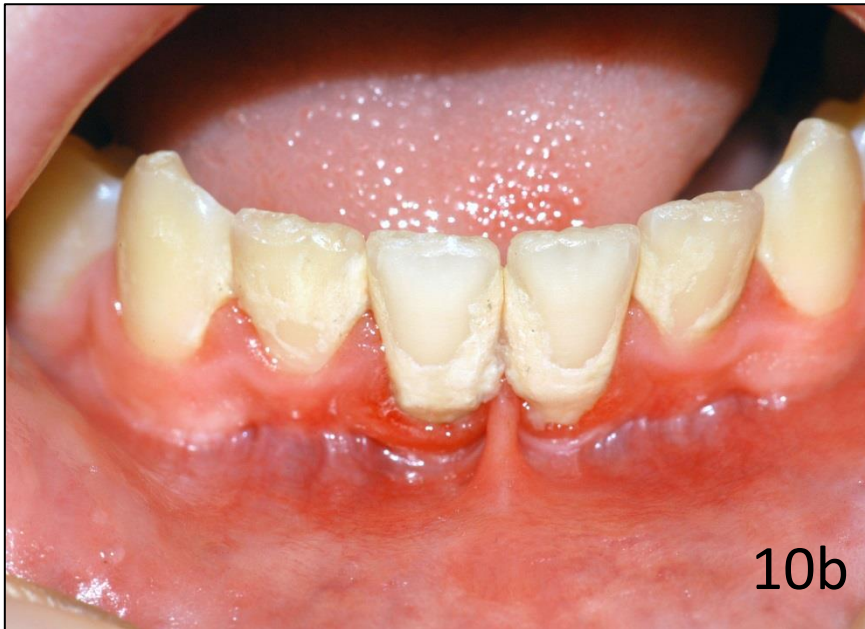




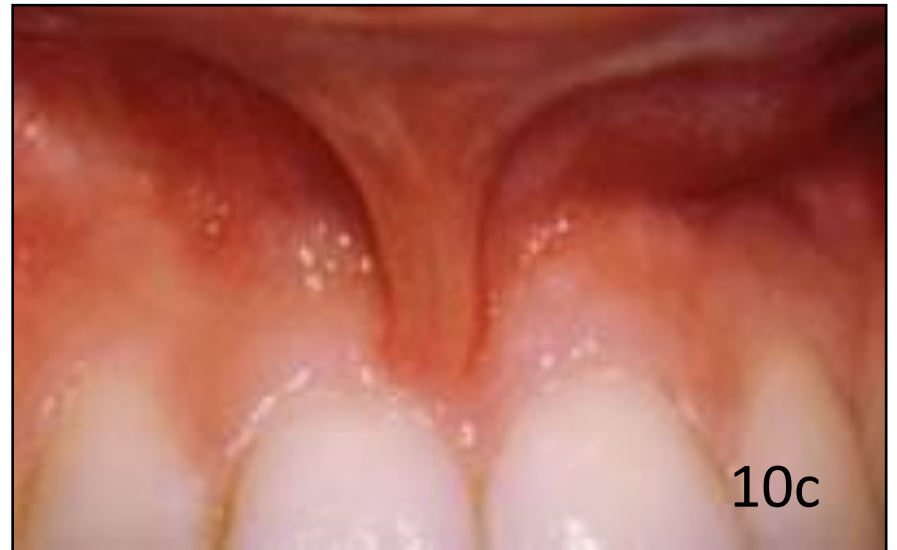
10a

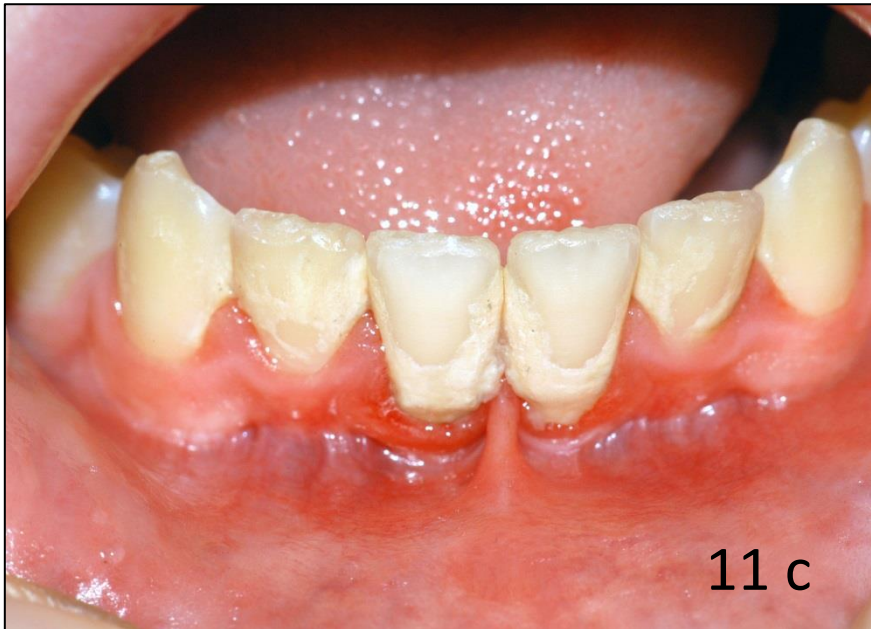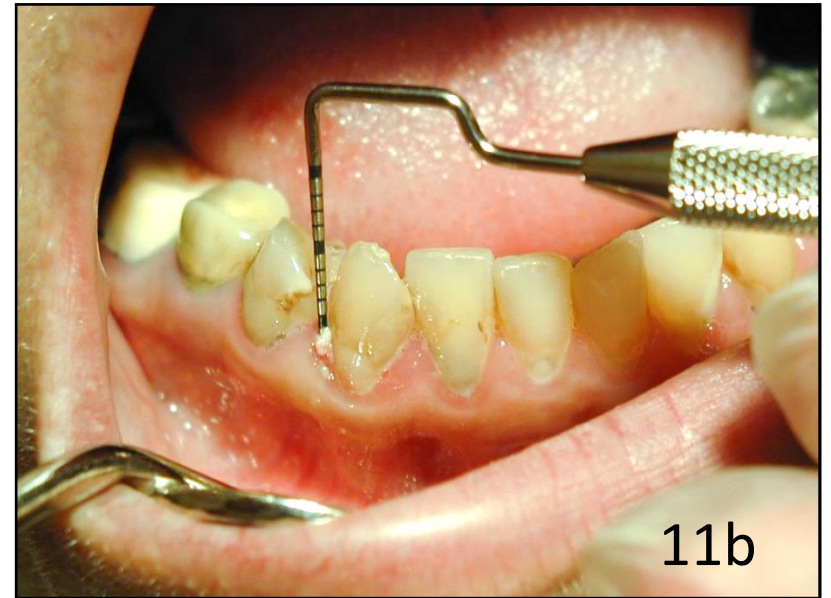
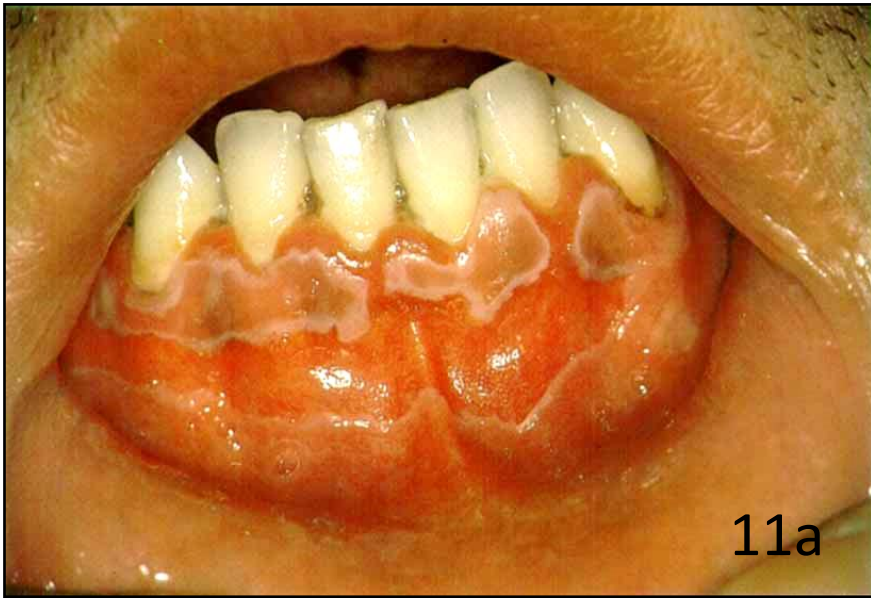10 - What type of frenulum is this?



10b

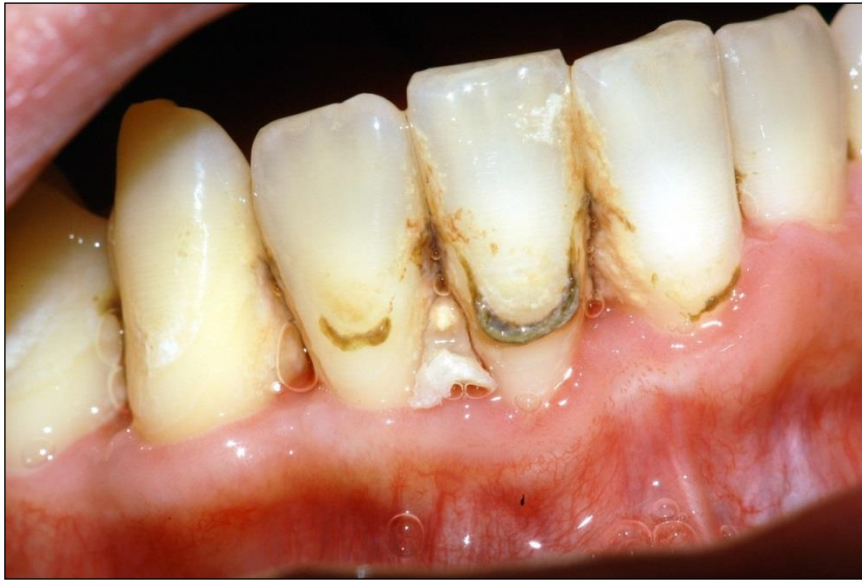

10c



11 – Describe whitish soft materials that we can see in the pictures.  
11a, b, c

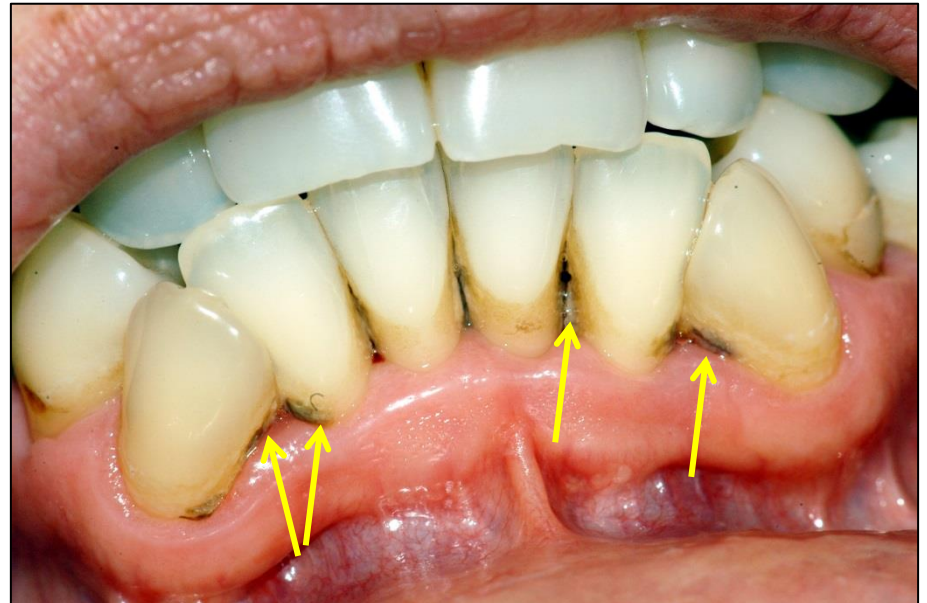
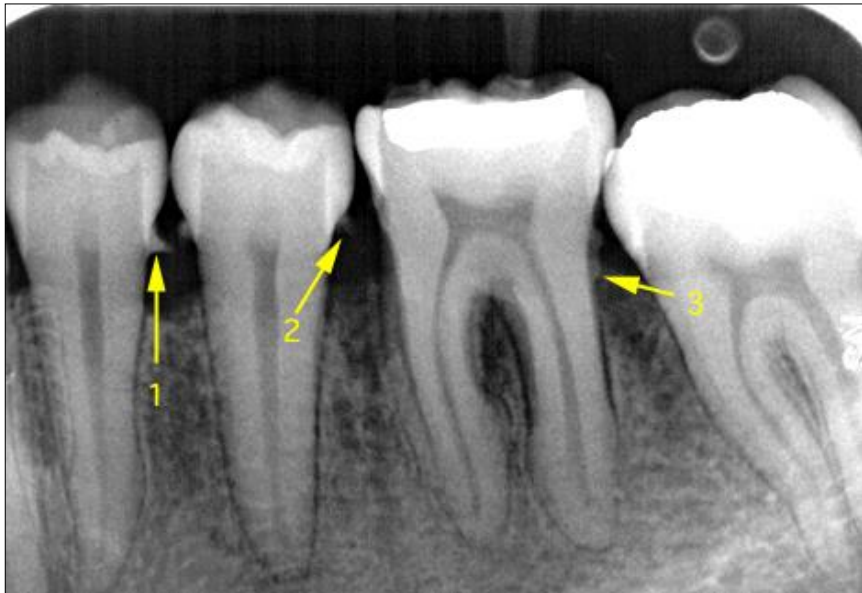



12a - What is the name of the structure (exact term) that we can see especially with tooth 41?

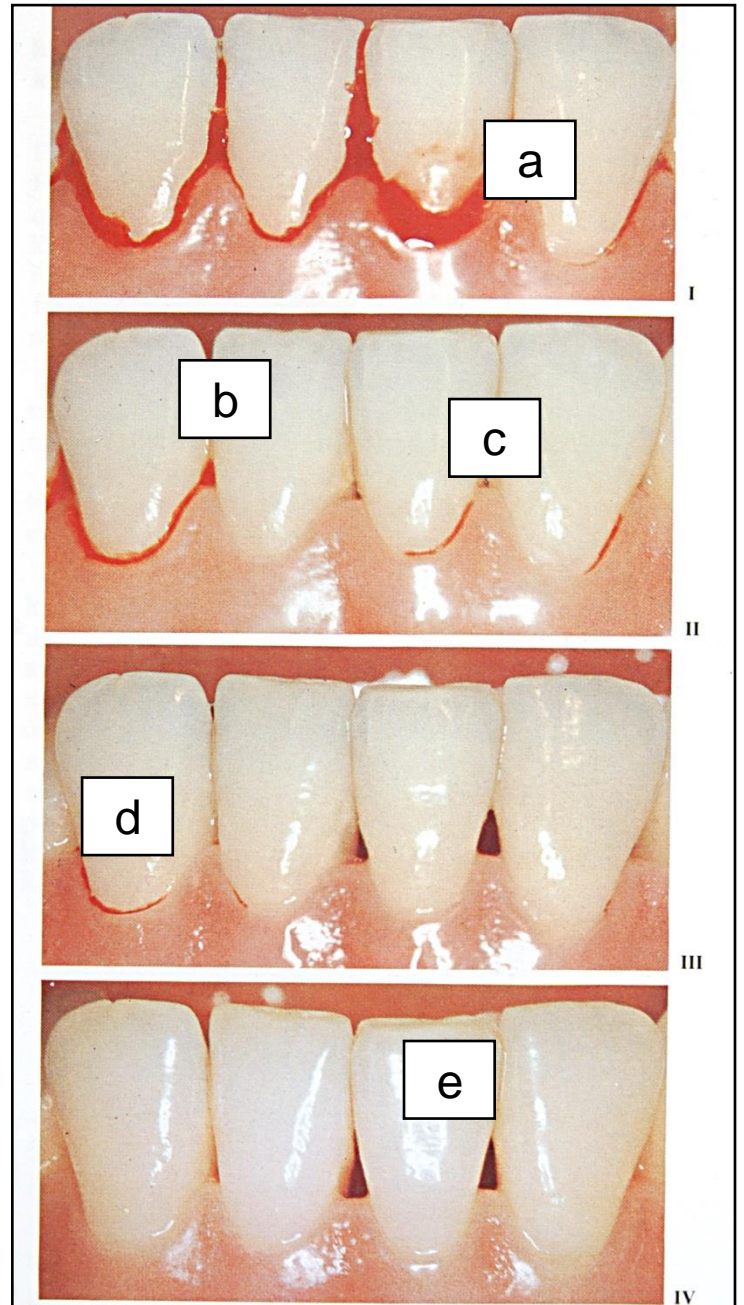
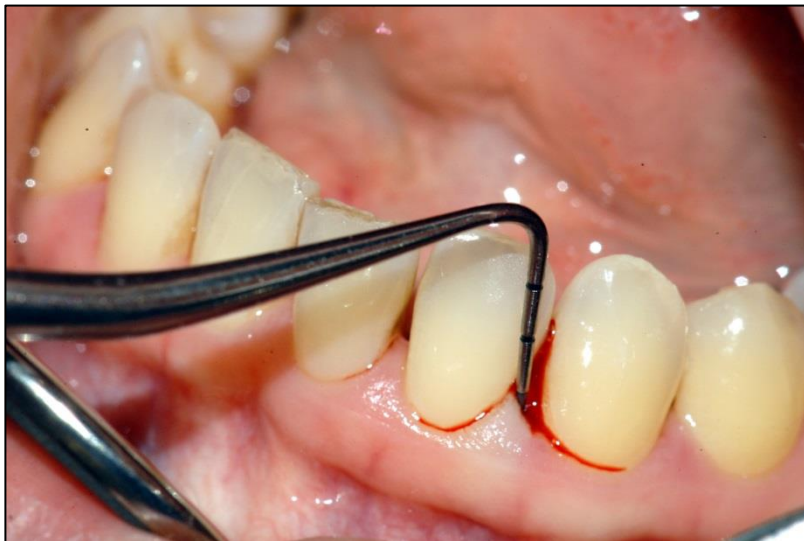12b - What structure can be in the interdental space 42-41?

12c - What structures (exact term) are indicated by the yellow arrows?



13a-e - Assign the correct PBI values to each site

13f - What is the BOP value of tooth 33?





14 - Is it possible to find these values as the result of the examination of one patient? Yes-no answer

14a - PBI 4 a CPITN 000/000

14b - PBI 0 a CPITN 434/434

14c - PBI 0 a BOP+

14d - API 82% a HYG 28%

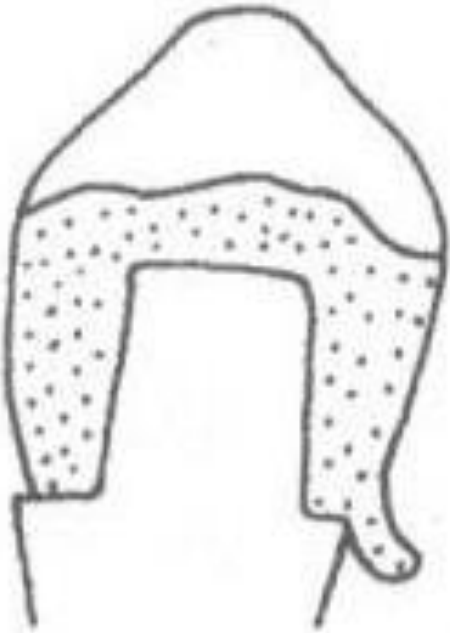14e - in which typical case it is possible,  
that the PBI is low and the is high?

14f - in which typical case it is possible,  
that the API is low and the PBI is high?

15- Describe the status of these fillings a-d

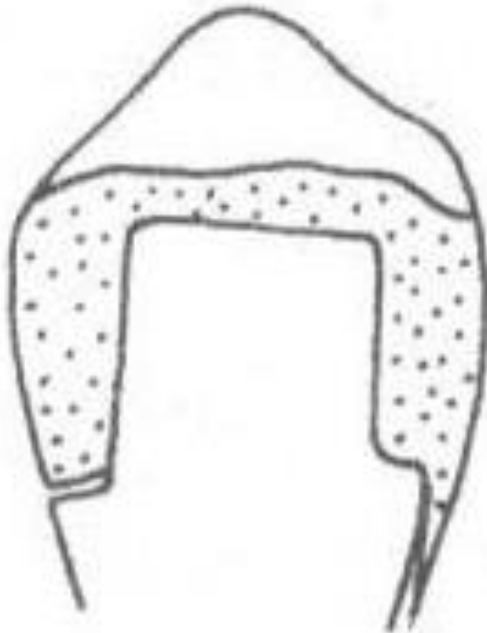15e - Which tooth has a filling that can irritate periodontal tissue?

a/

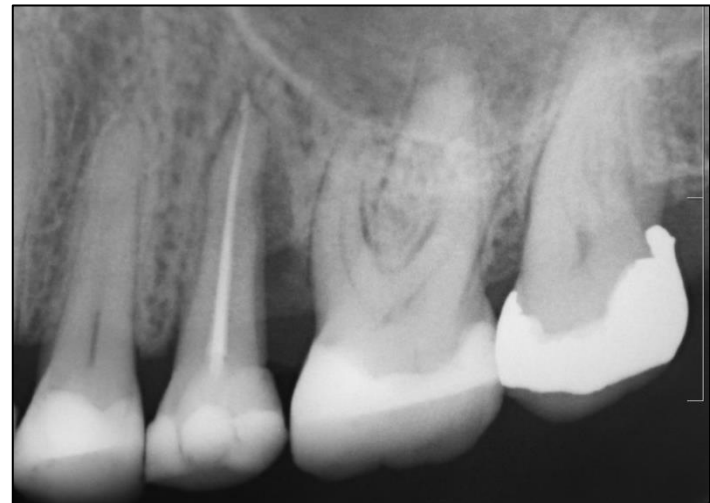

b/

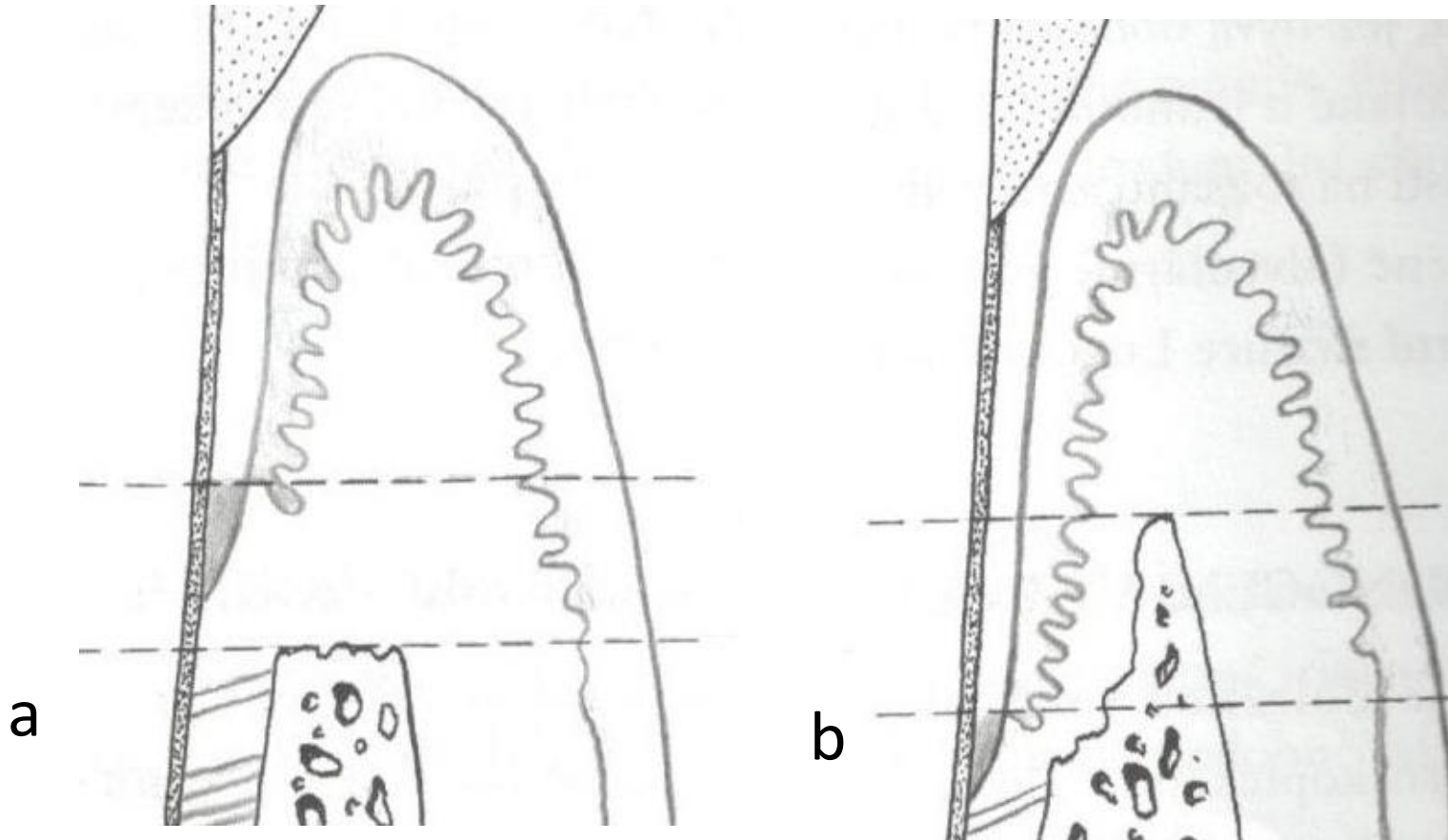
c/



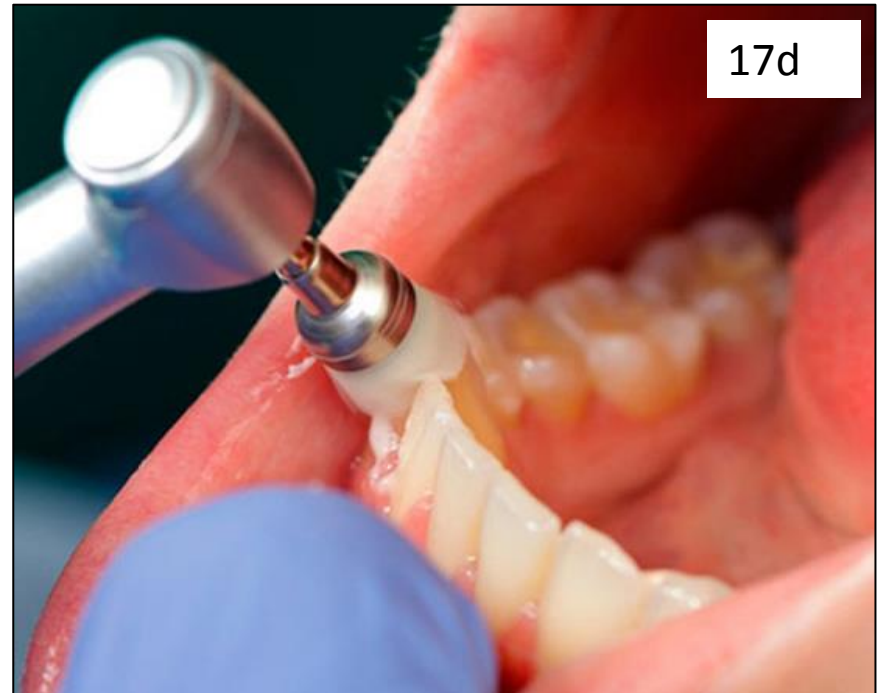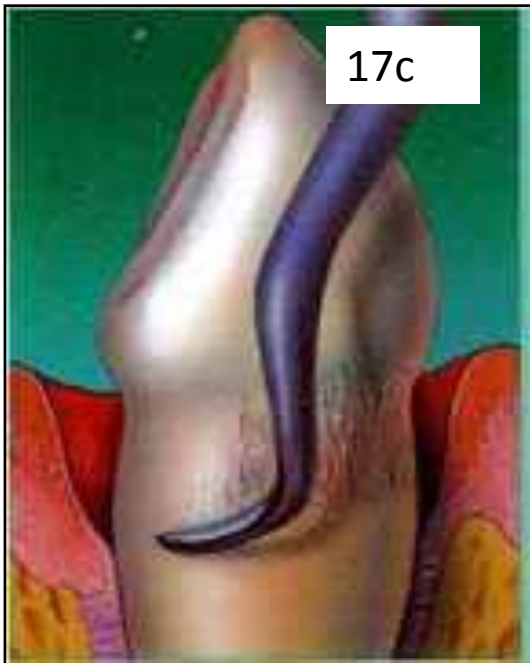
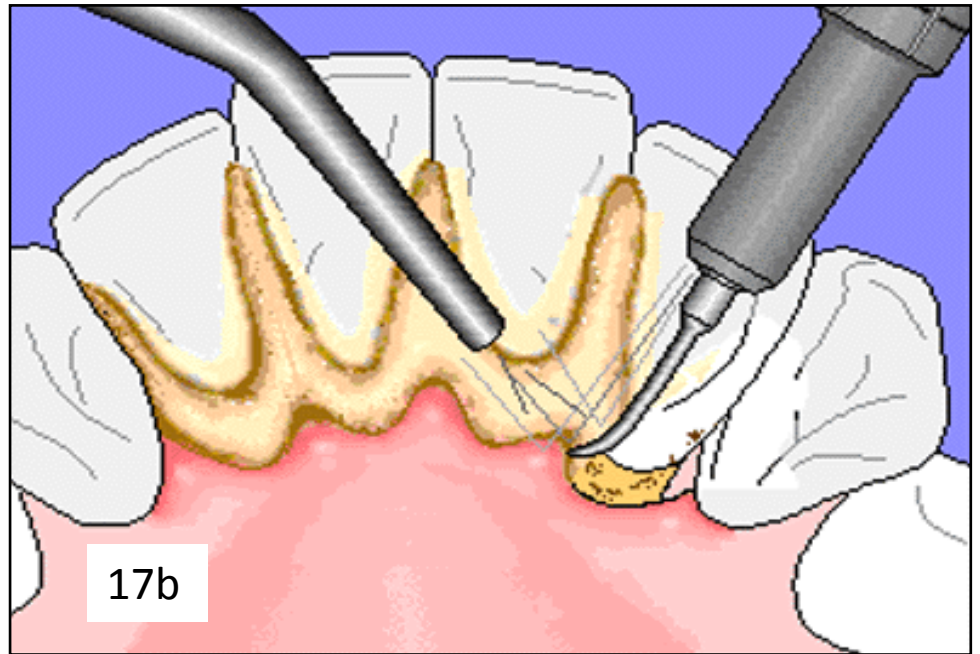
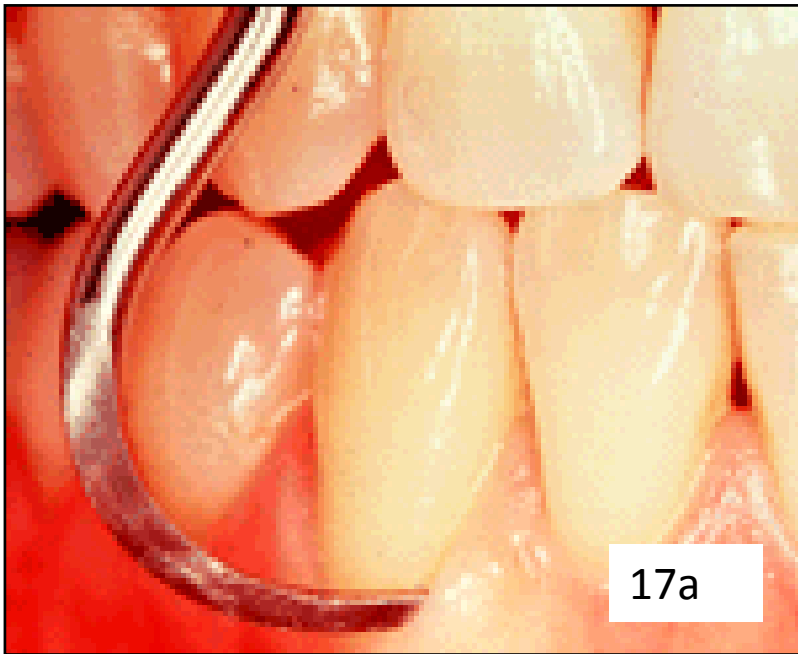d/



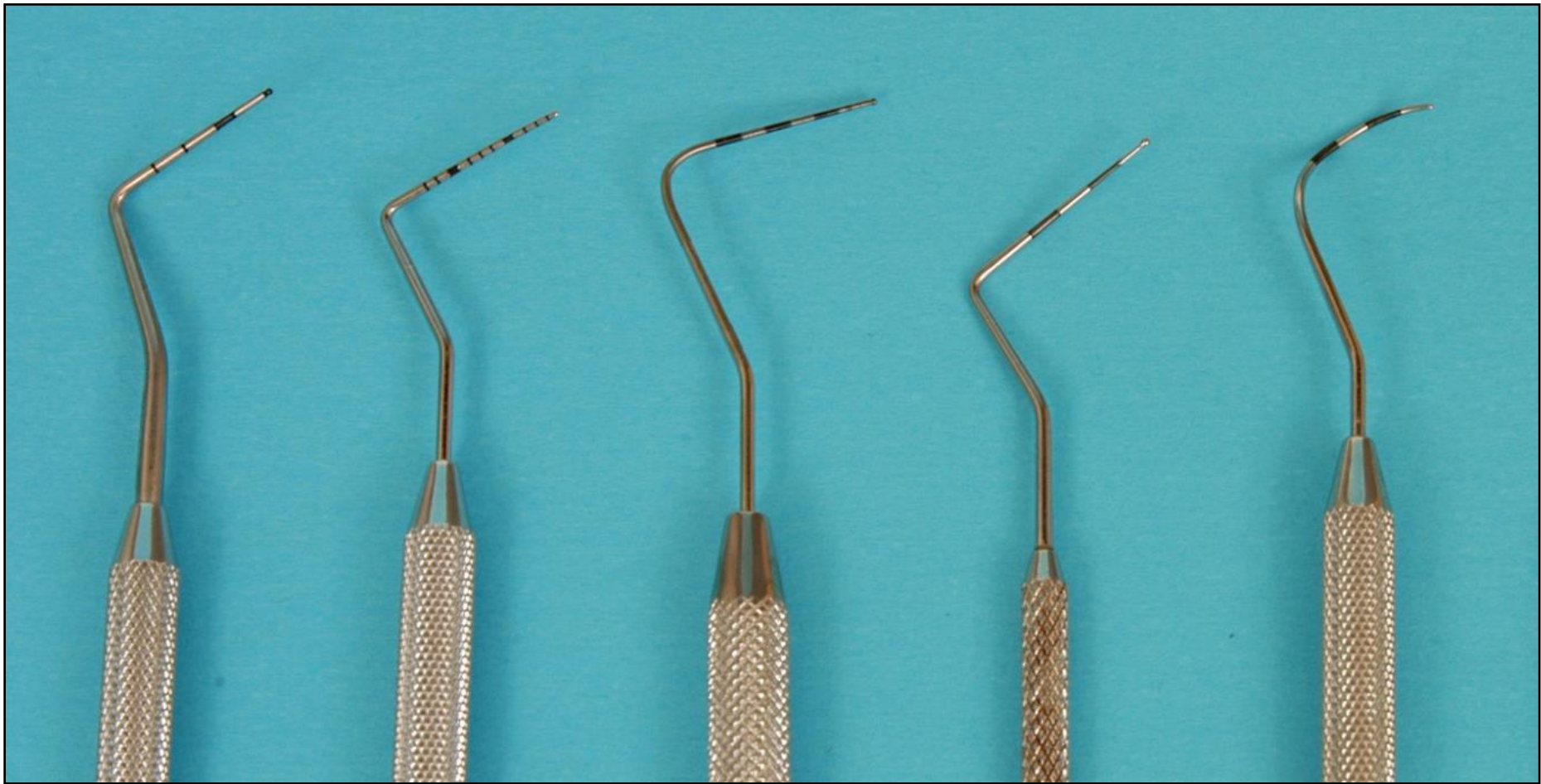




16 - Describe the type of periodontal pockets in these schemes a, b



17 a-d  
Describe  
terms  
(exact  
terms) for  
these  
procedures



a

b

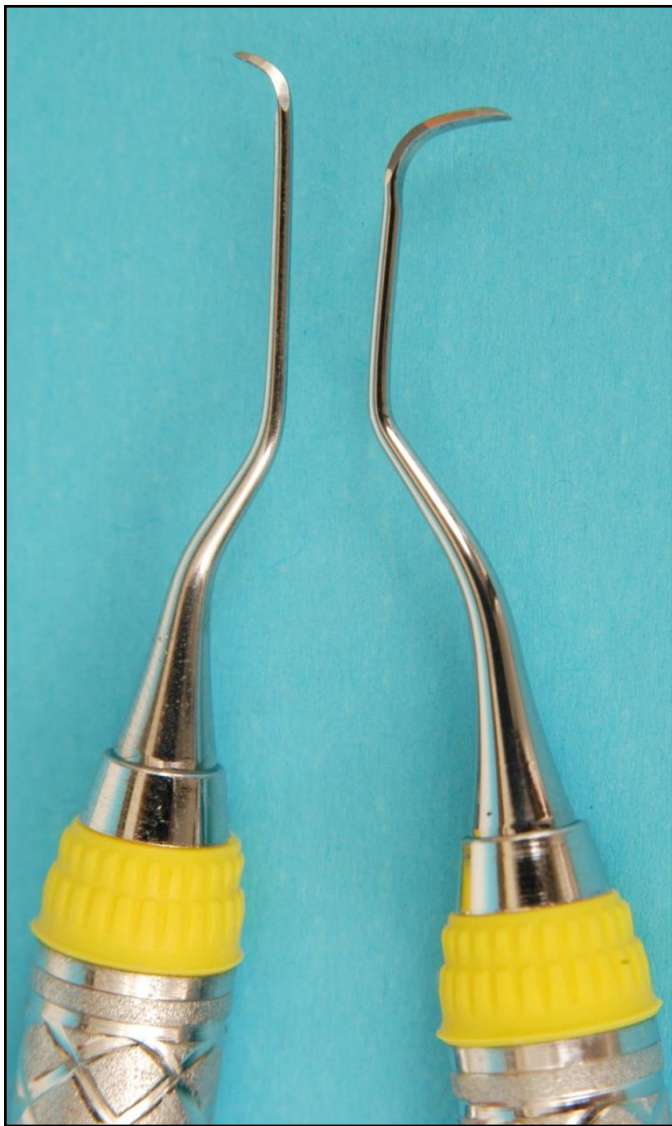c

d

e

18 - Describe the periodontal probes you know  
(2-3 of them)





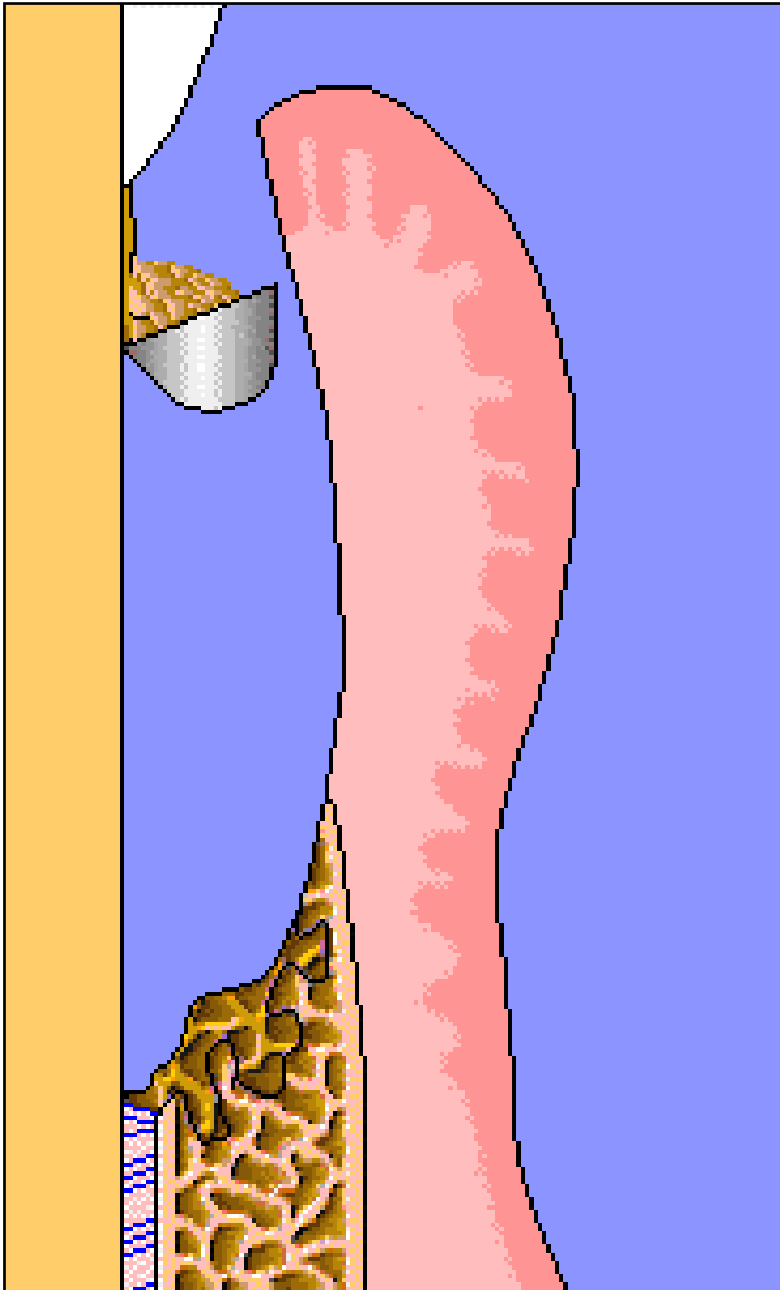
19a - What is the difference between the two instruments?  
- Describe exactly their names



19b - What are the names of these periodontal instruments?

19c - What is the difference between these two instruments?  
- Describe exactly their names





20 - What are the terms for periodontal treatment done by:

- a - universal curette
- b - Gracey's curette

21 - which tissue is created during healing of perio pocket:

- a - what the term for tissue the pocket heals
- b - common name for this type of healing
- c - is it possible that another type of healing will occur at the depth of the defect?

1a	5a	9a	14a	18a
1b	5b	9b	14b	18b
1c	5c	9c	14c	18c
1d		9d	14d	18d
1e	6	9e	14e	18e
	Aa		14f	
2a	Ab	10a		19a
2b	Ac	10b	15a	19b
2c	Ba	10c	15b	19c
2d	Bb		15c	
2e	Bc	11a	15d	20a
2f	Ca	11b	15e	20b
	Cb	11c		
3a	Cc		16a	21a
3b		12a	16b	21b
3c	7a	12b		21c
3d	7b	12c	17a	
3e	7c		17b	
	7d	13a	17c	
4a	7e	13b	17d	
4b	7...	13c		
4c		13d		
4d	8a	13e		
4e	8b	13f		
4f				