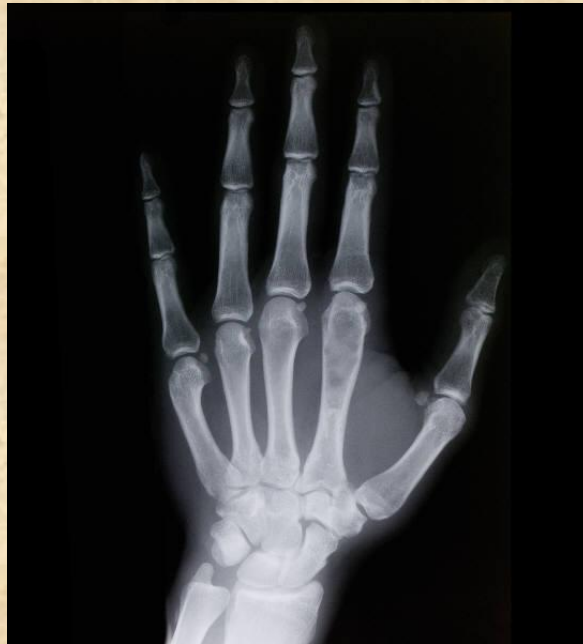

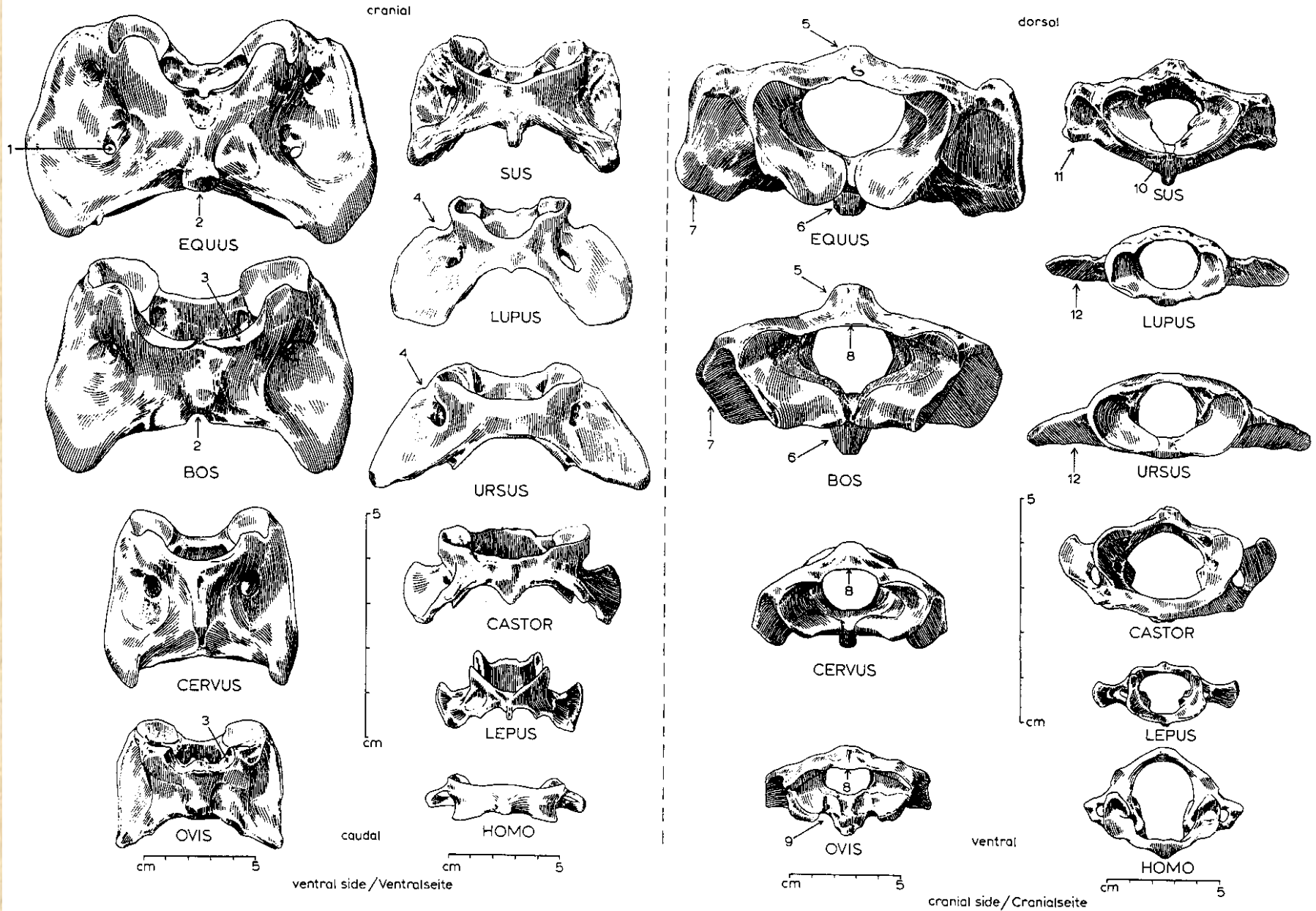
# Základy osteologie

Obratle, žebra a kosti přední končetiny




# Obratle a žebra

# Atlas (nosič)



# Obratle a žebra

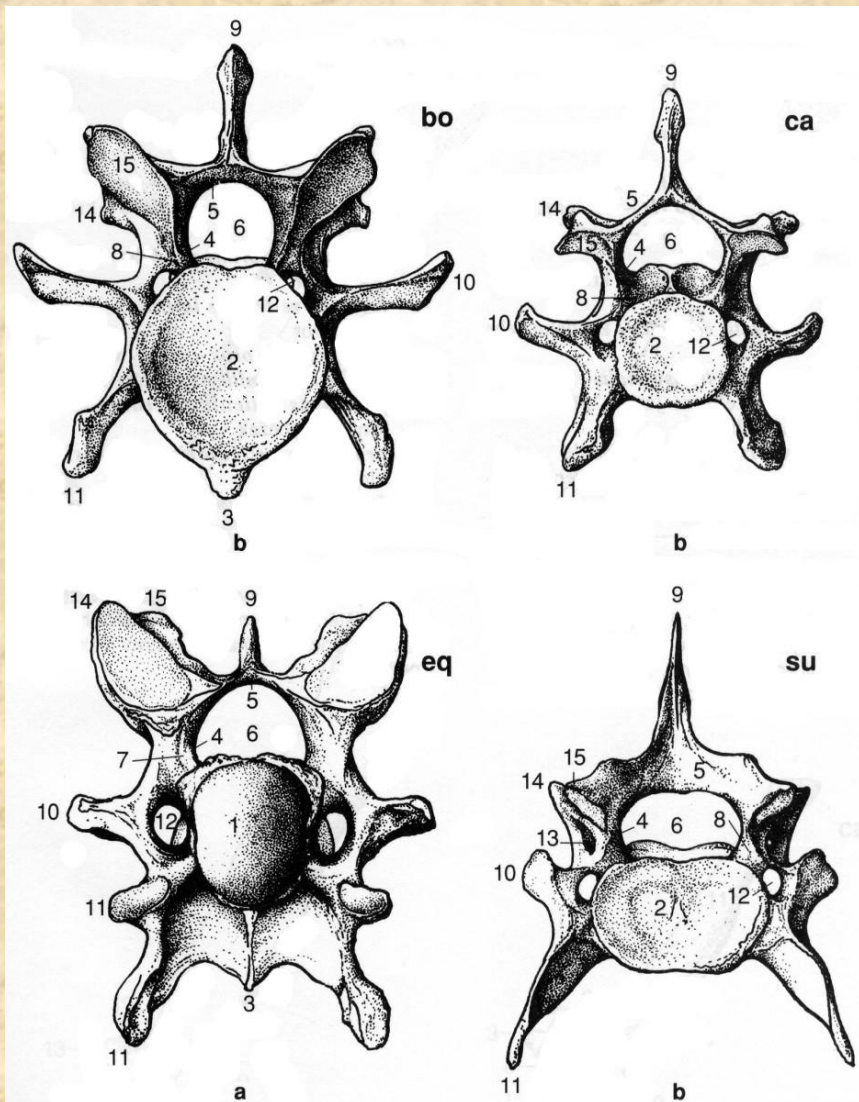
# *Epistrofeus (čepovec)*



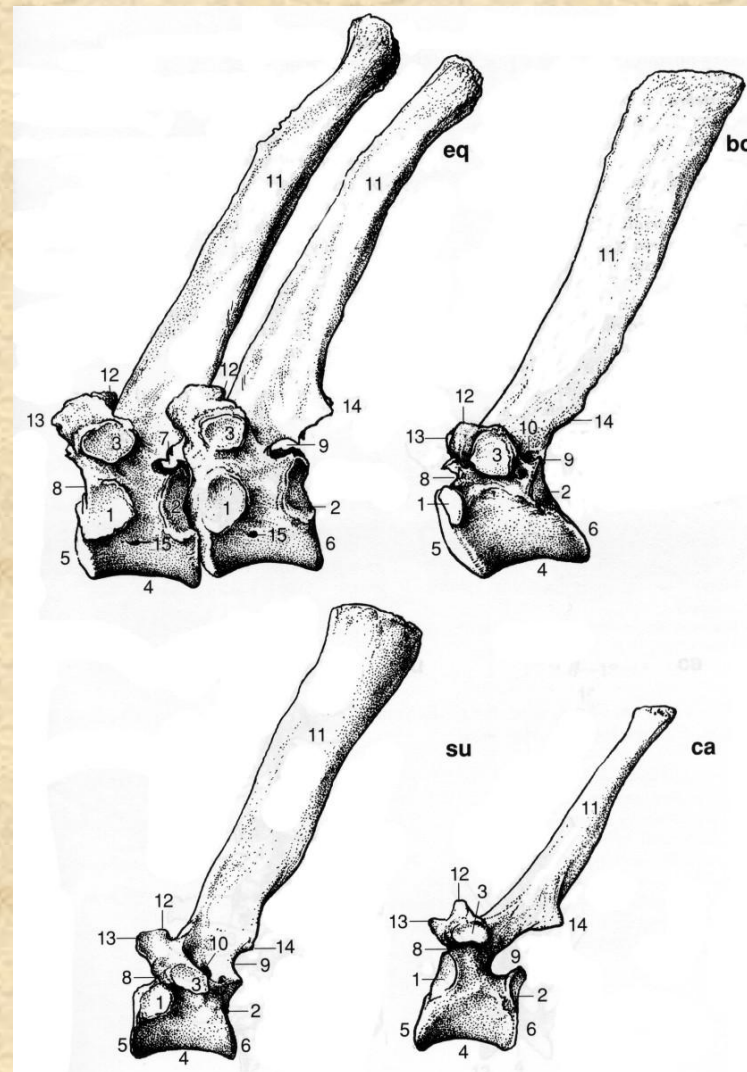
left lateral side  
laterale Seite (sin)

ventral  
cranial side  
craniale Seite

# Obratle a žebra

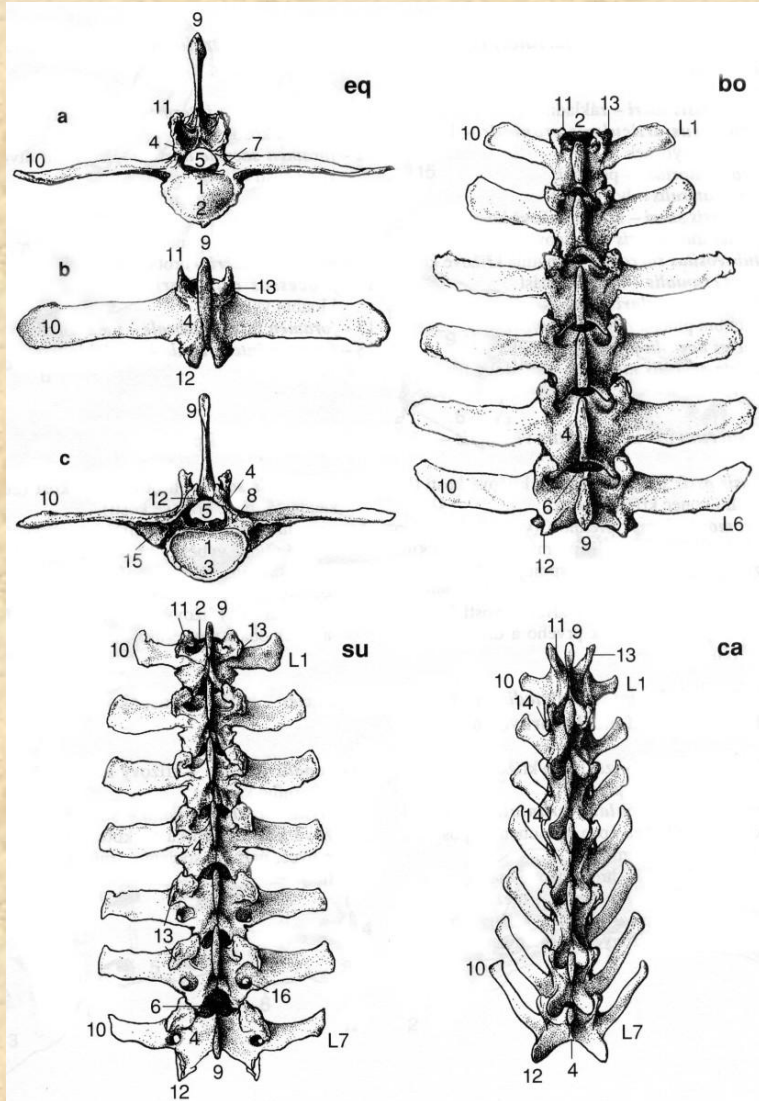


**Krční obratle (*vertebra cervicis*)**

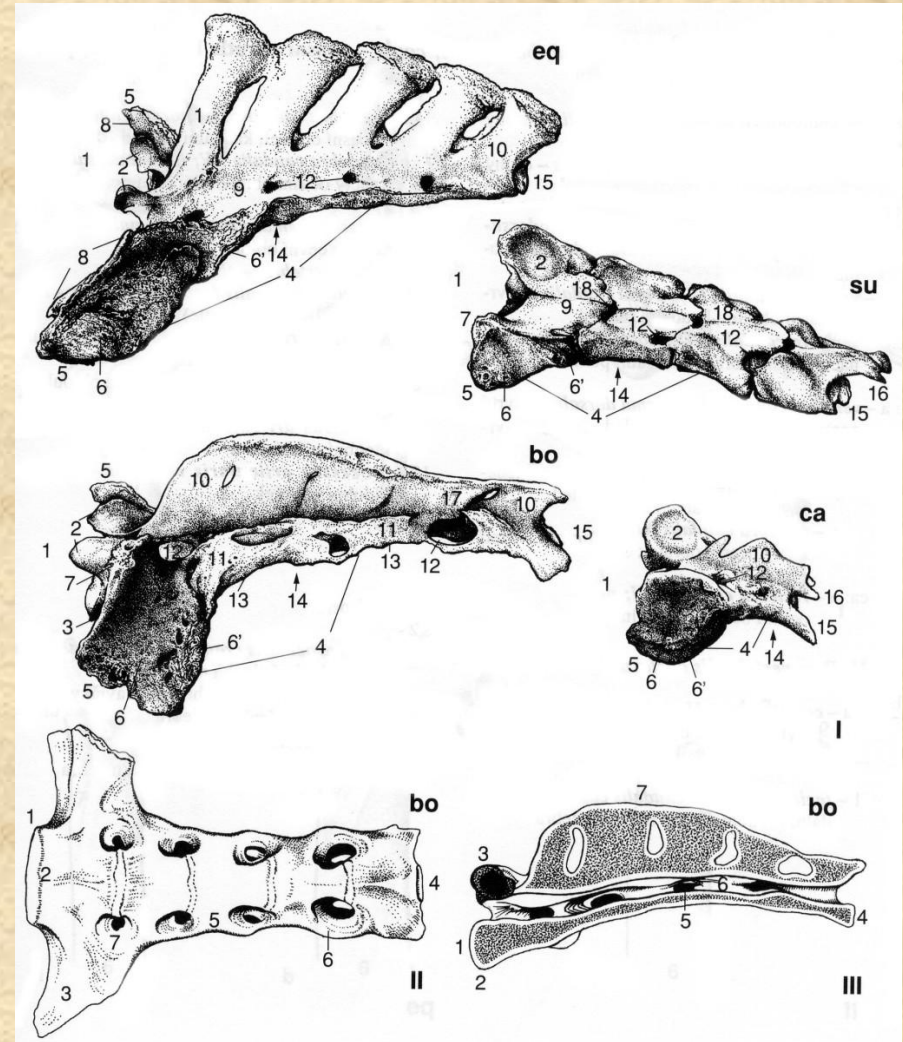


**Hrudní obratle (*vertebrae thoracicae*)**

# Obratle a žebra

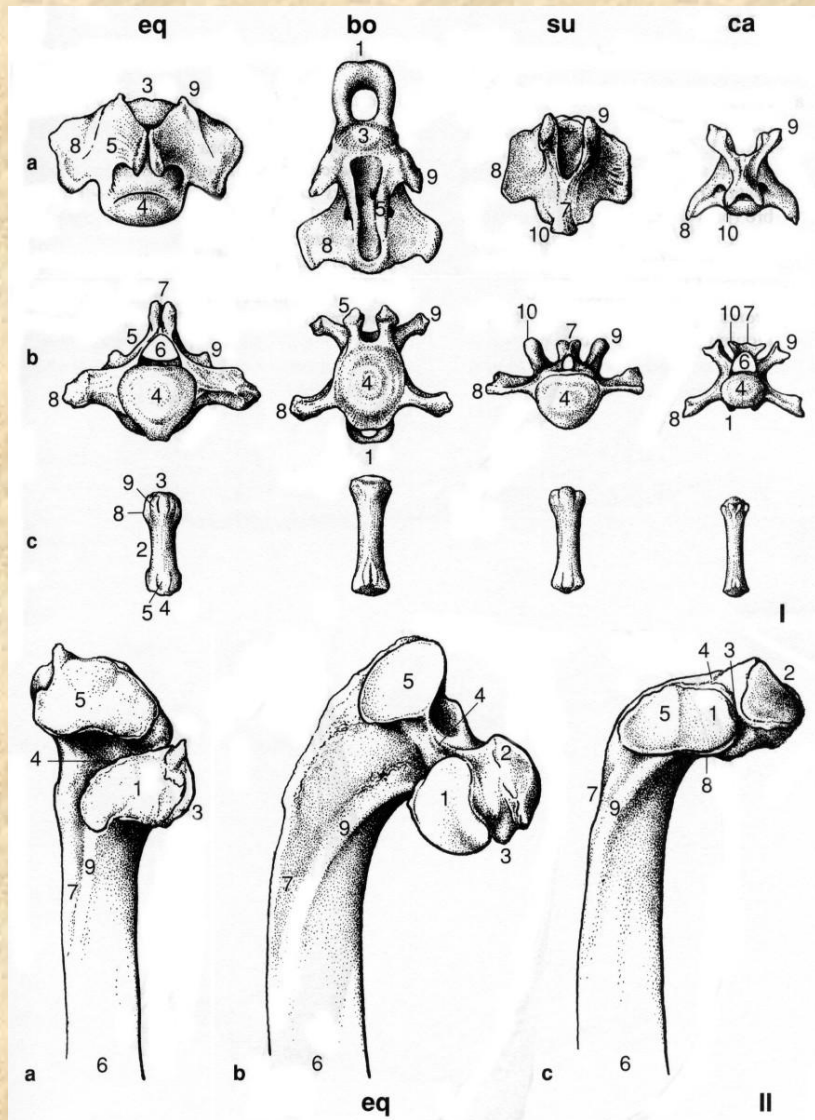


Bederní obratle (*vertebrae lumbales*)

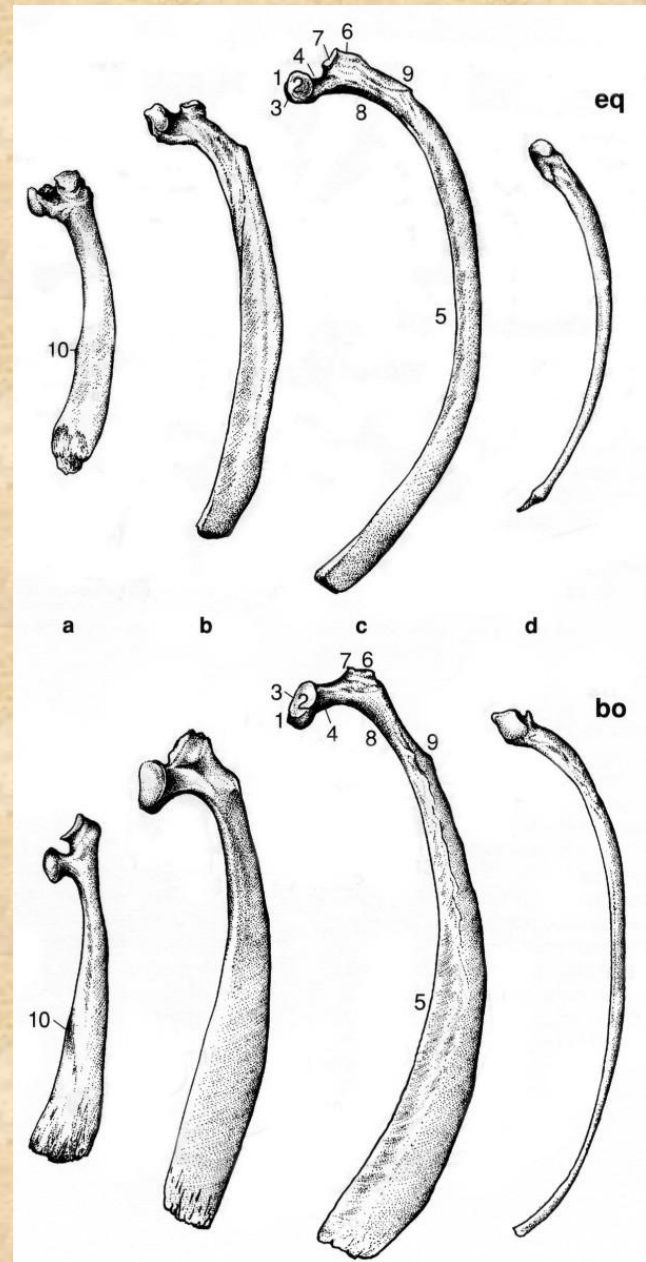


Kost křížová (*os sacrum*)

# Obratle a žebra

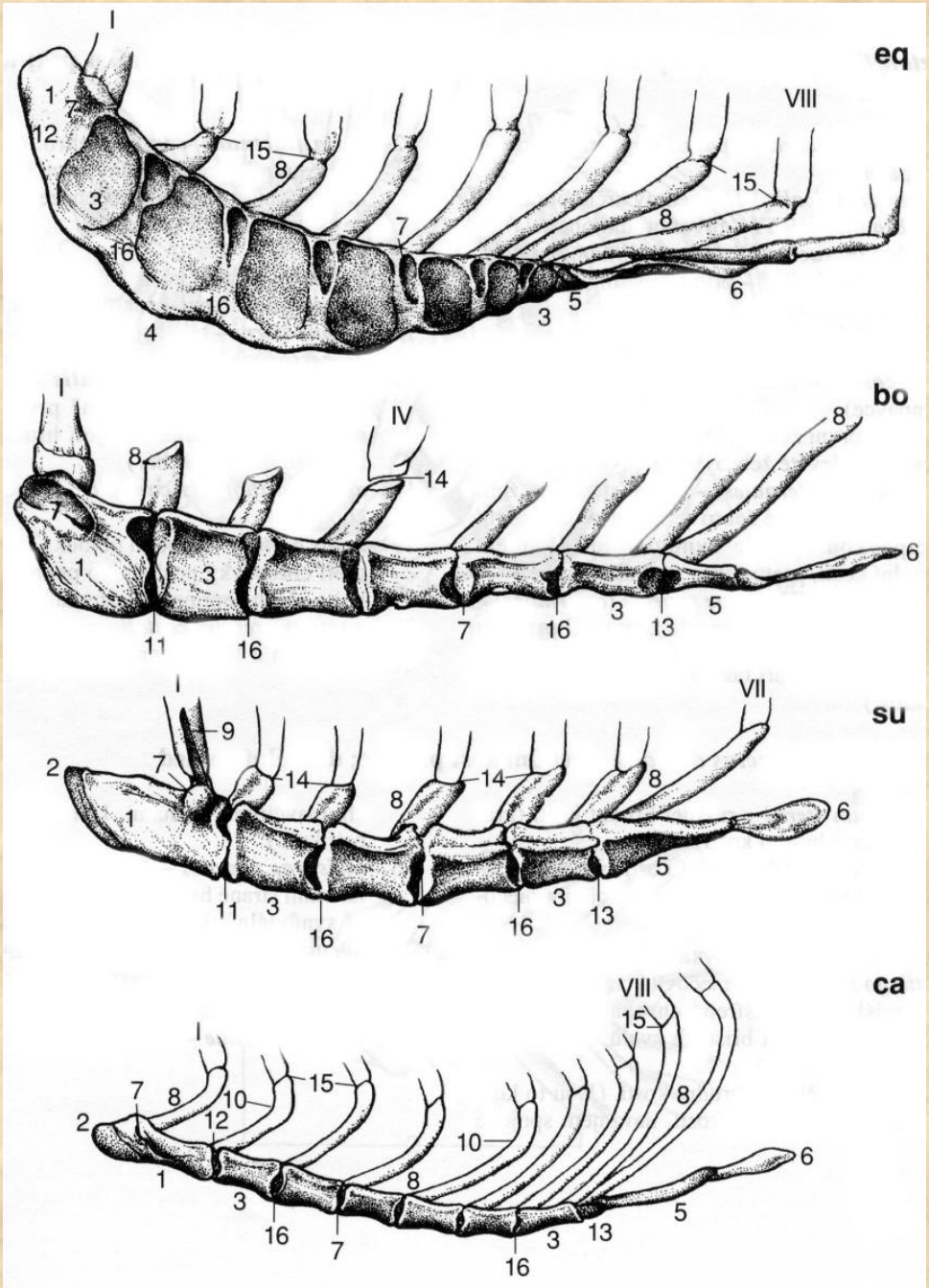


**Ocasní obratle (*vertebrae caudales*)  
a hlavičky žebří (caput costae) koně**

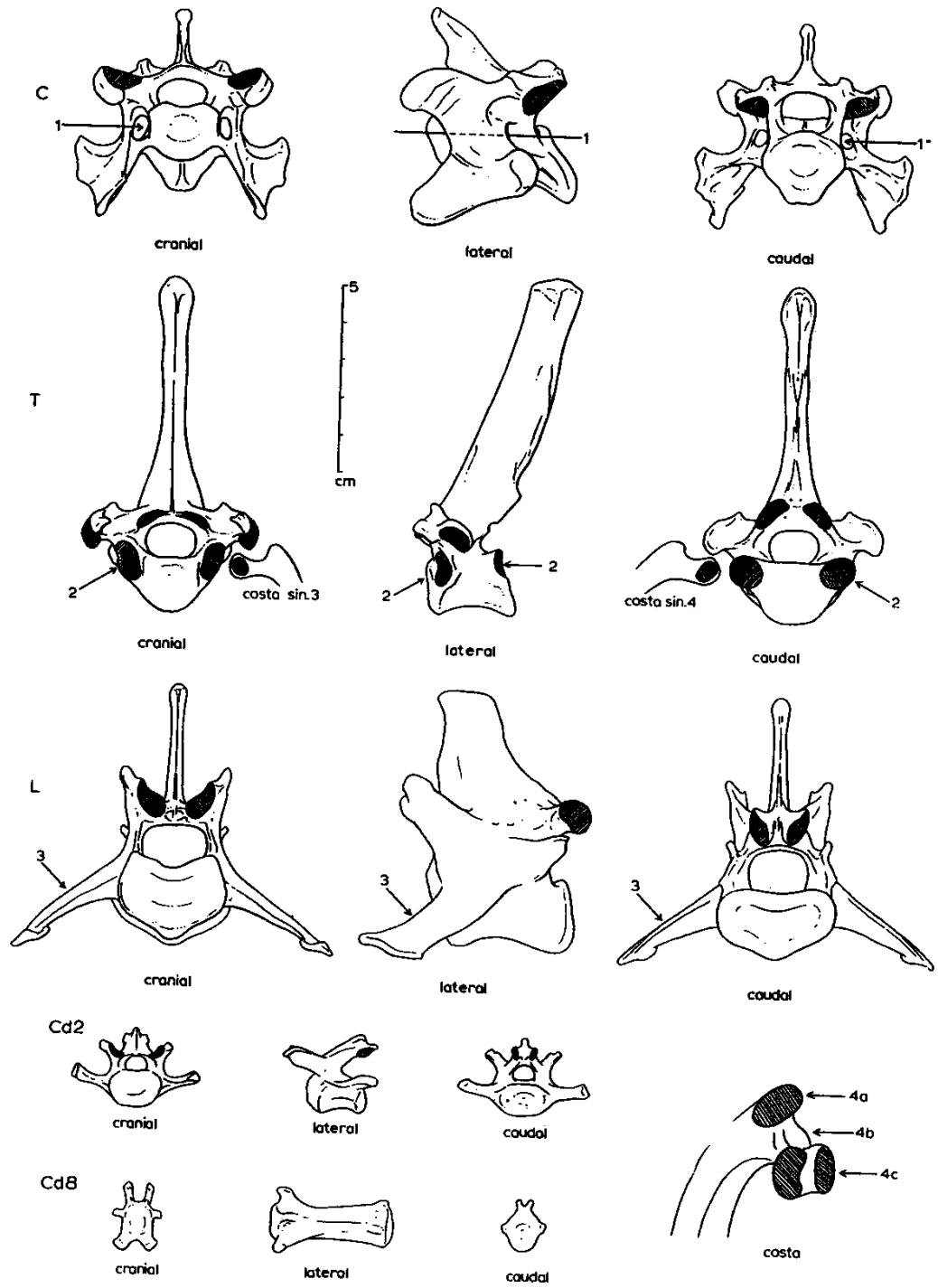


**Žebra (*costae*)**

# Hrudní kost (*sternum*)

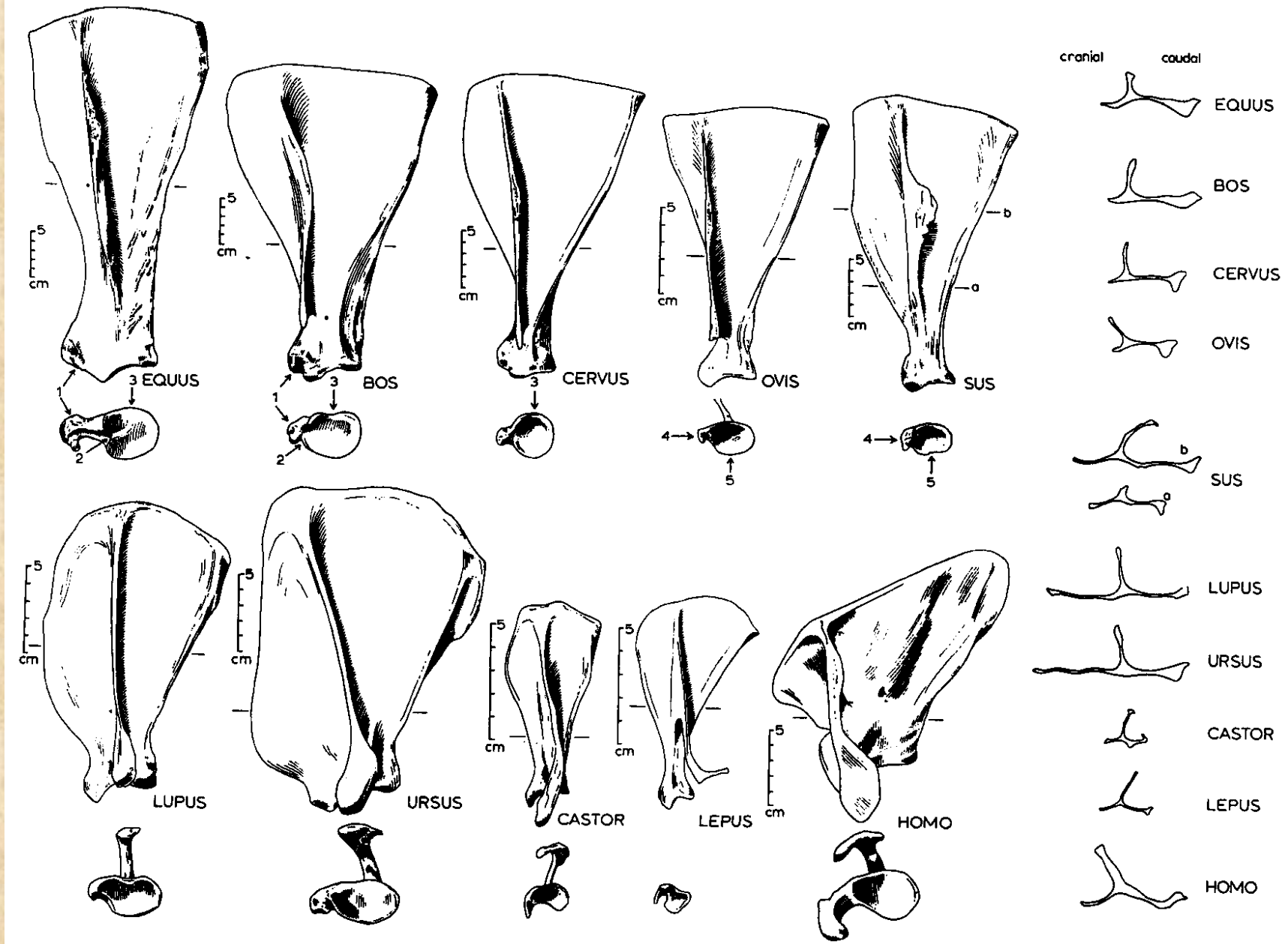


# Obratle vlka

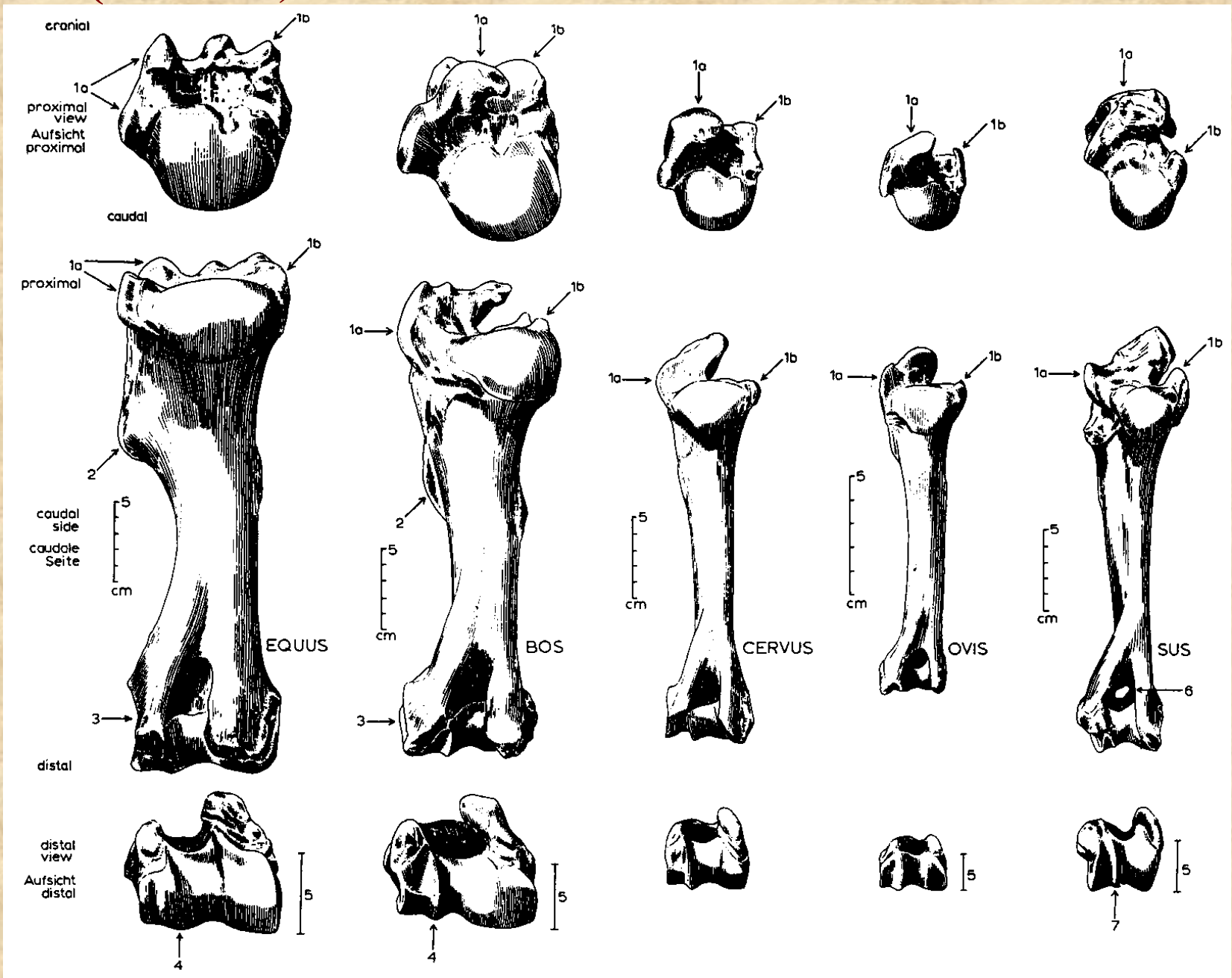




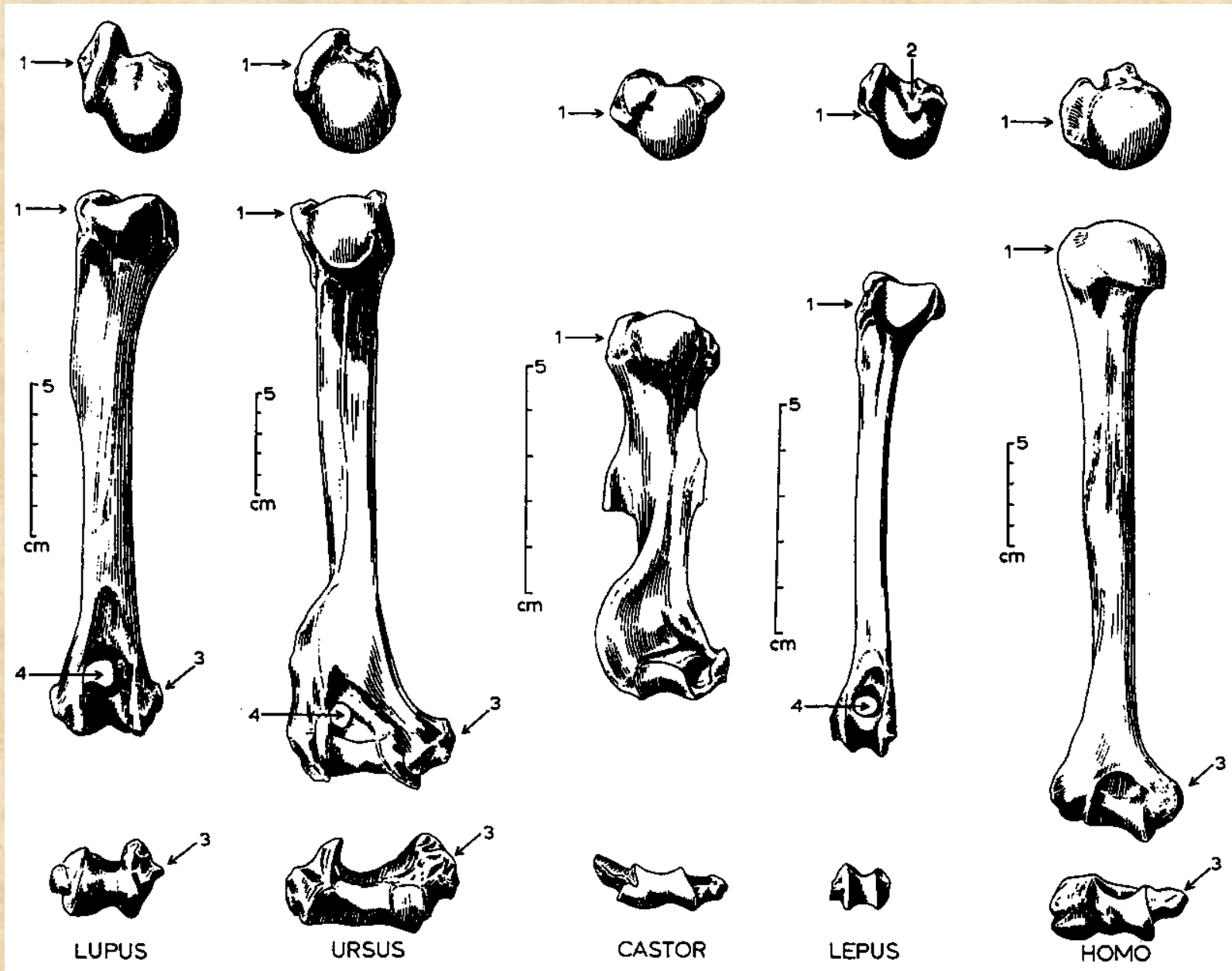
# Lopatka (*scapula*)



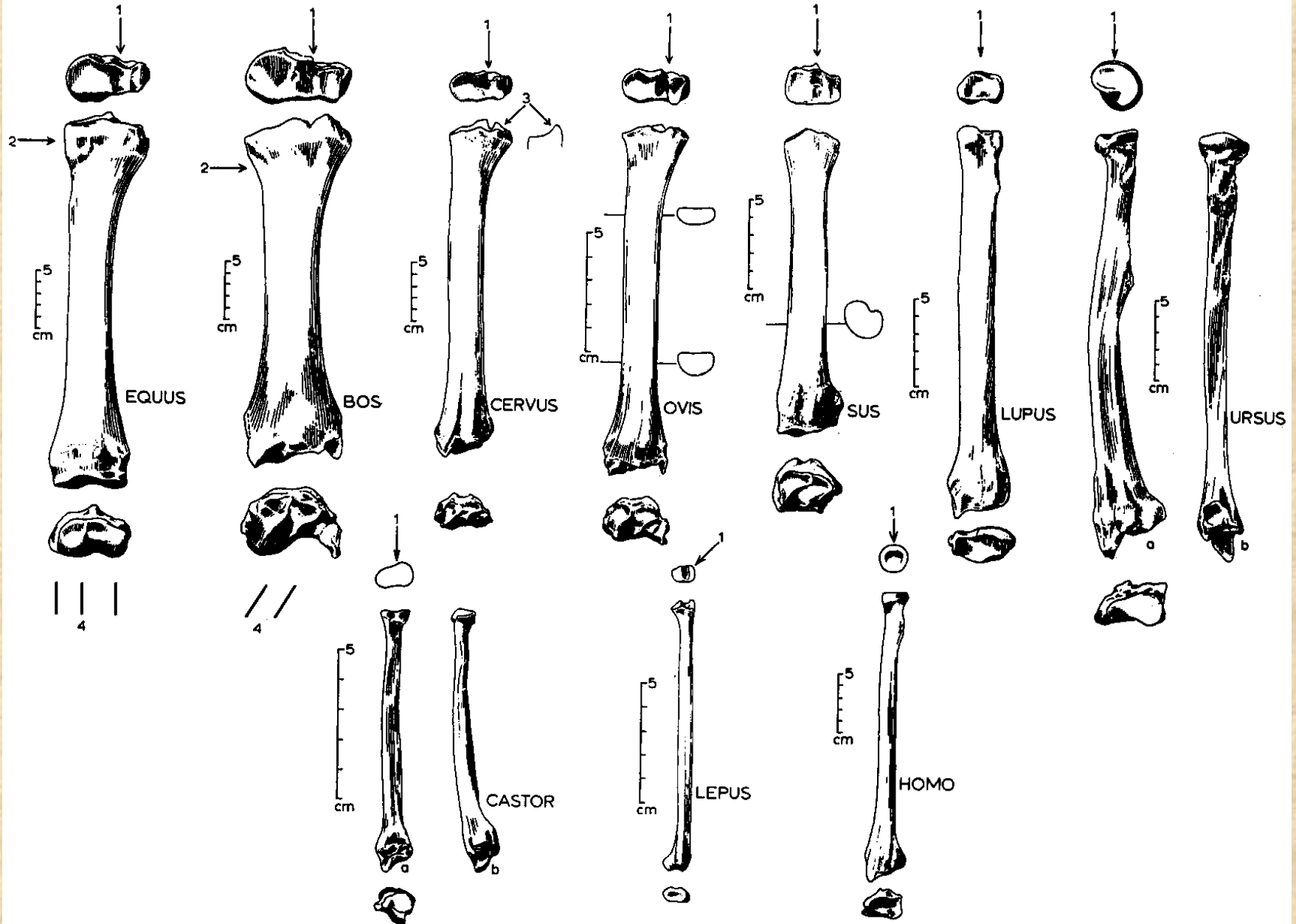
# Pažní kost (*humerus*)



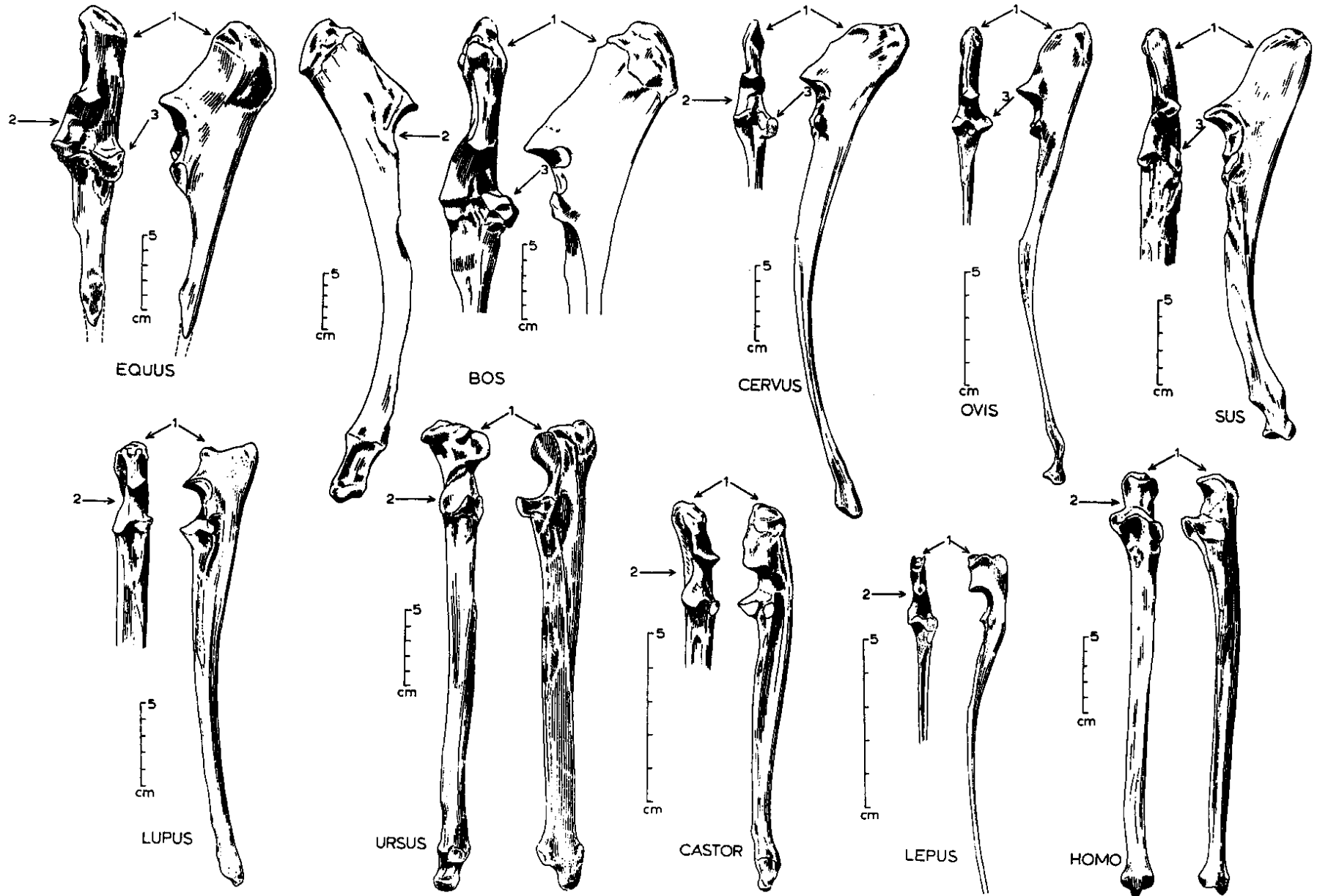
# Pažní kost (*humerus*)



# Vřetenní kost (*radius*)

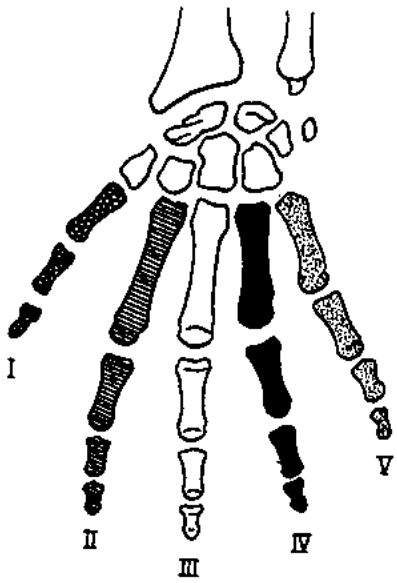


# Loketní kost (*ulna*)



# Stavba Autopodia

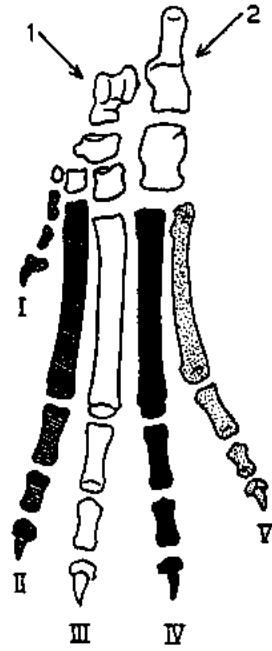
HOMO  
ant.



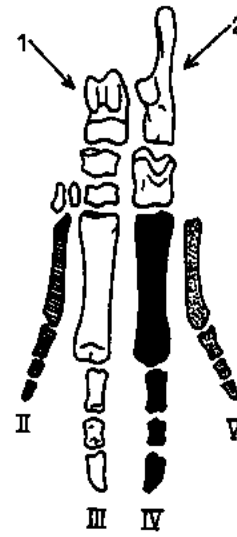
HOMO  
post.



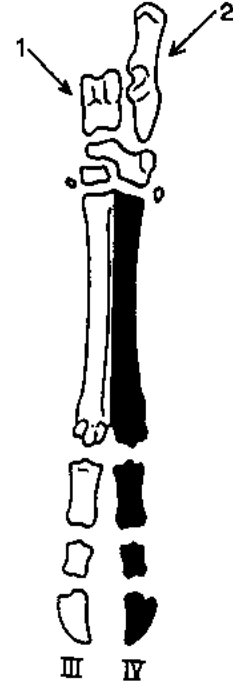
LUPUS  
post.



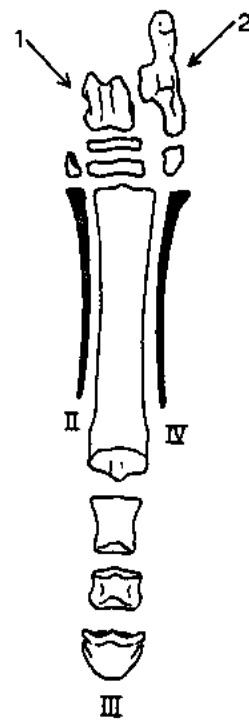
SUS  
post.



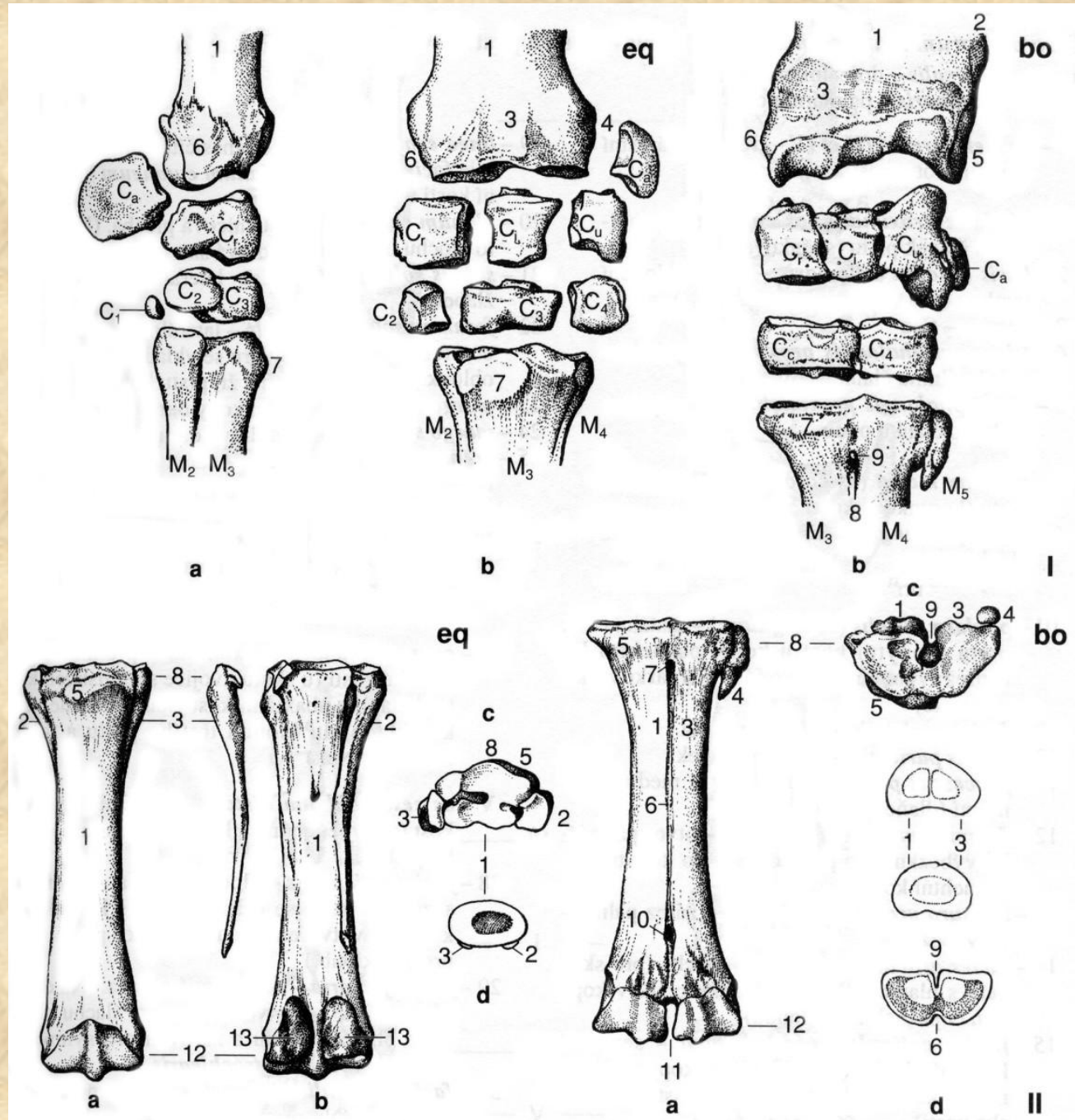
BOS  
post.



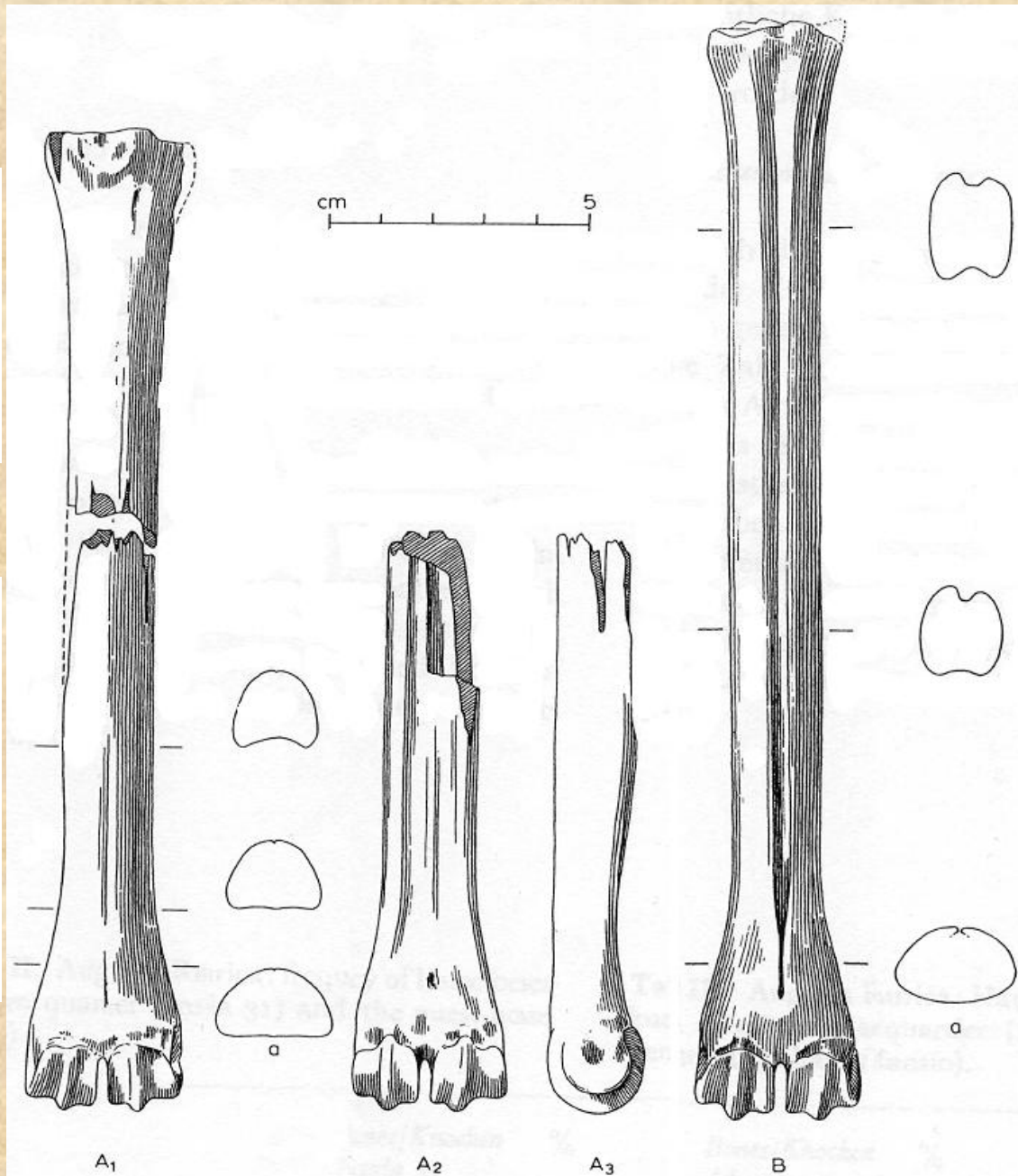
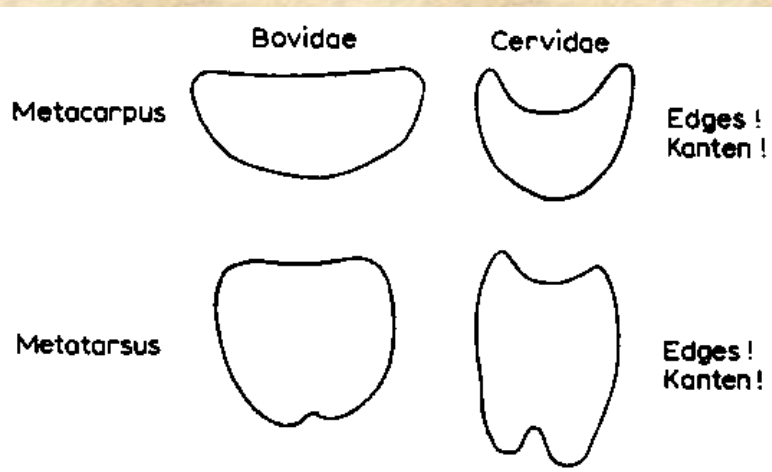
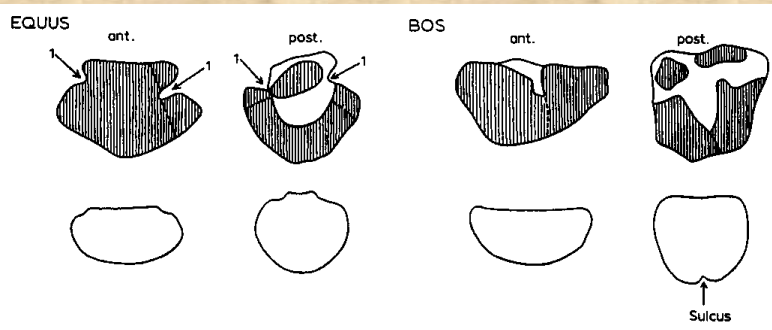
EQUUS  
post.



# Zápěstí (*carpus*)

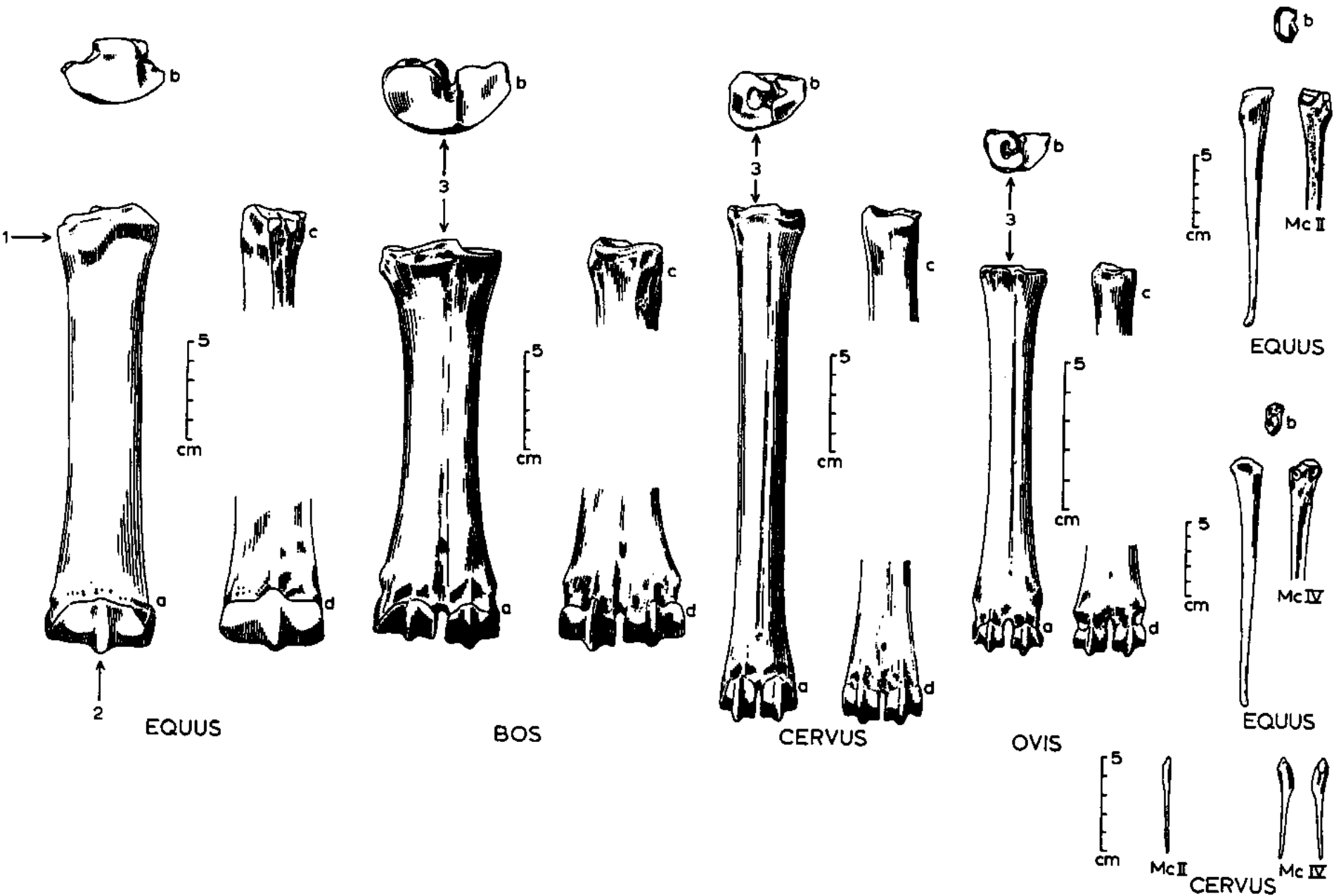


# Rozdíl mezi záprstními a nártními kostmi

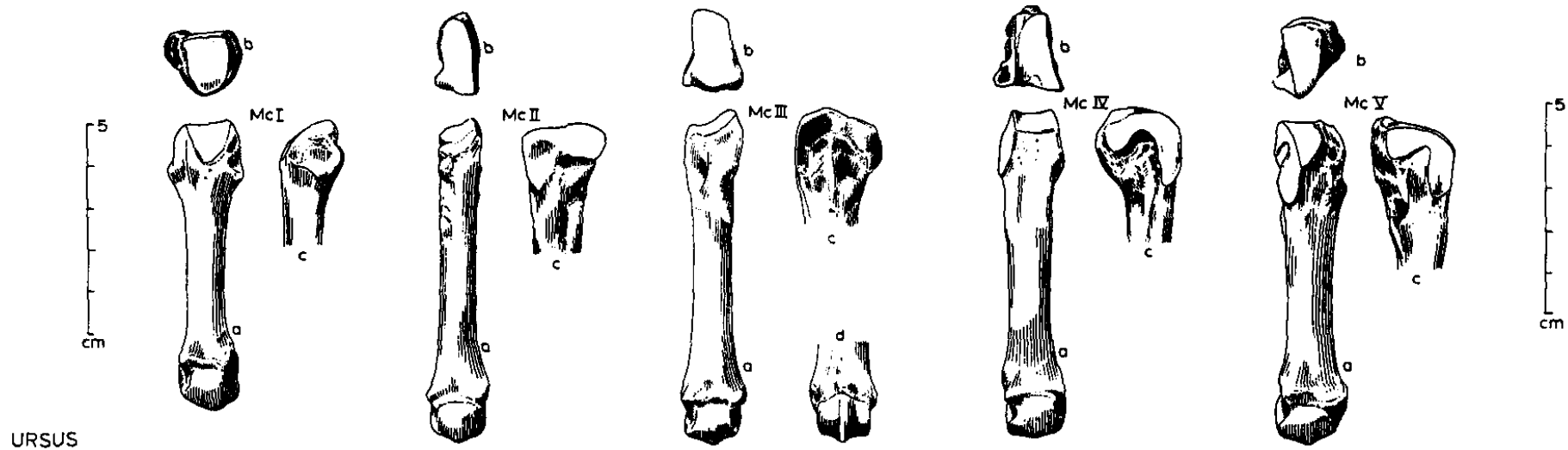
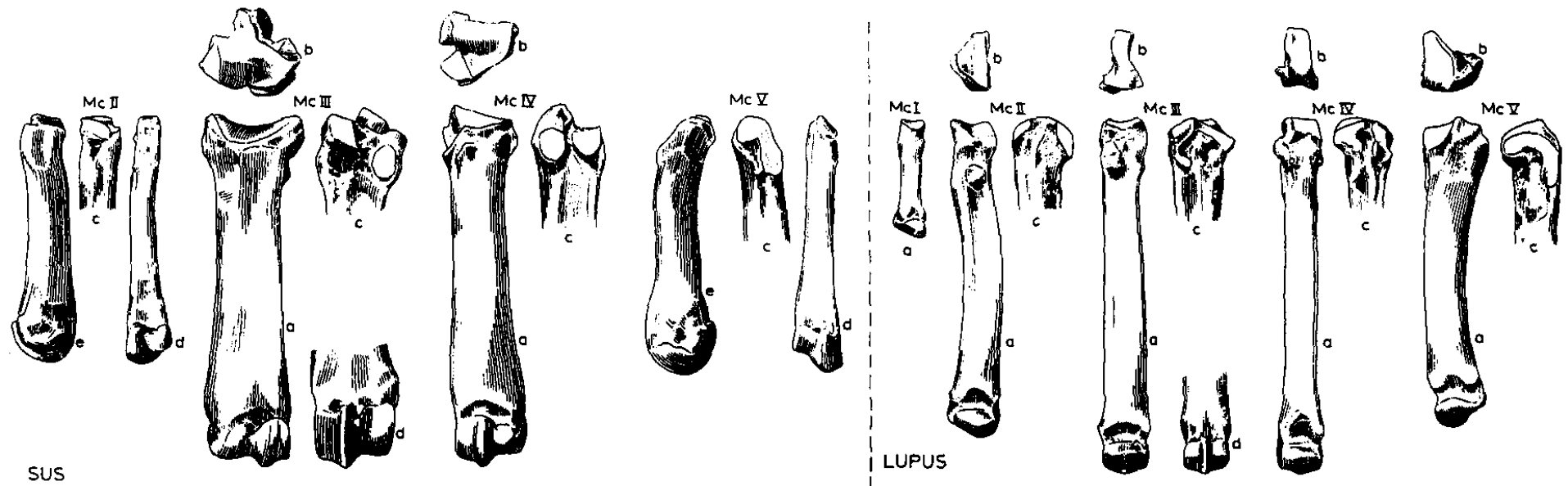




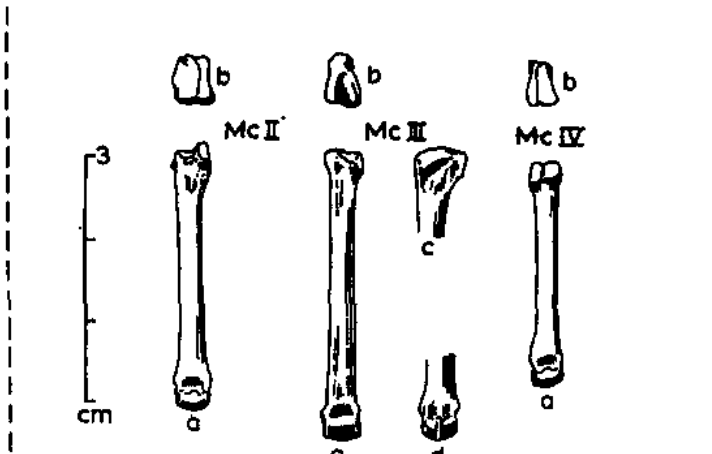
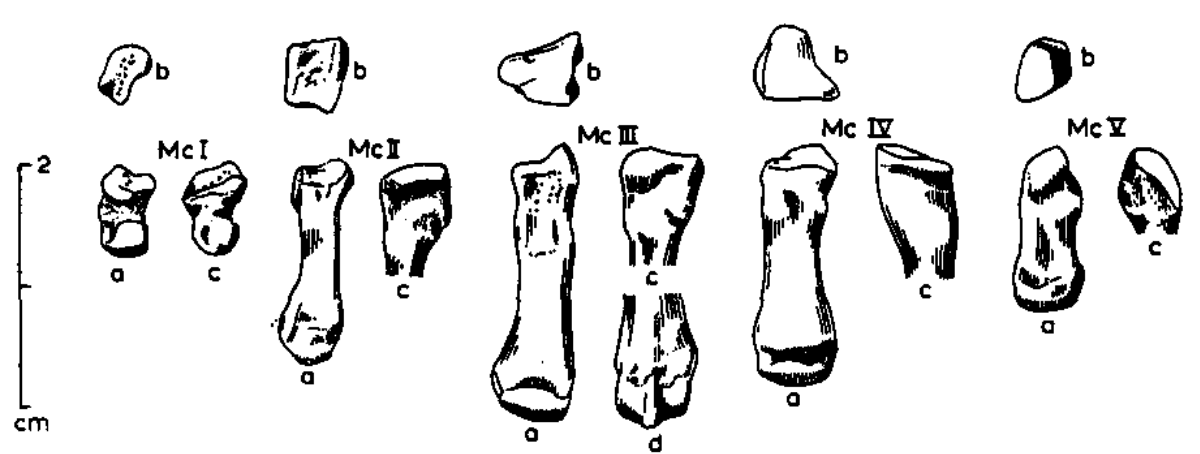
# Záprstní kosti (*metacarpalia*)



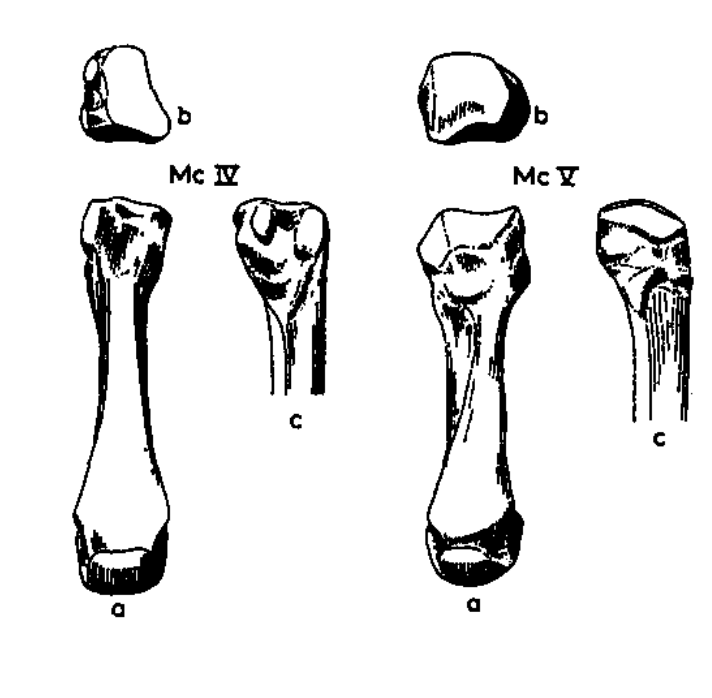
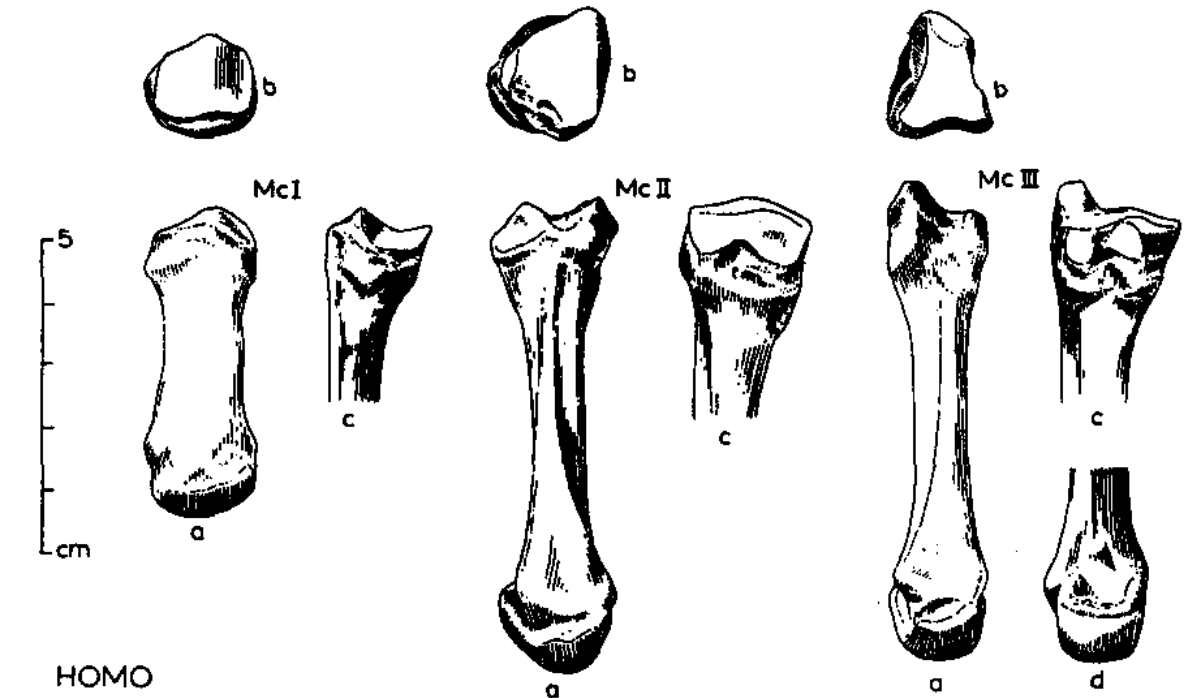
# Záprstní kosti (*metacarpalia*)



# Záprstní kosti (*metacarpalia*)



CASTOR LEPUS



HOMO



**Děkuji za pozornost!**

