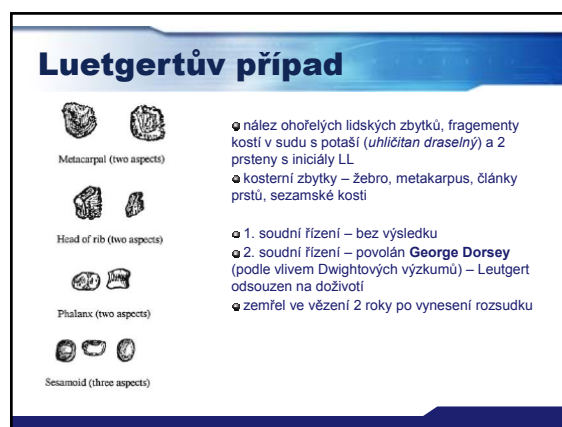
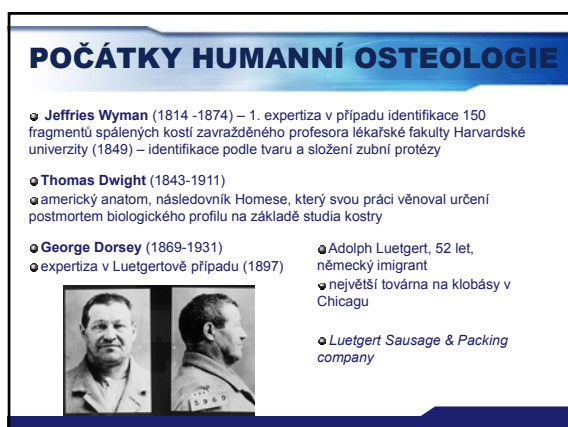
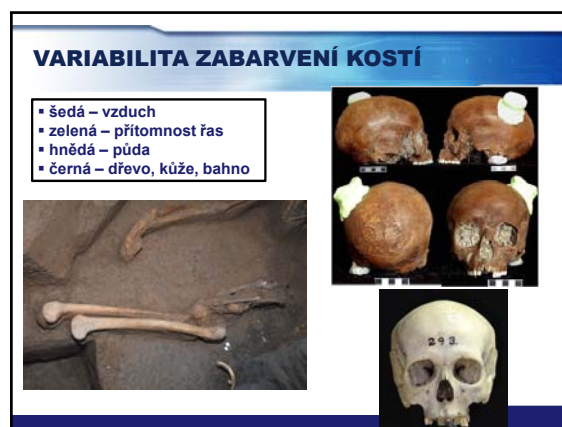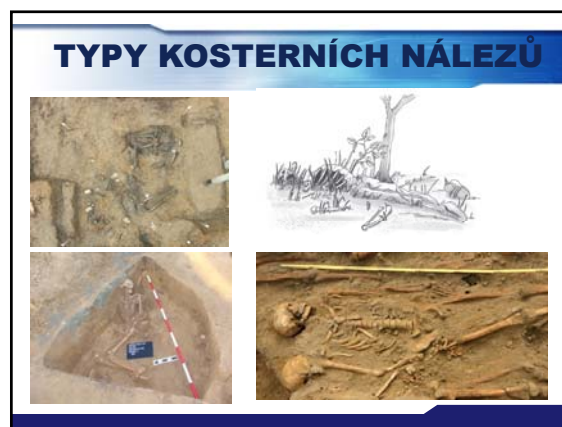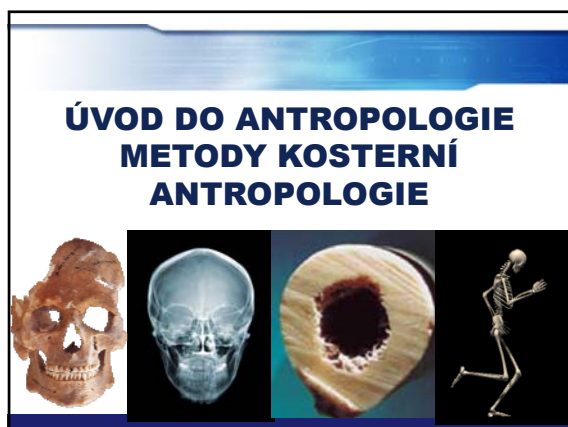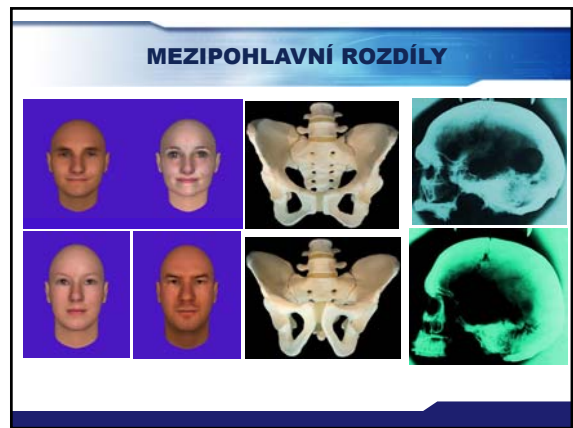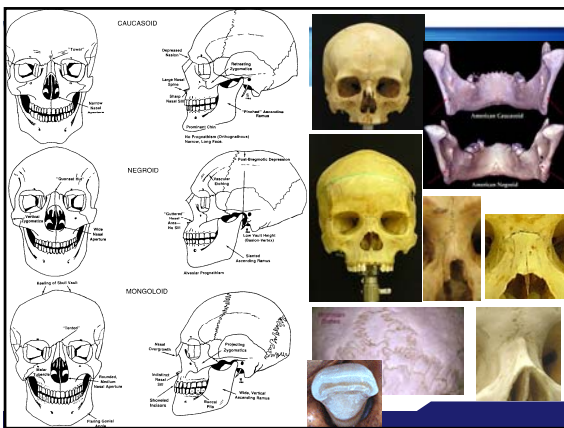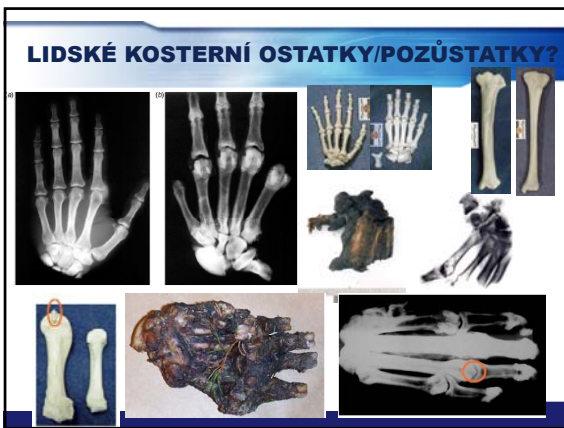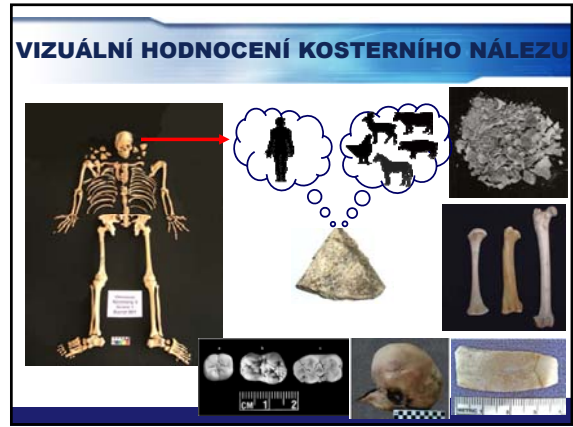Sex	Age	Alveolaria	Foramina	Foramina	Mandibula	Mandibula	Alveolaria
Male	1	wide	large	small	small	small	small
Female	2	narrow	small	large	large	large	large
Infant	3	absent	absent	absent	absent	absent	absent
Child	4	small	small	small	small	small	small
Adolescent	5	medium	medium	medium	medium	medium	medium
Adult	6	large	large	large	large	large	large
Elderly	7	very large	very large	very large	very large	very large	very large

### ODHAD VĚKU

Age	Skull	Ribs
10-15	Small, rounded	Small, curved
16-20	Medium, oval	Medium, curved
21-25	Large, oval	Large, curved
26-30	Large, oval	Large, curved
31-35	Large, oval	Large, curved
36-40	Large, oval	Large, curved
41-45	Large, oval	Large, curved
46-50	Large, oval	Large, curved
51-55	Large, oval	Large, curved
56-60	Large, oval	Large, curved
61-65	Large, oval	Large, curved
66-70	Large, oval	Large, curved
71-75	Large, oval	Large, curved
76-80	Large, oval	Large, curved
81-85	Large, oval	Large, curved
86-90	Large, oval	Large, curved
91-95	Large, oval	Large, curved
96-100	Large, oval	Large, curved

### TRAUMATOLOGIE KOSTERNÍHO NÁLEZU

### ZRANĚNÍ OSTRÝM PŘEDMĚTEM

### ZRANĚNÍ TUPÝM PŘEDMĚTEM

Blunt Trauma: 1. Impact, 2. Compression, 3. Fracture

Gunshot Trauma: 1. Entrance, 2. Exit, 3. Fracture

F. Kanz, K. Grossschmidt / Forensic Science International 150 (2004) 203-216



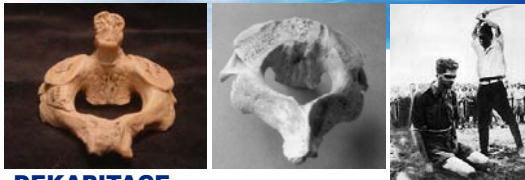
### ANTE/PERI/POSTMORTEM ZÁSAHY NA KOSTŘE



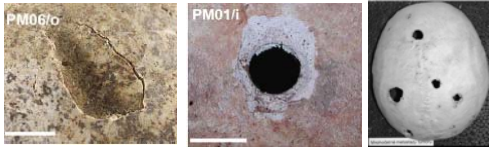
řetězová pila      pilka na kov      pitevná pilka



### DEKAPITACE

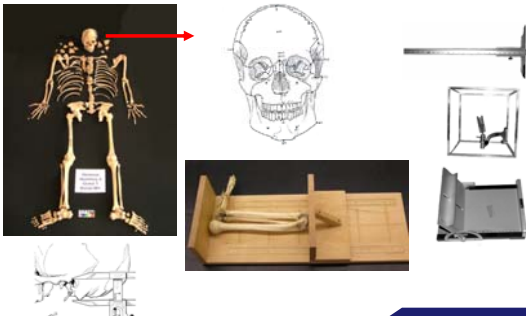


### TRAMATOLOGICKÉ MIMICRY



20

### OSTEOMETRIE, ANTROPOMETRIE



### BIOLOGICKÝ PROFIL - TĚLESNÉ PROPORCE



- URČENÍ POHLAVÍ
- ODHAD POPULAČNÍ AFINITY
- ODHAD VĚKU – fetus, novorozenci