

11

Zrak II

Vytváření obrazu

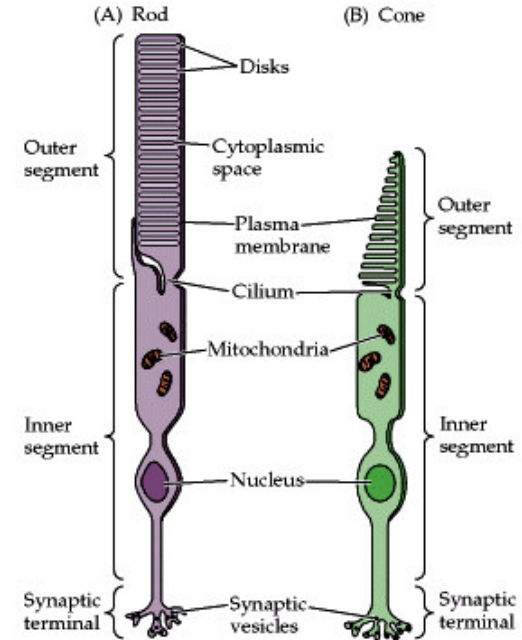
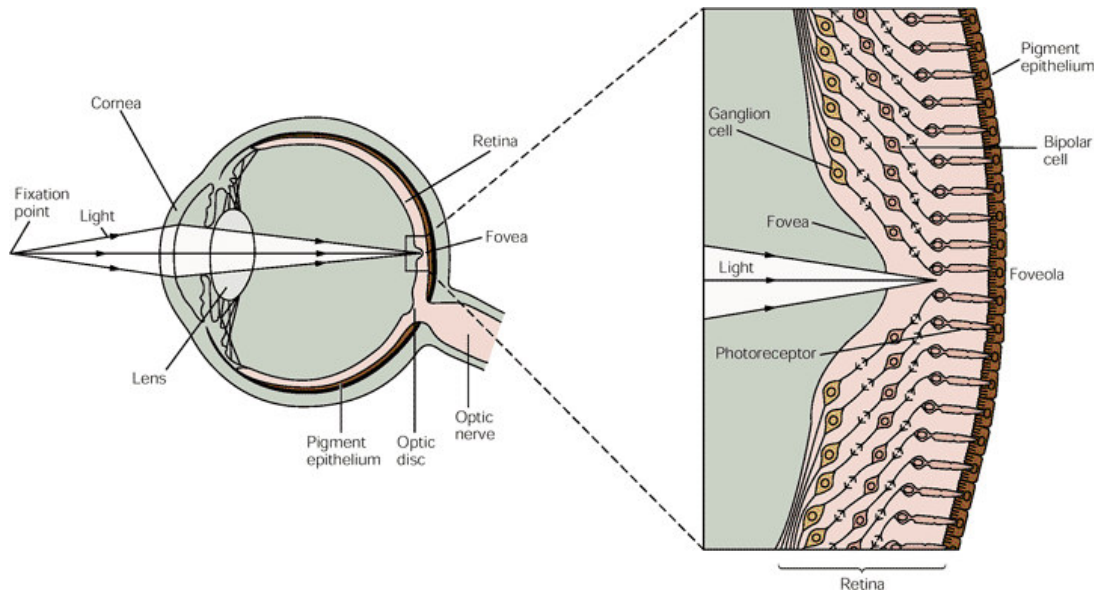
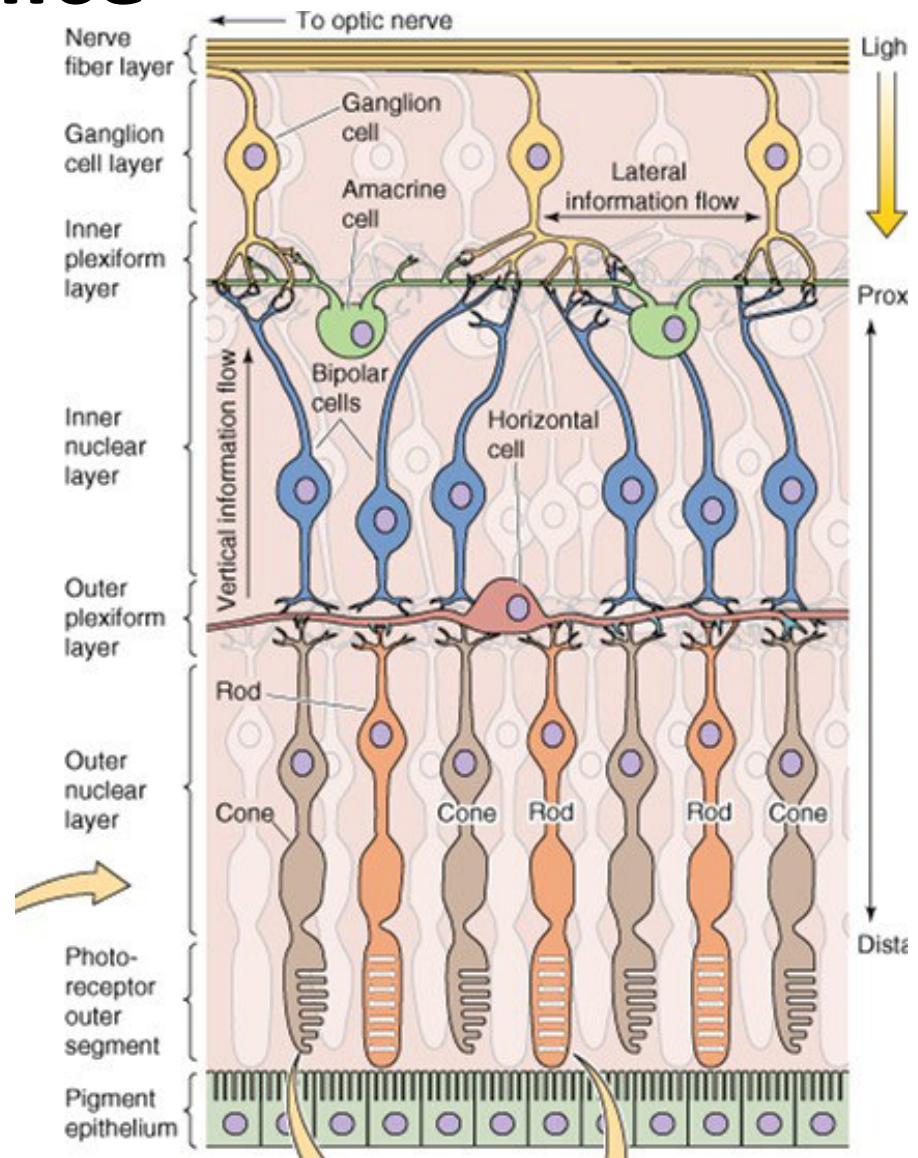


Table 26-1 Differences Between Rods and Cones and Their Neural Systems

Rods	Cones
High sensitivity to light, specialized for night vision	Lower sensitivity, specialized for day vision
More photopigment, capture more light	Less photopigment
High amplification, single photon detection	Lower amplification
Low temporal resolution: slow response, long integration time	High temporal resolution: fast response, short integration time
More sensitive to scattered light	Most sensitive to direct axial rays
Rod system	Cone system
Low acuity: not present in central fovea, highly convergent retinal pathways	High acuity: concentrated in fovea, dispersed retinal pathways
Achromatic: one type of rod pigment	Chromatic: three types of cones, each with a distinct pigment that is most sensitive to a different part of the visible light spectrum

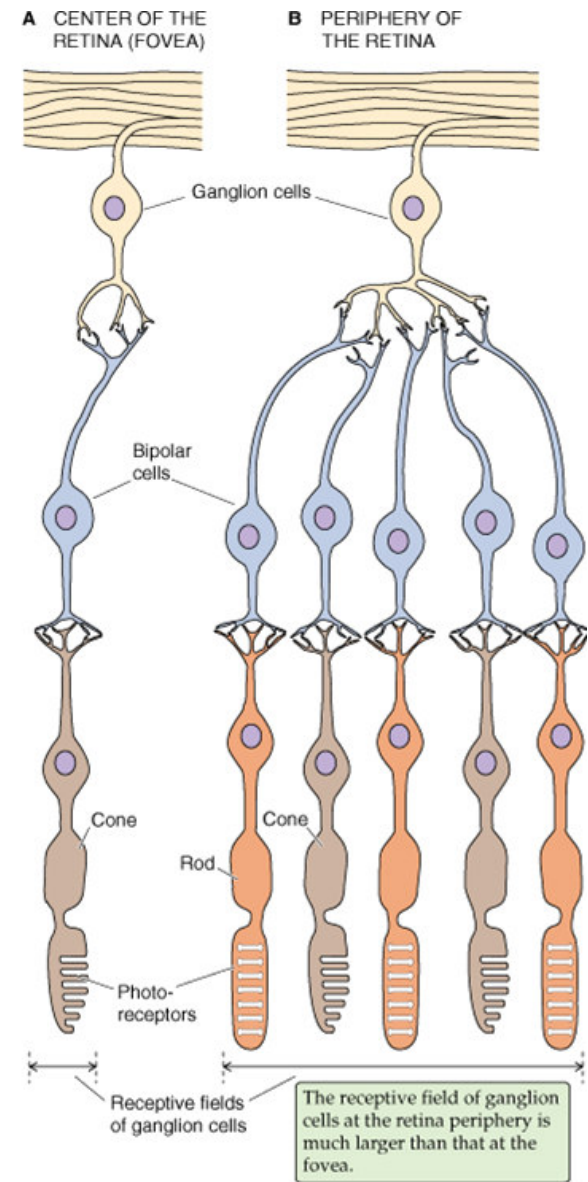
Sítnice

- Fotoreceptory
- Interneurony
 - Horizontální buňky
 - Horizontální propojení
 - Bipolární buňky
 - Vertikální propojení
 - Amakrinní buňky
 - Horizontální i vertikální propojení
- Gangliové buňky
 - Tvorba AP
 - Transmise AP do mozku

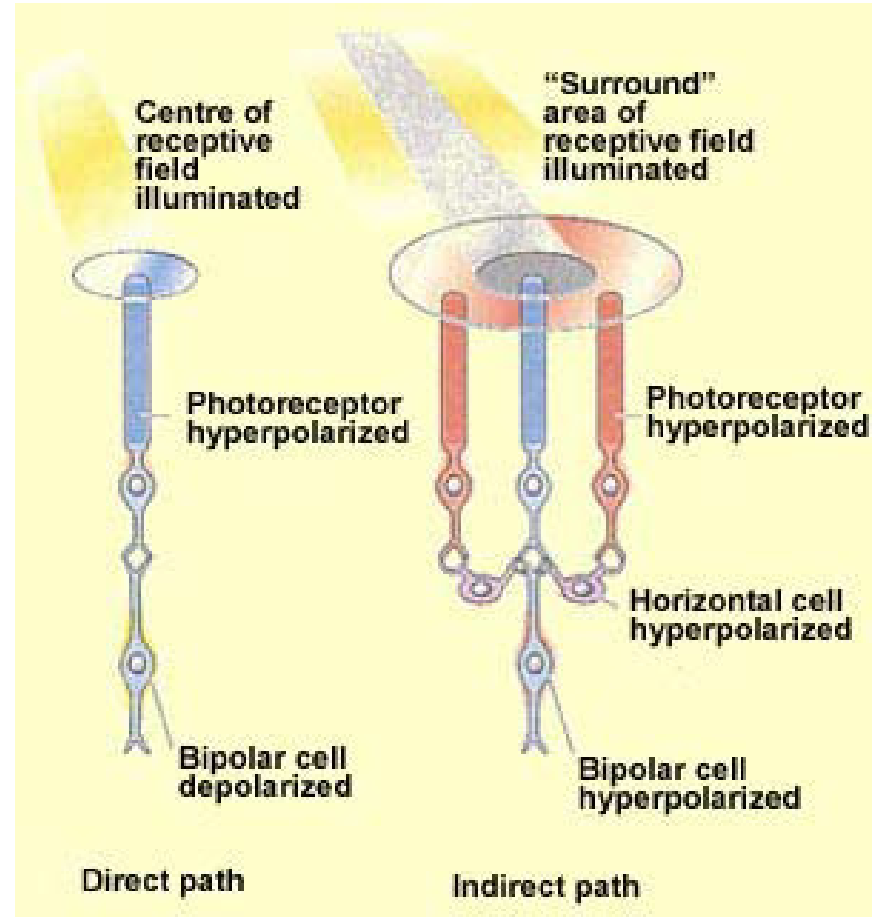
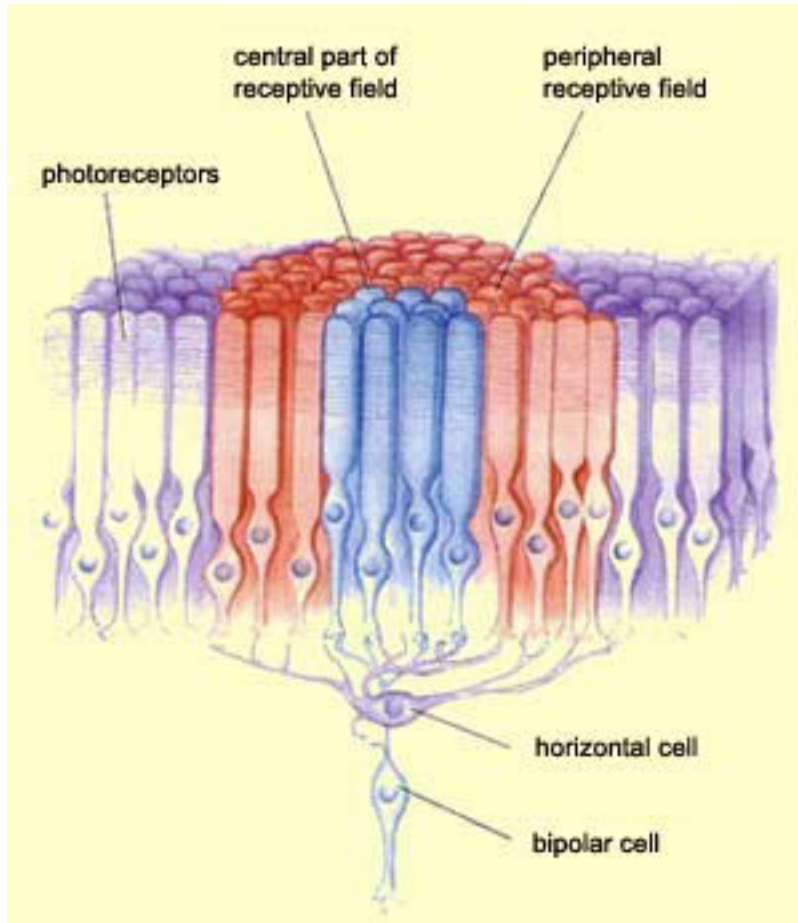


Sítnice



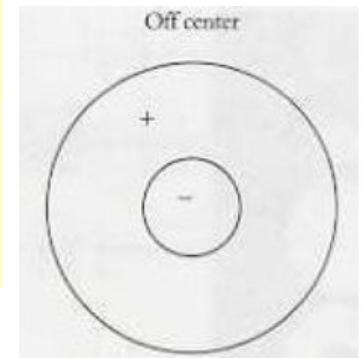
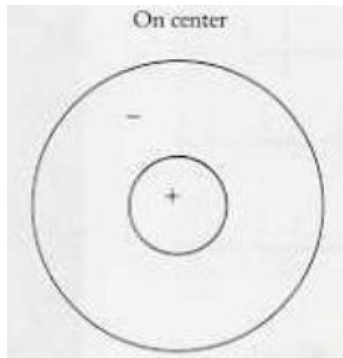
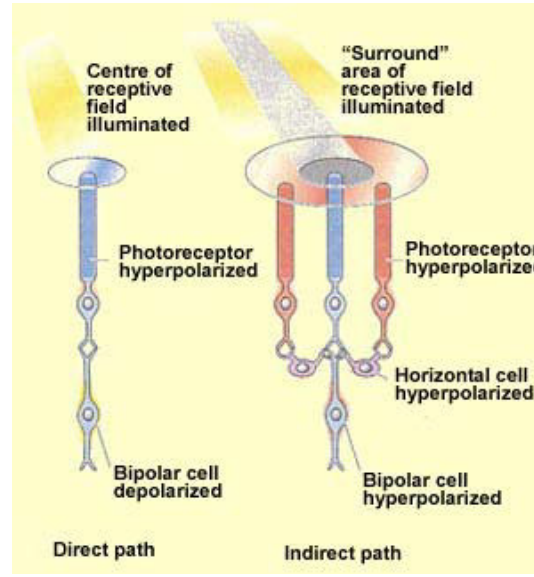
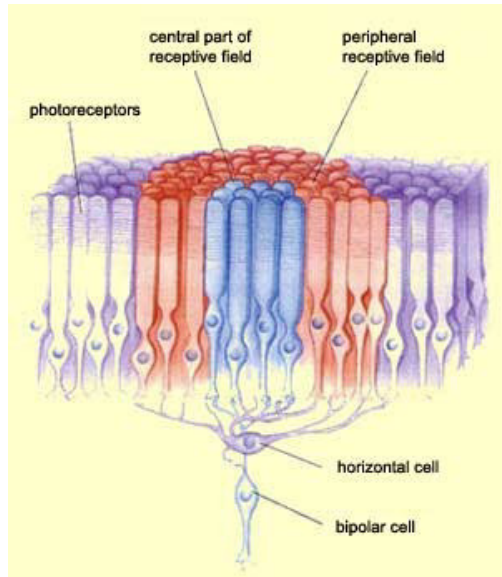
- Fovea
 - Malá konvergence signálu
 - Malé receptivní pole
 - Vysoké rozlišení
 - Malá senzitivita ke světlu
- Periferie sítnice
 - Velká konvergence signálu
 - Velké receptivní pole
 - Nízké rozlišení
 - Vysoká senzitivita ke světlu



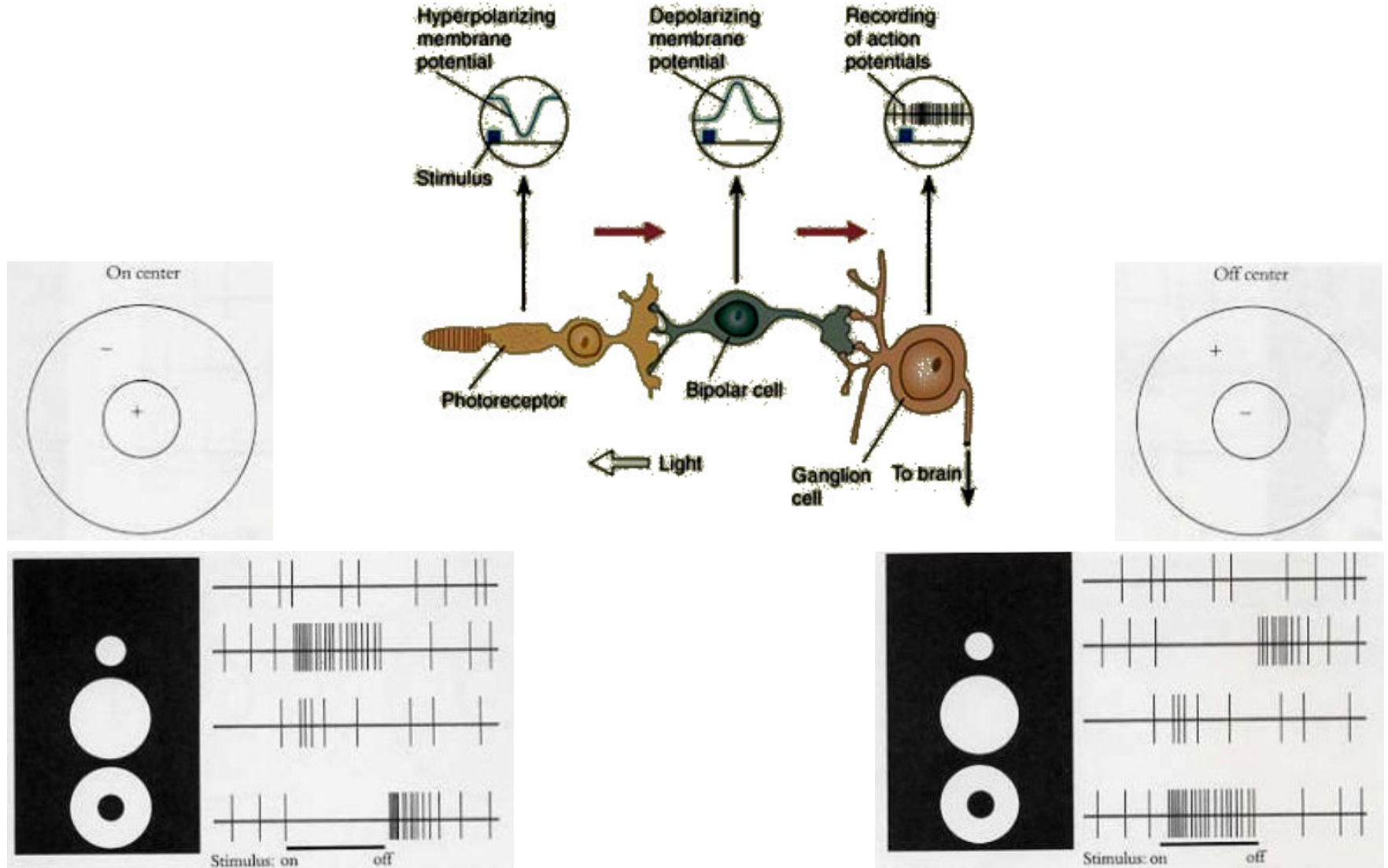
Receptivní pole



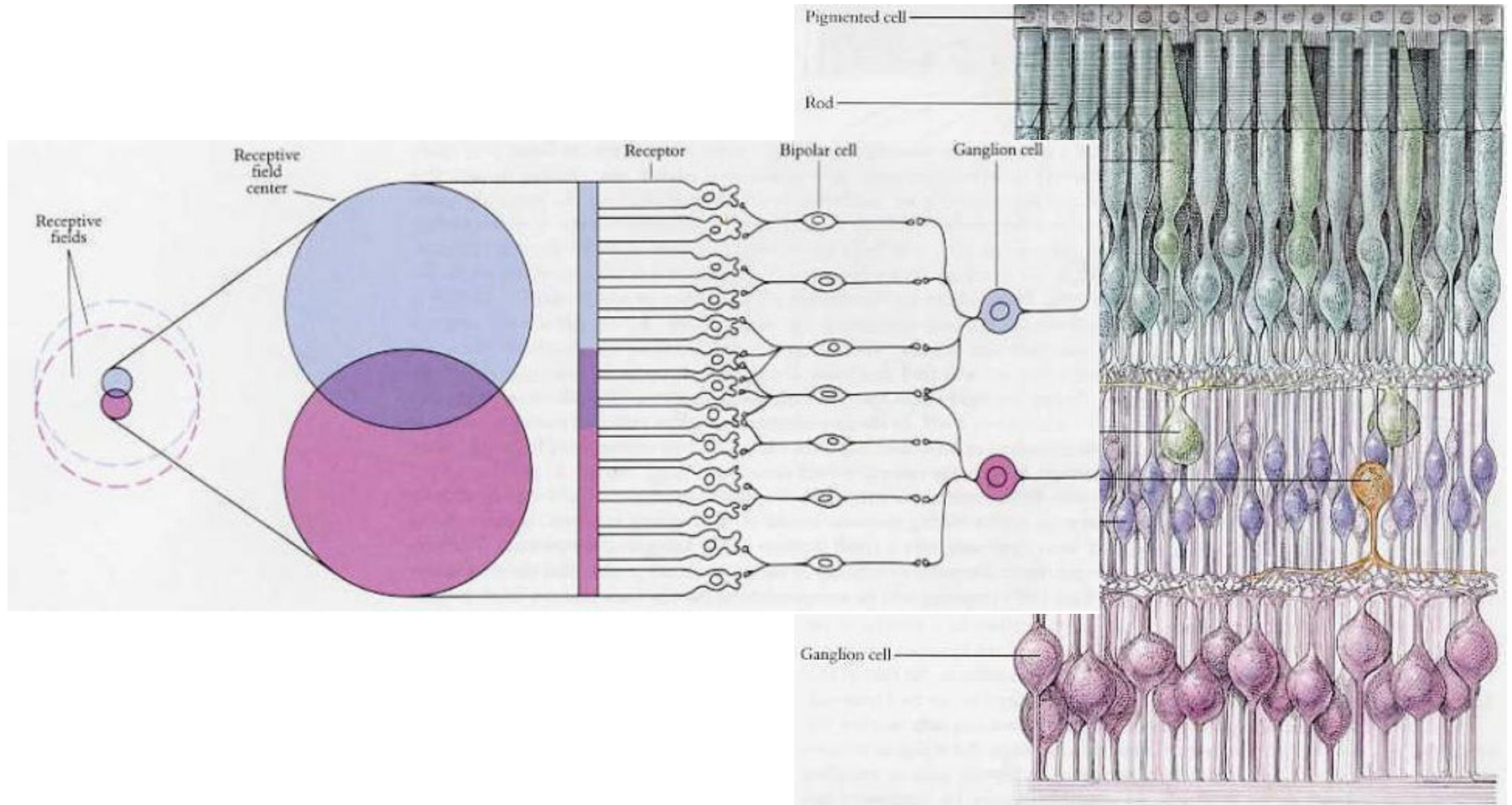
Receptivní pole



Receptivní pole


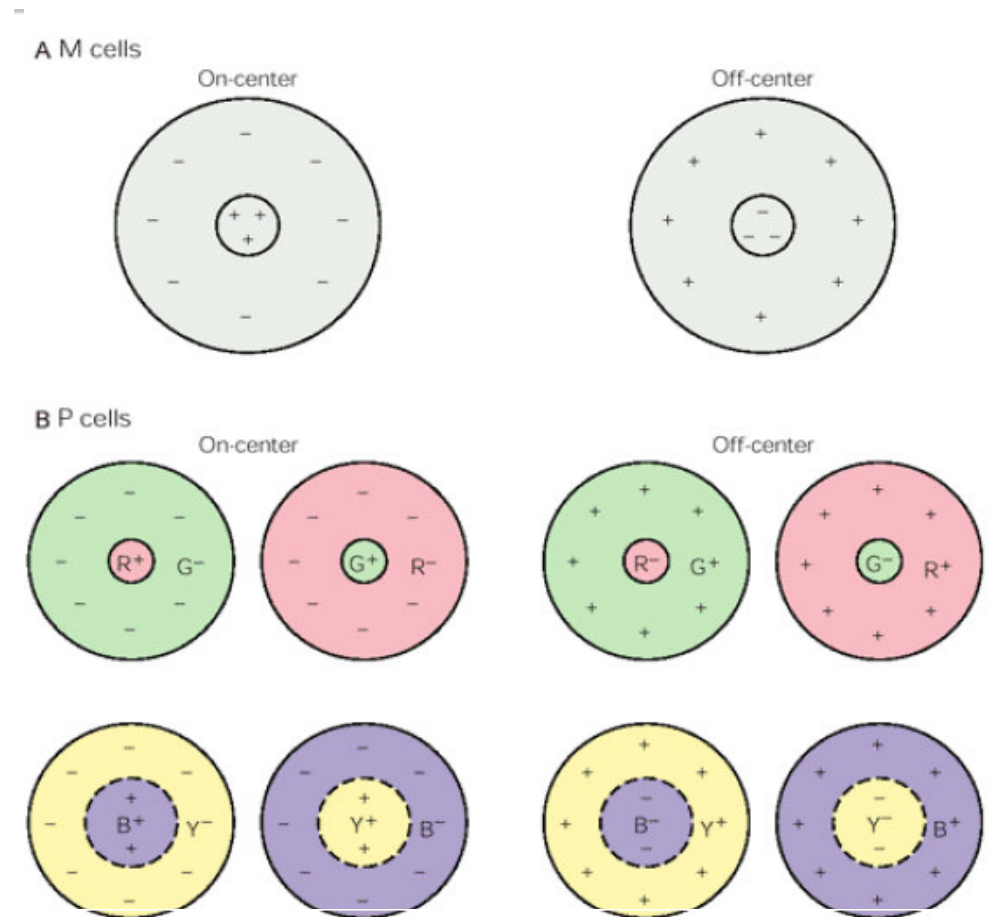


Receptivní pole



Receptivní pole

- Magnocelulární systém
 - Velká receptivní pole
 - Tyčinky i čípky
 - **M gangliové buňky (10%)**
 - Vysoká rychlost vedení
 - Dobrá senzitivita na jas/nízký kontrast
 - Minimální senzitivita na barvu
- Parvocelulární systém
 - Malá receptivní pole
 - Čípky i tyčinky
 - **P gangliové buňky (80%)**
 - Pomalá rychlost vedení
 - Špatná senzitivita na nízký kontrast
 - Dobrá senzitivita na barvu



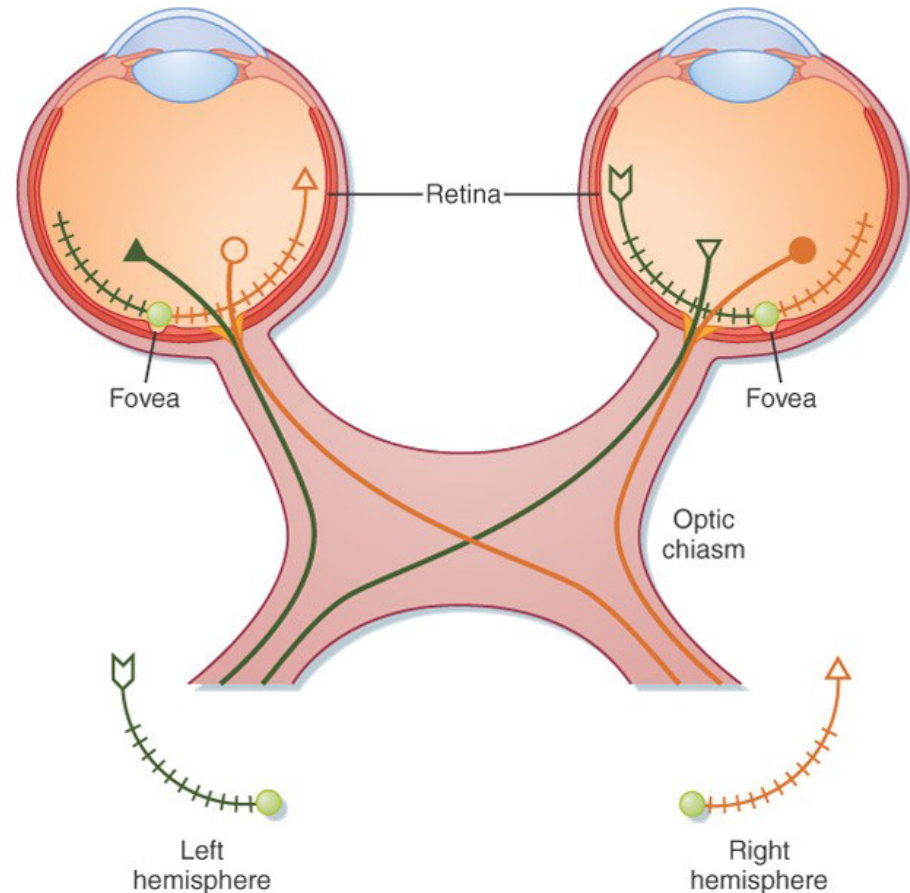
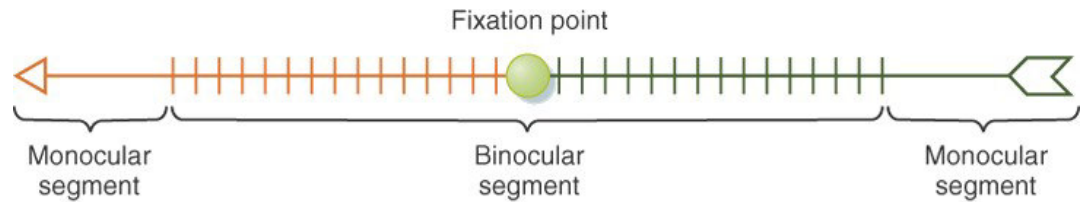
Nervus opticus a tractus opticus

- Nervus opticus

- Informace z jednoho oka
- Informace z „celého“ zorného pole

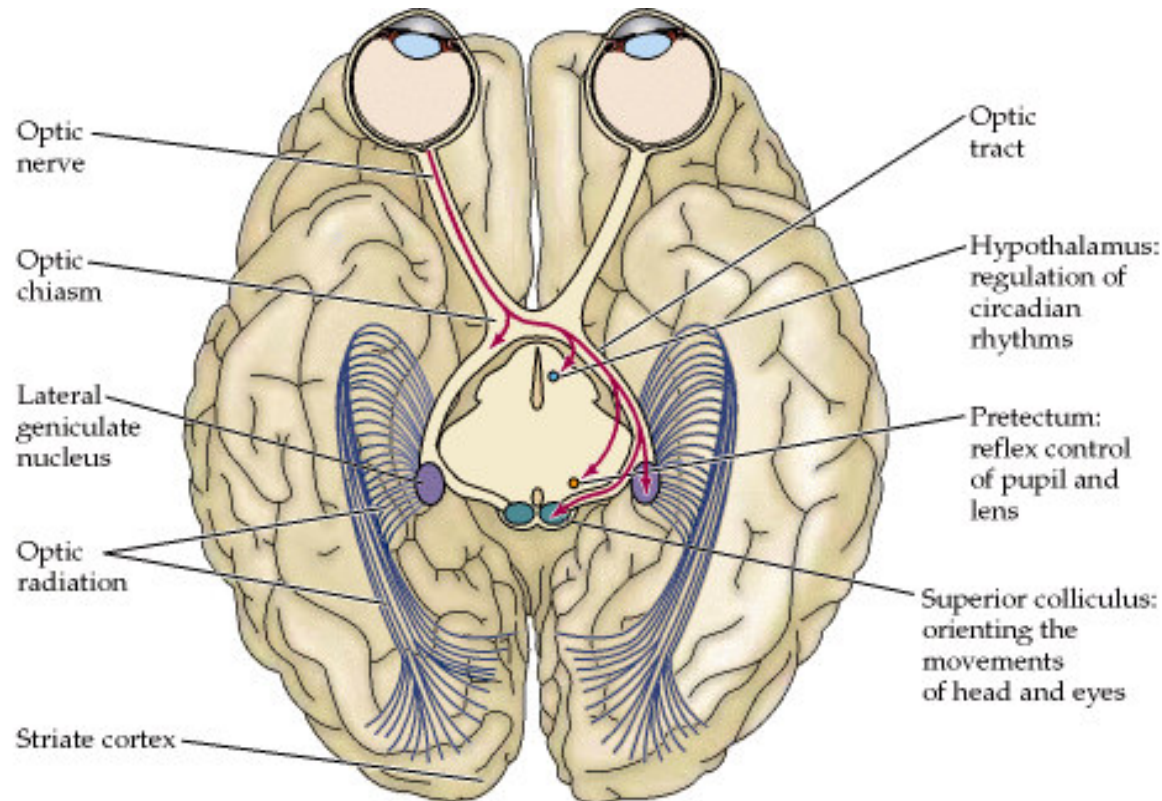
- Tractus opticus

- Informace z obou očí
- Informace z poloviny zorného pole



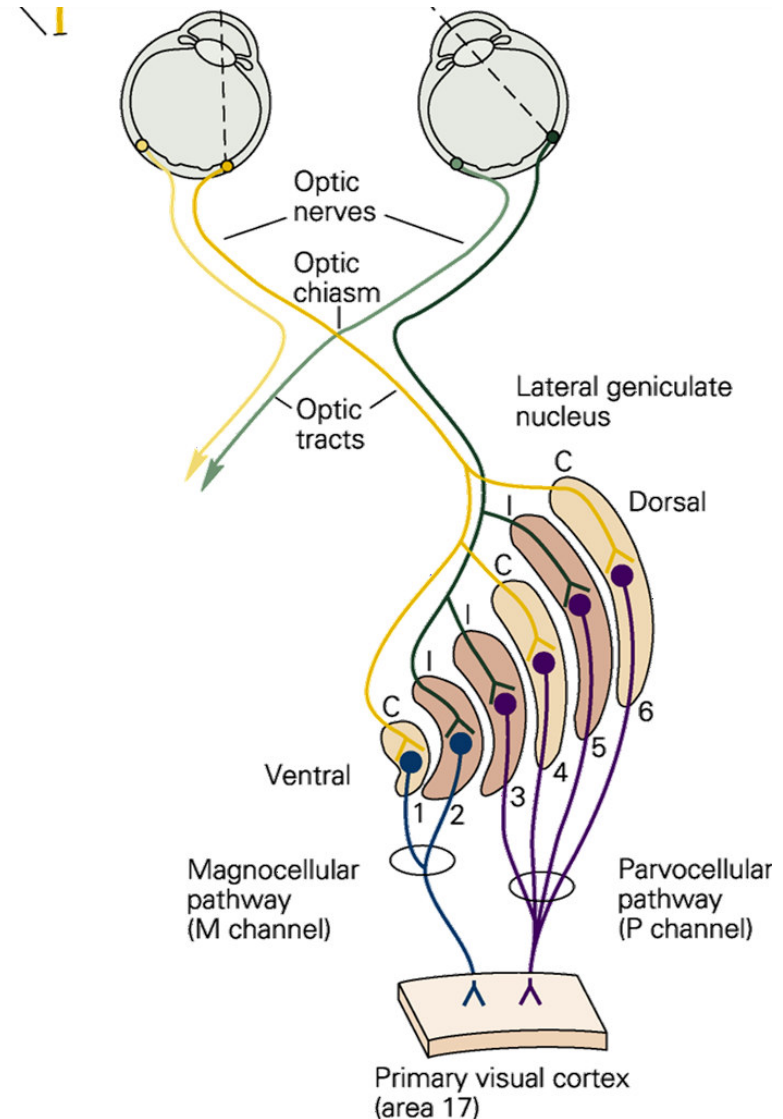
Zraková dráha

- Nucleus corporis geniculati lateralis
 - Thalamus
 - Většina signálu
 - Dále cestou radiation optica do neokortexu
- Hypothalamus
 - Regulace cirkadiální aktivity
- Pretectum
 - Pupilární reflex
- Colliculi superiores
 - Reflexní pohyby očí a hlavy



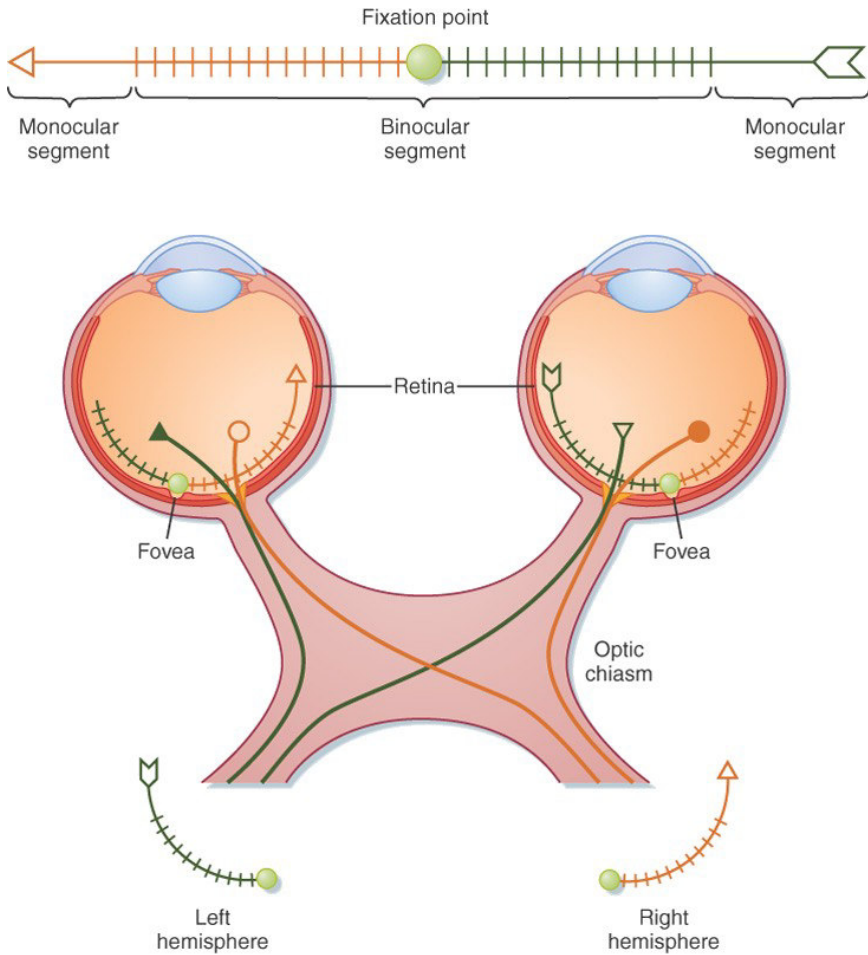
Nucleus corporis geniculati lateralis

- Šest jaderných vrstev
- Retinotopická organizace
- Každá vrstva dostává informace pouze z jednoho oka
- Vrstva 1-2
 - Magnocelulární systém
 - M gangliové buňky
 - Velká receptivní pole / reakce na jas
 - Informace o lokalizaci a pohyby
- Vrstva 3-6
 - Parvocelulární systém
 - P gangliové buňky
 - Malá receptivní pole / reakce na barvu
 - Informace o tvaru a barvě

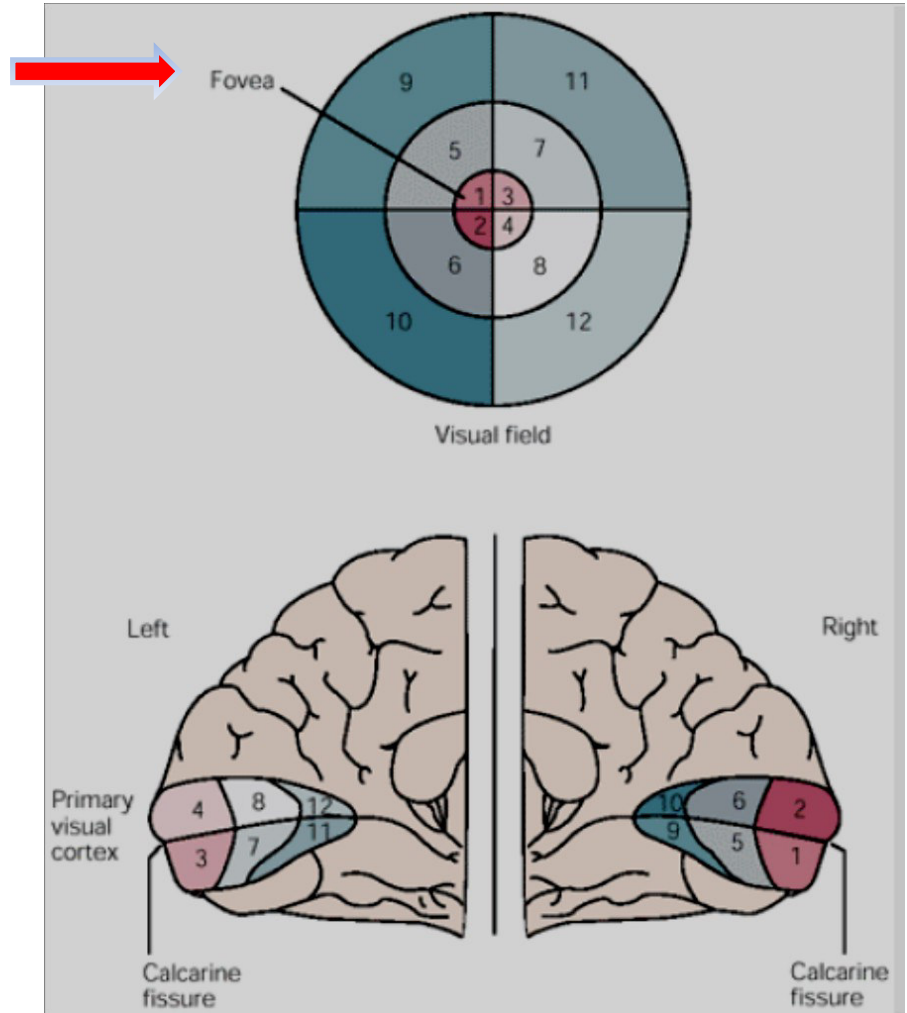


Primární zrakový kortex

Retinotopická organizace

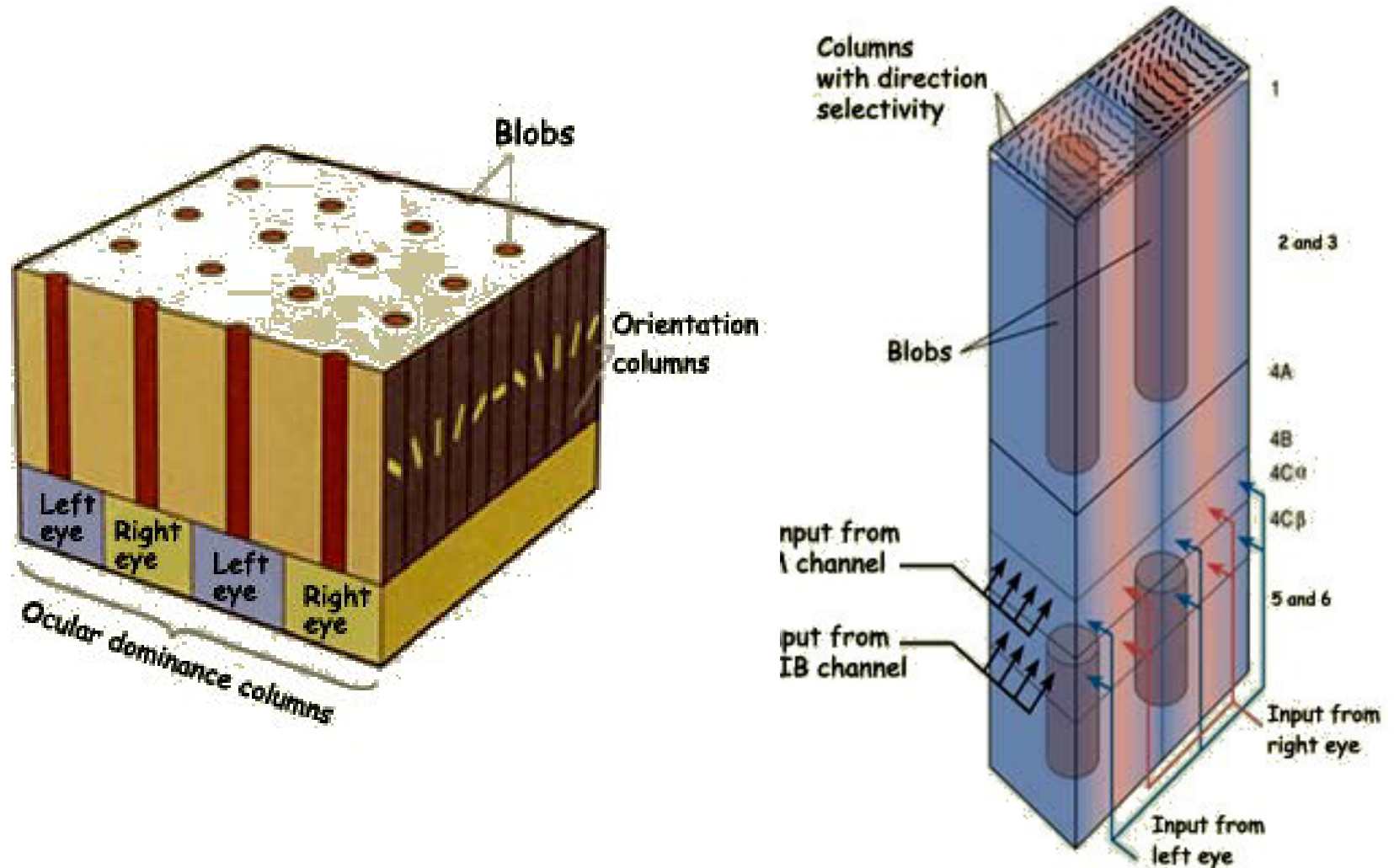


Copyright © 2008, 2004, 1998, 1993, 1988, 1983 by Mosby, Inc., an affiliate of Elsevier Inc.



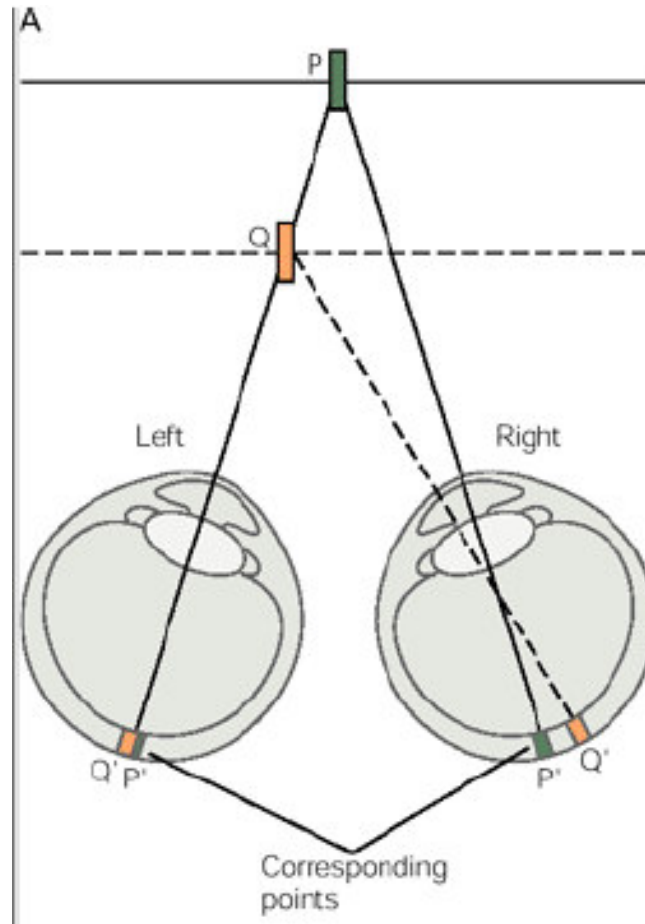
<http://www.slideshare.net/drpsdeb/presentations>

Primární zrakový kortex



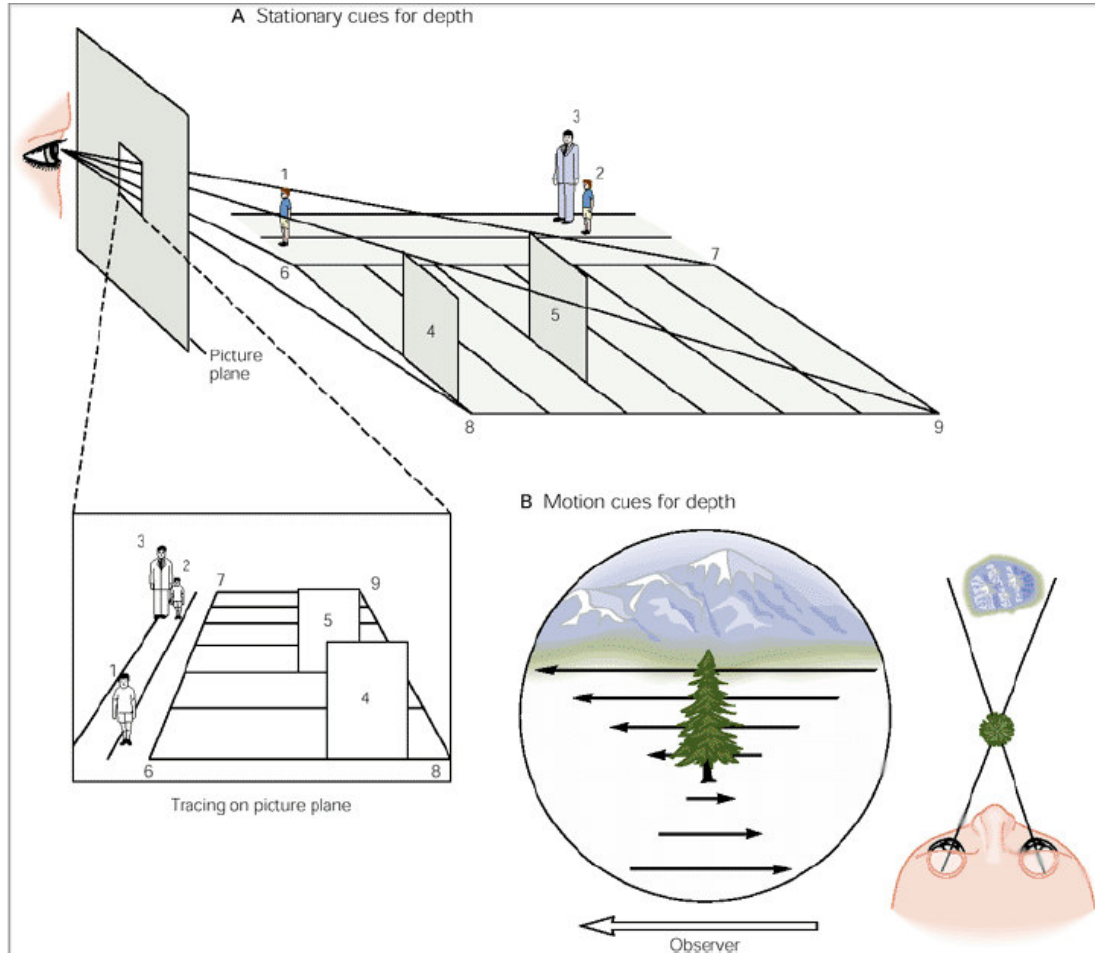
Prostorové vidění

Binokulární

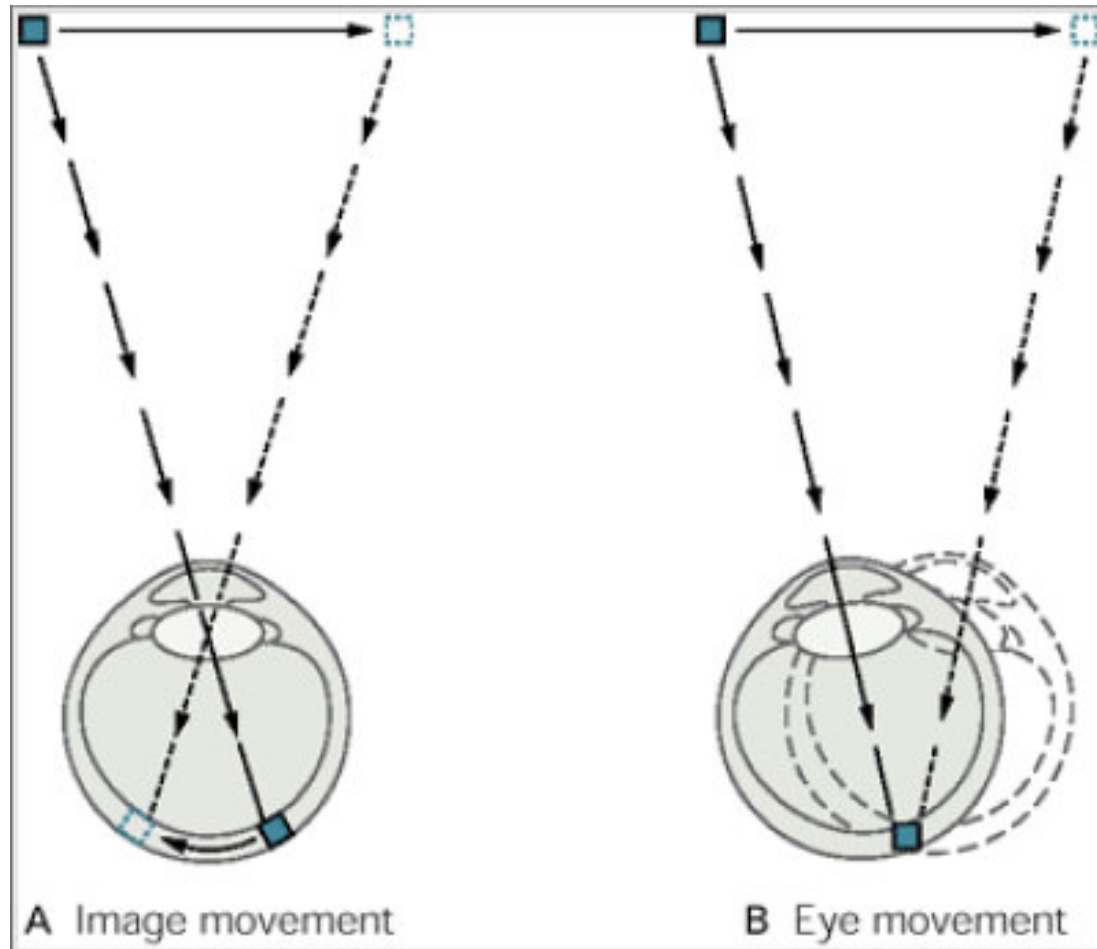


Prostorové vidění

Monokulární – získané zkušenosti

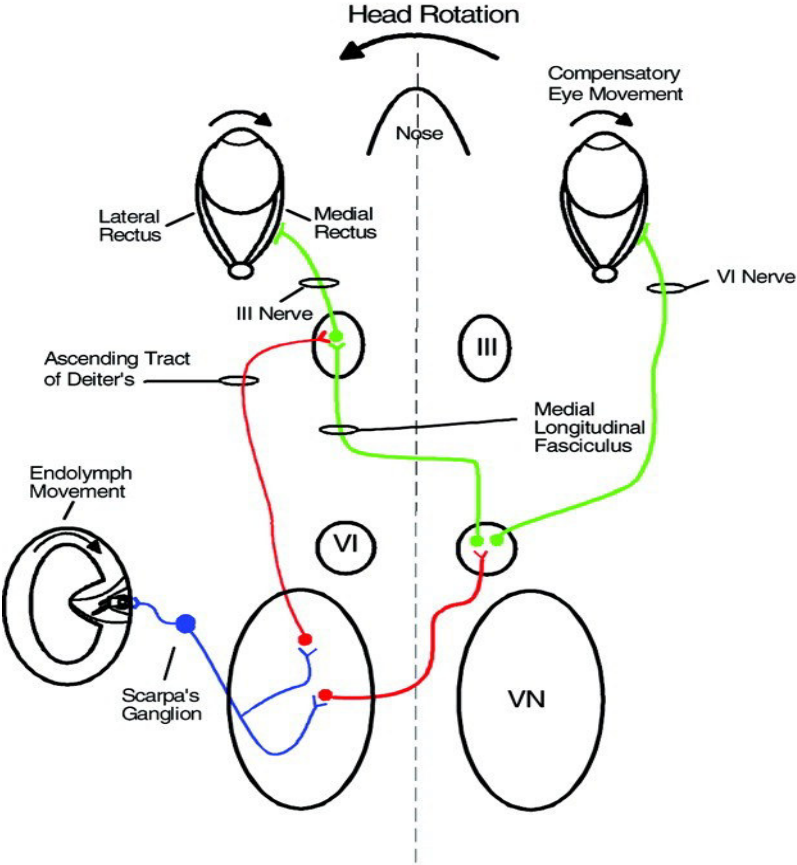


Pohyb v zorném poli

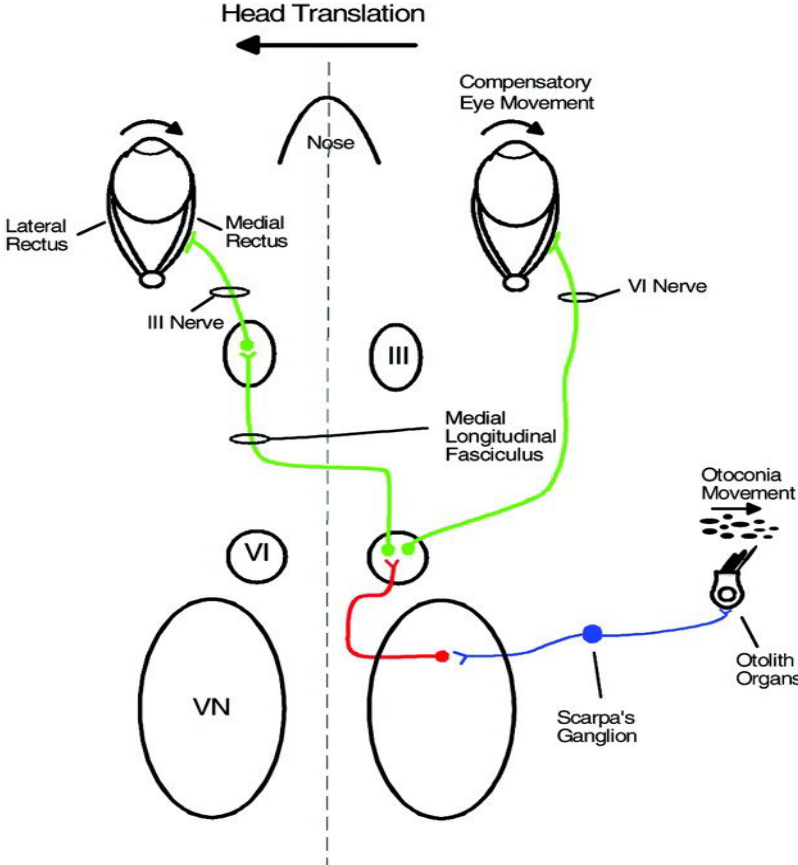


Vestibulookulární reflex

Rotational VOR



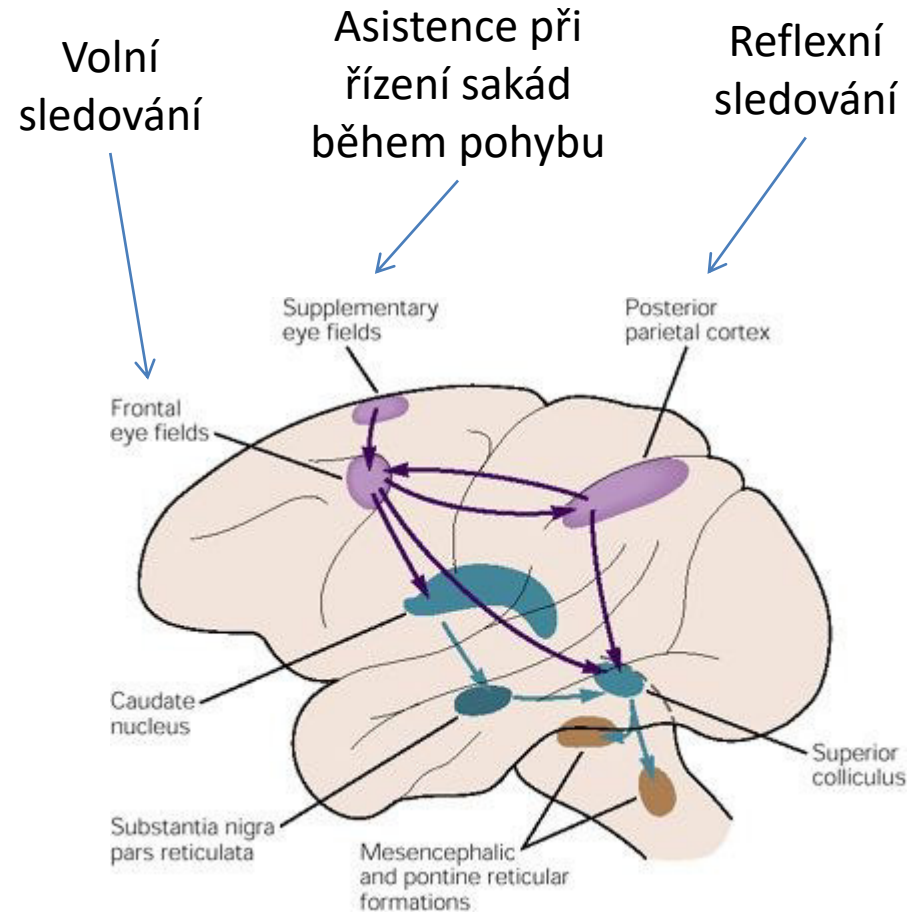
Translational VOR



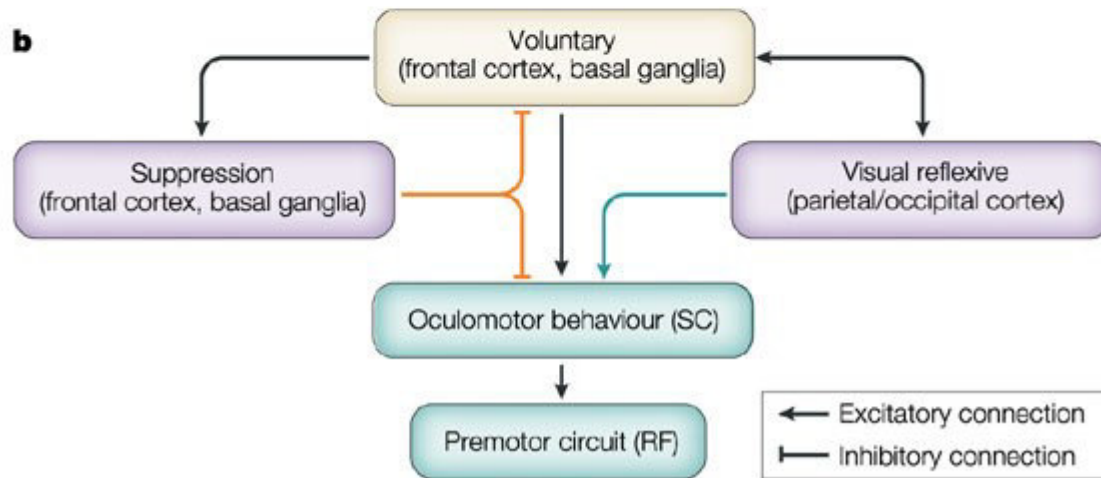
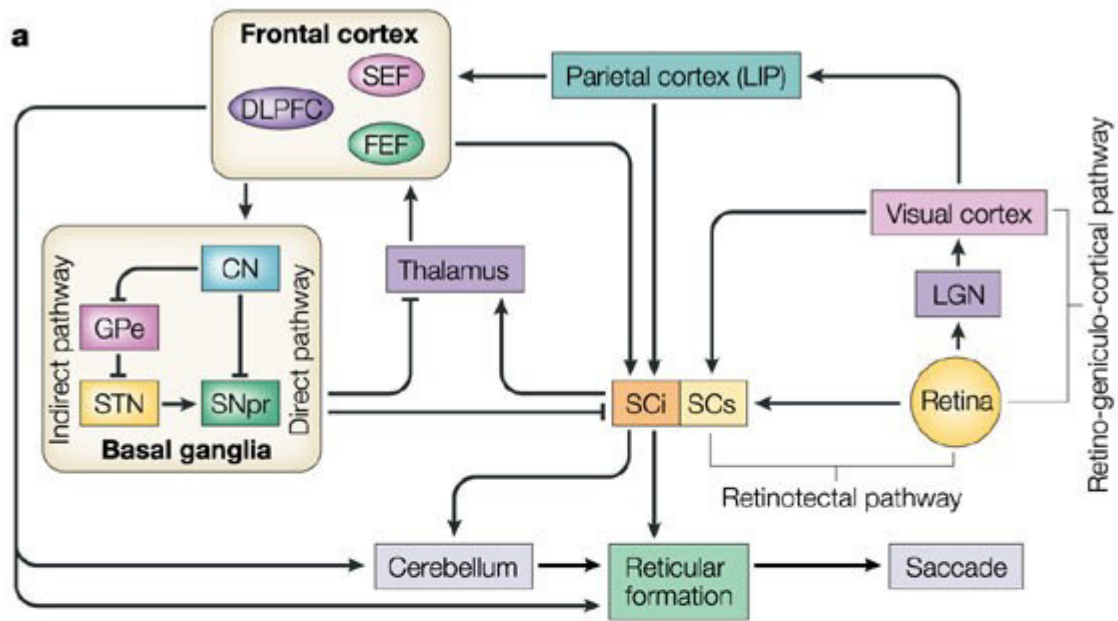
Sakadické pohyby



<https://en.wikipedia.org/wiki/Saccade#/media/File:Szakkad.jpg>



<https://s-media-cache-ak0.pinimg.com/564x/51/f7/26/51f7267e7c8a59caa90f904cd4f965eb.jpg>



Nystagmus

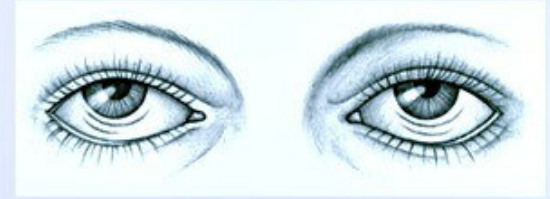- Nekontrolované rytmické konjugované pohyby očních bulbů
- Fyziologický
 - Postrotační
 - Optokinetický
- Patologický
 - Poruchy vestibulárního systému
 - Poruchy vestibulocerebella
 - Další poruchy CNS

Classifying nystagmus

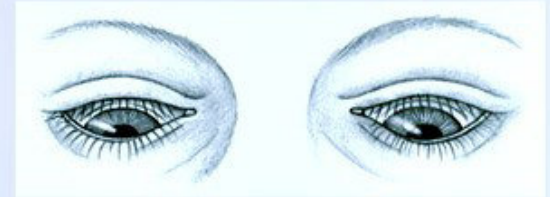
The various types of jerk and pendular nystagmus are illustrated below.

JERK NYSTAGMUS

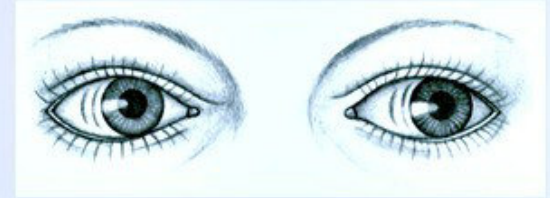Convergence-retraction nystagmus refers to the irregular jerking of the eyes back into the orbit during upward gaze. It can indicate midbrain tegmental damage.



Downbeat nystagmus refers to the irregular downward jerking of the eyes during downward gaze. It can signal lower medullary damage.

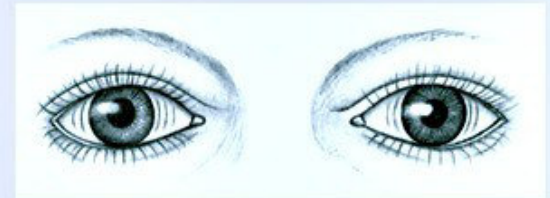


Vestibular nystagmus, the horizontal or rotary movement of the eyes, suggests vestibular disease or cochlear dysfunction.

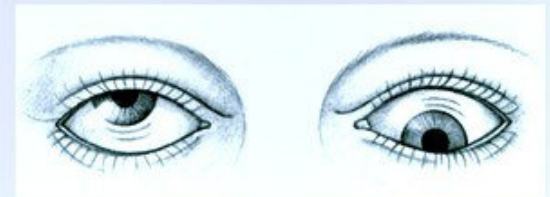


PENDULAR NYSTAGMUS

Horizontal, or pendular, nystagmus refers to oscillations of equal velocity around a center point. It can indicate congenital loss of visual acuity or multiple sclerosis.



Vertical, or seesaw, nystagmus is the rapid, seesaw movement of the eyes: One eye appears to rise while the other appears to fall. It suggests an optic chiasm lesion.



Pupilární reflex

