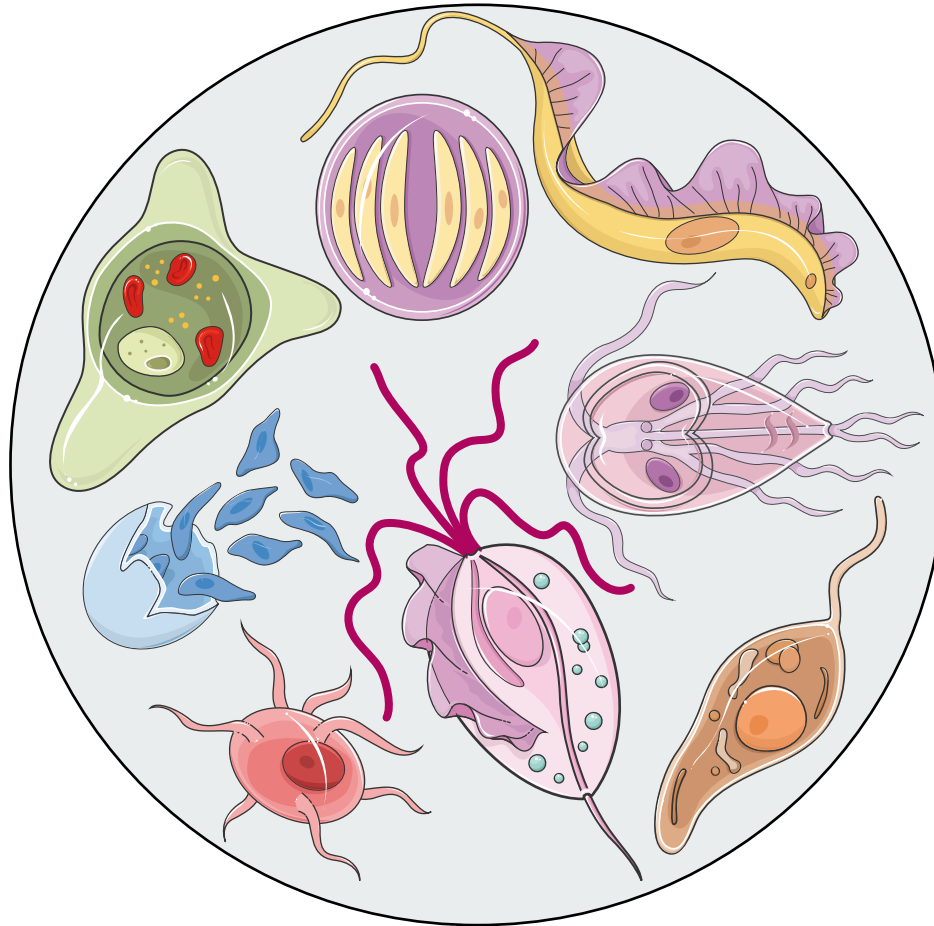


Biology of parasitic protozoa

VII. Ciliophora, Opalinata (SAR)



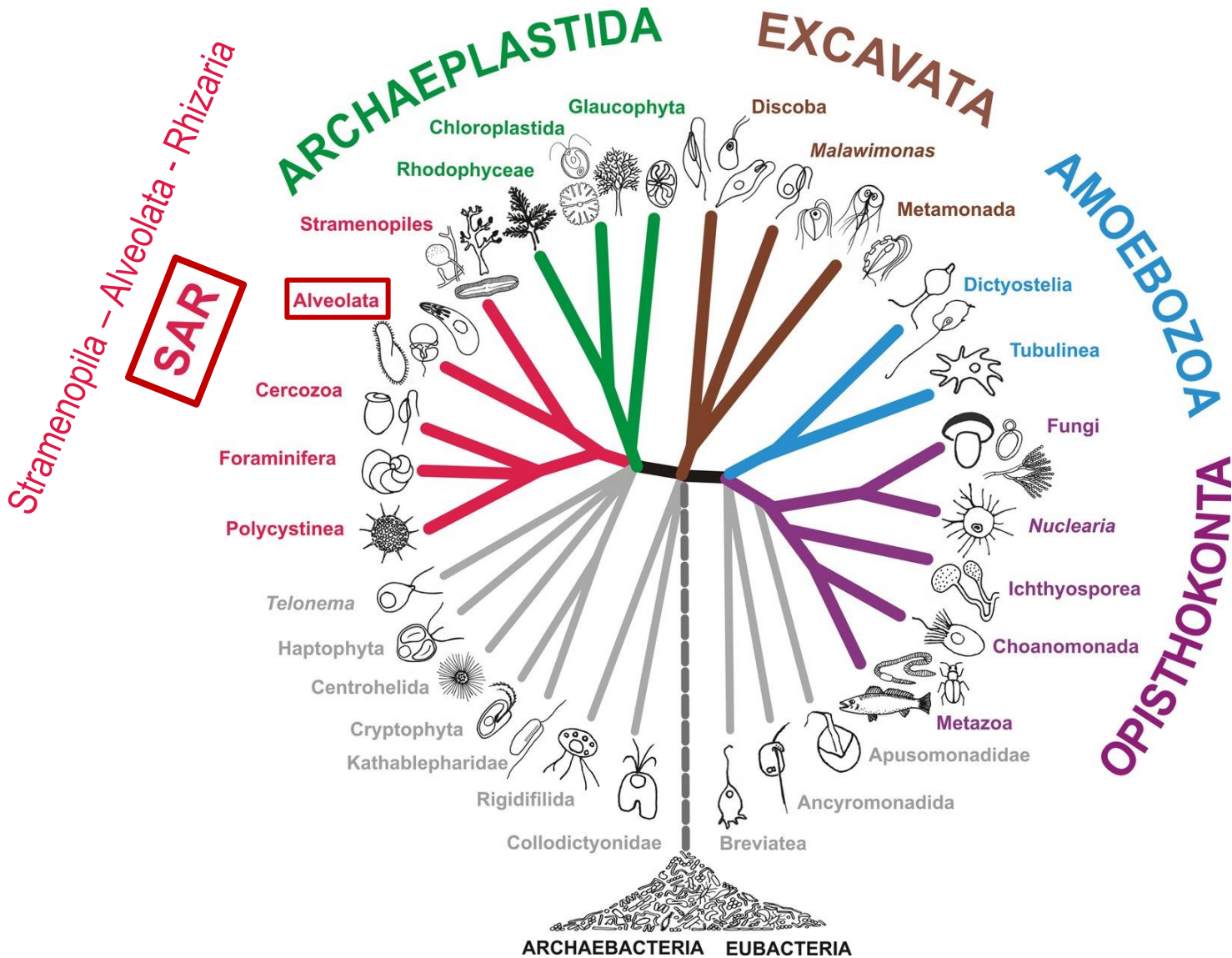
Andrea Bardůnek Valigurová

andreav@sci.muni.cz

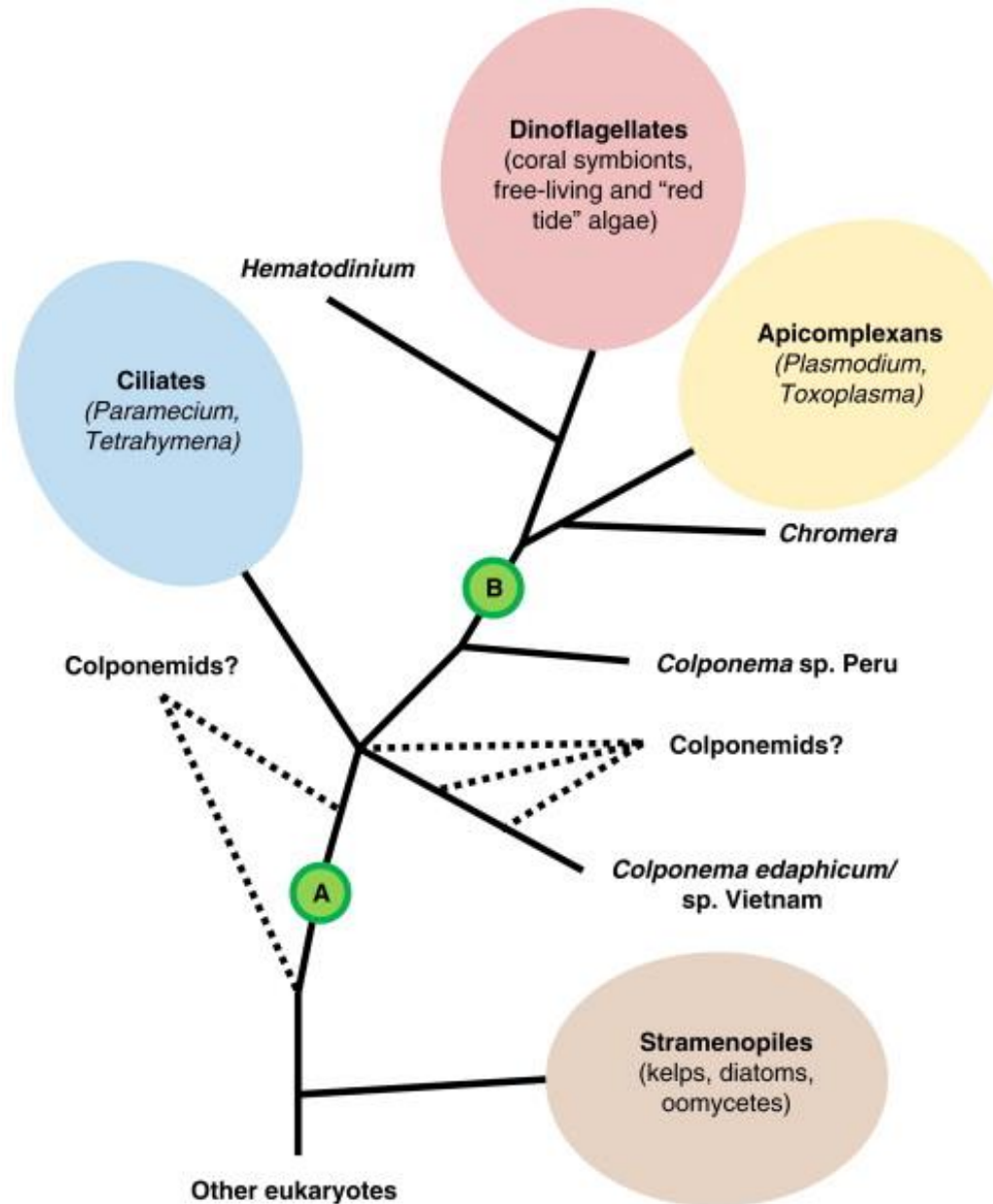
Notice

This presentation contains some material available on the web without the permission of the creator or the copyright owner. This presentation is to be used for educational purposes only. Educational purposes are defined as a communicating material for a particular course of instruction or for the administration of such course. Educational purposes do not cover the use of copyright material in PowerPoint for public lectures or other purposes.

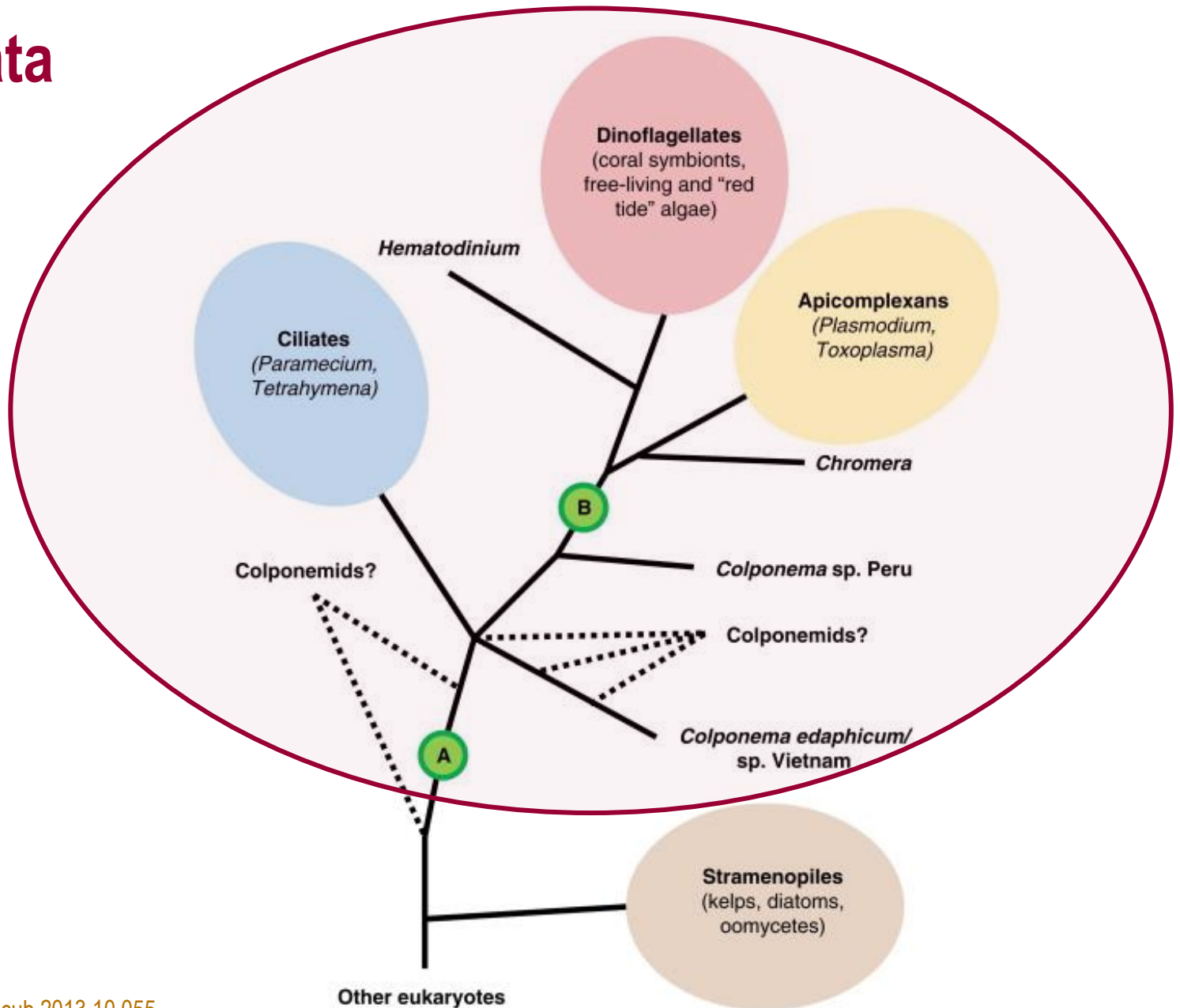
5 supergroups = megagroups



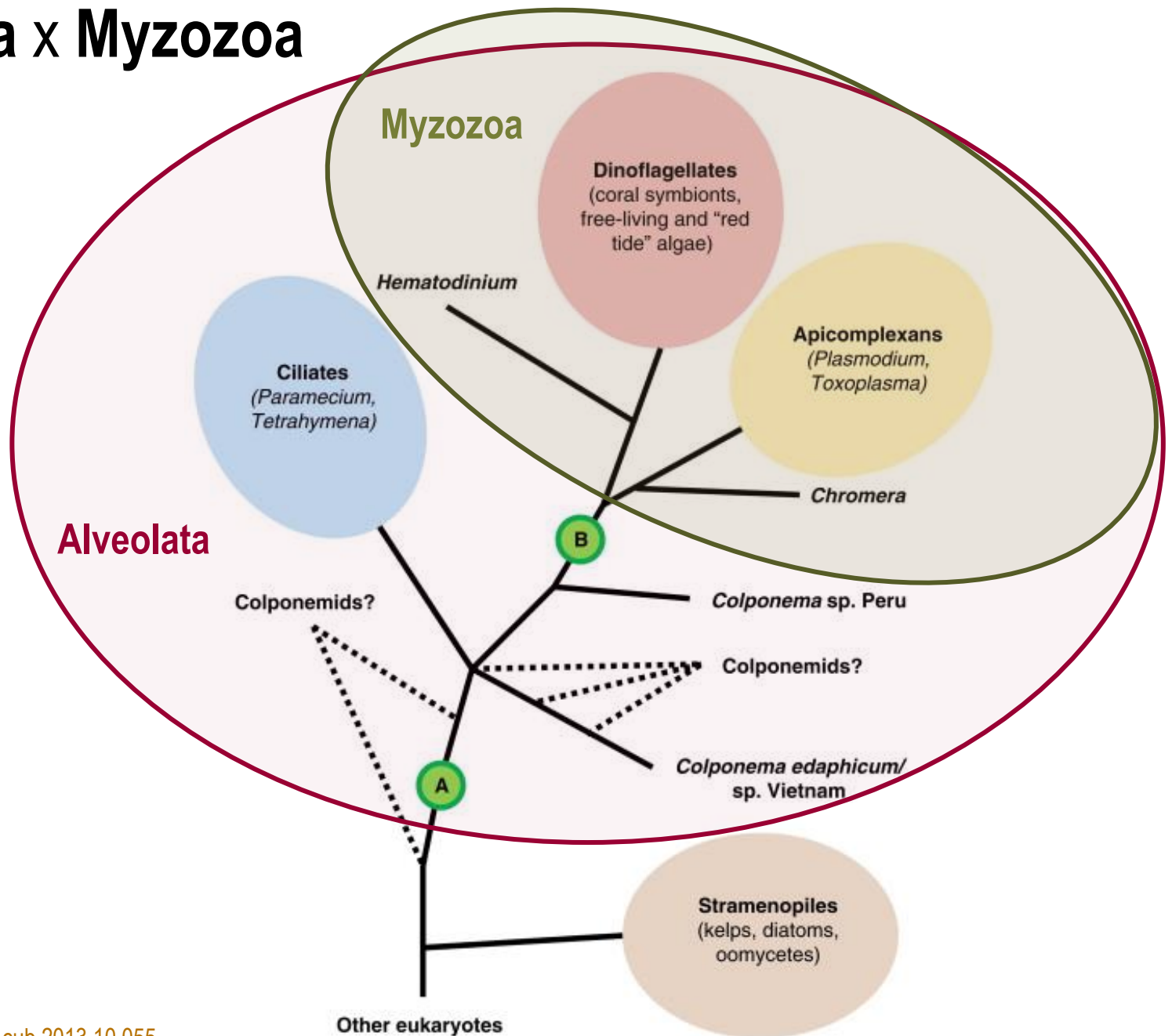
Ciliates

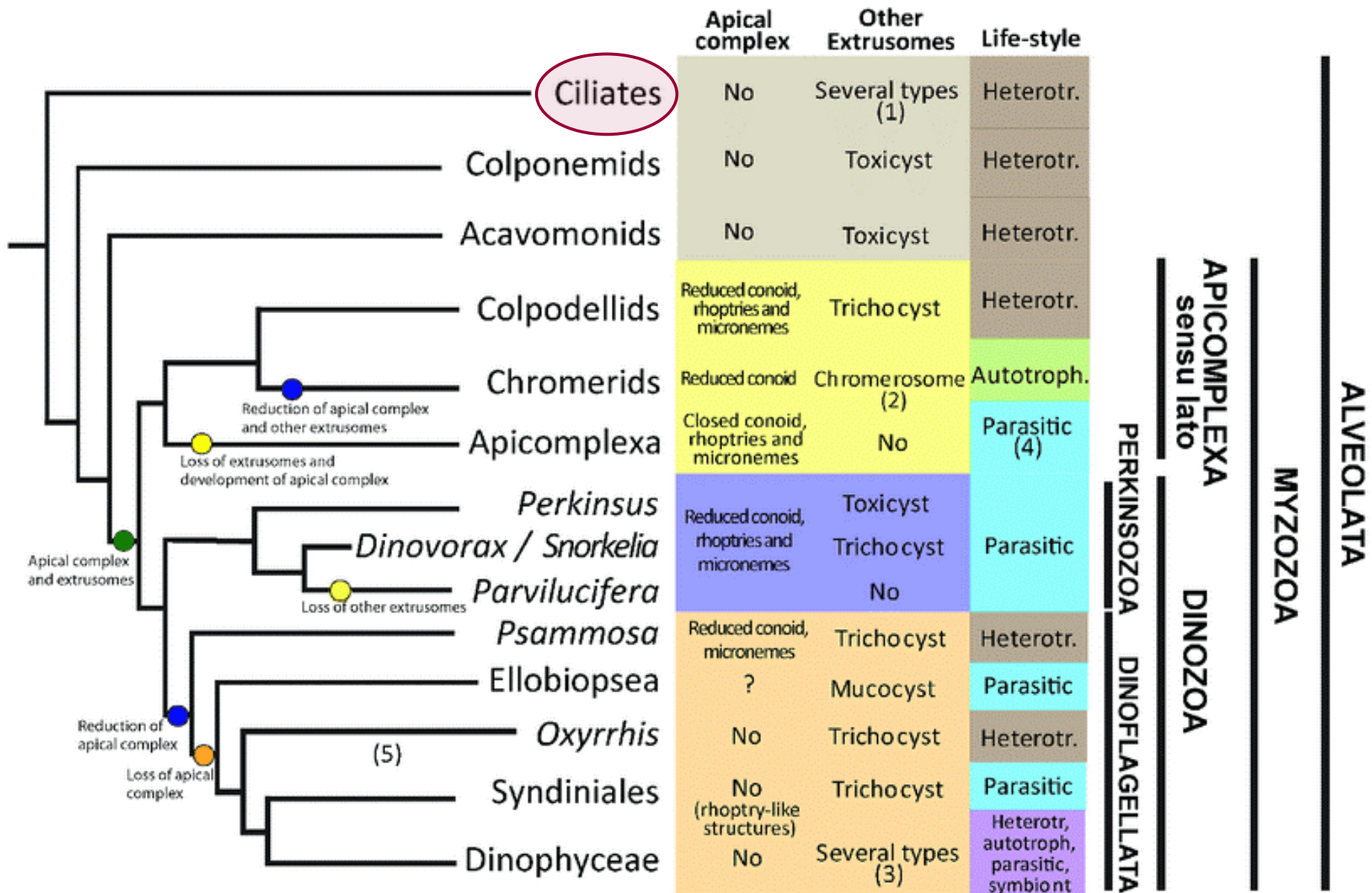


Alveolata




Alveolata x Myzozoa





Ciliophora

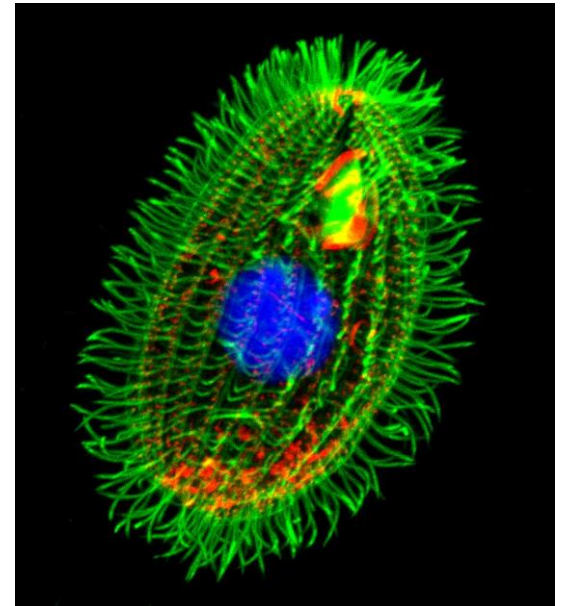
- monophyletic taxon
- quickly moving protists
- files or rows of cilia on cell surface
- cell surface covered with cortex
- nuclear dualism - larger **macronucleus** (somatic, physiologically active, containing thousands of copies of genes) and smaller **micronucleus** (diploid, a germ nucleus whose meiotic products are exchanged during conjugation)
- sexual reproduction = **conjugation**
- asexual reproduction by binary fission (mostly transverse)
- about 8,000 representatives (parasitic approx. 2,500)
- mostly free-living in ponds, lakes, estuaries, saltmarshes, oceans
- ectosymbionts on surface of animals (*Trichodina* on the gills and fish skin), cavity parasites and commensals (*Balantidium* in intestine, ciliates in rumen), tissue parasites (*Ichthyophthirius multifiliis* on fish skin)



Impregnation of cytoskeletal structures with silver

Ciliature

- cilia typically arranged in longitudinal rows = kineties
- exceptionally:
 - i. lacking cilia
 - ii. ciliated only in some phase of life cycle
 - iii. cilia distributed on the cell surface irregularly
- undulating membrane = longitudinal row of paired cilia
- membranella = plate-like a cluster of cilia
- cirrus = finger-like cluster of cilia



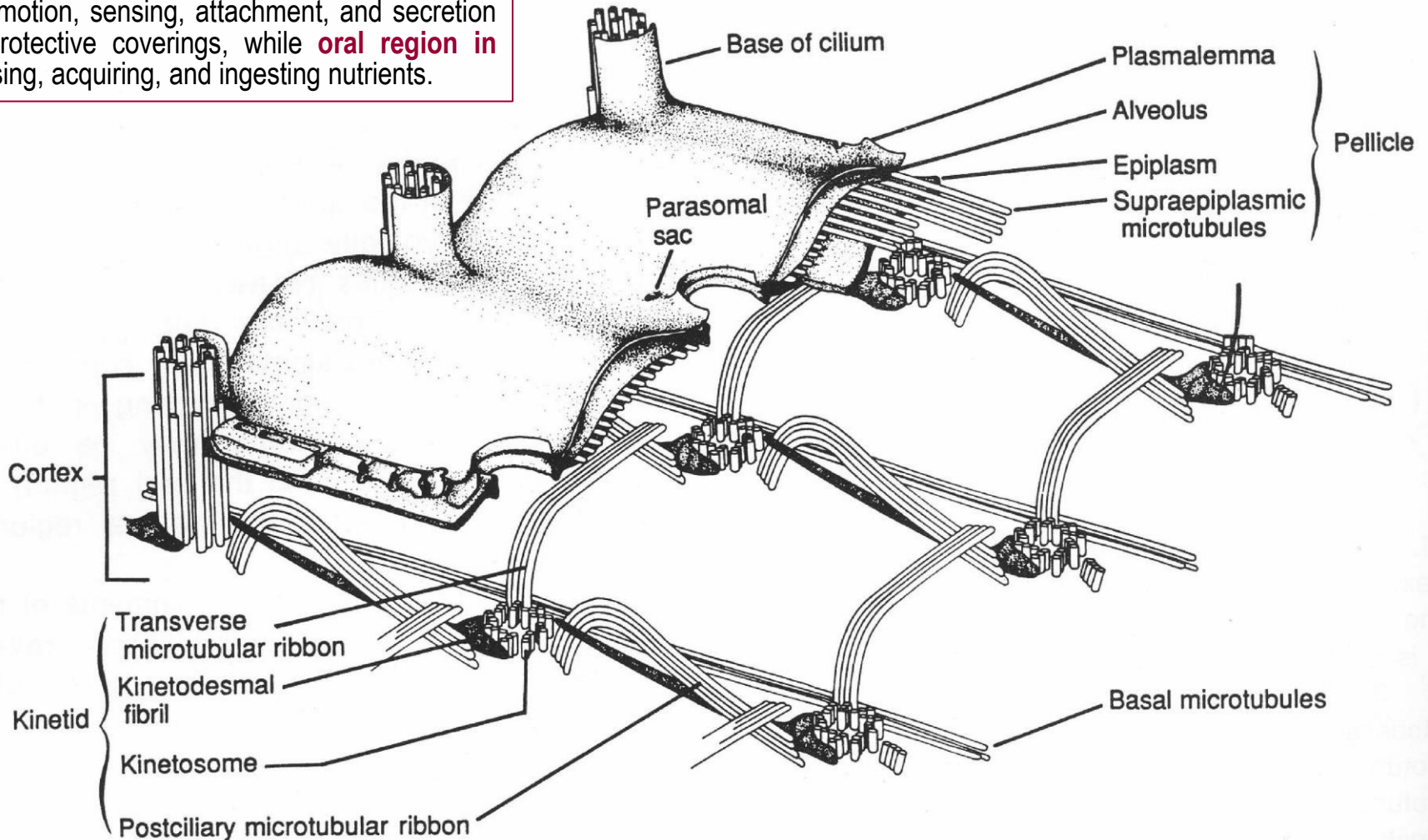
Tetrahymena thermophila stained for tubulin (green), centrin (red) and DNA (blue)

Cortex

- cell's own covering (pellicle) = unit membrane, subpellicular alveoli (Alveolata)
- **infraciliature** = **kinetosomes** of cilia + associated **microtubular and fibrillar formations**:
 - i. striated kinetodesmal fibrils
 - ii. postciliary bands of microtubules
 - iii. transverse bands of microtubules
- basal microtubules courses beside the kinetosomes but is not directly connected to them

Generalised somatic cortex of a ciliate

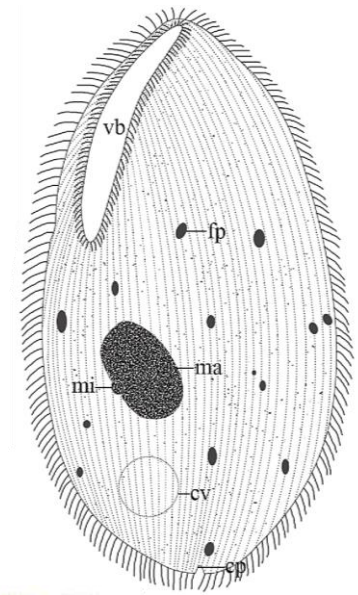
Cortex of a “typical” ciliate can be divided into **somatic** and **oral** regions. **Somatic region** (composed of a “skeletal” support opposed by the hydrostatic pressure within cell) functions in locomotion, sensing, attachment, and secretion of protective coverings, while **oral region** in sensing, acquiring, and ingesting nutrients.



Nuclear dualism

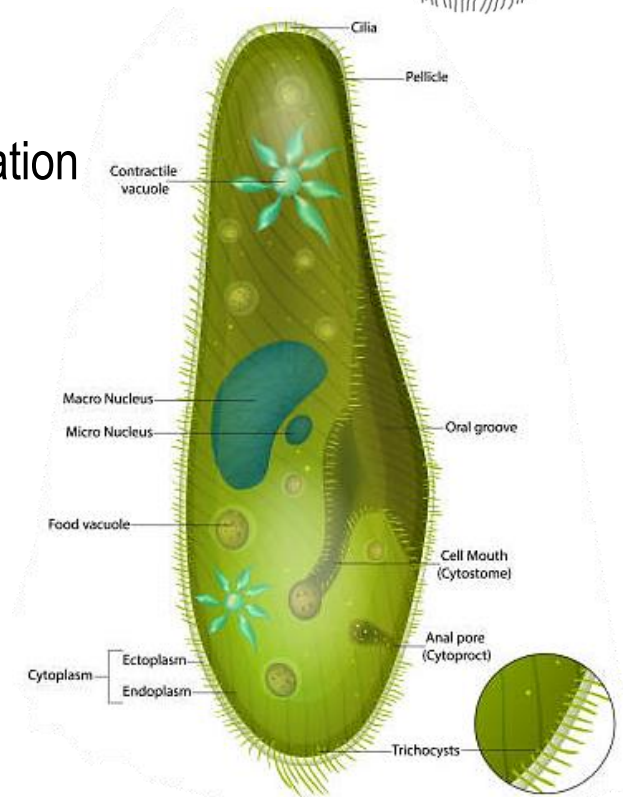
Macronucleus

- excess of chromosomes = polyploidy (20 to more than 200n)
- vegetative nucleus with an incomplete genome (e.g. only 5%)
- 2,300 kb DNA = "gene sized fragments", equipped with telomeres)
- number of nucleoli, active synthesis of RNA
- forming from a micronuclear derivative after conjugation
- unknown division of mechanism (amitosis?)



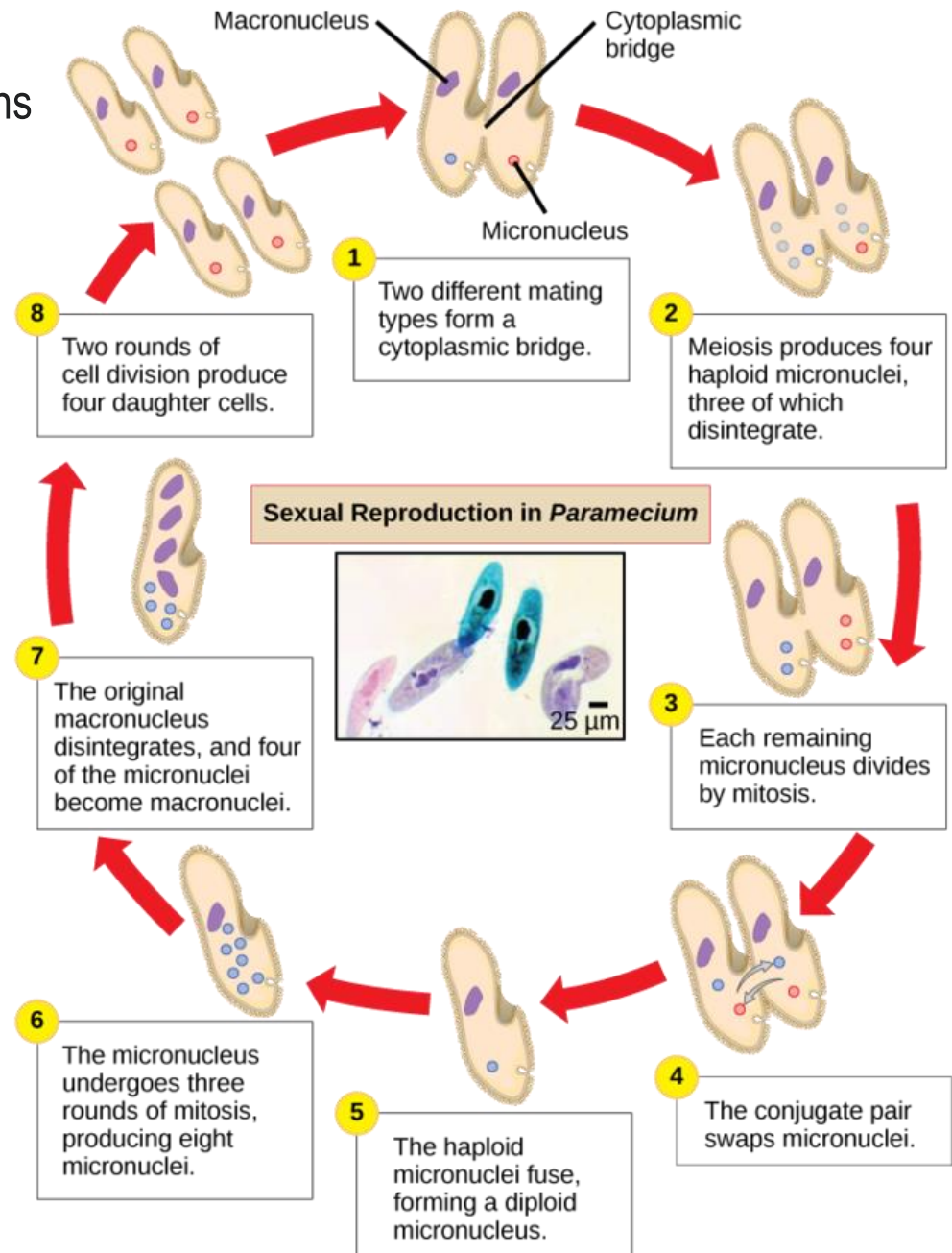
Micronucleus

- classic diploid nucleus
- intranuclear spindle during division
- amiconucleate clones incapable of conjugation



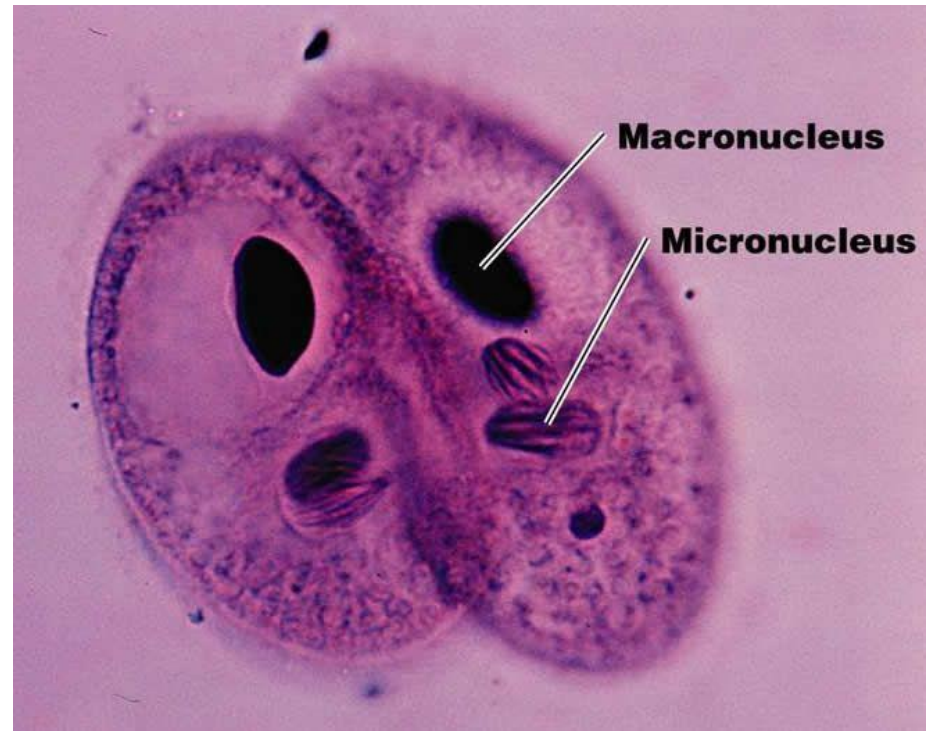
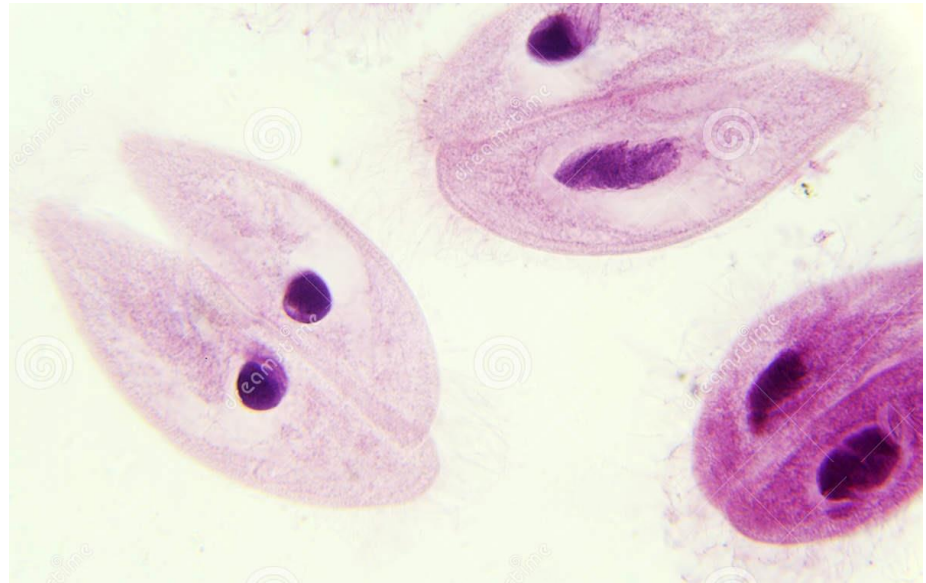
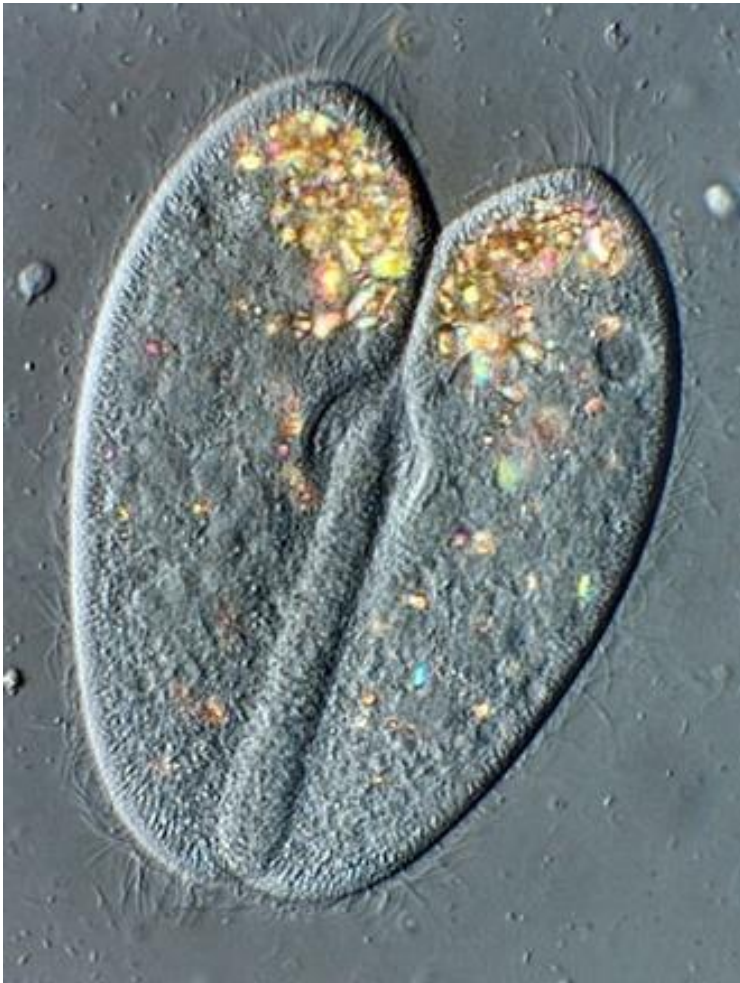Conjugation

- sexual process - compatible mating strains meet and partly fuse (gamonts are morphologically indistinguishable)
- cytoplasmic bridge forms between the gamonts (conjugants)
- micronucleus undergoes meiotic division into 4 haploid micronuclei per cell \Rightarrow 3 degenerate and 4th undergo mitosis and divides into **stationary** and **migratory pronuclei**
- conjugants exchange **migratory pronucleus** and separate, old macronucleus degenerates
- pronucleus merges with a stationary pronucleus \Rightarrow **synkaryon** which divides mitotically
- new macronucleus forms from one new micronucleus
- binary fission \Rightarrow identical daughter cells

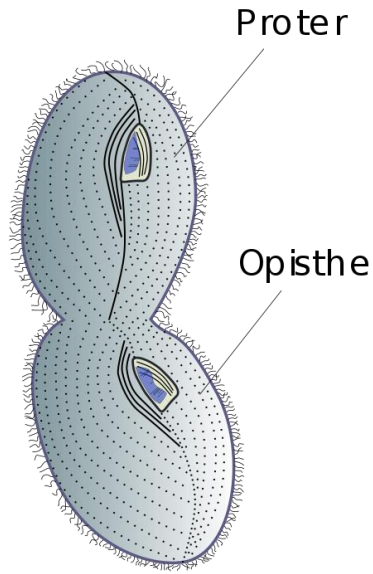


Conjugation

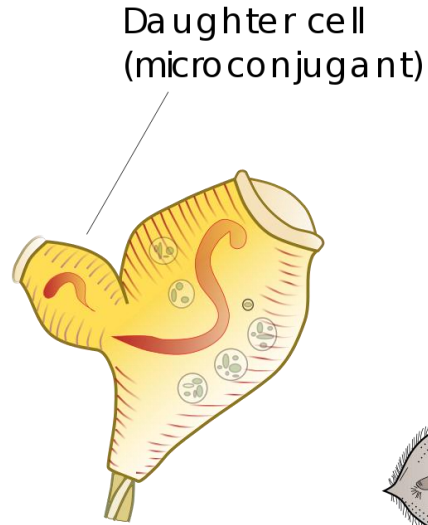
(in *Paramecium*)



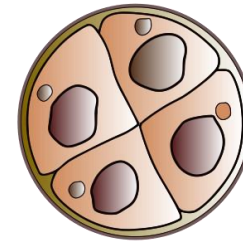
Kinds of binary fission in ciliates



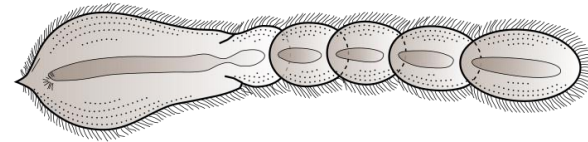
Transverse fission
(modeled after *Frontonia*)



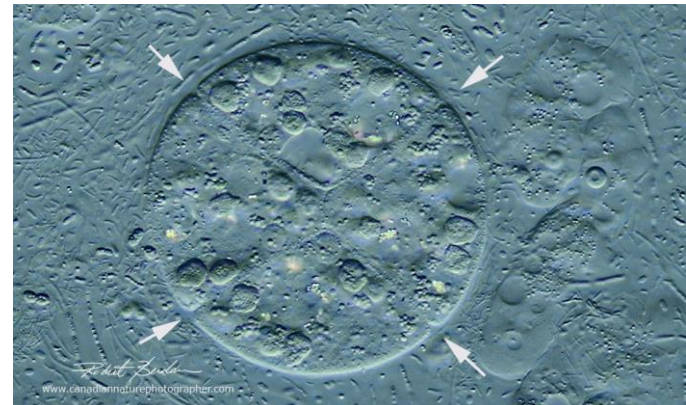
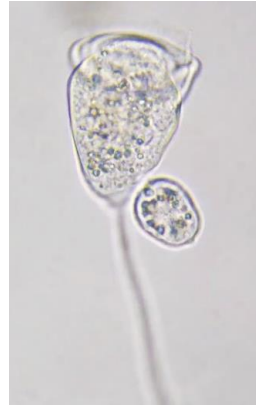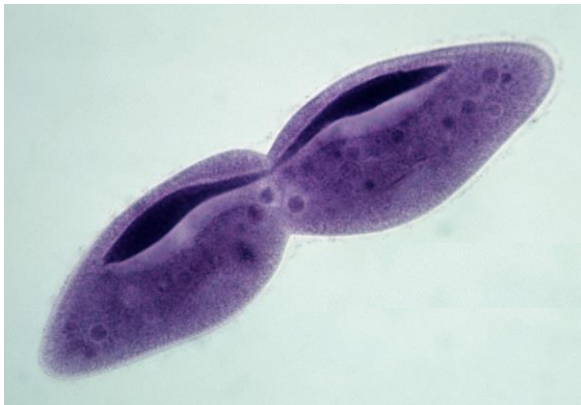Budding
(preconjugation fission in
Vorticella microstoma)



Palintomy
(multiple fission, usually within a cyst,
modeled after Colpoda)

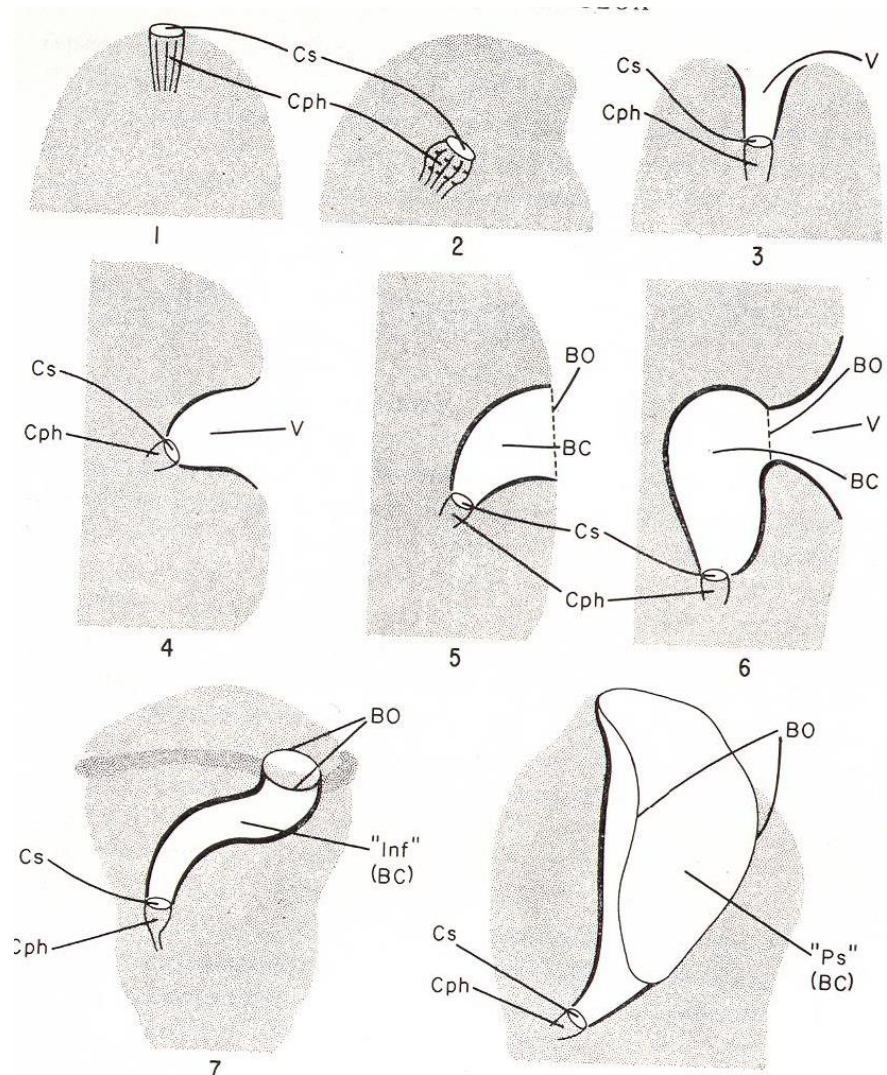


Strobilation, or Catenulation
(multiple fission modeled
after *Anoplophrya*)



Food intake

- most ciliates are **phagotrophs** = absorption of food particles
- combination of pinocytosis and osmosis in some ciliates
- cell mouth = **cytostome** (cs)
- **vestibulum** (v) at the bottom of the oral cavity (bc) or **infundibulum** (inf) ⇒ filter feeding more efficient
- peristome (ps)
- **cytopharynx** (cph) behind the mouth
- **cytopyge** (cytoproct) to discharge the waste (undigested residues)
- osmoregulation via **pulsating vacuoles**



Variability in the oral structures of ciliates

Classification of Ciliophora

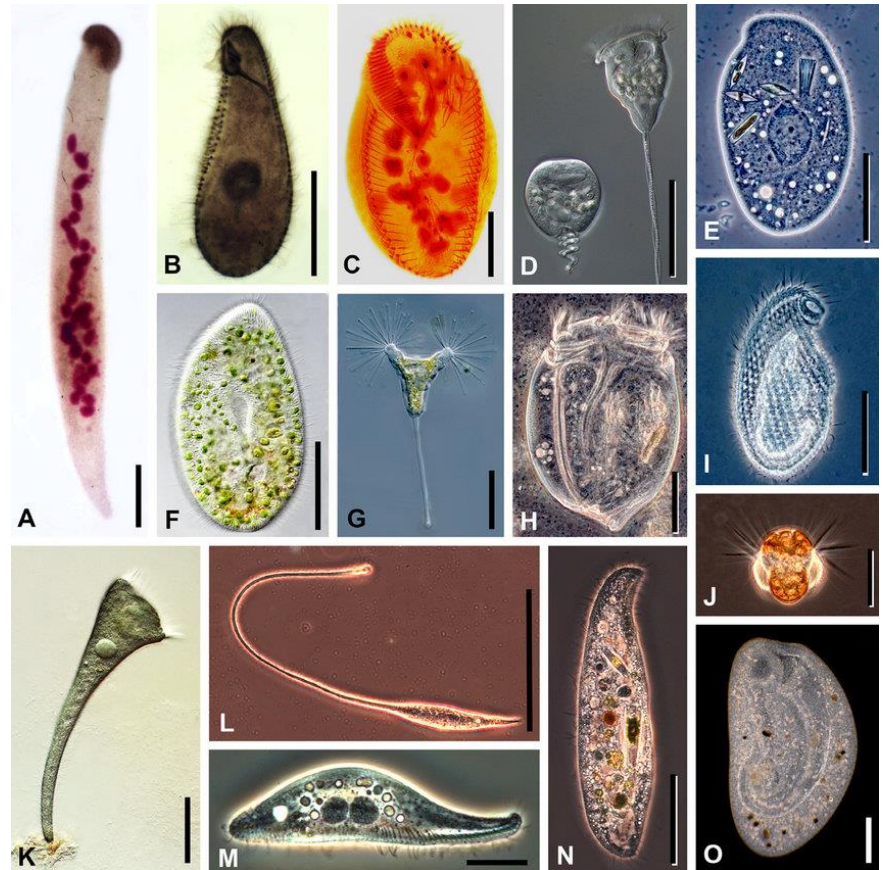
- oldest - based on somatic ciliature
- later - oral ciliature: Kinetophragminophorea, Oligohymenophorea, Polyhymenophorea
- **recent** - type of infraciliature, whether the macronucleus divides and whether during its division the MT spindles are inside or outside the macronucleus

Postciliodesmatophorea

- macronucleus does not divide and arises *de novo* from micronucleus, or when dividing, MT spindles are outside the nucleus, small group

Intramacronucleata

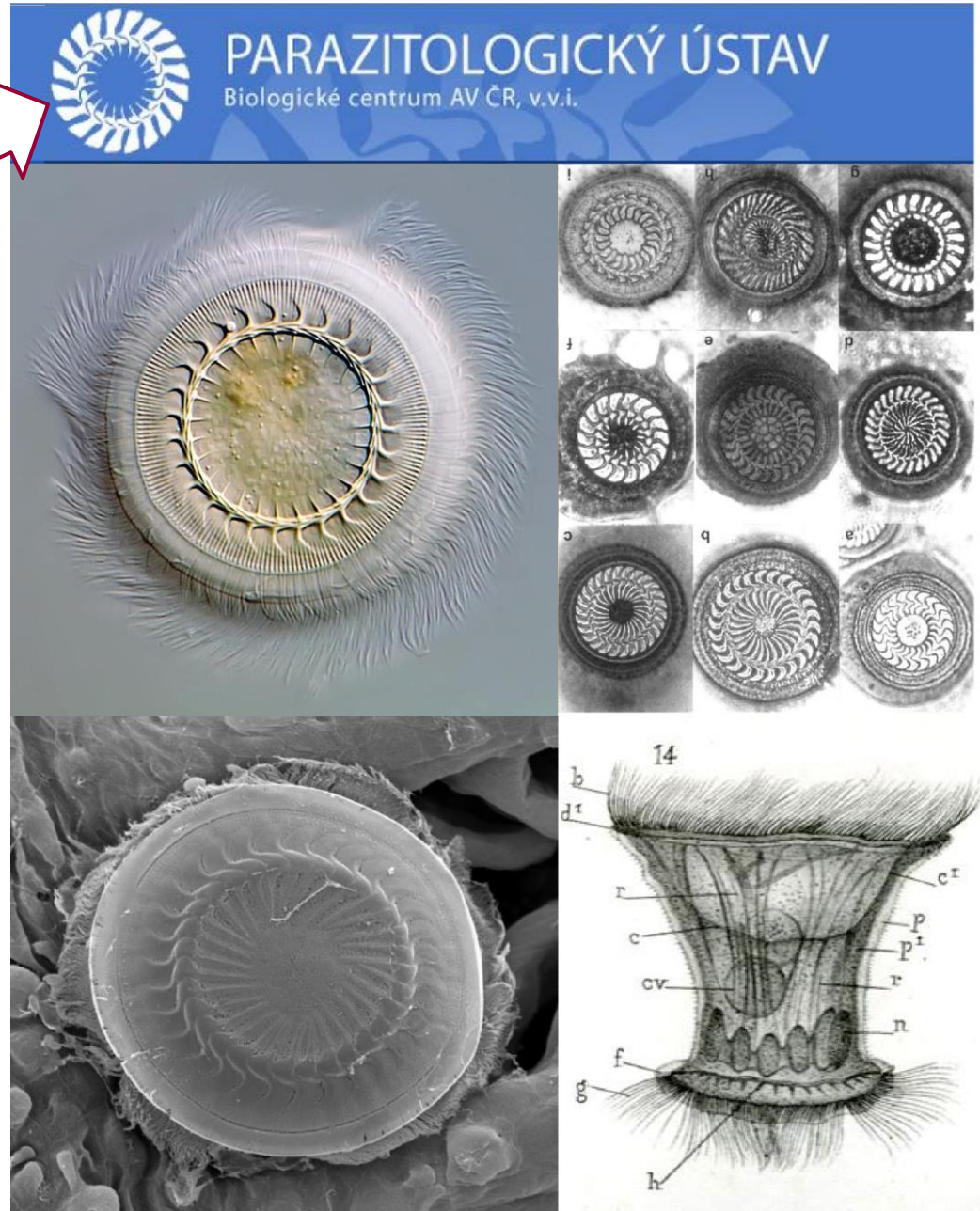
- macronucleus divides, MT spindle inside of dividing nucleus, most ciliates



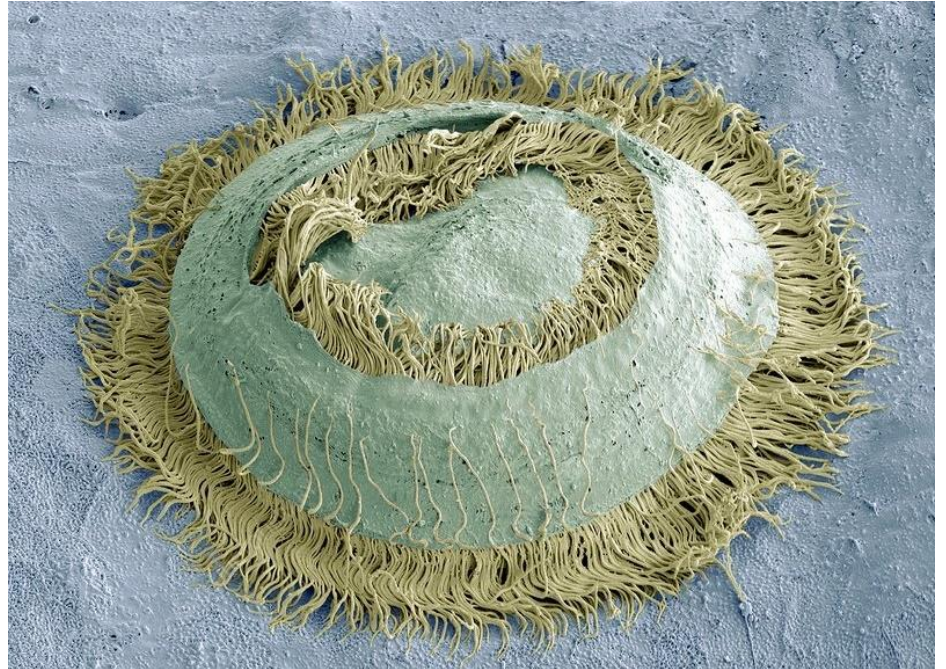
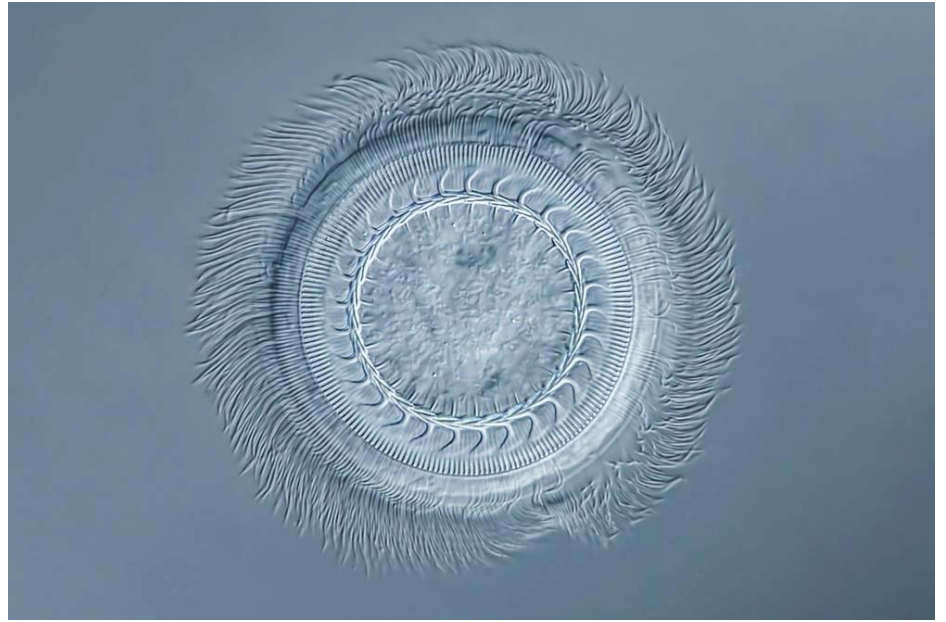
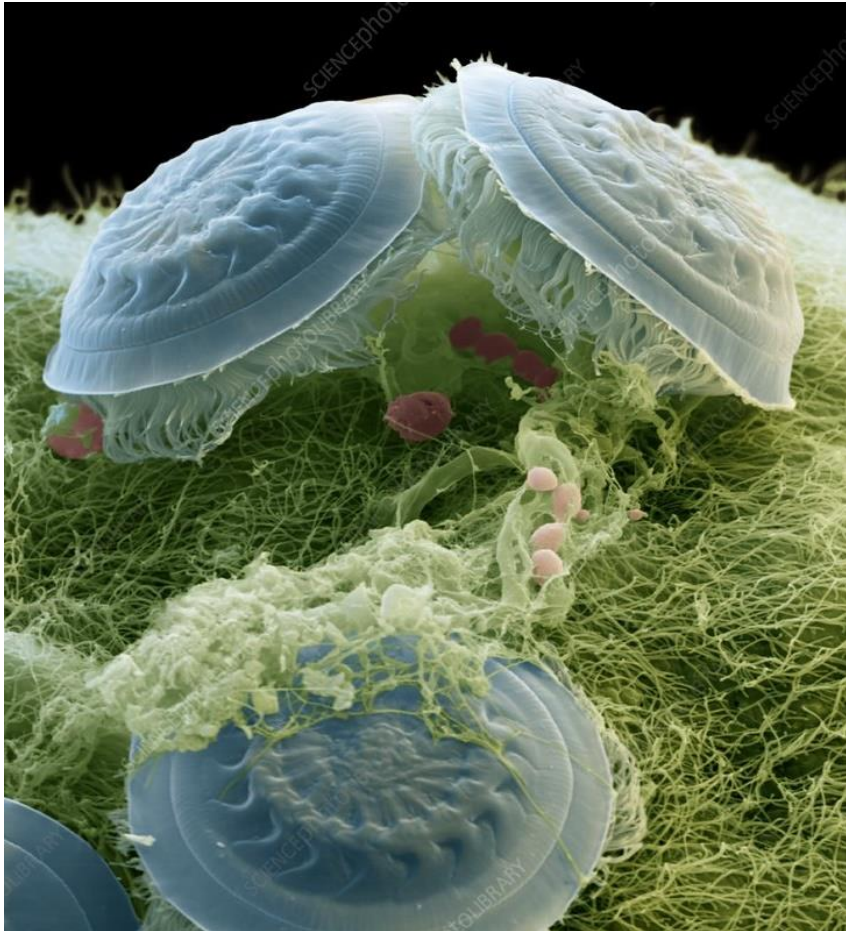
Intramacronucleata


Trichodinidae

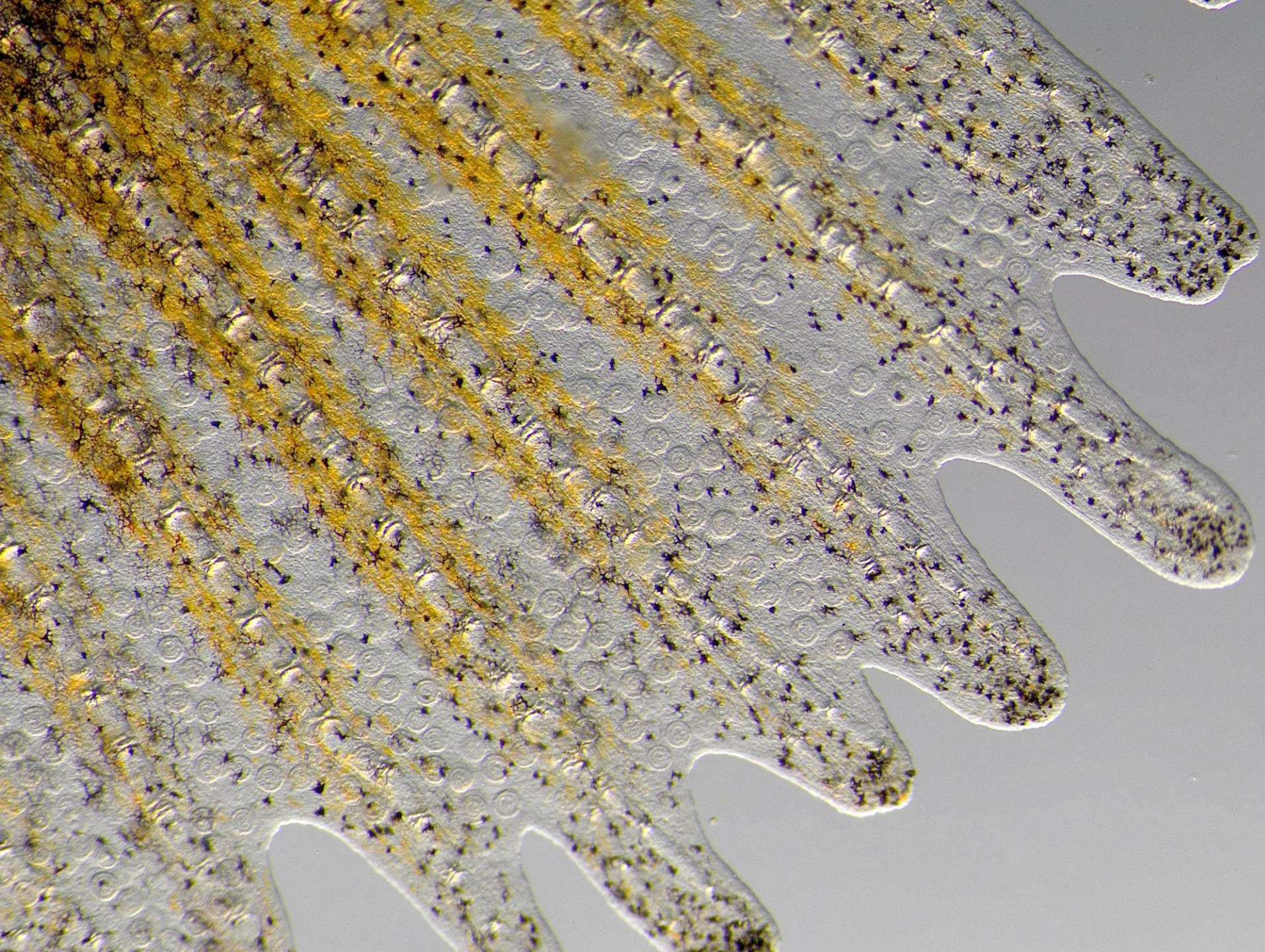
- ecto commensals × ectoparasites
- direct cycle
- transmission by direct contact
- indicator of poor water quality
- pathogens of aquarium fish (infected fish often rubs against objects in the aquarium and gradually weakens)
- spiral cilia around the cytostome = identification feature
- binary fission
- genera *Trichodina*, *Trichodinella*, *Hemitrichodina*, *Paratrichodina*, *Tripartiella*, *Vauchomia*,...



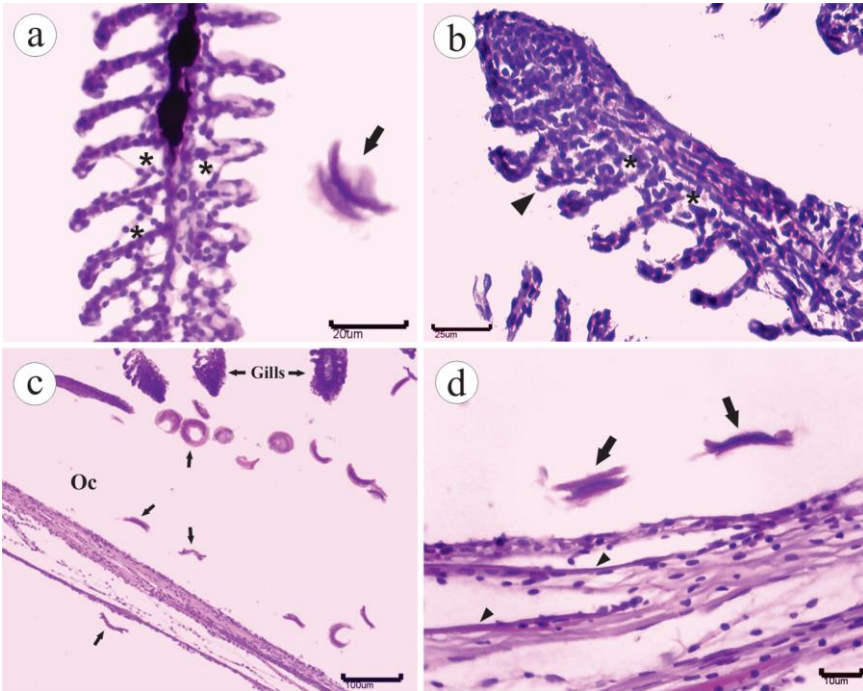
genus *Trichodina*



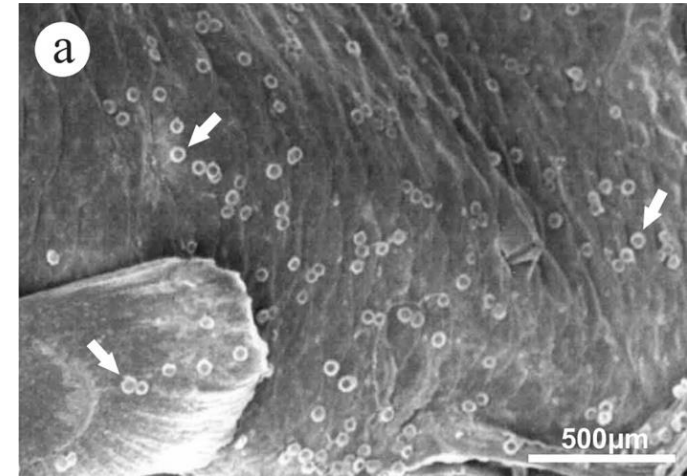




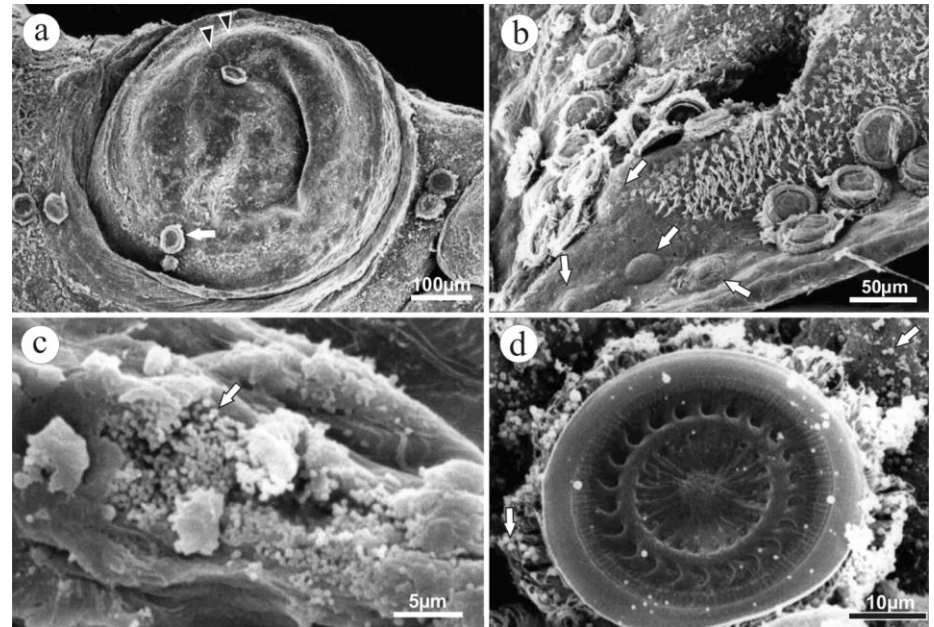
Trichodina heterodentata



Prochilodus lineatus larvae highly parasitised by *Trichodina heterodentata*. **A)** Oedema (asterisk) in the secondary lamella, parasite (arrow). **B)** Discrete hyperplasia with focal fusion of secondary lamella (arrow), discrete mononuclear inflammatory infiltrate and oedema. **C)** Trichodinids (arrows) present inside and outside the operculum cavity (oc) showing no altered epithelium. **D)** Parasite (arrow), and pocket scale without alteration (arrow head).



Abundant parasites (arrows) on the fish body surface.



Abundant parasites on eyes (white arrow) with suction areas (arrowhead) **(A)** and on skin near the nostril with many suction areas **(B)**; ulceration on dorsal fin with cocci attached **(C, arrows)** and numerous bacteria surrounding the ciliate **(D, arrows)**.

ORIGINAL ARTICLE

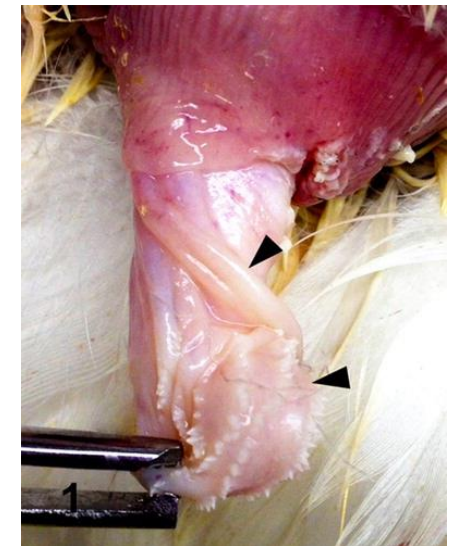
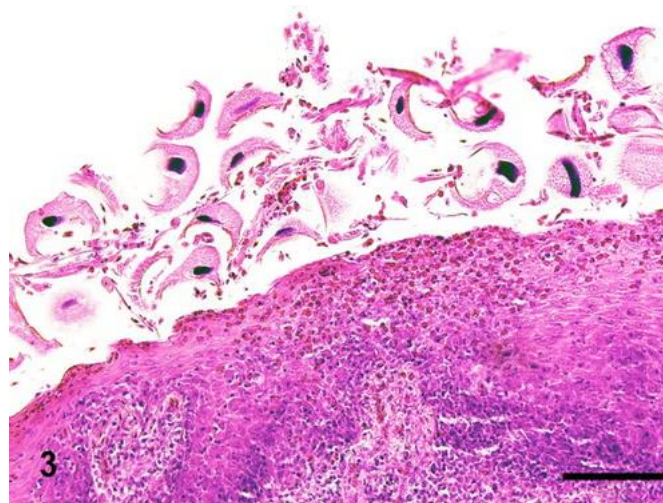
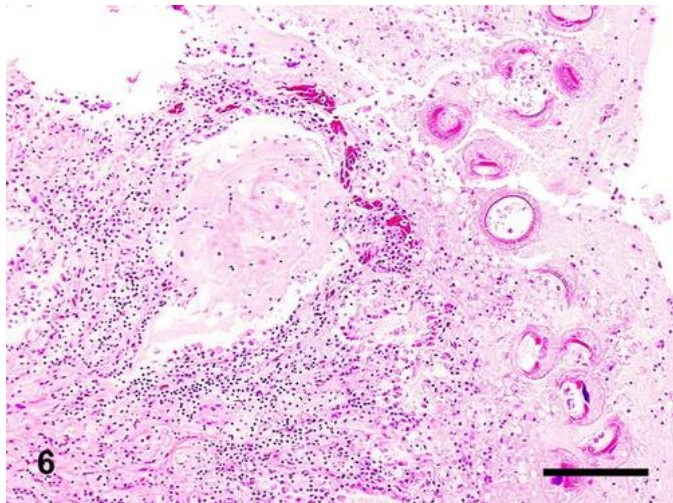
Trichodinosis associated with pathology of the reproductive tract in waterfowl

S. Carnaccini^a, L. J. Lowenstine^b, C. G. Senties-Cué^a, A. Nyaoke^c, M. Bland^d, A. A. Bickford^a, H. L. Shivaprasad^e and S. T. Stoute^a

^aCalifornia Animal Health & Food Safety Laboratory System (CAHFS), University of California, Davis, Turlock, CA, USA; ^bDepartment of Pathology, Microbiology and Immunology, School of Veterinary Medicine, University of California, Davis, CA, USA; ^cCalifornia Animal Health & Food Safety Laboratory System (CAHFS), University of California, Davis, San Bernardino, CA, USA; ^dCutler Associates International, Napa, CA, USA; ^eCalifornia Animal Health & Food Safety Laboratory System (CAHFS), University of California, Davis, Tulare, CA, USA

ABSTRACT

Trichodinid ciliophorans are opportunistic parasites of many species of fish, amphibians, and molluscs, but yet never reported in association with lesions in birds. Postmortem and histopathological evaluation of a commercial adult Toulouse gander and female goose, and a wild Mallard drake revealed the presence of severe pathological parasitic colonization of their reproductive tracts. Histopathological findings included moderate to severe granulocytic inflammation, acanthosis, accentuation of the rete pegs, and proliferative hyperplastic squamous metaplasia of the mucosa of the ejaculatory ducts and groove, *sulcus spermaticus*, glandular part of the phallus (*cavum penis*), and oviduct in association with large numbers of ciliated protozoa anchored to the tissues or free in the lumen. These protozoa had characteristic morphological features analogous to the family of *Trichodinidae*. The source of this parasitism could not be determined. To our knowledge, this is the first report of trichodinosis associated with pathology in birds.



Phallus. Trichodinids associated with acanthosis, superficial heterophilic and submucosal lymphoplasmacytic inflammation.

Chilodonellidae

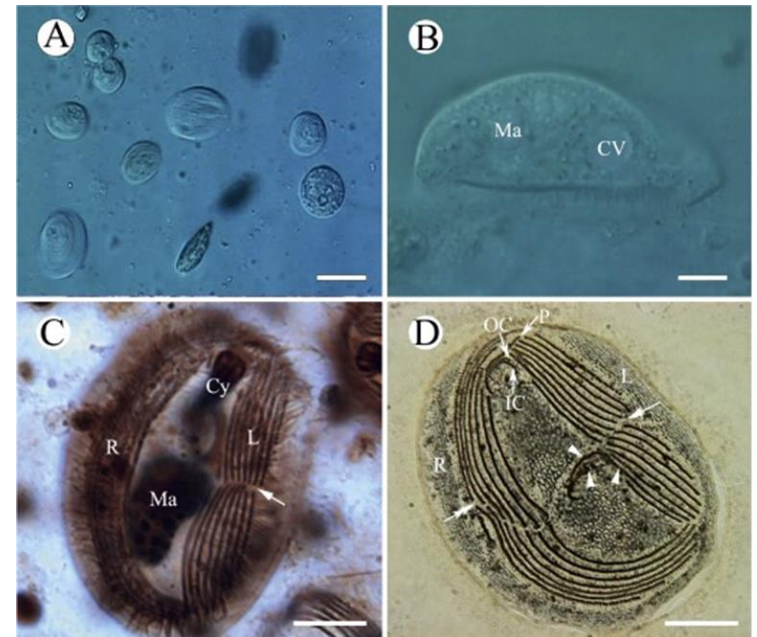
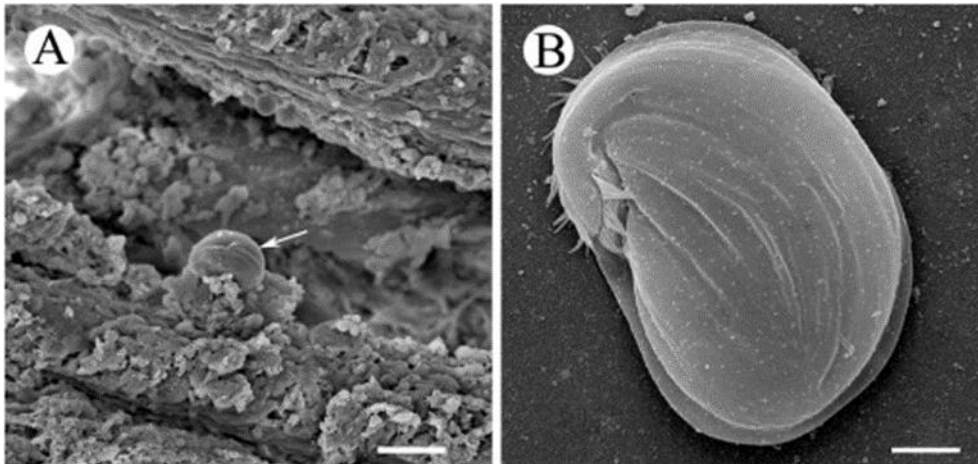
genus *Chilodonella*

- prominent cytopharynx with 3 circumoral kineties; ventral ciliary rows (kineties) forming 2 longitudinal bands close to the body margins
- parasitising fish skin and gills - break down the host surface and feeding on the debris \Rightarrow emaciation, loss of condition, hypoxia, lethargy and even death; heavy infections - parasites cover almost the entire host surface

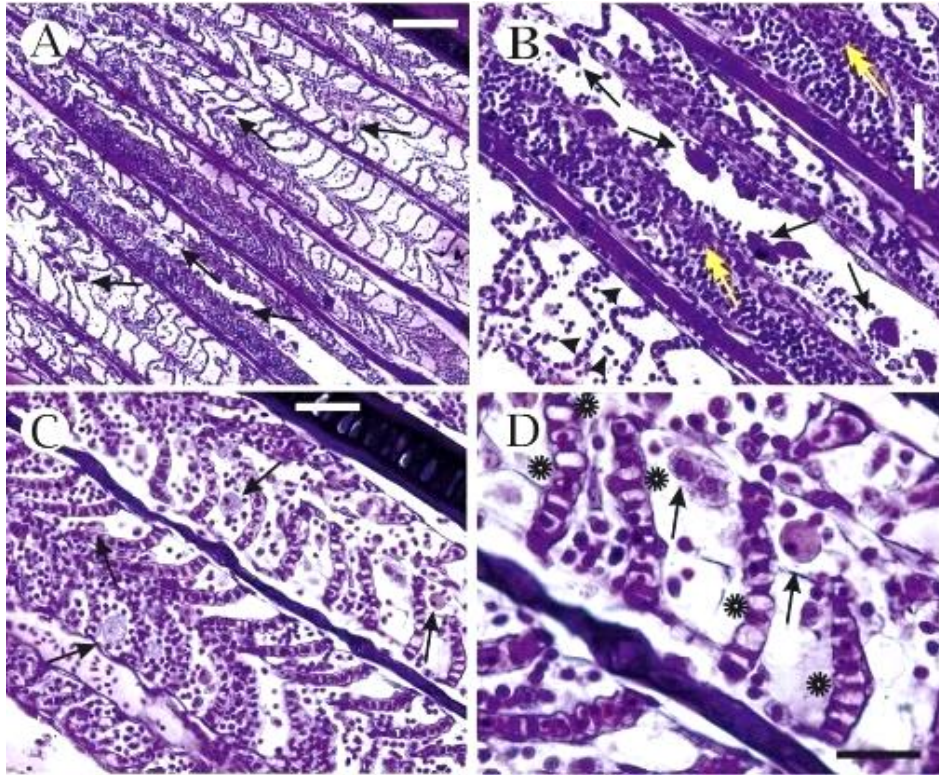


Carp with heavy *Chilodonella* infection, displaying **excess mucus**

Chilodonella hexasticha

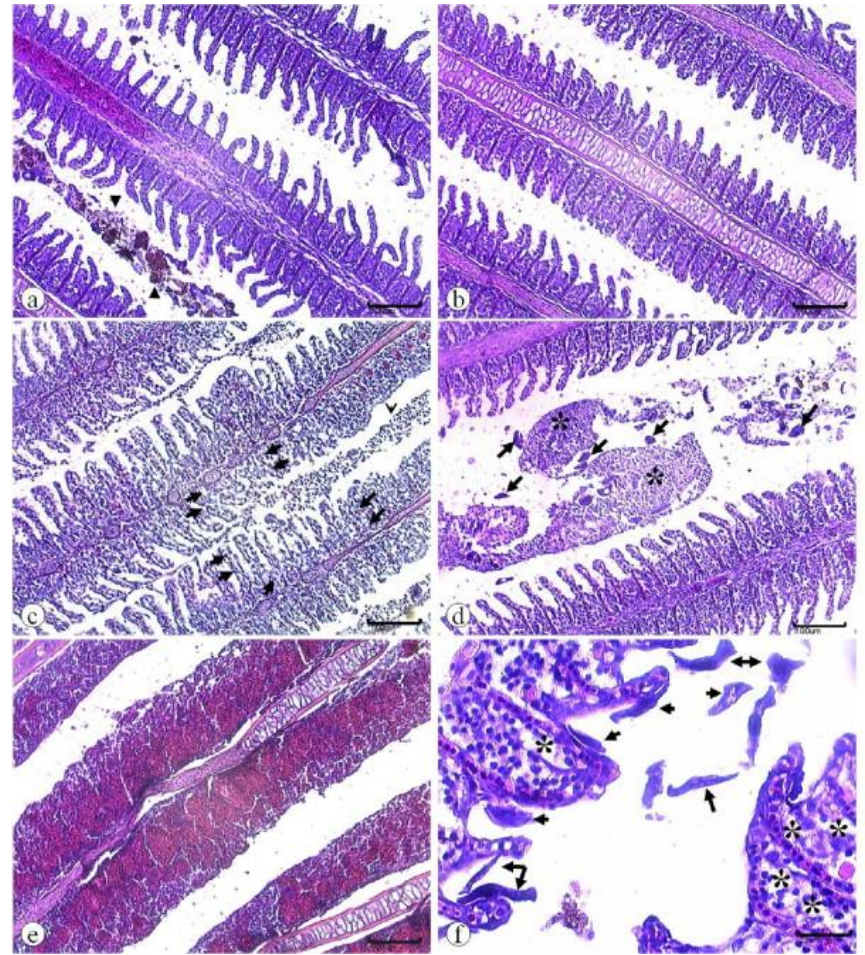


Chilodonella hexasticha



Histopathological sections of *Carassius auratus* gills. Chilodonellids scattered over gill filaments (A-B, arrows) and located between or at the tips of lamellae (C-D, arrows), resulting in severe fusion of lamellae (B-C, yellow double arrow) and desquamation of epithelium cells (B, arrowhead). Necrosis of the epithelium between gill lamellae evident in some areas (D, asterisk). HE.

<https://doi.org/10.1016/j.vetpar.2018.10.009>



Histopathology of the gills of *Piaractus mesopotamicus* parasitised by *Chilodonella hexasticha*. Epithelial hyperplasia (A-F), lamellar fusion (B-F), necrosis (C - arrows; F - asterisk), cellular desquamation (D - asterisk), interstitial hemorrhage (E), and chilodonellids (D, F - arrows). HE.

<https://doi.org/10.1016/j.vetpar.2012.07.030>

Chilodonella uncinata

- cosmopolitan parasite of freshwater fish gills and skin
- suspected facultative endoparasite of mosquito larva (potential biocontrol of medically important mosquito vectors ???)

<https://actascientific.com/ASMI/pdf/ASMI-02-0435.pdf>

***Chilodonella uncinata* – a protozoa pathogenic to mosquito larvae**

Bina Pani Das

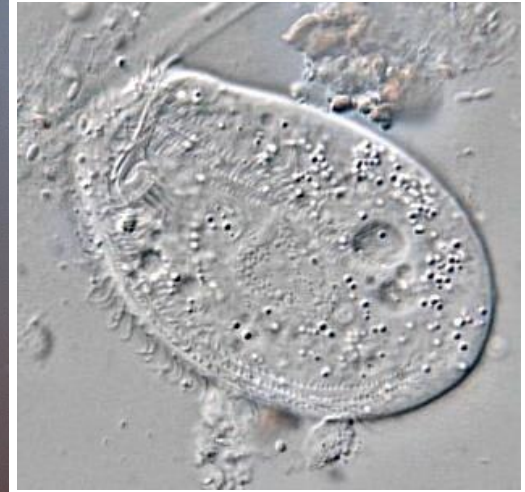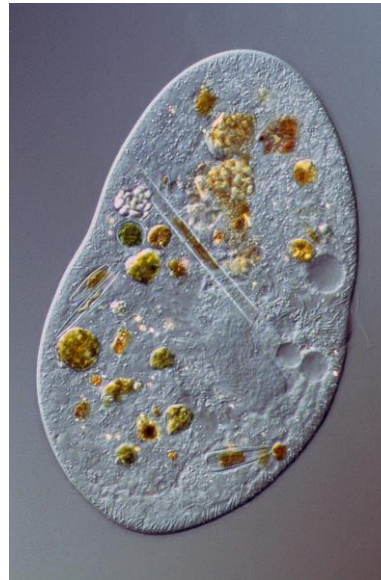Division of Medical Entomology and Vector Control, National Institute of Communicable Diseases, 22 Sham Nath Marg, Delhi 110 054, India

During August 2001, repeated high mortalities observed in *Culex tritaeniorhynchus* and *Cx. pseudovishnui* mosquito larvae collected from paddy fields prompted me to detect the causative organism. A ciliated protozoan, *Chilodonella uncinata*, was found to cause chronic and fatal infection in the natural population of mosquitoes in and around Delhi, North India. Anopheline larvae were less (14.13%) susceptible to *Chilodonella* infection than culicine larvae (75.21%). Body cavities of dead and transparent larvae were found packed with thousands of motile endoparasitic stage of the ciliate. Numerous cuticular cysts were observed on cadaver of larvae and pupae. The use of cuticular cyst in differentiating ciliate genera pathogenic to mosquitoes is discussed. The limited study points to the biological control potential of *Ch. uncinata* against vectors of Japanese encephalitis.

<https://www.jstor.org/stable/24108543>



25 µm




https://www.youtube.com/watch?v=TPrLu8-H_h4

<https://www.youtube.com/watch?v=e-btCEUR-hY>

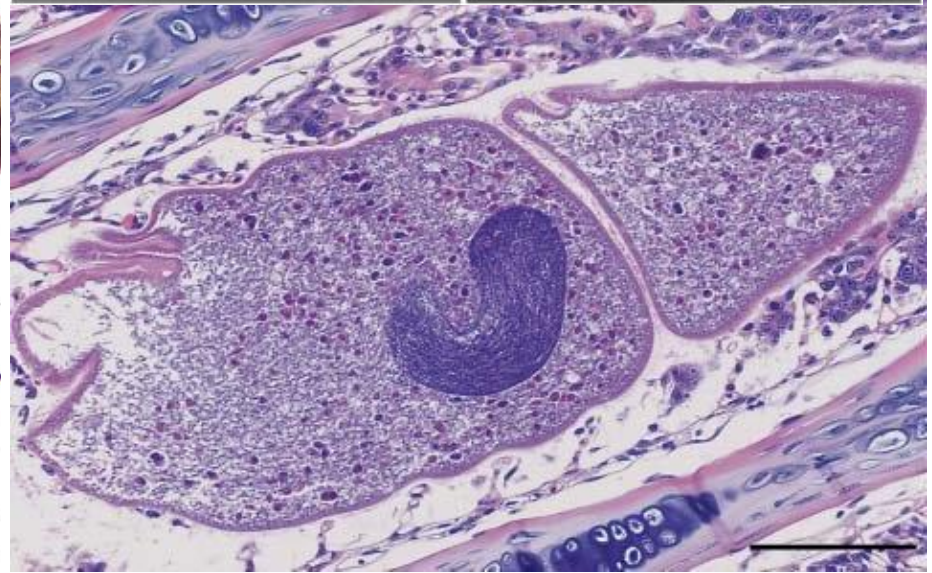

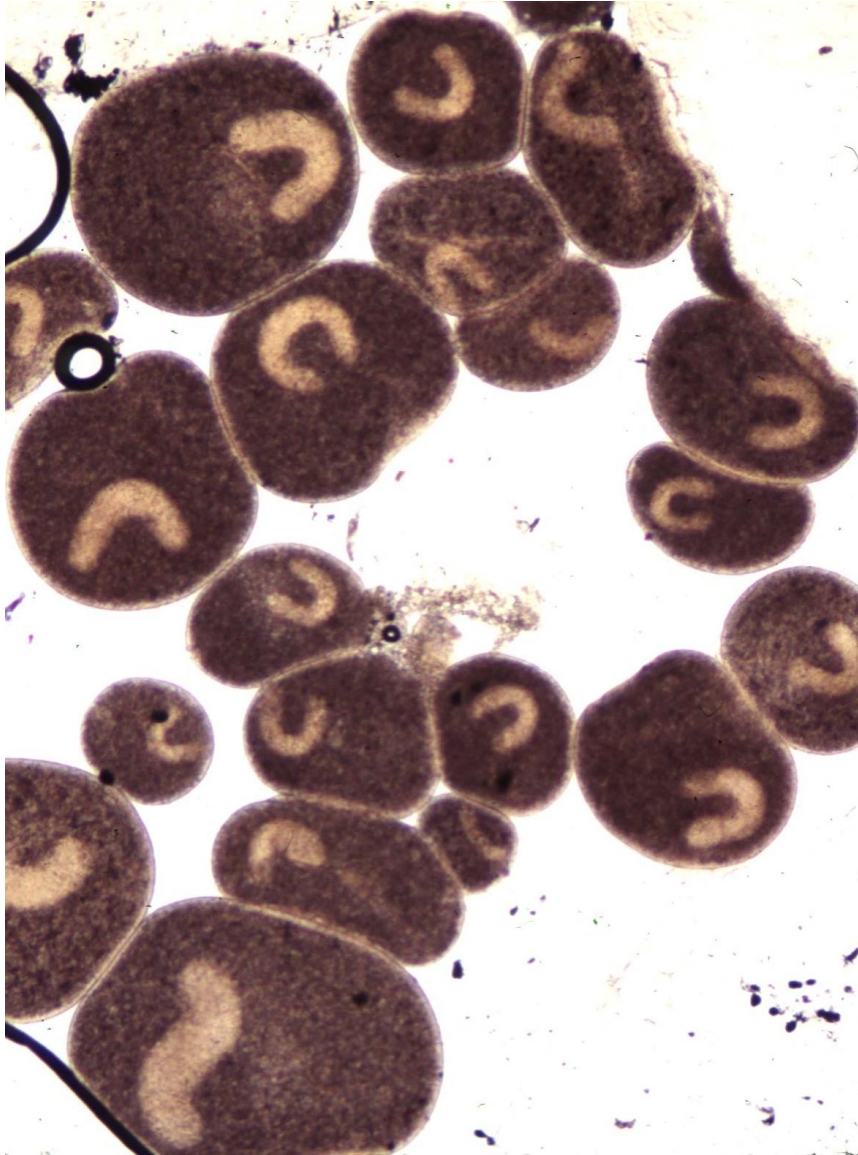
Ichthyophthiriidae

Ichthyophthirius multifiliis

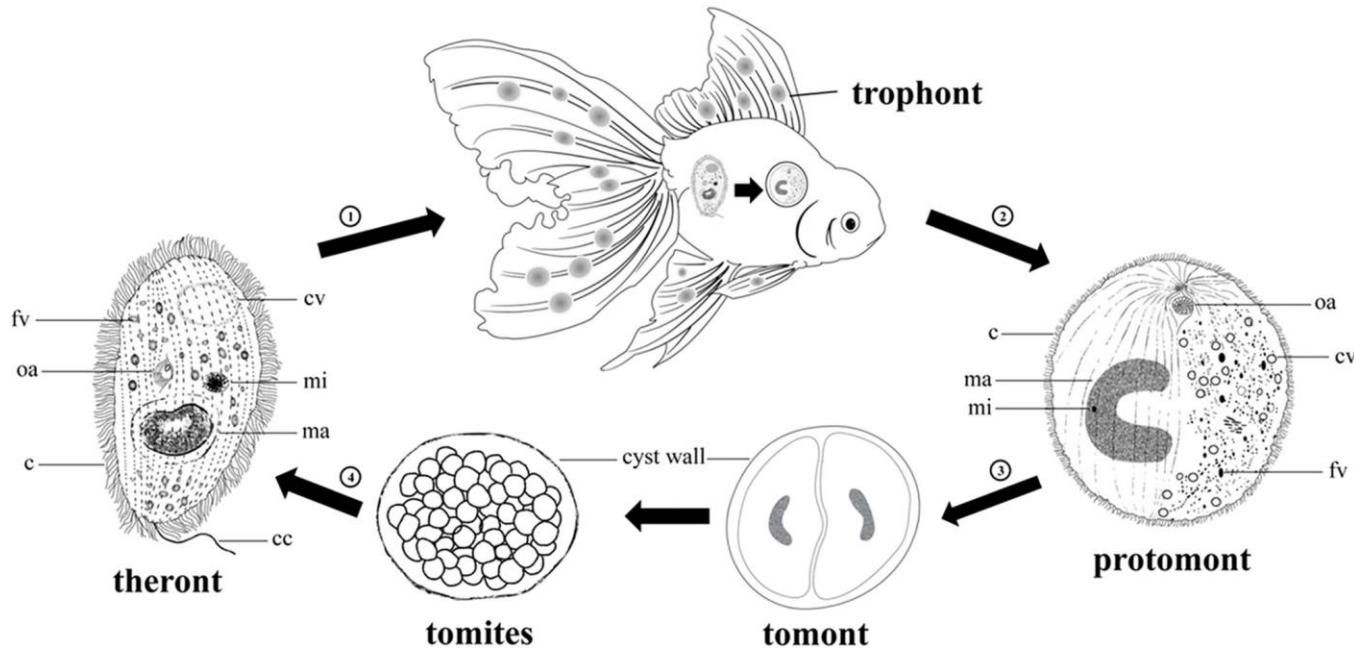
- only species within the genus
- infecting most freshwater fish species
- feeding stage = macroscopically visible **trophonts** (trophozoite resides inside host = endoparasite, visible as a white spot on the surface of the fish) (up to 1 mm in diameter)
- using cytostome, trophont eats away the corridors in the skin, gill or fin epithelium of fish
- **encystation** and rapid division (within cyst) to form **tomites** inside the cyst at the bottom
- tomites transform into **theronts** with a perforatorium that are looking for a new fish host



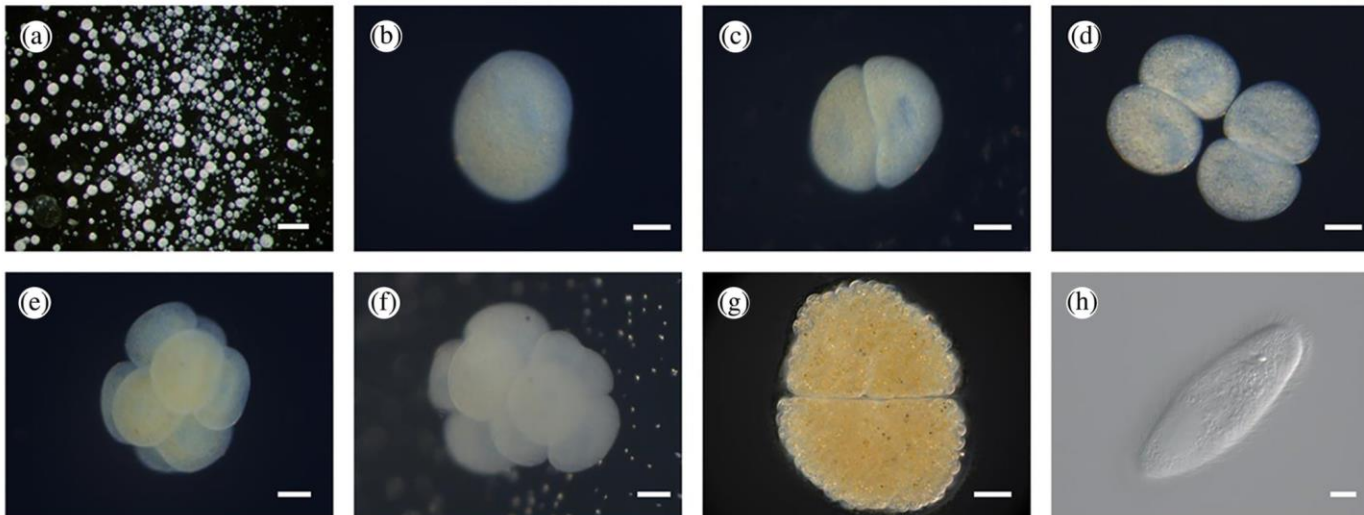
Ichthyophthirius multifiliis



Life cycle of *Ichthyophthirius multifiliis*



1) Theront invades host epidermis and grows into a trophont. 2) Trophont leaves host to become a protomont, which can swim freely. 3) Protomont secretes a cyst wall to become a tomont. Tomont undergoes binary fission, producing large numbers of tomites. 4) Tomites transform into theronts that break out from the cyst wall to find new host. *c* - cilia; *cc*, caudal cilium; *cv*, contractile vacuole; *fv* - food vacuole; *ma* - macronucleus; *mi* - micronucleus; *oa* - oral apparatus.




Detailed processes of a tomont's division. A) Tomonts. B) One-cell period. C) Two-cell period. D) Four-cell period. E) Eight-cell period. F) Sixteen-cell period. G) Multi-cell period. H) Theront.

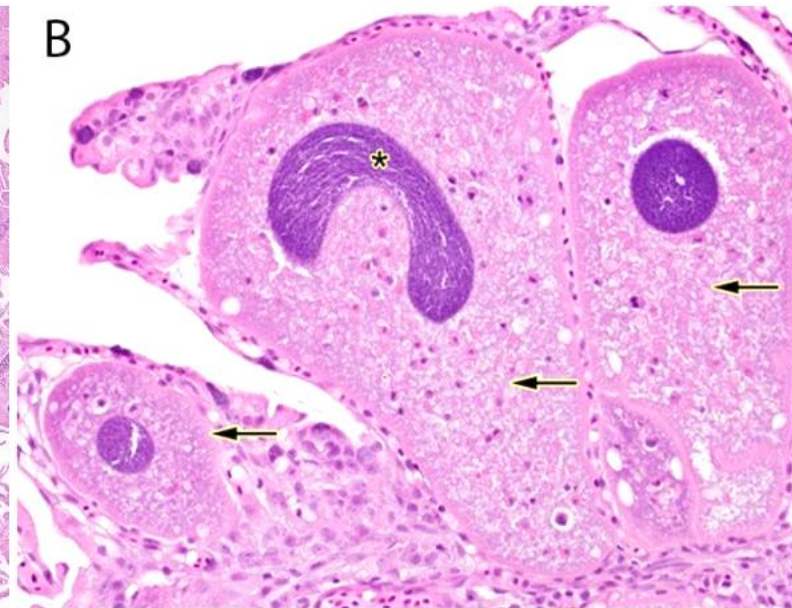
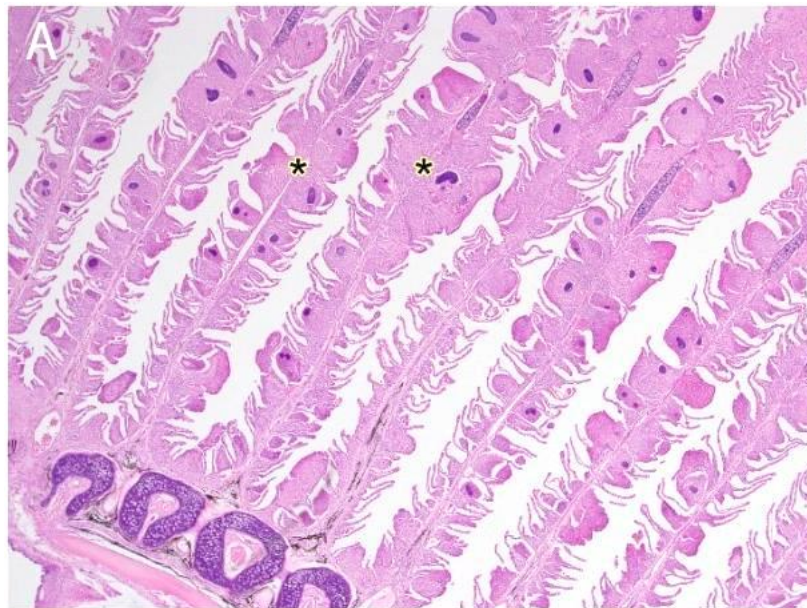
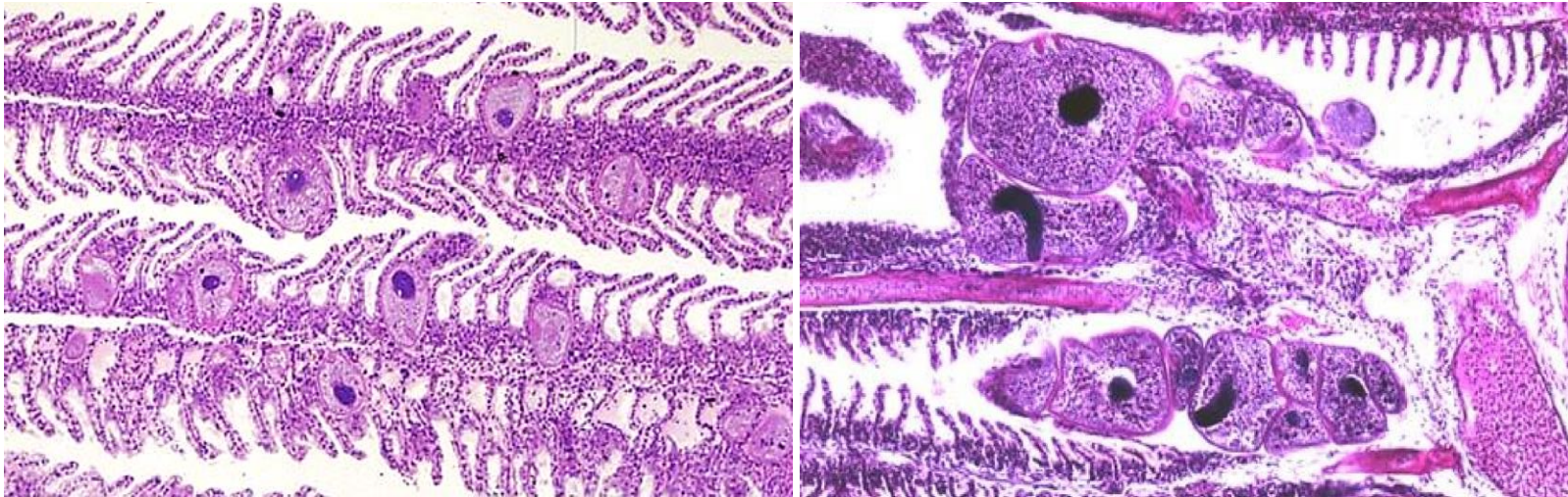
Symptoms of ichthyophthiriasis

- trophonts, continuously rotating, are surrounded by host epidermal cells and leukocytes, producing a minute elevation of the skin (light-reflecting nodules) = **white spot disease**
- infection challenges hosts' osmoregulation and respiration + secondary bacterial and fungal infections

Clinical signs: anorexia, hyperventilation, discoloration, abnormal behaviour (inactivity, isolation), resting on the bottom, flashing (rubbing and scratching against objects), balance disturbance, upside-down swimming near the surface



Pathology of ichthyophthiriasis

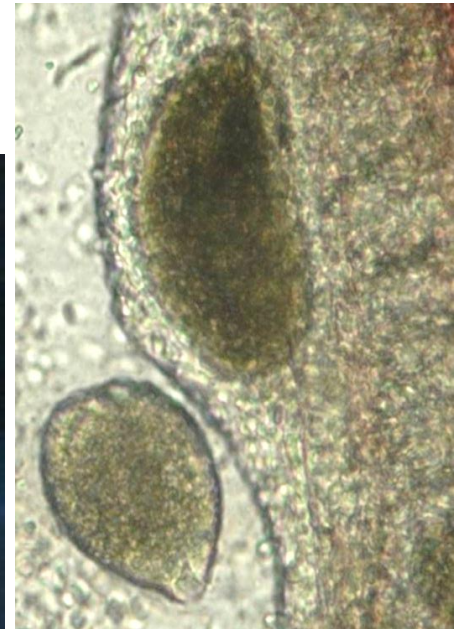
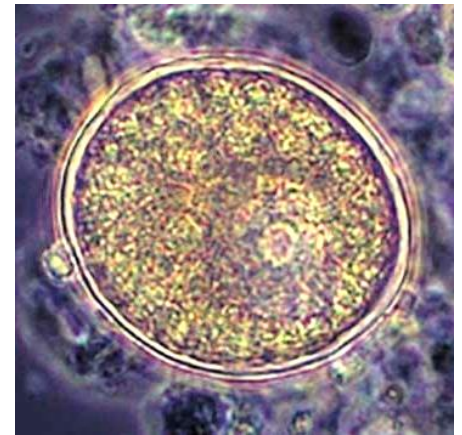


A) Histology of gills with widespread lamellar epithelial hyperplasia with lamellar fusion (asterisks). **B)** Subepithelial ciliated protozoal cysts (arrows) contain a characteristic crescent-shaped macronucleus (asterisks) with abundant phagocytized erythrocytic and cellular debris.

Cryptocaryonidae

Cryptocaryon irritans

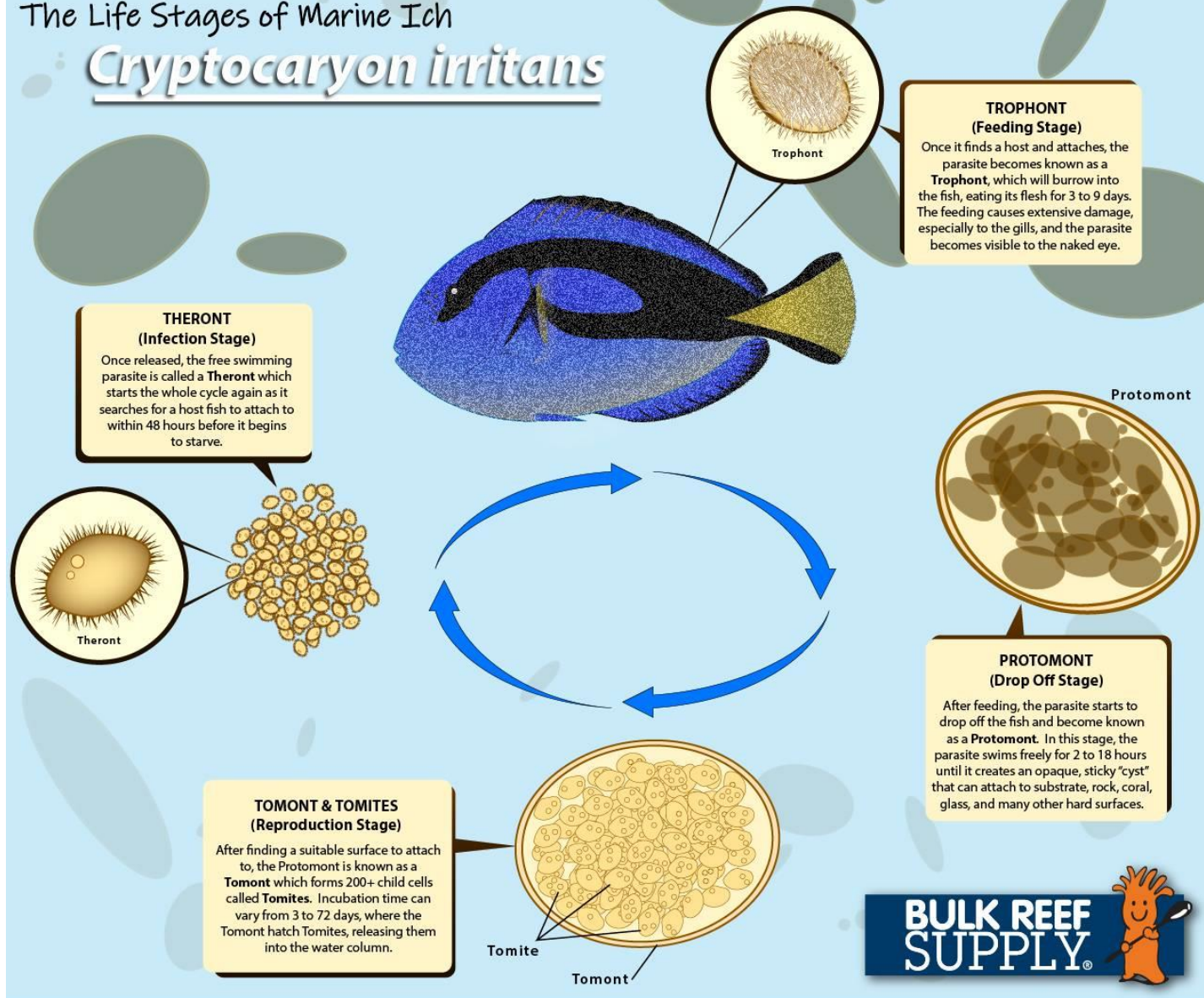
- only species within the genus
- originally classified as *Ichthyophthirius marinus*
- invading epithelium of fish skin, fins, gills and even the eyes
- feeding on the body fluids, tissue debris and whole cells of its host
- marine white spot disease or „marine ich (pronounced ick)“
- symptoms and life-cycle are generally similar to those of *I. multifilis*
- most common agents of disease in marine aquaria



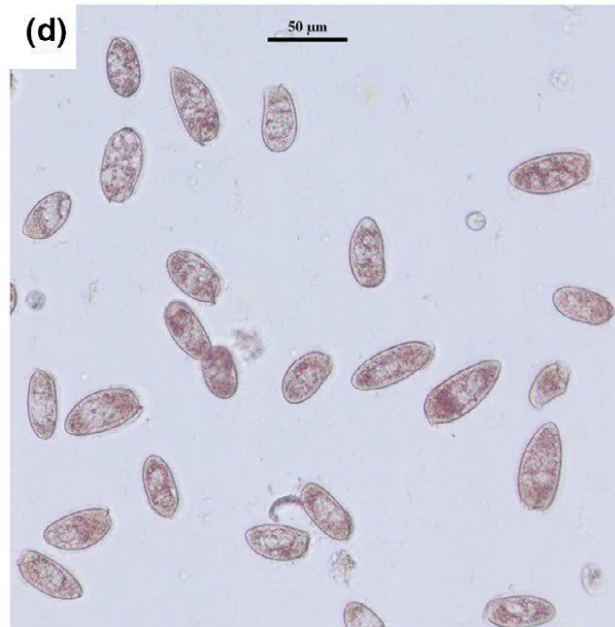

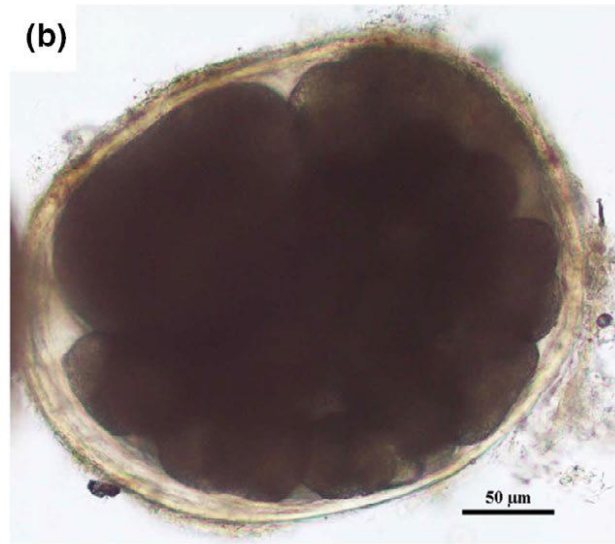
Life cycle of *Cryptocaryon irritans*

The Life Stages of Marine Ich

Cryptocaryon irritans



Life stages of *Cryptocaryon irritans*



A) 2 trophonts settling in a gill cavity

B) early toront

C) later tomont phase

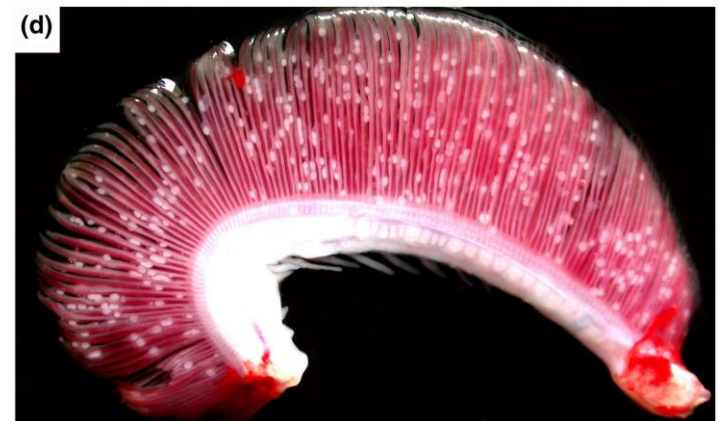D) theronts

<https://doi.org/10.1111/raq.12594>

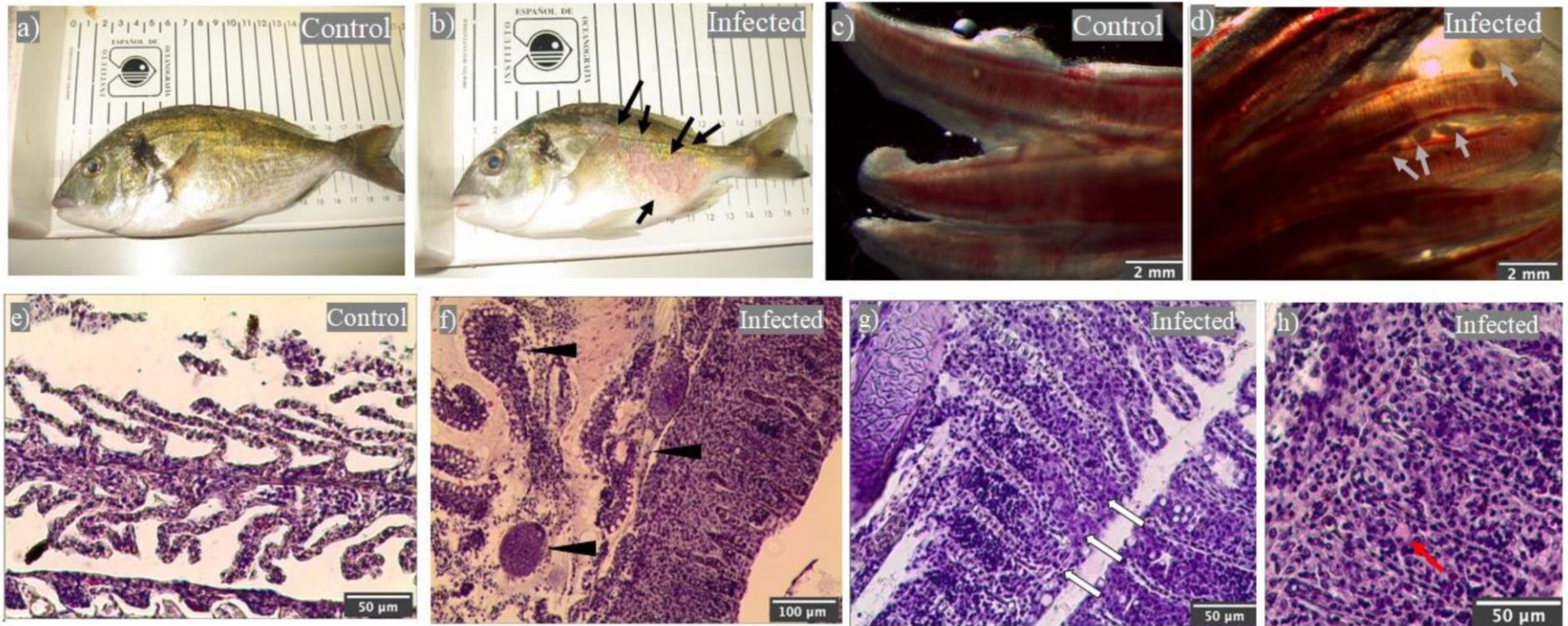
Symptoms of *Cryptocaryon irritans* infection

Infected fish hover just under the water surface (A) are lethargic and unresponsive, suddenly scratch their body on the bottom / wall of the tank or net cage, breathe more rapidly and lose their appetite.

Clinical signs: pinhead-sized white nodules on the gills and body (B-D), mucus hyperproduction, skin discoloration, corneal cloudiness, ragged fins and pale gills ⇒ often fatal due to asphyxiation, osmotic imbalance and/or secondary bacterial infections



Pathology of *Cryptocaryon irritans* infection



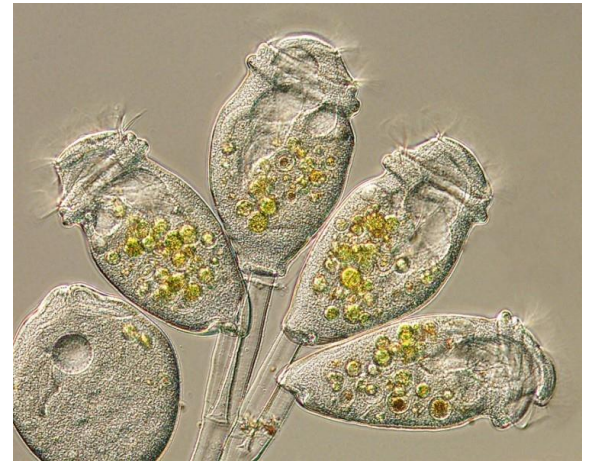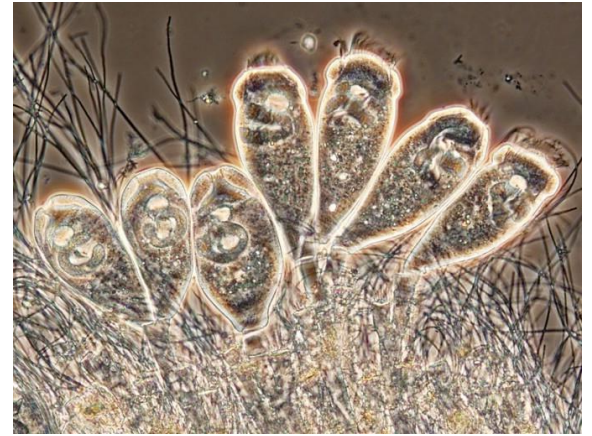***Cryptocaryon irritans* trophonts in the gills of gilthead seabream.** Macroscopical and binocular representatives of healthy (control in **A, C**) and infected (**B, D**) gilthead seabream. Gill sections stained from control (**E**) and infected (**F-H**) gilthead seabream. Note the parasite adhering to the gills (**F**). Black arrows point to skin injuries during *C. irritans* infection. Grey arrows and black arrow heads point to *C. irritans* trophonts. White arrows point to the undifferentiated tissue between the secondary lamellae. Red arrows point to eosinophilic cells.


<https://doi.org/10.3390/ijms23020937>

Sessilida - Epistylididae

genus *Epistylis*

- urn-shaped peritrich ciliate
- mature zooids or trophonts sedentary or sessile
- ring of cilia on the distal end
- rigid dichotomous stalk, attaches by a disk to host's hard surfaces (spines, scales, gill)
- often branching to form a colony
- skin, fins, and gills of fish
- ectocommensals x ectoparasites = feeding primarily on bacteria and organic material, but eroding scales and hard spines of fins \Rightarrow irritation and inflammation of host epithelium at the attachment point \Rightarrow site for secondary infections of *Aeromonas hydrophila*
- except for injury incurred by attachment, they are seldom harmful to the host unless there is massive infection



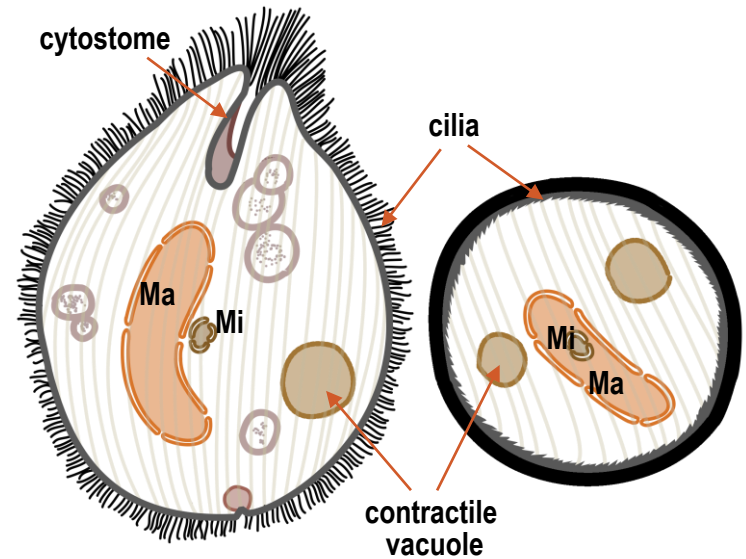


***Epistylis* sp.** **A)** in fresh-mounted slide under LM. **B)** Zooid in binary fission and detail of bacteria (arrow heads) attached on the peduncle of the ciliate. **C)** *Oreochromis niloticus* with fin erosion and loss of scale (arrowheads) associated with *Epistylis* colonisation. **D)** *Pseudoplatystoma* sp. showing total erosion of dorsal fin and *Epistylis* colonies on the dorsal fin and head (arrow heads).

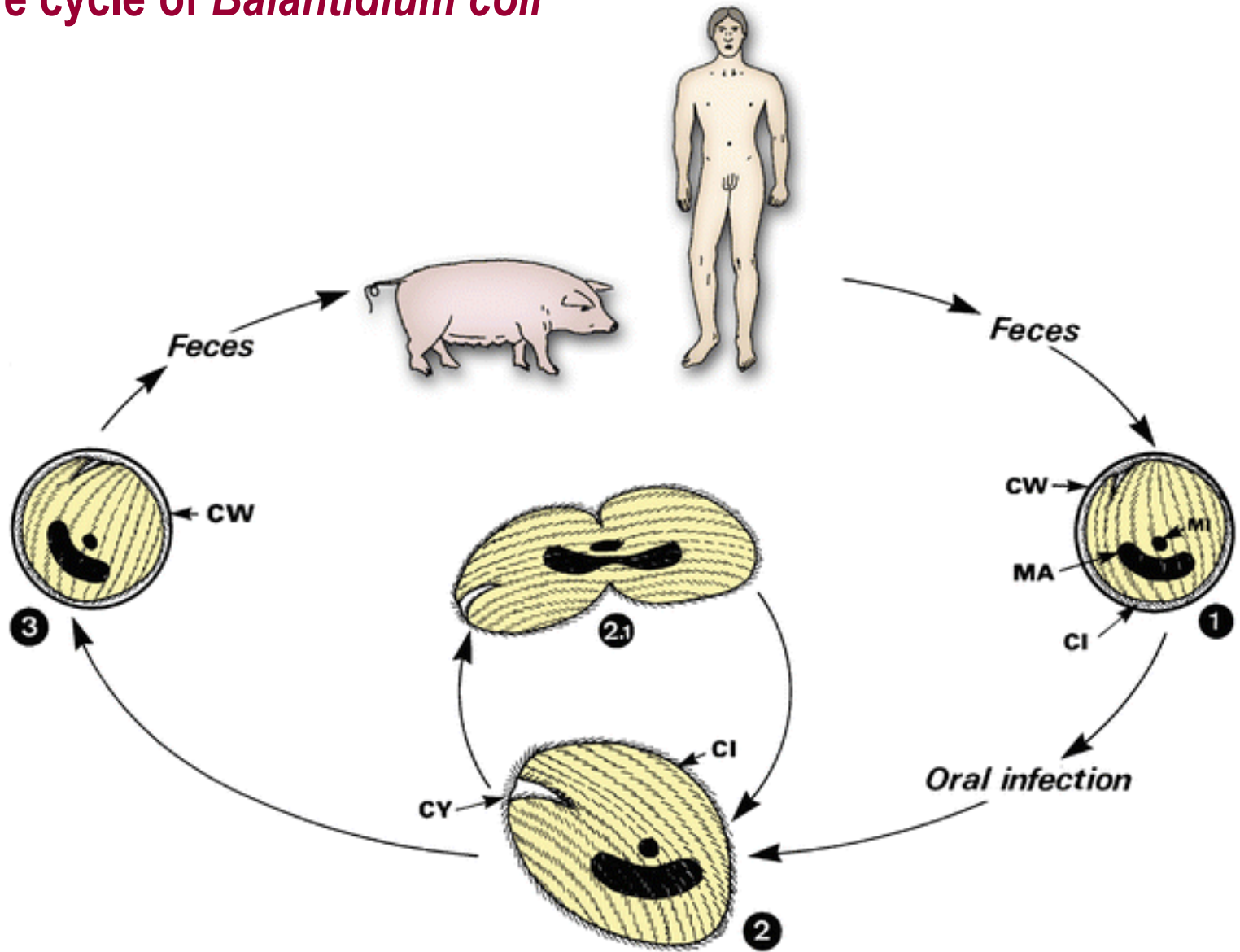
Balantidiidae

Balantidium coli

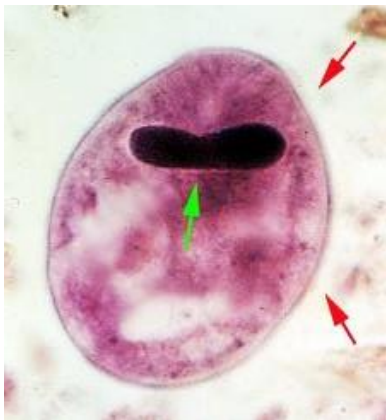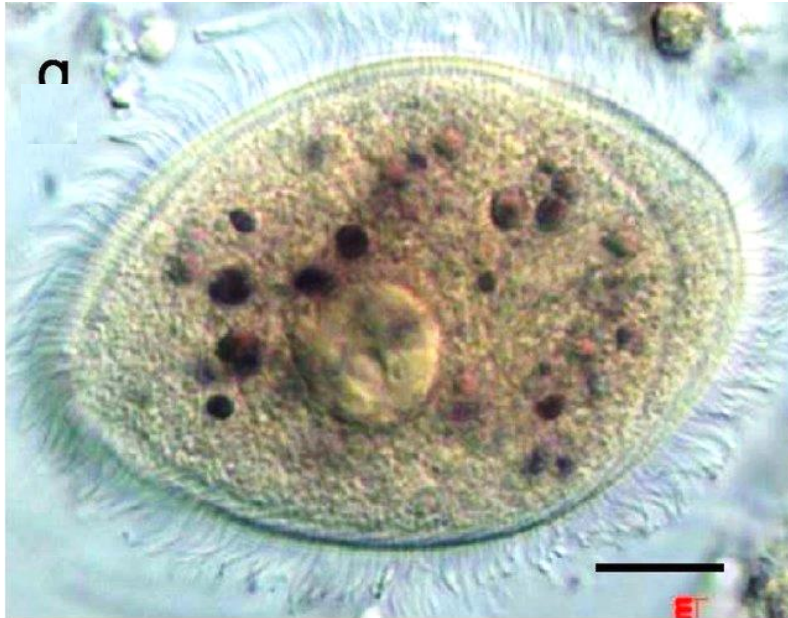- *Neobalantidium coli*, *Balantioides coli*
- **trophozoite** (50 x 200 μm), **cyst** (50 x 60 μm)
- colonising lumen of the large intestine and caecum
- commensal, but under certain circumstances, acting as an opportunistic pathogen \Rightarrow invasive, attacking the intestinal wall, rarely extraintestinal infections
- primary reservoir: pig (usually without symptoms)
- humans can also be reservoirs, and other potential animal hosts include rodents, dogs, nonhuman primates and birds
- in older literature, human balantidiosis also known as "butchers' disease" = referring to its frequent occurrence in butchers who often come into contact with the contents of the pig's colon



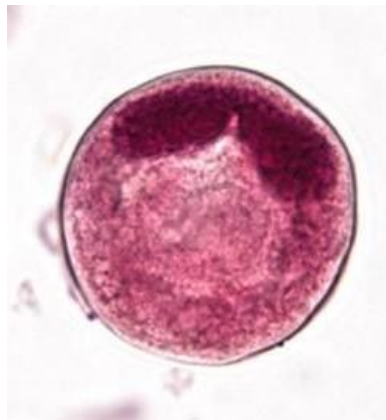
Life cycle of *Balantidium coli*



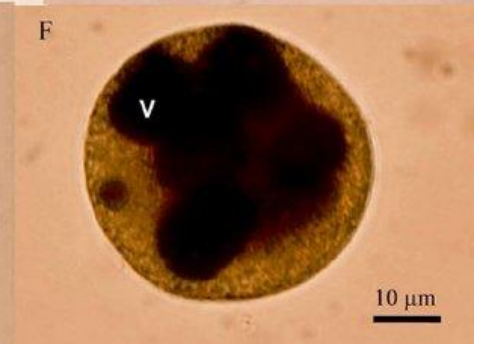
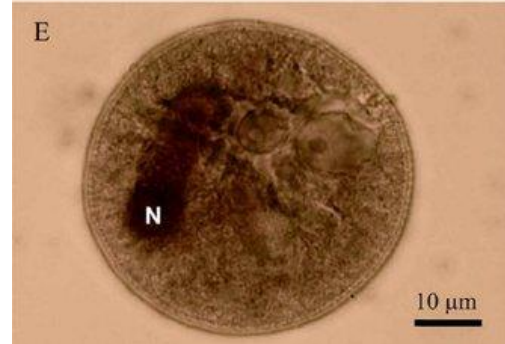
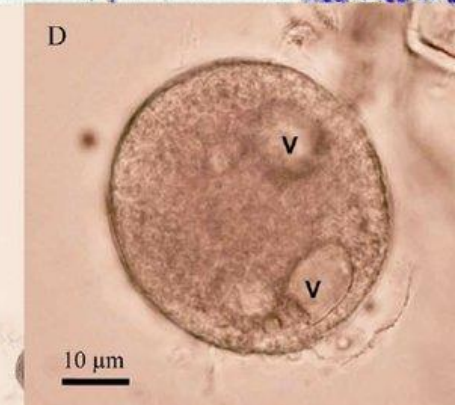
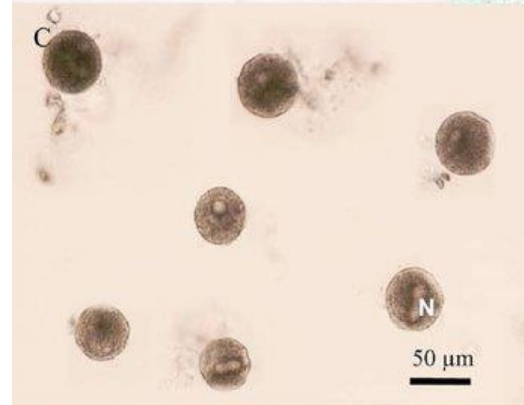
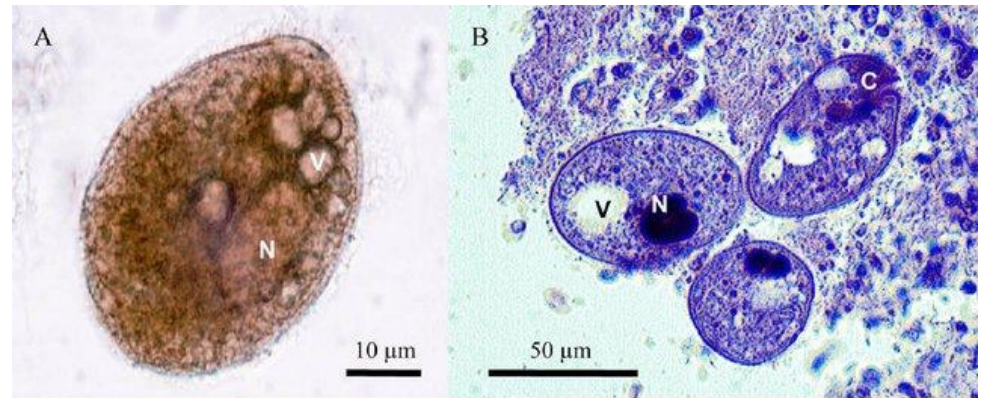
Morphology of *B. coli* life stages



trofozoite



cyst



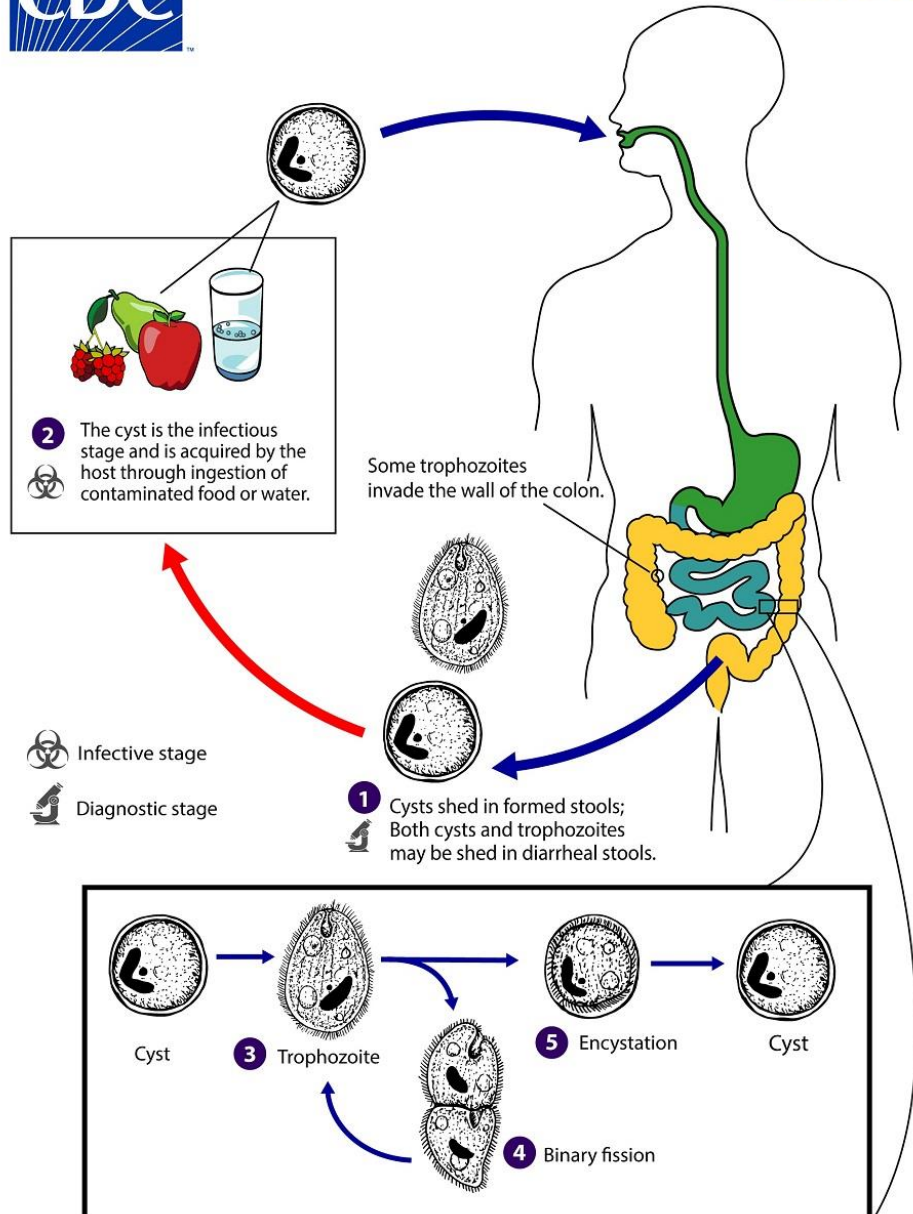
A) Trophozoite stained with Lugol's iodine. Note the macronucleus (N) and vacuoles (V). **B)** HE stained histological section of pig intestine showing 3 trophozoites; cytotome (C), macronucleus (N). **C)** Cysts from gorilla stained with Lugol's iodine. Macronucleus (N) is visible in some cysts. **D-F)** Cysts stained with Lugol's iodine; macronucleus (N), vacuoles (V) varying from 0-6 or more.

Human balantidiasis

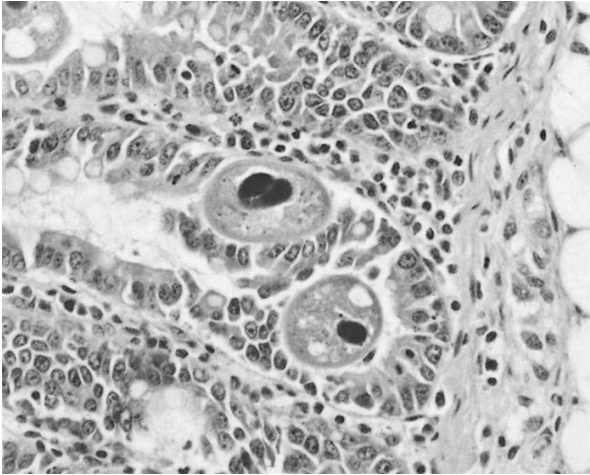
- excystation in small intestine
- often asymptomatic
- **mild chronic form:** diarrhoea, constipation, abdominal pain (many years)
- **acute form:** dysentery (blood and mucus in stool)
- extraintestinal infection is rare but potentially serious, typically secondary to intestinal infection
- rupture of fulminant colonic ulcers, rarely intestinal perforation ⇒ peritonitis and liver abscesses – **can be fatal**
- invasion of urogenital tract due to contamination from anal region or through fistulae caused by severe infection



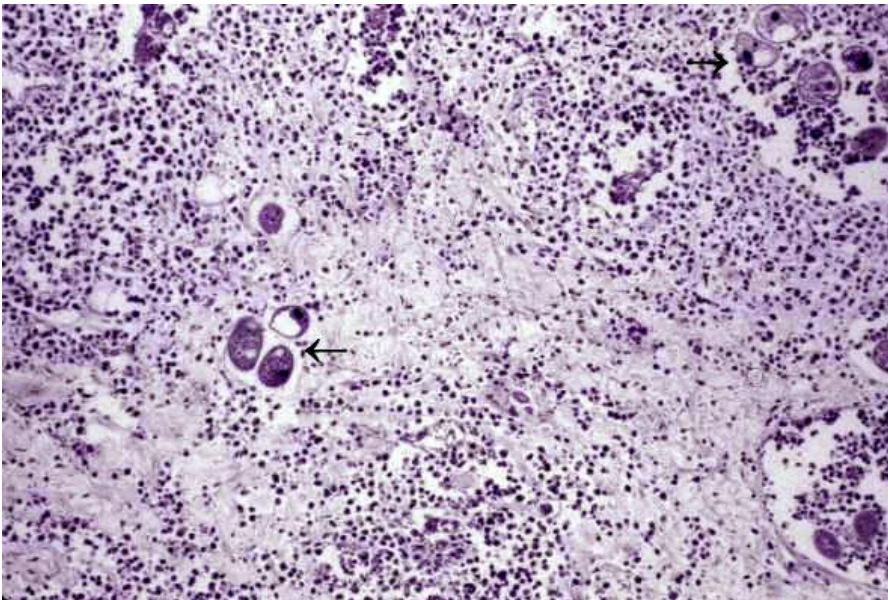
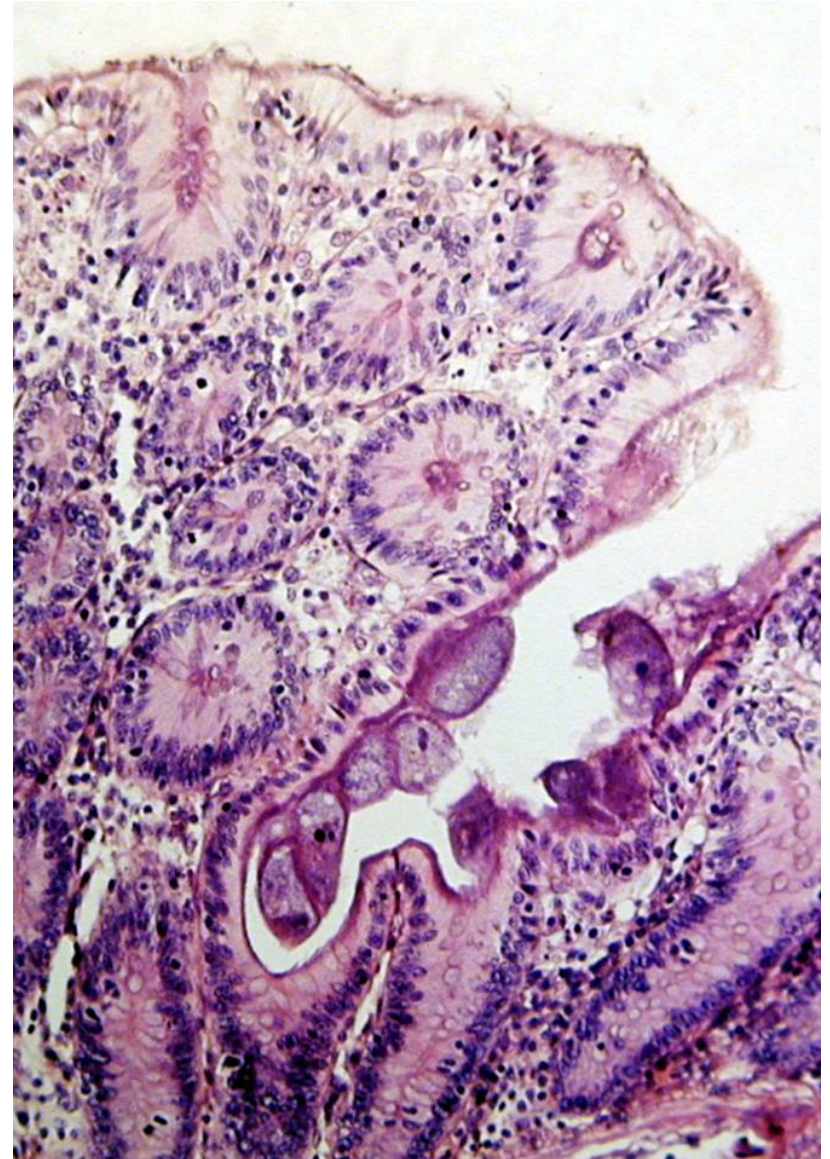
Balantidium coli



Pathology of human balantidiasis



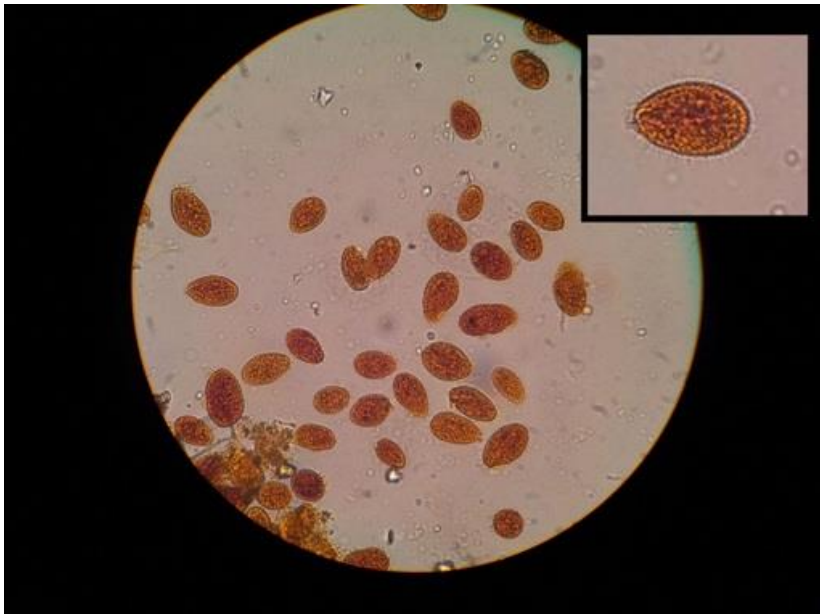
Virulence factor:
hyaluronidase helping *B. coli* to penetrate intestinal mucosa



Balantidium coli trophozoites among necrotic debris and acute inflammatory cells found in colonic ulcers.

Urinary balantidiasis

Accidental finding of *B. coli* in urine of patient with acute renal failure.

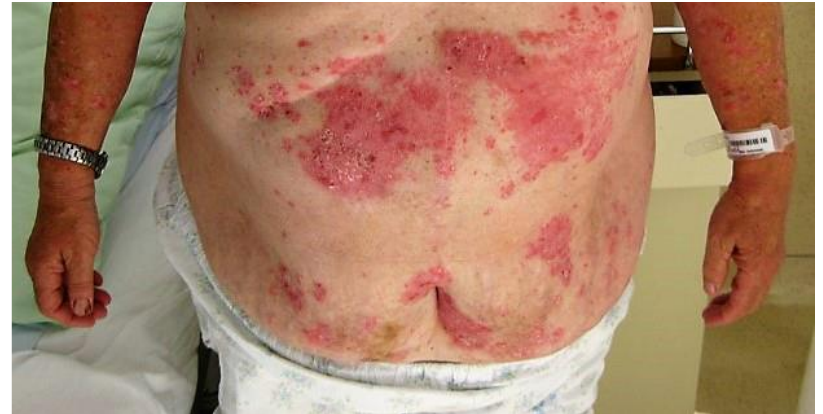

Microscopic examination showing few red cells and ovoid to oblong ciliated parasites.

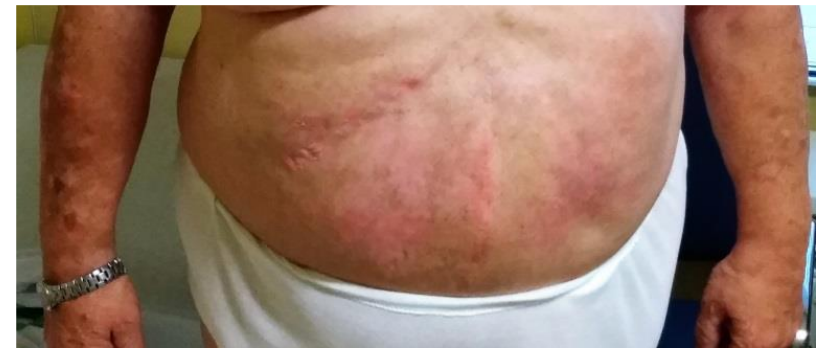https://www.jcdr.net/article_fulltext.asp?id=4343

<https://www.ncbi.nlm.nih.gov/pmc/articles/PMC8957295>

B. coli was also incidentally found in the urine of a female after being in contact with infected pig. This patient had numerous comorbidities ⇒ immunocompromise suspected key factor in urinary balantidiasis

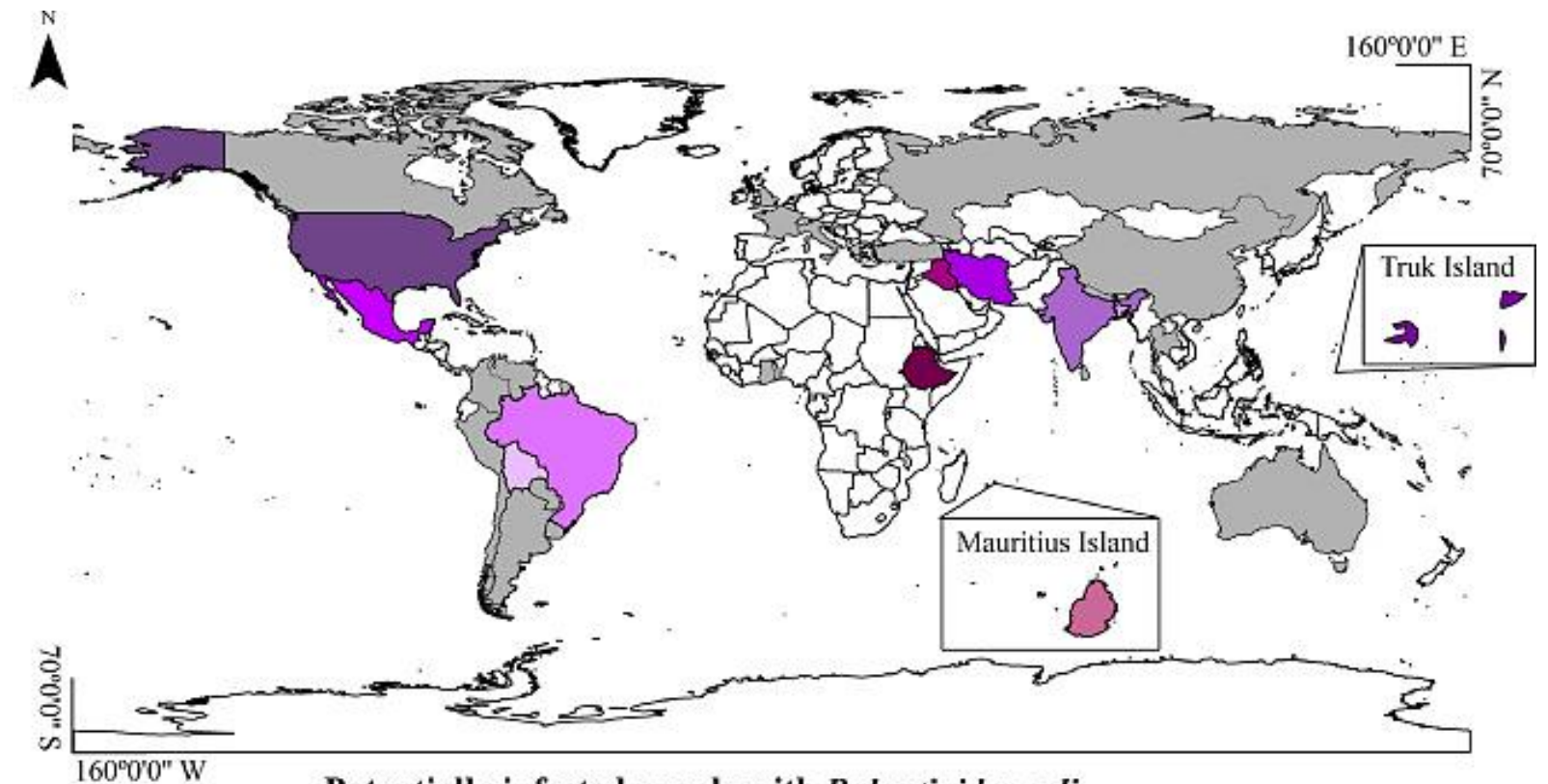


Skin condition of the infected patient before the systemic treatment for psoriasis and balantidiasis was started.




Skin condition after treatment with metronidazole and apremilast.

DOI: 10.4172/2472-1212.1000177



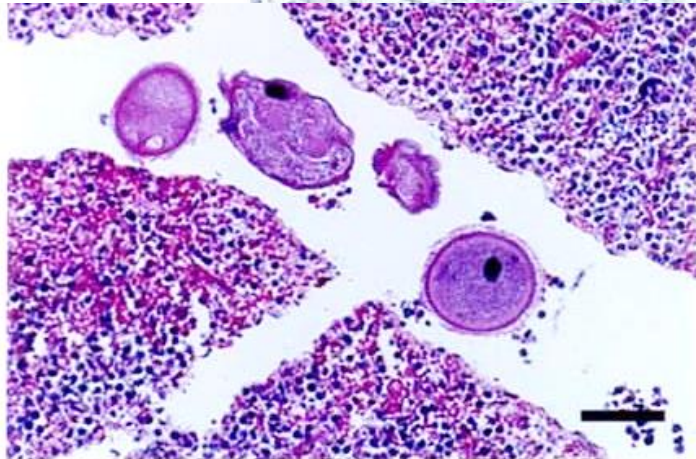
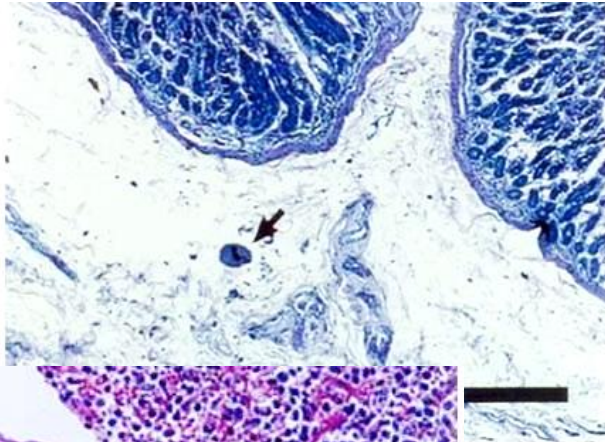
Potentially infected people with *Balantioides coli*



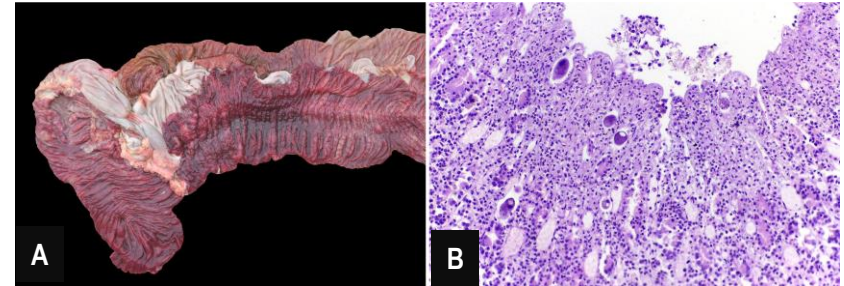
Pathology of animal balantidiasis

- *B. coli* is frequently associated with enteric diseases in man and nonhuman primates, with rare disease manifestations of swine or other mammals

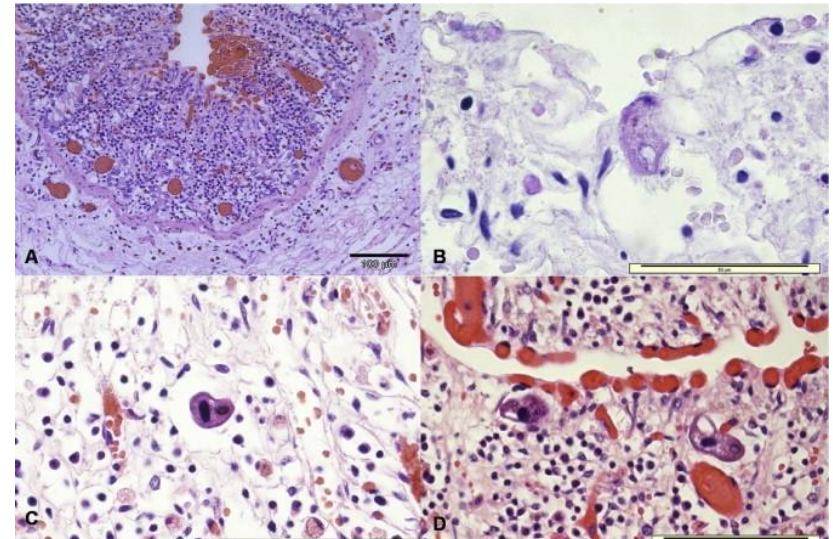
Trophozoite of *B. coli* in submucosa of the abomasum of Barbary sheep.



B. coli in duct of gastric lymph node of Barbary sheep

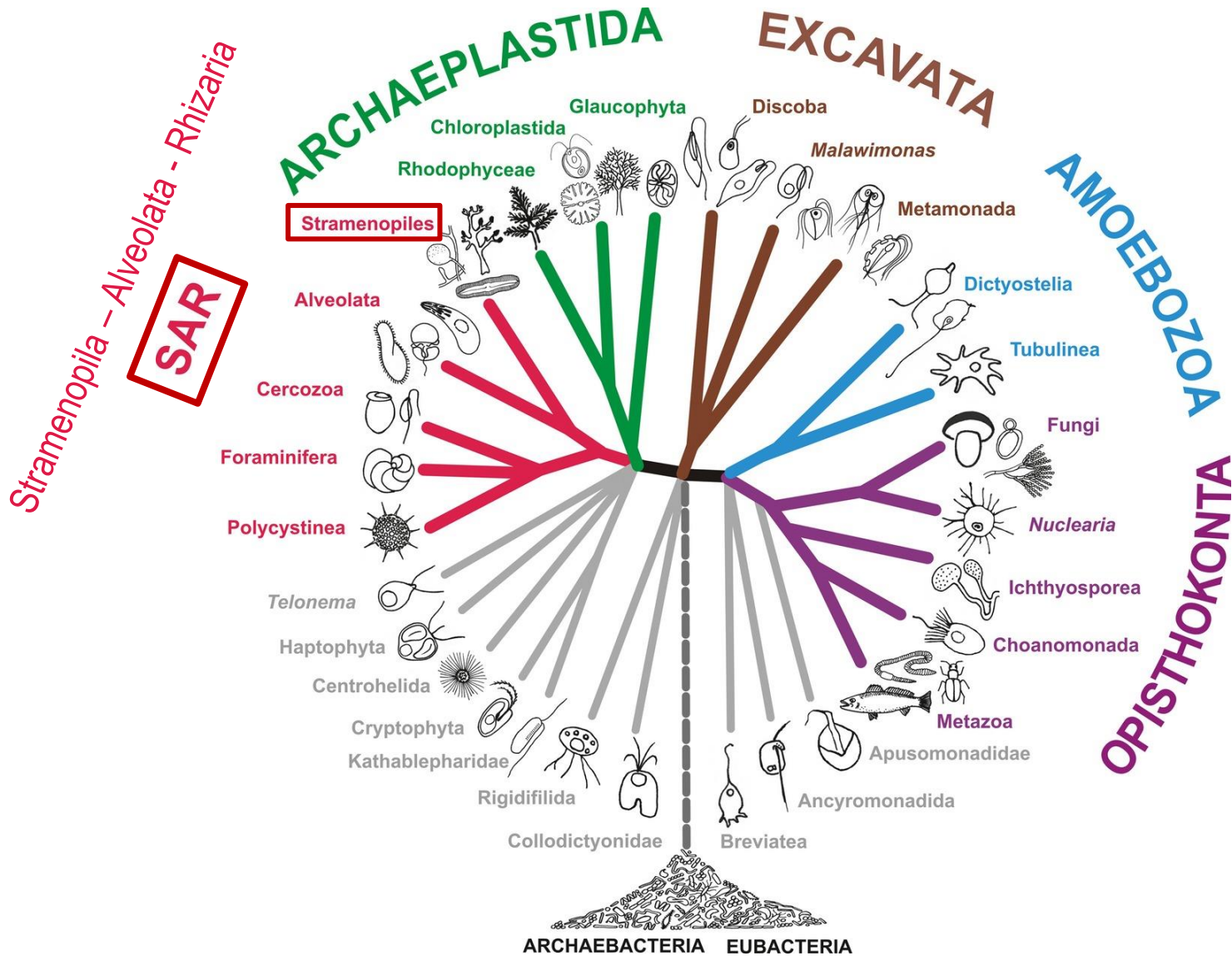


B. coli typhlocolitis in horses A) grossly characterised by diffusely reddened mucosa of the cecum and ventral large colon. B) Mucosa of large colon and cecum present superficial necrosis associated with multiple trophozoites of *B. coli*. HE.



Colon of Finnish horse with balantidiasis. A) Severe haemorrhage and destruction of mucosa with congestion and oedema at the submucosa. B) Ciliated protozoan invading the colonic surface and C-D) are embedded within the colonic mucosa. HE.

5 supergroups = megagroups



Opalinata

- formerly Slopalinida
- multiciliated – cilia (flagella) without tubular hairs evenly spaced cortical ridges underlain by microtubules, ranging from singlets to ribbons
- cyst forming; many osmotrophic in vertebrate guts

Proteromonadea

- 1-2 pairs of anisokont cilia; uninucleate endobionts in intestinal tract of amphibians, reptiles and mammals

Proteromonas lacertae

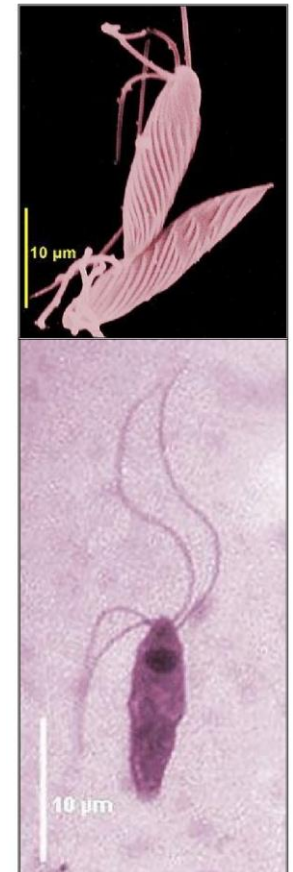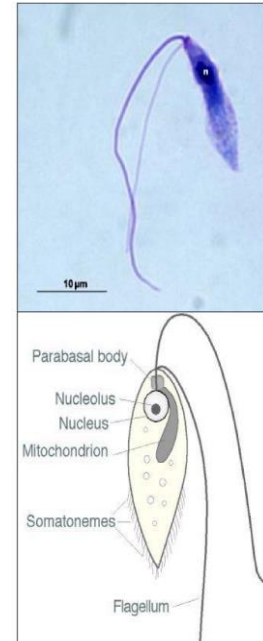
- model species in intestine of lizards, 2 flagella

Karotomorpha bufonis

- intestine of toads, 4 flagella

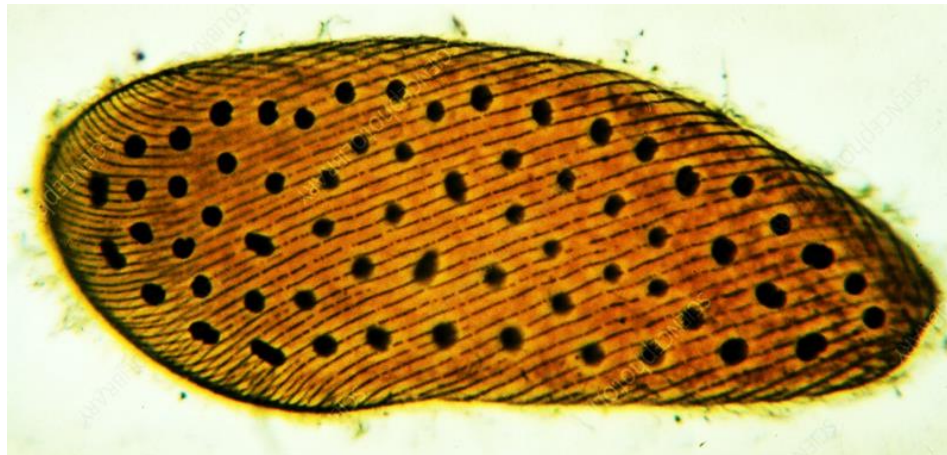
Opalineae

Blastocystis

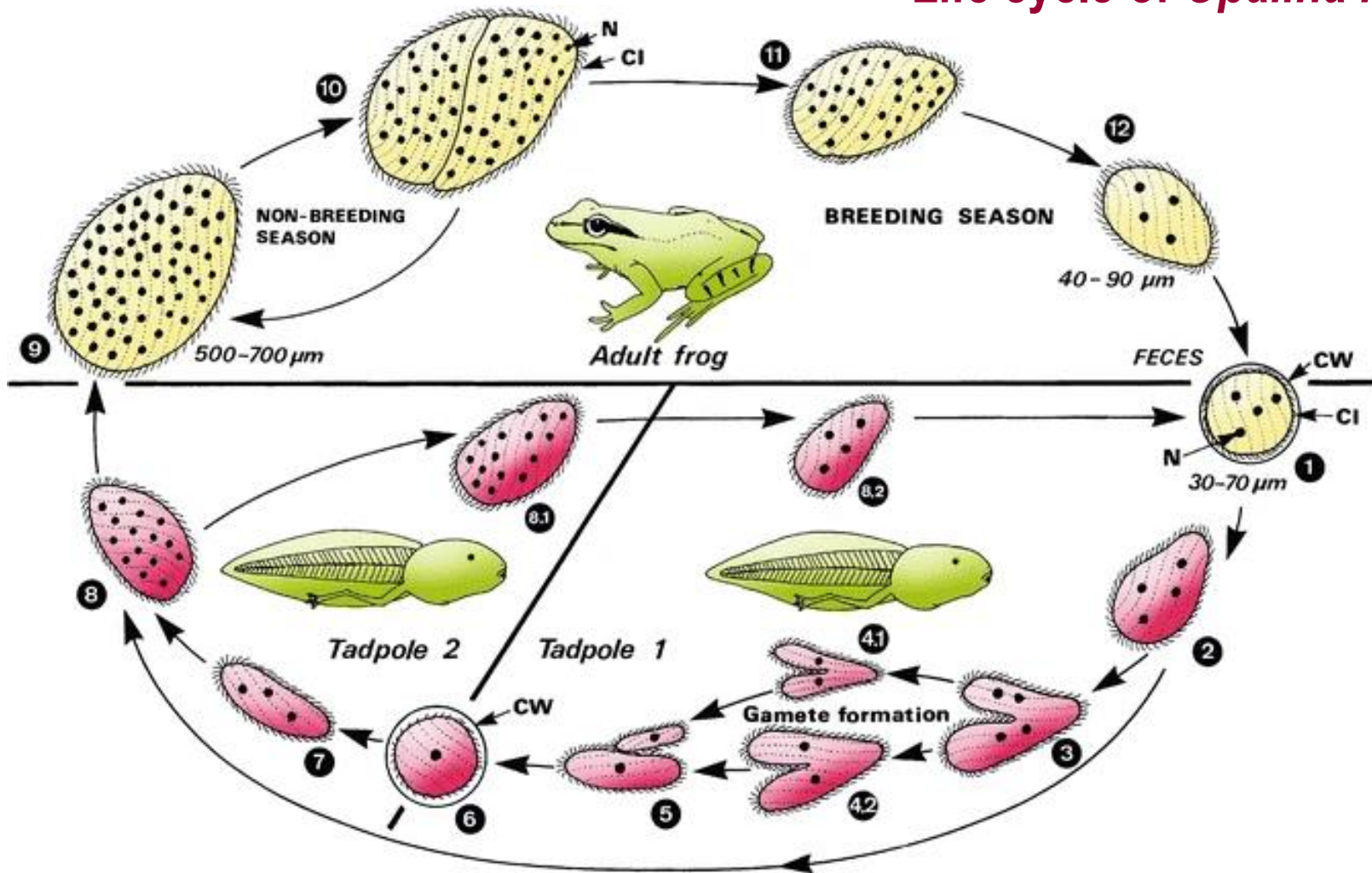


Opalineae

- unusual protists with large cells, previously placed in Ciliophora
- name derived from iridescent appearance when light reflects on their delicately folded surface
- flagella originating from an anterior morphogenetic centre = falx, organised in oblique longitudinal rows or files
- microtubular ribbons supporting longitudinal pellicular ridges between ciliary rows
- 2 to hundreds monomorphic nuclei
- intestinal endobionts of amphibians and some fish
- **life cycle complex** - sexual process induced by host hormones and linked to its life cycle
- genera *Cepedea*, *Opalina*, *Protoopalina*, *Protozelleriella*, *Zelleriella*



Life cycle of *Opalina ranarum*



1) Cysts are excreted by adult frog and ingested by a tadpole. 2) After hatching the young gamont migrates to cloaca. 3-4) Formation of micro- and macrogametes (meiosis). 5) Fusion of the heterogametes. 6) Encystation of the zygote and excretion via faeces. 7-8) After oral uptake of a cyst by another tadpole the trophozoite grows up in the cloaca (up to 0.5 mm). 8.1-8.2) Inside tadpole the small trophozoite may start division, leading to formation and excretion of cysts (1) giving rise to new trophozoites (2-8) after ingestion by another tadpole. 9) After tadpole metamorphosis completion, trophozoites (agamonts, trophonts) grow up and form up to 2,000 nuclei. 10) During frog nonbreeding season, trophozoites multiply by binary fission (either longitudinal or oblique-transverse). 11-12) During breeding season frog hormones induce rapid trophozoites' divisions without compensatory nuclear divisions and growth. Thus the parasites (precystic forms) become successively smaller. These stages, finally having 2–12 nuclei, encyst (1), are set free with the faeces of the host, and become infectious for tadpoles. *Cl* - cilia, *CW* - cyst wall, *N* - nucleus

Opalineae

- *Opalina* (flattened, 1a) and *Cepedea* (cylindrical; 1b, 6a) are multinucleate genera
- *Zelleriella* (flattened; 1c) and *Protoopalina* (cylindrical; 1d, 6b) have 2 nuclei

Fig. 6 Microphotographs of two protargol-stained opalinids. *Cepedea* sp. (a) was isolated from *Kassina senegalensis*. Note multiple nuclei and kineties originatin in the anterior (upper) part of the cell. *Protoopalina intestinalis* (b) was isolated from *Bombina bombina*. Its two nuclei are much larger than in *Cepedea* and are visibly connected. Some flagella are faintly apparent around the cells. The scale bar (10 μ m) applies to both cells. The preparations were stained by Ivan Čepička

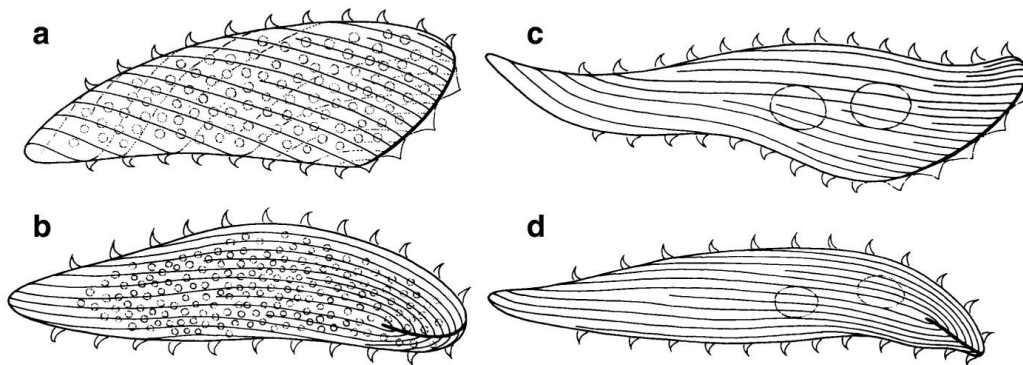
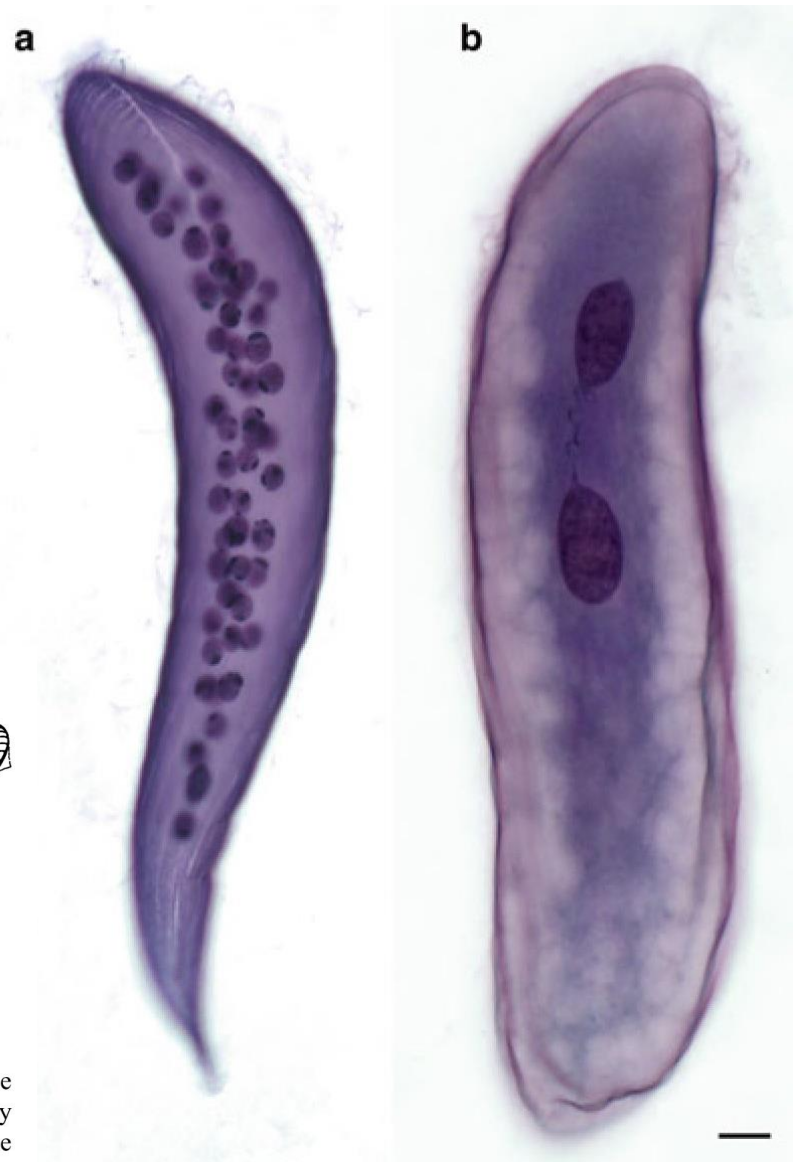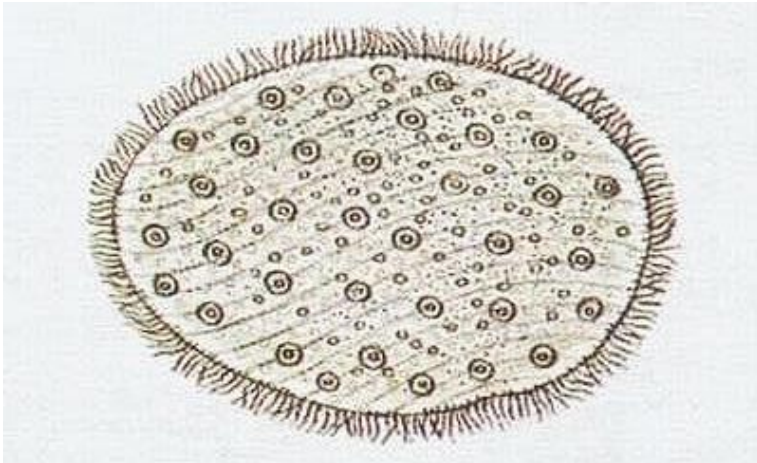
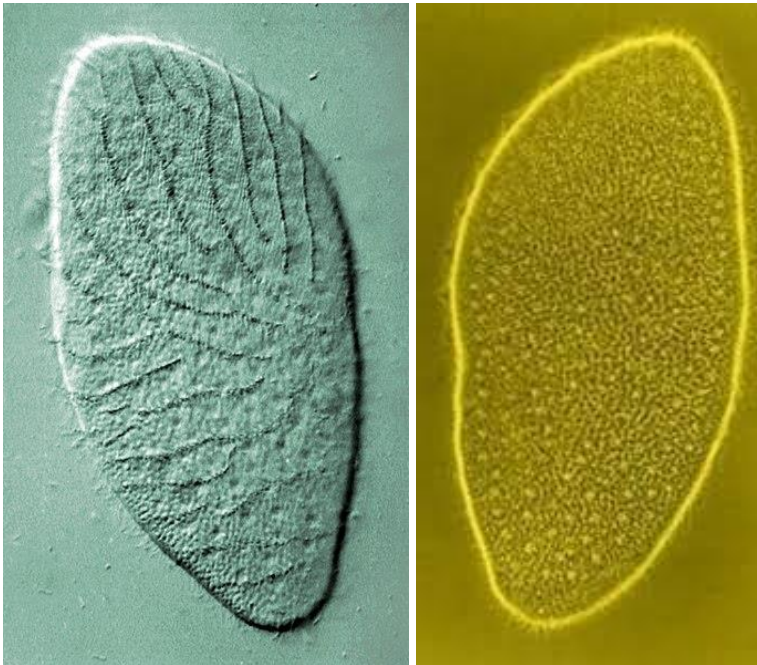


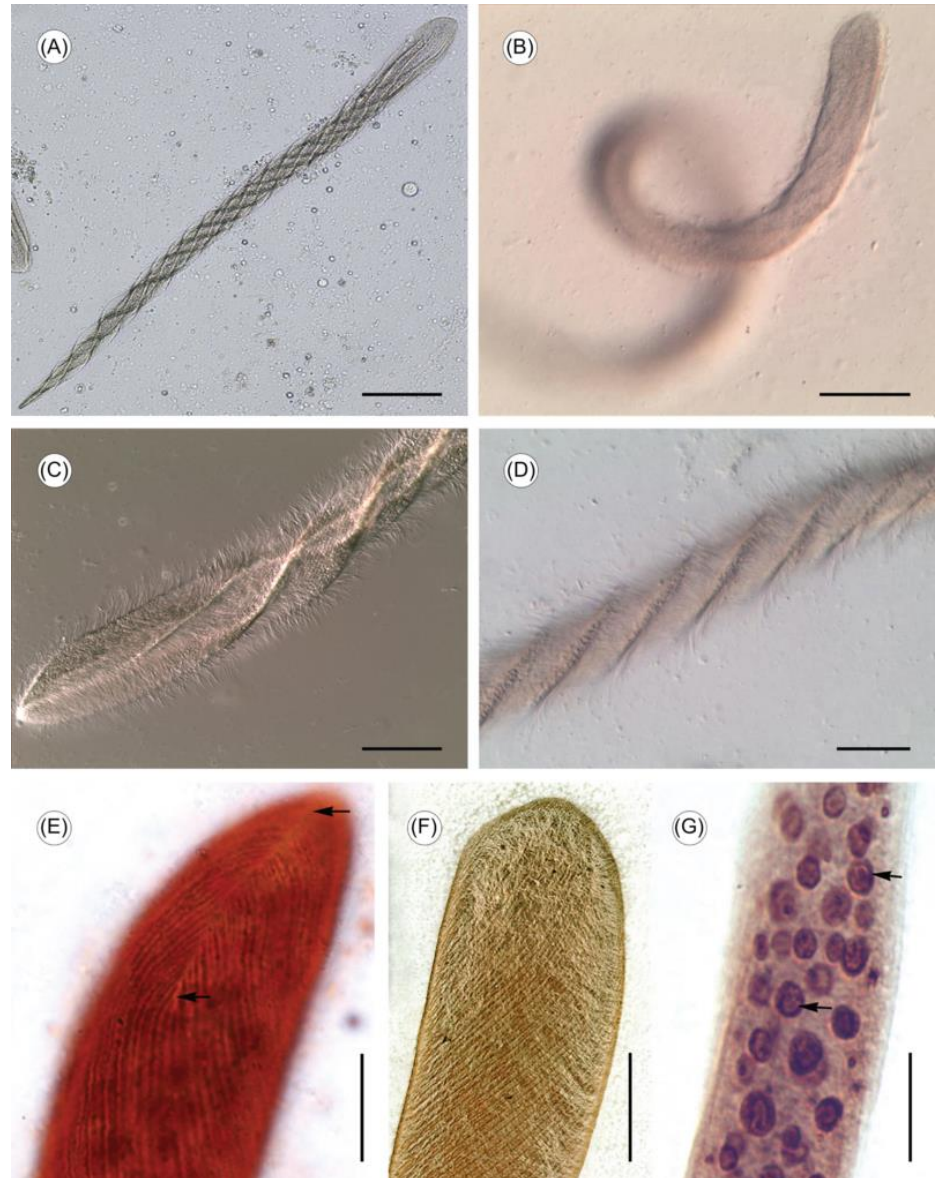
Fig. 1 Schematic drawings of four opalinid genera. Circles within the cells represent nuclei; the lines represent kineties (rows of flagella). Metachronal waves of beating flagella are symbolized by the waves at the periphery of the cells. The anterior part of cells with falx (bold line) points to the right. *Opalina* (a) is multinucleate, and its cell body is flat. The kineties run to the cell margin from where they continue on the other side (dotted lines). *Cepedea* (b) is also multinucleate, but its cell body is circular in cross section. *Zelleriella* (c) is binucleate with flat body, either caudate, as seen in the figure, or rounded posteriorly. *Protoopalina* (d) is a binucleate genus with cylindrical cells (Figure from Corliss (1989))

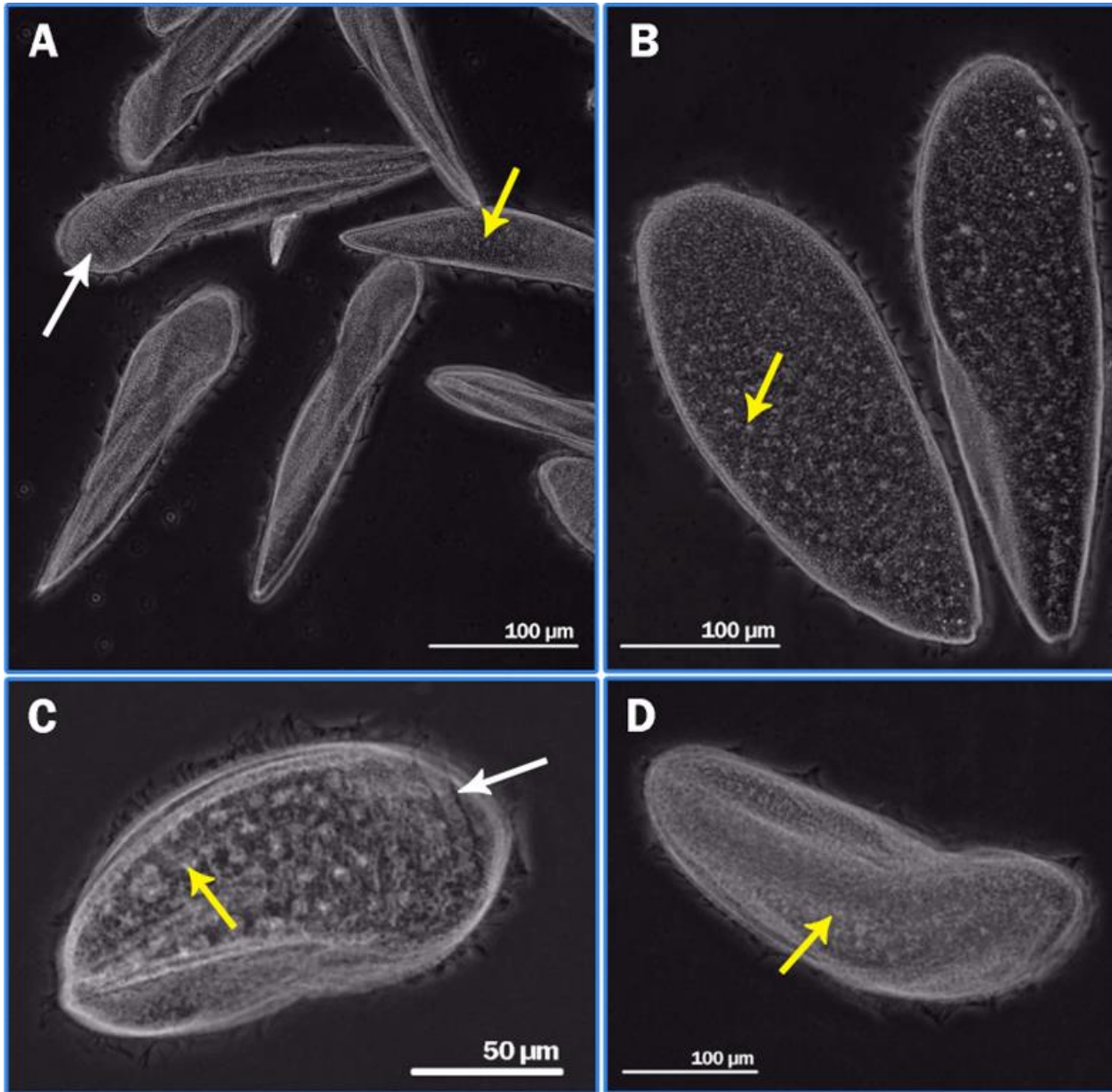
Opalina ranarum

- model organism

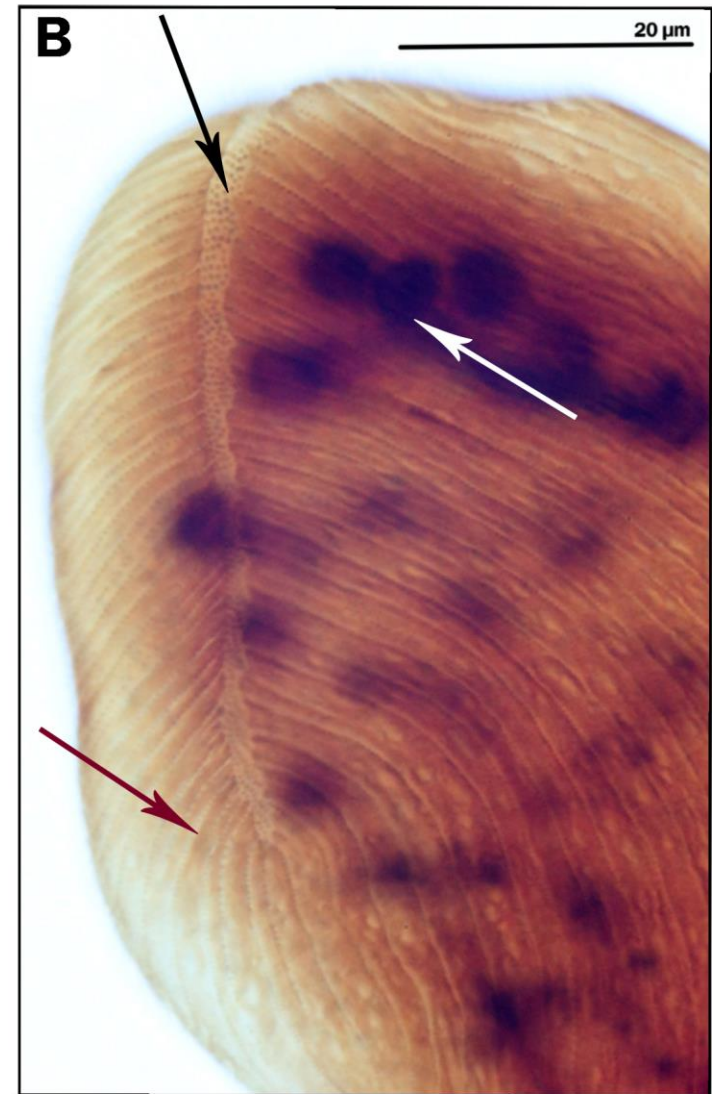
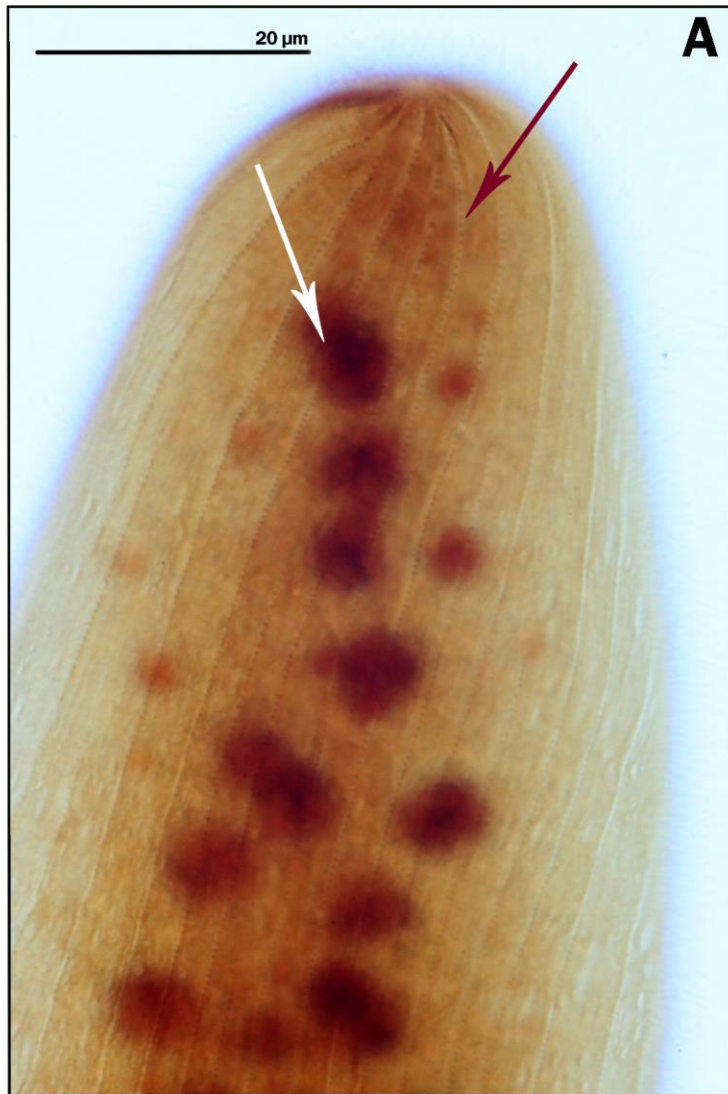


Cepedea longa

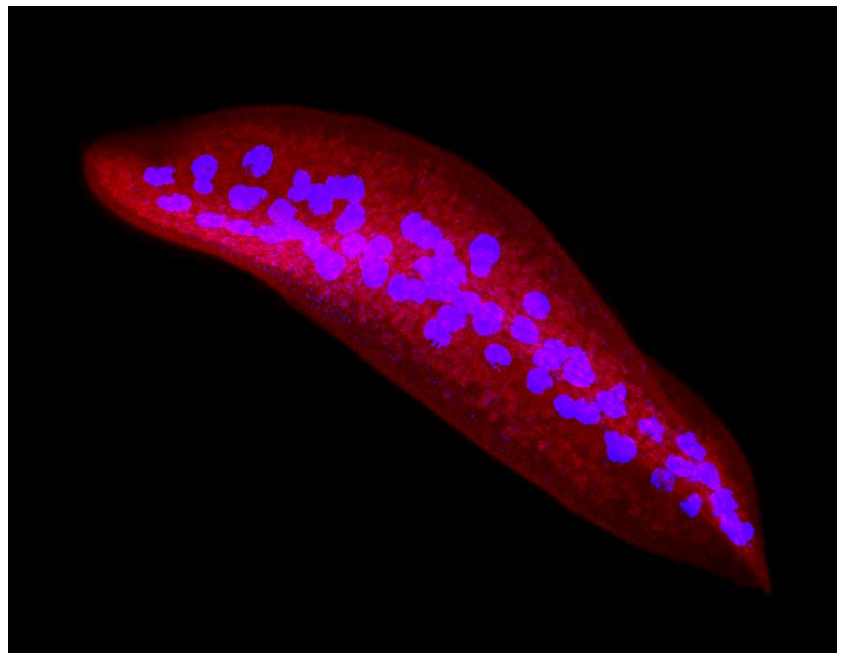
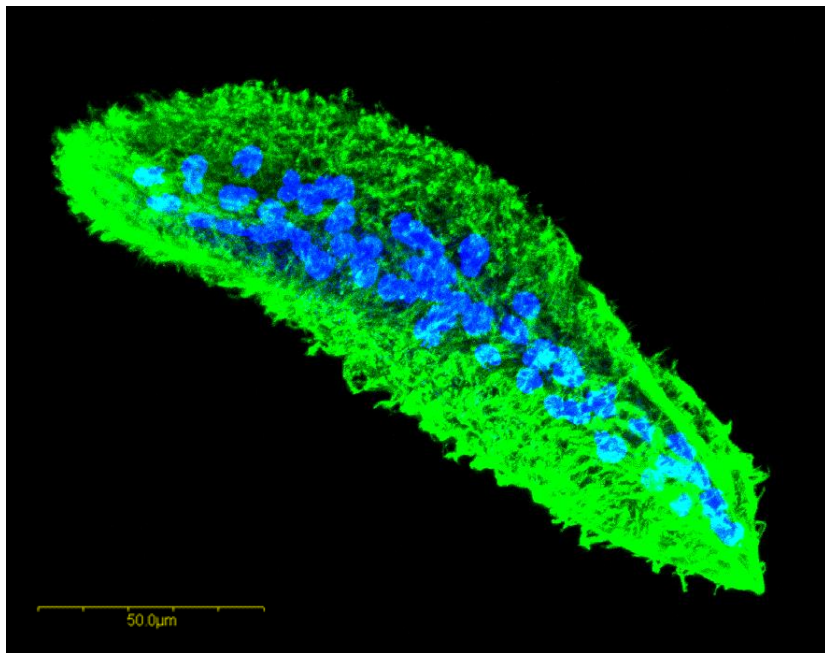
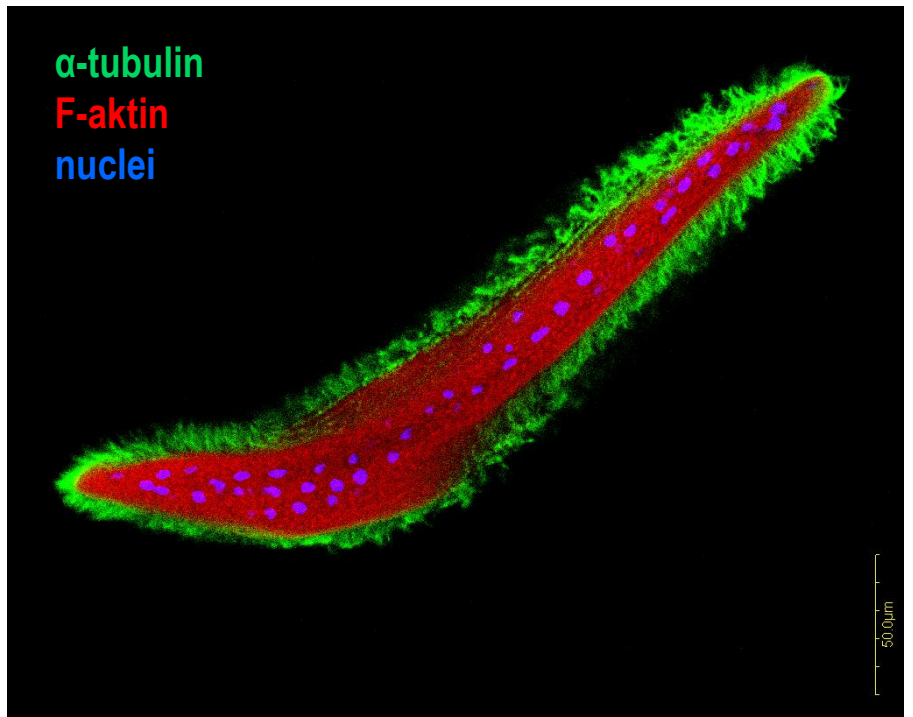
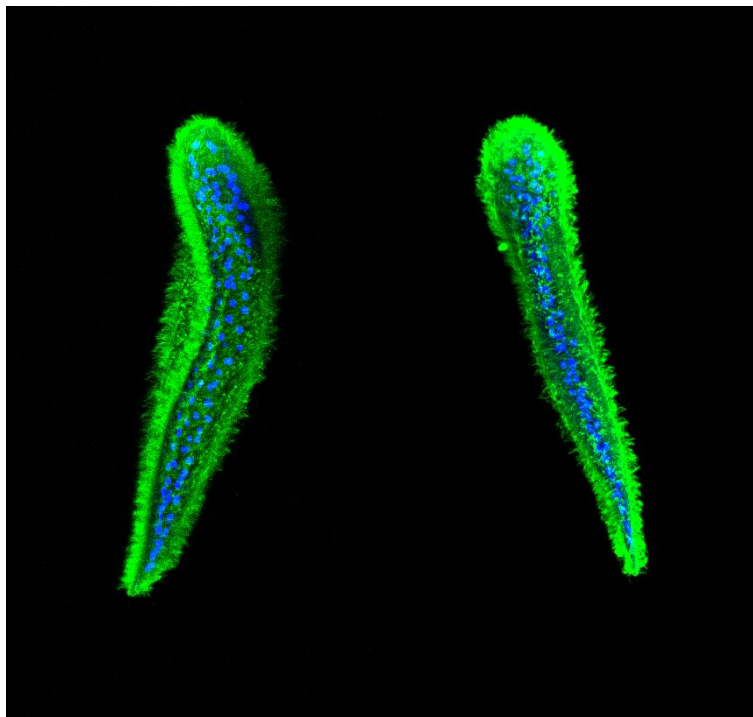


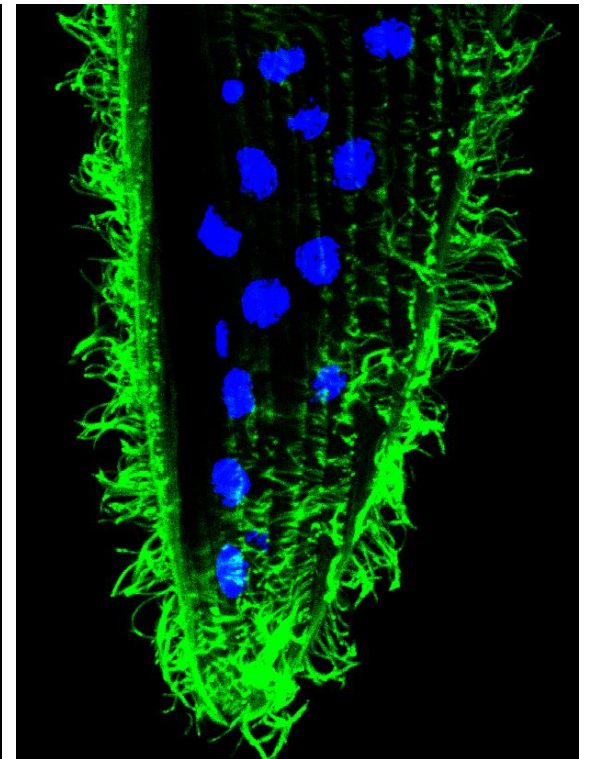
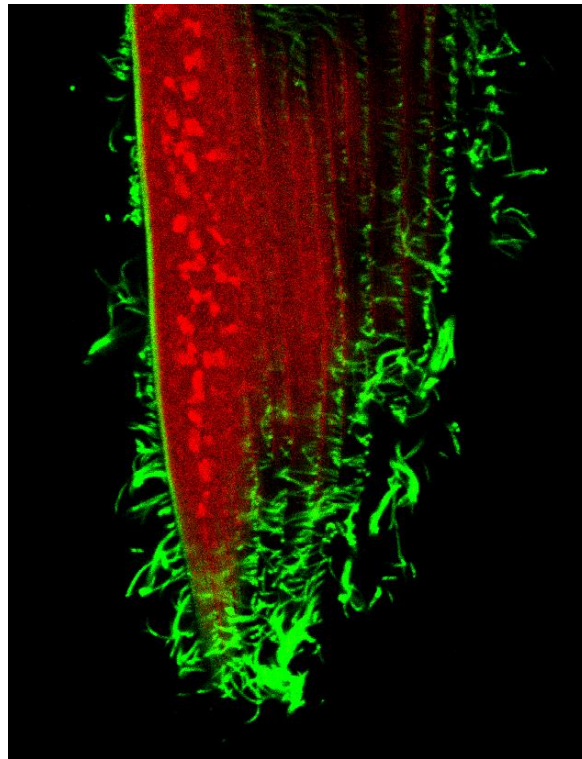
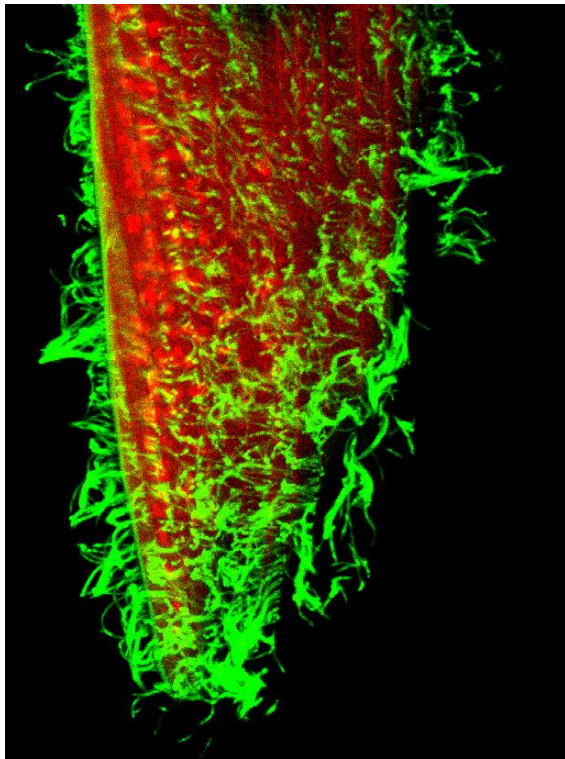
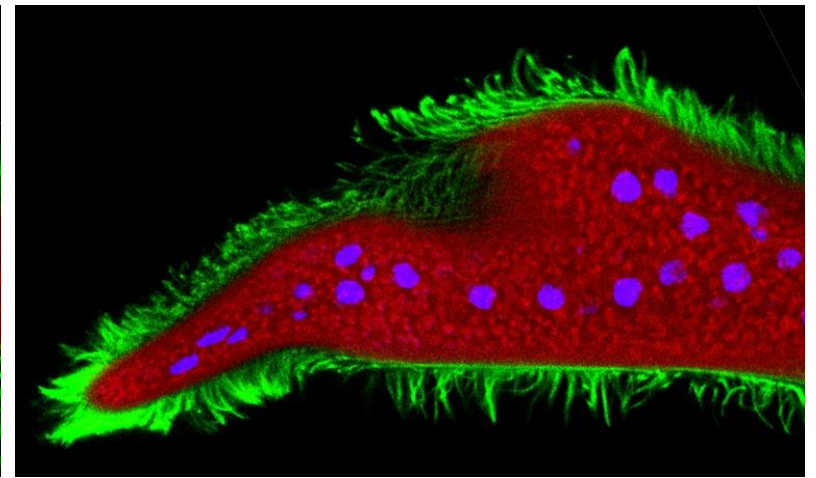
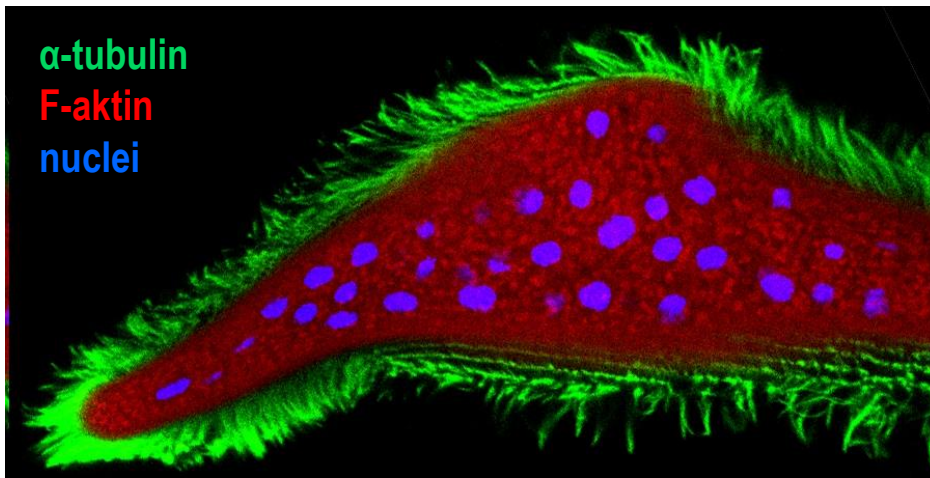


A) *Copepoda* trophonts; **B)** *Opalina* (left) and *Copepoda* (right) trophonts; **C)** putative protrophont of *Copepoda*; **D)** *Copepoda* trophont
white arrow - direction of movement of metachronal waves, *yellow arrow* - nuclei



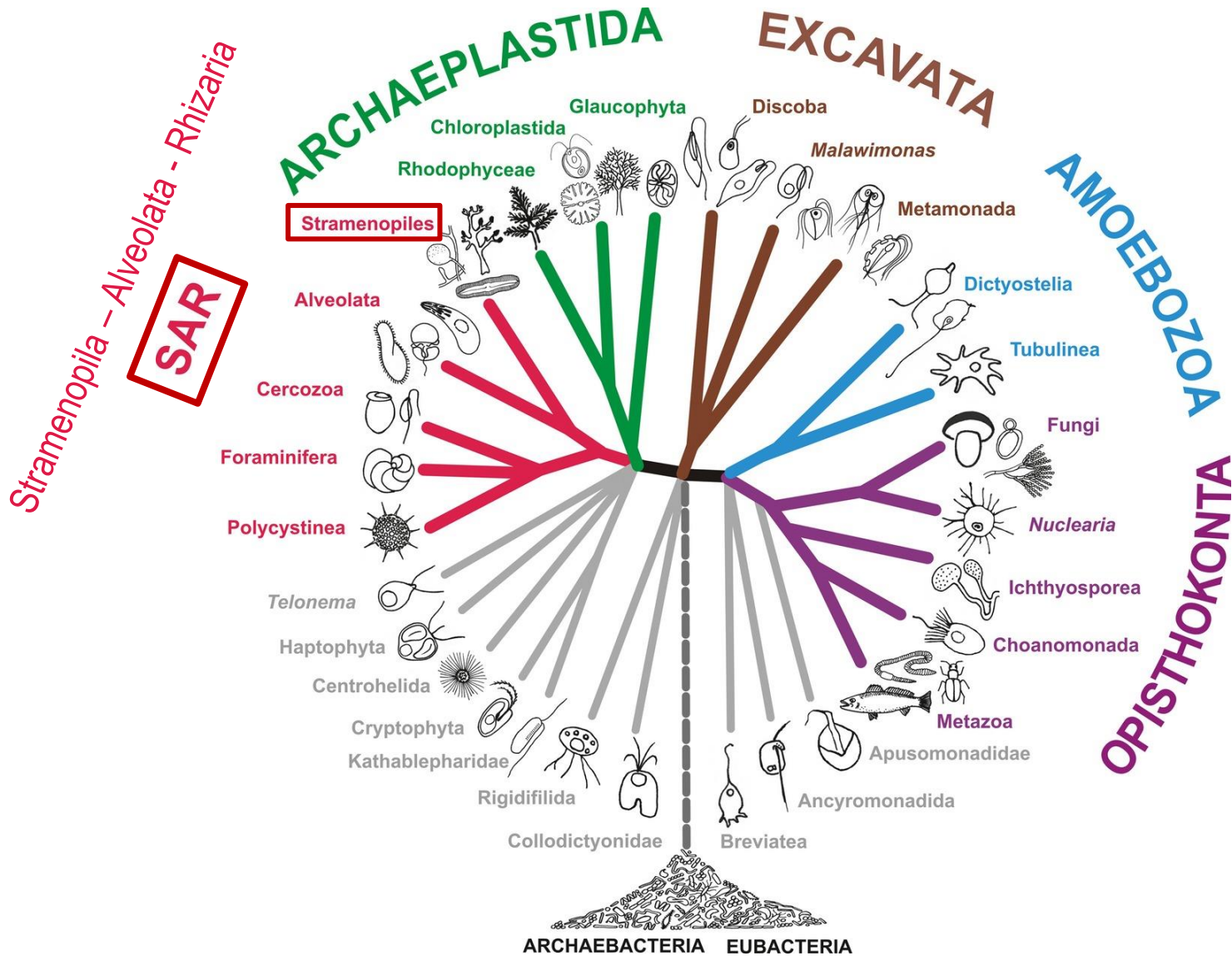
white arrow - nuclei, **red arrow** - basal bodies with flagella arranged in oblique rows,
black arrow - falx (3-4 basal bodies visible in one row = *Cepedea*)





- **α-tubulin immunolabeling**: strong signal in the flagella and area of the pellicle between individual rows of flagella
- longitudinal folds between the rows of flagella are supported by bands of **microtubules**
- rows of flagella supported on the left side by a strip of **microfilaments (F-actin)**

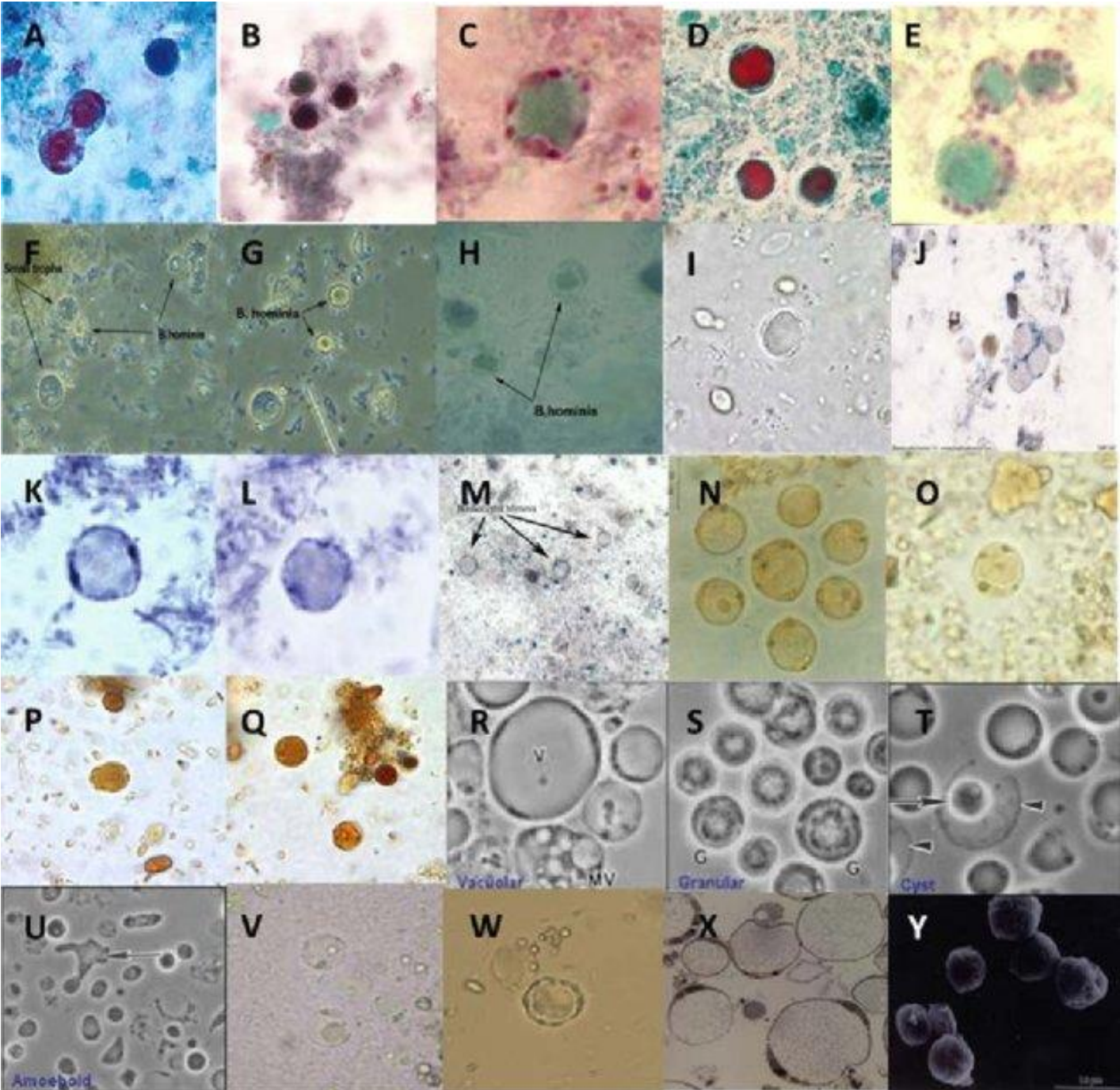
5 supergroups = megagroups



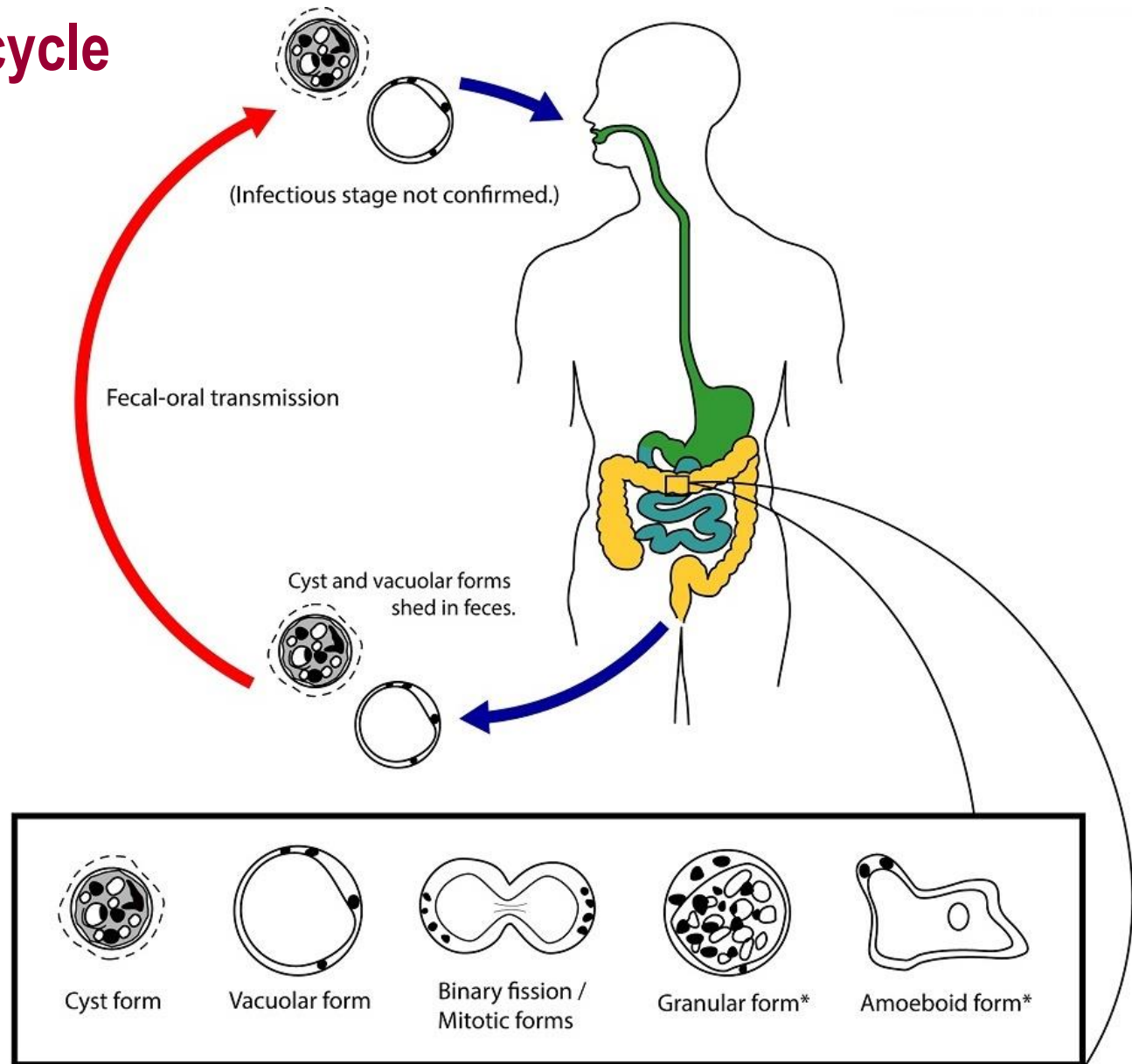
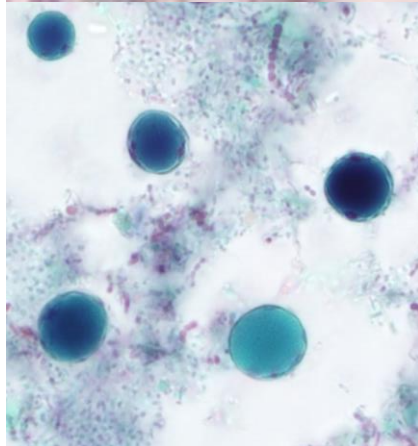
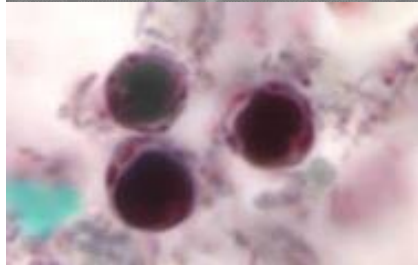
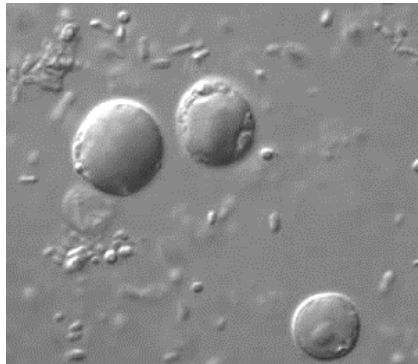
genus *Blastocystis*

- single genus belonging to extremely diverse (genetically and phenotypically) group of Stramenopiles
- no flagella, usually observed in the form of spherical cells with huge vacuoles
- quite common in the intestines of many vertebrates (including humans) and invertebrates
- classic form found in human stools is the cyst with 6-40 μm in diameter
- potentially associated with human intestinal pathology (usually referred to as *B. hominis*), in some cases also with skin problems such as urticaria – but clinical significance of *Blastocystis* is unclear
- often connected with irritable bowel syndrome and other gastrointestinal symptoms – not clear whether *Blastocystis* can cause these disorders or is just more efficient in colonisation of the altered environment of unhealthy intestine
- more complicated by the fact that *Blastocystis* genetically very variable (some subtypes are more pathogenic than other ones) - based on analysis of ribosomal genes 17 subtypes (subtypes arguably represent separate species) were identified \Rightarrow 9 in humans
- detected in both symptomatic and asymptomatic persons
- no effective therapeutic strategy

Blastocystis spp.

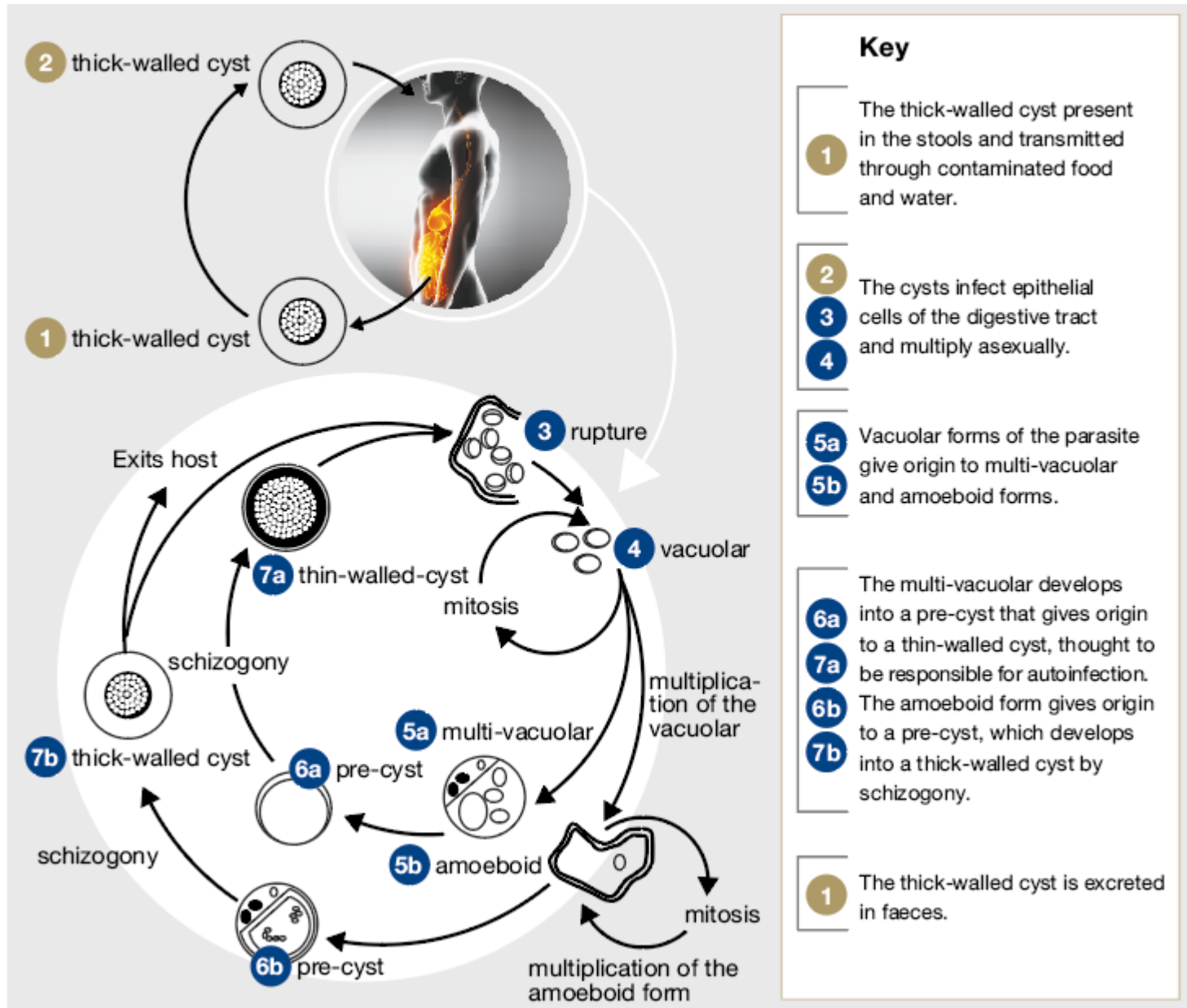


Blastocystis life cycle

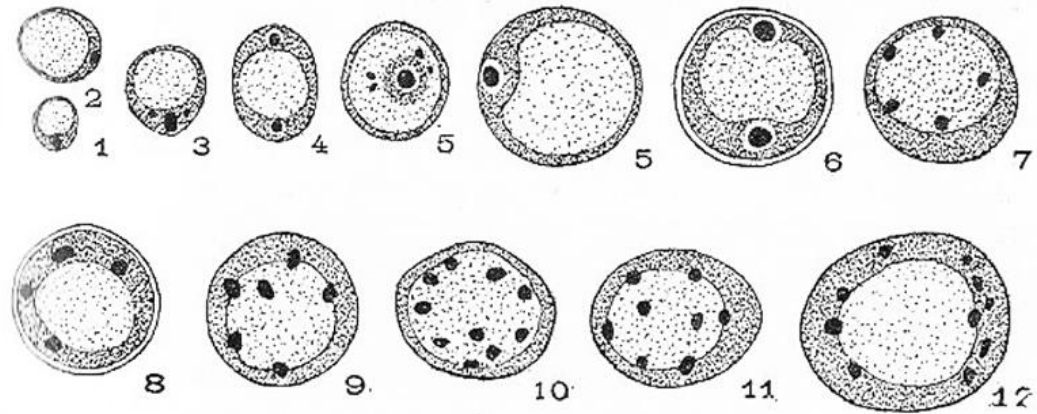


*Various forms that may occasionally be seen in human stool samples and in culture. Their biological significance is not well understood.

Blastocystis life cycle



Morphological forms of *Blastocystis*

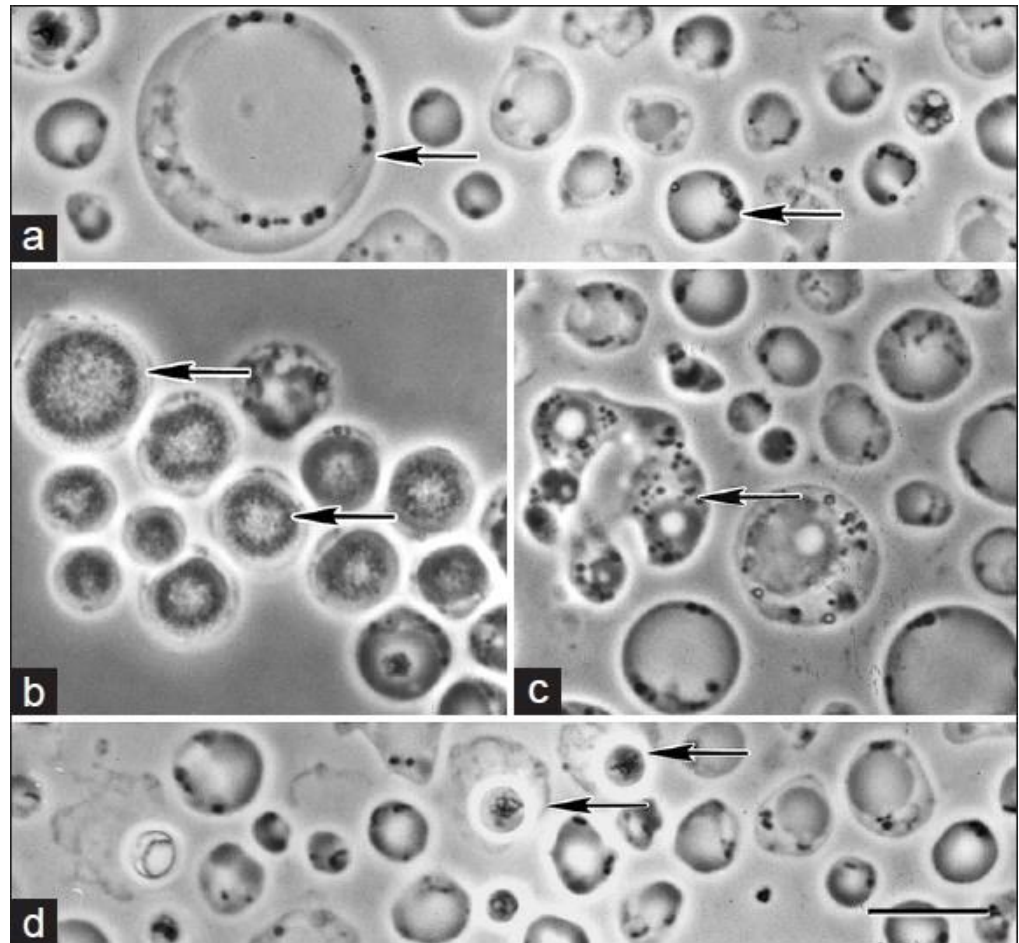


A) **Vacuolar forms** of *Blastocystis* with large centrally placed vacuole that shows extensive variation in size (arrows).

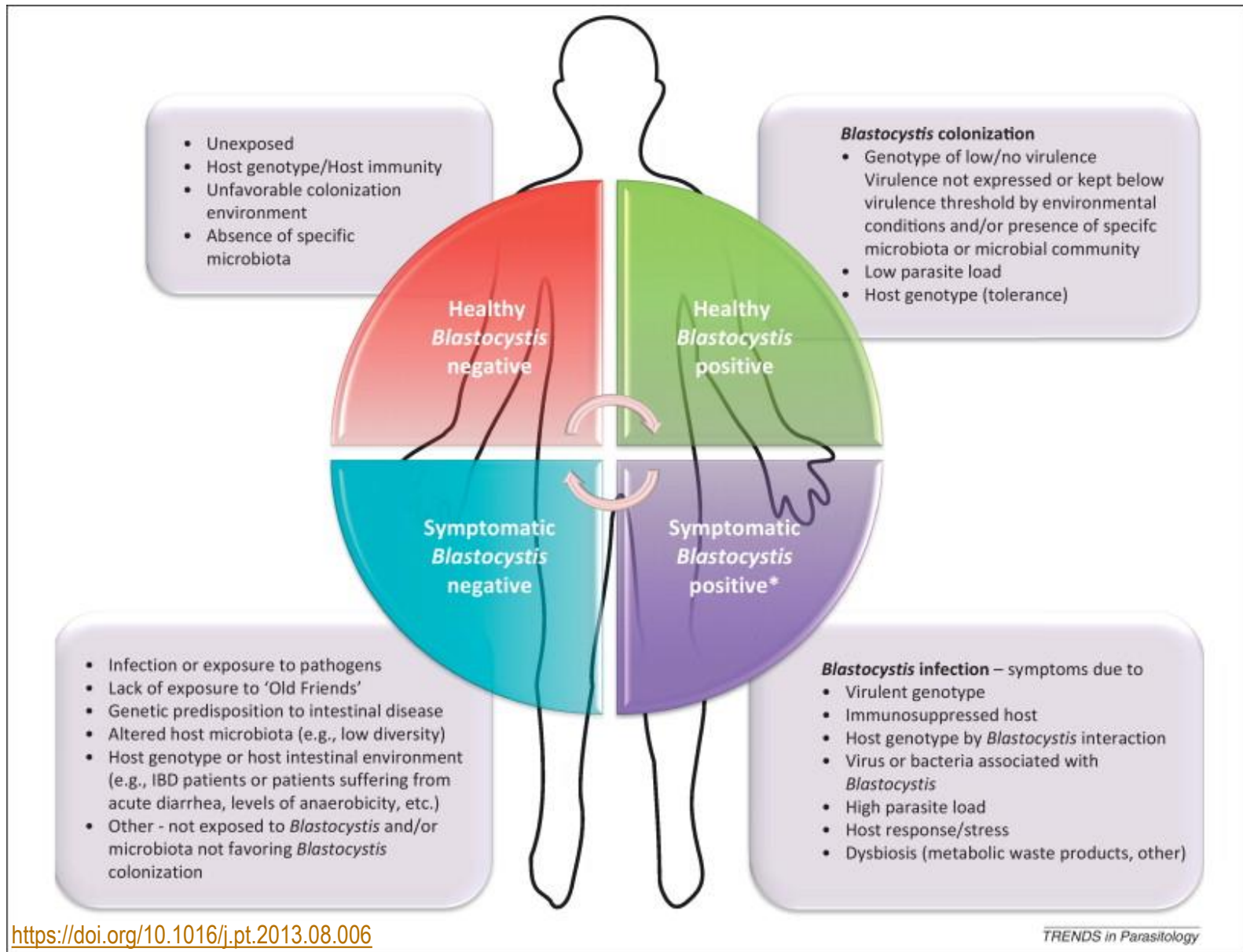
B) **Granular forms** with distinct granules filling the central body.

C) **Amoeboid form** with characteristic pseudopodia.

D) **Cyst forms**. Note the smaller size and the characteristic refractile cyst wall surrounded by loose irregular outer coat.



Possible interactions and explanations for *Blastocystis* carriage and symptomatic status of the host



RESEARCH

Open Access



Higher amoebic and metronidazole resistant forms of *Blastocystis* sp. seen in schizophrenic patients

Freddy Franklin^{1,2}, Arutchelvan Rajamanikam^{1,2}, Chandramathi Samudi Raju², Jesjeet Singh Gill³, Benedict Francis³, Luke Woon Sy-Cherng⁴ and Suresh Kumar^{1*}

Abstract

Background: *Blastocystis* sp. is one of the most common colonisers of the intestinal tract that demonstrate strong interaction with accompanying gut bacteria. Previously, the protozoan isolated from individuals with irritable bowel syndrome (IBS) showed altered phenotypic features suggesting that it can be triggered to become pathogenic. Previous studies reported altered gut microbiota and high prevalence of *Blastocystis* sp. in schizophrenia patients. However, the phenotypic characteristics of *Blastocystis* sp. isolated from individuals with SZ have yet to be described.

Methods: In this study, faecal samples from 50 patients with severe schizophrenia (SZ) and 100 non-schizophrenic (NS) individuals were screened for *Blastocystis* sp. infection. Positive isolates were subjected to genotypic and phenotypic characterization.

Results: We found that 12 out of 50 (24%) SZ and 5 out of 100 (5%) NS individuals were detected *Blastocystis* sp. positive using both in vitro culture and PCR method with no significant association to age and gender. Out of the 15 sequenced isolates, ST3 was the most prevalent subtype (66.7%) followed by ST1 (20%) and ST6 (13.3%). The isolates from SZ individuals demonstrated significant slower growth rate (34.9 ± 15.6 h) and larger range of cell diameter (3.3–140 μ m). We detected higher amoebic forms and metronidazole resistance among SZ isolates with variation in cell surface glycoprotein where 98% of cells from SZ showed consistent medium to high binding affinity (+2 to +3) to Concanavalin A staining compared to NS isolates that demonstrated only 76% high lectin (+3) binding affinity. Cysteine and serine protease levels were predominantly found among SZ isolates. We also demonstrate the presence of metalloprotease in *Blastocystis* sp. especially among NS isolates. Introduction of solubilised antigens from SZ isolates increased the cell proliferation of HCT116 cells by two fold when compared to NS isolates.

Conclusion: Our findings demonstrated *Blastocystis* sp. isolated from SZ individuals showed variation in phenotype specifically in morphology and drug resistance. The findings indicate that the gut environment (SZ and NS) and treatment of SZ could have influenced the phenotype of *Blastocystis* sp.

Keywords: *Blastocystis*, Schizophrenia, Amoebic, Metronidazole resistant

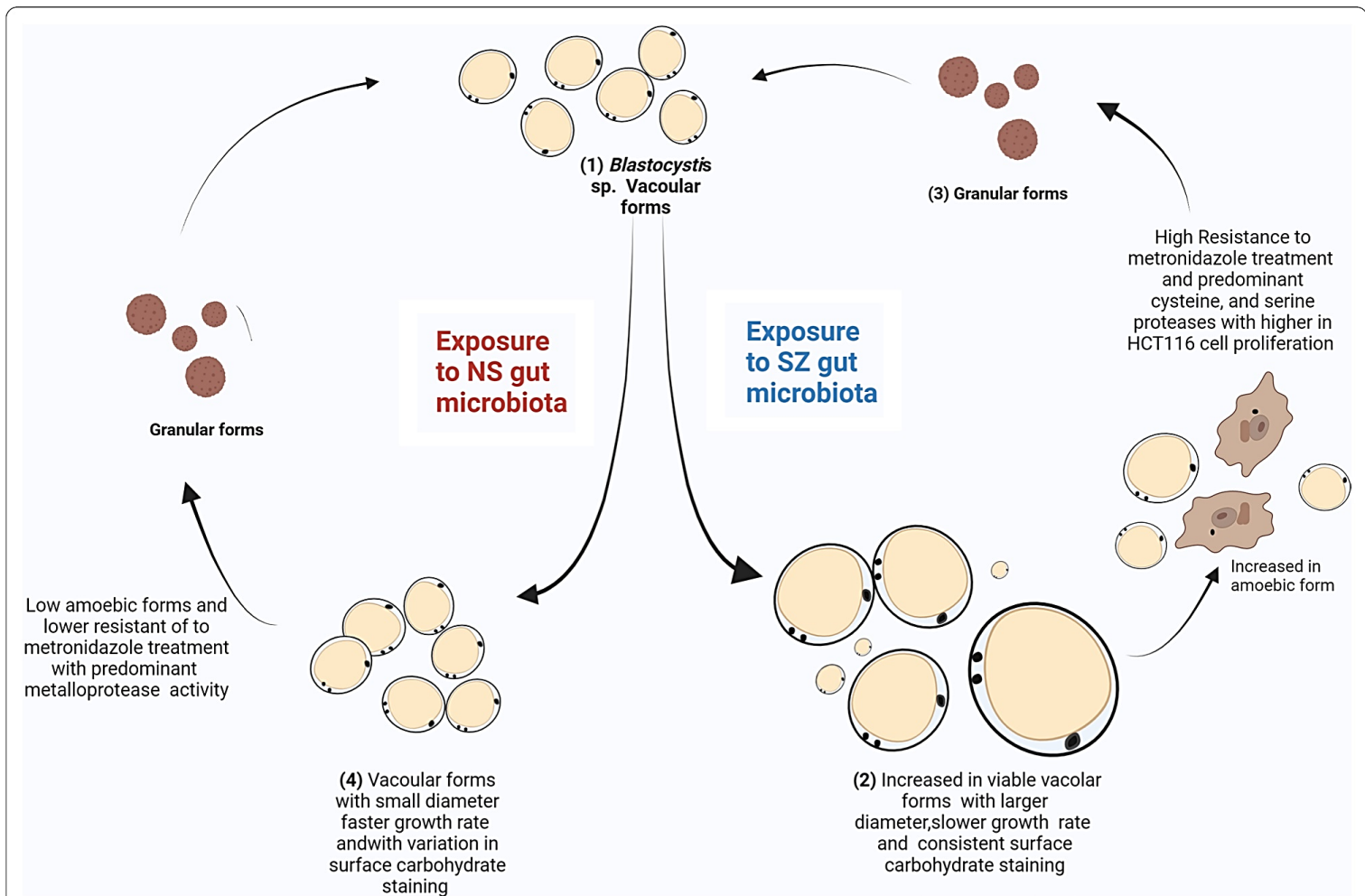
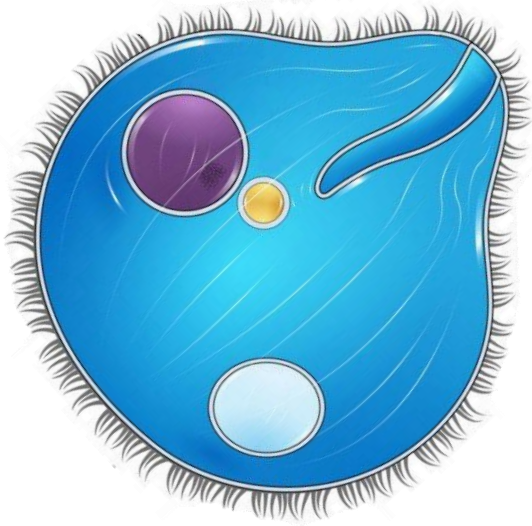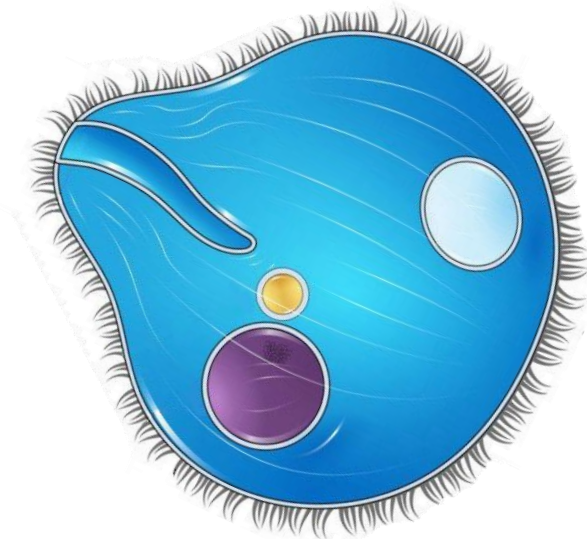


Fig. 8 Schematic diagram depicting the major findings in the current study. One of the critical findings in this study is that the life cycle and the morphology of *Blastocystis* sp. are host dependent and undergo alteration because of the host microenvironment such as the gut microbiota. (1) Exposure of the SZ gut microbiota causes an alteration in phenotypic characteristics of *Blastocystis* sp. such as increased parasite diameter up to 140 μm and longer average generation time of 34.9 ± 15.06 h. SZ isolates consistently showed a medium to high lectin staining indicating rough surface morphology. (2) There was also a significant increase in amoebic forms among SZ isolates, which resulted in higher resistance of metronidazole treatment with predominant cysteine and serine protease activity. The SZ isolates also demonstrated higher average cell proliferation of HCT116 cell line. (3) The resultant granular forms are more robust and produces more viable vacuolar forms of the parasite [100]. (4) The NS isolates exhibited higher growth rate (17.31 ± 5.4) with consistently smaller diameter ($34 \mu\text{m}$). NS isolates demonstrated variation in surface lectin staining (predominantly high with smaller percentage showing little to no fluorescence) and low amoebic forms. NS isolates also showed lower resistance towards metronidazole treatment with predominant metalloprotease activity and low proliferation of HCT166 cell line. SZ denotes individuals with schizophrenia whereas NS denotes non-schizophrenic individuals



Thank you for your attention 😊



Lectures

- ✓ Introduction: BPP 2022 I
- ✓ Euglenozoa (Excavata): BPP 2022 II
- ✓ Fornicata / Preaxostyla / Parabasala (Excavata): BPP 2022 III
- ✓ Apicomplexa I (SAR): BPP 2022 IV
- ✓ Apicomplexa II (SAR): BPP 2022 V
- ✓ Amoebae (Excavata, Amoebozoa): BPP 2022 VI
- ✓ Ciliophora, Opalinata (SAR): BPP 2022 VII

⇒ **Pneumocystis (Opisthokonta, Fungi): BPP 2022 VIII**

- Microsporidia (Opisthokonta, Fungi): **BPP 2022 IX**
- Myxozoa (Opisthokonta, Animalia): **BPP 2022 X**