


Author's Accepted Manuscript

Neural evidence for defective top-down control of visual processing in Parkinson's and Alzheimer's disease

Nemcova Elfmarkova Nela, Gajdos Martin, Rektorova Irena, Marecek Radek, Steven Z. Rapcsak



PII: S0028-3932(17)30366-4
DOI: <https://doi.org/10.1016/j.neuropsychologia.2017.09.034>
Reference: NSY6516

To appear in: *Neuropsychologia*

Received date: 29 January 2017
Revised date: 11 August 2017
Accepted date: 27 September 2017

Cite this article as: Nemcova Elfmarkova Nela, Gajdos Martin, Rektorova Irena, Marecek Radek and Steven Z. Rapcsak, Neural evidence for defective top-down control of visual processing in Parkinson's and Alzheimer's disease, *Neuropsychologia*, <https://doi.org/10.1016/j.neuropsychologia.2017.09.034>

This is a PDF file of an unedited manuscript that has been accepted for publication. As a service to our customers we are providing this early version of the manuscript. The manuscript will undergo copyediting, typesetting, and review of the resulting galley proof before it is published in its final citable form. Please note that during the production process errors may be discovered which could affect the content, and all legal disclaimers that apply to the journal pertain.

Neural evidence for defective top-down control of visual processing in Parkinson's and Alzheimer's disease

Nemcova Elfmarkova Nela^{a, b}, Gajdos Martin^a, Rektorova Irena^{a,b*}, Marecek Radek^{a,b}, Rapcsak Steven Z^c

^a Brain and Mind Research Programme, Central European Institute of Technology, CEITEC MU, Masaryk University, Brno, Czech Republic

^b First Department of Neurology, School of Medicine, Masaryk University and St. Anne's Hospital, Brno, Czech Republic

^c Department of Neurology, University of Arizona, Tucson, AZ, USA.

***Correspondence to:** Professor Irena Rektorova, MD, PhD. First Department of Neurology, Faculty of Medicine, Applied Neuroscience Research Group, CEITEC, Masaryk University, Kamenice 5, 625 00 Brno. Tel.: +420 54318 2623. irena.rektorova@fnusa.cz

Abstract

Introduction

We used a functional MRI paradigm involving conventional vs. unconventional views of objects to assess bottom-up vs. top-down visual processing in Parkinson's disease (PD) with normal cognition, PD with mild cognitive impairment (MCI), and MCI due to Alzheimer's disease (AD) as compared to healthy controls. We particularly aimed at determining whether the task discriminated between PD with and without MCI and between two MCI groups due to distinct pathologies (AD and PD).

Methods

116 right-handed subjects (21 MCI due to AD; 16 PD with normal cognition; 24 PD with MCI; 55 healthy controls) performed a visual object-matching task in a 3T MR scanner. T statistic maps were computed to contrast task-based activation during unconventional vs. conventional view conditions. One-way ANOVAs and post hoc tests were performed to assess differences across and between groups.

Results

Both MCI groups performed worse than controls in the unconventional views condition and showed reduced activation of right anterior cingulate cortex and right superior parietal lobule (PD with MCI), and right middle and inferior frontal gyri (MCI due to AD). Neural responses in cortical areas within the ventral and dorsal visual pathway appeared to be preserved in both MCI groups. Receiver operating characteristic analysis of MRI contrast in the right superior parietal lobule distinguished PD with and without MCI with 87.50% sensitivity and 86.98% specificity.

Conclusions

Impaired recognition of objects presented in unconventional orientations in MCI due to PD and AD was associated with decreased activation of frontoparietal regions, consistent with defective top-down regulation of visual processing. Aberrant activation of superior parietal cortex may serve as an early imaging biomarker of impending cognitive impairment in PD.

Keywords

Parkinson' s disease; Alzheimer' s disease; mild cognitive impairment; fMRI; top-down visual processing.

1. Introduction

Contemporary neuroscience models of visual cognition postulate the existence of two processing streams (Ungerleider Leslie & Mortimer, 1982) that originate in primary visual cortex (V1) (Ungerleider & Haxby, 1994). The ‘what’ or ventral stream located within temporo-occipital cortex is important for identification of objects, whereas the ‘where’ or ‘how’ dorsal stream projects to parietal cortex and is implicated in visuospatial functions including the processing of information about object orientation critical for visually guided actions (Creem & Proffitt, 2001; Goodale & Milner, 1992; Ungerleider Leslie & Mortimer, 1982; Ungerleider & Haxby, 1994; Valyear, Culham, Sharif, Westwood, & Goodale, 2006). Consistent with the dual pathway model, some authors have described a behavioural double dissociation between object identity and object orientation judgments in patients with damage to the ventral vs. dorsal visual streams (Turnbull, 1997; Valyear et al., 2006). Similarly, some fMRI studies in normal subjects have reported selective activation of the ventral vs. dorsal pathways when objects were presented in conventional vs. unconventional orientations (Valyear et al., 2006). By contrast, a number of imaging studies have reported the engagement of both ventral and dorsal pathways during object identity and orientation judgments (Altmann, Grodd, Kourtzi, Bulthoff, & Karnath, 2005; Ganis, Schendan, & Kosslyn, 2007; Grill-Spector, Kourtzi, & Kanwisher, 2001; Schendan & Stem, 2007; Schendan & Stern, 2008). It has also been shown that, in addition to bottom-up processing of visual information by the ventral and dorsal pathways, presenting objects in unconventional orientations engages frontoparietal cortical networks implicated in top-down attention and executive control

functions (Ganis et al., 2007; Kosslyn et al., 1994; Schendan & Stem, 2007; Schendan & Stern, 2008).

Identification of objects from unconventional views and mental rotation have also been used to assess the functional integrity of cortical visual pathways in neurodegenerative disorders, including mild cognitive impairment due to Alzheimer's disease (AD-MCI) (H. I. Jacobs, Van Boxtel, Jolles, Verhey, & Uylings, 2012; H. I. L. Jacobs et al., 2015), in preclinical individuals at-risk for AD (Yassa, Verduzco, Cristinzio, & Bassett, 2008), and in Parkinson's disease (PD) (Nombela et al., 2014; K. L. Possin, 2010; Uc et al., 2005). The authors used these specific cognitive tasks with an aim to test task-induced engagement of parietal cortices in both AD and PD because of the early involvement of these brain regions in both diseases (Bohnen, Kaufer, Ivanco, et al., 2003; Braak & Braak, 1996; Buckner et al., 2005; Garcia-Garcia et al., 2012; Hosokai et al., 2009; Huang et al., 2008; Huang et al., 2007; H. I. Jacobs et al., 2012; Liepelt et al., 2009; McKee et al., 2006; Pappata et al., 2011). These studies have found that MCI patients and subjects at-risk for AD performed as well as controls on these visuospatial tasks, but showed evidence of compensatory increases in activation and functional connectivity within components of the network activated in normal subjects, including both occipito-temporo-parietal visual areas and frontoparietal regions involved in attention and executive control. Only one study used functional imaging during a mental rotation task in PD (Nombela et al., 2014) and provided evidence of an association between defective mental rotation and reduced activation of left parietal cortex. However, no study exists that directly compares neural correlates of visual processing of objects from unconventional (spatially rotated) views in well-defined groups of patients with mild cognitive impairment (MCI) caused by different pathologies (AD, PD).

Therefore, in the present study we used an object matching fMRI task with objects presented in both conventional and unconventional views in order to assess engagement of brain areas involved in bottom-up and top-down visual processing in four groups of subjects: PD with normal cognition (PD-NC), PD with MCI (PD-MCI), MCI due to AD (AD-MCI), and age-matched healthy controls (HC). We particularly aimed at determining whether the task discriminated between 1. PD-NC and PD-MCI, and 2. MCI groups caused by distinct pathologies (AD, PD). We predicted that behavioural deficits on our visual object-matching task in patient groups will be associated with abnormal neural activation and that identifying the specific brain regions involved will provide useful information about possible underlying cognitive mechanisms in both MCI groups.

2. Materials and Methods

2.1. Subjects

116 right-handed subjects (21 AD-MCI; 16 PD-NC; 24 PD-MCI, and 55 HC) performed a visual object-matching task in a 3T MR scanner (for demographic data, see Table 1). AD-MCI, PD-NC and PD-MCI patients were recruited and longitudinally followed at the First Department of Neurology, St. Anne's University Hospital in Brno, Czech Republic. They were matched with 55 HC subjects in age, sex, and education. We classified participants into PD-NC, PD-MCI, AD-MCI and HC groups according to published criteria (Albert et al., 2011; Litvan et al., 2012; Ward & Gibb, 1990) based on clinical assessment, interview with the patients and their caregivers, brain MRI, and a detailed cognitive assessment using a comprehensive neuropsychological battery. The AD-MCI cohort included non-demented individuals with some concerns about cognitive decline, objective impairment in episodic memory or in multiple cognitive domains in addition to memory >1.5 SD below the mean for their age and education matched peers, and preserved independent functioning (Albert et al.,

2011). PD-MCI was defined as a cognitive decline with a performance >1.5 SD below the mean for age- and education-matched control population on two or more tests from the neuropsychological battery (Berankova D, 2015) in patients already diagnosed with PD. This is in accordance with level 1 (comprehensive) MDS criteria for diagnosis of PD-MCI (Litvan et al., 2012). PD-NC patients performed as well as HC on all cognitive measures. All of the assessments in PD subjects were conducted in the “on” state on dopaminergic medication.

None of the subjects had a current depressive episode or any major psychiatric disease. Exclusion criteria included a history of any illness affecting the central nervous system (other than AD-MCI and PD-NC/PD-MCI), substance abuse, and ferromagnetic metal in the body. None of the PD subjects underwent deep brain stimulation surgery. Visual acuity and colour perception were assessed prior to the study entry in all subjects. Ironless glasses were used inside the scanner in those subjects who needed visual acuity correction. The study was approved by the local ethics committee, and all of the patients signed an informed consent form.

2.2. Neuropsychological and motor assessment

All participants underwent a neuropsychological examination using a comprehensive cognitive battery evaluating attention, executive function, memory, visuospatial function and language (Berankova D, 2015), see Suppl. material for detailed description. Composite cognitive domains' z-scores were calculated for each subject (Aarsland et al., 2010). Activities of daily living were assessed by Functional Activities Questionnaire (FAQ-CZ) (Bartoš, Martínek, Bezdíček, Buček, & Řípová, 2008) and depression by the Geriatric Depression Scale (GDS) (Yesavage & Sheikh, 1986).

The definition of cognitive impairment was based on performance on individual tests in one or more cognitive domains (Albert et al., 2011; Litvan et al., 2012). All PD patients were

examined by the Unified Parkinson's Disease Rating Scale (UPDRS) III Motor Examination scores in the "on" dopaminergic state (Fahn S, 1987).

2.3. Procedure

The visual cognitive task consisted of 60 pairs of emotionally neutral images of common objects (30 pairs of conventional view images, 30 pairs of unconventional view - spatially rotated, i.e. with one image of the object pair presented in an unconventional rotation, see Figure 1, lines 3 and 4) and 30 pairs of dots with a symbol placed on the right or left side (a control task). Each event type comprised the following sequence: a mask stimulus (1 s), followed by the picture of the first object (1 s), followed by a mask (1 s), followed by the picture of the second object (1 s), followed by a mask (1 s), ending with a fixation cross (5 s). Participants viewed successive paired images. The second image of each pair was either: same (identical) as the first image (conventional condition 1); different in identity (conventional condition 2); same as the first image but spatially rotated (unconventional condition 3); different in identity and spatially rotated (unconventional condition 4).

Each of the event types (conventional 1 and 2, unconventional condition 3 and 4, control task for left and right side) occurred fifteen times during a protocol. Participants were instructed to respond as quickly as possible by pressing a YES (left) button if the second object of the paired images was the same as the first object (regardless of spatial orientation) or by pressing NO (right) button if they were different. In the control task participants responded with buttons depending on the side of a dot symbol placement, see Figure 1. Conditions were randomly intermixed. The number of correct responses was an outcome measure.

All subjects performed a visual object-matching task in a 3T MR scanner and they underwent training of the task before they were scanned. Only subjects who understood the commands

and successfully completed at least 5 consecutive trials during the training period were eligible for the study.

The behavioural data from visual task were analyzed using Kruskal–Wallis one-way analysis of variance. Non-parametric post hoc tests (multiple comparisons of means) were used to specify between-groups differences.

2.4. MRI data acquisition and preprocessing

We acquired 435 scans of task fMRI scans using gradient-echo echo-planar imaging sequence: TR = 2.080 ms, TE = 30 ms, FOV = 192 mm, flip angle = 90°, matrix size 64 x 64, slice thickness = 3 mm, 39 transversal slices followed by high-resolution anatomical T1-weighted images using MPRAGE sequence with 240 sagittal slices, TR = 2300 ms, TE = 2.36 ms, FOV= 256 mm, flip angle = 8°, matrix size 256×256, slice thickness = 1 mm,. Images were acquired for each subject using the 3.0T Siemens Prisma MR machine.

The SPM12 (Ashburner 2012) running under Matlab 8.2 (Mathworks Inc., USA) was used to analyze fMRI data. The preprocessing consisted of realignment and unwarping of functional scans, normalization to fit a standard anatomical space (MNI) (Talairach and Tournoux 1988; Mazziotta et al. 2001; Lancaster et al. 2007) and spatial smoothing using a Gaussian filter with a full width at half maximum of 5 mm. The SPM12 with DARTEL toolbox was also used for segmentation of T1 images and for voxel based morphometry (VBM).

2.5. MRI data analysis

The effect of stimulation was computed using a general linear model as implemented in SPM12. The experimental stimulation time course was convolved with a canonical hemodynamic response function. Six movement regressors (obtained during realignment and

unwarping of functional scans) were used as nuisance regressors; t statistic maps were computed to assess the effects of activation or deactivation with respect to the conventional view task, unconventional view task and control conditions. Corresponding contrast files were then used in the second-level random effect analyses to assess differences across the groups (one-way ANOVA) within two different cohorts: 1. HC, PD-NC, and PD-MCI to allow comparisons of PD patients with and without cognitive impairment and 2. HC, AD-MCI, and PD-MCI to compare groups with cognitive impairment attributable to different brain pathologies. Age, gender, brain atrophy and education were used as covariates. Brain atrophy was estimated as ratio of gray matter volume (GMV) to total intracranial volume (TIV), where TIV was computed as sum of GMV, white matter volume and cerebrospinal fluid. Group results were assessed using cluster level inference at p (FWE) < 0.05 at a height threshold of p (uncor) < 0.001 . Post-hoc t-tests were used to specify between-groups differences.

We also performed voxel-based morphometry (VBM) from T1 (MPRAGE) sequences (Rektorova, Krajcovicova, Marecek, Novakova, & Mikl, 2014) to assess gray matter atrophy in the HC, PD-NC, PD-MCI and in the HC, AD-MCI and PD-MCI cohorts.

The ROC analysis was used to classify specific groups of subjects based on fMRI contrasts in regions of between-groups differences. The leave-one-out cross-validation (LOOCV) technique was used to avoid biased results (Gengsheng & Hotilovac, 2008; Hanley & McNeil, 1982).

Finally, in order to interpret fMRI contrast results in regions of between-groups differences we further performed correlation analyses between behavioural and fMRI results within relevant groups of subjects using Spearman correlation analyses.

3. Results

3.1. Demographics, clinical status, and cognitive assessment

Demographic and clinical variables for all groups are shown in Table 1. Patients with PD were on levodopa \pm dopamine agonist \pm COMT (catechol-O-methyltransferase) inhibitor. All PD patients had bilateral parkinsonism. Nine PD-NC patients had left-sided and seven had right-sided symptoms dominance. Eight out of the PD-MCI participants had left-sided, and 16 had right-sided parkinsonian symptoms dominance. None of the subjects from PD-NC, PD-MCI, and AD-MCI groups were on antipsychotic medication and/or suffered from hallucinations, psychosis or major depression.

The AD-MCI group consisted of 57% single-domain amnesic MCI and 43% multiple-domain (amnesic plus) MCI. The PD-MCI group consisted of 50% single-domain MCI and 50% multiple-domain MCI (50% amnesic plus and 50% non-amnesic).

We found that the groups differed in age, the post-hoc t-test revealed that only AD-MCI were significantly older than PD-NC. AD-MCI and PD-MCI completed significantly fewer years of education than PD-NC. In HC and AD-MCI groups there were significantly more females than males, in PD-NC and PD-MCI there were significantly more males. The disease duration in AD-MCI (1.9 ± 1.1 years) was significantly shorter than in PD-NC (4.4 ± 2.5 years) and PD-MCI (5.5 ± 4.0 years). In global cognitive function, as assessed by MMSE, HC and PD-NC had significantly higher scores than AD-MCI and PD-MCI. The HC group performed significantly better in activities of daily living than AD-MCI and PD-MCI groups as assessed by FAQ-CZ, see also Table 1.

For comprehensive neuropsychological battery results in all groups, see supplementary material Table S1. Composite cognitive domains' z-scores and statistical differences between groups are displayed in Tables S2a-f in Supplementary material. There were significant differences ($p < 0.000$) in the attention and memory domain z-scores between AD-MCI and

HC, between PD-MCI and HC, and between PD-MCI and PD-NC. Regarding the executive functions domain z-score we found significant differences ($p < 0.000$) between AD-MCI and HC/PD-NC groups and between PD-MCI and HC/PD-NC groups. In visuospatial domain z-score the PD-MCI group differed significantly from the HC group ($p = 0.023$). In the language domain there were no significant differences among groups.

3.2. Performance on the visual object-matching task

The groups did not differ in either the conventional view task condition ($p = 0.080$) or in the control task condition ($p = 0.110$), for results in raw scores, see Table 2 for task accuracy. We found significant differences across groups only for the unconventional view task condition ($p = 0.007$). The post-hoc tests revealed that both AD-MCI and PD-MCI differed from HC ($p = 0.003$ and $p = 0.011$, respectively). Therefore, we used the unconventional vs. conventional view task conditions contrasts for the second-level (between groups) fMRI data analyses. Results for reaction times are displayed in Table S3 in Supplementary material. No significant differences across groups were found.

3.3. MRI results: structural

There were no significant differences in GMV across the two cohorts of interest as assessed by VBM (data not shown). However, direct pair-wise comparison between AD-MCI and HC revealed GMV decreases in the posterior cingulate cortex and precuneus in AD-MCI indicating the involvement of these early AD cortical signature regions (Dickerson et al., 2009); $p < 0.05$ (FWE corrected, cluster level), see Table S4 in Supplementary Material.

3.4. MRI results: functional

The results of the unconventional vs conventional view task contrast in the HC and patient groups are shown in Figure 2 and summarized in Tables S5a-d in Supplementary Material. Consistent with previous functional imaging studies (Ganis et al., 2007; Kosslyn et al., 1994; Schendan & Stem, 2007; Schendan & Stern, 2008), an unconventional views effect in HC was observed in object-sensitive visual areas within the ventral (temporo-occipital) and dorsal (occipito-parietal) pathways and in frontoparietal areas implicated in selective attention, working memory, and executive control including anterior cingulate cortex (ACC), anterior insula, inferior frontal gyrus (IFG), middle frontal gyrus (MFG), and superior and inferior parietal lobules (SPL, IPL, respectively) (Fedorenko, Duncan, & Kanwisher, 2013; Niendam et al., 2012; Spreng, Stevens, Chamberlain, Gilmore, & Schacter, 2010; Vincent, Kahn, Snyder, Raichle, & Buckner, 2008). Similar brain regions were engaged in the PD-NC group (though the clusters were smaller in size), see Figure 2 and Table S5b. In the PD-MCI group the unconventional vs conventional view task contrast revealed significant activations in bilateral inferior temporal gyri and inferior frontal and precentral gyri only, see Figure 2 and Table S5c. The AD-MCI subjects significantly engaged only temporo-occipital cortices, see Figure 2 and Table S5d.

In comparing the HC, PD-NC, and PD-MCI cohorts in the second level analysis, an ANOVA revealed significant differences in the right ACC ($p=0.000$) and right SPL ($p=0.007$) (results are shown in the Table 3a). Using a post-hoc t-test we found that PD-MCI and HC groups differed in activation of ACC (decreased in PD-MCI) while PD-MCI as compared to PD-NC showed significantly decreased activation of the right SPL ($p=0.004$), see Figure 3.

In the HC, AD-MCI and PD-MCI cohort comparison, an ANOVA revealed differences in the right MFG ($p=0.000$) and right IFG ($p=0.000$) (results of the analysis are summarized in the

Table 3b). Using the post-hoc t-test we found that only AD-MCI and HC groups differed in activation of the right MFG/ IFG which was decreased in the AD-MCI group ($p=0.014$), see Figure 3.

3.5. ROC analysis based on fMRI contrast in areas of specific between-groups differences

ROC analysis based on the fMRI contrast in the right MFG/IFG was significant for distinguishing AD-MCI from HC, $AUC=0.80$ (0.70-0.90). fMRI contrast in the ACC significantly differentiated PD-NC from PD-MCI, AUC 0.82 (0.67-0.96). The best result was achieved by ROC analysis of fMRI contrast in the right SPL which distinguished PD-MCI from PD-NC with 87.5% sensitivity and 86.98% specificity, $AUC=0.94$ (0.86-1.00), see Supplementary Figure S1.

The LOOCV technique based on contrast files for unconventional vs conventional view task conditions in the right SPL revealed a high sensitivity (86.7%) for distinguishing PD-MCI from PD-NC while specificity was also good (83.3%).

In order to interpret our fMRI results in MCI groups we performed correlation analyses between behavioural measures (task accuracy and reaction times) and relevant fMRI contrasts in our regions of interest (i.e. regions of significant between-groups differences) separately in the AD-MCI and PD-MCI groups. Detailed results are depicted in Tab S6a-d in Supplementary material.

In the PD-MCI group we found significant positive correlations between unconventional vs. conventional view task fMRI contrast of the right SPL and the unconventional view task accuracy ($R = 0.46$) as well as conventional view task accuracy ($R = 0.45$). The same fMRI

contrast in the right MFG was negatively correlated with reaction times of the unconventional view task only ($R = -0.44$). When the unconventional view task vs. control task fMRI contrast was taken into account we found significant correlation between ACC values and task accuracy of the unconventional task condition and between ACC values and reaction times of the conventional task, while MFG and IFG fMRI contrast values were related only to conventional view task accuracy, see Tab S6b in Supplementary material.

In the AD-MCI group we found significant negative correlation only between unconventional view task vs. control task fMRI contrast and reaction times in the right MFG for both conventional and unconventional tasks ($R = -0.57$ and $R = -0.61$, respectively).

4. Discussion

In this study we used an fMRI paradigm involving matching objects from conventional vs. unconventional views to investigate neural correlates of bottom-up vs. top-down visual processing in patients with neurodegenerative disorders. In our HC subjects the fMRI contrast of unconventional vs. conventional views tasks demonstrated increased recruitment of both domain-specific temporal-occipital/ventral pathway and occipito-parietal/dorsal pathway visual areas, as well as the engagement of domain-general frontoparietal regions implicated in top-down control of visual processing. These results are consistent with the notion that recognizing objects under impoverished or unfamiliar viewing conditions requires the engagement of an “object model verification process” (OMVP) (Ganis et al., 2007; Kosslyn et al., 1994; Schendan & Stern, 2007; Schendan & Stern, 2008). According to OMVP theory, the greater task difficulty associated with identifying objects from unconventional views is expected to produce increased activation of both domain-general frontoparietal networks involved in selective attention, working memory, and executive control (Ganis et al., 2007; Kosslyn et al., 1994; Lowe, 2000) and domain-specific regions within the dorsal and ventral

visual pathways. The enhanced recruitment of domain-specific regions occurs because the cognitive operations required for identifying objects presented in unconventional views are likely to involve mental rotation mediated by the dorsal pathway (Ganis et al., 2007; Kosslyn et al., 1994; Schendan & Stem, 2007; Schendan & Stern, 2008), as well as extensive search for stored memory representations of objects within the ventral pathway that provide the best match for the visual input. Therefore, an “unconventional views effect” in brain activation is observed both in domain-specific visual areas that represent structural information about objects and in domain-general frontoparietal attention and executive control networks.

Interestingly, in our cognitively impaired patients bottom-up processing within domain-specific visual areas was still preserved and was similar to that of HC. By contrast, both MCI groups showed decreased engagement of domain-general frontoparietal regions implicated in attention and executive control, including the right ACC, SPL (PD-MCI vs. HC and PD-NC, respectively) and right IFG/MFG (AD-MCI vs. HC), suggesting that the behavioural deficit was primarily attributable to defective top-down regulation of visual processing and subsequent failure of OMVP. The correlation analysis with behavioural results further supports this notion. Furthermore, these functional abnormalities preceded structural brain changes, as VBM demonstrated no significant frontoparietal cortical atrophy in patients compared to HC.

As for AD-MCI and subjects at-risk for AD, previous studies have shown *increased* activation and connectivity within domain-specific visual and domain-general frontoparietal regions during tasks involving recognition of objects from unconventional views (H. I. L. Jacobs et al., 2015) and mental rotation (H. I. Jacobs et al., 2012; Yassa et al., 2008) compared to HC. It is important to emphasize that the behavioural tasks of the abovementioned studies were slightly different from that in the current study. Moreover,

participants with presumed AD pathology in these studies still performed within normal range on the cognitive tasks, suggesting that increased engagement of domain-specific and domain-general regions probably reflected the neural correlates of successful compensation. In our AD-MCI patients reduced activation of domain-general frontoparietal regions was associated with a behavioural deficit on the unconventional views task providing evidence that compensatory mechanisms were no longer available. Taken together, there seems to be a continuum from compensatory increase in neural activation/connectivity in subjects at-risk for AD and AD-MCI with preserved task performance to decreased activation/connectivity in AD-MCI patients with a behavioural deficit indicating loss of neural capacity for compensation. Importantly, reduced neural activation was only observed in domain-general regions while recruitment of domain-specific regions within the ventral and dorsal visual pathways was still preserved in our AD-MCI group.

There was no significant difference in activation between AD-MCI and PD-MCI subjects suggesting that similar pathophysiological mechanisms (i.e. impaired recruitment of domain-general frontoparietal networks resulting in defective top-down control of visual processing) were responsible for the deficits in the unconventional views task in both patient groups despite distinct brain pathologies (although different network nodes were implicated in AD-MCI vs. PD-MCI compared to HC). The proposed breakdown of frontoparietal attention and control networks is also supported by the fact that both MCI groups showed significant impairments on standard neuropsychological tests of attention and executive function and calculated cognitive domain z-scores compared to HC (see supplementary material, Tab. S1 and S2a-f). Our results are consistent with other fMRI studies demonstrating decreased activation/connectivity within frontoparietal attention and executive control networks in amnesic AD-MCI as compared to HC (Neufang et al., 2011; Rombouts, Barkhof, Van Meel,

& Scheltens, 2002; Saykin et al., 2004; Sorg et al., 2007), and in PD-MCI as compared to PD-NC (Amboni et al., 2015; Baggio et al., 2015; Gratwicke, Jahanshahi, & Foltynie, 2015), and with cognitive studies demonstrating impaired top-down control of visual attention in PD (Tommasi et al., 2015) and in AD-MCI (Redel et al., 2012). While impaired attention, working memory capacity and executive function in PD-MCI have been mostly linked to fronto-striatal and mesocortical dopamine network deficits (Gratwicke et al., 2015, Cools et al., 2008), dementia in both AD and PD has been related to cholinergic network dysfunction (Ballinger, Ananth, Talmage, & Role, 2016; Bohnen et al., 2015; Bohnen et al., 2003; Francis, Palmer, Snape, & Wilcock, 1999; Hilker et al., 2005; Perez-Lloret & Barrantes, 2016). Of note, cholinergic afferents are relatively enriched in frontal cortices (Petrou et al., 2014) and prefrontal projections to the nucleus basalis of Meynert may modulate cholinergic inputs to sensory cortices and thus represent another component of the top-down frontoparietal attention network (Gratwicke et al., 2015) (in addition to direct projections from frontoparietal cortices to extrastriate visual areas). In line with this notion, treatment with a cholinesterase inhibitor (ChEI) led to increased activation in prefrontal regions and improved attention and working memory in both AD-MCI (Rombouts et al., 2002; Saykin et al., 2004) and PD-MCI (Katherine L. Possin et al., 2013). Pharmacological-fMRI-behavioural study using our fMRI paradigm might shed further light on pathophysiological mechanisms underlying the visual deficits demonstrated in both MCI groups and help determine whether similar interventions can improve top-down attentional control of visual processing.

Our PD-NC patients revealed no significant abnormalities of brain activation or impaired performance on the visual object-matching task compared to HC. When PD-MCI group was directly compared with HC and PD-NC using a post-hoc test, decreased activation of ACC and SPL was demonstrated in the PD-MCI group. The abnormal engagement of ACC in PD-

MCI and PD-dementia has been related to reduced dopaminergic function (Ito et al., 2002) and higher Lewy body densities (Kövari et al., 2003) and has been held responsible for poor performance of frontal executive tasks (Fera et al., 2007; Rosenberg-Katz et al., 2016).

In terms of SPL, our findings are consistent with the results of Nombela et al. (Nombela et al., 2014) who reported reduced engagement of SPL and precuneus during a mental rotation task in non-demented PD patients. Interestingly, our right SPL peak coordinate ($x = 21, y = -58, z = 61$) is very close to the coordinate (26, -53, 65) which was implicated in a mental rotation task and was associated with increasing angle of rotation (Gogos et al., 2010). However, we would like to point out that SPL is a critical node of the dorsal attention network (Corbetta & Shulman, 2002) and this region is consistently engaged when performing a variety of demanding visuospatial and visuoperceptual tasks requiring the deployment of selective attention (e.g., mental rotation, recognition of objects from unconventional views, identification of degraded objects or words, visual search (Cohen, Dehaene, Vinckier, Jobert, & Montavont, 2008; Ganis et al., 2007; Nee et al., 2013; Vandenberghe, Molenberghs, & Gillebert, 2012; Zacks, 2008). In line with these results our SPL peak coordinate was very similar to the coordinate of the SPL engaged in the dorsal attentional network (24, -56, 55) as described by Gao and Lin (2012) and depicted using rs-fMRI data and functional connectivity analysis. Moreover, we found significant robust correlations between the fMRI (unconventional vs. conventional task condition) contrast in SPL and our behavioural task accuracy for both unconventional and conventional view task conditions in the PD-MCI group suggesting that the SPL engagement was not specific just for our unconventional view task condition with one rotated object. Taken together, it seems that our SPL region is more likely involved in attention rather than just mental rotation, i.e. it is sensitive to task difficulty rather than task content. However, we have to acknowledge that our fMRI task design does

not enable to fully distinguish between the SPL involvement in the dorsal visual pathway and dorsal attentional network.

Lastly, our result may also reflect a reduction in working memory capacity in the PD-MCI group since working memory demands are increased when the first target must be remembered in enough detail to mentally rotate. By definition, working memory manages the encoding, maintenance and use of mental representations. Our peak SPL coordinate (21, -58, 61) was almost identical to the coordinate (24, -57, 60) reported by Rahm et al. (2014) to be implicated in the visual working memory task performance which did not involve mental rotation but was related to memory load. This result provides additional evidence that SPL has more general role in attention/executive control since we believe that working memory and selective attention/executive control are overlapping constructs with common neural substrates that are impossible to separate based on fMRI data. Notably, working memory capacity deficits have been reported already in early PD stages and deteriorate with the disease progression (Cools et al., 2008; Litvan et al. et al., 2012; Fallon et al., 2015).

Functional imaging abnormalities in posterior cortical regions have been related to cognitive decline in PD (Bohnen et al., 2003; Garcia-Garcia et al., 2012; Hosokai et al., 2009; Huang et al., 2008; Huang et al., 2007; Liepelt et al., 2009; Pappata et al., 2011), progression of cognitive deficits (Olde Dubbelink et al., 2014); and changes in intersecting pentagon drawing, i.e. a task associated with posterior cortical functions was a predictor of PD-dementia (Williams-Gray et al., 2009; Williams-Gray, Foltynie, Brayne, Robbins, & Barker, 2007). In our study, the magnitude of activation in SPL differentiated PD-NC from PD-MCI with a high sensitivity and specificity while the two groups of PD patients did not significantly differ in task accuracy. Therefore, aberrant activation in this area seems to precede behavioural changes in this patient group.

5. Conclusions

Results of fMRI analysis using a visual object matching paradigm with conventional vs. unconventional view contrasts revealed that impaired task performance in both AD-MCI and PD-MCI groups was associated with decreased engagement of domain-general frontoparietal networks involved in working memory tasks and in the top-down control of visual processing required for successful implementation of OMVP. By contrast, recruitment of domain-specific visual areas underlying bottom-up processing remained relatively preserved. Differences between PD-MCI and PD-NC were found particularly in the right SPL, a critical component of the dorsal attention network, and ROC analysis of fMRI data within this region distinguished PD-MCI from PD-NC with a high sensitivity and specificity. The fMRI contrast in this region was associated with our behavioural task accuracy in the PD-MCI group. Therefore, aberrant SPL activation may serve as an early imaging biomarker of incipient PD-MCI. Further longitudinal studies are needed to determine the utility of our fMRI paradigm as a preclinical marker of mild cognitive impairment and dementia in PD.

Funding

This project has received funding from the European Union's Horizon 2020 research and innovation programme under the Marie Skłodowska-Curie grant agreement No 734718 (CoBeN), and it was supported by the project CEITEC 2020 [LQ1601] by the Ministry of Education, Youth and Sports of the Czech Republic, and by the EU Joint Programming initiative within Neurodegenerative Diseases, funded by the Norwegian Strategic Research Council (APGeM—Preclinical genotype-phenotype predictors of Alzheimer's disease and other dementias, grant agreement number 3056-00001).

Disclaimer:

The article reflects only the author's view and the Research Executive Agency (REA) is not responsible for any use that may be made of the information it contains.

Disclosure statement

The authors do not have any financial, personal or other relationship with other people or organizations that could inappropriately influence or bias their work. There are no actual or potential conflicts of interests. None of the author's institutions have contracts relating this research through which it or any organization may stand to gain financially now or in the future. There are no other agreements of authors or their institutions that could be seen as involving a financial interest in this work.

Acknowledgements

The authors acknowledge and deeply thank our participants for their commitment to our research project. We acknowledge also the core facility MAFIL of CEITEC supported by the MEYS CR (LM2015062 Czech-BioImaging).

References

- Aarsland, D., K. Bronnick, C. Williams-Gray, D. Weintraub, K. Marder, J. Kulisevsky, D. Burn, P. Barone, J. Pagonabarraga, L. Allcock, G. Santangelo, T. Foltynie, C. Janvin, J. P. Larsen, R. A. Barker & M. Emre (2010) Mild cognitive impairment in Parkinson disease: a multicenter pooled analysis. *Neurology*, 75, 1062-9.
- Albert, M. S., S. T. DeKosky, D. Dickson, B. Dubois, H. H. Feldman, N. C. Fox, A. Gamst, D. M. Holtzman, W. J. Jagust, R. C. Petersen, P. J. Snyder, M. C. Carrillo, B. Thies & C. H. Phelps (2011) The diagnosis of mild cognitive impairment due to Alzheimer's disease: recommendations from the National Institute on Aging-Alzheimer's Association workgroups on diagnostic guidelines for Alzheimer's disease. *Alzheimers Dement*, 7, 270-9.
- Altmann, C. F., W. Grodd, Z. Kourtzi, H. H. Bulthoff & H. O. Karnath (2005) Similar cortical correlates underlie visual object identification and orientation judgment. *Neuropsychologia*, 43, 2101-2108.

- Amboni, M., A. Tessitore, F. Esposito, G. Santangelo, M. Picillo, C. Vitale, A. Giordano, R. Erro, R. de Micco, D. Corbo, G. Tedeschi & P. Barone (2015) Resting-state functional connectivity associated with mild cognitive impairment in Parkinson's disease. *J Neurol*, 262, 425-34.
- Baggio, H. C., B. Segura, R. Sala-Llonch, M. J. Marti, F. Valldeoriola, Y. Compta, E. Tolosa & C. Junque (2015) Cognitive impairment and resting-state network connectivity in Parkinson's disease. *Hum Brain Mapp*, 36, 199-212.
- Ballinger, E. C., M. Ananth, D. A. Talmage & L. W. Role (2016) Basal Forebrain Cholinergic Circuits and Signaling in Cognition and Cognitive Decline. *Neuron*, 91, 1199-218.
- Bartoš, A., P. Martínek, O. Bezdíček, A. Buček & D. Řířová (2008) Dotazník funkčního stavu FAQ-CZ – česká verze pro zhodnocení každodenních aktivit pacientů s Alzheimerovou nemocí. *Psychiatrie pro praxi* 1, 31–34
- Berankova D, J. E., Mrackova M, Eliasova I, Kostalova M, Skutilova S, Rektorova I., 2015. Addenbrooke's Cognitive Examination and Individual Domain Cut-Off Scores for Discriminating between Different Cognitive Subtypes of Parkinson's Disease. 1-7. Hindawi Publishing Corporation Parkinson's Disease.
- Bohnen, N. I., R. L. Albin, M. L. Muller, M. Petrou, V. Kotagal, R. A. Koeppe, P. J. Scott & K. A. Frey (2015) Frequency of cholinergic and caudate nucleus dopaminergic deficits across the predemented cognitive spectrum of Parkinson disease and evidence of interaction effects. *JAMA Neurol*, 72, 194-200.
- Bohnen, N. I., D. I. Kaufer, L. S. Ivanco & et al. (2003) Cortical cholinergic function is more severely affected in parkinsonian dementia than in alzheimer disease: An in vivo positron emission tomographic study. *Archives of Neurology*, 60, 1745-1748.
- Braak, H. & E. Braak (1996) Development of Alzheimer-related neurofibrillary changes in the neocortex inversely recapitulates cortical myelogenesis. *Acta Neuropathol*, 92, 197-201.
- Buckner, R. L., A. Z. Snyder, B. J. Shannon, G. LaRossa, R. Sachs, A. F. Fotenos, Y. I. Sheline, W. E. Klunk, C. A. Mathis, J. C. Morris & M. A. Mintun (2005) Molecular, structural, and functional characterization of Alzheimer's disease: evidence for a relationship between default activity, amyloid, and memory. *J Neurosci*, 25, 7709-17.
- Cohen, L., S. Dehaene, F. Vinckier, A. Jobert & A. Montavont (2008) Reading normal and degraded words: contribution of the dorsal and ventral visual pathways. *Neuroimage*, 40, 353-66.
- Cools, R., S. E. Gibbs, A. Miyakawa, W. Jagust & M. D'Esposito (2008) Working memory capacity predicts dopamine synthesis capacity in the human striatum. *Journal of Neuroscience*, 28, 1208-1212.
- Corbetta, M. & G. L. Shulman (2002) Control of goal-directed and stimulus-driven attention in the brain. *Nat Rev Neurosci*, 3, 201-15.
- Creem, S. H. & D. R. Proffitt (2001) Defining the cortical visual systems: "what", "where", and "how". *Acta Psychol (Amst)*, 107, 43-68.
- Dickerson, B. C., A. Bakkour, D. H. Salat, E. Feczko, J. Pacheco, D. N. Greve, F. Grodstein, C. I. Wright, D. Blacker, H. D. Rosas, R. A. Sperling, A. Atri, J. H. Growdon, B. T. Hyman, J. C. Morris, B. Fischl & R. L. Buckner (2009) The cortical signature of Alzheimer's disease: regionally specific cortical thinning relates to symptom severity in very mild to mild AD dementia and is detectable in asymptomatic amyloid-positive individuals. *Cereb Cortex*, 19, 497-510.
- Fahn S, E. R., members of the UPDRS Development Committee. 1987. Unified Parkinson's disease rating scale. In *Recent developments in Parkinson's disease* ed. M. C. Fahn S, Goldstein M, Calne DB (eds), pp 53–163. New York: MacMillan.
- Fallon, S. J., K. Smulders, R. A. Esselink, B. P. van de Warrenburg, B. R. Bloem & R. Cools (2015) Differential optimal dopamine levels for set-shifting and working memory in Parkinson's disease. *Neuropsychologia*, 77, 42-51.
- Fedorenko, E., J. Duncan & N. Kanwisher (2013) Broad domain generality in focal regions of frontal and parietal cortex. *Proceedings of the National Academy of Sciences*, 110, 16616-16621.

- Fera, F., G. Nicoletti, A. Cerasa, N. Romeo, O. Gallo, M. C. Gioia, G. Arabia, P. Pugliese, M. Zappia & A. Quattrone (2007) Dopaminergic modulation of cognitive interference after pharmacological washout in Parkinson's disease. *Brain Res Bull*, 74, 75-83.
- Francis, P. T., A. M. Palmer, M. Snape & G. K. Wilcock (1999) The cholinergic hypothesis of Alzheimer's disease: a review of progress. *J Neurol Neurosurg Psychiatry*, 66, 137-47.
- Ganis, G., H. E. Schendan & S. M. Kosslyn (2007) Neuroimaging evidence for object model verification theory: Role of prefrontal control in visual object categorization. *Neuroimage*, 34, 384-398.
- Gao, W. & W. Lin (2012) Frontal parietal control network regulates the anti-correlated default and dorsal attention networks. *Hum Brain Mapp*, 33, 192-202.
- Garcia-Garcia, D., P. Clavero, C. Gasca Salas, I. Lamet, J. Arbizu, R. Gonzalez-Redondo, J. A. Obeso & M. C. Rodriguez-Oroz (2012) Posterior parietooccipital hypometabolism may differentiate mild cognitive impairment from dementia in Parkinson's disease. *Eur J Nucl Med Mol Imaging*, 39, 1767-77.
- Gengsheng, Q. & L. Hotilovac (2008) Comparison of non-parametric confidence intervals for the area under the ROC curve of a continuous-scale diagnostic test. *Stat Methods Med Res*, 17, 207-21.
- Gogos, A., M. Gavrilescu, S. Davison, K. Searle, J. Adams, S. L. Rossell, R. Bell, S. R. Davis & G. F. Egan (2010) Greater superior than inferior parietal lobule activation with increasing rotation angle during mental rotation: An fMRI study. *Neuropsychologia*, 48, 529-535.
- Goodale, M. A. & A. D. Milner (1992) Separate visual pathways for perception and action. *Trends Neurosci*, 15, 20-5.
- Gratwicke, J., M. Jahanshahi & T. Foltynie (2015) Parkinson's disease dementia: a neural networks perspective. *Brain*, 138, 1454-1476.
- Grill-Spector, K., Z. Kourtzi & N. Kanwisher (2001) The lateral occipital complex and its role in object recognition. *Vision Research*, 41, 1409-1422.
- Hanley, J. A. & B. J. McNeil (1982) The meaning and use of the area under a receiver operating characteristic (ROC) curve. *Radiology*, 143, 29-36.
- Hilker, R., K. Schweitzer, S. Coburger, M. Ghaemi, S. Weisenbach, A. H. Jacobs, J. Rudolf, K. Herholz & W. D. Heiss (2005) Nonlinear progression of Parkinson disease as determined by serial positron emission tomographic imaging of striatal fluorodopa F 18 activity. *Arch Neurol*, 62, 378-82.
- Hosokai, Y., Y. Nishio, K. Hirayama, A. Takeda, T. Ishioka, Y. Sawada, K. Suzuki, Y. Itoyama, S. Takahashi, H. Fukuda & E. Mori (2009) Distinct patterns of regional cerebral glucose metabolism in Parkinson's disease with and without mild cognitive impairment. *Mov Disord*, 24, 854-62.
- Huang, C., P. Mattis, K. Perrine, N. Brown, V. Dhawan & D. Eidelberg (2008) Metabolic abnormalities associated with mild cognitive impairment in Parkinson disease. *Neurology*, 70, 1470-1477.
- Huang, C., C. Tang, A. Feigin, M. Lesser, Y. Ma, M. Pourfar, V. Dhawan & D. Eidelberg (2007) Changes in network activity with the progression of Parkinson's disease. *Brain*, 130, 1834-46.
- Ito, K., A. Nagano-Saito, T. Kato, Y. Arahata, A. Nakamura, Y. Kawasumi, K. Hatano, Y. Abe, T. Yamada, T. Kachi & D. J. Brookes (2002) Striatal and extrastriatal dysfunction in Parkinson's disease with dementia: a 6- F-18 fluoro-L-dopa PET study (vol 125, pg 1358, 2002). *Brain*, 125, 2144-2144.
- Jacobs, H. I., M. P. Van Boxtel, J. Jolles, F. R. Verhey & H. B. Uylings (2012) Parietal cortex matters in Alzheimer's disease: an overview of structural, functional and metabolic findings. *Neurosci Biobehav Rev*, 36, 297-309.
- Jacobs, H. I. L., E. H. B. M. Gronenschild, E. A. T. Evers, I. H. G. B. Ramakers, P. A. M. Hofman, W. H. Backes, J. Jolles, F. R. J. Verhey & M. P. J. Van Boxtel (2015) Visuospatial processing in early Alzheimer's disease: A multimodal neuroimaging study. *Cortex*, 64, 394-406.
- Kosslyn, S. M., N. M. Alpert, W. L. Thompson, C. F. Chabris, S. L. Rauch & A. K. Anderson (1994) Identifying objects seen from different viewpoints. A PET investigation. *Brain*, 117 (Pt 5), 1055-71.

- Kövari, E., G. Gold, F. R. Herrmann, A. Canuto, P. R. Hof, C. Bouras & P. Giannakopoulos (2003) Lewy body densities in the entorhinal and anterior cingulate cortex predict cognitive deficits in Parkinson's disease. *Acta Neuropathologica*, 106, 83-88.
- Liepert, I., M. Reimold, W. Maetzler, J. Godau, G. Reischl, A. Gaenslen, H. Herbst & D. Berg (2009) Cortical hypometabolism assessed by a metabolic ratio in Parkinson's disease primarily reflects cognitive deterioration—[18F]FDG-PET. *Movement Disorders*, 24, 1504-1511.
- Litvan, I., J. G. Goldman, A. I. Troster, B. A. Schmand, D. Weintraub, R. C. Petersen, B. Mollenhauer, C. H. Adler, K. Marder, C. H. Williams-Gray, D. Aarsland, J. Kulisevsky, M. C. Rodriguez-Oroz, D. J. Burn, R. A. Barker & M. Emre (2012) Diagnostic criteria for mild cognitive impairment in Parkinson's disease: Movement Disorder Society Task Force guidelines. *Mov Disord*, 27, 349-56.
- Lowe, D. G. (2000) Towards a computational model for object recognition in IT cortex. *Biologically Motivated Computer Vision, Proceeding*, 1811, 20-31.
- McKee, A. C., R. Au, H. J. Cabral, N. W. Kowall, S. Seshadri, C. A. Kubilus, J. Drake & P. A. Wolf (2006) Visual association pathology in preclinical Alzheimer disease. *J Neuropathol Exp Neurol*, 65, 621-30.
- Nee, D. E., J. W. Brown, M. K. Askren, M. G. Berman, E. Demiralp, A. Krawitz & J. Jonides (2013) A meta-analysis of executive components of working memory. *Cereb Cortex*, 23, 264-82.
- Neufang, S., A. Akhrif, V. Riedl, H. Forstl, A. Kurz, C. Zimmer, C. Sorg & A. M. Wohlschläger (2011) Disconnection of frontal and parietal areas contributes to impaired attention in very early Alzheimer's disease. *J Alzheimers Dis*, 25, 309-21.
- Niendam, T. A., A. R. Laird, K. L. Ray, Y. M. Dean, D. C. Glahn & C. S. Carter (2012) Meta-analytic evidence for a superordinate cognitive control network subserving diverse executive functions. *Cogn Affect Behav Neurosci*, 12, 241-68.
- Nombela, C., J. B. Rowe, S. E. Winder-Rhodes, A. Hampshire, A. M. Owen, D. P. Breen, G. W. Duncan, T. K. Khoo, A. J. Yarnall, M. J. Firbank, P. F. Chinnery, T. W. Robbins, J. T. O'Brien, D. J. Brooks, D. J. Burn & R. A. Barker (2014) Genetic impact on cognition and brain function in newly diagnosed Parkinson's disease: ICICLE-PD study. *Brain*, 137, 2743-58.
- Olde Dubbelink, K. T., M. M. Schoonheim, J. B. Deijen, J. W. Twisk, F. Barkhof & H. W. Berendse (2014) Functional connectivity and cognitive decline over 3 years in Parkinson disease. *Neurology*, 83, 2046-53.
- Pappata, S., G. Santangelo, D. Aarsland, C. Vicidomini, K. Longo, K. Bronnick, M. Amboni, R. Erro, C. Vitale, M. G. Caprio, M. T. Pellecchia, A. Brunetti, G. De Michele, M. Salvatore & P. Barone (2011) Mild cognitive impairment in drug-naïve patients with PD is associated with cerebral hypometabolism. *Neurology*, 77, 1357-62.
- Perez-Lloret, S. & F. J. Barrantes (2016) Deficits in cholinergic neurotransmission and their clinical correlates in Parkinson's disease. *Npj Parkinson's Disease*, 2, 16001.
- Petrou, M., K. A. Frey, M. R. Kilbourn, P. J. Scott, D. M. Raffel, N. I. Bohnen, M. L. Muller, R. L. Albin & R. A. Koeppe (2014) In vivo imaging of human cholinergic nerve terminals with (-)-5-(18)F-fluoroethoxybenzovesamicol: biodistribution, dosimetry, and tracer kinetic analyses. *J Nucl Med*, 55, 396-404.
- Possin, K. L. (2010) Visual spatial cognition in neurodegenerative disease. *Neurocase*, 16, 466-87.
- Possin, K. L., G. A. Kang, C. Guo, E. M. Fine, A. J. Trujillo, C. A. Racine, R. Wilhelm, E. T. Johnson, J. L. Witt, W. W. Seeley, B. L. Miller & J. H. Kramer (2013) Rivastigmine is Associated with Restoration of Left Frontal Brain Activity in Parkinson's Disease. *Movement disorders : official journal of the Movement Disorder Society*, 28, 1384-1390.
- Rahm, B., J. Kaiser, J. M. Unterrainer, J. Simon & C. Bledowski (2014) fMRI characterization of visual working memory recognition. *Neuroimage*, 90, 413-22.
- Redel, P., P. Bublak, C. Sorg, A. Kurz, H. Foerstl, H. J. Mueller, W. X. Schneider, R. Perneczky & K. Finke (2012) Deficits of spatial and task-related attentional selection in mild cognitive impairment and Alzheimer's disease. *Neurobiology of Aging*, 33.

- Rektorova, I., L. Krajcovicova, R. Marecek, M. Novakova & M. Mikl (2014) Default Mode Network Connectivity Patterns associated with Visual Processing at Different Stages of Parkinson's Disease. *Journal of Alzheimers Disease*, 42, S217-S228.
- Rombouts, S. A., F. Barkhof, C. S. Van Meel & P. Scheltens (2002) Alterations in brain activation during cholinergic enhancement with rivastigmine in Alzheimer's disease. *J Neurol Neurosurg Psychiatry*, 73, 665-71.
- Rosenberg-Katz, K., I. Maidan, Y. Jacob, N. Giladi, A. Mirelman & J. M. Hausdorff (2016) Alterations in conflict monitoring are related to functional connectivity in Parkinson's disease. *Cortex*, 82, 277-86.
- Saykin, A. J., H. A. Wishart, L. A. Rabin, L. A. Flashman, T. L. McHugh, A. C. Mamourian & R. B. Santulli (2004) Cholinergic enhancement of frontal lobe activity in mild cognitive impairment. *Brain*, 127, 1574-83.
- Schendan, H. E. & C. E. Stern (2007) Mental rotation and object categorization share a common network of prefrontal and dorsal and ventral regions of posterior cortex. *Neuroimage*, 35, 1264-1277.
- Schendan, H. E. & C. E. Stern (2008) Where vision meets memory: prefrontal-posterior networks for visual object constancy during categorization and recognition. *Cereb Cortex*, 18, 1695-711.
- Sorg, C., V. Riedel, M. Muhlau, V. D. Calhoun, T. Eichele, L. Laer, A. Drzezga, H. Forstl, A. Kurz, C. Zimmer & A. M. Wohlschlaeger (2007) Selective changes of resting-state networks in individuals at risk for Alzheimer's disease. *Proc Natl Acad Sci U S A*, 104, 18760-5.
- Spreng, R. N., W. D. Stevens, J. P. Chamberlain, A. W. Gilmore & D. L. Schacter (2010) Default network activity, coupled with the frontoparietal control network, supports goal-directed cognition. *Neuroimage*, 53, 303-17.
- Tommasi, G., M. Fiorio, J. Yelnik, P. Krack, F. Sala, E. Schmitt, V. Fraix, L. Bertolasi, J. F. Le Bas, G. K. Ricciardi, A. Fiaschi, J. Theeuwes, P. Pollak & L. Chelazzi (2015) Disentangling the Role of Cortico-Basal Ganglia Loops in Top-Down and Bottom-Up Visual Attention: An Investigation of Attention Deficits in Parkinson Disease. *J Cogn Neurosci*, 27, 1215-37.
- Turnbull, O. H. (1997) A double dissociation between knowledge of object identity and object orientation. *Neuropsychologia*, 35, 567-570.
- Uc, E. Y., M. Rizzo, S. W. Anderson, S. Qian, R. L. Rodnitzky & J. D. Dawson (2005) Visual dysfunction in Parkinson disease without dementia. *Neurology*, 65, 1907-1913.
- Ungerleider Leslie & M. Mortimer. 1982. Two cortical visual systems. In *Analysis of visual behavior* ed. M. A. G. D. J. Ingle, R. J. W. Mansfield. Cambridge, MA: MIT Press.
- Ungerleider, L. G. & J. V. Haxby (1994) 'What' and 'where' in the human brain. *Curr Opin Neurobiol*, 4, 157-65.
- Valyear, K. F., J. C. Culham, N. Sharif, D. Westwood & M. A. Goodale (2006) A double dissociation between sensitivity to changes in object identity and object orientation in the ventral and dorsal visual streams: A human fMRI study. *Neuropsychologia*, 44, 218-228.
- Vandenberghe, R., P. Molenberghs & C. R. Gillebert (2012) Spatial attention deficits in humans: the critical role of superior compared to inferior parietal lesions. *Neuropsychologia*, 50, 1092-103.
- Vincent, J. L., I. Kahn, A. Z. Snyder, M. E. Raichle & R. L. Buckner (2008) Evidence for a frontoparietal control system revealed by intrinsic functional connectivity. *J Neurophysiol*, 100, 3328-42.
- Ward, C. D. & W. R. Gibb (1990) Research diagnostic criteria for Parkinson's disease. *Adv Neurol*, 53, 245-9.
- Williams-Gray, C. H., J. R. Evans, A. Goris, T. Foltynie, M. Ban, T. W. Robbins, C. Brayne, B. S. Kolachana, D. R. Weinberger, S. J. Sawcer & R. A. Barker (2009) The distinct cognitive syndromes of Parkinson's disease: 5 year follow-up of the CamPaIGN cohort. *Brain*, 132, 2958-69.
- Williams-Gray, C. H., T. Foltynie, C. E. Brayne, T. W. Robbins & R. A. Barker (2007) Evolution of cognitive dysfunction in an incident Parkinson's disease cohort. *Brain*, 130, 1787-98.

- Yassa, M. A., G. Verduzco, C. Cristinzio & S. S. Bassett (2008) Altered fMRI activation during mental rotation in those at genetic risk for Alzheimer disease. *Neurology*, 70, 1898-1904.
- Yesavage, J. A. & J. I. Sheikh (1986) 9/Geriatric Depression Scale (GDS). *Clinical Gerontologist*, 5, 165-173.
- Zacks, J. M. (2008) Neuroimaging studies of mental rotation: a meta-analysis and review. *J Cogn Neurosci*, 20, 1-19.

Table 1 Demographic and clinical variables

	HC (n=55)	AD_MCI (n=21)	PD-NC (n=16)	PD_MCI (n=24)	p- value
Age in years \pm SD	66.7 \pm 7.3	69.8\pm7.4[*]	62.7\pm6.8[*]	65.1 \pm 10	0.04
Education in years \pm SD	15.4 \pm 2.5	14.4\pm2.6[*]	17.2\pm3.2^{*,‡}	14\pm3.1[‡]	0.01
Sex (% of male)	31[*]	43[*]	75[‡]	67[‡]	0.00
Levodopa daily equivalent dose (Tomlinson et al., 2010)	-	-	731.5 \pm 488.7	902.3 \pm 483.6	0.26
UPDRS III (Motor Examination)	-	-	16.8 \pm 9.1	17.7 \pm 8.8	0.82
MMSE	28.5\pm1.2[*]	27.0\pm1.4[‡]	28.5\pm1.1[*]	26.8\pm2.4[‡]	0.00
GDS	2.4 \pm 2.6	3.0 \pm 2.7	2.4 \pm 1.9	3.0 \pm 2.4	0.45
FAQ-CZ	98.5\pm2.6^{*,‡}	93.5\pm8.0[*]	97.6 \pm 2.3	93.4\pm9.4[‡]	0.00

Table 1 legends: UPDRS III – Unified Parkinson’s Disease Rating Scale III (motor examination) (Fahn S, 1987), MMSE – Mini Mental State Examination, GDS – Geriatric Depression Scale, FAQ-CZ – Functional Activities Questionnaire, percentage of self-sufficiency, SD – standard deviation. Significant between-groups differences (as revealed by post-hoc tests) are in bold marked with superscripts and showing that PD-MCI were younger than AD-MCI; PD-NC completed more years of education than AD-MCI and PD-MCI groups; PD groups had higher prevalence of males compared to non-PD groups; MMSE was

lower in MCI groups compared to non-MCI groups; FAQ-CZ was lower in both MCI groups compared to HC.

Table 2 Task accuracy of the relevant visual cognitive task conditions in all groups:

Task condition	HC	AD_MCI	PD	PD_MCI
Conventional view	90.5 ± 11.5	79.8 ± 27.0	88.1 ± 9.8	79.2 ± 19.8
Unconventional view	75.7 ± 12.7^{*,‡}	63.3 ± 19.1[*]	69.5 ± 11.6	63.3 ± 17.3[‡]
Control task	96.5 ± 10.8	83.8 ± 29.2	93.7 ± 10.5	90.8 ± 19.2

Table 2 legends: mean accuracy ± SD (accuracy was assessed as percentage of correct responses), maximum score = 100, i.e. the best task performance. Significant between-groups differences (as revealed by post-hoc tests) are in bold marked with superscripts and showing that both MCI groups differed from HC only in the unconventional view task condition.

Table 3a. Unconventional vs. conventional view task contrasts: second level analysis

HC vs. PD-NC vs. PD-MCI groups of subjects (ANOVA), p (FWE) < 0.05.

Area	K voxel	p (FWE-corr)	X	Y	Z
Anterior Cingulate Cortex	1516	0.000	3	20	28
Superior Parietal Lobule	301	0.007	21	-58	61

Table 3b. Unconventional vs. conventional view task contrasts: second level analysis

HC vs. AD-MCI vs. PD-MCI groups of subjects (ANOVA), p (FWE) < 0.05 .

Area	K voxel	p (FWE-corr)	X	y	z
Middle Frontal Gyrus	1046	0.000	39	38	22
Inferior Frontal Gyrus	1046	0.000	33	23	25

Highlights

We studied visual task-induced activations in PD, PD-MCI and AD-MCI groups

Object recognition in MCI groups was related to decreased frontoparietal involvement

Our results are consistent with defective top-down regulation of visual processing

Abnormal activation of SPL may serve as an early marker of cognitive impairment in PD

Figure 1. Visual matching task using conventional and unconventional views of object pairs and the control task




Figure legends:

Line 1: Conventional view task condition; the correct answer is YES (left button)

Line 2: Conventional view task condition; the correct answer is NO (right button)

Line 3: Unconventional view task condition; the correct answer is YES (left button)

Line 4: Unconventional view task condition; the correct answer is NO (right button)

Line 5: Control task condition (right button)

Line 6: Control task condition (left button)

Figure 2. Unconventional vs conventional view task contrast in the HC group, PD, PD-MCI and AD-MCI groups

First level within-group analyses; $p < 0.05$ (FWE corrected, cluster level)

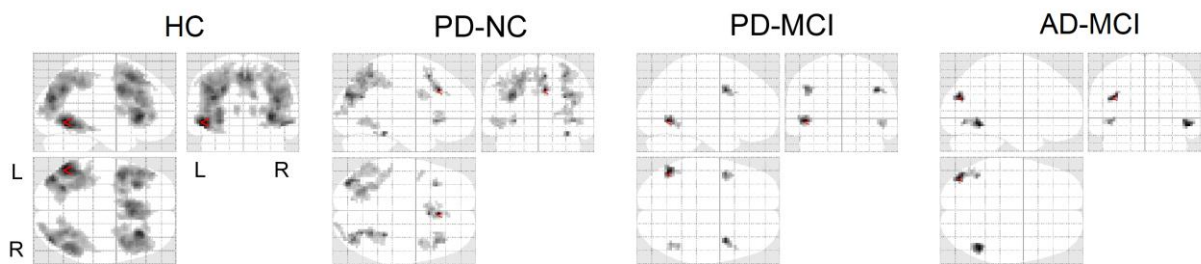


Figure 3. Unconventional vs conventional view task contrast: between-groups differences

Second level analyses: posthoc t-tests; $p < 0.05$ (FWE corrected, cluster level)

